ARMED FORCES INSTITUTE OF PATHOLOGY
Office of the Armed Forces Medical Examiner
1413 Research Blvd., Bldg. 102
Rockville, MD 20850
1-800-944-7912

AUTOPSY EXAMINATION REPORT

Name: Mowhosh, Abid
SSAN: NA
Date of Birth: 1947
Date/Time of Death: (b)(6) 2003
Date/Time of Autopsy: 2 Dec 2003

Autopsy No.: MI (b)(6)
AFIP No.: (b)(6)
Rank: (b)(6)
Place of Death: Al Qaim, Iraq
Place of Autopsy: BIAP Mortuary, Baghdad, Iraq

Date of Report: 18 Dec 2003

Circumstances of Death: This Iraqi (b)(6) died while in U.S. custody. The details surrounding the circumstances at the time of death are classified.

Authorization for Autopsy: Armed Forces Medical Examiner, per 10 U.S. Code 1471

Identification: Visual by 3rd Armored Cavalry Regiment, postmortem fingerprint and DNA obtained

CAUSE OF DEATH: Asphyxia due to smothering and chest compression

MANNER OF DEATH: Homicide

ACLU Detainee DeathII ARMY MEDCOM 1

FINAL AUTOPSY DIAGNOSES:

I. History of smothering and chest and abdominal compression

II. Blunt force trauma
- A. Contusions and abrasions of the skin and soft tissue of the chest and abdomen with patterned contusions
  - 1. Fractures of left ribs 3-7
- B. Extensive contusions and abrasions of the extremities with patterned contusions
- C. Minor contusion of the scalp

III. Cardiomyopathy (650 grams)
- A. Left ventricle hypertrophy (1.7cm)
  - 1. Myocyte hypertrophy and interstitial and perivascular fibrosis
- B. Mild atherosclerosis of the aorta
- C. Pulmonary edema (combined weight = 1350 grams)

IV. Status post cholecystectomy
- A. Perihepatic and pericolonic adhesions

V. Hepatic steatosis (fatty change), microscopic

VI. Hepattis B positive (DNA)

VII. Pleural and pulmonary adhesions

VIII. Perisplenic adhesions

IX. Nodular prostate

X. Early decomposition

XI. No displaced fractures or radiopaque projectiles on radiographs

XII. Toxicology negative

ACLU Detainee DeathII ARMY MEDCOM 2

EXTERNAL EXAMINATION

The body is that of a well-developed, well-nourished appearing, obese, 71 1/2 inch tall, 250 pounds minimum (estimated) male whose appearance is consistent with the reported age of 56 years. Lividity is posterior and purple. There is facial suffusion and congestion of the conjunctival vessels but no petechiae of the eyes, face, or oral mucosa. Rigor is not apparent. There is early decomposition consisting of vascular marbling of the anterior chest.

The scalp is covered with gray-brown hair measuring 1 ¾ inch in length and in a normal distribution. There is a brown beard and mustache. The irides are brown and slightly obscured by corneal clouding. The ears and external auditory canals are unremarkable. The nares are patent and the lips are atraumatic. The nose and maxillae are palpably stable. The teeth appear natural and adequate in repair. There are no injuries of the oral cavity.

The neck is straight, and the trachea is midline and mobile. The chest is symmetric. The abdomen is protuberant. The genitalia are those of a normal adult male. The testes are descended and free of masses. Pubic hair is present in a normal distribution. The buttocks and anus are developmentally unremarkable.

The upper and lower extremities are symmetric and without clubbing or edema. Flexicuff wrist ties encircle each wrist but there are no associated abrasions or contusions.

Identifying marks and scars include an oblique 8 x ¼ inch scar and 2 adjacent oblique scars measuring ¾ x ½ inch each on the right upper quadrant of the abdomen (cholecystectomy). On the skin of the right patella is a 1 ¼ inch linear scar and on the skin of the left patella is a 1 ¼ inch linear scar. On the posterior right shoulder and arm are a 4 x 2 inch scar, a 1 ½ x 1 ½ inch scar, a 2 ¾ inch linear scar, a 3 ½ inch linear scar, and a 1 x ¼ inch scar.

Encircling the right wrist is a white plastic identification band with (b)(6)

CLOTHING AND PERSONAL EFFECTS

The following clothing items and personal effects accompany the body at the time of autopsy:

- Long black shirt
- White undershirt
- Tan boxer style underpants

MEDICAL INTERVENTION

- Intravenous puncture marks in the right groin and right antecubital fossa
- A 1 ½ x 7/8 inch dried orange abrasion overlying the sternum (CPR artifact)

ACLU Detainee DeathII ARMY MEDCOM 3

RADIOGRAPHS

A complete set of postmortem radiographs is obtained and demonstrates the following:

- No displaced fractures
- No radiopaque foreign objects (bullets or shrapnel)

EVIDENCE OF INJURY

The ordering of the following injuries is for descriptive purposes only, and is not intended to imply order of infliction or relative severity. All wound pathways are given relative to standard anatomic position.

DESCRIPTION OF BLUNT FORCE INJURIES:

Head and Neck:
On the right parieto-occipital scalp is a 1 ½ x 1 ¼ inch purple contusion without fracture of the underlying skull. There is a ½ x ¼ inch area of discoloration of the superior belly of the right omohyoid muscle without injury of the remaining anterior strap muscles. Dissection of the posterior neck and spinal cord is free of injury.

Chest and Abdomen:
On the anterior right side of the chest superior to the nipple is a 5 x 1 ¾ inch crescentic purple contusion and on the left side of the anterior chest is a 2 ¾ x 1 ¼ inch purple contusion. On the midline of the anterior abdominal wall are a 5 x 3 ½ inch purple contusion, a triangular 5 ½ x 2 inch purple contusion, and a triangular 6 ½ x 2 inch purple contusion. On the left lower quadrant of the abdomen is a 4 x 3 ¼ inch purple contusion. Adjacent to and admixed with the above contusions are numerous circular to ovoid red-purple contusions ranging from ¼ to ½ inch. On the midline of the upper back is a 3 ¾ x 2 inch purple contusion. On the left costovertebral angle is a 7 ½ x 3 inch purple contusion. On the postero-lateral left rib cage is a faint 6 x 3 ½ inch purple contusion. On the right costovertebral angle and lower back are a 4 ½ x 2 inch purple contusion and a 7 ¾ x 1 ½ inch purple contusion.

Injuries within the chest include non-displaced fractures of the anterior aspect of the 5th-7th ribs on the left side and 3rd-6th ribs on the postero-lateral left side. Dissection of the parietal pleura from the rib cage reveals hemorrhage surrounding these fractures. There are no injuries of the lungs or remaining organs of the chest and abdominal cavities. Dissection of the skin of the back reveals scattered ¼ - ½ inch purple contusions of the soft tissue.

Pelvis and Buttocks:
On the right buttock and extending onto the anterior right hip is an irregularly shaped 13 ½ x 8 inch dark purple contusion with hemorrhage of the underlying subcutaneous tissue but without contusion or fracture of the underlying musculoskeletal system. Adjacent to this contusion is a patterned contusion consisting of two parallel oblique purple contusions measuring 3 ¾ x 1 inch and 4 x 1 ¾ inch with a ½ inch area of clearing

ACLU Detainee DeathII ARMY MEDCOM 4

between these contusions. On the left buttock and extending onto the posterior thigh are an irregularly shaped 7 ½ x 4 ¾ inch purple contusion and two oblique parallel purple contusions measuring 5 ½ inches and 6 ½ inches.

Lower Extremities:
On the anterior right thigh is an oblique 9 x 6 inch red-purple contusion. On the mid anterior right thigh are two parallel purple contusions occupying an area 6 x 3 inches with a 3/8-1/2 inch are of central clearing. Adjacent to these contusions are multiple pinpoint red abrasions. On the skin overlying the right patella is a 2 ½ x 1 ½ inch purple contusion. On the right anterior shin is a 4 x 3 inch purple contusion. On the skin overlying the right lateral malleolus is a 5 ½ x 2 ¼ inch purple contusion and on the skin overlying the right medial malleolus is an 8 ¼ x 4 inch purple contusion. On the plantar surface of the right foot is a 2 x 1 ¼ inch purple contusion. In the right popliteal fossa is a 4 x 4 ½ inch purple contusion.

On the left inguinal area is a 1 ½ x 2 ¼ inch purple contusion. On the anterior left thigh are 2 purple contusions measuring 4 ¼ x 3 ½ inches and ¾ x ½ inch, respectively. On the anterior and lateral left thigh is a patterned contusion consisting of three parallel oblique purple contusions occupying an area 6 x 4 inches with ½ inch areas of clearing between contusions. On the skin overlying the left patella and anterior shin is a patterned contusion consisting of two parallel, horizontal purple contusions occupying an area 6 x 4 inches with ½ inch area of clearing between contusions. On the anterior left shin is a patterned contusion occupying an area 6 x 4 ¾ inches and consisting of an irregularly shaped contusion within which are two parallel purple contusions with a 3/16 inch area of clearing. On the medial left shin is a ¾ inch purple contusion. On the skin overlying the left medial malleolus is a 3 x 2 inch purple contusion. On the posterior left thigh is a 5 x 5 ½ inch purple contusion. On the left calf is an oblique 10 x 2 ¾ inch purple contusion with a ½ inch area of central clearing.

Upper Extremities:
On the anterior and posterior left arm, elbow, and forearm is a 13 ½ x 9 ¼ inch area of diffuse purple contusion without an apparent pattern. There is no injury of the underlying bones. On the anterior left shoulder is a 2 ¾ x 1 ¼ inch purple contusion. On the anterior right shoulder is a 3 ½ x ¾ inch purple contusion. On the posterior right arm is a 2 ½ x 2 inch purple contusion. On the posterior right elbow is a 10 x 9 inch purple contusion without injury of the underlying bones. There is no significant injury of either hand or wrist.

INTERNAL EXAMINATION

HEAD:
The galeal and subgaleal soft tissues of the scalp have the noted minor contusion. The calvarium is intact, as is the dura mater beneath it. Clear cerebrospinal fluid surrounds the 1250 gm brain, which has unremarkable gyri and sulci. Coronal sections demonstrate

ACLU Detainee DeathII ARMY MEDCOM 5

sharp demarcation between white and grey matter, without hemorrhage or contusive injury. The ventricles are of normal size. The basal ganglia, brainstem, cerebellum, and arterial systems are free of injury or other abnormalities. There are no skull fractures. The atlanto-occipital joint is stable.

NECK:
The anterior strap muscles of the neck are homogenous and red-brown, without hemorrhage. There is a focal area of discoloration of the superior belly of the right omohyoid muscle. The thyroid cartilage and hyoid are intact. The larynx is lined by intact white mucosa. The thyroid is symmetric and red-brown, without cystic or nodular change. The tongue is free of bite marks, hemorrhage, or other injuries.

Incision and dissection of the posterior neck demonstrates no deep paracervical muscular injury and no cervical spine fractures or ligament injury. Sections of the cervical spinal cord are unremarkable.

BODY CAVITIES:
There are the noted rib fractures. No excess fluid is in the pleural, pericardial, or peritoneal cavities. The organs occupy their usual anatomic positions with surgical absence of the gallbladder and perihepatic adhesions. There are bilateral fibrous pleural, perisplenic, and pericolonic adhesions.

RESPIRATORY SYSTEM:
The right and left lungs weigh 650 and 700 gm, respectively. The external surfaces are deep red-purple and have the noted adhesions. The pulmonary parenchyma is diffusely congested and edematous. No mass lesions or areas of consolidation are present.

CARDIOVASCULAR SYSTEM:
The 650 gm heart is contained in an intact pericardial sac. The epicardial surface is smooth, with extensive fat investment. The coronary arteries are present in a normal distribution, with a right-dominant pattern. Cross sections of the vessels show no significant atherosclerosis. The myocardium is homogenous, red-brown, and firm. The valve leaflets are thin and mobile. The walls of the left and right ventricles are 1.7 and 0.6-cm thick, respectively. The endocardium is smooth and glistening. The aorta gives rise to three intact and patent arch vessels. The renal and mesenteric vessels are unremarkable.

LIVER & BILIARY SYSTEM:
The 1900 gm liver has an intact capsule and a sharp anterior border. The parenchyma is tan-brown and congested, with the usual lobular architecture. No mass lesions or other abnormalities are seen. The gallbladder is surgically absent.

SPLEEN:
The 275 gm spleen has the noted perisplenic adhesions. The parenchyma is maroon and congested, with distinct Malpighian corpuscles.

ACLU Detainee DeathII ARMY MEDCOM 6

PANCREAS:
The pancreas is firm and yellow-tan, with the usual lobular architecture. No mass lesions or other abnormalities are seen.

ADRENALS:
The right and left adrenal glands are symmetric but autolysed. No masses or areas of hemorrhage are identified.

GENITOURINARY SYSTEM:
The right and left kidneys weigh 180 gm each. The external surfaces are intact and smooth. The cut surfaces are red-tan and congested, with uniformly thick cortices and sharp corticomedullary junctions. The pelves are unremarkable and the ureters are normal in course and caliber. White bladder mucosa overlies an intact bladder wall. The bladder is empty. The prostate is normal in size, with lobular, yellow-tan parenchyma and nodular. The seminal vesicles are unremarkable. The testes are free of mass lesions, contusions, or other abnormalities.

GASTROINTESTINAL TRACT:
The esophagus is intact and lined by smooth, grey-white mucosa. The stomach contains approximately 30 ml of brown liquid. The gastric wall is intact. The duodenum, loops of small bowel, and colon are unremarkable. The appendix is present and unremarkable.

ADDITIONAL PROCEDURES

- Documentary photographs are taken by TSGT (b)(6)
- Special Agent (b)(6) of Army Criminal Investigative Division (CID) attended the autopsy
- Specimens retained for toxicologic testing and/or DNA identification are: blood, spleen, liver, lung, kidney, brain, gastric, and psoas
- The dissected organs are forwarded with body
- Personal effects are released to the appropriate mortuary operations representatives

MICROSCOPIC EXAMINATION

Heart: Sections show mild – moderate myocyte hypertrophy, perivascular and interstitial fibrosis, and fatty infiltration of the right ventricle. Postmortem overgrowth of bacteria without an inflammatory response is noted.

Lungs: Sections show intra-alveolar edema fluid, perivasuclar anthracosis, congestion, and postmortem overgrowth of bacteria without an inflammatory response. No polarizable foreign material is identified.

Kidney: Section shows vascular congestion and autolysis. No polarizable foreign material is identified.

Liver: Sections show moderate predominantly macrovesicular steatosis, mild periportal fibrosis, and no significant inflammation.

ACLU Detainee DeathII ARMY MEDCOM 7

Brain: Section shows no significant pathologic abnormality.

Right omohyoid muscle: Section shows no significant pathologic abnormality.

Contusion of the right buttock: Sections shows extravasation of erythrocytes without a significant inflammatory response and no significant hemosiderin deposition by H and E stain.

SEROLOGY

Postmortem serologic testing for antibodies to human immunodeficiency virus (HIV) and hepatitis C virus were non-reactive (negative).

Spleen was positive for hepatitis B DNA by PCR.

TOXICOLOGY

Toxicologic analysis of blood and liver was negative for carbon monoxide, cyanide, ethanol (alcohol), and illicit substances (drugs).

OPINION

This 56 year-old Iraqi detainee died of asphyxia due to smothering and chest compression. Significant findings of the autopsy included rib fractures and numerous contusions (bruises), some of which were patterned due to impacts with a blunt object(s). Another finding of the autopsy was an enlarged heart, the etiology of which is uncertain. Other findings included a fatty liver, which can be seen most commonly with obesity or alcohol abuse. The spleen was positive for hepatitis B DNA by polymerase chain reaction (PCR). There were scars in the chest cavity most likely due to an old infection. Scars were noted in the abdominal cavity due to prior surgical removal of the gallbladder.

Although an enlarged heart may result in sudden death, the history surrounding the death along with patterned contusions and broken ribs support a traumatic cause of death and therefore the manner of death is best classified as homicide.

(b)(6)

(b)(6) Medical Examiner

ACLU Detainee DeathII ARMY MEDCOM 8

CERTIFICATE OF DEATH *(OVERSEAS)*
Acte de décès *(D'Outre-Mer)*

NAME OF DECEASED *(Last, First, Middle)* Nom du décédé (Nom et prénoms)	GRADE Grade	BRANCH OF SERVICE Arme	SOCIAL SECURITY NUMBER Numéro de l'Assurance Sociale
BTB Mowhosh, Abid	MG		

ORGANIZATION Organisation	NATION *(e.g., United States)* Pays	DATE OF BIRTH Date de naissance	SEX Sexe
Detainee in Iraq	Iraq		☑ MALE Masculin ☐ FEMALE Féminin

RACE Race	MARITAL STATUS État Civil	RELIGION Culte
☒ CAUCASOID Caucasique	☐ SINGLE Célibataire	☐ DIVORCED Divorcé
☐ NEGROID Negroide	☐ MARRIED Marié	☐ SEPARATED Séparé
☐ OTHER (Specify) Autre (Spécifier)	☐ WIDOWED Veuf	☐ PROTESTANT Protestant ☐ CATHOLIC Catholique ☐ JEWISH Juif ☐ OTHER (Specify) Autre (Spécifier)

NAME OF NEXT OF KIN Nom du plus proche parent	RELATIONSHIP TO DECEASED Parenté du décédé avec le susdit
STREET ADDRESS Domicile à (Rue)	CITY OR TOWN AND STATE *(Include ZIP Code)* Ville (Code postal compris)

MEDICAL STATEMENT Déclaration médicale

CAUSE OF DEATH *(Enter only once cause per line)* Cause du décès (N'indiquer qu'une cause par ligne)		INTERVAL BETWEEN ONSET AND DEATH Intervalle entre l'attaque et le décès
DISEASE OR CONDITION DIRECTLY LEADING TO DEATH[1] Maladie ou condition directement responsable de la mort[1]	Asphyxia due to smothering and chest compression	
ANTECEDENT CAUSES Symptômes précurseurs de la mort. — MORBID CONDITION, IF ANY, LEADING TO PRIMARY CAUSE Condition morbide, s'il y a lieu, menant à la cause primaire		
ANTECEDENT CAUSES Symptômes précurseurs de la mort. — UNDERLYING CAUSE, IF ANY, GIVING RISE TO PRIMARY CAUSE Raison fondamentale, s'il y a lieu, ayant suscité la cause primaire		
OTHER SIGNIFICANT CONDITIONS[2] Autres conditions significatives[2]		

MODE OF DEATH Condition de décès	AUTOPSY PERFORMED Autopsie effectuée ☑ YES Oui ☐ NO Non	CIRCUMSTANCES SURROUNDING DEATH DUE TO EXTERNAL CAUSES Circonstances de la mort suscitées par des causes extérieures
☐ NATURAL Mort naturelle	MAJOR FINDINGS OF AUTOPSY Conclusions principales de l'autopsie	
☐ ACCIDENT Mort accidentelle		
☐ SUICIDE Suicide	NAME OF PATHOLOGIST Nom du pathologiste (b)(6)	
☒ HOMICIDE Homicide	DATE Date 02 Dec 2003	AVIATION ACCIDENT Accident d'Avion ☐ YES Oui ☑ NO Non

DATE OF DEATH *(Hour, day, month, year)* Date du décès (Heure, le jour, le mois, l'année)	PLACE OF DEATH Lieu de décès
(b)(6) 2003	Al Qaim, Iraq

I HAVE VIEWED THE REMAINS OF THE DECEASED AND DEATH OCCURRED AT THE TIME INDICATED AND FROM THE CAUSES AS STATED ABOVE.
J'ai examiné les restes mortels du dé funt et je conclus que le décès est survenu à l'heure indiquée et à, la suite des causes énumérées ci-dessus.

NAME OF MEDICAL OFFICER Nom du médicin militaire ou du médicin sanitaire	TITLE OR DEGREE Titre ou diplôme
(b)(6)	Medical Examiner

GRADE Grade	INSTALLATION OR ADDRESS Installation ou adresse
(b)(6)	Dover AFB, DE 19902
DATE Date 12 May 2004	(b)(6)

[1] State disease, injury or complication which
[2] State conditions contributing to the death,
[1] Préciser la nature de la maladie, de la blessure ou de la complication qui a contribué à la mort, mais non la manière de mourir, telle qu'un arrêt du coeur, etc
[2] Préciser la condition qui a contribué à la mort, mais n'ayant aucun rapport avec la maladie ou à la condition qui a provoqué la mort.

DD FORM 1 APR 77 2064 REPLACES DA FORM 3565, 1 JAN 72 AND DA FORM 3565-R(PAS), 26 SEP 75, WHICH ARE OBSOLETE.

MEDCOM 0009

ACLU Detainee DeathII ARMY MEDCOM 9

ARMED FORCES INSTITUTE OF PATHOLOGY
Office of the Armed Forces Medical Examiner
1413 Research Blvd., Bldg. 102
Rockville, MD 20850
1-800-944-7912

FINAL AUTOPSY REPORT

Name: Al-Jamadi, Manadel
SSAN: N/A
Date of Birth: Unk
Date Found: (b)(6) 2003
Date of Autopsy: 09 NOV 2003
Date of Report: 09 JAN 2004

Autopsy No.: (b)(6)
AFIP No.: (b)(6)
Rank: CIV, Iraqi National
Place of Death: near Baghdad, Iraq
Place of Autopsy: Mortuary Affairs, Camp Sayther, Baghdad International Airport

Circumstances of Death: This Iraqi National male was captured by Navy Seal (b)(2) and died while detained at Abu Ghraib Prison in Iraq.

Authorization for Autopsy: Office of the Armed Forces Medical Examiner, IAW 10 USC 1471

Identification: Visual Identification as per Investigating Agency

CAUSE OF DEATH: Blunt Force Injuries Complicated by Compromised Respiration

MANNER OF DEATH: Homicide

ACLU Detainee DeathII ARMY MEDCOM 10

FINAL AUTOPSY DIAGNOSES:

I. Blunt Forces Injuries:

A. Head:

i. Right periorbital contusion and subjunctival hemorrhage
ii. Contusions of the right side of the face and nose
iii. Parietal subgaleal and temporalis muscle contusions
iv. Lower lip and buccal mucosa contusions

B. Torso:

i. Multiple cutaneous contusions and abrasions
ii. Anterior and posterior chest wall contusions
iii. Sternal contusion
iv. Fractures of right anterior ribs 5&6 and left anterior ribs 3-6
v. Left lung contusion

C. Extremities:

i. Multiple cutaneous abrasions and contusions

II. Ligature marks of the wrists and ankles

III. Remote Gunshot Wound of Torso (projectile removed from spleen)

IV. No significant natural diseases identified, within limitations of examination

V. Toxicology: negative

ACLU Detainee DeathII ARMY MEDCOM 11

EXTERNAL EXAMINATION

The body is that of a well-developed, well-nourished 5ft 10-inch tall, 165-pound (estimated) Caucasian male. Lividity is fixed on the posterior aspect of the body. Rigor is present and symmetric on all extremities. The temperature is cold, that of the refrigeration unit.

The scalp is covered with brown hair with temporal graying and frontal balding. Facial hair consists of a close trimmed brown and grey beard and mustache. The irides are brown and the pupils are round and equal in diameter. Petechial hemorrhages of the sclera are not present. The external auditory canals are free of secretions and blood. The ears are unremarkable. The nares are patent. Injuries to the face will be described below in the "evidence of injury section". The nose and maxillae are palpably stable. The teeth are natural. Petechiae of the buccal mucosa are not present.

The neck is straight, and the trachea is midline and mobile. The chest is symmetric. The abdomen is flat. There is a well-healed 2 x ¼-inch oblique scar on the left lower quadrant of the abdomen. There is a jagged irregular well-healed 6 x 2-inch horizontal scar extending from the lower left quadrant of the abdomen across the anterior lateral aspect of the left thigh. The genitalia are those of a normal adult male. The testes are descended and free of masses. Pubic hair is present in a normal distribution. Ano-genital trauma is not present and the buttocks and anus are otherwise unremarkable

On the posterior torso there is a well-healed vertical 3 x ¼-inch scar in the midline over the thoracic spine. There is a 3 x 2-inch vertical scar in the midline of the lumbar spine. A well-healed 3-x ¼-inch irregularly shaped scar is on the left lower back. A vertical ¾ x ¼-inch scar is on the upper aspect of the right buttock. A 1 x ¼-inch vertical scar is present on the left buttock. There is an oblique 3 x ¼-inch scar on the lower aspect of the left buttock. Injuries to the torso will be described below in the "evidence of injuries" section.

The upper and lower extremities are symmetric without clubbing or edema. Injuries to the palms of the hands and soles of the feet are not noted. There is a vertical 6 x ¼-inch scar on the medial aspect of the distal left thigh, which extends to the upper left leg. On the dorsum of the right foot is a 1x ½-inch scar. On the dorsal aspect of the left foot is a 1x ½-inch scar. Injuries to the extremities will be described below in the "evidence of injury section".

CLOTHING AND PERSONAL EFFECTS

The deceased in unclad and personal effects are not present with body at the time of autopsy.

ACLU Detainee DeathII ARMY MEDCOM 12

MEDICAL INTERVENTION

None.

RADIOGRAPHS

Postmortem radiographs are obtained and support the clinical diagnoses.

EVIDENCE OF INJURY

I. BLUNT FORCE INJURIES:

A. Head and Neck:
Externally, a circumferential periorbital contusion surrounds the right eye with associated subconjunctival hemorrhage of the eyeball. A 1¼ x ¾-inch contusion is on the right side of the face, lateral to right eye. There is a ¾ x ¼-inch contusion on the left side of the nose, immediately adjacent to the left medial canthus. A ¼ x ¼-inch round contusion is on the right lower lip. There is a 1 x ½-inch contusion on the buccal mucosa of the lower lip. Reflection of the scalp reveals bilateral subgaleal hemorrhages of the parietal scalp with contusions of the right and left temporalis muscles. Injury to the skull is not identified. The brain and spinal cord are without injury. Incision and layerwise dissection of the anterior and posterior neck demonstrates no injury of the anterior neck and deep paracervical muscular tissues and no cervical spine fractures.

B.Torso:
On the upper lateral aspect of the left side of the chest is a 5 x 2-inch contusion. On the upper quadrant of the left side of the abdomen is an oblique 5 x 1-inch contusion. Just inferior to this contusion is an oval 3 x 2-inch contusion. On the posterior lateral aspect of the left buttock is a 3 x 1-inch linear contusion. On the mid aspect of the left buttock is an oval 3 x 2-inch contusion.

Internally, there are contusions of the muscles of the upper right and left chest walls. Posteriorly, there are muscle contusions of the right upper back. There are fractures of left anterior ribs three through six and right anterior ribs five and six. There are contusions over the mid aspect of the sternum. The left lung is involved by a 5 x 3-cm contusion of the anterior aspect of the upper lobe of the left lung.

C.Extremities:
On the posterior aspect of the right forearm is a linear 6 x 2-inch contusion with a 3 x ¼-inch abrasion in its center. On the dorsum of the right hand is a 3 x 2-inch contusion and smaller contusions overlay the dorsal aspect of the second and third right digits. On the anterior aspect of the left upper arm is a ¾ x ¾-inch contusion. This contusion is continuous with the previously described injury on the lateral aspect of the upper left chest. There is a 2 x 1-inch contusion on the medial aspect of the left elbow. On the posterior aspect of the left elbow is a 2 x 2-inch contusion. There are contusions

ACLU Detainee DeathII ARMY MEDCOM 13

overlying the dorsum of the left hand centered over the fourth and fifth metacarpal joints. On the anterior aspect of the right thigh are three linear horizontal contusions. The most proximal contusion measures 3 x ½-inches. Iimmediately inferior to this is a 2 ½ x ½-inch contusion and the most inferior contusion, located at the mid anterior thigh, measures 4 x ½-inches. A vertical 6 x 3-inch contusion is located on the anterior-lateral aspect of the mid right thigh. A 4 x 3-inch contused-abrasion overlies the anterior aspect of the right knee. On the anterior mid left thigh is a 1 ½ x 1-inch contusion. The left knee is covered by a 3 x 1-inch vertical contused-abrasion. On the anterior aspect of the left leg is a 7 x 2 ½-inch irregularly shaped contusion. On the posterior aspect of the distal left thigh, in the midline, is a 2 x 2-inch oval contusion. On the dorsal aspect of the left foot are ½-inch oval contusions overlying the second, third, fourth, and fifth metacarpelphalangeal joints.

II. LIGATURE INJURIES:

The wrists and ankles show evidence of binding ligature injuries. On the anterior aspect of the right wrist is a 2 x ¼-inch linear horizontal contusion and on the back of the right wrist is 2 x ¼-inch linear horizontal contusion. Cut sections into these wounds show hemorrhage into the superficial subcutaneous tissue. On the front of the left wrist on the lateral aspect is a 1 x ¾-inch contusion, extending to the left thumb. On the back of the left wrist is a 2 ¼ x ½-inch contusion, which extends across the diameter of the wrist. Cut sections into these wrist wounds show hemorrhage into the superficial aspects of the subcutaneous tissue. On the lateral aspect of the anterior right ankle is a 3 x 3-inch contused-abrasion and on the posterior-lateral aspect of the right ankle is a 2 x 1-inch contused-abrasion. On the anterior aspect of the left ankle is 3 ½ x 1-inch linear contusion extending from the lateral to mid aspect of the left ankle. Incision into these ankle wounds show hemorrhage into the superficial subcutaneous tissue.

III. REMOTE GUNSHOT WOUND OF THE TORSO:

Dissection of the spleen reveals a minimally deformed medium caliber jacketed projectile within the splenic parenchyma. The projectile is surrounded by dense fibrous tissue.

INTERNAL EXAMINATION

HEAD:
Injuries to the subgaleal soft tissues of the scalp have been described. The remainder of the galeal and subgaleal soft tissues are free of injury. The calvarium is intact, as is the dura mater beneath it. Clear cerebrospinal fluid surrounds the 1400 gm brain, which has unremarkable gyri and sulci. Coronal sections demonstrate sharp demarcation between white and grey matter, without hemorrhage or contusive injury. The ventricles are of normal size. The basal ganglia, brainstem, cerebellum, and arterial systems are free of

ACLU Detainee DeathII ARMY MEDCOM 14

injury or other abnormalities. There are no skull fractures. The atlanto-occipital joint is stable.

NECK:
The anterior strap muscles of the neck are homogenous and red-brown, without hemorrhage. The thyroid cartilage and hyoid are intact. The larynx is lined by intact white mucosa. The thyroid is symmetric and red-brown, without cystic or nodular change. The tongue is free of bite marks, hemorrhage, or other injuries.

BODY CAVITIES:
Injuries to the chest have been described. The vertebral bodies are visibly and palpably intact. No excess fluid is in the pleural, pericardial, or peritoneal cavities. The organs occupy their usual anatomic positions.

RESPIRATORY SYSTEM:
Injury to the left lung has been described. The right and left lungs weigh 650 and 485 gms, respectively. The uninjured external surfaces are smooth and deep red-purple. The pulmonary parenchyma is diffusely congested and edematous. No mass lesions or areas of consolidation are present.

CARDIOVASCULAR SYSTEM:
The 425 gm heart is contained in an intact pericardial sac. The epicardial surface is smooth, with minimal fat investment. The coronary arteries are present in a normal distribution, with a right-dominant pattern. Cross sections of the vessels show no significant atherosclerosis. There is 30% stenosis of the proximal left anterior descending coronary artery. Otherwise, the remaining coronary arteries are widely patent. The myocardium is homogenous, red-brown, and firm. The valve leaflets are thin and mobile. The walls of the left and right ventricles are 1.4 and 0.4-cm thick, respectively. The endocardium is smooth and glistening. The aorta gives rise to three intact and patent arch vessels. The renal and mesenteric vessels are unremarkable.

LIVER & BILIARY SYSTEM:
The 1500 gm liver has an intact, smooth capsule and a sharp anterior border. The parenchyma is tan-brown and congested, with the usual lobular architecture. No mass lesions or other abnormalities are seen. The gallbladder contains 10 cc of green-black bile and no stones. The mucosal surface is green and velvety. The extrahepatic biliary tree is patent.

SPLEEN:
Recovery of a remote projectile has been discussed. The 130 gm spleen has a smooth, intact, red-purple capsule. The parenchyma is maroon and congested, with distinct Malpighian corpuscles.

ACLU Detainee DeathII ARMY MEDCOM 15

PANCREAS:
The pancreas is firm and yellow-tan, with the usual lobular architecture. No mass lesions or other abnormalities are seen.

ADRENALS:
The right and left adrenal glands are symmetric, with yellow cortices and grey medullae. No masses or areas of hemorrhage are identified.

GENITOURINARY SYSTEM:
The right and left kidneys weigh 115 and 120 gms, respectively. The external surfaces are intact and smooth. The cut surfaces are red-tan and congested, with uniformly thick cortices and sharp corticomedullary junctions. The pelves are unremarkable and the ureters are normal in course and caliber. White bladder mucosa overlies an intact bladder wall. The bladder contains approximately 300 cc of yellow urine. The prostate is normal in size, with lobular, yellow-tan parenchyma. The seminal vesicles are unremarkable. The testes are free of mass lesions, contusions, or other abnormalities.

GASTROINTESTINAL TRACT:
The esophagus is intact and lined by smooth, grey-white mucosa. The stomach contains approximately 200 cc of dark brown partially digested food. The gastric wall is intact. The duodenum, loops of small bowel, and colon are unremarkable. The appendix is present.

ADDITIONAL PROCEDURES

- Documentary photographs are taken by (b)(6) OAFME
- Attending the autopsy is Special Agent (b)(6) Army CID.
- Specimens retained for toxicologic testing and/or DNA identification are: vitreous, blood, urine, spleen, liver, lung, brain, bile, gastric, and psoas muscle
- The dissected organs are forwarded with body

MICROSCOPIC EXAMINATION

Selected portions of organs are retained in formalin, without preparation of histologic slides.

TOXICOLOGY

AFIP Accession (b)(6) dated 24 Nov 2003
Volatiles: Blood-negative for ethanol
Cyanide: Blood- negative
Drugs of abuse: Blood-negative

ACLU Detainee DeathII ARMY MEDCOM 16

OPINION

(b)(6) an Iraqi National, died while detained at the Abu Ghraib prison where he was held for interrogations by government agencies. According to an investigative report, (b)(6) was captured by Navy Seal (b)(2) and resisted apprehension. External injuries are consistent with injuries sustained during apprehension. Ligature injuries are present on the wrists and ankles. Fractures of the ribs and a contusion of the left lung imply significant blunt force injuries of the thorax and likely resulted in impaired respiration. According to investigating agents, interviews taken from individuals present at the prison during the interrogation indicate that a hood made of synthetic material was placed over the head and neck of the detainee. This likely resulted in further compromise of effective respiration. (b)(6) was not under the influence of drugs of abuse or ethanol at the time of death. The cause of death is blunt force injuries of the torso complicated by compromised respiration. The manner of death is homicide.

(b)(6)

Medical Examiner

ACLU Detainee DeathII ARMY MEDCOM 17

CERTIFICATE OF DEATH *(OVERSEAS)*
Acte de décès *(D'Outre-Mer)*

NAME OF DECEASED *(Last, First, Middle)* Nom du décédé *(Nom et prénoms)*	GRADE Grade	BRANCH OF SERVICE Arme	SOCIAL SECURITY NUMBER Numéro de l'Assurance Sociale
BTB Al-Jamadi, Manadel			

ORGANIZATION Organisation	NATION *(e.g., United States)* Pays	DATE OF BIRTH Date de naissance	SEX Sexe
Detainee in Iraq	USA		☑ MALE Masculin ☐ FEMALE Féminin

RACE Race	MARITAL STATUS État Civil		RELIGION Culte	
X CAUCASOID Caucasique	SINGLE Célibataire	DIVORCED Divorcé	PROTESTANT Protestant	OTHER (Specify) Autre (Spécifier)
NEGROID Negroide	MARRIED Marié	SEPARATED Séparé	CATHOLIC Catholique	
OTHER (Specify) Autre (Spécifier)	WIDOWED Veuf		JEWISH Juif	

NAME OF NEXT OF KIN Nom du plus proche parent	RELATIONSHIP TO DECEASED Parenté du décédé avec le susdit
STREET ADDRESS Domicilé à (Rue)	CITY OR TOWN AND STATE *(Include ZIP Code)* Ville *(Code postal compris)*

MEDICAL STATEMENT Déclaration médicale

CAUSE OF DEATH *(Enter only once cause per line)* Cause du décès *(N'indiquer qu'une cause par ligne)*		INTERVAL BETWEEN ONSET AND DEATH Intervalle entre l'attaque et le décès
DISEASE OR CONDITION DIRECTLY LEADING TO DEATH[1] Maladie ou condition directement responsable de la mort[1]	Blunt force injuries complicated by compromised respiration	
ANTECEDENT CAUSES Symptômes précurseurs de la mort. — MORBID CONDITION, IF ANY, LEADING TO PRIMARY CAUSE Condition morbide, s'il y a lieu, menant à la cause primaire		
ANTECEDENT CAUSES Symptômes précurseurs de la mort. — UNDERLYING CAUSE, IF ANY, GIVING RISE TO PRIMARY CAUSE Raison fondamentale, s'il y a lieu, ayant suscité la cause primaire		
OTHER SIGNIFICANT CONDITIONS[2] Autres conditions significatives[2]		

MODE OF DEATH Condition de décès	AUTOPSY PERFORMED Autopsie effectuée ☑ YES Oui ☐ NO Non	CIRCUMSTANCES SURROUNDING DEATH DUE TO EXTERNAL CAUSES Circonstances de la mort suscitées par des causes extérieures
NATURAL Mort naturelle	MAJOR FINDINGS OF AUTOPSY Conclusions principales de l'autopsie	
ACCIDENT Mort accidentelle		
SUICIDE Suicide	NAME OF PATHOLOGIST Nom du pathologiste (b)(6)	
X HOMICIDE Homicide	DATE Date 09 Nov 2003	AVIATION ACCIDENT Accident à Avion ☐ YES Oui ☑ NO Non

DATE OF DEATH *(Hour, day, month, year)* Date de décès *(l'heure, le jour, le mois, l'année)*	PLACE OF DEATH Lieu de décès
(b)(6) 2003	Baghdad, Iraq

I HAVE VIEWED THE REMAINS OF THE DECEASED AND DEATH OCCURRED AT THE TIME INDICATED AND FROM THE CAUSES AS STATED ABOVE.
J'ai examiné les restes mortels du dé funtel je conclus que le décès est survenu à l'heure indiquée et à la suite des causes énumérées ci-dessus.

NAME OF MEDICAL OFFICER Nom du médicin militaire ou du médicin sanitaire	TITLE OR DEGREE Titre ou diplômé
(b)(6)	Medical Examiner

GRADE Grade	INSTALLATION OR ADDRESS Installation ou adresse
(b)(6)	Dover AFB, DE 19902
DATE Date 13 MAY 2004	(b)(6)

[1] State disease, injury or complication which c...
[2] State conditions contributing to the death, b...
[1] Préciser la nature de la maladie, de la bless... arrêt du coeur, etc.
[2] Préciser la condition qui a contribué à la mort, mais n'ayant aucun rapport avec la maladie ou à la condition qui a provoqué la mort.

DD FORM 1 APR 77 2064 REPLACES DA FORM 3565, 1 [illegible] AND DA FORM [illegible] (PAS), 26 SEP 75, WHICH ARE OBSOLETE.

MEDCOM 0018

ARMED FORCES INSTITUTE OF PATHOLOGY
Office of the Armed Forces Medical Examiner
1413 Research Blvd., Bldg. 102
Rockville, MD 20850
1-800-944-7912

AUTOPSY EXAMINATION REPORT

Name:BTB Taled Ehad Kazam
SSAN:NA
Date of Birth:Unknown
Date/Time of Death (b)(6) 2003

Autopsy No.: (b)(6)
AFIP No (b)(6)
Rank: NA
Place of Death: Abu Ghraib Prison, Iraq

Date/Time of Autopsy: 22 Aug 2003
Date of Report: 9 Oct 2003

Place of Autopsy: Camp Sather, Iraq

Circumstances of Death: The decedent was a prisoner in Abu Ghraib prison in U.S. Custody. On or about (b)(6) 2003 he was noted to be pulseless and apneic. Cardiopulmonary resuscitation was unsuccessful. There was no prior complaint or trauma.

Authorization for Autopsy: Armed Forces Medical Examiner, per 10 U.S. Code 1471

Identification: Tentative by Army Criminal Investigation Division (CID). Antemortem dental, fingerprint, and DNA profile not available.

CAUSE OF DEATH: Arteriosclerotic Cardiovascular Disease (ASCVD)

MANNER OF DEATH: Natural

ACLU Detainee DeathII ARMY MEDCOM 19

FINAL AUTOPSY DIAGNOSES:

I. Mild-moderate three vessel coronary arteriosclerosis
   A. Ischemic cardiomyopathy (450 grams)
   B. Left ventricle hypertrophy (1.8 cm)
   C. Pulmonary edema and congestion (combined weight 1900 grams)
   D. Chronic passive congestion of the liver
   E. Congestive splenomegaly (350 grams)

II. Hemangioma of the liver

III. Mild decomposition

ACLU Detainee DeathII ARMY MEDCOM 20

EXTERNAL EXAMINATION

The body is that of a well-developed, well-nourished appearing, muscular 72inch tall 160 pounds (estimated) male with an estimated age of 40 years. Lividity is posterior, purple, and fixed. Rigor is absent.

There is early postmortem decomposition indicated by corneal clouding and early skin slippage.

Identifying marks include a ½ inch circular scar on the anterior left forearm and a vertical 3-½ inch scar on the posterior right hand.

The scalp is covered with gray-black hair in a normal distribution. Corneal clouding obscures the irides and pupils. The external auditory canals are unremarkable. The ears are unremarkable. The nares are patent and the lips are atraumatic. The nose and maxillae are palpably stable. The teeth appear natural and in good repair.

The neck is straight, and the trachea is midline and mobile. The chest is symmetric. The abdomen is flat. The genitalia are those of a normal adult male. The testes are descended and free of masses. Pubic hair is present in a normal distribution. The buttocks and anus are unremarkable.

The upper and lower extremities are symmetric and without clubbing or edema.

CLOTHING AND PERSONAL EFFECTS

None.

MEDICAL INTERVENTION

No attached medical devices or artifacts of therapy.

EVIDENCE OF INJURY

None.

INTERNAL EXAMINATION

HEAD:
The galeal and subgaleal soft tissues of the scalp are free of injury. The calvarium is intact, as is the dura mater beneath it. Clear cerebrospinal fluid surrounds the 1500 gm brain, which has unremarkable gyri and sulci and vascular congestion. Coronal sections demonstrate sharp demarcation between white and grey matter, without hemorrhage or contusive injury. The ventricles are of normal size. The basal ganglia, brainstem,

ACLU Detainee DeathII ARMY MEDCOM 21

cerebellum, and arterial systems are free of injury or other abnormalities. There are no skull fractures. The atlanto-occipital joint is stable.

NECK:
The anterior strap muscles of the neck are homogenous and red-brown, without hemorrhage. The thyroid cartilage and hyoid are intact. The larynx is lined by intact white mucosa. The thyroid is symmetric and red-brown, without cystic or nodular change. The tongue is free of bite marks, hemorrhage, or other injuries.

BODY CAVITIES:
The ribs, sternum, and vertebral bodies are visibly and palpably intact. No excess fluid is in the pleural, pericardial, or peritoneal cavities. The organs occupy their usual anatomic positions.

RESPIRATORY SYSTEM:
The right and left lungs are edematous, congested and weigh 1000 and 900 gm, respectively. The external surfaces are smooth and deep red-purple. No mass lesions or areas of consolidation are present.

CARDIOVASCULAR SYSTEM:
The 450 gm heart is globular in shape but contained in an intact pericardial sac. The epicardial surface is smooth, with minimal fat investment. The coronary arteries are present in a normal distribution, with a right-dominant pattern. Cross sections of the vessels show multifocal stenoses of the left anterior descending coronary artery. The right coronary artery has 50-75% mulitfocal stenoses of the proximal and mid segments. The myocardium is homogenous, red-brown, and firm. The valve leaflets are thin and mobile. The walls of the left and right ventricles are 1.8and 0.6-cm thick, respectively. The septum is hypertrophied measuring 2.0 cm in thickness. The endocardium is smooth and glistening. The aorta gives rise to three intact and patent arch vessels. The renal and mesenteric vessels are unremarkable.

LIVER & BILIARY SYSTEM:
The 1900 gm liver has an intact, smooth capsule with congested parenchyma. There is a 1 ¾ x 1 ½ inch subcapsular hemangioma. The gallbladder contains a minute amount of green-black bile and no stones. The mucosal surface is green and velvety. The extrahepatic biliary tree is patent.

SPLEEN:
The 350-gram spleen has a smooth, intact, red-purple capsule. The parenchyma is maroon and congested, with distinct Malpighian corpuscles.

PANCREAS:
The pancreas is firm and yellow-tan, with the usual lobular architecture. No mass lesions or other abnormalities are seen.

ACLU Detainee DeathII ARMY MEDCOM 22

ADRENALS:
The right and left adrenal glands are symmetric, with bright yellow cortices and grey medullae. No masses or areas of hemorrhage are identified.

GENITOURINARY SYSTEM:
The right and left kidneys weigh 350 gm, each. The external surfaces are intact and smooth. The cut surfaces are red-tan and congested, with uniformly thick cortices and sharp corticomedullary junctions. The pelves are unremarkable and the ureters are normal in course and caliber. White bladder mucosa overlies an intact bladder wall. The bladder is devoid of urine. The prostate is normal in size, with lobular, yellow-tan parenchyma. The seminal vesicles are unremarkable. The testes are free of mass lesions, contusions, or other abnormalities.

GASTROINTESTINAL TRACT:
The esophagus is intact and lined by smooth, grey-white mucosa. The stomach contains approximately 25 ml of yellow liquid. The gastric wall is intact. The duodenum, loops of small bowel, and colon are unremarkable. The appendix is present and unremarkable.

ADDITIONAL PROCEDURES

- Documentary photographs are taken by (b)(6)
- Specimens retained for toxicologic testing and/or DNA identification are: vitreous, blood, spleen, liver, brain, gastric contents, and psoas muscle
- The dissected organs are forwarded with body

MICROSCOPIC EXAMINATION

Selected portions of organs are retained in formalin, without preparation of histologic slides.

TOXICOLOGIC ANALYSIS

Toxicologic analysis of blood and vitreous fluid were negative for ethanol (alcohol) and illicit substances.

ACLU Detainee DeathII ARMY MEDCOM 23

OPINION

This Iraqi male prisoner of war died of arteriosclerotic cardiovascular disease. Significant findings of the autopsy included an enlarged heart and significant narrowing of one of the arteries supplying blood to the heart. The lungs, liver, and spleen were congested most likely due to inadequate pumping of the heart. An unrelated finding was a hemangioma (a benign blood vessel tumor) of the liver that did not contribute to death. There was no internal or external trauma.

The manner of death is natural.

(b)(6)

(b)(6) Medical Examiner

ACLU Detainee DeathII ARMY MEDCOM 24

CERTIFICATE OF DEATH (OVERSEAS)
Acte de décès (D'Outre-Mer)

NAME OF DECEASED (Last, First, Middle) Nom du décédé (Nom et prénoms)	GRADE Grade	BRANCH OF SERVICE Arme	SOCIAL SECURITY NUMBER Numéro de l'Assurance Sociale
BTB Taled, Ehad, Kazam			

ORGANIZATION Organisation	NATION (e.g., United States) Pays	DATE OF BIRTH Date de naissance	SEX Sexe
Detainee in Iraq	Iraq		☑ MALE Masculin ☐ FEMALE Féminin

RACE Race	MARITAL STATUS État Civil	RELIGION Culte
☒ CAUCASOID Caucasique	☐ SINGLE Célibataire	☐ DIVORCED Divorcé
☐ NEGROID Negroide	☐ MARRIED Marié	☐ SEPARATED Séparé
☐ OTHER (Specify) Autre (Spécifier)	☐ WIDOWED Veuf	☐ PROTESTANT Protestant ☐ CATHOLIC Catholique ☐ JEWISH Juif ☐ OTHER (Specify) Autre (Spécifier)

NAME OF NEXT OF KIN Nom du plus proche parent	RELATIONSHIP TO DECEASED Parenté du décédé avec le susdit
STREET ADDRESS Domicile à (Rue)	CITY OR TOWN AND STATE (Include ZIP Code) Ville (Code postal compris)

MEDICAL STATEMENT Déclaration médicale

	CAUSE OF DEATH (Enter only once cause per line) Cause du décès (N'indiquer qu'une cause par ligne)	INTERVAL BETWEEN ONSET AND DEATH Intervalle entre l'attaque et le décès
DISEASE OR CONDITION DIRECTLY LEADING TO DEATH[1] Maladie ou condition directement responsable de la mort[1]	Arteriosclerotic Cardiovasular Disease	
ANTECEDENT CAUSES Symptômes précurseurs de la mort. — MORBID CONDITION, IF ANY, LEADING TO PRIMARY CAUSE Condition morbide, s'il y a lieu, menant à la cause primaire		
ANTECEDENT CAUSES Symptômes précurseurs de la mort. — UNDERLYING CAUSE, IF ANY, GIVING RISE TO PRIMARY CAUSE Raison fondamentale, s'il y a lieu, ayant suscité la cause primaire		
OTHER SIGNIFICANT CONDITIONS[2] Autres conditions significatives[2]		

MODE OF DEATH Condition de décès	AUTOPSY PERFORMED Autopsie effectuée ☑ YES Oui ☐ NO Non MAJOR FINDINGS OF AUTOPSY Conclusions principales de l'autopsie	CIRCUMSTANCES SURROUNDING DEATH DUE TO EXTERNAL CAUSES Circonstances de la mort suscitées par des causes extérieures
☒ NATURAL Mort naturelle		
☐ ACCIDENT Mort accidentelle		
☐ SUICIDE Suicide	NAME OF PATHOLOGIST Nom du pathologiste (b)(6)	
☐ HOMICIDE Homicide	DATE Date 22 Aug 2003	AVIATION ACCIDENT Accident d'Avion ☐ YES Oui ☑ NO Non

DATE OF DEATH (Hour, day, month, year) Date de décès (l'heure, le jour, le mois, l'année)	PLACE OF DEATH Lieu de décès
20 Aug 2003	Abu Ghraib Prison, Iraq

I HAVE VIEWED THE REMAINS OF THE DECEASED AND DEATH OCCURRED AT THE TIME INDICATED AND FROM THE CAUSES AS STATED ABOVE
J'ai examiné les restes mortels du dé funtet je conclus que la décès est survenu à l'heure indiquée et à, la suite des causes énumérées ci-dessus.

NAME OF MEDICAL OFFICER Nom du médicin militaire ou du médicin sanitaire	TITLE OR DEGREE Titre ou diplôme
(b)(6)	Medical Examiner

GRADE Grade	INSTALLATION OR ADDRESS Installation ou adresse
(b)(6)	Dover AFB, DE 19902 (b)(6)

DATE Date 12 May 2004

[1] State disease, injury or complication which caused death, but not mode of dying such as heart failure, etc.
[2] State conditions contributing to the death, but not related to the disease or condition causing death.
[1] Préciser la nature de la maladie, de la blessure ou de la complication qui a contribué à la mort, mais non la manière de mourir, telle qu'un arrêt du coeur, etc
[2] Préciser la condition qui a contribué à la mort, mais n'ayant aucun rapport avec la maladie ou à la condition qui a provoqué la mort.

DD FORM 1 APR 77 2064 REPLACES DA FORM 3565, 1 JAN 72 AND DA FORM 3565-R(PAS), 26 SEP 75, WHICH ARE OBSOLETE.

ARMED FORCES INSTITUTE OF PATHOLOGY
Office of the Armed Forces Medical Examiner
1413 Research Blvd., Bldg. 102
Rockville, MD 20850
1-800-944-7912

AUTOPSY EXAMINATION REPORT

Name: BTB Spah, Dham
SSAN: NA
Date of Birth: Unknown
Date/Time of Death: (b)(6) 2003

Autopsy No.: (b)(6)
AFIP No. (b)(6)
Rank: NA
Place of Death: Abu Ghraib Prison, Iraq

Date/Time of Autopsy: 25 Aug 2003
Date of Report: 24 Oct 2003
Place of Autopsy: Camp Sather, Iraq

Circumstances of Death: This Iraqi enemy prisoner of war was an inmate of Abu Ghraib Prison. On or about (b)(6) 2003 (b)(6) was brought to the gate by other detainees and was noted to be pulseless and apneic.

Authorization for Autopsy: Armed Forces Medical Examiner, per 10 U.S. Code 1471

Identification: Presumptive by US Army Criminal Investigative Division (CID). Antemortem fingerprint, dental, and DNA records non-existent.

CAUSE OF DEATH: Arteriosclerotic cardiovascular disease (ASCVD)

MANNER OF DEATH: Natural

FINAL AUTOPSY DIAGNOSES:

I. 3 vessel moderate to severe coronary artery atherosclerotic stenoses
   A. Ischemic cardiomyopathy (525 grams)
   B. Left ventricular hypertrophy (1.8 cm)
   C. Focal bridging of the left anterior descending coronary artery (LAD)
   D. Pulmonary congestion (1600 grams)

II. Mild decomposition
   A. Postmortem freeze artifact
   B. Postmortem bile toxicology consistent with decomposition

III. Fibrous pleural adhesions

ACLU Detainee DeathII ARMY MEDCOM 27

EXTERNAL EXAMINATION

The body is that of a well-developed, thin, muscular, 70 inch tall, 150 pounds (estimated) male whose appearance is consistent with an estimated age of 40-60 years. Lividity is posterior, purple, and fixed. Rigor is indeterminate secondary to postmortem freezing. There is mild decomposition consisting of clouding of the corneas, early skin slippage, and slight green discoloration of the right lower quadrant of the abdomen.

Identifying marks include a ¾ x ½ inch scar on the skin overlying the right patella.

The scalp is covered with straight black hair in a normal distribution. Corneal clouding obscures the irides and the pupils. The external auditory canals are unremarkable. The ears are unremarkable. The nares are patent and the lips are atraumatic. The nose and maxillae are palpably stable. The teeth appear natural and adequate.

The neck is straight, and the trachea is midline and mobile. The chest is symmetric. The abdomen is flat. The genitalia are those of a normal adult male. The testes are descended and free of masses. Pubic hair is present in a normal distribution. The buttocks and anus are unremarkable.

The upper and lower extremities are symmetric and without clubbing or edema.

CLOTHING AND PERSONAL EFFECTS

None.

MEDICAL INTERVENTION

None.

EVIDENCE OF INJURY

None.

INTERNAL EXAMINATION

HEAD:
The galeal and subgaleal soft tissues of the scalp are free of injury. The calvarium is intact, as is the dura mater beneath it. Clear cerebrospinal fluid surrounds the partially frozen 1450 gm brain, which has unremarkable gyri and sulci. Coronal sections demonstrate sharp demarcation between white and grey matter, without hemorrhage or contusive injury. The ventricles are of normal size. The basal ganglia, brainstem, cerebellum, and arterial systems are free of injury or other abnormalities. There are no skull fractures. The atlanto-occipital joint is stable.

NECK:
The anterior strap muscles of the neck are homogenous and red-brown, without hemorrhage. The thyroid cartilage and hyoid are intact. The larynx is lined by intact white mucosa. The thyroid is symmetric and red-brown, without cystic or nodular change. The tongue is free of bite marks, hemorrhage, or other injuries.

BODY CAVITIES:
The ribs, sternum, and vertebral bodies are visibly and palpably intact. No excess fluid is in the pleural, pericardial, or peritoneal cavities. There are fibrous adhesions in both pleural cacities. The organs occupy their usual anatomic positions.

RESPIRATORY SYSTEM:
The right and left lungs weigh 850 and 750 gm, respectively. The external surfaces are smooth and deep red-purple. The pulmonary parenchyma is diffusely congested and edematous. No mass lesions or areas of consolidation are present.

CARDIOVASCULAR SYSTEM:
The 525 gm heart is contained in an intact pericardial sac. The epicardial surface is smooth, with minimal fat investment. The coronary arteries are present in a normal distribution, with a right-dominant pattern. Cross sections of the vessels show 50-75% multifocal stenoses of the proximal portion of the left anterior descending coronary artery with focal bridging, a focal proximal 90% stenosis with calcification and 75-90% multifocal stenoses of the mid portion of the right coronary artery. There is a focal 75% stenosis of the proximal left circumflex coronary artery. No acute changes (plaque hemorrhage, rupture, or thrombosis) are noted. The myocardium is homogenous, red-brown, and firm. The valve leaflets are thin and mobile. The wall of the left ventricle is hypertrophied measuring 1.8 cm in thickness. The endocardium is smooth and glistening. The aorta gives rise to three intact and patent arch vessels. The renal and mesenteric vessels are unremarkable.

LIVER & BILIARY SYSTEM:
The 1400 gm liver has an intact, smooth capsule and a sharp anterior border. The parenchyma is tan-brown and congested, with the usual lobular architecture. No mass lesions or other abnormalities are seen. The gallbladder contains a minute amount of green-black bile and no stones. The mucosal surface is green and velvety. The extrahepatic biliary tree is patent.

SPLEEN:
The 150 gm spleen has a smooth, intact, red-purple capsule. The parenchyma is maroon and congested, with distinct Malpighian corpuscles. There is an adjacent 10 gram accessory spleen near the hilum.

PANCREAS:
The pancreas is firm and yellow-tan, with the usual lobular architecture. No mass lesions or other abnormalities are seen.

ACLU Detainee DeathII ARMY MEDCOM 29

ADRENALS:
The right and left adrenal glands are symmetric, with bright yellow cortices and grey medullae. No masses or areas of hemorrhage are identified.

GENITOURINARY SYSTEM:
The right and left kidneys weigh 200 gm each. The external surfaces are intact and smooth. The cut surfaces are red-tan and congested, with uniformly thick cortices and sharp corticomedullary junctions. The pelves are unremarkable and the ureters are normal in course and caliber. White bladder mucosa overlies an intact bladder wall. The bladder is empty. The prostate is normal in size, with lobular, yellow-tan parenchyma. The seminal vesicles are unremarkable. The testes are free of mass lesions, contusions, or other abnormalities.

GASTROINTESTINAL TRACT:
The esophagus is intact and lined by smooth, grey-white mucosa. The stomach contains approximately 10 ml of green liquid. The gastric wall is intact. The duodenum, loops of small bowel, and colon are unremarkable. The appendix is present and unremarkable.

ADDITIONAL PROCEDURES

- Documentary photographs are taken by (b)(6)
- Specimens retained for toxicologic testing and/or DNA identification are: blood, vitreous, liver, kidney, brain, bile, and psoas muscle
- The dissected organs are forwarded with the body
- Personal effects are released to the appropriate mortuary operations representatives of the 54th Quartermaster Company.

MICROSCOPIC EXAMINATION

Selected portions of organs are retained in formalin, without preparation of histologic slides.

TOXICOLOGY

Toxicologic analysis of bile revealed an ethanol concentration of 47 mg/dL, acetaldehyde 8 mg/dL, and trace amounts of 2-propanol and 1-propanol all of which are consistent with decomposition. No illicit substances were detected.

OPINION

This Iraqi male prisoner of war died of arteriosclerotic coronary artery disease. Significant findings of the autopsy included severe narrowing of the blood vessels supplying blood to the heart and enlargement of the heart. No external or internal trauma was noted.

The manner of death is natural.

ACLU Detainee DeathII ARMY MEDCOM 30

BTB Spah, Dham

(b)(6)

(b)(6) Medical Examiner

ACLU Detainee DeathII ARMY MEDCOM 31

CERTIFICATE OF DEATH *(OVERSEAS)*
Acte de décès *(D'Outre-Mer)*

NAME OF DECEASED *(Last, First, Middle)* Nom du décédé (Nom et prénoms)	GRADE Grade	BRANCH OF SERVICE Arme	SOCIAL SECURITY NUMBER Numéro de l'Assurance Sociale
BTB Spah, Dham			

ORGANIZATION Organisation	NATION *(e.g., United States)* Pays	DATE OF BIRTH Date de naissance	SEX Sexe
Detainee in Iraq	Iraq		☑ MALE Masculin ☐ FEMALE Féminin

RACE Race		MARITAL STATUS État Civil		RELIGION Culte	
☒	CAUCASOID Caucasique	☐	SINGLE Célibataire	☐	PROTESTANT Protestant
☐	NEGROID Negroide	☐	MARRIED Marié	☐	CATHOLIC Catholique
☐	OTHER (Specify) Autre (Spécifier)	☐	WIDOWED Veuf	☐	JEWISH Juif
		☐	DIVORCED Divorcé	☐	OTHER (Specify) Autre (Spécifier)
		☐	SEPARATED Séparé		

NAME OF NEXT OF KIN Nom du plus proche parent	RELATIONSHIP TO DECEASED Parenté du décédé avec le susdit
STREET ADDRESS Domicilé à (Rue)	CITY OR TOWN AND STATE *(Include ZIP Code)* Ville (Code postal compris)

MEDICAL STATEMENT Déclaration médicale

CAUSE OF DEATH *(Enter only once cause per line)* Cause du décès (N'indiquer qu'une cause par ligne)			INTERVAL BETWEEN ONSET AND DEATH Intervalle entre l'attaque et le décès
DISEASE OR CONDITION DIRECTLY LEADING TO DEATH[1] Maladie ou condition directement responsable de la mort		Arteriosclerotic Cardiovascular Disease	
ANTECEDENT CAUSES Symptômes précurseurs de la mort	MORBID CONDITION, IF ANY, LEADING TO PRIMARY CAUSE Condition morbide, s'il y a lieu, menant à la cause primaire		
	UNDERLYING CAUSE, IF ANY, GIVING RISE TO PRIMARY CAUSE Raison fondamentale, s'il y a lieu, ayant suscité la cause primaire		
OTHER SIGNIFICANT CONDITIONS[2] Autres conditions significatives[2]			

MODE OF DEATH Condition de décès		AUTOPSY PERFORMED Autopsie effectuée ☑ YES Oui ☐ NO Non	CIRCUMSTANCES SURROUNDING DEATH DUE TO EXTERNAL CAUSES Circonstances de la mort suscitées par des causes extérieures
☒	NATURAL Mort naturelle	MAJOR FINDINGS OF AUTOPSY Conclusions principales de l'autopsie	
☐	ACCIDENT Mort accidentelle		
☐	SUICIDE Suicide	NAME OF PATH'S OCIST Nom du pathologiste (b)(6)	
☐	HOMICIDE Homicide	DATE Date 25 Aug 2003	AVIATION ACCIDENT Accident d'Avion ☐ YES Oui ☑ NO Non

DATE OF DEATH *(Hour, day, month, year)* Date du décès *(Heure, le jour, le mois, l'année)*	PLACE OF DEATH Lieu de décès
(b)(6) 2003	Abu Ghraib, Iraq

I HAVE VIEWED THE REMAINS OF THE DECEASED AND DEATH OCCURRED AT THE TIME INDICATED AND FROM THE CAUSES AS STATED ABOVE
J'ai examiné les restes mortels du dé lunlat je conclus que le décès est survenu à l'heure indiquée et à, la suite des causes énumérées ci-dessus.

NAME OF MEDICAL OFFICER Nom du médecin militaire ou du médecin sanitaire	TITLE OR DEGREE Titre ou diplôme
(b)(6)	Medical Examiner

GRADE Grade	INSTALLATION OR ADDRESS Installation ou adresse
(b)(6)	Dover AFB, DE 19902

DATE Date 12 Nov 2004 (b)(6)

[1] State disease, injury or complication which
[2] State conditions contributing to the death, but not related to the disease or condition causing death.
[1] Préciser la nature de la maladie, de la blessure ou de la complication qui a contribué à la mort, mais non la manière de mourir, telle qu'un arrêt du coeur, etc
[2] Préciser la condition qui a contribué à la mort, mais n'ayant aucun rapport avec la maladie ou à la condition qui a provoqué la mort.

DD FORM 1 APR 77 2064 REPLACES DA FORM 3565, 1 JAN 72 AND DA FORM 3565-R(PAS), 26 SEP 75, WHICH ARE OBSOLETE.

ARMED FORCES INSTITUTE OF PATHOLOGY
Office of the Armed Forces Medical Examiner
1413 Research Blvd., Bldg. 102
Rockville, MD 20850
1-800-944-7912

FINAL AUTOPSY REPORT

Name: believed to be **Abed Mohamed Naiem**
SSAN: (b)(6)
Date of Birth: Unknown, appears to be 50+ yrs
Date of Death: (b)(6) 2003 (b)(6)
Date of Autopsy: 24 August 2003
Date of report: 29 September 2003

Autopsy No: (b)(6)
AFIP No.: (b)(6)
Rank: n/a
Place of Death: Abu Ghurayb Prison, Iraq
Place of Autopsy: 54th QM Co,
Baghdad Intl Airport, Iraq

Circumstances of Death: Other prisoners brought the decedent forward to the prison gate complaining of chest pain. He reportedly participated in a fast that day. Medics responded within 5 minutes and began CPR because there was no pulse or blood pressure. A physician arrived 30 minutes after patient presentation and he began intravenous glucagon and D50 solution because of a history of diabetes (taking oral Glibenese) as reported by (b)(6) a prisoner in the camp. By this time pupils were fixed and dilated, and the decedent remained pulseless throughout resuscitation attempts. No body temperature was recorded in the records available for review. The remains were ritually washed by prisone (b)(6) prior to transport to the mortuary.

Authorization for Autopsy: Office of the Armed Forces Medical Examiner, IAW 10 US Code 1471

Identification: Positive identification not established because antemortem exemplars are unavailable. Postmortem dental exam and x-rays, DNA specimen and fingerprints obtained for possible future reference.

CAUSE OF DEATH: Atherosclerotic cardiovascular disease complicated by diabetes

MANNER OF DEATH: Natural

FINAL AUTOPSY DIAGNOSES:

I. Atherosclerotic cardiovascular disease
- 80% stenosis of the proximal left anterior descending coronary artery
- Atheromatous aorta

II. Diabetes
III. Moderate decomposition
IV. No evidence of trauma
V. Toxicological examination (in mg/dL)

	Acetaldehyde	ethanol	acetone	1-propanol
• Cavity blood	6	36	Trace	Trace
• Bile		39	Trace	Trace

- Cavity blood positive for lidocaine (drug used in resuscitation attempts.)

ACLU Detainee DeathII ARMY MEDCOM 33

ME (b)(6) (b)(6)
believed to be **Abed Mohamed Najem**

EXTERNAL EXAMINATION

The body is that of a well-developed, well-nourished appearing 68 inch tall, 200 pounds (estimated), Middle Eastern male whose appearance is an estimated 50 plus years; date of birth is unknown. Decomposition is moderate, consisting of skin slippage, marbling, bloating, bloody purge, foul odor and green discoloration of the torso. Lividity is inapparent. Rigor is passed, and the temperature is cold.

The scalp is covered with black straight hair in a normal distribution, and the face has a full beard and mustache. The iris color is difficult to ascertain because of corneal clouding, but appeared to be brown, and the pupils are round and equal in diameter. The external auditory canals are free of blood or abnormal secretions. The ears are unremarkable. The nares are patent and the lips are atraumatic. The nose and maxilla are palpably stable. The teeth appear natural and in poor repair.

The neck is straight, and the trachea is midline and mobile. The chest is symmetric. The abdomen is protuberant, but decompresses following the initial incision. The genitalia are those of a normal adult male. The testes are descended and free of masses. Pubic hair is present in a normal distribution. The buttocks and anus are unremarkable.

The upper and lower extremities are symmetric and without clubbing or edema.

CLOTHING AND PERSONAL EFFECTS

The following clothing items and personal effects are present on the body at the time of autopsy:

- None, the body is unclad.

MEDICAL INTERVENTION

- None.

RADIOGRAPHS

X-rays are unavailable at this location.

EVIDENCE OF INJURY

No injuries are seen following a complete postmortem examination.

INTERNAL EXAMINATION

HEAD:
The entire brain was too decomposed for adequate examination, being in a semi-liquid state. There are no skull fractures. The atlanto-occipital joint is stable.

NECK:

ACLU Detainee DeathII ARMY MEDCOM 34

The anterior strap muscles of the neck are homogenous and red-brown, without hemorrhage. The thyroid cartilage and hyoid are intact. The larynx is lined by intact white mucosa. The thyroid is symmetric and red-brown, without cystic or nodular change. The tongue is free of bite marks, hemorrhage, or other injuries. There is no soot staining of the larynx or the trachea.

Incision and dissection of the posterior neck demonstrates no deep paracervical muscular injury and no cervical spine fractures.

BODY CAVITIES:
The ribs, sternum, and vertebral bodies are visibly and palpably intact. No excess fluid is in the pericardial or peritoneal cavities. There is 100 mL of decomposition fluid in each hemithorax. The organs occupy their usual anatomic positions.

RESPIRATORY SYSTEM:
The right and left lungs weigh 320 gm and 250 gm, respectively. The external surfaces are smooth and deep red-purple. The pulmonary parenchyma is diffusely congested and edematous. No mass lesions or areas of consolidation are present.

CARDIOVASCULAR SYSTEM:
The 250 gm heart is contained in an intact pericardial sac. The epicardial surface is smooth, with minimal fat investment. The coronary arteries are present in a normal distribution, with a right-dominant pattern. Cross sections of the vessels show 80% stenosis of the proximal left anterior descending coronary artery. The myocardium is homogenous, red-brown, and soft. The valve leaflets are thin and mobile. The wall thickness of the left and right ventricles are not measured due to decompositional changes. The endocardium is smooth and glistening. The aorta gives rise to three intact and patent arch vessels and has significant involvement with atheromatous plaques throughout its length, significantly worse in the distal abdominal aorta. The renal and mesenteric vessels are unremarkable.

LIVER & BILIARY SYSTEM:
The 1240 gm liver has an intact, smooth capsule and a sharp anterior border. The parenchyma is tan-brown with a slight yellow discoloration, with the usual lobular architecture. No mass lesions or other abnormalities are seen. The gallbladder contains a minute amount of green-black bile and no stones. The mucosal surface is green and velvety. The extrahepatic biliary tree is patent.

SPLEEN:
The 90 gm spleen has a smooth, intact, red-purple capsule. The parenchyma is maroon and diffluent, without discernible Malpighian corpuscles.

PANCREAS:
The pancreas is autolyzed and yellow-tan, with the usual lobular architecture. No mass lesions or other abnormalities are seen.

ADRENALS:
The right and left adrenal glands are symmetric, with bright yellow cortices and autolyzed grey medullae. No masses or areas of hemorrhage are identified.

ACLU Detainee DeathII ARMY MEDCOM 35

ME (b)(6) (b)(6)
believed to be **Abed Mohamed Najem**

GENITOURINARY SYSTEM:
The right and left kidneys weigh 70 gm and 90 gm, respectively. The external surfaces are intact and granular, with a pigskin texture. There are multiple small cysts in each kidney. The cut surfaces are red-tan and congested, with uniformly thick cortices and sharp corticomedullary junctions. The pelves are unremarkable and the ureters are normal in course and caliber. White bladder mucosa overlies an intact bladder wall. The bladder contains no urine. The prostate is normal in size, with nodular, yellow-tan parenchyma. The seminal vesicles are unremarkable. The testes are free of mass lesions, contusions, or other abnormalities.

GASTROINTESTINAL TRACT:
The esophagus is intact and lined by smooth, grey-white mucosa. The stomach contains only scant, pasty, grey material. The gastric wall is intact. The duodenum, loops of small bowel, and colon are unremarkable. The appendix is present and there are cecal adhesions.

ADDITIONAL PROCEDURES

- Documentary photographs are taken by OAFME photographer (b)(6)
- No trace evidence is collected.
- Specimens retained for toxicologic testing and/or DNA identification are: cavity blood, liver, spleen, semiliquid brain, bile, and psoas muscles.
- The dissected organs are forwarded with body.

MICROSCOPIC EXAMINATION

Selected portions of organs are retained in formalin, without preparation of histologic slides.

OPINION

This Middle Eastern male, believed to be (b)(6) died as a result of atherosclerotic cardiovascular disease complicated by diabetes. The manner of death is natural.

(b)(6)

Armed Forces Medical Examiner System

ACLU Detainee DeathII ARMY MEDCOM 36

(b)(6)

CERTIFICATE OF DEATH *(OVERSEAS)*
Acte de décès *(D'Outre-Mer)*

NAME OF DECEASED *(Last, First, Middle)* Nom du décédé (Nom et prénoms)	GRADE Grade	BRANCH OF SERVICE Arme	SOCIAL SECURITY NUMBER Numéro de l'Assurance Sociale
3TB Abed, Mohamed, Najem			

ORGANIZATION Organisation	NATION *(e.g., United States)* Pays	DATE OF BIRTH Date de naissance	SEX Sexe
Detainee in Iraq	Iraq		☑ MALE Masculin ☐ FEMALE Féminin

RACE Race	MARITAL STATUS État Civil	RELIGION Culte
☒ CAUCASOID Caucasique	☐ SINGLE Célibataire	☐ PROTESTANT Protestant
☐ NEGROID Negroide	☐ MARRIED Marié	☐ CATHOLIC Catholique
☐ OTHER (Specify) Autre (Spécifier)	☐ WIDOWED Veuf	☐ JEWISH Juif
	☐ DIVORCED Divorcé	☐ OTHER (Specify) Autre (Spécifier)
	☐ SEPARATED Séparé	

NAME OF NEXT OF KIN Nom du plus proche parent	RELATIONSHIP TO DECEASED Parenté du décédé avec le susdit
STREET ADDRESS Domicile à (Rue)	CITY OR TOWN AND STATE *(Include ZIP Code)* Ville (Code postal compris)

MEDICAL STATEMENT Déclaration médicale

CAUSE OF DEATH *(Enter only once cause per line)* Cause du décès (N'indiquer qu'une cause par ligne)			INTERVAL BETWEEN ONSET AND DEATH Intervalle entre l'attaque et le décès
DISEASE OR CONDITION DIRECTLY LEADING TO DEATH[1] Maladie ou condition directement responsable de la mort[1]		Atherosclerotic cardiovascular disease complicated by diabetes	
ANTECEDENT CAUSES Symptômes précurseurs de la mort.	MORBID CONDITION, IF ANY, LEADING TO PRIMARY CAUSE Condition morbide, s'il y a lieu, menant à la cause primaire		
	UNDERLYING CAUSE, IF ANY, GIVING RISE TO PRIMARY CAUSE Raison fondamentale, s'il y a lieu, ayant suscité la cause primaire		
OTHER SIGNIFICANT CONDITIONS[2] Autres conditions significatives[2]			

MODE OF DEATH Condition de décès	AUTOPSY PERFORMED Autopsie effectuée	CIRCUMSTANCES SURROUNDING DEATH DUE TO EXTERNAL CAUSES Circonstances de la mort suscitées par des causes extérieures
☒ NATURAL Mort naturelle	☑ YES Oui ☐ NO Non	
☐ ACCIDENT Mort accidentelle	MAJOR FINDINGS OF AUTOPSY Conclusions principales de l'autopse	
☐ SUICIDE Suicide	NAME OF PATHOLOGIST Nom du pathologiste (b)(6)	
☐ HOMICIDE Homicide	DATE Date 24 Aug 2003	AVIATION ACCIDENT Accident à Avion ☐ YES Oui ☑ NO Non

DATE OF DEATH *(Hour, day, month, year)* Date du décès *(l'heure, le jour, le mois, l'année)*	PLACE OF DEATH Lieu de décès
(b)(6) 2003	Abu Ghurayb Prison, Iraq

I HAVE VIEWED THE REMAINS OF THE DECEASED AND DEATH OCCURRED AT THE TIME INDICATED AND FROM THE CAUSES AS STATED ABOVE.
J'ai examiné les restes mortels du dé funtet je conclus que le décès est survenu à l'heure indiquée et à, la suite des causes énumérées ci-dessus.

NAME OF MEDICAL OFFICER Nom du médicin militaire ou du médicin sanitaire	TITLE OR DEGREE Titre ou diplôme
(b)(6)	

GRADE Grade	INSTALLATION OR ADDRESS Installation ou adresse
(b)(6)	Dover AFB, DE 19902
DATE Date 14MAY04	(b)(6)

[1] State disease, injury or complication which caused death.
[2] State conditions contributing to the death, but not related to the disease or condition causing death.
[1] Préciser la nature de la maladie, de la blessure ou de la complication qui a contribué à la mort, mais non la manière de mourir, telle qu'un arrêt du coeur, etc.
[2] Préciser la condition qui a contribué à la mort, mais n'ayant aucun rapport avec la maladie ou à la condition qui a provoqué la mort.

DD FORM 1 APR 77 **2064** REPLACES DA FORM 3565, 1 JAN 72 AND DA FORM 3565-RIPAS, 26 SEP 75, WHICH ARE OBSOLETE.

ACLU Detainee DeathII ARMY MEDCOM 37

ARMED FORCES INSTITUTE OF PATHOLOGY
Office of the Armed Forces Medical Examiner
1413 Research Blvd., Bldg. 102
Rockville, MD 20850
1-800-944-7912

FINAL AUTOPSY REPORT

Name: believed to be **Hamza Hassad Twfeek Najm Byaty Al-Zubydy**

SSAN: n/a, Enemy PW (b)(6)
Date of Birth: Unknown, appears middle aged
Date of Death: (b)(6) 2003 (b)(6)
Date of Autopsy: 24 August 2003
Date of report: 29 September 2003

Autopsy No: (b)(6)
AFIP No. (b)(6)
Rank: n/a
Place of Death: Diwania, Iraq
Place of Autopsy: 54th QM Co, Baghdad Intl. Airport, Iraq

Circumstances of Death: The decedent was an enemy prisoner of war detainee at the Biap prison who was being transported in a bus when he became short of breath, hypotensive and tachycardic. A medic with the 115th MP Battalion administered an IV bolus, which briefly improved his symptoms and signs, but he soon arrested. When examined later in the day by a physician, rigor and lividity were established, but "no visible markings, wounds, lesions, deformity" were seen. No body temperature was recorded in the records available for review.

Authorization for Autopsy: Office of the Armed Forces Medical Examiner, IAW 10 US Code 1471

Identification: Positive identification is not established because of a lack of antemortem exemplars. Postmortem dental exam and x-rays, DNA specimen and fingerprints are obtained for possible future reference.

CAUSE OF DEATH: Undetermined atraumatic cause

MANNER OF DEATH: Natural

FINAL AUTOPSY DIAGNOSES:

I. No evidence of significant natural disease, within the limitations of this autopsy.
II. No evidence of trauma
III. Toxicological examination
- Blood and urine were negative for ethanol
- Blood was negative for prescription and illicit drugs

EXTERNAL EXAMINATION

The body is that of a well-developed, well-nourished appearing 72 inch tall, 210 pounds (estimated), middle eastern male who appears middle aged. (Date of birth is unknown.). Lividity is inapparent due to postmortem changes. Rigor is passed, and the temperature is cold.

ACLU Detainee DeathII ARMY MEDCOM 38

The scalp is covered with black, straight, long hair in a normal distribution and there is a full beard and mustache. The irides are difficult to determine due to cloudy cornea, but appear brown, and the pupils are round and equal in diameter. The external auditory canals are free of blood and unusual secretions. The ears are unremarkable. The nares are patent and the lips are atraumatic. The nose and maxillae are palpably stable. The teeth appear natural and in fair repair.

The neck is straight, and the trachea is midline and mobile. The chest is symmetric. The abdomen is flat. The genitalia are those of a normal adult male. The testes are descended and free of masses. Pubic hair is present in a normal distribution. The buttocks and anus are unremarkable.

The upper and lower extremities are symmetric and without clubbing or edema.

CLOTHING AND PERSONAL EFFECTS

The following clothing items and personal effects are present on the body at the time of autopsy:

- Green knee-length shirt
- Buff colored boxer shorts

MEDICAL INTERVENTION

- A 500 mL bag of lactated Ringer's solution connected to an IV cannula that apparently fell out of the right antecubital fossa.

RADIOGRAPHS

Radiographs are unavailable at this location.

EVIDENCE OF INJURY

There is no evidence of injury following a complete postmortem examination.

Decompositional changes consist of skin slippage, marbling, foul odor and a green color to the anterior thorax and abdomen.

INTERNAL EXAMINATION

HEAD:
The galeal and subgaleal soft tissues of the scalp are free of injury. The calvarium is intact, as is the dura mater beneath it. Clear cerebrospinal fluid surrounds the 1400 gm brain, which has unremarkable gyri and sulci. Coronal sections demonstrate sharp demarcation between white and grey matter, without hemorrhage or contusive injury. The ventricles are of normal size. The basal ganglia, brainstem, cerebellum, and arterial systems are free of injury or other abnormalities. There are no skull fractures. The atlanto-occipital joint is stable.

NECK:
The anterior strap muscles of the neck are homogenous and red-brown, without hemorrhage. The thyroid cartilage and hyoid are intact. The larynx is lined by intact white mucosa. The thyroid is symmetric and red-brown, without cystic or nodular change. The tongue is free of bite marks, hemorrhage, or other injuries. There is no soot staining of the larynx or the trachea.

ACLU Detainee DeathII ARMY MEDCOM 39

Incision and dissection of the posterior neck demonstrates no deep paracervical muscular injury and no cervical spine fractures.

BODY CAVITIES:
The ribs, sternum, and vertebral bodies are visibly and palpably intact. No excess fluid is in the right pleural, pericardial, or peritoneal cavities, although there is scant decomposition fluid. The organs occupy their usual anatomic positions.

RESPIRATORY SYSTEM:
The right and left lungs weigh 950 gm and 1050 gm, respectively. The external surfaces are smooth and deep red-purple. The pulmonary parenchyma is diffusely congested and edematous. No mass lesions or areas of consolidation are present.

CARDIOVASCULAR SYSTEM:
The 270 gm heart is contained in an intact pericardial sac. The epicardial surface is smooth, with minimal fat investment. The coronary arteries are present in a normal distribution, with a right-dominant pattern. Cross sections of the vessels show no significant atherosclerotic cardiovascular disease. The myocardium is homogenous, red-brown, and firm. The valve leaflets are thin and mobile. The endocardium is smooth and glistening. The aorta gives rise to three intact and patent arch vessels. The renal and mesenteric vessels are unremarkable.

LIVER & BILIARY SYSTEM:
The 1250 gm liver has an intact, smooth capsule and a sharp anterior border. The parenchyma is tan-brown and congested, with the usual lobular architecture. No mass lesions or other abnormalities are seen. The gallbladder contains 15 mL of green-black bile and no stones. The mucosal surface is green and velvety. The extrahepatic biliary tree is patent.

SPLEEN:
The 260 gm spleen has a smooth, intact, red-purple capsule. The parenchyma is maroon and diffluent, with indistinct Malpighian corpuscles.

PANCREAS:
The pancreas is firm and yellow-tan, with the usual lobular architecture. No mass lesions or other abnormalities are seen.

ADRENALS:
The right and left adrenal glands are symmetric, with bright yellow cortices and grey medullae. No masses or areas of hemorrhage are identified.

GENITOURINARY SYSTEM:
The right and left kidneys weigh 75 gm and 75 gm, respectively. The external surfaces are intact and smooth. The cut surfaces are red-tan and congested, with uniformly thick cortices and sharp corticomedullary junctions. The pelves are unremarkable and the ureters are normal in course and caliber. White bladder mucosa overlies an intact bladder wall. The bladder contains approximately 170 mL of hazy, pink urine. The prostate is normal in size, with nodular, yellow-tan parenchyma.

ACLU Detainee DeathII ARMY MEDCOM 40

ME (b)(6) (b)(6)
believed to be **Hamza Hassad Twfeek Najm Byaty Al-Zubydy**

The seminal vesicles are unremarkable. The testes are free of mass lesions, contusions, or other abnormalities.

GASTROINTESTINAL TRACT:
The esophagus is intact and lined by smooth, grey-white mucosa. The stomach contains approximately 100 mL of grey, pasty, partially digested, unrecognizable food. The gastric wall is intact. The duodenum, loops of small bowel, and colon are unremarkable. The appendix is present.

ADDITIONAL PROCEDURES

- Documentary photographs are taken by OAFME photographer (b)(6)
- No trace evidence is collected.
- Specimens retained for toxicologic testing and/or DNA identification are: cavity blood, liver, spleen, urine, gastric contents, brain, bile, and psoas muscles.
- The dissected organs are forwarded with the body.

MICROSCOPIC EXAMINATION

Selected portions of organs are retained in formalin, without preparation of histologic slides.

OPINION

This Middle Eastern male, believed to be (b)(6) died as a result of an unknown non-traumatic and nontoxic cause. The manner of death is natural.

(b)(6)

Armed Forces Medical Examiner System

MEDCOM 0041
ACLU Detainee DeathII ARMY MEDCOM 41

(b)(6)

CERTIFICATE OF DEATH *(OVERSEAS)*
Acte de décès *(D'Outre-Mer)*

NAME OF DECEASED *(Last, First, Middle)* Nom du décédé (Nom et prénoms)	GRADE Grade	BRANCH OF SERVICE Arme	SOCIAL SECURITY NUMBER Numéro de l'Assurance Sociale
3TBHamza Hassad, Twfeek Najm, Byaty Al-Zubydy			

ORGANIZATION Organisation	NATION *(e.g., United States)* Pays	DATE OF BIRTH Date de naissance	SEX Sexe
Detainee in Iraq	Iraq		☑ MALE Masculin ☐ FEMALE Feminin

RACE Race	MARITAL STATUS État Civil	RELIGION Culte
☒ CAUCASOID Caucasique	☐ SINGLE Célibataire ☐ DIVORCED Divorcé	☐ PROTESTANT Protestant ☐ OTHER (Specify) Autre (Spécifier)
☐ NEGROID Negroide	☐ MARRIED Marié	☐ CATHOLIC Catholique
☐ OTHER (Specify) Autre (Spécifier)	☐ WIDOWED Veuf ☐ SEPARATED Séparé	☐ JEWISH Juif

NAME OF NEXT OF KIN Nom du plus proche parent	RELATIONSHIP TO DECEASED Parenté du décédé avec le susdit
STREET ADDRESS Domicile à (Rue)	CITY OR TOWN AND STATE *(Include ZIP Code)* Ville (Code postal compris)

MEDICAL STATEMENT Déclaration médicale

CAUSE OF DEATH *(Enter only once cause per line)* Cause du décès (N'indiquer qu'une cause par ligne)		INTERVAL BETWEEN ONSET AND DEATH Intervalle entre l'attaque et le décès
DISEASE OR CONDITION DIRECTLY LEADING TO DEATH[1] Maladie ou condition directement responsable de la mort[1]	Undeterminded atraumatic cause	
ANTECEDENT CAUSES Symptômes précurseurs de la mort — MORBID CONDITION, IF ANY, LEADING TO PRIMARY CAUSE Condition morbide, s'il y a lieu, menant à la cause primaire		
ANTECEDENT CAUSES Symptômes précurseurs de la mort — UNDERLYING CAUSE, IF ANY, GIVING RISE TO PRIMARY CAUSE Raison fondamentale, s'il y a lieu, ayant suscité la cause primaire		
OTHER SIGNIFICANT CONDITIONS[2] Autres conditions significatives[2]		

MODE OF DEATH Condition de décès	AUTOPSY PERFORMED Autopsie effectuée	CIRCUMSTANCES SURROUNDING DEATH DUE TO EXTERNAL CAUSES Circonstances de la mort suscitées par des causes extérieures
☒ NATURAL Mort naturelle	☑ YES Oui ☐ NO Non	
☐ ACCIDENT Mort accidentelle	MAJOR FINDINGS OF AUTOPSY Conclusions principales de l'autopsie	
☐ SUICIDE Suicide	NAME OF PATHOLOGIST Nom du pathologiste: (b)(6)	
☐ HOMICIDE Homicide	DATE Date: 24 Aug 2003	AVIATION ACCIDENT Accident à Avion ☐ YES Oui ☑ NO Non

DATE OF DEATH *(Hour, day, month, year)* Date du décès (l'heure, le jour, le mois, l'année)	PLACE OF DEATH Lieu de décès
(b)(6) 2003	Diwania, Iraq

I HAVE VIEWED THE REMAINS OF THE DECEASED AND DEATH OCCURRED AT THE TIME INDICATED AND FROM THE CAUSES AS STATED ABOVE.
J'ai examiné les restes mortels du dé funt et je conclus que le décès est survenu à l'heure indiquée et à, la suite des causes énumérées ci-dessus.

NAME OF MEDICAL OFFICER Nom du médicin militaire ou du médicin sanitaire	TITLE OR DEGREE Titre ou diplôme
(b)(6)	Armed Forces Medical Examiner

GRADE Grade	INSTALLATION OR ADDRESS Installation ou adresse
(b)(6)	Dover AFB, DE 19902 (b)(6)

DATE Date: 14MAY04

[1] State disease, injury or complication which
[2] State conditions contributing to the death, b
[1] Préciser la nature de la maladie, de la blessure ou de la complication qui a contribué à la mort, mais non la manière de mourir, telle qu'un arrêt du cœur, etc.
[2] Préciser la condition qui a contribué à la mort, mais n'ayant aucun rapport avec la maladie ou à la condition qui a provoqué la mort.

DD FORM 1 APR 77 2064 REPLACES DA FORM 3565, 1 JAN 72 AND DA FORM 3565-RIPAS), 26 SEP 75, WHICH ARE OBSOLETE.

ARMED FORCES INSTITUTE OF PATHOLOGY
Office of the Armed Forces Medical Examiner
1413 Research Blvd., Bldg. 102
Rockville, MD 20850
1-800-944-7912

AUTOPSY EXAMINATION REPORT

Name: Dababa, Dilar
SSAN: n/a
Date of Birth: unknown
Date of Death: (b)(6) 2003
Date of Autopsy: 17 June 2003
Date of Report: 11 May 2004

Autopsy No.: (b)(6)
AFIP No.: (b)(6)
Rank: Civilian, Iraqi national
Place of Death: Iraq
Place of Autopsy: Baghdad International Airport, Baghdad, Iraq

Circumstances of Death: This approximately 45 year-old civilian Iraq male detainee died in U.S. custody approximately 12 hours after a reported escape attempt by the decedent. Physical force was required to subdue the detainee, and during the restraining process, his forehead hit the ground.

Authorization for Autopsy: The Armed Forces Medical Examiner, IAW 10 USC 1471.

Identification: Visual; Fingerprints and DNA samples obtained

CAUSE OF DEATH: Closed Head Injury with a Cortical Brain Contusion and Subdural Hematoma

MANNER OF DEATH: Homicide

ACLU Detainee DeathII ARMY MEDCOM 43

FINAL AUTOPSY DIAGNOSES:

I. Closed Head Injury
   a. Subarachnoid hemorrhage over brain
   b. Cortical brain contusion, right occipital region, 4 x 4 x 3 cm
      i. Intracortical hemorrhage with fresh erythrocytes, fibrin, and polymorphonuclear leukocytes
      ii. Negative for fibroblasts, macrophages, capillary proliferation, hemosiderin or iron
   c. Right subdural hematoma, 20 ml
      i. Fresh erythrocytes, fibrin, and polymorphonuclear leukocytes
      ii. Negative for fibroblasts, macrophages, capillary proliferation, hemosiderin or iron
   d. No skull fractures
   e. Left frontal subgaleal hemorrhage with scalp laceration
      i. Status post suturing of laceration

II. Additional Injuries
   a. Fracture right lateral 8th rib with soft tissue hemorrhage
   b. Multiple contusions, abrasions, and minor lacerations of head, torso, and extremities
   c. Abrasions and contusions around wrists and ankles, consistent with restraint
   d. Hemorrhage of right sternocleidomastoid muscle of neck
      i. Hyoid bone intact without hemorrhage or fracture

III. No evidence of natural disease within the limitations of the examination

IV. Toxicology: AFIP
   a. Volatiles: Blood and urine negative for ethanol
   b. Drugs: Urine positive for lidocaine; negative for all other screened medications and drugs of abuse

ACLU Detainee DeathII ARMY MEDCOM 44

EXTERNAL EXAMINATION

The body is that of a well developed, well nourished unclad adult male, received in a black body bag labeled with a tag "BTB: (b)(6) The body weighs approximately 150 lbs, is 66" in height and appears compatible with the reported age of approximately 45 years. The body temperature is that of the refrigeration unit. Rigor is present to an equal degree in all extremities. Lividity is present and fixed on the posterior surface of the body, except in areas exposed to pressure.

The scalp is covered with black hair averaging 2 cm in length. There is a black mustache and black facial stubble. The irides are brown, and the cornea are clear. The sclerae and conjunctivae are pale and free of petechiae. The earlobes are not pierced. The external auditory canals and external nares are free of foreign material and abnormal secretions. The nasal skeleton is palpably intact. The lips are without evident injury. There is bloody fluid within the mouth, but no injuries are identified within the oral cavity. The teeth are natural and in good condition. Below the chin is a 1.5 cm well healed linear scar.

The neck is straight and the trachea is midline and mobile. The chest is symmetric and well developed. The abdomen is flat and soft. The extremities are well developed with normal range of motion. The fingernails are intact. No tattoos are evident. The external genitalia are those of a normal adult circumcised male. The testes are descended and free of masses. Pubic hair is present in a normal distribution. The buttocks and anus are unremarkable.

CLOTHING AND PERSONAL EFFECTS

No clothing items or personal effects are present on the body at the time of autopsy.

EVIDENCE OF THERAPY

There is an endotracheal tube appropriately placed. There is white tape with gauze in both antecubital fossae, overlying needle puncture marks and associated ecchymoses. There are needle puncture marks with associated ecchymoses on the upper anterior forearm. There are three EKG adhesive pads, two on the upper chest and one on the mid abdomen. There are three stitches placed in a laceration of the left forehead. In the left inguinal region, there is a 1 cm incised wound, consistent with a venous access attempt.

EVIDENCE OF INJURY

The ordering of the following injuries is for descriptive purposes only and is not intended to imply order of infliction or relative severity.

Head and Neck:

On the upper midline of the forehead, just below the hairline is a horizontally oriented 4 x 2 cm abrasion. On the upper left aspect of the forehead, there is a 1.5 cm previously sutured incision with a surrounding 3 x 2 cm abrasion. On the upper right aspect of the

ACLU Detainee DeathII ARMY MEDCOM 45

forehead, there is a 3 x 2 cm abrasion. At the right lateral edge of the right eye, extending up to the eyebrow and laterally along the orbital ridge, there is a 6 x 5 cm red contusion with focal abrasion along the bony prominence. On the right cheek, there is a central horizontally oriented 3 x 1 cm red contusion. On the upper lateral aspect of the left cheek, there is a horizontally oriented 3 x 1.5 cm abrasion. On the lower medial aspect of the right cheek, there are two 0.3 cm abrasions.

Above the left ear, at the crease between the pinna and the scalp, there is a 1 cm laceration. Behind the left ear, there is a 3 x 2 cm purple contusion. On the left lateral aspect of the neck, extending from behind the left ear anteriorly along the edge of the mandible, there is a 15 x 13 cm red contusion. Behind the right ear, there is diffuse erythema of the posterior aspect of the pinna and a 4 x 3 cm dark contusion. On the right lateral aspect of the neck, extending from behind the right ear anteriorly along the edge of the mandible, there is a 14 x 10 cm area with multiple small curvilinear abrasions and contusions, up to 0.5 cm in length. On the left anterior aspect of the neck, there is a diagonal 13 x 1.5 cm linear abrasion.

Across the back of the neck, there is a 25 x 10 cm area of diffuse erythema. Within this area, on the right lateral aspect of the neck, there are three horizontally oriented linear abrasions; a 2 x 2 cm superior abrasion, a mid 3 x 2 cm abrasion, and a 3 x 1 cm lower abrasion.

Upon reflection of the scalp, there is a 3 x 2 cm area of subgaleal hemorrhage of the left frontal region, surrounding the laceration. Upon removal of the calvarium, there is approximately 20 ml of clotted but soft and non-adherant subdural hemorrhage over the right side of the brain. There is diffuse subarachnoid hemorrhage over the brain. Serial sectioning of the brain reveals a 4 x 4 x 3 cm area of intracortical brain hemorrhage in the right occipital brain.

On internal examination of the neck, there is diffuse hemorrhage of the right sternocleidomastoid muscle. However, there is no hemorrhage of the anterior strap muscles of the neck, and the hyoid bone is intact and free of hemorrhage.

Chest and Abdomen:

On the anterior and lateral aspect of the right shoulder, there is a 10 x 13 cm irregular area of abrasion. Over the right clavicle, there are two diagonal 7 x 0.3 cm linear abrasions. Just below the left clavicle, there is a 4 x 2 cm irregular abrasion. On the anterior left shoulder, there is a 3 x 3 cm red contusion.

Over the mid chest, there is a 30 x 20 cm area of mottled erythema and red contusion. Within this area, over the sternum, there is a 7 x 5 cm red abrasion with focal linearity. On the lower left aspect of the chest, there is a diagonal 7 x 0.2 cm linear abrasion.

ACLU Detainee DeathII ARMY MEDCOM 46

On the mid abdomen, just above the umbilicus, there is a healing 5 x 0.1 cm abrasion. On the lower abdomen, just to the right of midline, there is a 1.5 x 1 cm abrasion. On the lower left abdomen, there is a 1.5 x 1 cm abrasion.

On internal examination of the chest, there is a fracture of the lateral aspect of the right 8th rib with associated soft tissue hemorrhage.

Back:

Across the upper back, there is a horizontal 45 x 5 cm linear red contusion. At the left lateral edge of this band, there is a 4 x 2 cm abrasion on the posterior aspect of the shoulder. On the left lateral aspect of the upper back, there are two linear abrasions, 2 x 0.2 cm each.

Upper Extremities:

On the lower anterior aspect of the right upper arm, there are two linear abrasions, 2 x 0.2 cm each. On the back of the right elbow, there is a 9 x 4 cm red contusion.

Around the right wrist, there is a complex nearly circumferential abrasion. On the radial aspect (base of the thumb) of the wrist, there is a 4 x 8 cm abrasion. On the ulnar aspect (below the 5th finger) of the wrist, there is a 5 x 1.5 cm abrasion. Connecting these two abrasions and extending around the palmar aspect of the wrist are two linear bands of contusion with focal abrasion, 0.5 cm in width each. On the back of the right hand, below the 4th and 5th fingers, there is a diagonal 3 x 0.2 cm abrasion and a 3 x 0.1 cm abrasion.

On the lower anterior aspect of the left upper arm, there is a 1 x 1 cm abrasion. On the back of the left elbow, there is an 8 x 7 cm red purple contusion. On the anterior mid left forearm, there is a 1 x 1 cm abrasion.

Around the left wrist, there is nearly circumferential contusion. On the radial aspect (base of the thumb) of the wrist, there is a 3 x 4 cm abrasion. On the ulnar aspect (below the 5th finger) of the wrist, there is a 4 x 4 cm abrasion. Connecting these two abrasions, extending around the dorsal aspect of the wrist are two linear bands of contusion with focal abrasion, 0.3 cm in width each.

Lower Extremities:

On the anterior medial aspect of the mid right thigh, there is a 3 x 3 cm triangular shaped abrasion. On the anterior aspect of the lower right thigh, just above the knee, there is a 1 x 1 cm abrasion and a medial 7 x 5 cm red contusion. On the medial aspect of the knee there is a 1 x 1 cm abrasion. Just below the right knee, there is a 2 x 2 cm abrasion. Over the right popliteal fossa (back of the knee), there is a 15 x 10 cm red contusion.

ACLU Detainee DeathII ARMY MEDCOM 47

Extending down the anterior aspect of the right lower leg, there is a vertically oriented 20 x 5 cm red contusion. Around the right ankle is a circumferential abrasion, ranging in width from 1 to 1.5 cm.

Just above the left knee, there is a 5 x 4 cm red contusion. On the lateral aspect of the left knee, there are three 1 cm abrasions, and on the lower mid aspect of the knee, there is a 3 x 2 cm abrasion. Just below the knee, there is a 2 x 1 cm abrasion. Over the left popliteal fossa (back of the knee), there is a 15 x 5 cm red contusion with a 3 x 4 cm abrasion at the lower edge.

Extending down the anterior aspect of the left lower leg, there is a vertically oriented 17 x 5 cm red contusion. Around the left ankle, there are two circumferential abrasions, 1 cm in width each and 1 cm apart. On the medial aspect of the left ankle, there is a 1 x 1.5 cm abrasion.

INTERNAL EXAMINATION

BODY CAVITIES:
The body is opened by the usual thoraco-abdominal incision and the chest plate is removed. No adhesions or abnormal collections of fluid are present in any of the body cavities. All body organs are present in the normal anatomical position. The vertebral bodies are visibly and palpably intact. The subcutaneous fat layer of the abdominal wall is 3 cm thick. There is no internal evidence of blunt force or penetrating injury to the thoraco-abdominal region.

HEAD: (CENTRAL NERVOUS SYSTEM)
The head has the previously described injuries. The scalp is reflected, and there are no skull fractures found. The calvarium of the skull is removed. The dura mater and falx cerebri are intact. There is no epidural hemorrhage present. The leptomeninges are thin and delicate. The cerebral hemispheres are symmetrical. The structures at the base of the brain, including cranial nerves and blood vessels, are intact. Coronal sections through the cerebral hemispheres reveal no evidence of infection or tumor. The ventricles are of normal size. Transverse sections through the brain stem and cerebellum are unremarkable. The dura is stripped from the basilar skull, and no fractures are found. The atlanto-occipital joint is stable. The brain weighs 1400 grams. (see "Neuropathology Report").

NECK:
The neck has the previously described hemorrhage of the right sternocleidomastoid muscle. Examination of the other soft tissues of the neck, including strap muscles, thyroid gland and large vessels, reveals no abnormalities. All other anterior strap muscles of the neck are homogeneous and red-brown, without hemorrhage. The thyroid cartilage and hyoid bone are intact. The larynx is lined by intact white mucosa and is unobstructed. The thyroid gland is symmetric and red-brown, without cystic or nodular change. There is no evidence of infection or tumor, and the airway is patent. Incision and dissection of the posterior neck

ACLU Detainee DeathII ARMY MEDCOM 48

demonstrates no deep paracervical muscular injury, hemorrhage, or fractures of the dorsal spinous processes.

CARDIOVASCULAR SYSTEM:
The pericardial surfaces are smooth, glistening and unremarkable: the pericardial sac is free of significant fluid and adhesions. A moderate amount of epicardial fat is present. The coronary arteries arise normally, follow a right dominant distribution and are widely patent, without evidence of significant atherosclerosis or thrombosis. The chambers and valves exhibit the usual size-position relationship and are unremarkable. The myocardium is dark red-brown, firm and unremarkable: the atrial and ventricular septa are intact. The left ventricle is 1.5 cm in thickness and the right ventricle is 0.4 cm in thickness. The aorta and its major branches arise normally, follow the usual course and are widely patent, free of significant atherosclerosis and other abnormality. The venae cavae and their major tributaries return to the heart in the usual distribution and are free of thrombi. The heart weighs 375 grams.

RESPIRATORY SYSTEM:
The upper airway is clear of debris and foreign material: the mucosal surfaces are smooth, yellow-tan and unremarkable. The pleural surfaces are smooth, glistening and unremarkable bilaterally. The pulmonary parenchyma is red-purple, exuding a moderate amount of bloody fluid; no focal lesions are noted. The pulmonary arteries are normally developed, patent and without thrombus or embolus. The right lung weighs 650 grams; the left 600 grams.

LIVER & BILIARY SYSTEM:
The hepatic capsule is smooth, glistening and intact, covering dark red-brown, moderately congested parenchyma with no focal lesions noted. The gallbladder contains 10 ml of green-brown, mucoid bile; the mucosa is velvety and unremarkable. The extrahepatic biliary tree is patent, without evidence of calculi. The liver weighs 2,000 grams.

ALIMENTARY TRACT:
The tongue is free of bite marks, hemorrhage, or other injuries. The esophagus is lined by gray-white, smooth mucosa. The gastric mucosa is arranged in the usual rugal folds, and the lumen contains approximately 20 ml of dark fluid. The small and large bowel are unremarkable. The pancreas has a normal pink-tan lobulated appearance and the ducts are clear. The appendix is present and is unremarkable.

GENITOURINARY SYSTEM:
The renal capsules are smooth and thin, semi-transparent and strip with ease from the underlying smooth, red-brown cortical surfaces. The cortices are sharply delineated from the medullary pyramids, which are red-purple to tan and unremarkable. The calyces, pelves and ureters are unremarkable. White bladder mucosa overlies an intact bladder wall. The urinary bladder contains 50 ml. of dark yellow urine. The prostate gland is normal in size, with lobular, yellow-tan parenchyma. The seminal vesicles are unremarkable. The testes are free of mass lesions, contusions, or other abnormalities. The right and left kidneys each weigh 175 grams.

ACLU Detainee DeathII ARMY MEDCOM 49

RETICULOENDOTHELIAL SYSTEM:
The spleen has a smooth, intact capsule covering red-purple, moderately firm parenchyma; the lymphoid follicles are unremarkable. The regional lymph nodes appear normal. The spleen weighs 300 grams.

ENDOCRINE SYSTEM:
The pituitary, thyroid and adrenal glands are unremarkable.

MUSCULOSKELETAL SYSTEM:
Muscle development is normal. No bone or joint abnormalities are noted.

MICROSCOPIC EXAMINATION

BRAIN: See "Neuropathology Report" below.

HEART: Sections of the myocardium reveal intact striated muscle fibers. There is no evidence of atrophy, hypertrophy, or recent or old myocardial infarction.

LUNGS: The alveolar spaces and small air passages are expanded and contain no significant inflammatory component or edema fluid. The alveolar walls are thin and not congested. The arterial and venous vascular systems are normal. The peribronchial lymphatics are unremarkable.

LIVER: The hepatic architecture is intact. The portal areas show no increased inflammatory component or fibrous tissue. The hepatic parenchymal cells are well-preserved with mild microvesicular and macrovesicular steatosis and focal cholestasis. There is focal benign nodule formation, and there are no sinusoidal abnormalities.

SPLEEN: The capsule and white pulp are unremarkable. There is minimal congestion of the red pulp.

KIDNEYS: The subcapsular zones are unremarkable. The glomeruli are mildly congested without cellular proliferation, mesangial prominence, or sclerosis. The tubules are well preserved. There is no interstitial fibrosis or significant inflammation. There is no thickening of the walls of the arterioles or small arterial channels. The transitional epithelium of the collecting system is normal.

Neuropathology Report (AFIP, Department of Neuropathology, Washington, D.C.)

"The principle neuropathologic findings are subarachnoid, subdural, and intracortical hemorrhage. The hemorrhages consist of fresh erythrocytes, fibrin, and polymorphonuclear leukocytes. We do not identify fibroblasts, macrophages, capillary proliferation, or hemosiderin on H&E. An iron stain is also negative for hemosiderin.

ACLU Detainee DeathII ARMY MEDCOM 50

The histologic features in this case indicate a hemorrhage of less than 48 hours duration. It is not possible histologically to be more specific.

The gross description of a left frontal skull lesion combined with a right occipital cortical lesion is consistent with a contrecoup contusion; the intracortical hemorrhages are also indicative of a contusion. We identify no other significant neuropathological changes."

ADDITIONAL PROCEDURES

- Documentary photographs are taken by OAFME photographers
- Specimens retained for toxicologic testing and/or DNA identification are: vitreous fluid, heart blood, urine, bile, and psoas muscle
- The dissected organs are forwarded with the body

OPINION

This approximately 45 year-old male civilian Iraqi detainee died of a closed head injury with a cortical brain contusion and a subdural hemotoma while in U.S. custody. These injuries reportedly occurred when he hit his forehead while being subdued following an escape attempt, and the right occipital cortical brain hemorrhage is consistent with a recent contrecoup contusion.

The manner of death is homicide.

(b)(6)

(b)(6) **Medical Examiner**

ACLU Detainee DeathII ARMY MEDCOM 51

DEPARTMENT OF DEFENSE
ARMED FORCES INSTITUTE OF PATHOLOGY
WASHINGTON, DC 20306-6000

REPLY TO ATTENTION OF

AFIP (b)(6)

TO:

OFFICE OF THE ARMED FORCES MEDICAL EXAMINER
ARMED FORCES INSTITUTE OF PATHOLOGY
WASHINGTON, DC 20306-6000

PATIENT IDENTIFICATION
AFIP Accessions Number Sequence
(b)(6)
Name
DABABA, DILAR

SSAN Autopsy: (b)(6)
Toxicology Accession # (b)(6)

JULY 7, 2003

CONSULTATION REPORT ON CONTRIBUTOR MATERIAL

AFIP DIAGNOSIS REPORT OF TOXICOLOGICAL EXAMINATION

Specimens Received: BLOOD, URINE, BILE AND VITREOUS FLUID
Condition of Specimens: GOOD
Date of Incident: (b)(6) 2003 **Date Received:** 6/24/2003

VOLATILES: The **BLOOD AND URINE** were examined for the presence of ethanol at a cutoff of 20 mg/dL. No ethanol was detected.

DRUGS: The **URINE** was screened for acetaminophen, amphetamine, antidepressants, antihistamines, barbiturates, benzodiazepines, cannabinoids, cocaine, dextromethorphan, lidocaine, narcotic analgesics, opiates, phencyclidine, phenothiazines, salicylates, sympathomimetic amines and verapamil by gas chromatography, color test or immunoassay. The following drugs were detected:

Positive Lidocaine: Lidocaine was detected in the urine by gas chromatography and confirmed by gas chromatography/mass spectrometry.

(b)(6)
Office of the Armed Forces Medical Examiner

(b)(6)
Office of the Armed Forces Medical Examiner

ACLU Detainee DeathII ARMY MEDCOM 52

(b)(6)

CERTIFICATE OF DEATH *(OVERSEAS)*
Acte de décès *(D'Outre-Mer)*

NAME OF DECEASED *(Last, First, Middle)* *Nom du décédé (Nom et prénoms)*	GRADE Grade	BRANCH OF SERVICE Arme	SOCIAL SECURITY NUMBER Numéro de l'Assurance Sociale
BTB Dababa, Dilar			

ORGANIZATION Organisation	NATION *(e.g., United States)* Pays	DATE OF BIRTH Date de naissance	SEX Sexe
Detainee in Iraq	Iraq		☑ MALE Masculin ☐ FEMALE Féminin

RACE Race	MARITAL STATUS État Civil	RELIGION Culte
☒ CAUCASOID Caucasique	☐ SINGLE Célibataire	☐ PROTESTANT Protestant
☐ NEGROID Negroide	☐ MARRIED Marié	☐ CATHOLIC Catholique
☐ OTHER (Specify) Autre (Spécifier)	☐ WIDOWED Veuf	☐ JEWISH Juif
	☐ DIVORCED Divorcé	☐ OTHER (Specify) Autre (Spécifier)
	☐ SEPARATED Séparé	

NAME OF NEXT OF KIN Nom du plus proche parent	RELATIONSHIP TO DECEASED Parenté du décédé avec le susdit
STREET ADDRESS Domicile à (Rue)	CITY OR TOWN AND STATE *(Include ZIP Code)* *Ville (Code postal compris)*

MEDICAL STATEMENT Déclaration médicale

CAUSE OF DEATH *(Enter only once cause per line)* Cause du décès (N'indiquer qu'une cause par ligne)		INTERVAL BETWEEN ONSET AND DEATH Intervalle entre l'attaque et le décès
DISEASE OR CONDITION DIRECTLY LEADING TO DEATH[1] Maladie ou condition directement responsable de la mort[1]	Closed Head Injury with a Cortical Brain Contusion and Subdural Hematoma	
ANTECEDENT CAUSES Symptômes précurseurs de la mort, MORBID CONDITION, IF ANY, LEADING TO PRIMARY CAUSE Condition morbide, s'il y a lieu, menant à la cause primaire		
ANTECEDENT CAUSES Symptômes précurseurs de la mort, UNDERLYING CAUSE, IF ANY, GIVING RISE TO PRIMARY CAUSE Raison fondamentale, s'il y a lieu, ayant suscité la cause primaire		
OTHER SIGNIFICANT CONDITIONS[2] Autres conditions significatives[2]		

MODE OF DEATH Condition de décès	AUTOPSY PERFORMED Autopsie effectuée ☑ YES Oui ☐ NO Non	CIRCUMSTANCES SURROUNDING DEATH DUE TO EXTERNAL CAUSES Circonstances de la mort suscitées par des causes extérieures
☐ NATURAL Mort naturelle	MAJOR FINDINGS OF AUTOPSY Conclusions principales de l'autopsie	
☐ ACCIDENT Mort accidentelle		
☐ SUICIDE Suicide	NAME OF PATHOLOGIST Nom du pathologiste (b)(6)	
☒ HOMICIDE Homicide	DATE Date 17 Jun 2003	AVIATION ACCIDENT Accident d'Avion ☐ YES Oui ☑ NO Non

DATE OF DEATH *(Hour, day, month, year)* Date du décès *(l'heure, le jour, le mois, l'année)*	PLACE OF DEATH Lieu du décès
(b)(6) 2003	Iraq

I HAVE VIEWED THE REMAINS OF THE DECEASED AND DEATH OCCURRED AT THE TIME INDICATED AND FROM THE CAUSES AS STATED ABOVE.
J'ai examiné les restes mortels du dé funt et je conclus que le décès est survenu à l'heure indiquée et à, la suite des causes énumérées ci-dessus.

NAME OF MEDICAL OFFICER Nom du médicin militaire ou du médicin sanitaire	TITLE OR DEGREE Titre ou diplôme
(b)(6)	Medical Examiner

GRADE Grade	INSTALLATION OR ADDRESS Installation ou adresse
(b)(6)	Dover AFB, DE 19902
DATE Date 14 May 04	(b)(6)

[1] *State disease, injury or complication which caused death, but not mode of dying such as heart failure, etc.*
[2] *State conditions contributing to the death, but not related to the disease or condition causing death.*
[1] *Préciser la nature de la maladie, de la blessure ou de la complication qui a contribué à la mort, mais non la manière de mourir, telle qu'un arrêt du coeur, etc*
[2] *Préciser la condition qui a contribué à la mort, mais n'ayant aucun rapport avec la maladie ou à la condition qui a provoqué la mort.*

DD FORM 1 APR 77 **2064** REPLACES DA FORM 3545, 1 JAN 72 AND DA FORM 3545-R(PAS), 26 SEP 75, WHICH ARE OBSOLETE.

ARMED FORCES INSTITUTE OF PATHOLOGY
Office of the Armed Forces Medical Examiner
1413 Research Blvd., Bldg. 102
Rockville, MD 20850
1-800-944-7912

AUTOPSY EXAMINATION REPORT

Name: BTB Mohamed Tariq Zaid

Autopsy No.: ME (b)(6)
(Mission# (b)(6)
AFIP No. (b)(6)

SSAN: NA
Date of Birth: Unknown
Date/Time of Death: (b)(6) 2003
Date/Time of Autopsy: 25 Aug 2003
Date of Report: 23 October 2003

Rank: NA
Place of Death: Iraq
Place of Autopsy: Camp Sather, Iraq

Circumstances of Death: (b)(6) was an enemy prisoner of war in US custody who on or about (b)(6) August was noted to be lying on the ground with shallow respiration and decreased sweating. Emergency medical services were summoned and (b)(6) was noted to have an axillary temperature of 102 degrees and decreased oxygen saturation. Attempts at intravenous access were unsuccessful and fluids were administered transrectally. He was transported to Kadamiya University Hospital where he was pronounced dead on arrival.

Authorization for Autopsy: Armed Forces Medical Examiner, per 10 U.S. Code 1471

Identification: Presumptive by Army Criminal Investigative Division (CID). Antemortem fingerprint, dental, and DNA unavailable.

CAUSE OF DEATH: Heat related

MANNER OF DEATH: Accident

FINAL AUTOPSY DIAGNOSES:

I. Heat stroke
   A. Antemortem axillary temperature 102 degrees, clinical
   B. Intravascular volume depletion, clinical
   C. Pulmonary congestion (1650 grams)
      1. Hypoxia, clinical

II. Mild decomposition

ACLU Detainee DeathII ARMY MEDCOM 55

EXTERNAL EXAMINATION

The body is that of a well-developed, well-nourished appearing, muscular, 68 inch tall, 180-200 pounds (estimated) male whose appearance is consistent with an estimated age of greater than 40 years. Lividity is posterior, purple, and fixed. Rigor is absent.

There is early decomposition indicated by mild skin slippage, corneal and scleral drying, and decomposition fluid (30 and 20 mls) in the pleural cavities.

The scalp is covered with black hair in a normal distribution. Corneal clouding obscures the irides and the pupils. The external auditory canals are unremarkable. The ears are unremarkable. The nares are patent and the lips are atraumatic. The nose and maxillae are palpably stable. The teeth appear natural and adequate in repair.

The neck is straight, and the trachea is midline and mobile. The chest is symmetric. The abdomen is flat. The genitalia are those of a normal adult male. The testes are descended and free of masses. Pubic hair is present in a normal distribution. The buttocks and anus are unremarkable.

The upper and lower extremities are symmetric and without clubbing or edema.

CLOTHING AND PERSONAL EFFECTS

None.

MEDICAL INTERVENTION

- Endotracheal tube
- Rectal catheter connected to normal saline
- Intravenous puncture marks of antecubital fossae

EVIDENCE OF INJURY

The ordering of the following injuries is for descriptive purposes only, and is not intended to imply order of infliction or relative severity. All wound pathways are given relative to standard anatomic position.

INJURY: On the anterior forearm is a circular 0.3 cm red abrasion.

INTERNAL EXAMINATION

HEAD:
The galeal and subgaleal soft tissues of the scalp are free of injury. The calvarium is intact, as is the dura mater beneath it. Clear cerebrospinal fluid surrounds the 1300 gm

ACLU Detainee DeathII ARMY MEDCOM 56

brain, which has unremarkable gyri and sulci. Coronal sections demonstrate sharp demarcation between white and grey matter, without hemorrhage or contusive injury. The ventricles are of normal size. The basal ganglia, brainstem, cerebellum, and arterial systems are free of injury or other abnormalities. There are no skull fractures. The atlanto-occipital joint is stable.

NECK:
The anterior strap muscles of the neck are homogenous and red-brown, without hemorrhage. The thyroid cartilage and hyoid are intact. The larynx is lined by intact white mucosa. The thyroid is symmetric and red-brown, without cystic or nodular change. The tongue is free of bite marks, hemorrhage, or other injuries.

BODY CAVITIES:
The ribs, sternum, and vertebral bodies are visibly and palpably intact. There are 30 ml and 20 ml of thin oily liquid in the right and left pleural cavities, respectively. The organs occupy their usual anatomic positions.

RESPIRATORY SYSTEM:
The right and left lungs weigh 850 and 800 gm, respectively. The external surfaces are smooth and deep red-purple. The pulmonary parenchyma is diffusely congested and edematous. No mass lesions or areas of consolidation are present.

CARDIOVASCULAR SYSTEM:
The 300 gm heart is contained in an intact pericardial sac. The epicardial surface is smooth, with minimal fat investment. The coronary arteries are present in a normal distribution, with a right-dominant pattern. Cross sections of the vessels show no stenosis or arteriosclerotic change. The myocardium is homogenous, red-brown, and firm. The valve leaflets are thin and mobile. The walls of the left and right ventricles are 1.5 and 0.6 cm thick, respectively. The endocardium is smooth and glistening. The aorta gives rise to three intact and patent arch vessels. The renal and mesenteric vessels are unremarkable.

LIVER & BILIARY SYSTEM:
The 1150 gm liver has an intact, smooth capsule and a sharp anterior border. The parenchyma is tan-brown and congested, with the usual lobular architecture. No mass lesions or other abnormalities are seen. The gallbladder contains approximately 20 ml of black bile and no stones. The mucosal surface is green and velvety. The extrahepatic biliary tree is patent.

SPLEEN:
The 150 gm spleen has a smooth, intact, red-purple capsule. The parenchyma is maroon and congested, with distinct Malpighian corpuscles.

PANCREAS:
The pancreas is firm and yellow-tan, with the usual lobular architecture. No mass lesions or other abnormalities are seen.

ACLU Detainee DeathII ARMY MEDCOM 57

ADRENALS:
The right and left adrenal glands are symmetric, with bright yellow cortices and grey medullae. No masses or areas of hemorrhage are identified.

GENITOURINARY SYSTEM:
The right and left kidneys weigh 150 gm, each. The external surfaces are intact and smooth. The cut surfaces are red-tan and congested, with uniformly thick cortices and sharp corticomedullary junctions. The pelves are unremarkable and the ureters are normal in course and caliber. White bladder mucosa overlies an intact bladder wall. The bladder contains approximately 20 ml of yellow-brown concentrated urine. The prostate is normal in size, with lobular, yellow-tan parenchyma. The seminal vesicles are unremarkable. The testes are free of mass lesions, contusions, or other abnormalities.

GASTROINTESTINAL TRACT:
The esophagus is intact and lined by smooth, grey-white mucosa. The stomach is devoid of contents. The gastric wall is intact. The duodenum, loops of small bowel, and colon are unremarkable. The appendix is present and is unremarkable.

ADDITIONAL PROCEDURES

- Documentary photographs are taken by (b)(6)
- The autopsy is conducted in the presence of Special Agent (b)(6) of the (b)(2) CID)
- Specimens retained for toxicologic testing and/or DNA identification are: blood, liver, kidney, brain, bile, and psoas
- The dissected organs are forwarded with body
- Personal effects are released to the appropriate mortuary operations representatives of the (b)(2)

MICROSCOPIC EXAMINATION

Selected portions of organs are retained in formalin, without preparation of histologic slides.

TOXICOLOGY

Toxicologic analysis of bile and liver was negative for ethanol (alcohol) and illicit substances.

ACLU Detainee DeathII ARMY MEDCOM 58

OPINION

This Iraqi prisoner of war died of heat stroke. The clinical presentation of an axillary temperature of 102 degrees, dehydration, hypoxia, and obtundation, along with non-specific autopsy findings and the lack of significant natural disease or trauma are supportive of heat stroke. Temperatures in the area were reported to be grater than 110 degrees. No significant internal or external trauma was noted. No illicit substances or ethanol was detected.

The manner of death is accident.

(b)(6)

(b)(6) Medical Examiner

CERTIFICATE OF DEATH *(OVERSEAS)*
Acte de décès *(D'Outre-Mer)*

NAME OF DECEASED *(Last, First, Middle)* Nom du décédé (Nom et prénoms)	GRADE Grade	BRANCH OF SERVICE Arme	SOCIAL SECURITY NUMBER Numéro de l'Assurance Sociale
BTB Mohamed, Tariq, Zaid			

ORGANIZATION Organisation	NATION *(e.g., United States)* Pays	DATE OF BIRTH Date de naissance	SEX Sexe
Detainee in Iraq	Iraq		☑ MALE Masculin ☐ FEMALE Féminin

RACE Race		MARITAL STATUS État Civil			RELIGION Culte		
X	CAUCASOID Caucasique		SINGLE Célibataire		DIVORCED Divorcé		PROTESTANT Protestant		OTHER (Specify) Autre (Spécifier)
	NEGROID Negroide		MARRIED Marié		SEPARATED Séparé		CATHOLIC Catholique		
	OTHER (Specify) Autre (Spécifier)		WIDOWED Veuf				JEWISH Juif		

NAME OF NEXT OF KIN Nom du plus proche parent	RELATIONSHIP TO DECEASED Parenté du décédé avec le susdit
STREET ADDRESS Domicile à (Rue)	CITY OR TOWN AND STATE *(Include ZIP Code)* Ville *(Code postal compris)*

MEDICAL STATEMENT Déclaration médicale

CAUSE OF DEATH *(Enter only once cause per line)* Cause du décès (N'indiquer qu'une cause par ligne)		INTERVAL BETWEEN ONSET AND DEATH Intervalle entre l'attaque et le décès
DISEASE OR CONDITION DIRECTLY LEADING TO DEATH[1] Maladie ou condition directement responsable de la mort[1]	Heat related	
ANTECEDENT CAUSES Symptômes précurseurs de la mort — MORBID CONDITION, IF ANY, LEADING TO PRIMARY CAUSE Condition morbide, s'il y a lieu, menant à la cause primaire		
ANTECEDENT CAUSES Symptômes précurseurs de la mort — UNDERLYING CAUSE, IF ANY, GIVING RISE TO PRIMARY CAUSE Raison fondamentale, s'il y a lieu, ayant suscité la cause primaire		
OTHER SIGNIFICANT CONDITIONS[2] Autres conditions significatives[2]		

MODE OF DEATH Condition de décès	AUTOPSY PERFORMED Autopsie effectuée	CIRCUMSTANCES SURROUNDING DEATH DUE TO EXTERNAL CAUSES Circonstances de la mort suscitées par des causes extérieures
☐ NATURAL Mort naturelle	☑ YES Oui ☐ NO Non	
X ACCIDENT Mort accidentelle	MAJOR FINDINGS OF AUTOPSY Conclusions principales de l'autopsie	
☐ SUICIDE Suicide	NAME OF PATHOLOGIST Nom du pathologiste (b)(6)	
☐ HOMICIDE Homicide	DATE Date 23 Oct 2003	AVIATION ACCIDENT Accident à Avion ☐ YES Oui ☑ NO Non

DATE OF DEATH *(Hour, day, month, year)* Date du décès (l'heure, le jour, le mois, l'année)	PLACE OF DEATH Lieu du décès
(b)(6) 2003	Iraq

I HAVE VIEWED THE REMAINS OF THE DECEASED AND DEATH OCCURRED AT THE TIME INDICATED AND FROM THE CAUSES AS STATED ABOVE
J'ai examiné les restes mortels du dé funt je conclus que le décès est survenu à l'heure indiquée et à la suite des causes énumérées ci-dessus.

NAME OF MEDICAL OFFICER Nom du médicin militaire ou du médicin sanitaire	TITLE OR DEGREE Titre ou diplôme
(b)(6)	Medical Examiner

GRADE Grade	INSTALLATION OR ADDRESS Installation ou adresse
(b)(6)	Dover AFB, DE 19902
DATE Date 12 May 2004	(b)(6)

[1] State disease, injury or complication which
[2] State conditions contributing to the death, but not related to the disease or condition causing death.
[1] Préciser la nature de la maladie, de la blessure ou de la complication qui a contribué à la mort, mais non la manière de mourir, telle qu'un arrêt du coeur, etc
[2] Préciser la condition qui a contribué à la mort, mais n'ayant aucun rapport avec la maladie ou à la condition qui a provoqué la mort.

DD FORM 1 APR 77 2064 REPLACES DA FORM 3565, 1 JAN 72 AND DA FORM 3565-R(PAS), 26 SEP 75, WHICH ARE OBSOLETE.

ACLU Detainee DeathII ARMY MEDCOM 60

ARMED FORCES INSTITUTE OF PATHOLOGY
Office of the Armed Forces Medical Examiner
1413 Research Blvd., Bldg. 102
Rockville, MD 20850
1-800-944-7912

AUTOPSY EXAMINATION REPORT

Name: Mihdy, Wathik
Prisoner#: (b)(6)
Date of Birth: unknown
Date of Death: (b)(6) 2003
Date of Autopsy: 23 Aug 2003
Date of Report: 19 May 2004

Autopsy No.: (b)(6)
AFIP No.: (b)(6)
Rank: NA
Place of Death: Abu Ghraib Prison, Iraq
Place of Autopsy: BIAP, Iraq

Circumstances of Death: According to reports, other detainees brought this Iraqi male detainee to the gate. He had apparently complained of chest pain during his detention. He appeared to have been dead for some time.

Authorization for Autopsy: Office of the Armed Forces Medical Examiner, IAW 10 USC 1471

Identification: By prisoner number, DNA sample and fingerprints obtained

CAUSE OF DEATH: Arteriosclerotic cardiovascular disease

MANNER OF DEATH: Natural

ACLU Detainee DeathII ARMY MEDCOM 61

FINAL AUTOPSY DIAGNOSES:

I. Arteriosclerotic cardiovascular disease
   A. Left anterior descending coronary artery
      1. Segmental 80% stenosis of the proximal segment
      2. 80% focal stenosis of the mid segment
   B. Right coronary artery
      1. 50% multifocal stenoses of the proximal segment
      2. 50-75% multifocal stenoses of the distal segment
   C. Mild to moderate atherosclerosis of the proximal aorta
   D. Focal 90% stenosis of the basilar artery of the brain
II. Cholelithiasis, incidental
III. Early decomposition
IV. No significant trauma
V. Toxicology negative for ethanol and drugs of abuse

ACLU Detainee DeathII ARMY MEDCOM 62

EXTERNAL EXAMINATION

The body is that of a 65 inches tall, 180 pounds (estimated) Iraqi male who appears to be older than 50 years. Lividity is posterior and fixed, and rigor is absent. The body is partially frozen.

The scalp is covered with gray-black hair in a normal distribution. There is a beard and mustache. Corneal clouding obscures the irides and pupils. There are no petechiae of the sclerae, conjuctival, or buccal mucosa. The external auditory canals are unremarkable. The ears are unremarkable. The nares are patent and the lips are atraumatic. The nose and maxillae are palpably stable. The teeth appear natural and are in poor repair.

The neck is straight, and the trachea is midline and mobile. The chest is symmetric. The abdomen is flat. The genitalia are those of a normal adult male. The testes are descended and free of masses. Pubic hair is present in a normal distribution. The buttocks and anus are unremarkable.

The upper and lower extremities are symmetric and without clubbing or edema.

There is early decomposition consisting of corneal clouding, superficial skin slippage on the buttocks and right calf, and slight green discoloration of the skin.

CLOTHING AND PERSONAL EFFECTS

The following clothing items and personal effects are present on the body at the time of autopsy:
The body is received nude at the time of autopsy.

MEDICAL INTERVENTION

There are no attached medical devices at the time of autopsy.

EVIDENCE OF INJURY

The ordering of the following injuries is for descriptive purposes only, and is not intended to imply order of infliction or relative severity. All wound pathways are given relative to standard anatomic position.

On the skin of the right knee is a 0.4 cm superficial red abrasion. On the anterior left ankle is a 0.3 cm crusted healing superficial wound.

INTERNAL EXAMINATION

HEAD:
The galeal and subgaleal soft tissues of the scalp are free of injury. The calvarium is intact, as is the dura mater beneath it. Clear cerebrospinal fluid surrounds the 1300 gm brain, which has unremarkable gyri and sulci. Coronal sections demonstrate sharp demarcation between white and grey matter, without hemorrhage or contusive injury.

ACLU Detainee DeathII ARMY MEDCOM 63

The ventricles are of normal size. The basal ganglia, brainstem, and cerebellum are free of injury or other abnormalities. There is a focal 90% stenosis of the basilar artery without plaque hemorrhage, rupture, or thrombosis. There are no skull fractures. The atlanto-occipital joint is stable.

NECK:
Layerwise neck dissection reveals the anterior strap muscles of the neck are homogenous and red-brown, without hemorrhage. The thyroid cartilage and hyoid are intact. The larynx is lined by intact white mucosa. The thyroid is symmetric and red-brown, without cystic or nodular change. The tongue is free of bite marks, hemorrhage, or other injuries.

Incision and dissection of the posterior neck demonstrates no deep paracervical muscular injury and no cervical spine fractures.

BODY CAVITIES:
The ribs, sternum, and vertebral bodies are visibly and palpably intact. Each pleural cavity contains approximately 10 ml of decomposition fluid. The organs occupy their usual anatomic positions.

RESPIRATORY SYSTEM:
The right and left lungs weigh 550 and 425 gm, respectively. The external surfaces are smooth and deep red-purple. The pulmonary parenchyma is diffusely congested and edematous. No mass lesions or areas of consolidation are present.

CARDIOVASCULAR SYSTEM:
The 250 gm heart is contained in an intact pericardial sac. The epicardial surface is smooth, with minimal fat investment. The coronary arteries are present in a normal distribution, with a right-dominant pattern. Cross sections of the vessels show the left anterior descending coronary artery has approximate 80% segmental stenosis of the proximal segment and 80% focal stenosis of the mid segment. The right coronary artery has multi-focal 50% stenoses of the proximal segment and 50-75% multifocal stenoses of the distal segment. The myocardium is homogenous, red-purple, and soft. The valve leaflets are thin and mobile. The walls of the left and right ventricles are 1.5 and 0.3-cm thick, respectively. The septum measures 1.5 cm in thickness. The endocardium is smooth and glistening. The aorta gives rise to three intact and patent arch vessels. There is mild to moderate atherosclerosis of the proximal aorta. The renal and mesenteric vessels are unremarkable.

LIVER & BILIARY SYSTEM:
The 1300 gm liver has an intact, smooth capsule and a sharp anterior border. The parenchyma is tan-brown and congested, with the usual lobular architecture. No mass lesions or other abnormalities are seen. The gallbladder contains a minute amount of green-black bile and multi-faceted black stones. The mucosal surface is green and velvety. The extrahepatic biliary tree is patent.

ACLU Detainee DeathII ARMY MEDCOM 64

SPLEEN:
The 50 gm spleen has a smooth, intact, red-purple capsule. The parenchyma is maroon and congested, with distinct Malpighian corpuscles.

PANCREAS:
The pancreas is firm and yellow-tan, with the usual lobular architecture. No mass lesions or other abnormalities are seen.

ADRENALS:
The right and left adrenal glands are symmetric, with bright yellow cortices and grey medullae. No masses or areas of hemorrhage are identified.

GENITOURINARY SYSTEM:
The right and left kidneys weigh 50 gm each and maintain fetal lobulation. The external surfaces are intact and smooth. The cut surfaces are red-tan and congested, with uniformly thick cortices and sharp corticomedullary junctions. The pelves are unremarkable and the ureters are normal in course and caliber. White bladder mucosa overlies an intact, empty bladder. The prostate is normal in size, with lobular, yellow-tan parenchyma. The seminal vesicles are unremarkable. The testes are free of mass lesions, contusions, or other abnormalities

GASTROINTESTINAL TRACT:
The esophagus is intact and lined by autolyzed, grey-white mucosa. The stomach contains less than 10 ml of red straw-colored liquid. The gastric wall is intact. The duodenum, loops of small bowel, and colon are unremarkable. The appendix is present and unremarkable.

ADDITIONAL PROCEDURES

- Documentary photographs are taken by (b)(6)
- Specimens retained for toxicologic testing and/or DNA identification are: vitreous, blood, liver, brain, kidney, and psoas
- The dissected organs are forwarded with the body
- Personal effects are released to the appropriate mortuary operations representatives

MICROSCOPIC EXAMINATION

Selected portions of organs are retained in formalin, without preparation of histologic slides.

TOXICOLOGY

Toxicologic analysis of blood and liver was negative for ethanol and drugs of abuse.

ACLU Detainee DeathII ARMY MEDCOM 65

OPINION

This Iraqi male detainee died of arteriosclerotic cardiovascular disease (ASCVD). Significant findings of the autopsy included blockages in the blood vessels supplying blood to the heart and the base of the brain. The reported history of complaining of chest pain prior to death is supportive of a cardiovascular death. There were no significant injuries.

The manner of death is natural.

(b)(6)

(b)(6) Medical Examiner

ACLU Detainee DeathII ARMY MEDCOM 66

DEPARTMENT OF DEFENSE
ARMED FORCES INSTITUTE OF PATHOLOGY
WASHINGTON, DC 20306-6000

REPLY TO ATTENTION OF

AFIP (b)(6)

PATIENT IDENTIFICATION
AFIP Accessions Number Sequence
(b)(6)

TO:

OFFICE OF THE ARMED FORCES MEDICAL EXAMINER
ARMED FORCES INSTITUTE OF PATHOLOGY
WASHINGTON, DC 20306-6000

Name
MIDHY, WATHIK

SSAN **Autopsy:** EPW #1
Toxicology Accession # (b)(6)

SEPTEMBER 15, 2003

CONSULTATION REPORT ON CONTRIBUTOR MATERIAL

AFIP DIAGNOSIS **REPORT OF TOXICOLOGICAL EXAMINATION**

Specimens Received: BLOOD, LIVER, KIDNEY, BRAIN, MUSCLE AND VITREOUS FLUID
Condition of Specimens: GOOD
Date of Incident (b)(6) 2003 **Date Received:** 8/27/2003

VOLATILES: The **BLOOD AND LIVER** were examined for the presence of ethanol at a cutoff of 20 mg/dL. No ethanol was detected.

DRUGS: The **BLOOD** was screened for acetaminophen, amphetamine, antidepressants, antihistamines, barbiturates, benzodiazepines, cannabinoids, cocaine, dextromethorphan, lidocaine, narcotic analgesics, opiates, phencyclidine, phenothiazines, salicylates, sympathomimetic amines and verapamil by gas chromatography, color test or immunoassay. The following drugs were detected:

None were found.

(b)(6)
Office of the Armed Forces Medical Examiner

(b)(6)
Office of the Armed Forces Medical Examiner

ACLU Detainee DeathII ARMY MEDCOM 67

ARMED FORCES INSTITUTE OF PATHOLOGY
Office of the Armed Forces Medical Examiner
1413 Research Blvd., Bldg. 102
Rockville, MD 20850
1-800-944-7912

FINAL AUTOPSY REPORT

Name: HUSSEIN, BASIM MOHAMMED Autopsy No.: AFME(b)(6)
PW Number: (b)(6)
Date of Birth: (b)(6) 1977
Date/Time of Death: (b)(6) 2003/(b)(6)
Place of Death: EPW Camp, Baghdad International Airport, Baghdad, Iraq
Date/Time of Autopsy: 13 July 2003/1300
Place of Autopsy: Mortuary, Baghdad International Airport, Baghdad, Iraq

Circumstances of Death: The decedent was a 26 year-old Iraq detainee who was arrested upon suspicion of possession of a pipe bomb on (b)(6) 2003. He was brought to the detention center on the Baghdad International Airport Compound on (b)(6) 2003. He reportedly had a long history of pulmonary tuberculosis and was evaluated by a US military physician upon arrival and provided treatment. On (b)(6) 2003 at approximately 0500, he was found in the detention center with a profuse amount of blood emerging from the nose and mouth. Resuscitative efforts were to no avail and death was pronounced at approximately 0515 on (b)(6) 2003.

Authorization for Autopsy: Regional Armed Forces Medical Examiner

Identification: PW Bracelet and Tags

CLINICAL DIAGNOSES:

1. Hemoptysis
2. Death in Custody

PATHOLOGIC DIAGNOSES:

A. RESPIRATORY SYSTEM:
   1. Hemoptysis secondary to Pulmonary Tuberculosis
      a. Cavitary Lesion of Left Lung
      b. Multiple Caseating Granulomata- Left Lung
      c. Blood Within Tracheobronchial Tree
      d. Focal Consolidation- Bilateral Lungs
      e. Bilateral Pleural Adhesions

B. CARDIOVASCULAR SYSTEM
   1. Pericardial Effusion- 30 cc.

ACLU Detainee DeathII ARMY MEDCOM 68

C. GENITOURINARY SYSTEM
1. Absent Right Testicle

D. NO EVIDENCE OF SIGNIFICANT TRAUMA

CAUSE OF DEATH: MASSIVE HEMOPTYSIS DUE TO CAVITARY PULMONARY TUBERCULOSIS

MANNER OF DEATH: NATURAL

ACLU Detainee DeathII ARMY MEDCOM 69

EXTERNAL EXAMINATION

An autopsy was performed on the body of (b)(6) at the Baghdad International airport compound morgue, Baghdad Iraq, on the 13th day of July, 2003. The body was that of a well-developed, thin, Caucasoid male fully clad in gray pants and a tan shirt. The body was cold. Rigor was present to an equal degree in all extremities. Lividity was present and fixed on the posterior surfaces of the body, except in areas exposed to pressure. The scalp hair was back and straight. Facial hair consisted of a beard. The irides were brown. The corneae were clear. The conjunctivae were unremarkable without petechiae. The sclerae were white. The external auditory canals were free of foreign material and abnormal secretions. Blood emerged from the external nares and oral cavity. The nasal skeleton was palpably intact. The lips were without evident injury. The teeth were natural and in poor condition. Examination of the neck revealed no evidence of injury. The chest was unremarkable. No evidence of injury of the ribs or the sternum was evident externally. The abdomen was scaphoid. No healed surgical scars were noted. The extremities showed no evidence of fractures, lacerations or deformities. The fingernails were intact. No tattoos or needle tracks were observed. The external genitalia were those of a normal adult male. The posterior torso was without note. No evidence of medical therapy was noted.

EVIDENCE OF INJURY:
There is no evidence of significant recent injury.

INTERNAL EXAMINATION

BODY CAVITIES:
The body was opened by the usual thoraco-abdominal incision and the chest plate was removed. Extensive adhesions were noted within the hemithoraces bilaterally. Fluid was present within the pericardial sac as noted below. All body organs were present in the normal anatomical position. The subcutaneous fat layer of the abdominal wall was ½ inch thick. There was no internal evidence of blunt force or penetrating injury to the thoraco-abdominal region.

HEAD: (Central Nervous System)
The scalp was reflected. The calvarium of the skull was removed. The dura mater and falx cerebri were intact. There was no epidural or subdural hemorrhage present. The leptomeninges were thin and delicate. The cerebral hemispheres were symmetrical. The structures at the base of the brain, including cranial nerves and blood vessels were intact. Coronal sections through the cerebral hemispheres revealed no lesions. Transverse sections through the brain stem and cerebellum were unremarkable. The brain weighed 1800 grams.

ACLU Detainee DeathII ARMY MEDCOM 70

NECK:
A separate layerwise dissection of the neck was performed. Examination of the soft tissues of the neck, including strap muscles, thyroid gland and large vessels, revealed no abnormalities. The hyoid bone and larynx were intact.

CARDIOVASCULAR SYSTEM:
The pericardial surfaces were smooth, glistening and unremarkable; the pericardial sac was free of adhesions. 30 cc of clear green fluid was present in the pericardial sac. The coronary arteries arose normally, followed the usual distribution and were widely patent, without evidence of significant atherosclerosis or thrombosis. The chambers and valves exhibited the usual size-position relationship and were unremarkable. The myocardium was dark red-brown, firm and unremarkable; the atrial and ventricular septa were intact. The heart weighed 250 grams. The aorta and its major branches arose normally, followed the usual course and were widely patent, free of significant atherosclerosis and other abnormality. The venae cavae and its major tributaries returned to the heart in the usual distribution and were free of thrombi.

RESPIRATORY SYSTEM:
The upper airway was clear of debris. Blood was noted within the tracheobronchial tree, but the mucosal surfaces were otherwise smooth and unremarkable. As noted above, extensive adhesions were present in the hemithoraces bilaterally. The right lung weighed 500 grams and was red-purple. No discrete lesions were noted. The left lung also weighed 500 grams. The lower lobe contained a 6 cm cavity with surrounding white, caseating nodules ranging in size from 2-5 mm. The left upper lobe contained a similar 4 cm cavity. These cavities had smooth walls and contained a small amount of blood. No discrete connection with any vascular structure was noted, but both cavities communicated with the tracheobronchial tree. The pulmonary parenchyma of the left lung was red-purple. The pulmonary arteries were normally developed, patent and without thrombus or embolus.

LIVER AND BILIARY SYSTEM:
The hepatic capsule was smooth, glistening and intact, covering dark red-brown, moderately congested parenchyma with no focal lesions noted. The liver weighed 1350 grams. The gallbladder contained 10 cc. of green-brown, mucoid bile; the mucosa was velvety and unremarkable. The extrahepatic biliary tree was patent, without evidence of calculi.

ALIMENTARY SYSTEM:
The tongue exhibited no evidence of recent injury. The esophagus was lined by gray-white, smooth mucosa. The gastric mucosa was arranged in the usual rugal folds and the lumen contained small amount of brown mucoid material. The small and large bowel were unremarkable. The pancreas had a normal pink-tan lobulated appearance and the ducts were clear. The appendix was not identified.

ACLU Detainee DeathII ARMY MEDCOM 71

GENITOURINARY SYSTEM:
The renal capsules were smooth and thin, semi-transparent and stripped with ease from the underlying smooth, red-brown cortical surface. The cortex was sharply delineated from the medullary pyramids, which were red-purple to tan and unremarkable. The calyces, pelves and ureters were unremarkable. The right kidney weighed 140 grams; the left 140 grams. The urinary bladder contained approximately 10 cc of clear yellow urine; the mucosa was gray-tan and smooth. The prostate gland and seminal vesicles were without note. The right testicle was not identified. The left testicle was atraumatic.

RETICULOENDOTHELIAL SYSTEM:
The spleen had a smooth, intact capsule covering red-purple, moderately firm parenchyma; the lymphoid follicles were unremarkable. The spleen weighed 120 grams. The regional lymph nodes appeared normal.

ENDOCRINE SYSTEM:
The pituitary, thyroid and adrenal glands were unremarkable.

MUSCULOSKELETAL SYSTEM:
Muscle development was normal. No bone or joint abnormalities were noted other noted above. Incisions were made into the soft tissues of the back and lower extremities and no evidence of hemorrhage was noted.

OPINION:
This 26-year-old Iraqi male died as the result of massive hemoptysis (bleeding into the tracheobronchial tree) as a result of cavitary pulmonary tuberculosis. There is no evidence of significant trauma. The cause of death is MASSIVE HEMOPTYSIS DUE TO CAVITARY PULMONARY TUBERCULOSIS. The manner of death is NATURAL.

(b)(6)

Regional Armed Forces Medical Examiner

ACLU Detainee DeathII ARMY MEDCOM 72

This was a case that I did while I was in Baghdad. NCIS took the tox samples for shipment back to the AFIP. However, when I called the Tox lab yesterday, they said that they never received the specimens. I do not think that tox is crucial to the case, but it would be helpful. Could someone check with tox one last time to confirm that it is, in fact, not there? If the specimens never made it, then the case is ready to go.

Dr. (b)(6)

ACLU Detainee DeathII ARMY MEDCOM 73

(b)(6)

CERTIFICATE OF DEATH *(OVERSEAS)*
Acte de décès *(D'Outre-Mer)*

NAME OF DECEASED *(Last, First, Middle)* Nom du décédé (Nom et prénoms)	GRADE Grade	BRANCH OF SERVICE Arme	SOCIAL SECURITY NUMBER Numéro de l'Assurance Sociale
;TB Basim, Mohammed, Hussain			

ORGANIZATION Organisation	NATION *(e.g., United States)* Pays	DATE OF BIRTH Date de naissance	SEX Sexe
Detainee in Iraq	Iraq		☑ MALE Masculin ☐ FEMALE Féminin

RACE Race	MARITAL STATUS État Civil	RELIGION Culte
☒ CAUCASOID Caucasique	☐ SINGLE Célibataire	☐ PROTESTANT Protestant
☐ NEGROID Negroide	☐ MARRIED Marié	☐ CATHOLIC Catholique
☐ OTHER (Specify) Autre (Spécifier)	☐ WIDOWED Veuf	☐ JEWISH Juif
	☐ DIVORCED Divorcé	☐ OTHER (Specify) Autre (Spécifier)
	☐ SEPARATED Séparé	

NAME OF NEXT OF KIN Nom du plus proche parent	RELATIONSHIP TO DECEASED Parenté du décédé avec le susdit
STREET ADDRESS Domicile à (Rue)	CITY OR TOWN AND STATE *(Include ZIP Code)* Ville (Code postal compris)

MEDICAL STATEMENT Déclaration médicale

	CAUSE OF DEATH *(Enter only once cause per line)* Cause du décès (N'indiquer qu'une cause par ligne)	INTERVAL BETWEEN ONSET AND DEATH Intervalle entre l'attaque et le décès
DISEASE OR CONDITION DIRECTLY LEADING TO DEATH [1] Maladie ou condition directement responsable de la mort	Massive hemoptysis due to tuberculosis	
ANTECEDENT CAUSES Symptômes précurseurs de la mort. MORBID CONDITION, IF ANY, LEADING TO PRIMARY CAUSE Condition morbide, s'il y a lieu, menant à la cause primaire		
UNDERLYING CAUSE, IF ANY, GIVING RISE TO PRIMARY CAUSE Raison fondamentale, s'il y a lieu, ayant suscité la cause primaire		
OTHER SIGNIFICANT CONDITIONS [2] Autres conditions significatives		

MODE OF DEATH Condition de décès	AUTOPSY PERFORMED Autopsie effectuée	CIRCUMSTANCES SURROUNDING DEATH DUE TO EXTERNAL CAUSES Circonstances de la mort suscitées par des causes extérieures
☒ NATURAL Mort naturelle	☑ YES Oui ☐ NO Non	
☐ ACCIDENT Mort accidentelle	MAJOR FINDINGS OF AUTOPSY Conclusions principales de l'autopsie	
☐ SUICIDE Suicide	NAME OF PATHOLOGIST Nom du pathologiste (b)(6)	
☐ HOMICIDE Homicide	DATE Date 13 Jul 2003	AVIATION ACCIDENT Accident à Avion ☐ YES Oui ☑ NO Non

DATE OF DEATH (Hour, ...) Date de décès (l'heure, le jour, le mois, l'année)	PLACE OF DEATH ... Lieu de décès
(b)(6) 2003	Iraq

I HAVE VIEWED THE REMAINS OF THE DECEASED AND DEATH OCCURRED AT THE TIME INDICATED AND FROM THE CAUSES AS STATED ABOVE.
J'ai examiné les restes mortels du dé funt et je conclus que le décès est survenu à l'heure indiquée et à, la suite des causes énumérées ci-dessus.

NAME OF MEDICAL OFFICER Nom du médicin militaire ou du médicin sanitaire	TITLE OR DEGREE Titre ou diplôme
(b)(6)	

GRADE Grade	INSTALLATION OR ADDRESS Installation ou adresse
(b)(6)	Dover AFB, DE 19902

DATE Date 14MAY 04

(b)(6)

[1] State disease, injury or complication which caused death, but not mode of dying such as heart failure, etc.
[2] State conditions contributing to the death, but not related to the disease or condition causing death.
[1] Préciser la nature de la maladie, de la blessure ou de la complication qui a contribué à la mort, mais non la manière de mourir, telle qu'un arrêt du coeur, etc.
[2] Préciser la condition qui a contribué à la mort, mais n'ayant aucun rapport avec la maladie ou à la condition qui a provoqué la mort.

DD FORM 1 APR 77 2064 REPLACES DA FORM 3565, 1 JAN 72 AND DA FORM 3565-RIPAS), 26 SEP 75, WHICH ARE OBSOLETE.

(b)(6)

CERTIFICATE OF DEATH *(OVERSEAS)*
Acte de décès *(D'Outre-Mer)*

NAME OF DECEASED (Last, First, Middle) Nom du décédé (Nom et prénoms)	GRADE Grade	BRANCH OF SERVICE Arme	SOCIAL SECURITY NUMBER Numéro de l'Assurance Sociale
BTB WAHID, ABDUL	CIV		

ORGANIZATION Organisation	NATION (e.g., United States) Pays	DATE OF BIRTH Date de naissance	SEX Sexe
AFGHANISTAN CIVILIAN	AFGHANISTAN		☒ MALE Masculin ☐ FEMALE Féminin

RACE Race	MARITAL STATUS État Civil	RELIGION Culte
☒ CAUCASOID Caucasique	☐ SINGLE Célibataire ☐ DIVORCED Divorcé	☐ PROTESTANT Protestant ☐ OTHER (Specify) Autre (Spécifier)
☐ NEGROID Négroïde	☐ MARRIED Marié ☐ SEPARATED Séparé	☐ CATHOLIC Catholique ☒ UNKNOWN
☐ OTHER (Specify) Autre (Spécifier)	☐ WIDOWED Veuf	☐ JEWISH Juif

NAME OF NEXT OF KIN Nom du plus proche parent	RELATIONSHIP TO DECEASED Parenté du décédé avec le susdit
STREET ADDRESS Domicile à (Rue)	CITY OR TOWN AND STATE (Include ZIP Code) Ville (Code postal compris)

MEDICAL STATEMENT Déclaration médicale

CAUSE OF DEATH (Enter only one cause per line) Cause du décès (N'indiquer qu'une cause par ligne)		INTERVAL BETWEEN ONSET AND DEATH Intervalle entre l'attaque et le décès
DISEASE OR CONDITION DIRECTLY LEADING TO DEATH[1] Maladie ou condition directement responsable de la mort	MULTIPLE BLUNT FORCE INJURIES COMPLICATED BY PROBABLE RHABDOMYOLYSIS	
ANTECEDENT CAUSES Symptômes précurseurs de la mort	MORBID CONDITION, IF ANY, LEADING TO PRIMARY CAUSE Condition morbide, s'il y a lieu, menant à la cause primaire	
	UNDERLYING CAUSE, IF ANY, GIVING RISE TO PRIMARY CAUSE Raison fondamentale, s'il y a lieu, ayant suscité la cause primaire	
OTHER SIGNIFICANT CONDITIONS[2] Autres conditions significatives[2]		

MODE OF DEATH Condition de décès	AUTOPSY PERFORMED Autopsie effectuée ☒ YES Oui ☐ NO Non	CIRCUMSTANCES SURROUNDING DEATH DUE TO EXTERNAL CAUSES Circonstances de la mort suscitées par des causes extérieures
☐ NATURAL Mort naturelle	MAJOR FINDINGS OF AUTOPSY Conclusions principales de l'autopsie	
☐ ACCIDENT Mort accidentelle		
☐ SUICIDE Suicide	NAME OF PATHOLOGIST Nom du pathologiste (b)(6)	
☒ HOMICIDE Homicide	(b)(6) DATE Date 13 NOV 2003	AVIATION ACCIDENT Accident d'Avion ☐ YES Oui ☒ NO Non

DATE OF DEATH (Hour, day, month, year) Date de décès (l'heure, le jour, le mois, l'année)	PLACE OF DEATH Lieu de décès
(b)(6) NOV 2003	HELMAND PROVINCE, AFGHANISTAN

I HAVE VIEWED THE REMAINS OF THE DECEASED AND DEATH OCCURRED AT THE TIME INDICATED AND FROM THE CAUSES AS STATED ABOVE.
J'ai examiné les restes mortels du défunt et je conclus que le décès est survenu à l'heure indiquée et à la suite des causes énumérées ci-dessus

NAME OF MEDICAL OFFICER Nom du médecin militaire ou du médecin sanitaire	TITLE OR DEGREE Titre ou diplôme
(b)(6)	ARMED FORCES REGIONAL MEDICAL EXAMINER

GRADE Grade	INSTALLATION OR ADDRESS Installation ou adresse
(b)(6)	BAGRAM AIR FIELD, AFGHANISTAN (b)(6)
DATE Date 13 NOV 2003	

[1] State disease, injury or complication which directly caused death
[2] State conditions contributing to the death, but not related to the disease or condition causing death
[1] Préciser la nature de la maladie, de la blessure ou de la complication qui a entraîné la mort, mais non la manière de mourir, telle qu'un arrêt du cœur, etc.
[2] Préciser les conditions qui ont contribué à la mort, mais n'ayant aucun rapport avec la maladie ou la condition qui a provoqué la mort.

DD FORM 2064, APR 1977 REPLACES DA FORM 3565, 1 JAN 1972 AND DA FORM 3565-RIPASI, 20 SEP 1975, WHICH ARE OBSOLETE. USAPA V1.00

Office of the Armed Forces Regional Medical Examiner
Landstuhl Regional Medical Center
Landstuhl, GE - APO AE 09180
DSN (314) 486-6781/7492
Comm 001 49 (0) 6371 86 6781/7492

FINAL AUTOPSY REPORT
(Addendum)

Name: Hatab, Nadem Sadoon
SSAN: (b)(6)
Date of Birth: UNK
Date of Death (b)(6) 03
Date of Autopsy: 10 JUN 03
Date of Report: 22 OCT 03

Autopsy No.: (b)(6)
Rank/SVC: CIV Detainee
Org: EPW
Place of Death: Nasiriyah, Iraq
Place of Autopsy: Talil, Iraq
Investigative Agency: NCIS

Circumstances of Death: Decedent is a reported 52 y/o Iraqi Male, Civilian Detainee, who was found unresponsive outside in isolation at Whitehorse detainment facility; Nasiriyah, Iraq. He was pronounced at 1230 hours.

Authorization for Autopsy: Office of the Armed Forces Medical Examiner, IAW 10 USC 1471

Identification: Visual recognition; fingerprints and specimens for DNA obtained

Cause of Death: Strangulation

Manner of Death: Homicide

Autopsy Diagnoses:

Head, neck and torso injuries:
1. Right hyoid bone fracture with associated recent hemorrhage
2. Rib fractures; right anterior 4-7, left anterior 4-5
3. Contusions; mid abdomen, back and buttocks extending to the left flank
4. Abrasions, lateral buttocks

Extremity injuries:
1. Contusions, back of legs and knees
2. Abrasions; knees, left fingers and encircling left wrist
3. Lacerations and superficial cuts, right 4th and 5th fingers

Toxicology: Negative

(b)(6)

ACLU Detainee DeathII ARMY MEDCOM 76

(b)(6)

Hatab, Nadem Sadoon

Opinion: Based on these autopsy findings and the investigative and historical information available to me, this believed to be 52 year old Male (b)(6) died as a result of asphyxia (lack of oxygen to the brain) due to strangulation as evidenced by the recently fractured hyoid bone in the neck with soft tissue hemorrhage extending downwards to the level of the right thyroid cartilage. Although the right superior horn of the thyroid cartilage was palpably intact prior to excision, an underlying hairline fracture cannot be entirely ruled out. Additional findings at autopsy include blunt force injuries, predominantly recent contusions (bruises), on the torso and lower extremities. The abrasions encircling the left wrist are consistent with the use of restraints. There is no evidence of defense injuries or natural disease. The alcohol detected on toxicologic analysis is most likely due to postmortem production. The manner of death in my opinion is homicide.

This is the second addendum report. The first addition has been made to reflect the presence of a second Forensic Pathologist at autopsy who concurs with the findings and opinions listed in this report. On the second addendum report, changes are made to clarify the descriptions of the larynx in the Internal Examination and Evidence of Injury Sections.

Original signed, on file

(b)(6)

ARMED FORCES REGIONAL MEDICAL EXAMINER

ACLU Detainee DeathII ARMY MEDCOM 77

(b)(6)

HATAB, NADEM SADOON

I. POSTMORTEM EXAMINATION:

A. GENERAL: The postmortem examination is performed at Talil Air Base, Iraq. The autopsy is performed by Forensic Pathologist (b)(6) (b)(6) the Armed Forces Regional Medical Examiner (AFRME). Assisting in the autopsy procedures is (b)(6) Forensic Assistant.

The autopsy is witnessed by Special Agent (b)(6) Naval Criminal Investigation Service. Additional witnesses at autopsy include (b)(6) Forensic Pathologist.

The autopsy is started at approximately 0500 hours.

B. PHOTOGRAPHY: Photographs are taken by (b)(6) and (b)(6) (b)(6) and are on file in the Medical Photography Section, Landstuhl Regional Medical Center, Landstuhl, Germany.

C. AUTHORIZATION: The autopsy is authorized by the Armed Forces Medical Examiner under Title 10 U.S. Code, Section 1471, with an SF 523 signed by the Armed Forces Regional Medical Examiner, appointed representative.

D. IDENTIFICATION: The remains are presumptively identified visually by Naval Criminal Investigation Agents and authorities at the Whitehorse detainment facility. Specimens for DNA analysis are obtained.

E. MEDICAL RECORD REVIEW: Medical and dental records are not available for review.

II. GROSS AUTOPSY FINDINGS:

A. CLOTHING AND PERSONAL EFFECTS: The remains are presented for autopsy unclothed with no accompanying clothing or personal effects.

B. EXTERNAL EXAMINATION: The remains are those of a well developed, well nourished apparent middle eastern male of average build that appears compatible with the listed age of 52 years. Length is approximately 69 inches. The body shows signs of moderate decomposition as evidenced by greening and darkening of the skin, bloating, marbling, skin slippage and severe visceral autolysis. Injuries are described below in the Evidence of Injury Section.

RIGOR: Passed.

LIVIDITY: Fixed, faintly visible on the posterior dependent surfaces.

TEMPERATURE: That of the refrigeration unit.

MEDCOM 0078
ACLU Detainee DeathII ARMY MEDCOM 78

(b)(6)

HATAB, NADEM SADOON

SKIN: Unremarkable except for decomposition changes and evidence of injury described below in the Evidence of Injury Section.

HAIR: Straight black-gray hair, up to ½ inches in length covers the head. Facial hair consists of a short gray beard. The remaining body hair, the color of the black head hair, is in a normal adult male distribution.

HEAD/SCALP/FACE: The head is normocephalic, and except for decomposition changes including slippage, the scalp is intact and the facial features are normally developed.

EARS: Unremarkable.

EYES: Brown irides surround 4 mm pupils. The globes are dried and flattened. The corneae are mildly clouded and the sclerae are predominantly white. The conjunctivae are unremarkable. There is no evidence of petechiae.

NOSE: Well formed and unremarkable except for postmortem artifact.

MOUTH/LIPS: Unremarkable.

TEETH: Dentition is in fair repair.

NECK/CHEST/ABDOMEN/BACK/ANUS: Except for injuries described below in the Evidence of Injury Section and decomposition changes, unremarkable. The abdomen is bloated and protuberant.

EXTERNAL GENITALIA: Normal adult circumcised male with bilaterally descended testes. There is prominent scrotal bloating.

ARMS/HANDS/FINGERNAILS: Unremarkable except for injuries described below in the Evidence of Injury Section and decomposition changes. The fingernails are short, irregular yet intact.

LEGS/FEET/TOENAILS: Unremarkable, except for injuries described below in the Evidence of Injury Section and decomposition changes.

MEDCOM 0079
ACLU Detainee DeathII ARMY MEDCOM 79

C. INTERNAL EXAMINATION:

BODY CAVITIES: The body is opened by the usual Y-shaped incision. The pleural and peritoneal surfaces are smooth and dusky. The pericardium is unremarkable. There are no fibrovascular adhesions or abnormal collections of fluid except for a moderate amount of decomposition fluid. The mediastinum and retroperitoneum show no antemortem abnormalities. The leaves of the diaphragm are intact and the organs are normally disposed.

HEAD/CENTRAL NERVOUS SYSTEM: Reflection of the scalp shows the usual scattered reflection petechiae. The calvarium is intact. Removal of the calvarium shows the epidural space to be normal. No collections of subdural or subarachnoid blood are evident. The brain is removed in the usual manner. Marked softening and discoloration due to decomposition precludes definitive evaluation. No abnormalities are otherwise identified. The base of the skull is unremarkable.

NECK: Examination of the soft tissues of the neck and internal structures by a separate, bloodless layerwise dissection reveals the hyoid bone fracture and associated soft tissue hemorrhage described below in the Evidence of Injury Section. No non-traumatic abnormalities are identified.

CARDIOVASCULAR SYSTEM: The heart is of normal size and shape. The epicardium is intact and unremarkable. The chambers demonstrate the usual shape and configuration with no gross hypertrophy. The coronary arteries are normally disposed and there is no atherosclerosis. Marked autolytic changes preclude definitive evaluation. No evidence of natural disease or injury is identified. The aorta follows the usual course and exhibits no atherosclerosis. The origins of the major vessels are normally disposed and unremarkable. The great vessels of venous return are in the usual position and unremarkable.

RESPIRATORY SYSTEM: The larynx, trachea, and bronchi show no non-traumatic abnormalities. Injuries are described below in the Evidence of Injury Section. The right and left lungs are normally shaped with no evidence of natural disease on cut sections. Marked autolytic changes preclude definitive evaluation.

HEPATOBILIARY SYSTEM: The liver is of normal size and shape. It has a smooth, dusky capsule. Cut surfaces show the usual anatomic landmarks with a dark brown-green parenchyma. Marked decomposition and autolytic changes preclude definitive evaluation. The gallbladder is empty. Except for decomposition changes no abnormalities are identified.

INTESTINAL TRACT: The pharynx and esophagus are unremarkable. The stomach lies in the normal position and contains approximately 20 ml of dark brown fluid without food particles, tablets, capsules or residues. Except for decomposition changes, the small bowel and large bowel are unremarkable. The appendix is unremarkable.

ACLU Detainee DeathII ARMY MEDCOM 80

LYMPHORETICULAR SYSTEM: The spleen is of normal size and weight and is unremarkable except for decomposition changes. The thymus is not identified. Lymph nodes where visualized show no notable pathologic change.

URINARY SYSTEM: The right and left kidneys are of normal size and weight. The cortical surfaces are smooth and dull with marked decompositional changes precluding definitive evaluation of the parenchyma. The pelves and ureters are unremarkable. The bladder is empty.

INTERNAL GENITALIA: The prostate is palpably unremarkable. On cut sections, the testes show no abnormal masses or evidence of injury.

ENDOCRINE SYSTEM: Except for marked autolysis the pituitary, thyroid, adrenals, and pancreas show the usual anatomic features without evidence of natural disease or injury.

MUSCULOSKELETAL SYSTEM: Fractures are described below in the Evidence of Injury section. Except for autolysis, skeletal muscle demonstrates the normal appearance. The bone and bone marrow, where visualized, is unremarkable.

D. **EVIDENCE OF MEDICAL TREATMENT:** None.

E. **EVIDENCE OF INJURY:** Multiple blunt and sharp force injuries:

(1) **HEAD AND NECK INJURIES:**

a. On internal examination the distal right portion of the hyoid bone is palpably and visibly fractured with prominent associated recent hemorrhage extending downwards to the soft tissues of the right thyroid cartilage. The right superior horn of the thyroid cartilage is palpably intact.

(2) **TORSO INJURIES:**

a. External examination: An 8 x 6 inch irregular red-purple contusion is centered over the umbilicus on the mid lower abdomen. On the mid lower back is a 3 x ¾ inch elongated red-purple contusion. A 2 x 1 inch irregular abrasion is on the left flank. On the right lateral buttock, is a 4 x 4 inch irregular abrasion with the suggestion of a "brush burn" pattern. A 4 ¼ x 3 inch irregular red-purple contusion is on the left postero-lateral buttock. On the left lower posterior-lateral buttock is a ¼ inch greatest dimension abrasion.

b. On internal examination the ribs are fractured with associated hemorrhage as follows: Right anterior 4-7; left anterior 4-5.

(3) **EXTREMITY INJURIES:** A 2 x 1 inch red-blue irregular contusion is on the left anterior arm just above the elbow. On the left wrist, a discontinuous focally ½ inch thick abrasion encircles the wrist. Small ½ inch irregular abrasions are on the prominences of the distal left phalangeal joints of the first and second fingers.

ACLU Detainee DeathII ARMY MEDCOM 81

(b)(6)

HATAB, NADEM SADOON

Superficial, predominantly linear cuts and irregular healing lacerations, ½ to 1" greatest dimension, are on the 4th and 5th fingers of the right hand. Multiple irregular abrasions in association with red-purple contusions cover both anterior knees. The back of the left knee has patchy, irregular blue-purple contusions in association with a 3" greatest dimension irregular dark blue-purple contusion. On the back of the left upper thigh is a 7 x 7 inch red-purple contusion with prominent subcutaneous and perimuscular hemorrhage. On the back of the mid thigh is a 3 x 1 inch irregular red-purple contusion with associated subcutaneous hemorrhage. The right upper thigh has a 6 inch greatest dimension irregular-purple contusion with associated subcutaneous hemorrhage extending to the perimuscular area. Beneath this just above the back of the right knee is a 3 x 2 inch irregular red-purple contusion. On the back of the right lateral ankle is a ½ inch irregular slightly crusted abrasion.

III. MICROSCOPIC EXAMINATION: Not performed due to damage resulting from decompositional gases and severe thermal artifact during transport.

IV. TOXICOLOGY: Samples of blood, urine and tissue samples of liver and kidneys are submitted for toxicologic analysis at the Armed Forces Medical Examiner's Forensic Toxicology Laboratory, Armed Forces Institute of Pathology (AFIP), Washington, DC:

AFIP Accession No.: (b)(6), (b)(6) August 2003.

See attached report.

V. OTHER PROCEDURES AND SPECIAL STUDIES: None performed.

VI. EVIDENCE: None collected.

(b)(6)

15 SEP 03 **ARMED FORCES REGIONAL MEDICAL EXAMINER**

MEDCOM 0082
ACLU Detainee DeathII ARMY MEDCOM 82

CERTIFICATE OF DEATH *(OVERSEAS)*
Acte de décès *(D'Outre-Mer)*

NAME OF DECEASED *(Last, First, Middle)* Nom du décédé (Nom et prénoms)	GRADE Grade	BRANCH OF SERVICE Arme	SOCIAL SECURITY NUMBER
HATAB, NAEM SADOON		CIV DETAINEE	(b)(6)

ORGANIZATION Organisation	NATION *(e.g., United States)* Pays	DATE OF BIRTH Date de naissance	SEX Sexe
	IRAQ	NA	☒ MALE Masculin ☐ FEMALE Féminin

RACE Race	MARITAL STATUS État Civil	RELIGION Culte
☐ CAUCASOID Caucasique	☐ SINGLE Célibataire ☐ DIVORCED Divorcé	☐ PROTESTANT Protestant ☐ OTHER *(Specify)* Autre *(Spécifier)*
☐ NEGROID Négroïde	☐ MARRIED Marié ☐ SEPARATED Séparé	☐ CATHOLIC Catholique IRAQI
☒ OTHER (Specify) Autre *(Spécifier)*	☐ WIDOWED Veuf	☐ JEWISH Juif

NAME OF NEXT OF KIN Nom du plus proche parent	RELATIONSHIP TO DECEASED Parenté du décédé avec le susdit
NA	
STREET ADDRESS Domicile à (Rue)	**CITY OF TOWN AND STATE** *(Include ZIP Code)* Ville (Code postal compris)

MEDICAL STATEMENT Declaration médicale

CAUSE OF DEATH *(Enter only one cause per line)* Cause du décès (N'indiquer qu'une cause par ligne)		INTERVAL BETWEEN ONSET AND DEATH Intervalle entre l'attaque et le décès
DISEASE OR CONDITION DIRECTLY LEADING TO DEATH[1] Maladie ou condition directement responsable de la mort.	PENDING FURTHER INVESTIGATION	
ANTECEDENT CAUSES Symptômes précurseurs de la mort. — MORBID CONDITION, IF ANY, LEADING TO PRIMARY CAUSE Condition morbide, s'il y a lieu, menant à la cause primaire		
ANTECEDENT CAUSES Symptômes précurseurs de la mort. — UNDERLYING CAUSE, IF ANY, GIVING RISE TO PRIMARY CAUSE Raison fondamentale, s'il y a lieu, ayant suscité la cause primaire		
OTHER SIGNIFICANT CONDITIONS[2] Autres conditions significatives		

MODE OF DEATH Condition de décès	AUTOPSY PERFORMED Autopsie effectuée ☐ YES Oui ☐ NO Non	CIRCUMSTANCES SURROUNDING DEATH DUE TO EXTERNAL CAUSES Circonstances de la mort suscitées par des causes extérieures
☐ NATURAL Mort naturelle	MAJOR FINDINGS OF AUTOPSY Conclusions principales de l'autopsie: MANNER OF DEATH: PENDING FURTHER INVESTIGATION	DECEDENT FOUND UNRESPONSIVE IN OUTSIDE ISOLATION; WHITEHORSE DETAINMENT FAC
☐ ACCIDENT Mort accidentelle		
☐ SUICIDE Suicide	NAME OF PATIENT (VICTIM) Nom du malade (victime): (b)(6)	
☐ HOMICIDE Homicide	(b)(6) — DATE Date: 10 JUN 03	AVIATION ACCIDENT Accident d'Avion ☐ YES Oui ☒ NO Non

DATE OF DEATH (Hour, ...)	PLACE OF DEATH Lieu de décès
(b)(6) 03; (b)(6)	NASYRAH, IRAQ

I HAVE VIEWED THE REMAINS OF THE DECEASED AND DEATH OCCURRED AT THE TIME INDICATED AND FROM THE CAUSES AS STATED ABOVE.
J'ai examiné les restes mortels du défunt et je conclus que le décès est survenu à l'heure indiquée et à la suite des causes énumérées ci dessus

NAME OF MEDICAL OFFICER Nom du médecin militaire ou du médecin assimilé	TITLE OR DEGREE Titre ou diplôme
(b)(6)	ARMED FORCES REGIONAL MEDICAL EXAMINER
GRADE Grade: (b)(6)	**INSTALLATION OR ADDRESS** Installation ou adresse: MEDICAL EXAMINER.
DATE Date: 10 JUN 03	**SIGNATURE** Signature: (b)(6)

[1] State disease, injury or complication which ...
[2] State conditions contributing to the death. ...
[1] Préciser la nature de la maladie, de la blessure ou de la complication ... telle qu'un arrêt du cœur, etc.
[2] ...

ACLU Detainee DeathII ARMY MEDCOM 83

ARMED FORCES INSTITUTE OF PATHOLOGY
Office of the Armed Forces Medical Examiner
1413 Research Blvd., Bldg. 102
Rockville, MD 20850
1-800-944-7912

FINAL AUTOPSY REPORT

Name: Fahad, Mobass
Alternate Reported Name: (b)(6)
SSAN: n/a
Date of Birth: (b)(6) 1979 (per records)
Date of Death: (b)(6) 2004
Date of Autopsy: 28 November 2004
Date of Report: 14 March 2005

ID number: (b)(6)
Autopsy No.: (b)(6)
AFIP No.: (b)(6)
Rank: Civilian
Place of Death: Iraq
Place of Autopsy: Dover AFB, Dover, DE

Circumstances of Death: This 25 year old male civilian, presumed Iraq national, died while in US custody in Iraq. By report, he was admitted to the hospital at the Baghdad Central Confinement Facility with seizures and asthma on 12 November 2004, requiring an emergent tracheostomy for airway stabilization. He was placed on seizure prophylaxis and stabilized for several days. During preparation for transfer back to the camp, he had a generalized tonic clonic seizure and went into cardiac arrest. CPR was unsuccessful, and he was pronounced dead. By report, he had been in a Fallujah hospital for previous seizures. For complete clinical details, please refer to the medical records.

Authorization for Autopsy: Office of the Armed Forces Medical Examiner, IAW 10 USC 1471

Identification: Visual, per detention facility records; postmortem fingerprints and DNA profile obtained.

CAUSE OF DEATH: Acute Myocarditis

MANNER OF DEATH: Natural

ACLU Detainee DeathII ARMY MEDCOM 84

FINAL AUTOPSY DIAGNOSES:

I. Acute myocarditis (Cardiovascular Pathology consultation)
   a. Microscopically, acute myocarditis
      i. Focal myocyte necrosis and interstitial inflammatory infiltrate, right ventricle
   b. 390 gm heart
      i. Focal moderate coronary atherosclerosis, single vessel diseae
         1. 60% luminal narrowing of proximal left anterior descending artery by pathologic intimal thickening

II. Clinical history of "Seizures" (Neuropathology consultation)
   a. Brain, 1400 gm (1385 gm fixed)
   b. Microscopically, global hypoxic-ischemic injury (Non-specific findings)
      i. Eosinophilic cytoplasm and nuclear hyperchromasia and pyknosis in basal ganglia, hippocampal formation, brain stem and cerebellum, and in a pseudolaminar distribution in the cerebral cortex
      ii. Focal petechia hemorrhage in brainstem
      iii. Meningeal congestion

III. Clinical history of "Asthma" (Pulmonary Pathology consultation)
   a. Vascular congestion of lungs; right lung 630 gm, left lung 520 gm
   b. Microscopically, mild changes suggestive but not diagnostic of asthma (reactive airway disease)
      i. Airway basement membrane thickening
      ii. Focal goblet cell metaplasia and mucus plugging
      iii. No significant eosinophilia or smooth muscle hyperplasia

IV. No evidence of significant injury
   a. Minor contusions of the right thigh
   b. Healing pustules of right arm and left buttock
   c. No internal evidence of trauma

V. No evidence of restraint

VI. Toxicology (AFIP)
   a. Volatiles: Heart blood and bile negative for ethanol
   b. Drugs: Blood negative for screened medications and drugs of abuse

ACLU Detainee DeathII ARMY MEDCOM 85

EXTERNAL EXAMINATION

The body is that of a well-developed, well-nourished Caucasian male clad in a cut yellow one-piece jumpsuit and a pair of blue paper shorts. The body weighs 220 pounds, is 68" in height and appears consistent with the reported age of 25 years. The body is initially received frozen and is thawed prior to autopsy. Rigor has dissipated, and the body is flaccid once thawed. Lividity is present and fixed on the posterior surface of the body, except in areas exposed to pressure. There is early red marbling of the extremities.

The scalp is covered with dark brown hair averaging 3 cm in length. Facial hair consists of a dark mustache and dark beard. The irides are brown, and the corneae are slightly cloudy. The sclerae and conjunctivae are pale and free of petechiae. The earlobes are not pierced. The external auditory canals, external nares and oral cavity are free of foreign material and abnormal secretions. The nasal skeleton is palpably intact. The lips are without evident injury. The teeth are natural with extensive decay and caries evident.

The neck is straight and the trachea is midline and mobile. The chest is symmetric and well developed. No injury of the ribs or sternum is evident externally. The abdomen is protuberant and soft, with numerous striae. Healed surgical scars of the abdomen are not noted. The extremities are well developed with normal range of motion. The fingernails are intact. The soles of the feet are calloused and hyperkeratotic. There is a 1 x 0.5 cm scar on the left knee. Tattoos are not noted, and needle tracks are not observed. The external genitalia are those of a normal adult circumcised male. The testes are descended and free of masses. The pubic hair is present in a normal distribution. The buttocks and anus are unremarkable.

EVIDENCE OF THERAPY

There is a piece of white tape with gauze covering a tracheostomy incision on the lower anterior aspect of the neck. There is an endotracheal tube in place, protruding from the mouth. There are needle puncture marks with associated ecchymoses of the bilateral antecubital fossae and on the back of the left hand. There is a cluster of needle puncture marks in the left inguinal region. There is an intravenous catheter in the right inguinal region, secured with black sutures. There are five adhesive EKG tabs on the body, two on the upper right anterior aspect of the chest, one on the upper left anterior aspect of the chest, one on the lower right anterior aspect of the chest, and one on the lower left anterior aspect of the abdomen. There are two adhesive defibrillator pads on the body, one on the anterior left mid aspect of the chest and one on the mid left side of the back. There is no other evidence of medical intervention.

EVIDENCE OF INJURY

The ordering of the following injuries is for descriptive purposes only and is not intended to imply order of infliction or relative severity.

ACLU Detainee DeathII ARMY MEDCOM 86

There is a 4 x 3 cm red contusion on the lower lateral aspect of the right thigh, and there is a 4 x 3 cm red contusion with central pallor on the lower medial aspect of the right thigh. Incision of the skin over these contusions reveals a small amount of hemorrhage within the subcutaneous adipose tissue, but no deep injury.

There is a 0.3 x 0.2 cm healing crust on the back of the right upper arm, and there is a 0.5 x 0.3 cm healing pustule on the lower lateral aspect of the left buttock.

On internal examination of the head, chest and abdomen, there is no evidence of injury.

INTERNAL EXAMINATION

BODY CAVITIES:
The body is opened by the usual thoraco-abdominal incision and the chest plate is removed. No adhesions or abnormal collections of fluid are present in any of the body cavities. All body organs are present in the normal anatomical position. The vertebral bodies are visibly and palpably intact. The subcutaneous fat layer of the abdominal wall is 8 cm thick. There is no internal evidence of blunt force or penetrating injury to the thoraco-abdominal region.

HEAD: (CENTRAL NERVOUS SYSTEM)
The scalp is reflected, and there is no subgaleal hemorrhage or skull fractures found. The calvarium of the skull is removed. The dura mater and falx cerebri are intact. There is no epidural or subdural hemorrhage present. The leptomeninges are thin and delicate. The cerebrospinal fluid is clear. The brain is darkly discolored from decompositional changes. The cerebral hemispheres are symmetrical. The structures at the base of the brain, including cranial nerves and blood vessels, are intact. The brain is fixed in formalin prior to submission to Neuropathology for sectioning. The dura is stripped from the basilar skull, and no fractures are found. The atlanto-occipital joint is stable. The brain weighs 1400 grams. See "Neuropathology Report" below.

NECK:
Examination of the soft tissues of the neck, including strap muscles, thyroid gland and large vessels, reveals no abnormalities. The anterior strap muscles of the neck are homogeneous and red-brown, without hemorrhage. The thyroid cartilage and hyoid bone are intact. The larynx is lined by intact white mucosa and is unobstructed. The thyroid gland is symmetric and red-brown, without cystic or nodular change. There is no evidence of infection, tumor, or trauma, and the airway is patent. Incision and dissection of the posterior neck demonstrates no deep paracervical muscular injury, hemorrhage, or fractures of the dorsal spinous processes.

CARDIOVASCULAR SYSTEM:
The pericardial surfaces are smooth, glistening and unremarkable; the pericardial sac is free of significant fluid and adhesions. A moderate amount of epicardial fat is present. The heart is fixed in formalin prior to submission to Cardiovascular Pathology for sectioning. The aorta and its major branches arise normally, follow the usual course and are widely patent, free of significant atherosclerosis and other abnormality. The venae cavae and their major

ACLU Detainee DeathII ARMY MEDCOM 87

tributaries return to the heart in the usual distribution and are free of thrombi. The heart weighs 390 grams. See "Cardiovascular Pathology Report" below.

RESPIRATORY SYSTEM:
The upper airway is clear of debris and foreign material; the mucosal surfaces are smooth, yellow-tan and unremarkable. The pleural surfaces are smooth, glistening and unremarkable bilaterally. The pulmonary parenchyma is red-purple, exuding a moderate amount of bloody fluid; no focal lesions are noted. The pulmonary arteries are normally developed, patent and without thrombus or embolus. The right lung weighs 630 grams; the left 520 grams.

LIVER & BILIARY SYSTEM:
The liver has an intact, smooth capsule and a sharp anterior border. The hepatic capsule is smooth, glistening and intact, covering dark red-brown, moderately congested and slightly firm parenchyma with no focal lesions noted. The gallbladder contains 10 ml of green-brown, mucoid bile; the mucosa is velvety and unremarkable. The extrahepatic biliary tree is patent, without evidence of calculi. The liver weighs 1950 grams.

ALIMENTARY TRACT:
The tongue is free of bite marks, hemorrhage, or other injuries. The esophagus is lined by gray-white, smooth mucosa. The gastric mucosa is arranged in the usual rugal folds and the lumen contains 100 ml of semisolid digesting food, including rice and vegetables. The small and large bowel are unremarkable. The pancreas has a normal pink-tan lobulated appearance and the ducts are clear. The appendix is present and is unremarkable.

GENITOURINARY SYSTEM:
The renal capsules are smooth and thin, semi-transparent and strip with ease from the underlying smooth, red-brown cortical surfaces. The cortices are sharply delineated from the medullary pyramids, which are red-purple to tan and unremarkable. The calyces, pelves and ureters are otherwise unremarkable. White bladder mucosa overlies an intact bladder wall. The urinary bladder contains a film of cloudy urine. The prostate gland is normal in size, with lobular, yellow-tan parenchyma. The seminal vesicles are unremarkable. The testes are free of mass lesions, contusions, or other abnormalities. The right kidney weighs 140 grams; the left 160 grams.

RETICULOENDOTHELIAL SYSTEM:
The spleen has a smooth, intact capsule covering red-purple, moderately firm parenchyma; the lymphoid follicles are unremarkable. The regional lymph nodes appear normal. The spleen weighs 180 grams.

ENDOCRINE SYSTEM:
The pituitary, thyroid and adrenal glands are unremarkable.

MUSCULOSKELETAL SYSTEM:
Muscle development is normal. No bone or joint abnormalities are noted.

ACLU Detainee DeathII ARMY MEDCOM 88

MICROSCOPIC EXAMINATION

HEART: See "Cardiovascular Pathology Report" below.

LUNGS: See "Pulmonary Pathology Report" below.

LIVER: The hepatic architecture is intact. The portal areas show no increased inflammatory component or fibrous tissue. The hepatic parenchymal cells are well-preserved with no evidence of cholestasis, fatty metamorphosis, or sinusoidal abnormalities.

SPLEEN: The capsule and white pulp are unremarkable. There is minimal congestion of the red pulp.

ADRENALS: The cortical zones are distinctive, and the medullae are not remarkable.

KIDNEYS: The subcapsular zones are unremarkable. The glomeruli are mildly congested without cellular proliferation, mesangial prominence, or sclerosis. The tubules are well preserved. There is no interstitial fibrosis or significant inflammation. There is no thickening of the walls of the arterioles or small arterial channels. The transitional epithelium of the collecting system is normal.

BRAIN: See "Neuropathology Report" below.

CARDIOVASCULAR PATHOLOGY REPORT

CV Path, (b)(6)

" Diagnosis: (b)(6)

1. Acute myocarditis with focal myocyte necrosis and interstitial inflammatory infiltrate, right ventricle
2. Focal moderate coronary atherosclerosis, single vessel disease

History: Approximately 24 year old male Iraqi detainee who died in US custody; history of seizures prior to death.

Heart: 390 grams; normal epicardial fat; closed foramen ovale; normal cardiac chamber dimensions: left ventricular cavity diameter 40 mm, left ventricular free wall thickness 13 mm, ventricular septum thickness 13 mm; right ventricle thickness 4 mm, without gross scars or abnormal fat infiltrates; unremarkable valves; no gross myocardial fibrosis or necrosis; histologic sections show focal myocyte necrosis with interstitial infiltrates of lymphocytes and neutrophils in right ventricle, left ventricle is unremarkable.

Coronary arteries: Normal ostia; right dominance; focal moderate atherosclerosis: 60% luminal narrowing of proximal left anterior descending artery by pathologic intimal thickening; no other significant narrowing.

ACLU Detainee DeathII ARMY MEDCOM 89

Comment: Although it is uncommon, we have seen cases of acute myocarditis limited to the right ventricle. It has also been suggested that this could represent an early phase of arrhythmogenic right ventricular dysplasia, as the etiology of this entity is not fully understood."

NEUROPATHOLOGY REPORT

Department of Neuropathology and Ophthalmic Pathology, AFIP:

"We examined the approximately 1385-gram formalin-fixed brain submitted in reference to this case. The dural fragment submitted for evaluation does not show significant pathologic findings. The brain is soft and friable and dusky in color and deformed with the right hemisphere appearing larger than the left. There is a 2 x 1.5 cm hyperemic area along the left middle frontal gyrus. The gyral pattern is normal. The brain stem and cerebellum are similarly deformed and dusky in color. Because of these extensive artefactual changes, the cranial nerves and blood vessels at the base of the brain cannot be evaluated. There is no evidence of subfalcine herniation; tonsillar and uncal herniation cannot be assessed because of the extensive artifact. Serial coronal sections of the cerebrum show overall dusky discoloration of the cortical ribbon with slight blurring of the gray-white junction. The ventricular system is distorted and difficult to evaluate. There is extensive distortion, softening and friability of the basal ganglia, hippocampal formations, thalamus, and hypothalamus. The substantia nigra and locus cereleus, and aqueduct cannot be accessed due to the artefactual changes. The spinal cord is not submitted, but the uppermost cervical cord and cervicomedullary junction are soft and distorted. The cerebellum and brainstem are dusky in color and macerated.

Summary of microscopic sections: 1. Superior/middle frontal gyrus, right. 2. Inferior parietal lobule, right. 3. Superior/middle temporal gyrus, right. 4. Cingulate gyrus, left. 5. Hippocampal formation, right. 6. Caudate/putatmen/pallidum, right. 7. Thalamus/hypothalamus at mammillary bodies, right. 8. Substanis nigra/midbrain. 9 Pons. 10. Medulla. 11. Cerebellum.

All sections were stained with H&E.

Microscopic sections demonstrate extensive neuronal changes in the form of shrunken eosinophilic cytoplasm and nuclear hyperchromasia and pyknosis in sections of basal ganglia, hippocampal formation, brain stem and cerebellum, and in a pseudolaminar distribution in sections of cerebral cortex. These features are consistent with global hypoxic-ischemic injury. There is focal petechial hemorrhage ntoed on the sections of the brainstem. Microscopic sections of the left middle frontal gyrus confirms the meningeal congestion."

ACLU Detainee DeathII ARMY MEDCOM 90

PULMONARY PATHOLOGY REPORT

Department of Pulmonary Pathology, AFIP:

"Lungs, autopsy material:

- Airway basement membrane thickening, focal goblet cell metaplasia and mucus plugging
- Vascular congestion

The sections of lung show focal mucus plugging associated with basement membrane thickening and goblet cell metaplasia (focal). We note the history of asthma, while the above changes are suggestive of asthmatic changes, they are not striking and the sections lack significant eosinophilia and muscle hyperplasia. The lungs additionally show vascular congestion. There is a mild to moderate amount of fibrin in the alveoli which may be secondary to vascular leak. Fibrin/platelet aggregates are seen in rare vessels in bronchovascular bundles as well as in the capillary bed. It is difficult to discern whether these are pre or postmortem."

ADDITIONAL PROCEDURES

- Documentary photographs are taken by OAFME photographers
- Specimens retained for toxicologic testing and/or DNA identification are: vitreous fluid, femoral blood, heart blood, urine, bile, spleen, liver, kidney, lung, psoas muscle, gastric contents, and adipose tissue
- The dissected organs are forwarded with the body
- Personal effects are released to the appropriate mortuary operations representative

OPINION

This adult male Iraqi detainee died in US custody of acute myocarditis, inflammation of the heart involving the right ventricle. He had a clinical history of "seizures", however, no etiology for the seizures was found on examination of the brain, and the episodes may have been cardiac in origin rather than neurologic. He also had a clinical history of asthma, and while there were microscopic changes suggestive of asthma, these pulmonary findings were not diagnostic for asthma nor significant enough to have contributed to his death. Acute myocarditis may be caused by infectious agents (bacterial, viral, fungal), connective tissue diseases, or can be idiopathic (no recognized cause).

The manner of death is natural.

(b)(6)

(b)(6) Deputy Medical Examiner

ACLU Detainee DeathII ARMY MEDCOM 91

DEPARTMENT OF DEFENSE
ARMED FORCES INSTITUTE OF PATHOLOGY
WASHINGTON, DC 20306-6000

REPLY TO ATTENTION OF

AFIP-(b)(6)

TO:

OFFICE OF THE ARMED FORCES MEDICAL EXAMINER
ARMED FORCES INSTITUTE OF PATHOLOGY
WASHINGTON, DC 20306-6000

PATIENT IDENTIFICATION
AFIP Accessions Number Sequence
(b)(6)
Name
FAHAD, MOBASS

SSAN: **Autopsy:** (b)(6)
Toxicology Accession #: (b)(6)
Date Report Generated: December 15, 2004

CONSULTATION REPORT ON CONTRIBUTOR MATERIAL

AFIP DIAGNOSIS **REPORT OF TOXICOLOGICAL EXAMINATION**

Condition of Specimens: GOOD
Date of Incident: (b)(6) 2004 **Date Received:** 11/30/2004

VOLATILES: The **HEART BLOOD AND BILE** were examined for the presence of ethanol at a cutoff of 20 mg/dL. No ethanol was detected.

DRUGS: The **BLOOD** was screened for amphetamine, antidepressants, antihistamines, barbiturates, benzodiazepines, cannabinoids, chloroquine, cocaine, dextromethorphan, lidocaine, narcotic analgesics, opiates, phencyclidine, phenothiazines, sympathomimetic amines and verapamil by gas chromatography, color test or immunoassay. The following drugs were detected:

None were found.

(b)(6)
Office of the Armed Forces Medical Examiner

(b)(6)
Office of the Armed Forces Medical Examiner

ACLU Detainee DeathII ARMY MEDCOM 92

ARMED FORCES INSTITUTE OF PATHOLOGY
Office of the Armed Forces Medical Examiner
1413 Research Blvd., Bldg. 102
Rockville, MD 20850
1-800-944-7912

FINAL AUTOPSY EXAMINATION REPORT

Name: Al Zarjawi, Ahmed N. (BTB)
SSAN: Detainee Number (b)(6)
Date of Birth: Unknown
Date of Death: (b)(6) 2004
Date of Autopsy: 27 OCT 2004
Date of Report: 17 FEB 2005

Autopsy No.: (b)(6)
AFIP No.: (b)(6)
Rank: Detainee in U.S. Custody
Place of Death: Iraq
Place of Autopsy: BIAP Mortuary, Baghdad, Iraq

Circumstances of Death: This Iraqi male was a detainee in U.S. custody at Camp Bucca Detention Facility in Umm Qasr, Iraq. The detainee was unconscious when four other detainees brought him to a common area and notified the guards. He received emergency medical care first at the scene and then was taken to a medical treatment facility. Resuscitation efforts were unsuccessful.

Authorization for Autopsy: Armed Forces Medical Examiner, per 10 U.S. Code 1471

Identification: Circumstantial identity is established by paperwork accompanying the detainee and his designation as detainee number (b)(6)

CAUSE OF DEATH: Undetermined

MANNER OF DEATH: Natural

ACLU Detainee DeathII ARMY MEDCOM 93

FINAL AUTOPSY DIAGNOSES:

I. **Hemoperitoneum, 150-milliliters and blood staining of the intraperitoneal organs**

II. **Small bilateral pleural effusions and minimal serous pericardial effusion**

III. **History of upper gastrointestinal hemorrhage (250-milliliters per medical records), with diffuse gastritis noted at autopsy**

IV. **No evidence of external or internal trauma**

V. **Early pulmonary emphysema**

VI. **The autopsy was attended by** (b)(6) **medical Examiner** (b)(6) (b)(6) **and SA** (b)(6) **USACID**

VII. **Toxicology is negative for ethanol, cyanide, and drugs of abuse. Atropine is present in blood.**

ACLU Detainee DeathII ARMY MEDCOM 94

EXTERNAL EXAMINATION

The remains are received unclad and without any accompanying clothing. The length is 72-inches and the estimated weight is 170-pounds. Lividity is posterior and fixed, except in areas exposed to pressure. Rigor is present but passing. The body temperature is that of the refrigeration unit. Paper bags cover both hands. A tag on the left great toe contains the writing (b)(6)

The scalp is covered with medium length, black hair in a normal distribution. The corneae are cloudy. The irides are brown and the pupils are round and equal in diameter. The head is atraumatic. The teeth are natural and in fair condition. Facial hair consists of a full beard and mustache.

The neck is mobile and the trachea is midline. The chest is symmetric. The abdomen is flat. The external genitalia are those of a normal adult, circumcised, male. The testes are descended and free of masses. Pubic hair is present in a normal distribution. The buttocks and anus are unremarkable.

The upper and lower extremities are symmetric and without clubbing or edema. The fingernails are intact. There is a ½-inch scar on the anterior left knee.

(b)(6) tattoo (b)(6)
(b)(6) tattoos (b)(6)
(b)(6) torso (b)(6)
(b)(6) tattoo (b)(6)
(b)(6) tattoo (b)(6)
(b)(6)
(b)(6) tattoo (b)(6)

MEDICAL INTERVENTION

Evidence of medical intervention consists of venipuncture sites in both antecubital fossae, a padded cervical collar around the neck, and a vague mark on the lateral left chest that is consistent with either the prior placement of an electrocardiogram lead pad or an attempt at defibrillation

RADIOGRAPHS

A complete set of postmortem radiographs is obtained and shows an absence of skeletal trauma and metallic foreign objects.

EVIDENCE OF INJURY

There is no evidence of injury on the body at the time of the autopsy.

INTERNAL EXAMINATION

HEAD:
The scalp and skull are free of injury. There is no epidural, subdural, or subarachnoid hemorrhage. The 1480-gram brain shows a normal pattern and appearance of gyri and

ACLU Detainee DeathII ARMY MEDCOM 95

sulci. Serial sectioning reveals no evidence of injury or significant natural disease processes. The atlanto-occipital joint is intact.

NECK:
There is no evidence of injury to the strap muscles of the anterior neck. The thyroid cartilage and hyoid bone are intact. The larynx is lined by intact white mucosa. The thyroid gland is symmetric and red-brown, without cystic or nodular change. The tongue is unremarkable.

BODY CAVITIES:
The ribs, sternum, and vertebral bodies are visibly and palpably intact. There are 50-milliliters of serosanguinous fluid in the right pleural cavity and 40-milliliters of serosanguinous fluid in the left pleural cavity. A minimal (20-milliliters) serous pericardial effusion is present. The peritoneal cavity contains 150-milliliters of blood, with a greater accumulation on the right side of the abdomen. The organs occupy their usual anatomic positions.

RESPIRATORY SYSTEM:
The right and left lungs weigh 540 and 450-grams, respectively. The external surfaces are smooth and deep red-purple. The pulmonary parenchyma is moderately congested. No mass lesions or areas of consolidation are present. The pulmonary arteries are unremarkable.

CARDIOVASCULAR SYSTEM:
The 480-gram heart is contained in an intact pericardial sac. The epicardial surface is smooth, with minimal fat investment. The coronary arteries are present in a normal distribution, with a right-dominant pattern. Cross sections of the vessels show no significant atherosclerosis. The myocardium is homogenous, red-brown, and firm. The valve leaflets are thin and mobile. The walls of the left and right ventricles are 1.4 and 0.5-centimeters thick, respectively. The endocardium is smooth and glistening. The aorta gives rise to three intact and patent arch vessels. The renal and mesenteric vessels are unremarkable.

LIVER & BILIARY SYSTEM:
The 1820-gram liver has an intact, smooth capsule and a sharp anterior border. The parenchyma is red-brown, firm, and congested, with the usual lobular architecture. No mass lesions or other abnormalities are seen. The gallbladder contains 15-milliliters of green-black bile and no stones. The mucosal surface is green and velvety. The extrahepatic biliary tree is patent.

SPLEEN:
The 260-gram spleen has a smooth, intact, red-purple capsule. The parenchyma is maroon and congested, with prominent Malpighian corpuscles. A 1-centimeter accessory spleen is present.

ACLU Detainee DeathII ARMY MEDCOM 96

PANCREAS:
The pancreas is irregularly hemorrhagic, with the usual lobular architecture. No mass lesions are seen. There is a small area that is grossly suspicious for a hemorrhage from a pancreatic vessel.

ADRENAL GLANDS:
The right and left adrenal glands are symmetric, with bright yellow cortices and gray medullae. No masses or areas of hemorrhage are identified.

GENITOURINARY SYSTEM:
The right and left kidneys each weigh 250-grams. The external surfaces are intact and smooth. The cut surfaces are red-tan and congested, with uniformly thick cortices and sharp corticomedullary junctions. The pelves are unremarkable and the ureters are normal in course and caliber. White bladder mucosa overlies an intact bladder wall. The urinary bladder is empty. The prostate gland is normal in size, with lobular, yellow-tan parenchyma. The seminal vesicles are unremarkable. The testes are free of mass lesions, contusions, or other abnormalities.

GASTROINTESTINAL TRACT:
The esophagus is intact and lined by smooth, gray-white mucosa. The stomach contains approximately 300-milliliters of green-black, fibrous food material but no gross blood. The gastric wall is intact with diffuse gastritis but no distinct ulceration or evidence of focal perforation. The duodenum, loops of small bowel, and colon are unremarkable. The appendix is present.

MUSCULOSKELETAL:
No non-traumatic abnormalities of muscle or bone are identified.

MICROSCOPIC EXAMINATION

Brain-representative sections are histologically unremarkable
Lung-sections of all lobes of both lungs demonstrate vascular congestion, scattered collections of intra-alveolar macrophages, moderate anthracotic pigment deposition, focal inspissated mucous, and early changes of pulmonary emphysema
Heart and Aorta- representative sections are histologically unremarkable
Liver-a representative section demonstrates passive congestion and mild microvesicular steatosis
Spleen- representative sections are histologically unremarkable
Kidneys-sections of both kidneys show postmortem changes
Stomach-representative sections show autolysis and exaggerated formalin pigment deposition
Pancreas-representative sections show marked autolysis, focal fat necrosis, and exaggerated formalin pigment deposition. A small focus of testes is also in one section.

ACLU Detainee DeathII ARMY MEDCOM 97

ADDITIONAL PROCEDURES/REMARKS

- Documentary photographs are taken by (b)(6) USAF
- Specimens retained for toxicologic testing and/or DNA identification are: heart blood, vitreous fluid, spleen, liver, brain, lung, bile, gastric contents, kidney, and psoas muscle
- The dissected organs are forwarded with body
- Personal effects are released to the appropriate mortuary operations representatives

OPINION

This Iraqi male, believed to be (b)(6) a detainee in the custody of the U.S. military died as a result of undetermined causes. A complete medicolegal autopsy, including toxicology and microscopic slide review failed to demonstrate a clear cause of death. The autopsy findings included hemoperitoneum, but this may have been an artifact of resuscitative efforts as there was neither an inflammatory exudate nor food material in the peritoneal cavity and the bleeding appeared to have been recent. There was no evidence of trauma noted at autopsy and the clinical history included an upper gastrointestinal hemorrhage noted during resuscitative attempts. No source of bleeding could be identified at autopsy, nor was there evidence of a perforated viscus. The death may have been due to an acute cardiac event; the heart was heavy for the size of this individual, though there was no evidence of coronary artery disease at autopsy. Taking into account the history and investigative information available as well as the lack of an identifiable anatomic cause of death, this death is best classified as a natural death due to undetermined causes.

(b)(6)

(b)(6) **Medical Examiner**

ACLU Detainee DeathII ARMY MEDCOM 98

ARMED FORCES INSTITUTE OF PATHOLOGY
Office of the Armed Forces Medical Examiner
1413 Research Blvd., Bldg. 102
Rockville, MD 20850
1-800-944-7912

FINAL AUTOPSY EXAMINATION REPORT

Name: BTB Nahar, Muhammad
SSAN: N/A
Date of Birth: BTB 1933
Date of Death: (b)(6) 2004
Date of Autopsy: 04 OCT 2004
Date of Report: 24 NOV2004

Autopsy No.: (b)(6)
AFIP No.: (b)(6)
Rank: Iraqi National
Place of Death: Marine Detention Facility, Iraq
Place of Autopsy: Baghdad Mortuary Baghdad Airport, Iraq

Circumstances of Death: This believed to be 71 year old Iraqi National died while in US Marine Corps custody while being processed into the Iraqi detention program. The Naval Criminal Investigative Service (NCIS) investigation revealed that the decedent suffered from ulcer disease for several years (per decedent's nephew) and the decedent was doing quite poorly just prior to being detained by the Marines.

Authorization for Autopsy: Office of the Armed Forces Medical Examiner, IAW 10 USC 1471.

Identification: Identification based on prison identification tag on the left great toe.

CAUSE OF DEATH: Acute Peritonitis due to a Perforating Gastric Ulcer

MANNER OF DEATH: Natural

FINAL AUTOPSY DIAGNOSES:

I. Autopsy findings

A. Acute Peritonitis due to a Perforating Gastric Ulcer associated with 1500 ml of purulent ascites and severe dehydration.

B. Mild to moderate atherosclerosis (25-50% stenosis) of the right coronary and left anterior descending branch of the left coronary artery.

C. Mild atherosclerosis of the basilar and right middle cerebral arteries of the brain.

ACLU Detainee DeathII ARMY MEDCOM 99

D. Fibrosis of the epicardial surface of the right ventricle of the heart.

E. Left renal scar.

F. Hydrocele of the right testicle.

II. Mild decomposition

III. Toxicology is negative for ethanol and drugs of abuse.

ACLU Detainee DeathII ARMY MEDCOM 100

EXTERNAL EXAMINATION

The body is that of a cachetic, dehydrated 65 ½ inch tall, 100 pounds (estimated) Iraqi National whose appearance is consistent with the reported age of 71 years. Lividity is fixed posteriorly. Rigor is easily broken in the extremities, and the temperature is cold from refrigeration.

The scalp is covered with curly black and gray hair in a normal distribution. The irides are brown and the pupils are round and equal in diameter. There are linear drying artifacts on each eye and small hyperpigmented areas on the superior aspects of each eye. The external auditory canals are dry and free of abnormal secretions. The ears are unremarkable. The nares are patent and the lips are atraumatic. The nose and maxillae are palpably stable. The teeth appear are natural and have severe periodontal disease. Facial hair consists of a black mustache and goatee style beard.

The neck is straight, and the trachea is midline and mobile. The chest is symmetric. A 2.5 x 2.1 cm oval scar is on the left chest and a 7.4 x 1.4 cm oval scar is over the xiphoid process. The abdomen is flat but has a palpable fluid wave. A 2.1 x 0.7 cm oval scar is on the right upper quadrant. The genitalia are those of a normal adult circumcised male. The testes are descended and free of masses. Pubic hair is present in a normal distribution. The left buttock has a 2.0 x 1.5 cm abrasion over the protruding left femoral neck. On the right side of the central lower back is a 0.7 x 0.7 cm oval hyperpigmented area. The anus is unremarkable.

The upper and lower extremities are symmetric and without clubbing or edema. The skin of the posterior surfaces of the hands retains "tents" when stretched. On the posterior surface of the left forearm are five oval scars that range in size from 1.2 x 1.2 cm to 2.5 x 2.0 cm and are in a linear pattern extending from the elbow to the wrist. The wrists and web spaces of the fingers are free of injuries. On the anterior surface of the right lower leg are three round to oval scars that range in size from 1.5 x 1.0 cm to 2.5 x 1.5 cm. A 2.0 x 1.5 cm circular scar is on the anterior surface of the left lower leg. The ankles and web spaces of the toes are free of injuries. A paper identification tag inscribed with (b)(6) (b)(6) is attached to the left great toe.

CLOTHING AND PERSONAL EFFECTS

The following clothing items and personal effects are present on the body at the time of autopsy:

A bright orange jumpsuit with a piece of cardboard inscribed with (b)(6) in the front pocket.

MEDICAL INTERVENTION

There are a cluster of four punctate defects over the medial surface of the left forearm and a cluster of three punctate defects on the posterior surface of the right hand, inspection by incision is consistent with needle punctures.

ACLU Detainee DeathII ARMY MEDCOM 101

RADIOGRAPHS

A complete set of postmortem radiographs is obtained and demonstrates the following: No foreign bodies and no evidence of fractures.

EVIDENCE OF INJURY

The ordering of the following injuries is for descriptive purposes only, and is not intended to imply order of infliction or relative severity. All wound pathways are given relative to standard anatomic position.

A 2.1 x 0.1 cm crusted linear abrasion is on the anterior surface of the right wrist and a 2.5 x 0.1 cm crusted abrasion on the posterior surface of the right forearm.

A 1.5 x 0.5 cm crusted abrasion is on the anterior surface of the left ankle.

INTERNAL EXAMINATION

HEAD:
The galeal and subgaleal soft tissues of the scalp are free of injury. The calvarium is intact, as is the dura mater beneath it. Clear cerebrospinal fluid surrounds the soft 1390 gm brain, which has unremarkable gyri and sulci. Coronal sections demonstrate sharp demarcation between white and grey matter, without hemorrhage or contusive injury. The ventricles are of normal size. The basal ganglia, brainstem, cerebellum, and arterial systems are free of injury. There is mild atherosclerosis of the basilar and right middle cerebral arteries. There are no skull fractures. The atlanto-occipital joint is stable.

NECK:
The anterior strap muscles of the neck are homogenous and red-brown, without hemorrhage. The thyroid cartilage and hyoid bone are intact. The larynx is lined by intact white mucosa. The thyroid gland is symmetric and red-brown, without cystic or nodular change. The tongue is free of bite marks, hemorrhage, or other injuries.

BODY CAVITIES:
The ribs, sternum, and vertebral bodies are visibly and palpably intact. The pleural cavities each have 100 ml of decomposition fluid. The pericardial and peritoneal cavities are free of fluid collections. The organs occupy their usual anatomic positions.

RESPIRATORY SYSTEM:
The right and left lungs weigh 423 and 438 gm, respectively. The external surfaces are smooth and deep red-purple. The pulmonary parenchyma is diffusely congested and edematous. No mass lesions or areas of consolidation are present.

CARDIOVASCULAR SYSTEM:
The 341 gm heart is contained in an intact pericardial sac. The epicardial surface is smooth, with minimal fat investment. A 4.2 x 2.6 cm area of epicardial fibrosis is on the anterior surface of the right ventricle. The coronary arteries are present in a normal distribution, with a right-dominant pattern. Cross sections of the vessels show mild

ACLU Detainee DeathII ARMY MEDCOM 102

atherosclerosis (<25% stenosis) in the right coronary and the left descending branch of the left coronary artery. The myocardium is homogenous, red-brown. and firm. The valve leaflets are thin and mobile. The walls of the left and right ventricles are 1.0 and 0.3-cm thick, respectively. The endocardium is smooth and glistening. The aorta gives rise to three intact and patent arch vessels. The renal and mesenteric vessels are unremarkable.

LIVER & BILIARY SYSTEM:
The 780 gm liver has an intact, smooth capsule and a sharp anterior border. The parenchyma is tan-brown and congested, with the usual lobular architecture. No mass lesions or other abnormalities are seen. The gallbladder contains a minute amount of green-black bile and no stones. The gallbladder mucosal surface is green and velvety. The extrahepatic biliary tree is patent.

SPLEEN:
The 94 gm spleen has a smooth, intact, red-purple capsule. The parenchyma is maroon and congested, with distinct Malpighian corpuscles.

PANCREAS:
The pancreas is firm and yellow-tan, with the usual lobular architecture. No mass lesions or other abnormalities are seen.

ADRENALS:
The right and left adrenal glands are symmetric, with bright yellow cortices and grey medullae. No masses or areas of hemorrhage are identified.

GENITOURINARY SYSTEM:
The right and left kidneys weigh 65 and 64 gm, respectively. The external surfaces have fine granularity. A 1.0 x 0.8 cm scar that is consistent with a ruptured renal cortical cyst is on the upper pole of the left kidney. The cut surfaces are red-tan and congested, with uniformly thick cortices and sharp corticomedullary junctions. The pelves are unremarkable and the ureters are normal in course and caliber. White bladder mucosa overlies an intact bladder wall. The bladder contains approximately 40 ml of cloudy yellow urine. The prostate is normal in size, with lobular, yellow-tan parenchyma. The seminal vesicles are unremarkable. The testes are free of mass lesions, contusions, or other abnormalities. The right testicle has a hydrocele that contains 30 ml of clear yellow fluid.

GASTROINTESTINAL TRACT:
The esophagus is intact and lined by smooth, grey-white mucosa. There is approximately 10 ml of clotted blood in the distal esophagus. The stomach contains approximately 120 ml of tan mucoid fluid. The anterior gastric wall has a 1.6 x 1.0 cm perforation near the pyloric sphincter that communicates with a 1.5 x 0.5 cm perforation of the posterior gastric wall near the pyloric sphincter. There is approximately 1500 ml of foul smelling cloudy tan fluid in the peritoneal cavity. The duodenum, loops of small bowel, and colon are unremarkable. The appendix is present.

ACLU Detainee DeathII ARMY MEDCOM 103

ADDITIONAL PROCEDURES

- Documentary photographs are taken by (b)(6)
- Specimens retained for toxicologic testing and/or DNA identification are: blood, urine, spleen, kidney, lung, liver, brain, bile, gastric contents, and psoas muscle.
- The dissected organs are forwarded with body.
- Personal effects are released to the appropriate mortuary operations representatives.

MICROSCOPIC EXAMINATION

Stomach: Acute ulceration with severe inflammation with bacteria present. Helicobacter pylori is not identified on either H&E or Diff-Quik stained slides

Portions of other organs are retained in formalin, without preparation of histologic slides.

OPINION

This believed to be 71 year old detainee died from acute peritonitis that resulted from a perforating gastric ulcer. The decedent was cachetic and severely dehydrated which indicates that he had the ulcer for a significant amount of time. The manner of death is natural.

(b)(6)

(b)(6) Medical Examiner

ACLU Detainee DeathII ARMY MEDCOM 104

DEPARTMENT OF DEFENSE
ARMED FORCES INSTITUTE OF PATHOLOGY
WASHINGTON, DC 20306-6000

REPLY TO ATTENTION OF

AFIP (b)(6)

TO:

OFFICE OF THE ARMED FORCES MEDICAL EXAMINER
ARMED FORCES INSTITUTE OF PATHOLOGY
WASHINGTON, DC 20306-6000

PATIENT IDENTIFICATION

AFIP Accessions Number **Sequence**
(b)(6)

Name
NAHAR, MUHAMMAD

SSAN: **Autopsy:** (b)(6)
Toxicology Accession #: (b)(6)
Date Report Generated: October 18, 2004

CONSULTATION REPORT ON CONTRIBUTOR MATERIAL

AFIP DIAGNOSIS **REPORT OF TOXICOLOGICAL EXAMINATION**

Condition of Specimens: GOOD
Date of Incident: **Date Received:** 10/6/2004

VOLATILES: The **URINE AND LIVER** were examined for the presence of ethanol at a cutoff of 20 mg/dL. No ethanol was detected.

DRUGS: The **LIVER** was screened for amphetamine, antidepressants, antihistamines, barbiturates, benzodiazepines, cannabinoids, chloroquine, cocaine, dextromethorphan, lidocaine, narcotic analgesics, opiates, phencyclidine, phenothiazines, sympathomimetic amines and verapamil by gas chromatography, color test or immunoassay. The following drugs were detected:

None were found.

(b)(6)
Office of the Armed Forces Medical Examiner

(b)(6)
Office of the Armed Forces Medical Examiner

ACLU Detainee DeathII ARMY MEDCOM 105

ARMED FORCES INSTITUTE OF PATHOLOGY
Office of the Armed Forces Medical Examiner
1413 Research Blvd., Bldg. 102
Rockville, MD 20850
1-800-944-7912

FINAL AUTOPSY REPORT

Name: Mohammad, Sher
SSAN: n/a
Date of Birth: unknown
Date of Death: (b)(6) 2004
Date of Autopsy: 30 September 2004
Date of Report: 14 April 2005

Autopsy No.: (b)(6)
AFIP No (b)(6)
Rank: Civilian
Place of Death: Salerno, Afghanistan
Place of Autopsy: Bagram, Afghanistan

Circumstances of Death: This adult male civilian, presumed Afghanistan national, was found dead while at the Regional Interrogation Facility, Salerno Firebase, Afghanistan. By report, he in processed at the RIF on (b)(6) 2004, and the following day, he complained of various cold symptoms and body aches related to a snake or insect bite. On examination by medical personnel, his vital signs were normal. Several hours later, he was found to be unresponsive and not breathing, and he was pronounced dead at the local medical facility.

Authorization for Autopsy: Office of the Armed Forces Medical Examiner, IAW 10 USC 1471

Identification: Visual, per detention facility records; postmortem fingerprints and DNA profile obtained

CAUSE OF DEATH: Atherosclerotic Cardiovascular Disease

MANNER OF DEATH: Natural

ACLU Detainee DeathII ARMY MEDCOM 106

FINAL AUTOPSY DIAGNOSES:

I. Atherosclerotic cardiovascular disease (AFIP Cardiovascular Pathology consultation)
   a. Moderate coronary atherosclerosis
      i. Left main coronary artery: 40% luminal narrowing by pathologic intimal thickening
      ii. Left anterior descending artery (LAD): 50% narrowing of proximal LAD by pathologic intimal thickening
      iii. Left circumflex artery (LCA): 20% narrowing of proximal LCA
      iv. Right coronary artery (RCA)
         1. 20% narrowing of proximal RCA
         2. 70% narrowing of mid RCA by smooth muscle and proteoglycan rich neointima, consistent with healed plaque erosion
   b. Cardiomegaly with left ventricular hypertrophy
      i. Heart, 470 gm (predicted normal value 343 gm, upper limit 453 gm)
      ii. Left ventricular free wall thickness, 15 mm
      iii. Ventricular septum thickness, 15 mm

II. Evidence of restraint
   a. White plastic zip-tie "Flexicuff" around right wrist with no underlying contusion or abrasion

III. Evidence of injury
   a. Minor abrasions of chest, upper back, upper arms, and right knee
   b. No internal evidence of trauma

IV. Additional findings
   a. Neuropathology consultation (AFIP Department of Neuropathology)
      i. No gross abnormalities, brain 1370 gm
      ii. Microscopically, minimal non-specific findings
         1. Two small foci of chronic inflammatory cells in the medulla; immunohistochemically, rare scattered lymphocytes
         2. No microorganisms or viral inclusions identified
   b. Globoid liver with rounded borders, 1660 gm
      i. Hepatic pathology consultation, AFIP
         1. Moderate vascular congestion
         2. Mild "dusting" of hepatocytes with hemosiderin
         3. No specific lesions identified
   c. Pulmonary edema and congestion; right lung 764 gm, left lung 614 gm
   d. Simple renal cysts

ACLU Detainee DeathII ARMY MEDCOM 107

V. Toxicology (AFIP)
   a. Volatiles: Blood and vitreous fluid negative for ethanol
   b. Drugs: Urine negative for screened medications and drugs of abuse

EXTERNAL EXAMINATION

The body is that of a well-developed, well-nourished unclad Caucasian male. On top of the body, there is a pair of tan, drawstring waist pants and a previously cut white sleeveless undershirt. The body weighs approximately 180 pounds, is 67" in height and appears approximately 40-60 years of age. The body temperature is cold, that of the refrigeration unit. Rigor is present to an equal degree in all extremities. Lividity is present and fixed on the posterior surface of the body, except in areas exposed to pressure, and there is moderate facial congestion.

The scalp is covered with dark brown hair averaging 4 cm in length with a slightly receding hairline in the temporal regions. Facial hair consists of a dark mustache and dark full beard. The irides are brown, and the corneae are slightly cloudy. The sclerae and conjunctivae are congested, but free of petechiae. The earlobes are not pierced. The external auditory canals, external nares and oral cavity are free of foreign material and abnormal secretions. The nasal skeleton is palpably intact. The lips are without evident injury. The teeth are natural and in good condition.

The neck is straight and the trachea is midline and mobile. The chest is symmetric and well developed. No injury of the ribs or sternum is evident externally. The abdomen is slightly protuberant and soft. Healed surgical scars of the abdomen are not noted. The extremities are well developed with normal range of motion. The fingernails are intact. The soles of the feet are calloused and lightly dirt stained. There is a thick callous on the anterior aspect of the left ankle, and the skin of the left knee is thickened and hyperkeratotic. There is a 3 x 0.1 cm pale linear scar on the back of the right forearm, and there are multiple pale scars on the back of the right hand, < 0.2 cm each. There is a 1 x 1 cm scar on the lateral aspect of the right ankle. Tattoos are not noted, and needle tracks are not observed. The external genitalia are those of a normal adult uncircumcised male. The testes are descended and free of masses. The pubic hair is present in a normal distribution. The buttocks and anus are unremarkable.

EVIDENCE OF THERAPY

There is a needle puncture mark of the right lower aspect of the neck, just above the clavicle, covered with a piece of white tape and gauze, and there is underlying associated soft tissue hemorrhage. There is no other evidence of medical intervention.

EVIDENCE OF INJURY

The ordering of the following injuries is for descriptive purposes only and is not intended to imply order of infliction or relative severity.

ACLU Detainee DeathII ARMY MEDCOM 108

There is a white plastic zip-tie strap around the right wrist, and there is blood coming from the right external auditory canal.

There is a 2 x 0.1 cm linear abrasion on the lower right side of the chest, and there is a healing 4 x 0.2 cm linear abrasion of the upper left side of the back. There is a 2.5 x 0.1 cm abrasion on the lateral aspect of the upper left arm, and there is a 3 x 0.1 cm healing abrasion on the medial aspect of the right elbow. There is a 2 x 1 cm abrasion on the lateral aspect of the right knee.

On internal examination of the head, chest and abdomen, there is no evidence of injury.

INTERNAL EXAMINATION

BODY CAVITIES:
The body is opened by the usual thoraco-abdominal incision and the chest plate is removed. No adhesions or abnormal collections of fluid are present in any of the body cavities. All body organs are present in the normal anatomical position. The vertebral bodies are visibly and palpably intact. The subcutaneous fat layer of the abdominal wall is 3 cm thick. There is no internal evidence of blunt force or penetrating injury to the thoraco-abdominal region.

HEAD; (CENTRAL NERVOUS SYSTEM)
The scalp is reflected, and there is no subgaleal hemorrhage or skull fractures found. The calvarium of the skull is removed. The dura mater and falx cerebri are intact. There is no epidural or subdural hemorrhage present. The leptomeninges are thin and delicate. The cerebrospinal fluid is clear. The cerebral hemispheres are symmetrical. The structures at the base of the brain, including cranial nerves and blood vessels, are intact. Coronal sections through the cerebral hemispheres revealed no lesions, and there is no evidence of infection, tumor, or trauma. The ventricles are of normal size. Transverse sections through the brain stem and cerebellum are unremarkable. The dura is stripped from the basilar skull, and no fractures are found. The atlanto-occipital joint is stable. The brain weighs 1370 grams. See "Neuropathology Report" below.

NECK;
Examination of the soft tissues of the neck, including strap muscles, thyroid gland and large vessels, reveals no abnormalities. The anterior strap muscles of the neck are homogeneous and red-brown, without hemorrhage. The thyroid cartilage and hyoid bone are intact. The larynx is lined by intact white mucosa and is unobstructed. The thyroid gland is symmetric and red-brown, without cystic or nodular change. There is no evidence of infection, tumor, or trauma, and the airway is patent. Incision and dissection of the posterior neck demonstrates no deep paracervical muscular injury, hemorrhage, or fractures of the dorsal spinous processes.

CARDIOVASCULAR SYSTEM:
The pericardial surfaces are smooth, glistening and unremarkable; the pericardial sac is free of significant fluid and adhesions. A moderate amount of epicardial fat is present. The

ACLU Detainee DeathII ARMY MEDCOM 109

coronary arteries arise normally in a right dominant pattern and follow the usual distribution. The chambers and valves exhibit the usual size-position relationship and are unremarkable. The myocardium is dark red-brown, firm and unremarkable; the atrial and ventricular septa are intact. The left ventricle is 1.5 cm in thickness and the right ventricle is 0.4 cm in thickness. The aorta and its major branches arise normally, follow the usual course and are widely patent, free of significant atherosclerosis and other abnormality. The venae cavae and their major tributaries return to the heart in the usual distribution and are free of thrombi. The heart weighs 470 grams. See "Cardiovascular Pathology Report" below.

RESPIRATORY SYSTEM:
The upper airway is clear of debris and foreign material; the mucosal surfaces are smooth, yellow-tan and unremarkable. The pleural surfaces are smooth, glistening and unremarkable bilaterally. The pulmonary parenchyma is red-purple, exuding a moderate amount of bloody fluid; no focal lesions are noted. The pulmonary arteries are normally developed, patent and without thrombus or embolus. The right lung weighs 764 grams; the left 614 grams.

LIVER & BILIARY SYSTEM:
The liver is globoid with very rounded margins. The hepatic capsule is smooth, glistening and intact, covering dark red-brown, moderately congested and slightly firm parenchyma with no focal lesions noted. The gallbladder contains 8 ml of green-brown, mucoid bile; the mucosa is velvety and unremarkable. The extrahepatic biliary tree is patent, without evidence of calculi. The liver weighs 1660 grams.

ALIMENTARY TRACT:
The tongue is free of bite marks, hemorrhage, or other injuries. The esophagus is lined by gray-white, smooth mucosa. The gastric mucosa is arranged in the usual rugal folds and the lumen contains 20 ml of fluid. The small and large bowel are unremarkable. The pancreas has a normal pink-tan lobulated appearance and the ducts are clear. The appendix is present and is unremarkable.

GENITOURINARY SYSTEM:
The renal capsules are smooth and thin, semi-transparent and strip with ease from the underlying smooth, red-brown cortical surfaces. The cortices are sharply delineated from the medullary pyramids, which are red-purple to tan and unremarkable. There are multiple smooth walled simple cysts, up to 1 cm in diameter. The calyces, pelves and ureters are otherwise unremarkable. White bladder mucosa overlies an intact bladder wall. The urinary bladder contains 30 ml of clear, yellow urine. The prostate gland is normal in size, with lobular, yellow-tan parenchyma. The seminal vesicles are unremarkable. The testes are free of mass lesions, contusions, or other abnormalities. The right kidney weighs 170 grams; the left 148 grams.

RETICULOENDOTHELIAL SYSTEM:
The spleen has a smooth, intact capsule covering red-purple, moderately firm parenchyma; the lymphoid follicles are unremarkable. The regional lymph nodes appear normal. The spleen weighs 225 grams.

ACLU Detainee DeathII ARMY MEDCOM 110

ENDOCRINE SYSTEM:
The pituitary, thyroid and adrenal glands are unremarkable.

MUSCULOSKELETAL SYSTEM:
Muscle development is normal. No bone or joint abnormalities are noted.

MICROSCOPIC EXAMINATION

HEART: See "Cardiovascular Pathology Report" below.

LUNGS: The alveolar spaces and small air passages are expanded with focal edema fluid, but no significant inflammatory component. The alveolar walls are thin and moderately congested. The arterial and venous vascular systems are normal. The peribronchial lymphatics are unremarkable.

LIVER: See "Hepatic Pathology Report" below.

SPLEEN: The capsule and white pulp are unremarkable. There is minimal congestion of the red pulp.

ADRENALS: The cortical zones are distinctive, and the medullae are not remarkable.

KIDNEYS: The subcapsular zones are unremarkable. The glomeruli are mildly congested without cellular proliferation, mesangial prominence, or sclerosis. The tubules are well preserved. There is no interstitial fibrosis or significant inflammation. There is no thickening of the walls of the arterioles or small arterial channels. The transitional epithelium of the collecting system is normal.

BRAIN: Multiple sections of brain demonstrate an unremarkable configuration of gray and white matter which is appropriate for age. There is no evidence of atrophy, inflammation, hemorrhage, or neoplasm. See "Neuropathology Report" below.

CARDIOVASCULAR PATHOLOGY REPORT

Department of Cardiovascular Pathology, AFIP:

"AFIP DIAGNOSIS: (b)(6) Moderate coronary atherosclerosis, mid right coronary artery; cardiomegaly with left ventricular hypertrophy

History: 40-50 year old Afghani male detainee, 67", 170 lbs, found dead in US custody

Heart: 475 grams (predicted normal value 343 grams, upper limit 453 grams for a 170 lbs man); normal epicardial fat; closed foramen ovale; normal cardiac chamber dimensions: left ventricular cavity diameter 30 mm, left ventricular free wall thickness 15 mm, ventricular septum thickness 15 mm; right ventricle thickness 4 mm, without gross scars or abnormal fat infiltrates; fenestrated aortic valve leaflets, otherwise unremarkable

ACLU Detainee DeathII ARMY MEDCOM 111

valves and endocardium; no gross myocardial fibrosis or necrosis; histologic sections show mild left ventricular myocyte hypertrophy, otherwise unremarkable

Coronary arteries: Normal ostia; right dominance; moderate atherosclerosis:

Left main coronary artery: 40% luminal narrowing by pathologic intimal thickening

Left anterior descending artery (LAD): 50% narrowing of proximal LAD by pathologic intimal thickening, no other significant narrowing

Left circumflex artery (LCA): 20% narrowing of proximal LCA, no other significant narrowing

Right coronary artery (RCA): 20% narrowing of proximal RCA, 70% narrowing of mid RCA by smooth muscle and proteoglycan rich neointima, consistent with healed plaque erosion; distal RCA and posterior descending artery open."

NEUROPATHOLOGY REPORT

Department of Neuropathology and Ophthalmic Pathology, AFIP:

"This case was reviewed in conference on 7 Apr 05. It was also seen in consultation with the Departments of Infectious and Parasitic Diseases Pathology.

Multiple irregular sections of formalin-fixed brain, 15 x 14 x 1.5 cm in aggregate, and a 4 x 3 cm fragment of grossly unremarkable dura were submitted for review. No significant gross abnormalities were identified in the submitted sections.

Summary of microscopic sections: 1. Basal ganglia. 2. Inferior temporal gyrus. 3. Cingulate gyrus. 4. Thalamus, hypothalamus, and substania nigra. 5. Cerebral cortex. 6. Pons. 7. Medulla. 8. Cerebellum.

The tissue was processed in paraffin; a section prepared from each paraffin block was stained with H&E. Additional sections prepared from selected paraffin blocks were stained with amyloid precursor protein, CD45RB, and CD68.

Microscopic sections of the medulla show two small foci of chronic inflammatory cells. Immunohistochemical staining for CD45RB highlight rare scattered lymphocytes in the medulla. Occasional vessels with widened perivascular spaces containing a few hemosiderin-laden macrophages are also noted. No microorganisms or viral inclusions are identified. These features are minimal and non-specific."

HEPATIC PATHOLOGY REPORT

Department of Hepatic Pathology, AFIP:

"There is moderate vascular congestion. No other specific lesion is identified except for mild "dusting" of hepatocytes with hemosiderin. Cause of death cannot be determined in this section of liver."

ACLU Detainee DeathII ARMY MEDCOM 112

ADDITIONAL PROCEDURES

- Documentary photographs are taken by OAFME photographers
- Specimens retained for toxicologic testing and/or DNA identification are: vitreous fluid, heart blood, urine, and bile
- The dissected organs are forwarded with the body
- Personal effects are released to the appropriate mortuary operations representative

OPINION

This adult male Afghanistan detainee died in US custody of atherosclerotic cardiovascular disease, with moderate coronary artery atherosclerosis (70% occlusion of right coronary artery; three vessel disease) and cardiomegaly (enlarged heart, 470 gm) with left ventricular hypertrophy. He also has an unusual, globoid shaped liver; however, no evidence of any chronic or active liver disease was found microscopically. He has evidence of restraint ("flexicuffs" around the right wrist); however, there is no evidence of significant trauma to explain the death.

The manner of death is natural.

(b)(6)

(b)(6) Medical Examiner

ACLU Detainee DeathII ARMY MEDCOM 113

DEPARTMENT OF DEFENSE
ARMED FORCES INSTITUTE OF PATHOLOGY
WASHINGTON, DC 20306-6000

REPLY TO
ATTENTION OF

AFIP: (b)(6)

TO:

OFFICE OF THE ARMED FORCES MEDICAL EXAMINER
ARMED FORCES INSTITUTE OF PATHOLOGY
WASHINGTON, DC 20306-6000

PATIENT IDENTIFICATION
AFIP Accessions Number Sequence
(b)(6)
Name
SHER, MOHAMMAD

SSAN: **Autopsy:** (b)(6)
Toxicology Accession #: (b)(6)
Date Report Generated: October 15, 2004

CONSULTATION REPORT ON CONTRIBUTOR MATERIAL

AFIP DIAGNOSIS **REPORT OF TOXICOLOGICAL EXAMINATION**

Condition of Specimens: GOOD
Date of Incident: **Date Received:** 10/4/2004

VOLATILES: The **BLOOD AND VITREOUS FLUID** were examined for the presence of ethanol at a cutoff of 20 mg/dL. No ethanol was detected.

DRUGS: The **URINE** was screened for amphetamine, antidepressants, antihistamines, barbiturates, benzodiazepines, cannabinoids, chloroquine, cocaine, dextromethorphan, lidocaine, lysergic acid diethylamide, narcotic analgesics, opiates, phencyclidine, phenothiazines, sympathomimetic amines and verapamil by gas chromatography, color test or immunoassay. The following drugs were detected:

None were found.

(b)(6)
Office of the Armed Forces Medical Examiner

(b)(6)
Office of the Armed Forces Medical Examiner

ACLU Detainee DeathII ARMY MEDCOM 114

ARMED FORCES INSTITUTE OF PATHOLOGY
Office of the Armed Forces Medical Examiner
1413 Research Blvd., Bldg. 102
Rockville, MD 20850
1-800-944-7912

FINAL AUTOPSY EXAMINATION REPORT

Name: BTB Abrahemy, Hasan Flah Hamed Hame
SSAN: ISN (b)(6)
Date of Birth: BTB 1977
Date of Death: (b)(6) 2004
Date of Autopsy: 04 OCT 2004
Date of Report: 04 NOV 2004

Autopsy No.: (b)(6)
AFIP No.: (b)(6)
Rank: Iraqi National
Place of Death: Abu Gharib Prison
Place of Autopsy: Baghdad Mortuary
Baghdad Airport, Iraq

Circumstances of Death: This believed to be 27 year old Iraqi National was a detainee in the Abu Gharib Prison, Iraq, that died of a perforating ballistic injury of the torso he sustained while in the prison yard. The decedent was witnessed to suddenly collapse while with a group of detainees and was found to have a possible gunshot wound of the chest. CID investigation indicated victim was injured when a gunfight occurred outside the prison and the decedent was hit with shrapnel from this fight. The suspected shrapnel was recovered on the ground near the decedent. Despite an emergent thoracotomy, the decedent died of his injury.

Authorization for Autopsy: Office of the Armed Forces Medical Examiner, IAW 10 USC 1471.

Identification: Identification is established by visual inspection of prison records.

CAUSE OF DEATH: Perforating Ballistic Injury of the Torso

MANNER OF DEATH: Homicide

FINAL AUTOPSY DIAGNOSES:

I. Perforating Ballistic Injury of the Torso

A. Injuries of the Torso
1. Probable entry injury is incorporated into thoracotomy incision and is identified as a 1.0 cm area of irregularity along the incision near the xiphoid process that is 18 inches below the top of the head (19 inches when re-approximated) and in the anterior midline. An oval defect is in the right sixth and seventh costal cartilages, beneath the skin irregularity.
2. A 1.0 x 1.0 cm shored exit wound that has a triangular skin tag at 5 o'clock and a 3.5 x 1.4 cm rectangular abrasion

ACLU Detainee DeathII ARMY MEDCOM 115

surrounding the defect, is 22 ½ inches below the top of the head and 2 inches right of the posterior midline.

3. Projectile path: Perforation of the skin and muscle immediately right of the xiphoid process at the right sixth costal cartilage, the left lobe of the liver, the intrahepatic portion of the inferior vena cava, the head of the pancreas, the right adrenal gland, the right renal vein, a superior branch of the right renal artery, the upper pole of the right kidney, the posterior aspect of the right leaflet of the diaphragm, the right twelfth rib and the lateral portion of the body of the first lumbar vertebra and perforation of the muscle and skin of the mid-right back.
4. Projectile direction: Front to back, left to right and slightly down.
5. Associated findings: Bilateral hemothorax (approximately 500 ml right and 200 ml left); hemoperitoneum (approximately 50 ml surrounding spleen)
6. Trace evidence recovered: None

B. Penetrating Injury of the Left Lower Leg
   1. A 0.7 x 0.3 cm crusted superficial penetrating injury of the lateral surface of the left lower leg into the skin only.
   2. Trace evidence recovered: small gray-black metallic fragment.

C. Other injuries
   1. Four recent (days) superficial incised wounds of the left forearm.

II. Medical Intervention
   1. Thoracotomy incision of the bilateral fifth intercostal spaces and sternum.
   2. Chest tube insertion site in the left 7th intercostal space.
   3. Needle puncture wound with surrounding ecchymosis on the left side of the neck.
   4. Needle puncture marks over the veins of the anterior surface of the right arm.
   5. Right femoral triangle puncture site with remaining suture material in the skin.

III. No significant natural diseases identified, within limitations of the examination.

IV. Identifying marks
   1. (b)(6) tattoo (b)(6)
   2. tattoo
   3. tattoo

ACLU Detainee DeathII ARMY MEDCOM 116

4. (b)(6) (b)(6) **tattoo** (b)(6)
5. (b)(6) (b)(6) **tattoo** (b)(6)
6. **Multiple linear scars on the left upper extremity, the chest, and the abdomen.**

V. **Toxicology is negative for ethanol. Diazepam (0.05 mg/L) and Nordiazepam (0.06 mg/L) are present in the chest blood.**

ACLU Detainee DeathII ARMY MEDCOM 117

EXTERNAL EXAMINATION

The body is that of a well-developed, thin appearing 68 inch long, 130 pounds (estimated) Iraqi male whose appearance is consistent with the reported age of approximately 27 years. Lividity is fixed posteriorly with pressure bearing area pallor. Rigor is easily broken in the extremities, and the temperature is cold from refrigeration.

The scalp is covered with black curly hair in a normal distribution. The irides are brown, and the pupils are round and equal in diameter. The external auditory canals are dry. The ears are unremarkable. The nares are patent and the lips are atraumatic. The nose and maxillae are palpably stable. The teeth appear natural and in good repair. The facial hair consists of a goatee style beard and mustache.

The neck is straight, and the trachea is midline and mobile. The chest is symmetric. There are injuries of the chest that are listed below. The abdomen is flat. The genitalia are those of a normal adult circumcised male. The testes are descended and free of masses. Pubic hair is present in a normal distribution. The buttocks and anus are unremarkable.

The upper and lower extremities are symmetric and without clubbing or edema.

There are multiple linear scars of various lengths on the chest, abdomen and posterior lateral surface of the left arm. (b)(6) tattoo (b)(6)
(b)(6) tattoo (b)(6)
(b)(6) tattoo (b)(6)
tattoo (b)(6) tattoo (b)(6)
(b)(6)

CLOTHING AND PERSONAL EFFECTS

The following clothing items and personal effects are present on the body at the time of autopsy:

A blood soaked dark colored t-shirt is in the body bag.

MEDICAL INTERVENTION

A non-sutured thoractomy incision of the fifth intercostal space begins on the left flank and traverses the sternum and terminates on the right chest, the pericardium is surgically opened, a puncture mark surrounded by an 8 x 8 cm ecchymosis is over the left jugular vein, a chest tube site is in the left seventh intercostal space, four (4) puncture marks are on the anterior surface of the right upper arm, and a puncture mark is in the right femoral triangle and is associated with suture material.

RADIOGRAPHS

A complete set of postmortem radiographs is obtained and demonstrates the following:

A metallic fragment in the left leg; no long bone fractures; and no other foreign bodies.

ACLU Detainee DeathII ARMY MEDCOM 118

EVIDENCE OF INJURY

The ordering of the following injuries is for descriptive purposes only, and is not intended to imply order of infliction or relative severity. All wound pathways are given relative to standard anatomic position.

I. Perforating Ballistic Injury of the Torso

A. Injuries of the Torso

1. Probable entry injury is incorporated into the thoracotomy incision and is identified as a 1.0 cm area of irregularity along the incision near the xiphoid process that is 18 inches below the top of the head (19 inches when re-approximated) and in the anterior midline. An oval defect is in the right sixth and seventh costal cartilage, beneath the skin irregularity.
2. A 1.0 x 1.0 cm shored exit wound that has a triangular skin tag at 5 o'clock and a 3.5 x 1.4 cm rectangular abrasion surrounding the defect, is 22 ½ inches below the top of the head and 2 inches right of the posterior midline.
3. Projectile path: Perforation of the skin and muscle immediately right of the xiphoid process at the right sixth costal cartilage, the left lobe of the liver, the intrahepatic portion of the inferior vena cava, the head of the pancreas, the right adrenal gland, the right renal vein, a superior branch of the right renal artery, the upper pole of the right kidney, the posterior aspect of the right leaflet of the diaphragm, the right twelfth rib and the lateral portion of the body of the first lumbar vertebra and perforation of the muscle and skin of the mid-right back.
4. Projectile direction: Front to back, left to right and slightly down.
5. Associated findings: Bilateral hemothorax (approximately 500 ml right and 200 ml left); hemoperitoneum (approximately 50 ml surrounding spleen)
6. Trace evidence recovered: None

B. Penetrating Injury of the Left Lower Leg

1. A 0.7 x 0.3 cm crusted superficial penetrating injury of the lateral surface of the left lower leg into the skin only.
2. Trace evidence recovered: small gray-black metallic fragment.

C. Other injuries

1. Four recent (days) superficial incised wounds of the left forearm.

ACLU Detainee DeathII ARMY MEDCOM 119

INTERNAL EXAMINATION

HEAD:
The galeal and subgaleal soft tissues of the scalp are free of injury. The calvarium is intact, as is the dura mater beneath it. Clear cerebrospinal fluid surrounds the 1180 gm brain, which has unremarkable gyri and sulci. Coronal sections demonstrate sharp demarcation between white and grey matter, without hemorrhage or contusive injury. The ventricles are of normal size. The basal ganglia, brainstem, cerebellum, and arterial systems are free of injury or other abnormalities. There are no skull fractures. The atlanto-occipital joint is stable.

NECK:
The anterior strap muscles of the neck are homogenous and red-brown, without hemorrhage. The thyroid cartilage is intact. The hyoid bone is fractured but not associated with any surrounding ecchymosis. The larynx is lined by intact white mucosa. The thyroid is symmetric and red-brown, without cystic or nodular change. The tongue is free of bite marks, hemorrhage, or other injuries.

BODY CAVITIES:
The ribs (except where noted above) and the vertebral bodies are visibly and palpably intact. There are approximately 200 ml of blood in the left pleural cavity and 500 ml of blood in the right pleural cavity. Approximately 50 ml of blood surrounds the spleen. The organs occupy their usual anatomic positions.

RESPIRATORY SYSTEM:
The right and left lungs weigh 250 and 274 gm, respectively. The lungs are atelectatic. The external surfaces are smooth and deep red-purple. The pulmonary parenchyma is diffusely congested and edematous. No mass lesions or areas of consolidation are present.

CARDIOVASCULAR SYSTEM:
The 288 gm heart is contained in a surgically opened pericardial sac. The epicardial surface is smooth, with minimal fat investment. The coronary arteries are present in a normal distribution, with a right-dominant pattern. Cross sections of the vessels show no atherosclerosis. The myocardium is homogenous, red-brown, and firm. The valve leaflets are thin and mobile. The walls of the left and right ventricles are 1.2 and 0.2-cm thick, respectively. The endocardium is smooth and glistening. The aorta gives rise to three intact and patent arch vessels. The aorta has mild atheromatous streaking. The renal (except where noted above) and mesenteric vessels are unremarkable.

LIVER & BILIARY SYSTEM:
The 1375 gm liver has the injuries described. The parenchyma is tan-brown and congested, with the usual lobular architecture. No mass lesions or other abnormalities are seen. The gallbladder contains a minute amount of green-black bile and no stones. The gallbladder mucosal surface is green and velvety. The extrahepatic biliary tree is patent.

ACLU Detainee DeathII ARMY MEDCOM 120

SPLEEN:
The 107gm spleen has a smooth, intact, red-purple capsule. The parenchyma is maroon and congested, with distinct Malpighian corpuscles.

PANCREAS:
The pancreas is firm and yellow-tan, with the usual lobular architecture. No mass lesions or other abnormalities are seen.

ADRENALS:
The right and left adrenal glands are symmetric, with bright yellow cortices and grey medullae. No masses or areas of hemorrhage are identified.

GENITOURINARY SYSTEM:
The right and left kidneys weigh 95 and 94-gm, respectively. The external surfaces are intact and smooth. The cut surfaces are red-tan and congested, with uniformly thick cortices and sharp corticomedullary junctions. The pelves are unremarkable and the ureters are normal in course and caliber. White bladder mucosa overlies an intact bladder wall. The bladder contains approximately 50 ml of cloudy red/yellow urine. The prostate is normal in size, with lobular, yellow-tan parenchyma. The seminal vesicles are unremarkable. The testes are free of mass lesions, contusions, or other abnormalities.

GASTROINTESTINAL TRACT:
The esophagus is intact and lined by smooth, grey-white mucosa. The gastric wall is intact. The duodenum, loops of small bowel, and colon are unremarkable. The appendix is present.

ADDITIONAL PROCEDURES

- Documentary photographs are taken by (b)(6)
- Specimens retained for toxicologic testing and/or DNA identification are: blood, urine, vitreous fluid, spleen, kidney, liver, brain, lung, bile, gastric contents, and psoas muscle.
- The dissected organs are forwarded with body.
- Personal effects are released to the appropriate mortuary operations representatives.

MICROSCOPIC EXAMINATION

Selected portions of organs are retained in formalin, without preparation of histologic slides.

ACLU Detainee DeathII ARMY MEDCOM 121

OPINION

This believed to be 27 year old Iraqi National was a detainee in the Abu Gharib Prison, Iraq, that died of a perforating ballistic injury of the torso he sustained while in the prison yard. A foreign body from a gunfight that was occurring outside the prison walls hit the decedent. The diazepam and nordiazepam found in the chest blood are of undetermined origin. The manner of death is homicide.

(b)(6)

(b)(6) **Medical Examiner**

ACLU Detainee DeathII ARMY MEDCOM 122

ARMED FORCES INSTITUTE OF PATHOLOGY
Office of the Armed Forces Medical Examiner
1413 Research Blvd., Bldg. 102
Rockville, MD 20850
1-800-944-7912

FINAL AUTOPSY EXAMINATION REPORT

Name: Habib, Fras M.
SSAN: Detainee Number (b)(6)
Date of Birth: Unknown
Date of Death: (b)(6) 2004
Date of Autopsy: 30 AUG 2004
Date of Report: 12 OCT 2004

Autopsy No.: (b)(6)
AFIP No.: (b)(6)
Rank: Detainee in U.S. Custody
Place of Death: Iraq
Place of Autopsy: BIAP Mortuary, Baghdad, Iraq

Circumstances of Death: This Iraqi male was a detainee in U.S. custody at Abu Ghraib prison in Baghdad, Iraq. A group of prisoners became unruly and the guards used lethal force to subdue the crowd. A shotgun was fired and this detainee was struck and killed.

Authorization for Autopsy: Armed Forces Medical Examiner, per 10 U.S. Code 1471

Identification: Circumstantial identity is established by paperwork accompanying the detainee and his designation as detainee number (b)(6)

CAUSE OF DEATH: Shotgun Wound of the Chest

MANNER OF DEATH: Homicide

FINAL AUTOPSY DIAGNOSES:

I. Shotgun Wounds of the Torso and Both Arms

A. Penetrating Shotgun Wound of the Chest
1. **Entrance: Left side of the back; no evidence of close-range discharge of a firearm on the surrounding skin**
2. **Wound Path: Skin, subcutaneous tissue, and muscle of the left back, posterior left 9th rib (with fracture), lower lobe of left lung, left atrium, right atrium, upper lobe of the right lung, intercostal space below the anterior aspect of the right 2nd rib, muscle and subcutaneous tissue of the right upper chest**
3. **Recovered: Deformed metallic foreign body located in the subcutaneous tissue of the right upper chest**
4. **Wound Direction: Left to right, back to front, and upward**
5. **Associated Injuries: Bilateral hemothoraces (right 1400-milliliters; left 2100-milliliters), hemopericardium (50-milliliters)**

B. Perforating Shotgun Wound of the Right Upper Back
1. **Entrance: Right upper back; no evidence of close-range discharge of a firearm on the surrounding skin**
2. **Wound Path: Skin and subcutaneous tissue of the right upper back (tangential wound path)**
3. **Exit: Right upper back; no projectile recovered**
4. **Wound Direction: Left to right and slightly upward**

C. Perforating Shotgun Wound of the Right Arm
1. **Entrance: Posterior right arm; no evidence of close-range discharge of a firearm on the surrounding skin**
2. **Wound Path: Skin, subcutaneous tissue, and muscle of the posterior right arm; muscle, subcutaneous tissue, and skin of the anterior right arm**
3. **Exit: Anterior right arm; no projectile recovered**
4. **Wound Direction: Left to right and back to front (with the body in anatomic position)**

D. Perforating Shotgun Wound of the Left Arm
1. **Entrance: Posterior left arm; no evidence of close-range discharge of a firearm on the surrounding skin**
2. **Wound Path: Skin, subcutaneous tissue, and muscle of the posterior left arm; muscle, subcutaneous tissue, and skin of the anterior left arm**
3. **Exit: Anterior left arm; no projectile recovered**
4. **Wound Direction: Left to right, back to front, and downward (with the body in anatomic position)**

ACLU Detainee DeathII ARMY MEDCOM 124

II. **No evidence of significant natural disease processes, within the limitations of the examination**

III. **Changes of early to moderate decomposition**

IV. **The recovered projectile is placed in a labeled container and turned over to the investigating agent who was present at the autopsy**

V. **Toxicology is negative for ethanol and drugs of abuse**

ACLU Detainee DeathII ARMY MEDCOM 125

EXTERNAL EXAMINATION

The remains are received clad in a cut away green shirt and white, boxer type shorts. No identification band is noted on the body, but the sequence of numbers (b)(6) is written on the lower chest left of the anterior midline. The body is in an early to moderate state of decomposition, with changes that include clouding of the corneae, loss of turgor of the globes of the eyes, marbling of the soft tissue, and generalized skin slippage. Bloody fluid is present in the oral cavity.

The body is that of a well-developed, well-nourished appearing, 70 ½-inches, 180-pounds (estimated), White male. The age of the individual is unknown. Lividity is posterior and fixed, except in areas exposed to pressure. Rigor has passed. The body temperature is that of the refrigeration unit.

The scalp is covered with medium length, black hair in a normal distribution. Facial hair consists of a black beard. The irides are brown and the pupils are round and equal in diameter. The external ears are unremarkable. The nose and maxillae are palpably stable. The teeth are natural and in fair condition.

The neck is mobile and the trachea is midline. The chest is symmetric. The abdomen is flat. The external genitalia are those of a normal adult, circumcised, male. Both testes are descended into the scrotum. Pubic hair is present in a normal distribution. There is no evidence of external trauma to the urogenital area. The buttocks and anus are unremarkable.

The upper and lower extremities are symmetric and without clubbing or edema. The fingernails are intact. No tattoos or other significant identifying body marks are noted.

EVIDENCE OF MEDICAL INTERVENTION

- Electrocardiogram monitoring pads on both sides of the upper chest and on the left lower quadrant of the abdomen
- Gauze dressing is tied around the wrists and feet

RADIOGRAPHS

Full body radiographs are obtained and show a metallic foreign body on the right side of the upper torso.

EVIDENCE OF INJURY

I. Shotgun Wounds of the Torso and Both Arms

A. Penetrating Shotgun Wound of the Chest

There is an entrance shotgun wound on the left side of the back, situated 18-inches below the top of the head and 3 ½-inches left of the posterior midline. No soot deposition or gunpowder stippling is present on the surrounding skin. The 3/16-inch wound has a 1/8-inch marginal abrasion between 5 and 8 o'clock. The wound path goes through the skin, subcutaneous tissue, and muscle of the left side

ACLU Detainee DeathII ARMY MEDCOM 126

of the back and enters the pleural cavity through the posterior aspect of the left 9th rib, which is fractured. The path then continues through the lower lobe of the left lung, the pericardium, both atria of the heart, the pericardium, and the upper lobe of the right lung. The wound path then exits the right pleural cavity below the anterior aspect of the right 2nd rib and perforates the chest wall musculature. A deformed, metallic projectile is recovered from the subcutaneous tissue of the right upper chest. The projectile is placed in a labeled container and turned over to the investigating USACID agent. Injuries associated with the wound path include bilateral hemothoraces (right 1400 milliliters; left 2100-milliliters) and hemopericardium (50-milliliters). The direction of the wound path is left to right, back to front, and upward.

B. Perforating Shotgun Wound of the Right Upper Back
There is an entrance shotgun wound on the right upper back, situated 16-inches below the top of the head and 7 1/8-inches right of the posterior midline of the body. The 5/16-inch wound has a ½ x 5/8-inch eccentric marginal abrasion between 6 and 12 o'clock. No soot deposition or gunpowder stippling is present on the surrounding skin. The wound path goes through skin and subcutaneous tissue prior to exiting the body through a ¼-inch skin defect situated 15-inches below the top of the head and 8-inches right of the posterior midline. A ¼ x ¼-inch eccentric marginal abrasion is present between 12 and 6 o'clock. No bullet or bullet fragments are recovered. The direction of the wound path is left to right and slightly upward.

C. Perforating Shotgun Wound of the Right Arm
There is an entrance shotgun wound on the posterior aspect of the right arm, situated 6-inches below the top of the right shoulder and 2-inches medial of the posterior midline of the right arm. The 1/4-inch, irregular, defect is surrounded by a minimal ring of contusion. No soot deposition or gunpowder stippling is present on the surrounding skin. The wound path goes through the skin, subcutaneous tissue, and muscle of the posterior right arm and the muscle, subcutaneous tissue, and skin of the anterior right arm. A ¼-inch exit wound within a 1 ½ x 1-inch area of contusion is situated 6-inches below the top of the right shoulder and 1 ¾-inches lateral to the anterior midline of the right arm. No bullet or bullet fragments are recovered. The direction of the wound path is left to right and back to front.

D. Perforating Shotgun Wound of the Left Arm
There is an entrance shotgun wound on the posterior aspect of the left arm, situated 5-inches below the top of the left shoulder and 2-inches medial to the posterior midline of the left arm. The 1/4-inch, irregular, ovoid defect has no associated abrasion or contusion. No soot deposition or gunpowder stippling is present on the surrounding skin. The wound path goes through the skin, subcutaneous tissue, and muscle of the posterior left arm and the muscle, subcutaneous tissue, and skin of the anterior left arm. A ¼-inch exit wound within a 1-inch area of contusion is situated 7 1/4-inches below the top of the left

ACLU Detainee DeathII ARMY MEDCOM 127

shoulder and ¼-inch medial to the anterior midline of the left arm. No bullet or bullet fragments are recovered. The direction of the wound path is left to right, back to front, and downward.

INTERNAL EXAMINATION

HEAD:
The scalp is uninjured. There are no skull fractures or other evidence of significant trauma present. The calvarium is removed to demonstrate an absence of epidural or subdural hemorrhage. Examination of the brain reveals a normal pattern of gyri and sulci. Serial sectioning reveals no evidence of traumatic or atraumatic abnormalities. The vessels at the base of the brain have a normal distribution and appearance. The brain weighs 1380-grams.

NECK:
The thyroid cartilage and hyoid bone are intact. The larynx is lined by intact white mucosa. The thyroid gland is symmetric and red-brown, without cystic or nodular change. The tongue is free of bite marks, hemorrhage, or other injuries.

BODY CAVITIES:
The ribs, sternum, and vertebral bodies are visibly and palpably intact. Injuries to the chest and mediastinum have been described previously. There is no abnormal accumulation of fluid in the peritoneal cavity. The organs occupy their usual anatomic positions.

RESPIRATORY SYSTEM:
The right and left lungs weigh 320 and 180-grams, respectively, and have the previously described injuries. The external surfaces are deep red-purple. No mass lesions or areas of consolidation are present. The pulmonary arteries are free of emboli.

CARDIOVASCULAR SYSTEM:
The 310-gram heart has the previously described injuries. The epicardial surface is smooth, with minimal fat investment. The coronary arteries are present in a normal distribution, with a right-dominant pattern. Cross sections of the vessels show no significant atherosclerosis. The myocardium is homogenous, red-brown, and firm. The valve leaflets are thin and mobile. The walls of the left and right ventricles are 1.4 and 0.5-centimeters thick, respectively. The endocardium is smooth and glistening. The aorta gives rise to three intact and patent arch vessels. The renal and mesenteric vessels are unremarkable.

LIVER & BILIARY SYSTEM:
The 1450-gram liver has an intact, smooth capsule and a sharp anterior border. The parenchyma is tan-brown and congested, with the usual lobular architecture. No mass lesions or other abnormalities are seen. The gallbladder is empty. The mucosal surface is green and velvety. The extrahepatic biliary tree is patent.

ACLU Detainee DeathII ARMY MEDCOM 128

SPLEEN:
The 180-gram spleen has a smooth, intact, red-purple capsule. The parenchyma is soft, maroon, and congested, with early decompositional changes.

PANCREAS:
The pancreas exhibits early to moderate decompositional changes.

ADRENAL GLANDS:
The right and left adrenal glands are symmetric, with yellow cortices, gray medullae, and early decompositional changes. No masses or areas of hemorrhage are identified.

GENITOURINARY SYSTEM:
The right and left kidneys weigh 140 and 110-grams, respectively. The external surfaces are intact and smooth. The cut surfaces are red-tan and congested, with uniformly thick cortices and sharp corticomedullary junctions. The pelves are unremarkable and the ureters are normal in course and caliber. White bladder mucosa overlies an intact bladder wall. The urinary bladder contains 150-milliliters of light yellow urine.

GASTROINTESTINAL TRACT:
The esophagus is intact and lined by smooth, hemorrhagic appearing mucosa. The stomach contains approximately 100-milliliters food particles, including beans and rice. The gastric wall is intact. The duodenum, loops of small bowel, and colon are unremarkable. The appendix is present.

MUSCULOSKELETAL:
No non-traumatic abnormalities of muscle or bone are identified.

MICROSCOPIC EXAMINATION

Selected portions of organs are retained in formalin, without preparation of histologic slides

ACLU Detainee DeathII ARMY MEDCOM 129

ADDITIONAL PROCEDURES/REMARKS

- Documentary photographs are taken by OAFME staff photographer, (b)(6) (b)(6)
- Specimens retained for toxicologic testing and/or DNA identification are: cavity blood, spleen, liver, brain, bile, urine, lung, gastric contents, kidney, and psoas muscle
- Full body radiographs are obtained and demonstrate the metallic foreign body subsequently recovered from the right chest wall
- The dissected organs and clothing are forwarded with body

OPINION

This White male detainee in U.S. custody died as a result of a shotgun wound to the chest that caused injury to the lungs and heart. There was also extensive bleeding into the chest cavity. A metallic projectile was recovered from the subcutaneous tissue of the right upper chest and turned over to the USACID Agent who was present at the autopsy. Additional shotgun wound paths involved the right upper back and both arms. The location and appearance of the wound paths involving the right upper back and right arm make it likely that a single projectile resulted in both wounds, with re-entry of the projectile into the right arm after exiting the right back. The manner of death is homicide.

(b)(6)

(b)(6) **Medical Examiner** (b)(6)

ACLU Detainee DeathII ARMY MEDCOM 130

DEPARTMENT OF DEFENSE
ARMED FORCES INSTITUTE OF PATHOLOGY
WASHINGTON, DC 20306-6000

REPLY TO
ATTENTION OF

AFIP (b)(6)

TO:

OFFICE OF THE ARMED FORCES MEDICAL EXAMINER
ARMED FORCES INSTITUTE OF PATHOLOGY
WASHINGTON, DC 20306-6000

PATIENT IDENTIFICATION
AFIP Accessions Number Sequence
(b)(6)
Name
HABIB, FAAS M.
Detainee ID: (b)(6)
SSAN: **Autopsy:** (b)(6)
Toxicology Accession #: (b)(6)
Date Report Generated: September 13, 2004

CONSULTATION REPORT ON CONTRIBUTOR MATERIAL

AFIP DIAGNOSIS **REPORT OF TOXICOLOGICAL EXAMINATION**

Condition of Specimens: GOOD
Date of Incident: (b)(6) 2004 **Date Received:** 9/7/2004

VOLATILES: The **BLOOD** and **URINE** were examined for the presence of ethanol at a cutoff of 20 mg/dL. No ethanol was detected.

DRUGS: The **BLOOD** was screened for acetaminophen, amphetamine, antidepressants, antihistamines, barbiturates, benzodiazepines, cannabinoids, chloroquine, cocaine, dextromethorphan, lidocaine, narcotic analgesics, opiates, phencyclidine, phenothiazines, salicylates, sympathomimetic amines and verapamil by gas chromatography, color test or immunoassay. The following drugs were detected:

None were found.

(b)(6)
Office of the Armed Forces Medical Examiner

(b)(6)
Office of the Armed Forces Medical Examiner

ACLU Detainee DeathII ARMY MEDCOM 131

ARMED FORCES INSTITUTE OF PATHOLOGY
Office of the Armed Forces Medical Examiner
1413 Research Blvd., Bldg. 102
Rockville, MD 20850
1-800-944-7912

FINAL AUTOPSY EXAMINATION REPORT

Name: Ghafar, Husham N.
SSAN: Detainee Number (b)(6)
Date of Birth: Unknown
Date of Death: (b)(6) 2004
Date of Autopsy: 30 AUG 2004
Date of Report: 12 OCT 2004

Autopsy No.: (b)(6)
AFIP No.: (b)(6)
Rank: Detainee in U.S. Custody
Place of Death: Iraq
Place of Autopsy: BIAP Mortuary, Baghdad, Iraq

Circumstances of Death: This Iraqi male was a detainee in U.S. custody at Abu Ghraib prison in Baghdad, Iraq. A group of prisoners became unruly and the guards used lethal force to subdue the crowd. A shotgun was fired and this detainee was struck and killed.

Authorization for Autopsy: Armed Forces Medical Examiner, per 10 U.S. Code 1471

Identification: Circumstantial identity is established by paperwork accompanying the detainee and his designation as detainee number (b)(6)

CAUSE OF DEATH: Shotgun Wound of the Head

MANNER OF DEATH: Homicide

ACLU Detainee DeathII ARMY MEDCOM 132

FINAL AUTOPSY DIAGNOSES:

I. **Shotgun Wound of the Head**

   A. **Penetrating Shotgun Wound of the Head**
      1. **Entrance: Right side of the back of the head; no evidence of close-range discharge of a firearm on the surrounding scalp**
      2. **Wound Path: Right parietal-occipital scalp, parietal-occipital skull, right cerebrum, left cerebrum**
      3. **Recovered: Deformed metallic foreign body located between the medial aspect of the left frontal lobe and the overlying dura**
      4. **Wound Direction: Right to left, back to front, and upward**
      5. **Associated Injuries: Subgaleal, subdural and subarachnoid hemorrhages, bilateral basilar skull fractures, cerebral contusions, and bone fragments along the hemorrhagic wound path**

II. **No evidence of significant natural disease processes, within the limitations of the examination**

III. **Changes of early to moderate decomposition**

IV. **The recovered projectile is placed in a labeled container and given to the investigating agent who was present at the autopsy**

V. **Toxicology is positive for morphine at a concentration of 0.23 mg/L in the blood. No ethanol or other drugs of abuse are detected.**

ACLU Detainee DeathII ARMY MEDCOM 133

EXTERNAL EXAMINATION

The remains are received without clothing. No identification bands are present on the body. The unclad body is that of a well-developed, well-nourished appearing, 69-inches, 140-pounds (estimated), White male. The age of the individual is not known. Lividity is posterior and fixed, except in areas exposed to pressure. Rigor has passed. The body temperature is that of the refrigeration unit. Early to moderate decomposition changes are present, including mild skin slippage, prominent vascular marbling, and clouding of the corneae.

The scalp is covered with medium length, brown hair in a normal distribution. Facial hair consists of a beard and mustache. The irides are brown and the pupils are round and equal in diameter. The external ears are unremarkable. The nose and maxillae are palpably stable. Bloody fluid is present in the nares. The teeth are natural and in fair condition.

The neck is mobile and the trachea is midline. The chest is symmetric. The abdomen is flat. The external genitalia are those of a normal adult male. Pubic hair is shaved. There is no evidence of external trauma to the urogenital area. The buttocks and anus are unremarkable. There are areas of hypopigmentation present on the lower trunk and the extremities.

The upper and lower extremities are symmetric and without clubbing or edema. The fingernails are intact. No tattoos or significant identifying body marks are present. Black writing is present on both sides of the chest; (b)(6) is on the right side and a series of illegible numbers is on the left side.

EVIDENCE OF MEDICAL INTERVENTION

- Vascular access devices in the left arm, both antecubital fossae, and the left subclavian area
- Oral-gastric intubation
- Endotracheal intubation
- Foley catheterization
- Electrocardiogram monitoring pads on the upper right chest and the left hip
- Contusion over the sternum, consistent with cardiopulmonary resuscitation

RADIOGRAPHS

Full body radiographs are obtained and show a metallic foreign body in the head.

EVIDENCE OF INJURY

I. Shotgun Wound of the Head

There is a penetrating ballistic entrance wound on the right side of the back of the head, situated 4 3/8-inches below the top of the head and 2 ¼-inches right of the posterior midline. The ovoid wound is ¼ x 3/16-inches, with a 1/16-inch marginal

ACLU Detainee DeathII ARMY MEDCOM 134

abrasion from the 3 to 6 o'clock positions. No soot deposition or gunpowder stippling is present on the surrounding skin. The wound path goes through the occipital scalp and includes a 5/16 x 3/8-inch defect in the right side of the occipital bone, with appropriate beveling. The wound path through the brain perforates the right occipital, right parietal, and both frontal lobes. A slightly deformed, round, metallic projectile is recovered from the dura overlying the medial aspect of the left frontal lobe of the brain at the anterior midline. The projectile is placed in a labeled container and turned over to the investigating USACID agent present at the autopsy. The wound direction is right to left, back to front, and upward. Injuries associated with the wound path include fine linear fractures extending across the middle fossae of the basilar skull, a 1-inch linear fracture of the occipital bone extending from the 4 o'clock position of the entrance wound skull defect, and subgaleal, subdural, and subarachnoid hemorrhages. Scattered cerebral contusions and bone fragments along the hemorrhagic wound path are also present.

INTERNAL EXAMINATION

HEAD:
Injuries of the head have been described previously. The vessels at the base of the brain have a normal distribution and appearance. The brain weighs 1150-grams.

NECK:
The thyroid cartilage and hyoid bone are intact. The larynx is lined by intact white mucosa. The thyroid gland is symmetric and red-brown, without cystic or nodular change. The tongue is free of bite marks, hemorrhage, or other injuries.

BODY CAVITIES:
The ribs, sternum, and vertebral bodies are visibly and palpably intact. Both pleural cavities contain 100-milliliters of decomposition fluid and the pericardial sac contains 20-milliliters of decomposition fluid. There is no abnormal accumulation of fluid in the peritoneal cavity. The organs occupy their usual anatomic positions.

RESPIRATORY SYSTEM:
The right and left lungs weigh 580 and 550-grams, respectively. The external surfaces are smooth and deep red-purple, with moderate anthracotic mottling. The pulmonary parenchyma is diffusely congested and edematous. No mass lesions or areas of consolidation are present. The pulmonary arteries are unremarkable.

CARDIOVASCULAR SYSTEM:
The 220-gram heart is contained in an intact pericardial sac. The epicardial surface is smooth, with minimal fat investment. The coronary arteries are present in a normal distribution, with a right-dominant pattern. Cross sections of the vessels show no significant atherosclerosis. The myocardium is homogenous, red-brown, and soft, with early decompositional changes. The valve leaflets are thin and mobile. The walls of the left and right ventricles are 1.1 and 0.3-centimeters thick, respectively. The endocardium is smooth. The aorta gives rise to three intact and patent arch vessels. Fatty streaking of the aorta is noted. The renal and mesenteric vessels are unremarkable.

ACLU Detainee DeathII ARMY MEDCOM 135

LIVER & BILIARY SYSTEM:
The 1050-gram liver has an intact, smooth capsule and a sharp anterior border. The parenchyma is tan-brown and congested, with the usual lobular architecture and changes of early decomposition. No mass lesions or other abnormalities are seen. The gallbladder contains 15-milliliters of green-black bile and no stones. The mucosal surface is green and velvety. The extrahepatic biliary tree is patent.

SPLEEN:
The 240-gram spleen has a smooth, intact, red-purple capsule. The parenchyma is soft, maroon, and congested, with changes of early decomposition.

PANCREAS:
The pancreas has the usual lobular architecture and early decompositional changes. No mass lesions or other abnormalities are seen.

ADRENAL GLANDS:
The right and left adrenal glands are symmetric, with yellow cortices, gray medullae, and decompositional changes. No masses or areas of hemorrhage are identified.

GENITOURINARY SYSTEM:
The right and left kidneys weigh 150 and 120-grams, respectively. The external surfaces are intact and smooth. The cut surfaces are red-tan and congested, with uniformly thick cortices and distinct corticomedullary junctions. The pelves are unremarkable and the ureters are normal in course and caliber. White bladder mucosa overlies an intact bladder wall. The urinary bladder is empty. The prostate gland is unremarkable. The testes have no masses and exhibit no evidence of trauma.

GASTROINTESTINAL TRACT:
The esophagus is intact and lined by smooth, hemorrhagic appearing mucosa. The stomach contains approximately 70-milliliters of dark brown fluid. The gastric wall is intact. The duodenum, loops of small bowel, and colon are unremarkable. The appendix is present.

MUSCULOSKELETAL:
No non-traumatic abnormalities of muscle or bone are identified.

MICROSCOPIC EXAMINATION

Selected portions of organs are retained in formalin, without preparation of histologic slides

ACLU Detainee DeathII ARMY MEDCOM 136

ADDITIONAL PROCEDURES/REMARKS

- Documentary photographs are taken by OAFME staff photographer, (b)(6) (b)(6)
- Specimens retained for toxicologic testing and/or DNA identification are: heart blood, spleen, liver, brain, bile, lung, kidney, adipose, and psoas muscle
- Full body radiographs are obtained and demonstrate the metallic foreign body subsequently recovered from the brain
- The dissected organs are forwarded with body

OPINION

This White male detainee in U.S. custody died as a result of a shotgun wound of the head that caused injury to the skull and brain. Toxicology was positive for morphine, which was likely the result of medical therapy received prior to death. One metallic projectile was recovered from the head and turned over to the investigating USACID agent who was present at the autopsy. The manner of death is homicide.

(b)(6)

(b)(6) **Medical Examiner** (b)(6)

ACLU Detainee DeathII ARMY MEDCOM 137

DEPARTMENT OF DEFENSE
ARMED FORCES INSTITUTE OF PATHOLOGY
WASHINGTON, DC 20306-6000

REPLY TO ATTENTION OF

AFIP: (b)(6)

TO:

OFFICE OF THE ARMED FORCES MEDICAL EXAMINER
ARMED FORCES INSTITUTE OF PATHOLOGY
WASHINGTON, DC 20306-6000

PATIENT IDENTIFICATION
AFIP Accessions Number Sequence
(b)(6)
Name
GHAFAR, HUSHAM N. (b)(6)
SSAN: Autopsy: (b)(6)
Toxicology Accession #: (b)(6)
Date Report Generated: September 27, 2004

CONSULTATION REPORT ON CONTRIBUTOR MATERIAL

AFIP DIAGNOSIS **REPORT OF TOXICOLOGICAL EXAMINATION**

Condition of Specimens: GOOD
Date of Incident: (b)(6) 2004 **Date Received:** 9/7/2004

VOLATILES: The **BLOOD AND BILE** were examined for the presence of ethanol at a cutoff of 20 mg/dL. No ethanol was detected.

DRUGS: The **BLOOD** was screened for acetaminophen, amphetamine, antidepressants, antihistamines, barbiturates, benzodiazepines, cannabinoids, chloroquine, cocaine, dextromethorphan, lidocaine, narcotic analgesics, opiates, phencyclidine, phenothiazines, salicylates, sympathomimetic amines and verapamil by gas chromatography, color test or immunoassay. The following drugs were detected:

Positive Opiate: Morphine was detected in the blood by immunoassay and confirmed by gas chromatography/mass spectrometry. The blood contained 0.23 mg/L of morphine as quantitated by gas chromatography/mass spectrometry.

(b)(6)
Office of the Armed Forces Medical Examiner

(b)(6)
Office of the Armed Forces Medical Examiner

ACLU Detainee DeathII ARMY MEDCOM 138

ARMED FORCES INSTITUTE OF PATHOLOGY
Office of the Armed Forces Medical Examiner
1413 Research Blvd., Bldg. 102
Rockville, MD 20850
1-800-944-7912

FINAL AUTOPSY REPORT

Name: Najem. Fawaz Badaa
National Detainee Reporting System: (b)(6)
Date of Birth: (b)(6) 1962
Date of Death: (b)(6) 2004
Date of Autopsy: 19 June 2004
Date of Report: 13 October 2004

Autopsy No.: (b)(6)
AFIP No.: (b)(6)
Rank: Iraqi civilian
Place of Death: Abu Ghraib, Iraq
Place of Autopsy: Baghdad, Iraq

Circumstances of Death: This 42 year-old male Iraqi civilian was in US custody at the Baghdad Central Confinement Facility in Abu Ghruyeb, Iraq. By report, he began making gasping sounds, which awoke another detainee. The decedent was found to be unresponsive and pulseless, and resuscitation efforts were unsuccessful.

Authorization for Autopsy: The Armed Forces Medical Examiner, IAW 10 USC 1471.

Identification: Visual and documentation accompanying the body; fingerprints and DNA sample obtained

CAUSE OF DEATH: Undetermined

MANNER OF DEATH: Undetermined

ACLU Detainee DeathII ARMY MEDCOM 139

FINAL AUTOPSY DIAGNOSES:

I. No evidence of any definitive significant trauma
   a. Minor contusions of abdomen and left arm

II. Cardiovascular Findings (AFIP Cardiovascular Pathology consultation)
   a. Mild coronary atherosclerosis
      i. 40% luminal narrowing of proximal left anterior descending coronary artery
      ii. 20% luminal narrowing of proximal left circumflex coronary artery
      iii. 30% luminal narrowing of proximal right coronary artery by intimal thickening
   b. Moderate dysplasia of atrioventricular nodal artery
      i. No increased fibrosis of septum

III. Additional Findings; probable artifacts of resuscitation or freezing of body
   a. Film of peritoneal blood of upper abdomen, < 50 ml
   b. Hepatic findings
      i. Subcapsular accumulation of blood over right lobe of liver; capsule grossly intact
      ii. Parenchymal clefts and focal disruption of right lobe of liver
         1. Histologically, no inflammatory response, fibrin or clot formation, or other evidence of any vital reaction

IV. Medical Intervention
   a. Endotracheal tube in place
   b. Intravenous catheter in left antecubital fossa
   c. One adhesive EKG tab on abdomen

V. Early to moderate decomposition
   a. Marbling of torso, arms and legs
   b. Marked facial and scalp congestion and dark discoloration
   c. Corneal opacification

VI. Toxicology (AFIP)
   a. Volatiles: Heart blood and urine negative for ethanol
   b. Cyanide: Heart blood negative
   c. Drugs: Heart blood negative for screened medications and drugs of abuse

ACLU Detainee DeathII ARMY MEDCOM 140

EXTERNAL EXAMINATION

The body is that of a well developed, well-nourished male clad in a pair of yellow "Reebok" shorts, a pair of grey drawstring pants, and a previously cut, white t-shirt. The body weighs approximately 150 pounds, is 67" in height and appears compatible with the reported age of 42 years. The body is cold, the temperature that of the refrigeration unit. Rigor is waning. Lividity is present and fixed on the posterior surface of the body, except in areas exposed to pressure, and over the face and head.

Early to moderate decompositonal changes are present, consisting of diffuse marbling of the back, upper arms and legs; early marbling of the sides of the abdomen; partial corneal opacification; and dark discoloration and congestion of the face, scalp and neck.

The scalp is covered with black hair with frontal and parietal alopecia but otherwise in a normal distribution, averaging 3 cm in length. Facial hair consists of a dark mustache and full beard. The irides appear dark, but are partially obscured by corneal clouding. The sclerae and conjunctivae are congested, especially of the left eye, but there are no petechiae. The earlobes are not pierced. The external auditory canals, external nares and oral cavity are free of foreign material and abnormal secretions. The nasal skeleton is palpably intact. The lips are without evident injury. The teeth are natural and in good condition.

Examination of the neck reveals the trachea to be midline and mobile. The chest is symmetric and well developed. No injury of the ribs or sternum is evident externally. The abdomen is slightly protuberant and soft. There is a 2 x 1 cm dark macule on the mid right side of the back.

The extremities are well developed with normal range of motion. There is a 2 x 1 cm hyperpigmented patch on the back of the right wrist. There are thick calluses on lateral aspect of the right ankle and on the soles of the feet, which are also dirt stained. The fingernails are short and intact. No tattoos are noted. The external genitalia are those of a normal adult circumcised male. The testes are descended and free of masses. Pubic hair is partially shaved but present in a normal distribution. The buttocks and anus are unremarkable.

There is an identification band with the name and photograph of the decedent around the left wrist, and there is an identification tag with the name of the decedent and date of death on the first toe of the left foot. There are creases around the lateral aspects of the ankles consistent with postmortem securing of the body.

EVIDENCE OF THERAPY

There is an endotracheal tube in place secured with white tape around the head, and there is an adhesive EKG tab on the lower right side of the abdomen. There is a needle puncture mark with surrounding ecchymosis in the right antecubital fossa, and there is an intravenous catheter secured with white tape in the left antecubital fossa.

ACLU Detainee DeathII ARMY MEDCOM 141

EVIDENCE OF INJURY

There is a 2 x 0.3 cm red contusion just above the umbilicus, and there is a 3.5 x 2.5 cm red contusion of the lower right aspect of the abdomen. On the anterior (palmar) aspect of the left lower forearm and wrist, there is a 4 x 3 cm red brown contusion, and there is a 3 x 2 cm contusion of the left thenar region.

On external examination of the body, there is no other evidence of trauma.

INTERNAL EXAMINATION

BODY CAVITIES:
The body is opened by the usual thoraco-abdominal incision, and the chest plate is removed. No adhesions or abnormal collections of fluid are present in the pleural or pericardial cavities. There is a film of blood in the upper peritoneal cavity, less than 50 ml. No adhesions or abnormal collections of fluid are present in the peritoneal cavity. All body organs are present in the normal anatomical position. The subcutaneous fat layer of the abdominal wall is 2 cm thick. There is no internal evidence of blunt force or penetrating injury to the thoraco-abdominal region.

HEAD: (CENTRAL NERVOUS SYSTEM)
The scalp is reflected, and there is marked subgaleal congestion and fixed lividity, but no subgaleal hemorrhage or skull fractures found. The calvarium of the skull is removed. The dura mater and falx cerebri are intact. There is no epidural or subdural hemorrhage present. The leptomeninges are thin and delicate. The cerebrospinal fluid is dark with decompositional change, most prominent over the occiput; however, there is no evidence of any subarachnoid hemorrhage. The cerebral hemispheres are symmetrical. The structures at the base of the brain, including cranial nerves and blood vessels, are intact. Coronal sections through the cerebral hemispheres revealed no lesions, and there is no evidence of infection, tumor, or trauma. Transverse sections through the brain stem and cerebellum are unremarkable. The dura is stripped from the basilar skull, and no fractures are found. The atlanto-occipital joint is stable. The brain weighs 1455 grams.

NECK:
Examination of the soft tissues of the neck, including strap muscles, thyroid gland and large vessels, reveals no abnormalities. The anterior strap muscles of the neck are homogeneous and red-brown, without hemorrhage. The thyroid cartilage and hyoid bone are intact. The larynx is lined by intact white mucosa and is unobstructed. The thyroid gland is symmetric and red-brown, without cystic or nodular change. There is no evidence of infection, tumor, or trauma, and the airway is patent. Incision and dissection of the posterior neck demonstrates no deep paracervical muscular injury, hemorrhage, or fractures of the dorsal spinous processes.

ACLU Detainee DeathII ARMY MEDCOM 142

CARDIOVASCULAR SYSTEM:
See "Cardiovascular Pathology Report" below. The pericardial surfaces are smooth, glistening and unremarkable; the pericardial sac is free of significant fluid and adhesions. A moderate amount of epicardial fat is present. The coronary arteries arise normally in a right dominant pattern and follow the usual distribution. There is mild atherosclerosis with focal areas of luminal stenosis of the coronary arteries, without evidence of thrombosis. The myocardium is dark red-brown, firm and unremarkable; the atrial and ventricular septa are intact. The left ventricle is 1.5 cm in thickness and the right ventricle is 0.4 cm in thickness. The aorta and its major branches arise normally, follow the usual course and are widely patent, free of significant atherosclerosis and other abnormality. The venae cavae and their major tributaries return to the heart in the usual distribution and are free of thrombi. The heart weighs 435 grams.

RESPIRATORY SYSTEM:
The upper airway is clear of debris and foreign material; the mucosal surfaces are smooth, yellow-tan and unremarkable. The pleural surfaces are smooth, glistening and unremarkable bilaterally. The pulmonary parenchyma is red-purple and edematous, exuding a moderate amount of bloody fluid; no focal lesions are noted. The pulmonary arteries are normally developed, patent and without thrombus or embolus. The right lung weighs 605 grams; the left 480 grams.

LIVER & BILIARY SYSTEM:
The hepatic capsule is smooth, glistening and intact, covering dark red-brown, moderately congested parenchyma. There is focal accumulation of subcapsular blood and underlying parenchymal disruption, with clefts and splitting of the parenchyma without associated hemorrhage, consistent with resuscitation or postmortem changes. The gallbladder contains 5 ml of green-brown, mucoid bile; the mucosa is velvety and unremarkable. The extrahepatic biliary tree is patent, without evidence of calculi. The liver weighs 1940 grams.

ALIMENTARY TRACT:
The tongue exhibits no evidence of recent injury. The esophagus is lined by gray-white, smooth mucosa. The gastric mucosa is arranged in the usual rugal folds and the lumen contains a film of dark fluid. The small and large bowel are unremarkable. The pancreas has a normal pink-tan lobulated appearance and the ducts are clear. The appendix is present and is unremarkable.

GENITOURINARY SYSTEM:
The renal capsules are smooth and thin, semi-transparent and strip with ease from the underlying smooth, red-brown cortical surfaces. The cortices are sharply delineated from the medullary pyramids, which are red-purple to tan and unremarkable. There is a single dark calculus in the right renal pelvis. The calyces, pelves and ureters are otherwise unremarkable. White bladder mucosa overlies an intact bladder wall. The urinary bladder contains 20 ml of cloudy, yellow urine. The prostate gland is symmetrical with lobular, yellow-tan parenchyma and no nodules or masses. The seminal vesicles are unremarkable. The testes are free of mass lesions, contusions, or other abnormalities. The right kidney weighs 210 grams; the left 220 grams.

ACLU Detainee DeathII ARMY MEDCOM 143

RETICULOENDOTHELIAL SYSTEM:
The spleen has a smooth, intact capsule covering red-purple, moderately firm parenchyma; the lymphoid follicles are unremarkable. The regional lymph nodes appear normal. The spleen weighs 260 grams.

ENDOCRINE SYSTEM:
The pituitary, thyroid and adrenal glands are unremarkable.

MUSCULOSKELETAL SYSTEM:
Muscle development is normal. No bone or joint abnormalities are noted.

MICROSCOPIC EXAMINATION

HEART: See "Cardiovascular Pathology Report" below.

BRAIN: See "Neuropathology Report" below.

LUNGS: The alveolar spaces and small air passages are expanded and contain no significant inflammatory component or edema fluid. The alveolar walls are thin and mildly congested. The arterial and venous vascular systems are normal. The peribronchial lymphatics are unremarkable.

LIVER: There are numerous clefts and splits of the parenchyma, focally with lakes of red blood cells. However, there is no inflammatory response or evidence of organization of the hemorrhage, with no fibrin or clot formation. The hepatic architecture is otherwise intact. The portal areas show no increased inflammatory component or fibrous tissue. The hepatic parenchymal cells are well-preserved with mild focal steatosis but no evidence of cholestasis, or sinusoidal abnormalities.

SPLEEN: The capsule and white pulp are unremarkable. There is moderate congestion of the red pulp.

ADRENALS: The cortical zones are distinctive and well supplied with lipoid. The medullae are not remarkable.

KIDNEYS: The subcapsular zones are unremarkable. The glomeruli are mildly congested without cellular proliferation, mesangial prominence, or sclerosis. The tubules are well preserved. There is no interstitial fibrosis or significant inflammation. There is no thickening of the walls of the arterioles or small arterial channels. The transitional epithelium of the collecting system is normal.

TESTES: Unremarkable

THYROID GLAND: Unremarkable

ACLU Detainee DeathII ARMY MEDCOM 144

CARDIOVASCULAR PATHOLOGY REPORT

Department of Cardiovascular Pathology, AFIP:

"**AFIP DIAGNOSIS:** (b)(6)

1. **Moderate dysplasia of atrioventricular nodal artery**
2. **Mild coronary artery atherosclerosis**

History: 42 year old male Iraqi detainee, 67", 150 lbs, death in custody
Heart: 435 grams (predicted normal value 322 grams, upper limit 425 grams for a 150 lbs male); normal epicardial fat; closed foramen ovale; left ventricular hypertrophy: left ventricular cavity diameter 35 mm, left ventricular free wall thickness 15 mm, ventricular septum thickness 15 mm; right ventricle thickness 4 mm, without gross scars or abnormal fat infiltrates; grossly unremarkable valves and endocardium; enlarged membranous septum; no gross myocardial fibrosis or necrosis; histologic sections show mild left ventricular myocyte hypertrophy, otherwise unremarkable
Coronary arteries: Normal ostia; right dominance; mild atherosclerosis: 40% luminal narrowing of proximal left anterior descending, 20% narrowing of proximal left circumflex, and 30% narrowing of proximal right coronary artery by pathologic intimal thickening
Conduction System: The sinoatrial node is unremarkable. The sinus nodal artery shows minimally increased proteoglycan. The atrioventricular (AV) nodal artery shows moderate dysplasia in its posterior approaches to the compact AV node and in its penetrating branches in the ventricular septum, but fibrosis is not significantly increased in the septum. The penetrating bundle is centrally located between the node and ventricular septum. The right proximal bundle branch is unremarkable. The left proximal bundle is not seen in these sections.
Comment: We do not see an obvious cardiac cause of death. Moderate dysplasia of the atrioventricular nodal artery is often associated with increased fibrosis in the crest of the ventricular septum, representing a potential substrate for cardiac arrhythmia. However, increased fibrosis is not seen in this case. We cannot exclude the possibility of cardiac arrhythmia related to various ion channelopathies or coronary vasospasm."

NEUROPATHOLOGY REPORT

Department of Neuropathology and Ophthalmic Pathology, AFIP:

"We reviewed multiple small fragments of dura, cerebrum, brainstem and cerebellum submitted in formalin in reference to this case. No gross abnormalities are present. Representative sections were processed in paraffin and sections stained with H&E, and immunohistochemical methods for beta amyloid precursor protein (BAPP), and glial fibrillary acidic protein (GFAP). This material was reviewed in conference by the staff of Neuropathology. Sections show few neurons within the cerebral cortex with shrunken or vacuolated cytoplasm and hyperchromatic nuclei, findings interpreted as non-specific acute neuronal injury. Stains for BAPP and GFAP are negative."

ACLU Detainee DeathII ARMY MEDCOM 145

ADDITIONAL PROCEDURES

- Documentary photographs are taken by OAFME photographers
- Specimens retained for toxicologic testing and/or DNA identification are: vitreous fluid, heart blood, urine, and bile
- The dissected organs are forwarded with the body
- Personal effects are released to the appropriate mortuary operations representative

OPINION

Based on available investigation and complete autopsy examination, no definitive cause of death for this 42 year-old male Iraqi civilian in US custody in Iraq could be determined. There is no evidence of any significant trauma to explain the death. There is a film of blood in the upper abdomen, and a small accumulation of subcapsular blood over the right lobe of the liver with associated subcapsular parenchymal disruption. However, the minimal amount of hemorrhage, lack of capsular laceration, and microscopic lack of vital reaction indicates this is likely a post-mortem artifact, either from resuscitation efforts or freezing of the body. There are non-specific cardiac findings, including moderate dysplasia of the atrioventricular nodal artery. However, there is no associated increased septal fibrosis, which can be a potential substrate for cardiac arrhythmia. There is also mild coronary artery atherosclerosis, but no luminal narrowing greater than 40% was found. A cardiac arrhythmia related to various ion channelopathies or coronary vasospasm cannot be excluded.

Therefore, the cause of death is best classified as undetermined, and the manner of death is undetermined.

(b)(6)

(b)(6) Medical Examiner

ACLU Detainee DeathII ARMY MEDCOM 146

DEPARTMENT OF DEFENSE
ARMED FORCES INSTITUTE OF PATHOLOGY
WASHINGTON, DC 20306-6000

REPLY TO ATTENTION OF

AFIP-(b)(6)

TO:

OFFICE OF THE ARMED FORCES MEDICAL EXAMINER
ARMED FORCES INSTITUTE OF PATHOLOGY
WASHINGTON, DC 20306-6000

PATIENT IDENTIFICATION
AFIP Accessions Number Sequence
(b)(6)

Name
NAJEM, FAWAZ B.

SSAN: **Autopsy:** (b)(6)
Toxicology Accession #: (b)(6)
Date Report Generated: June 30, 2004

CONSULTATION REPORT ON CONTRIBUTOR MATERIAL

AFIP DIAGNOSIS **REPORT OF TOXICOLOGICAL EXAMINATION**

Condition of Specimens: GOOD
Date of Incident: **Date Received:** 6/22/2004

VOLATILES: The **HEART BLOOD AND URINE** were examined for the presence of ethanol at a cutoff of 20 mg/dL. No ethanol was detected.

CYANIDE: There was no cyanide detected in the heart blood. The limit of quantitation for cyanide is 0.25 mg/L. Normal blood cyanide concentrations are less than 0.15 mg/L. Lethal concentrations of cyanide are greater than 3 mg/L.

DRUGS: The **BLOOD** was screened for amphetamine, antidepressants, antihistamines, barbiturates, benzodiazepines, cannabinoids, cocaine, dextromethorphan, lidocaine, narcotic analgesics, opiates, phencyclidine, phenothiazines, sympathomimetic amines and verapamil by gas chromatography, color test or immunoassay. The following drugs were detected:

None were found.

(b)(6)
Office of the Armed Forces Medical Examiner

(b)(6)
Office of the Armed Forces Medical Examiner

ACLU Detainee DeathII ARMY MEDCOM 147

ARMED FORCES INSTITUTE OF PATHOLOGY
Office of the Armed Forces Medical Examiner
1413 Research Blvd., Bldg. 102
Rockville, MD 20850
1-800-944-7912

FINAL AUTOPSY REPORT

Name: Abd Al Razak, Riadh Mohammed
National Detainee Reporting Systen (b)(6)
Date of Birth: (b)(6) 1952
Date of Death: (b)(6) 2004
Date of Autopsy: 19 June 2004
Date of Report: 22 September 2004

Autopsy No.: (b)(6)
AFIP No.: (b)(6)
Rank: Iraqi civilian
Place of Death: Abu Ghraib, Iraq
Place of Autopsy: Baghdad, Iraq

Circumstances of Death: This 52 year-old male Iraqi civilian collapsed while speaking to other detainees while in US custody at the Baghdad Central Confinement Facility in Abu Ghruyeb, Iraq, and resuscitative efforts were unsuccessful.

Authorization for Autopsy: The Armed Forces Medical Examiner, IAW 10 USC 1471.

Identification: Visual and documentation accompanying the body; fingerprints and DNA sample obtained

CAUSE OF DEATH: Atherosclerotic Cardiovascular Disease

MANNER OF DEATH: Natural

ACLU Detainee DeathII ARMY MEDCOM 148

FINAL AUTOPSY DIAGNOSES:

I. Atherosclerotic Cardiovascular Disease
   a. Severe coronary atherosclerosis with calcification
      i. Left main coronary artery, 50% luminal narrowing by fibrocalcific plaque
      ii. Total occlusion of proximal left anterior descending artery (LAD) with healed plaque rupture and organized thrombus; 75% narrowing of mid LAD by fibroatheroma; 65% narrowing of distal LAD by fibrocalcific plaque; total occlusion of ramus intermedius by healed rupture with fibrointimal thickening and smooth muscle proliferation
      iii. Total occlusion of proximal to mid left circumflex artery (LCA) by organized and recanalized thrombus; 70% fibrocalcific narrowing of distal LCA; 90% narrowing of obtuse marginal artery with fibrointimal thickening and smooth muscle proliferation
      iv. Right coronary artery (RCA), 25% narrowing of proximal RCA by fibrocalcific plaque; 40% narrowing of mid RCA by fibroatheroma; 70% fibrocalcific narrowing of distal RCA; 95% narrowing of posterior descending artery by fibroclcific plaque and smooth muscle proliferation
   b. Healed transmural myocardial infarction
      i. Involves anterior, septal and lateral left ventricle mid ventricle to apex
      ii. Microscopically, transmural fibrosis and fat replacement in anterior, septal and lateral walls of left ventricle
      iii. Aneurysmal dilatation
      iv. Epicardial fibrous adhesions at apex of left ventricle
   c. Cardiomegaly with biventricular hypertrophy
      i. Heart 666 gm (predicted normal value 343 gm)
      ii. Left ventricular cavity diameter 60 mm
      iii. Left ventricular free wall thickness 10 mm
      iv. Microscopically, biventricular myocyte hypertrophy with subendocaridal and perivascular interstitial fibrosis
   d. Moderate to severe atherosclerosis of the aorta
      i. Diffuse calcific intimal plaque formation
      ii. Focal plaque rupture with associated hemorrhage
   e. Pulmonary edema
      i. Right lung 965 grams
      ii. Left lung 818 grams

II. No evidence of any significant trauma
   a. Abrasion, 4 x 3 cm on back of right forearm
   b. Contusion, 7 x 4 cm on back of right hand

ACLU Detainee DeathII ARMY MEDCOM 149

III. Additional Findings
   a. Subcutaneous lipoma of anterior left side of neck
   b. Right renal calculus (kidney stone)
   c. Prostatic hypertrophy
   d. Symmetrically enlarged thyroid gland

IV. Medical Intervention
   a. Endotracheal tube in place
   b. Three adhesive EKG tabs on body

V. Early to moderate decomposition
   a. Diffuse marbling of body
   b. Corneal opacification

VI. Toxicology (AFIP)
   a. Volatiles: Heart blood and urine negative for ethanol
   b. Cyanide: Heart blood negative
   c. Drugs: Heart blood negative for screened medications and drugs of abuse

ACLU Detainee DeathII ARMY MEDCOM 150

EXTERNAL EXAMINATION

The body is that of a well developed, well-nourished male clad in a previously cut, white long sleeve shirt-dress ("dish dash") and white boxer shorts. The body weighs approximately 170 pounds, is 71" in height and appears compatible with the reported age of 52 years. The body is cold, the temperature that of the refrigeration unit. Rigor is waning. Lividity is present and fixed on the posterior surface of the body, except in areas exposed to pressure, and is especially pronounced on the face.

Early to moderate decompositonal changes are present, consisting of diffuse marbling and discoloration of the body and corneal opacification.

The scalp is covered with black and grey hair in a normal distribution, averaging 4 cm in length. Facial hair consists of a dark mustache and grey facial stubble. The irides appear dark, but are partially obscured by corneal clouding. The sclerae and conjunctivae are congested, especially on the left, with no petechiae. The earlobes are not pierced. The external auditory canals, external nares and oral cavity are free of foreign material and abnormal secretions. The nasal skeleton is palpably intact. The lips are without evident injury. The teeth are natural and in good condition.

Examination of the neck reveals the trachea to be midline and mobile. There is a palpable 3 x 2 cm subcutaneous nodule on the anterior left side of the neck. The chest is symmetric and well developed. No injury of the ribs or sternum is evident externally. The abdomen is slightly protuberant and soft. The extremities are well developed with normal range of motion. There is a 4 x 1.5 cm scar on the upper anterior aspect of the right forearm, and there are irregular scars over the left knee. The fingernails are short and intact. No tattoos are noted, and needle tracks are not observed. The external genitalia are those of a normal adult circumcised male. The testes are descended and free of masses. Pubic hair is present in a normal distribution. The buttocks and anus are unremarkable. There is an identification tag on the first toe of the left foot.

EVIDENCE OF THERAPY

There is an endotracheal tube in place secured with white tape around the head, and there are three adhesive EKG tabs on the body, two on the upper chest and one on the left thigh. There is a band-aid on the right antecubital fossa over a needle puncture mark with surrounding ecchymosis.

EVIDENCE OF INJURY

There is a 4 x 3 cm abrasion on the back of the right forearm and there is a 7 x 4 cm contusion on the back of the right hand. On external and internal examination of the body, there is no other evidence of trauma.

ACLU Detainee DeathII ARMY MEDCOM 151

INTERNAL EXAMINATION

BODY CAVITIES:
The body is opened by the usual thoraco-abdominal incision, and the chest plate is removed. There is approximately 50 ml of serosanguinous fluid in each pleural space, and there are multiple pleural adhesions of the right chest cavity. No adhesions or abnormal collections of fluid are present in the peritoneal cavity. All body organs are present in the normal anatomical position. The subcutaneous fat layer of the abdominal wall is 4 cm thick. There is no internal evidence of blunt force or penetrating injury to the thoraco-abdominal region.

HEAD: (CENTRAL NERVOUS SYSTEM)
The scalp is reflected, and there is no subgaleal hemorrhage or skull fractures found. The calvarium of the skull is removed. The dura mater and falx cerebri are intact. There is no epidural or subdural hemorrhage present. The leptomeninges are thin and delicate. The cerebrospinal fluid is dark with decompositional change, most prominent over the occiput; however, there is no evidence of any subarachnoid hemorrhage. The cerebral hemispheres are symmetrical. The structures at the base of the brain, including cranial nerves and blood vessels, are intact. Coronal sections through the cerebral hemispheres revealed no lesions, and there is no evidence of infection, tumor, or trauma. Transverse sections through the brain stem and cerebellum are unremarkable. The dura is stripped from the basilar skull, and no fractures are found. The atlanto-occipital joint is stable. The brain weighs 1180 grams.

NECK:
On dissection of the soft tissue of the neck, there is a well-circumscribed yellow 3 x 2 cm nodule just under the skin on the anterior left side of the neck, adjacent to the thyroid cartilage. On sectioning, the nodule is uniformly fatty, consistent with a lipoma. Examination of the soft tissues of the neck, including strap muscles, thyroid gland and large vessels, otherwise reveals no abnormalities. The anterior strap muscles of the neck are homogeneous and red-brown, without hemorrhage. The thyroid cartilage and hyoid bone are intact. The larynx is lined by intact white mucosa and is unobstructed. The thyroid gland is large but symmetric and red-brown, without cystic or nodular change. There is no evidence of infection, tumor, or trauma, and the airway is patent. Incision and dissection of the posterior neck demonstrates no deep paracervical muscular injury, hemorrhage, or fractures of the dorsal spinous processes.

CARDIOVASCULAR SYSTEM:
There are dense apical adhesions of the heart to the pericardial sac, and there is marked aneurysmal dilatation of the left ventricle. See "Cardiovascular Pathology Report" below. A moderate amount of epicardial fat is present, and the heart weighs 666 grams. The aorta and its major branches arise normally and follow the usual course. There is diffuse moderate to severe atherosclerosis of the aorta with extensive calcific intimal plaque formation and focal plaque rupture with associated hemorrhage. The venae cavae and their major tributaries return to the heart in the usual distribution and are free of thrombi.

ACLU Detainee DeathII ARMY MEDCOM 152

RESPIRATORY SYSTEM:
The upper airway is clear of debris and foreign material; the mucosal surfaces are smooth, yellow-tan and unremarkable. There are scattered pleural adhesions of the right chest cavity. The pleural surfaces are otherwise smooth, glistening and unremarkable bilaterally. The pulmonary parenchyma is red-purple and edematous, exuding a moderate amount of bloody fluid; no focal lesions are noted. The pulmonary arteries are normally developed, patent and without thrombus or embolus. The right lung weighs 965 grams; the left 818 grams.

LIVER & BILIARY SYSTEM:
The hepatic capsule is smooth, glistening and intact, covering dark red-brown, moderately congested parenchyma with no focal lesions noted. The gallbladder contains 5 ml of green-brown, mucoid bile; the mucosa is velvety and unremarkable. The extrahepatic biliary tree is patent, without evidence of calculi. The liver weighs 1498 grams.

ALIMENTARY TRACT:
The tongue exhibits no evidence of recent injury. The esophagus is lined by gray-white, smooth mucosa. The gastric mucosa is arranged in the usual rugal folds and the lumen contains 100 ml of dark fluid. The small and large bowel are unremarkable. The pancreas has a normal pink-tan lobulated appearance and the ducts are clear. The appendix is present and is unremarkable.

GENITOURINARY SYSTEM:
The renal capsules are smooth and thin, semi-transparent and strip with ease from the underlying smooth, red-brown cortical surfaces. The cortices are sharply delineated from the medullary pyramids, which are red-purple to tan and unremarkable. There is a single dark calculus in the right renal pelvis. The calyces, pelves and ureters are otherwise unremarkable. White bladder mucosa overlies an intact bladder wall. The urinary bladder contains 50 ml of cloudy, yellow urine. The prostate gland is enlarged but symmetrical with lobular, yellow-tan parenchyma and no nodules or masses. The seminal vesicles are unremarkable. The testes are free of mass lesions, contusions, or other abnormalities. The right kidney weighs 207 grams; the left 235 grams.

RETICULOENDOTHELIAL SYSTEM:
The spleen has a smooth, intact capsule covering red-purple, moderately firm parenchyma; the lymphoid follicles are unremarkable. The regional lymph nodes appear normal. The spleen weighs 278 grams.

ENDOCRINE SYSTEM:
The pituitary and adrenal glands are unremarkable. The thyroid gland is symmetrically enlarged, but free of nodules or masses.

MUSCULOSKELETAL SYSTEM:
Muscle development is normal. No bone or joint abnormalities are noted.

ACLU Detainee DeathII ARMY MEDCOM 153

MICROSCOPIC EXAMINATION

Heart: See "Cardiovascular Pathology Report" below.

Selected portions of other organs are retained in formalin, without preparation of histologic slides.

CARDIOVASCULAR PATHOLOGY REPORT

Department of Cardiovascular Pathology, AFIP:

"AFIP DIAGNOSIS: (b)(6)

1. **Severe coronary atherosclerosis with calcification, three vessel disease**
2. **Healed transmural infarction with aneurysmal dilatation, anterior, septal, and lateral left ventricle**
3. **Cardiomegaly with biventricular hypertrophy**

History: 52 year old male Iraqi detainee, 5'11", 170 lbs, found dead in bed
Heart: 666 grams (predicted normal value 343 grams, upper limit 453 grams for a 170 lbs male); focal epicardial fibrous adhesions at apex of left ventricle; closed foramen ovale; aneurysmal dilatation of left ventricle: left ventricular cavity diameter 60 mm, left ventricular free wall thickness 10 mm, ventricular septum thickness 10 mm; right ventricle thickness 4 mm; endocardial thickening in left atrium and left ventricle; unremarkable valves; healed transmural infarct, anterior and septal walls of left ventricle, mid ventricle to apex; subendocardial hyperemia, anterior and lateral walls of left ventricle; histologic sections show biventricular myocyte hypertrophy with subendocardial and perivascular interstitial fibrosis; transmural fibrosis and fat replacement in anterior, septal, and lateral walls of left ventricle.
Coronary arteries: Normal ostia; right dominance; severe calcific atherosclerois:

Left main coronary artery: 50% luminal narrowing by fibrocalcific plaque
Left anterior descending artery (LAD): Total occlusion of proximal LAD with healed plaque rupture and organized thrombus; 75% narrowing of mid LAD by thin capped fibroatheroma and 65% narrowing of distal LAD by fibrocalcific plaque; total occlusion of ramus intermedius by healed rupture with fibrointimal thickening and smooth muscle proliferation
Left circumflex artery (LCA): Total occlusion of proximal to mid LCA by organized and recanalized thrombus, 70% fibrocalcific narrowing of distal LCA; 90% narrowing of obtuse marginal artery with fibrointimal thickening and smooth muscle proliferation
Right coronary artery (RCA): 25% narrowing of proximal RCA by fibrocalcific plaque, 40% narrowing of mid RCA by thin capped fibroatheroma, and 70% fibrocalcific narrowing of distal RCA; 95% narrowing of posterior descending artery by fibrocalcific plaque and smooth muscle proliferation."

ACLU Detainee DeathII ARMY MEDCOM 154

ADDITIONAL PROCEDURES

- Full body radiographs are obtained and show no evidence of trauma.
- Documentary photographs are taken by OAFME photographers
- Specimens retained for toxicologic testing and/or DNA identification are: vitreous fluid, heart blood, urine, and bile
- The dissected organs are forwarded with the body
- Personal effects are released to the appropriate mortuary operations representative

OPINION

This 52 year-old male Iraqi civilian in US custody in Iraq died of atherosclerotic cardiovascular disease, with severe coronary artery disease and a healed myocardial infarction (previous heart attack), extensively involving the left ventricle. There is no evidence of any significant trauma.

The manner of death is natural.

(b)(6)

(b)(6) Medical Examiner

ACLU Detainee DeathII ARMY MEDCOM 155

DEPARTMENT OF DEFENSE
ARMED FORCES INSTITUTE OF PATHOLOGY
WASHINGTON, DC 20306-6000

REPLY TO ATTENTION OF

AFIP-(b)(6)

TO:

OFFICE OF THE ARMED FORCES MEDICAL EXAMINER
ARMED FORCES INSTITUTE OF PATHOLOGY
WASHINGTON, DC 20306-6000

PATIENT IDENTIFICATION
AFIP Accessions Number Sequence
(b)(6)
Name
ABD AL RAZAK, RIADH M.

SSAN: **Autopsy:** (b)(6)
Toxicology Accession #: (b)(6)
Date Report Generated: June 30, 2004

CONSULTATION REPORT ON CONTRIBUTOR MATERIAL

AFIP DIAGNOSIS **REPORT OF TOXICOLOGICAL EXAMINATION**

Condition of Specimens: GOOD
Date of Incident (b)(6) 2004 **Date Received:** 6/22/2004

VOLATILES: The **HEART BLOOD AND URINE** were examined for the presence of ethanol at a cutoff of 20 mg/dL. No ethanol was detected.

CYANIDE: There was no cyanide detected in the heart blood. The limit of quantitation for cyanide is 0.25 mg/L. Normal blood cyanide concentrations are less than 0.15 mg/L. Lethal concentrations of cyanide are greater than 3 mg/L.

DRUGS: The **HEART BLOOD** was screened for amphetamine, antidepressants, antihistamines, barbiturates, benzodiazepines, cannabinoids, cocaine, dextromethorphan, lidocaine, narcotic analgesics, opiates, phencyclidine, phenothiazines, sympathomimetic amines and verapamil by gas chromatography, color test or immunoassay. The following drugs were detected:

None were found.

(b)(6)
Office of the Armed Forces Medical Examiner

(b)(6)
Office of the Armed Forces Medical Examiner

ACLU Detainee DeathII ARMY MEDCOM 156

ARMED FORCES INSTITUTE OF PATHOLOGY
Office of the Armed Forces Medical Examiner
1413 Research Blvd., Bldg. 102
Rockville, MD 20850
1-800-944-7912

AUTOPSY EXAMINATION REPORT

Name: BTB Altia, Abdul K.
Prisoner #(b)(6)
Date of Birth: BTB 1940
Date of Death: BTB (b)(6) 2004
Date of Autopsy: 1 June 2004
Date of Report: 29 Jun 2004

Autopsy No.: (b)(6)
AFIP No.: (b)(6)
Rank: CIV
Place of Death: Abu Ghraib Prison
Place of Autopsy: BIAP Morgue

Circumstances of Death: This male died while in US custody in Abu Ghraib prison. By report he complained of chest pain to his son and then collapsed.

Authorization for Autopsy: Office of the Armed Forces Medical Examiner, IAW 10 USC 1471

Identification: By CID, DNA sample obtained

CAUSE OF DEATH: Atherosclerotic cardiovascular disease (ASCVD)

MANNER OF DEATH: Natural

FINAL AUTOPSY DIAGNOSES:

I. Atherosclerotic cardiovascular disease
   A. Left anterior descending coronary artery with multifocal stenoses ranging from 50-80%
   B. Right coronary artery with multifocal stenoses ranging from 50-85%
   C. Left circumflex coronary artery with focal 50% stenosis
   D. Moderate to severe atherosclerosis of the distal aorta
   E. Thickening of the mitral valve leaflets
   F. Pulmonary congestion (right 800 grams, left 650 grams)
   G. Prominent facial suffusion
   H. Bilateral earlobe creases (Frank's sign)

II. Pleural adhesions
III. Status post appendectomy, remote
IV. Fractures of the anterior ribs (right #5, left #3-7) consistent with cardiopulmonary resuscitation
V. No significant trauma
VI. Toxicology negative

ACLU Detainee DeathII ARMY MEDCOM 158

EXTERNAL EXAMINATION

The body is that of a thin male appearing greater than 50 years of age and measuring 69 inches in length and weighing approximately 160 pounds. Lividity is posterior, purple, and fixed. Rigor is passing.

The scalp is covered with gray hair in a normal distribution. There is a gray mustache and beard. Corneal clouding obscures the irides and pupils. The external auditory canals are unremarkable. The ears are significant for bilateral creases of the earlobes (Frank's sign). There is prominent facial suffusion. The nares are patent and the lips are atraumatic. The nose and maxillae are palpably stable. The teeth appear natural with partial upper plates.

The neck is straight, and the trachea is midline and mobile. The chest is symmetric. The abdomen is flat. The genitalia are those of a normal adult male. The testes are descended and free of masses. Pubic hair is present in a normal distribution. The buttocks and anus are unremarkable.

The upper and lower extremities are symmetric and without clubbing or edema.

Identifying marks and scars include a 3 ½ inch oblique scar on the right lower quadrant of the abdomen. On the posterior right arm and forearm is a 6 x 3 ½ inch area of depigmentation of the skin and scar. On the midline of the lower back is a ½ inch scar.

There is early decomposition consisting of skin slippage and vascular marbling.

CLOTHING AND PERSONAL EFFECTS

The following clothing items and personal effects are present on the body at the time of autopsy:

- Brown shirt
- Gray underpants
- Gray t-shirt
- White shirt

MEDICAL INTERVENTION

- Endotracheal tube in the oropharynx that enters the trachea
- Intravenous catheter (IV) in the back of the left hand
- Electrocardiograph (EKG) pads on the chest

RADIOGRAPHS

A complete set of postmortem radiographs is obtained and demonstrates the following:
No radiopaque projectiles or foreign matter

EVIDENCE OF INJURY

There are fractures of the right 5th and left 3rd-7th ribs on the anterior aspects.

ACLU Detainee DeathII ARMY MEDCOM 159

INTERNAL EXAMINATION

HEAD:
The galeal and subgaleal soft tissues of the scalp are free of injury. The calvarium is intact, as is the dura mater beneath it. Clear cerebrospinal fluid surrounds the 1250 gm brain, which has unremarkable gyri and sulci. Coronal sections demonstrate sharp demarcation between white and grey matter, without hemorrhage or contusive injury. The ventricles are of normal size. The basal ganglia, brainstem, cerebellum, and arterial systems are free of injury or other abnormalities. There are no skull fractures. The atlanto-occipital joint is stable.

NECK:
The anterior strap muscles of the neck are homogenous and red-brown, without hemorrhage. The thyroid cartilage and hyoid are intact. The larynx is lined by intact white mucosa. The thyroid is symmetric and red-brown, without cystic or nodular change. The tongue is free of bite marks, hemorrhage, or other injuries.

The cervical spine is intact and there is no paraspinous muscular hemorrhage.

BODY CAVITIES:
The sternum and vertebral bodies are visibly and palpably intact. No excess fluid is in the pleural, pericardial, or peritoneal cavities. The organs occupy their usual anatomic positions.

There are fractures of the anterior left ribs 3-7 and the right 5th rib on the anterior aspect.

RESPIRATORY SYSTEM:
There are dense fibrous adhesions of both pleural cavities. The right and left lungs weigh 800 and 650 gm, respectively. The external surfaces are deep red-purple. The pulmonary parenchyma is diffusely congested and edematous. No mass lesions or areas of consolidation are present.

CARDIOVASCULAR SYSTEM:
The 400 gm heart is contained in an intact pericardial sac. The epicardial surface is smooth, with minimal fat investment. The coronary arteries are present in a normal distribution, with a right-dominant pattern. Cross sections of the vessels show 50-80% multifocal stenoses of the left anterior descending coronary artery, focal 50% calcific stenosis of the left circumflex coronary artery, and 50-75% multifocal stenoses of the right coronary artery with a focal 85% stenosis. The myocardium is homogenous, red-brown, and firm. The mitral valve is thickened and fibrotic but there are no vegetations. The remaining valve leaflets are thin and mobile. The walls of the left and right ventricles are 1.4 and 0.4 cm thick, respectively. The endocardium is smooth and glistening. The aorta has moderate to severe atherosclerosis and gives rise to three intact and patent arch vessels. The renal and mesenteric vessels are unremarkable.

ACLU Detainee DeathII ARMY MEDCOM 160

LIVER & BILIARY SYSTEM:
The 1800 gm liver has an intact, smooth capsule and a sharp anterior border. The parenchyma is tan-brown and congested, with the usual lobular architecture. No mass lesions or other abnormalities are seen. The gallbladder contains a minute amount of green-black bile and no stones. The mucosal surface is green and velvety. The extrahepatic biliary tree is patent.

SPLEEN:
The 200 gm spleen has a smooth, intact, red-purple capsule. The parenchyma is maroon and congested, with distinct Malpighian corpuscles.

PANCREAS:
The pancreas is firm and yellow-tan, with the usual lobular architecture. No mass lesions or other abnormalities are seen.

ADRENALS:
The right and left adrenal glands are symmetric, with bright yellow cortices and grey medullae. No masses or areas of hemorrhage are identified.

GENITOURINARY SYSTEM:
The right and left kidneys weigh 175 and 200 gm, respectively. The external surfaces are intact and smooth. The cut surfaces are red-tan and congested, with uniformly thick cortices and sharp corticomedullary junctions. The pelves are unremarkable and the ureters are normal in course and caliber. White bladder mucosa overlies an intact bladder wall. The bladder contains approximately 10 ml of cloudy urine. The prostate is normal in size, with lobular, yellow-tan parenchyma. The seminal vesicles are unremarkable. The testes are free of mass lesions, contusions, or other abnormalities.

GASTROINTESTINAL TRACT:
The esophagus is intact and lined by smooth, grey-white mucosa. The stomach contains approximately 50 ml of dark green liquid. The gastric wall is intact. The duodenum, loops of small bowel, and colon are unremarkable. The appendix is surgically absent.

ADDITIONAL PROCEDURES

- Documentary photographs are taken by (b)(6)
- Specimens retained for toxicologic testing and/or DNA identification are: blood, urine, spleen, liver, lung, kidney, adipose, brain, bile, gastric, and psoas
- The dissected organs are forwarded with the body
- Personal effects are released to the appropriate mortuary operations representatives

MICROSCOPIC EXAMINATION

Selected portions of organs are retained in formalin, without preparation of histologic slides.

ACLU Detainee DeathII ARMY MEDCOM 161

TOXICOLOGY

Toxicologic analysis of blood and bile was negative for ethanol and drugs of abuse. Cyanide was not detected.

OPINION

This elderly Iraqi male died of atherosclerotic cardiovascular disease (blockage of the arteries that supply blood and oxygen to the heart). The rib fractures noted at autopsy are consistent with cardiopulmonary resuscitation (CPR). There was no significant trauma.

The manner of death is natural.

(b)(6)

(b)(6) Medical Examiner

ACLU Detainee DeathII ARMY MEDCOM 162

ARMED FORCES INSTITUTE OF PATHOLOGY
Office of the Armed Forces Medical Examiner
1413 Research Blvd., Bldg. 102
Rockville, MD 20850
1-800-944-7912

FINAL AUTOPSY REPORT

Name: Awad Al-Juwadi, Hussein
US Detainee # (b)(6)
Date of Birth (b)(6) 1929
Date of Death: (b)(6) 2004
Date of Autopsy: 18 MAY 2004
Date of Report: 18 JUN 2004

Autopsy No.: (b)(6)
AFIP No.: (b)(6)
Rank: Iraqi National
Place of Death: Baghdad, Iraq
Place of Autopsy: LSA Anaconda Mortuary, Balad Iraq

Circumstances of Death: This 75 year old male, an Iraqi National, was a detainee at the Central Baghdad Detainee Facility (Abu Ghraib). On (b)(6) 2004 he reportedly abruptly collapsed and became unconscious. Resuscitation was initiated and continued during transport to the facility hospital where he died. According to records provided by the investigative agency, (b)(6) had a past medical history significant for diabetes mellitus, hypertension and previous myocardial infarction.

Authorization for Autopsy: Office of the Armed Forces Medical Examiner, IAW 10 USC 1471

Identification: Presumptive identification accomplished by comparison to photographs and reports supplied by the investigative agency (b)(2) CID, LSA Anaconda, Balad, Iraq)

CAUSE OF DEATH: **Severe Atherosclerotic Cardiovascular Disease**

MANNER OF DEATH: **Natural**

ACLU Detainee DeathII ARMY MEDCOM 163

FINAL AUTOPSY DIAGNOSES:

I. Severe Atherosclerotic Cardiovascular Disease
- **a. Right Coronary Artery: 95% to pinpoint stenosis**
- **b. Left Coronary Artery: 80% stenosis with concentric calcification**
- **c. Proximal Left Descending Coronary Artery: 90% stenosis**
- **d. Status Post Remote Posterior Left Septal Infarction**
- **e. Severe Aortic Atherosclerosis**

II. Aortic Aneurysm (8cm)

III. Cardiomegaly (810gm)

IV. Marked Nephrosclerosis

V. No external injuries noted

VI. Toxicology: negative for drugs of abuse and ethanol

ACLU Detainee DeathII ARMY MEDCOM 164

EXTERNAL EXAMINATION

The body is that of a well-developed, well-nourished 70-inch tall, 200 pounds (estimated) Caucasian male whose appearance is consistent with the reported age of 75 years. Lividity is fixed on the posterior aspect of the body and rigor has passed. The temperature of the deceased is cold, that of the refrigeration unit.

The scalp is covered with white hair and there is frontal and occipital balding. The irides are hazel, and the pupils are round and equal in diameter. The external auditory canals are free of abnormal secretions or blood. The ears are unremarkable and they are not pierced. The nares are patent and the lips are atraumatic. The nose and maxillae are palpably stable. The deceased is edentulous.

The neck is straight, and the trachea is midline and mobile. The chest is symmetric. The abdomen is mildly protuberant. The genitalia are those of a normal adult circumcised male. The testes are descended and free of masses. Pubic hair is present in a normal distribution. The buttocks and anus are unremarkable.

The upper and lower extremities are symmetric and without evidence of clubbing, edema, and injuries. A well-circumscribed, ¼-inch verrucoid lesion is noted on the posterior-medial aspect of the mid right leg.

Tattoos are not present and scars are noted in the following locations:

- An oblique 1 ¾ x 1/16-inch well-healed scar is on the dorsal aspect of the left hand
- A vertical ¾ x ¼-inch well-healed scar is inferior to the left knee
- An ovoid ¼ x ½-inch well-healed scar is inferior to the right knee
- An oblique 1 x 1/8-inch well healed scar is on the anterior aspect of the left ankle

CLOTHING AND PERSONAL EFFECTS

The following clothing items and personal effects are present on the body at the time of autopsy:

- A long sleeved dark green shirt without a label
- Black briefs
- Additional items or personal effects are not present

MEDICAL INTERVENTION

Electrocardiogram monitor pads are affixed to the anterior aspect of the chest. Puncture marks consistent with intravenous devices are noted in the left antecubital fossa and right aspect of the groin.

ACLU Detainee DeathII ARMY MEDCOM 165

EVIDENCE OF INJURY

None

INTERNAL EXAMINATION

HEAD:
The galeal and subgaleal soft tissues of the scalp are free of injury. The calvarium is intact, as is the dura mater beneath it. The brain weighs 1500 gm and has unremarkable gyri and sulci. Coronal sections demonstrate sharp demarcation between white and grey matter, without hemorrhage or contusive injury. The ventricles are of normal size. The basal ganglia, brainstem, and cerebellum are free of injury or other abnormalities. Mild atherosclerosis (20-30%) is noted in the basilar artery; otherwise the remainder of the arterial system is free of abnormalities. There are no skull fractures. The atlanto-occipital joint is stable.

NECK:
The anterior strap muscles of the neck are homogenous and red-brown, without hemorrhage. The thyroid cartilage and hyoid bone are intact. The larynx is lined by intact mucosa. The thyroid gland is symmetric and red-brown, without cystic or nodular change. The tongue is free of bite marks, hemorrhage, or other injuries.

BODY CAVITIES:
The ribs, sternum, and vertebral bodies are visibly and palpably intact. No excess fluid is in the pleural, pericardial, or peritoneal cavities. The organs occupy their usual anatomic positions.

RESPIRATORY SYSTEM:
The right and left lungs are edematous and weigh 800 and 820 gm, respectively. There is prominent anthracotic pigment deposition on the pleura as well as throughout the lung parenchyma. The external surfaces are otherwise deep red-purple. The pulmonary parenchyma is diffusely congested and edematous and exudes edema fluid on cut sections. No mass lesions or areas of consolidation are present.

CARDIOVASCULAR SYSTEM:
There is marked enlargement of the heart. The heart weighs 820 gm. The epicardial surface is smooth, with minimal fat investment. The coronary arteries are present in a normal distribution, with a right-dominant pattern. Cross sections of the vessels show severe atherosclerosis. The proximal aspect of the left coronary artery show 80% calcific concentric stenosis; the proximal left anterior descending coronary artery shows 90% stenosis. The right coronary and circumflex arteries show 30-50% stenosis. The myocardium is red-brown and flaccid. The walls of the left and right ventricles measure 1.1 and 0.3-cm, respectively. Cut sections of the left ventricle show a 2 x 1 cm area of fibrosis on the posterior-septal left ventricular wall consistent with remote myocardial infarction. The valve leaflets are thin and mobile. The proximal aorta is involved by an

ACLU Detainee DeathII ARMY MEDCOM 166

8 cm aneurysm. Prominent calcific atherosclerosis of the abdominal aorta obscures the origins of the renal and mesenteric vessels.

LIVER & BILIARY SYSTEM:
The 1900 gm liver has an intact, smooth capsule and a sharp anterior border. The parenchyma is tan-brown and congested, with the usual lobular architecture. No mass lesions or other abnormalities are seen. The gallbladder contains 23 ml of green-black bile and no stones. The mucosal surface is green and velvety. The extrahepatic biliary tree is patent.

SPLEEN:
The 240 gm spleen has a smooth, intact, red-purple capsule. The parenchyma is maroon and congested, with distinct Malpighian corpuscles.

PANCREAS:
The pancreas is firm and yellow-tan, with the usual lobular architecture. No mass lesions or other abnormalities are seen.

ADRENALS GLANDS:
The right and left adrenal glands are symmetric, with yellow cortices and grey medullae. No masses or areas of hemorrhage are identified.

GENITOURINARY SYSTEM:
The right and left kidneys weigh 120 gm, each. The external capsules are removed with great difficulty from the underlying granular, dusky, cortical surfaces of the kidneys. Both kidneys demonstrate scattered cortical cysts ranging in size from ½ to ¾ cm. The cut surfaces are tan-brown and congested with poor demarcation of the cortico-medullary junctions. The pelves are unremarkable and the ureters are normal in course and caliber. The bladder is intact and empty. The prostate gland is normal in size with lobular yellow-tan parenchyma. The seminal vesicles are unremarkable. The testes are free of mass lesions, contusions, or other abnormalities.

GASTROINTESTINAL TRACT:
The esophagus is intact and lined by smooth, grey mucosa. The stomach contains 400 ml of partially digested food including corn and beans. The gastric wall is intact. The duodenum, loops of small bowel, and colon are unremarkable. The appendix is present.

ADDITIONAL PROCEDURES

- Documentary photographs are taken by (b)(6)
- Attending the autopsy are SA (b)(6) (b)(2) detachment CID
- Specimens retained for toxicologic testing and/or DNA identification are: brain, liver, spleen, psoas muscle, kidney, lung, vitreous fluid, blood, stomach contents, and bile
- The dissected organs are forwarded with body

ACLU Detainee DeathII ARMY MEDCOM 167

- Personal effects are released to the appropriate mortuary operations representatives

MICROSCOPIC EXAMINATION

Selected portions of organs are retained in formalin, without preparation of histologic slides.

TOXICOLOGY

AFIP Accession Number: (b)(6) Dated 7 June 2004
Volatiles: Blood and Bile- No ethanol detected
Cyanide: Blood- no cyanide detected
Drugs: Blood- no drugs of abuse detected, positive for atropine (a resuscitation medication)

OPINION

This 75-year-old man, (b)(6) and Iraqi National detained at the Baghdad Central Detention Facility died of severe atherosclerotic cardiovascular disease. His condition was complicated by marked cardiomegaly.
The manner of death is Natural.

(b)(6)

Medical Examiner

ACLU Detainee DeathII ARMY MEDCOM 168

DEPARTMENT OF DEFENSE
ARMED FORCES INSTITUTE OF PATHOLOGY
WASHINGTON, DC 20306-6000

REPLY TO ATTENTION OF

AFIP (b)(6)

TO:

OFFICE OF THE ARMED FORCES MEDICAL EXAMINER
ARMED FORCES INSTITUTE OF PATHOLOGY
WASHINGTON, DC 20306-6000

PATIENT IDENTIFICATION
AFIP Accessions Number Sequence
(b)(6)

Name
AWADAL-JAWADI, HUSSEIN

SSAN: Autopsy: (b)(6)
Toxicology Accession #: (b)(6)
Date Report Generated: June 7, 2004

CONSULTATION REPORT ON CONTRIBUTOR MATERIAL

AFIP DIAGNOSIS REPORT OF TOXICOLOGICAL EXAMINATION

Condition of Specimens: GOOD
Date of Incident: (b)(6) 2004 **Date Received:** 5/27/2004

VOLATILES: The **BLOOD AND BILE** were examined for the presence of ethanol at a cutoff of 20 mg/dL. No ethanol was detected.

CYANIDE: There was no cyanide detected in the blood. The limit of quantitation for cyanide is 0.25 mg/L. Normal blood cyanide concentrations are less than 0.15 mg/L. Lethal concentrations of cyanide are greater than 3 mg/L.

DRUGS: The **BLOOD** was screened for acetaminophen, amphetamine, antidepressants, antihistamines, barbiturates, benzodiazepines, cannabinoids, cocaine, dextromethorphan, lidocaine, narcotic analgesics, opiates, phencyclidine, phenothiazines, salicylates, sympathomimetic amines and verapamil by gas chromatography, color test or immunoassay. The following drugs were detected:

Positive Atropine: Atropine was detected in the blood by gas chromatography and confirmed by gas chromatography/mass spectrometry.

(b)(6)
Office of the Armed Forces Medical Examiner

(b)(6)
Office of the Armed Forces Medical Examiner

ACLU Detainee DeathII ARMY MEDCOM 169

ARMED FORCES INSTITUTE OF PATHOLOGY
Office of the Armed Forces Medical Examiner
1413 Research Blvd., Bldg. 102
Rockville, MD 20850
1-800-944-7912

FINAL AUTOPSY REPORT

Name: Mohamed Ali, Farhad
Alternate spellings: (b)(6)
Date of Birth: unknown
Date of Death: (b)(6) 2004
Date of Autopsy: 26 April 2004
Date of Report: 22 November 2004

Autopsy No.: (b)(6)
AFIP No.: (b)(6)
Rank: Civilian, Iraqi National
Place of Death: Mosul, Iraq
Place of Autopsy: Mosul, Iraq

Circumstances of Death: This approximately 27 year-old male civilian, presumed Iraqi national, died in US custody approximately 72 hours after being apprehended. By report, physical force was required during his initial apprehension during a raid. During his confinement, he was hooded, sleep deprived. and subjected to hot and cold environmental conditions, including the use of cold water on his body and hood.

Authorization for Autopsy: Office of the Armed Forces Medical Examiner, IAW 10 USC 1471

Identification: Visual, per detention facility records: postmortem fingerprints and DNA profile obtained

CAUSE OF DEATH: Undetermined

MANNER OF DEATH: Undetermined

ACLU Detainee DeathII ARMY MEDCOM 170

FINAL AUTOPSY DIAGNOSES:

I. Evidence of restraint
   a. White plastic "Flexcuffs" around each wrist
   b. Abrasions and contusions around wrists

II. Evidence of injury
   a. Minor abrasions and contusions of extremities
   b. Laceration above right eyebrow, 1 cm
   c. Contusion of right side of neck
   d. Minor abrasions of left side of forehead
   e. Subgaleal hemorrhage of bilateral frontal regions of scalp
   f. Intramuscular hemorrhage of anterior aspect of right shoulder
   g. No internal evidence of trauma

III. No evidence of significant natural disease within the limitations of the examination
   a. Cardiovascular System: No specific pathologic changes (AFIP Cardiovascular Pathology consultation)
      i. Heart weight, 450 gm
      ii. Histologically, left ventricular myocyte hypertrophy with focal mild subendocardial interstitial fibrosis
      iii. Contraction band necrosis, anterior right ventricle
      iv. Mildly thickened intramural coronary arteries
      v. Mild medial thickening of the sinus nodal artery
      vi. Focal mild dysplasia of penetrating branches of the AV nodal artery without increased fibrosis in the crest of the ventricular septum
   b. Neuropathology System: (AFIP Neuropathology Consultation)
      i. Cerebral edema, brain 1400 gm
      ii. Early acute neuronal injury
   c. Liver (AFIP Hepatic Pathology Consultation)
      i. Microvesicular steatosis, etiology undetermined
      ii. Marked congestion, likely agonal
   d. Pulmonary edema; right lung 700 gm, left lung 900 gm

IV. Early to moderate decomposition
   a. Green discoloration of abdomen
   b. Focal skin slippage

V. Evidence of medical intervention
   a. Endotracheal tube in place
   b. Intravenous catheter in the left antecubital fossa
   c. Intravenous catheter in the right inguinal region
   d. Three adhesive EKG tabs on anterior torso
   e. Pulse oximeter on left index finger

ACLU Detainee DeathII ARMY MEDCOM 171

f. Curvilinear abrasion on upper chest, consistent with defibrillation
g. Fractures of anterior aspect of left 3rd rib and right 2nd-4th and 6th ribs, consistent with CPR efforts

VI. Toxicology (AFIP)
a. Volatiles: Mixed volatiles consistent with postmortem production; mg/dL
    i. Blood: acetone 20, 2-propanol 7
    ii. Urine: acetone 67, 2-propanol 3
b. Drugs: Consistent with resuscitation efforts
    i. Lidocaine detected in the urine
    ii. Urine negative for other screened medications and drugs of abuse

ACLU Detainee DeathII ARMY MEDCOM 172

EXTERNAL EXAMINATION

The body is that of an unclad well-developed, well-nourished male. The body weighs approximately 190 pounds, is 72" in height and appears compatible with the reported age of 27 years. The body temperature is cold, that of the refrigeration unit. Rigor has dissipated, and the body is flaccid. Lividity is present and fixed on the posterior surface of the body, except in areas exposed to pressure.

There is early to moderate decomposition consisting of focal skin slippage of the arms, green discoloration of the abdomen, and early corneal clouding.

The scalp is covered with dark brown hair averaging 7 cm in length. Facial hair consists of a dark mustache and dark facial stubble. The irides are brown, and the corneae are slightly cloudy. The sclerae and conjunctivae are pale and free of petechiae. The earlobes are not pierced. The external auditory canals, external nares and oral cavity are free of foreign material and abnormal secretions. The nasal skeleton is palpably intact. The lips are without evident injury. The teeth are natural and in good condition.

The neck is straight and the trachea is midline and mobile. The chest is symmetric and well developed. No injury of the ribs or sternum is evident externally. The abdomen is flat and soft. Healed surgical scars are not noted. The extremities are well developed with normal range of motion. The fingernails are intact. Tattoos are not noted, and needle tracks are not observed. The external genitalia are those of a normal adult circumcised male. The testes are descended and free of masses. The pubic hair is shaved but is present in a normal distribution. The buttocks and anus are unremarkable.

A tag with the name of the decedent is secured to the right first toe.

EVIDENCE OF THERAPY

There is an endotracheal tube in place, and there are three adhesive EKG tabs on the body, two on the upper chest and one on the lower left side of the abdomen. There is an intravenous catheter in the left antecubital fossa, and there is an intravenous catheter in the right inguinal region. There is a 12 x 6 cm oval curvilinear abrasion on the upper right side of the chest, consist with defibrillation attempts. There is a pulse oximeter taped over the end of the left index finger. There are fractures of the anterior aspect of the right 3rd rib and left 2nd-4th and 6th ribs, consistent with CPR efforts.

EVIDENCE OF INJURY

The ordering of the following injuries is for descriptive purposes only and is not intended to imply order of infliction or relative severity. All wound pathways are given relative to standard anatomic position.

There is bilateral periorbital ecchymosis, more pronounced over the lower lids and slightly more prominent on the left side. On the left side of the forehead, there are two

ACLU Detainee DeathII ARMY MEDCOM 173

diagonally oriented parallel, linear abrasions. The medial one measures 4 x 0.2 cm and the lateral one is 3 x 0.1 cm. There are multiple small, ill-defined areas of excoriation and superficial abrasion over the central forehead and bridge of the nose. There is a 1 cm laceration just above the lateral aspect of the right eyebrow. There is a 6 x 6 cm red brown contusion on the right lateral aspect of the neck, just below the angle of the mandible.

Upon reflecting the scalp, there is bilateral frontal subgaleal scalp hemorrhage. The most prominent area is 3 x 2 cm, surrounding the laceration near the left eyebrow.

There is an 8 x 1 cm faint abrasion of the anterior aspect of the right shoulder, and there is a faint 3 x 3 cm red contusion of the anterior aspect of the left shoulder. There is a 9 x 0.2 cm curved linear abrasion just to the left of the umbilicus. There is a 1 x 0.3 cm abrasion of the lower left aspect of the abdomen.

Upon opening the chest, there is intramuscular hemorrhage of the anterior aspect of the right shoulder.

There is a 12 x 8 cm area of contusion and faint abrasion on the anterior lateral aspect of the right upper arm. There is a 6 x 2 cm red contusion on the anterior medial aspect of the right upper arm. There are three ill-defined bands of erythema and red contusion over the back of the left wrist, 7 x 3 cm in aggregate.

INTERNAL EXAMINATION

BODY CAVITIES:
The body is opened by the usual thoraco-abdominal incision and the chest plate is removed. No adhesions are present in any of the body cavities. There is 100 ml of serosanguinous fluid in each pleural space. There is no significant pericardial or peritoneal fluid. All body organs are present in the normal anatomical position. The vertebral bodies are visibly and palpably intact. The subcutaneous fat layer of the abdominal wall is 2 cm thick. There is no internal evidence of blunt force or penetrating injury to the abdominal region.

HEAD: (CENTRAL NERVOUS SYSTEM)
The scalp is reflected, and no skull fractures are found. The calvarium of the skull is removed. The dura mater and falx cerebri are intact. There is no epidural or subdural hemorrhage present. The leptomeninges are thin and delicate. The cerebrospinal fluid is clear. The cerebral hemispheres are symmetrical. The structures at the base of the brain, including cranial nerves and blood vessels, are intact. Coronal sections through the cerebral hemispheres revealed no lesions, and there is no evidence of infection, tumor, or trauma. The ventricles are of normal size. Transverse sections through the brain stem and cerebellum are unremarkable. The dura is stripped from the basilar skull, and no fractures are found. The atlanto-occipital joint is stable. The brain weighs 1400 grams.

ACLU Detainee DeathII ARMY MEDCOM 174

NECK:
Examination of the soft tissues of the neck, including strap muscles, thyroid gland and large vessels, reveals no abnormalities. The anterior strap muscles of the neck are homogeneous and red-brown, without hemorrhage. The thyroid cartilage and hyoid bone are intact. The larynx is lined by intact white mucosa and is unobstructed. The thyroid gland is symmetric and red-brown, without cystic or nodular change. There is no evidence of infection, tumor, or trauma, and the airway is patent. Incision and dissection of the posterior neck demonstrates no deep paracervical muscular injury, hemorrhage, or fractures of the dorsal spinous processes.

CARDIOVASCULAR SYSTEM:
The pericardial surfaces are smooth, glistening and unremarkable; the pericardial sac is free of significant fluid and adhesions. A moderate amount of epicardial fat is present. The coronary arteries arise normally, follow the usual distribution and are widely patent, without evidence of significant atherosclerosis or thrombosis. The chambers and valves exhibit the usual size-position relationship and are unremarkable. The myocardium is dark red-brown, firm and unremarkable; the atrial and ventricular septa are intact. The left ventricle is 1.3 cm in thickness and the right ventricle is 0.4 cm in thickness. The aorta and its major branches arise normally, follow the usual course and are widely patent, free of significant atherosclerosis and other abnormality. The venae cavae and their major tributaries return to the heart in the usual distribution and are free of thrombi. The heart weighs 450 grams. See "Cardiovascular Pathology Report" below.

RESPIRATORY SYSTEM:
The upper airway is clear of debris and foreign material; the mucosal surfaces are smooth, yellow-tan and unremarkable. The pleural surfaces are smooth, glistening and unremarkable bilaterally. The pulmonary parenchyma is red-purple, exuding moderate amounts of bloody fluid; no focal lesions are noted. The pulmonary arteries are normally developed, patent and without thrombus or embolus. The right lung weighs 700 grams; the left 900 grams.

LIVER & BILIARY SYSTEM:
The hepatic capsule is smooth, glistening and intact, covering dark red-brown, moderately congested parenchyma with no focal lesions noted. The gallbladder contains 10 ml of green-brown, mucoid bile; the mucosa is velvety and unremarkable. The extrahepatic biliary tree is patent, without evidence of calculi. The liver weighs 1450 grams.

ALIMENTARY TRACT:
The tongue is free of bite marks, hemorrhage, or other injuries. The esophagus is lined by gray-white, smooth mucosa. The gastric mucosa is arranged in the usual rugal folds and the lumen is essentially empty with only a film of mucous. The small and large bowel are unremarkable. The pancreas has a normal pink-tan lobulated appearance and the ducts are clear. The appendix is present and is unremarkable.

ACLU Detainee DeathII ARMY MEDCOM 175

GENITOURINARY SYSTEM:
The renal capsules are smooth and thin, semi-transparent and strip with ease from the underlying smooth, red-brown cortical surfaces. The cortices are sharply delineated from the medullary pyramids, which are red-purple to tan and unremarkable. The calyces, pelves and ureters are unremarkable. White bladder mucosa overlies an intact bladder wall. The urinary bladder contains 200 ml of clear, yellow urine. The prostate gland is normal in size, with lobular, yellow-tan parenchyma. The seminal vesicles are unremarkable. The testes are free of mass lesions, contusions, or other abnormalities. The right kidney weighs 150 grams; the left 160 grams.

RETICULOENDOTHELIAL SYSTEM:
The spleen has a smooth, intact capsule covering red-purple, moderately firm parenchyma; the lymphoid follicles are unremarkable. The regional lymph nodes appear normal. The spleen weighs 160 grams.

ENDOCRINE SYSTEM:
The pituitary, thyroid and adrenal glands are unremarkable.

MUSCULOSKELETAL SYSTEM:
Muscle development is normal. No bone or joint abnormalities are noted.

MICROSCOPIC EXAMINATION

HEART: See "Cardiovascular Pathology Report" below.

LUNGS: The alveolar spaces and small air passages are expanded and contain no significant inflammatory component or edema fluid. The alveolar walls are thin and slightly congested. The arterial and venous vascular systems are normal. The peribronchial lymphatics are unremarkable.

LIVER: The hepatic architecture is intact. The portal areas show no increased inflammatory component or fibrous tissue. The hepatic parenchymal cells are well-preserved with no evidence of cholestasis or sinusoidal abnormalities. See "Hepatic Pathology Report" below.

SPLEEN: The capsule and white pulp are unremarkable. There is minimal congestion of the red pulp.

TESTES: Unremarkable.

THYROID GLAND: Unremarkable.

ADRENALS: The cortical zones are distinctive, and the medullae are not remarkable.

ACLU Detainee DeathII ARMY MEDCOM 176

KIDNEYS: There is moderate autolysis. The subcapsular zones are unremarkable, and the glomeruli are mildly congested without cellular proliferation, mesangial prominence, or sclerosis. There is no interstitial fibrosis or significant inflammation. There is no thickening of the walls of the arterioles or small arterial channels.

BRAIN: See "Neuropathology Report" below.

CARDIOVASCULAR PATHOLOGY REPORT

Department of Cardiovascular Pathology, AFIP:

"AFIP DIAGNOSIS: (b)(6) No specific pathologic changes

History: Arab male detainee, death in custody

Heart: 450 grams; normal epicardial fat; closed foramen ovale; normal cardiac chamber dimensions: left ventricular cavity diameter 30 mm, left ventricular free wall thickness 13 mm, ventricular septum thickness 15 mm; right ventricular dilatation: right ventricle thickness 4 mm, without gross scars or abnormal fat infiltrates; grossly normal valves and endocardium; no gross myocardial fibrosis or necrosis; histologic sections show left ventricular myocyte hypertrophy with focal mild subendocardial interstitial fibrosis; contraction band necrosis, anterior right ventricle; mildly thickened intramural coronary arteries

Coronary arteries: Normal ostia; right dominance; no gross atherosclerosis

Conduction system: The sinoatrial node is histologically unremarkable, but there is mild medial thickening of the sinus nodal artery. The compact atrioventricular (AV) node shows mild fragmentation (Mahaim fibers) within the central fibrous body, but is otherwise unremarkable. The penetrating bundle is centrally located without inflammation, increased fat, vascularity or proteoglycan. The proximal bundle branches are intact and unremarkable. There is focal mild dysplasia of penetrating branches of the AV nodal artery, but no significantly increased fibrosis in the crest of the ventricular septum.

Comment: The heart weight of 450 grams may reflect some degree of left ventricular hypertrophy, depending on the subject's body weight."

NEUROPATHOLOGY REPORT

Department of Neuropathology and Ophthamic Pathology, AFIP:

"Neuropathology consult (b)(6) We reviewed the five H&E stained microscopic sections submitted in reference to this case.
Microscopic sections demonstrate multiple sections of grey and white matter, cerebellum and spinal cord/medulla. Sections show widened pericellular and perivascular spaces and

ACLU Detainee DeathII ARMY MEDCOM 177

scattered neurons with cytoplasmic eosinophilia and shrunken, pyknotic nuclei, most prominent in the dentate nucleus and cerebellum. These morphologic features represent cerebral edema and early acute neuronal injury.
This material was reviewed in conference by the staff of the Department of Neuropathology and Ophthalmic Pathology."

HEPATIC PATHOLOGY REPORT

Division of Hepatic Pathology, AFIP:

"Liver: (1) Microvesicular steatosis, etiology undetermined
(2) Marked congestion

Some toxins can cause microvesicular fat, usually associated with profound metabolic disturbances, but it can also be stress-related. There is no way to distinguish between these by histology alone. The congestion is presumably agonal. There is some lipofuscin pigment in centrilobular hepatocytes, but no bile stasis. The Masson stain shows no fibrosis to suggest underlying chronic liver disease. The PASD and iron stains show no lipofuscin or hemosiderin laden macrophages to suggest hepatocellular necrosis."

ADDITIONAL PROCEDURES

- Documentary photographs are taken by OAFME photographers
- Specimens retained for toxicologic testing and/or DNA identification are: vitreous fluid, heart blood, urine, bile, spleen, liver, lung, brain, kidney, and psoas muscle
- The dissected organs are forwarded with the body

ACLU Detainee DeathII ARMY MEDCOM 178

OPINION

Based on available investigation and complete autopsy examination, no definitive cause of death for this approximately 27 year-old male Iraqi civilian in US custody in Iraq could be determined. There is evidence of multiple minor injuries; however, there is no definitive evidence of any trauma significant enough to explain the death. The injuries include bilateral periorbital ecchymoses ("blackeyes"); abrasions and contusions of the face, torso, and extremities; contusion of the side of the neck; and subgaleal hemorrhage of the scalp.

There is evidence of restraint, consisting of "flexicuffs" around the wrists with associated minor contusions, and asphyxia from various means cannot be completely excluded in a restrained individual.

There are non-specific cardiac findings, including mild medial thickening of the sinus nodal artery and focal mild dysplasia of the penetrating branches of the atrioventricular nodal artery. However, there is no associated increased septal fibrosis, which can be a potential substrate for cardiac arrhythmia. There is no gross evidence of atherosclerosis of the coronary arteries. A cardiac arrhythmia related to various ion channelopathies or coronary vasospasm cannot be excluded.

The decedent was also subjected to cold and wet conditions, and hypothermia may have contributed to his death.

Therefore, the cause of death is best classified as undetermined, and the manner of death is undetermined.

(b)(6)

(b)(6) Medical Examiner

ACLU Detainee DeathII ARMY MEDCOM 179

DEPARTMENT OF DEFENSE
ARMED FORCES INSTITUTE OF PATHOLOGY
WASHINGTON, DC 20306-6000

REPLY TO ATTENTION OF

AFIP-(b)(6)

TO:

OFFICE OF THE ARMED FORCES MEDICAL EXAMINER
ARMED FORCES INSTITUTE OF PATHOLOGY
WASHINGTON, DC 20306-6000

PATIENT IDENTIFICATION
AFIP Accessions Number Sequence
(b)(6)
Name
MOHAMED, FASHAD

SSAN: **Autopsy:** (b)(6)
Toxicology Accession #: (b)(6)
Report Date: MAY 11 2004

CONSULTATION REPORT ON CONTRIBUTOR MATERIAL

AFIP DIAGNOSIS **REPORT OF TOXICOLOGICAL EXAMINATION**

Condition of Specimens: GOOD
Date of Incident: (b)(6) 2004 **Date Received:** 5/3/2004

VOLATILES: The **BLOOD AND URINE** were examined for the presence of ethanol (cutoff of 20 mg/dL), acetaldehyde, acetone, 2-propanol, 1-propanol, t-butanol, 2-butanol, iso-butanol and 1-butanol by headspace gas chromatography. The following volatiles were detected: (concentration(s) in mg/dL)

	Acetone	2-Propanol
BLOOD	20	7
URINE	67	3

DRUGS: The **URINE** was screened for acetaminophen, amphetamine, antidepressants, antihistamines, barbiturates, benzodiazepines, cannabinoids, cocaine, dextromethorphan, lidocaine, narcotic analgesics, opiates, phencyclidine, phenothiazines, salicylates, sympathomimetic amines and verapamil by gas chromatography, color test or immunoassay. The following drugs were detected:

Positive Lidocaine: Lidocaine was detected in the urine by gas chromatography and confirmed by gas chromatography/mass spectrometry.

(b)(6)
Office of the Armed Forces Medical Examiner

(b)(6)
Office of the Armed Forces Medical Examiner

ACLU Detainee DeathII ARMY MEDCOM 180

ARMED FORCES INSTITUTE OF PATHOLOGY
Office of the Armed Forces Medical Examiner
1413 Research Blvd., Bldg. 102
Rockville, MD 20850
1-800-944-7912

PRELIMINARY AUTOPSY EXAMINATION REPORT

Name: Abbas, Mohamad Abul
SSAN: Prisoner Number (b)(6)
Date of Birth: (b)(6) 1948
Date of Incident: (b)(6) 2004
Date of Autopsy: 10 MAR 2004
Date of Report: 11 MAR 2004

Autopsy No.: (b)(6)
AFIP No.: Pending
Rank: EPOW
Place of Death: Baghdad, Iraq
Place of Autopsy: Baghdad International Airport

Circumstances of Death: Circumstances of Death: This 55-year-old male Enemy Prisoner of War had a history of ischemic heart disease. His past medical history includes hypertension, hypercholesterolemia, and possibly two previous myocardial infarctions. His medications included atenolol. Zocar, and aspirin, as well as sublingual nitroglycerin as needed. On the evening of (b)(6) 2004 he complained of chest pain and shortness of breath. He was brought to the medical clinic for evaluation where he became unresponsive. Resuscitation efforts, including Advanced Cardiac Life Support at a medical treatment facility, were unsuccessful.

Authorization for Autopsy: Armed Forces Medical Examiner, per 10 U.S. Code 1471

Identification: Identification is obtained by paperwork accompanying the body, including a photograph with a matching prisoner number.

CAUSE OF DEATH: Atherosclerotic Cardiovascular Disease

MANNER OF DEATH: Natural

These findings are preliminary, and subject to modification pending further investigation and laboratory testing.

ACLU Detainee DeathII ARMY MEDCOM 181

PRELIMINARY AUTOPSY DIAGNOSES:

I. Atherosclerotic Cardiovascular Disease

- **A. History of ischemic heart disease**
- **B. Cardiomegaly, marked (heart weight 620 grams)**
- **C. Coronary atherosclerosis, focally severe**
- **D. Diffuse myocardial scarring**
- **E. Arterionephrosclerosis, mild**

II. Marked Pulmonary Edema

III. Remote penetrating ballistic injury of the left buttock

- **A. Entrance: Inferior-medial aspect of left buttock (scar)**
- **B. Wound Path: Skin, subcutaneous tissue, and muscle of left buttock, muscle of proximal left thigh**
- **C. Recovered: Metallic foreign body encapsulated in fibrous tissue within muscle of proximal left thigh**
- **D. Wound Direction: Left to right, back to front, and downward**

IV. Fractures of the 5th and 6th ribs on the right, associated with hemorrhage into chest wall musculature and abrasions/thermal injury of the chest (resuscitation efforts)

V. Laceration of the nose and abrasion of the right index finger

VI. Toxicology Pending

(b)(6)

(b)(6) **Deputy Medical Examiner**

ACLU Detainee DeathII ARMY MEDCOM 182

ARMED FORCES INSTITUTE OF PATHOLOGY
Office of the Armed Forces Medical Examiner
1413 Research Blvd., Bldg. 102
Rockville, MD 20850
1-800-944-7912

FINAL AUTOPSY EXAMINATION REPORT

Name: BTB Abdullah, Saad Mohammed
SSAN: N/A
Date of Birth: BTB (b)(6) 1950
Date of Death (b)(6) 2004
Date of Autopsy: 28 FEB 2004
Date of Report: 25 JUN 2004

Autopsy No.: (b)(6)
AFIP No.: (b)(6)
Rank: Iraqi Civilian
Place of Death: Abu Ghraib Prison
Place of Autopsy: BIAP Mortuary
Baghdad Airport, Iraq

Circumstances of Death: This believed to be 54 year old Iraqi male civilian was a detainee of the U.S. Armed Forces at Camp Ghanci, Abu Ghraib Prison, Iraq, when he was brought to the main gate unconscious by other detainees. The decedent reported an inability to urinate to medics earlier on the day of his death. When brought to the gate the other detainees reported the decedent was dizzy and nauseated prior to losing consciousness.

Authorization for Autopsy: Office of the Armed Forces Medical Examiner, IAW 10 USC 1471.

Identification: Identification is established by visual examination by CID agents.

CAUSE OF DEATH: Acute Peritonitis secondary to Perforating Gastric Ulcer.

MANNER OF DEATH: Natural

ACLU Detainee DeathII ARMY MEDCOM 183

FINAL AUTOPSY DIAGNOSES:

I. Acute Peritonitis secondary to Gastric Ulcer Perforation
   A. Perforating gastric ulcer of pyloric region of the stomach associated with 900 mls of purulent ascites and fibrinous exudate on the surface of the intestines, liver and spleen.

II. Mild atherosclerosis of the right coronary artery (< 25% stenosis).

III. Dense fibrous adhesions of the left lung to the parietal pleura of the left hemithorax.

IV. Mild decomposition.

V. Toxicology is negative for ethanol, drugs of abuse and cyanide.

ACLU Detainee DeathII ARMY MEDCOM 184

EXTERNAL EXAMINATION

The body is that of a well-developed 71 1/2 inch long, 185-190 pounds (estimated) male Iraqi civilian whose appearance is consistent with the reported age of 54 years. Lividity is difficult to assess because of dark skin pigmentation and early decomposition. Rigor is easily broken, and the temperature is ambient. Marbling of the skin of the arms, abdomen and lower legs are consistent with early decomposition changes.

The scalp is covered with black and gray hair in a normal distribution. The irides are obscured by clouded corneas but appear dark colored and the pupils appear round and equal in diameter. The conjunctivae are free of injuries. The external auditory canals are dry and free of abnormal secretions. The left ear is missing the top portion of the helix (remote injury) and the right ear is unremarkable. The nares are patent, the nasal septum is intact and the lips are atraumatic. The nose and maxillae are palpably stable. The teeth appear natural and in fair repair.

The neck is straight. A 0.7 x 0.5 cm nevus is on the posterior neck. The trachea is midline and mobile. The chest is symmetric and free of external injuries. A 5.2 x 3.1 cm oval area of hyperpigmented skin is on the right side of the abdomen. The abdomen is flat and free of palpable masses. The genitalia are those of a normal adult circumcised male. There are multiple pink (hypopigmented) areas of skin on the glans penis. The testes are descended and free of masses. Pubic hair is present in a normal distribution. The left buttock has a 4.9 x 1.9 cm oval scar. The anus is atraumatic and has non-thrombosed external hemorrhoids.

The upper and lower extremities are symmetric and without clubbing or edema. The fingernails are chipping and splitting and the web spaces between the fingers and toes are free of injuries. A 9.5 x 3.5 irregular scar is on the anterior lateral aspect of the left thigh and a 5.2 x 2.2 cm scar is immediately below the left knee.

CLOTHING AND PERSONAL EFFECTS

The following clothing items and personal effects are present on the body at the time of autopsy:

The decedent was received nude for autopsy examination.

MEDICAL INTERVENTION

There are no medical appliances on the body at the time of autopsy. Cardiopulmonary resuscitation was reportedly done at the time of the decedent's collapse.

RADIOGRAPHS

A complete set of postmortem radiographs is obtained and demonstrates the following:

Air under the diaphragm

No long bone fractures or foreign bodies.

ACLU Detainee DeathII ARMY MEDCOM 185

EVIDENCE OF INJURY

The ordering of the following injuries is for descriptive purposes only, and is not intended to imply order of infliction or relative severity. All wound pathways are given relative to standard anatomic position.

There are no significant injuries.

INTERNAL EXAMINATION

HEAD:
The galeal and subgaleal soft tissues of the scalp are free of injury. The calvarium is intact, as is the dura mater beneath it. Clear cerebrospinal fluid surrounds the 1450 gm brain, which is softened, discolored and has unremarkable gyri and sulci. Coronal sections demonstrate sharp demarcation between white and gray matter, without hemorrhage or contusive injury. The ventricles are of normal size. The basal ganglia, brainstem, cerebellum and arterial systems are free of injury or other abnormalities. There are no skull fractures. The atlanto-occipital joint is stable.

NECK:
The anterior strap muscles of the neck are homogenous and red-brown, without hemorrhage. The thyroid cartilage and hyoid bone are intact. The larynx is lined by intact gray-white mucosa. The thyroid gland is symmetric, red-brown and without cystic or nodular change. The tongue is free of bite marks, hemorrhage, or other injuries.

BODY CAVITIES:
The ribs, sternum, and vertebral bodies are visibly and palpably intact. The right pleural cavity contains approximately 400 ml of bloody fluid. The pericardial sac contains approximately 30 ml of serosanguineous fluid and the peritoneal cavity contains approximately 900 ml of purulent ascites. The organs occupy their usual anatomic positions.

RESPIRATORY SYSTEM:
The right and left lungs each weigh 1100 gm. The external surfaces are smooth and deep red-purple. The pulmonary parenchyma is diffusely congested and edematous. The left lung is densely adherent to the parietal pleura of entire left hemithorax. No mass lesions or areas of consolidation are present in either lung.

CARDIOVASCULAR SYSTEM:
The 475 gm heart is contained in an intact pericardial sac. The epicardial surface is smooth, with minimal fat investment. The coronary arteries are present in a normal distribution, with a right-dominant pattern. Cross sections of the vessels show mild atherosclerosis (< 25% stenosis) of the left anterior descending branch of the left coronary artery and right coronary artery. The myocardium is homogenous, red-brown, and firm. The valve leaflets are thin and mobile. The walls of the left and right ventricles are 1.2 and 0.3-cm thick, respectively. The endocardium is smooth and

ACLU Detainee DeathII ARMY MEDCOM 186

glistening. The aorta gives rise to three intact and patent arch vessels and has mild atherosclerosis. The renal and mesenteric vessels are unremarkable.

LIVER & BILIARY SYSTEM:
The 1275 gm liver has an intact, smooth capsule and a sharp anterior border. The parenchyma is tan-brown and congested, with the usual lobular architecture. No mass lesions or other abnormalities are seen. The gallbladder contains a minute amount of green-black bile and no stones. The gallbladder mucosal surface is green and velvety. The extrahepatic biliary tree is patent.

SPLEEN:
The 175 gm spleen has a smooth, intact, red-purple capsule. The parenchyma is maroon and congested, with distinct Malpighian corpuscles.

PANCREAS:
The pancreas is firm and yellow-tan, with the usual lobular architecture. No mass lesions or other abnormalities are seen.

ADRENALS:
The right and left adrenal glands are symmetric, with bright yellow cortices and gray medullae. No masses or areas of hemorrhage are identified.

GENITOURINARY SYSTEM:
The right and left kidneys weigh 150 gm and 130 gm, respectively. The external surfaces are coarsely granular. The cut surfaces are red-tan and congested, with uniformly thick cortices and sharp corticomedullary junctions. The pelves are unremarkable and the ureters are normal in course and caliber. White bladder mucosa overlies an intact bladder wall. The bladder contains a scant amount of urine. The prostate is normal in size, with lobular, yellow-tan parenchyma. The seminal vesicles are unremarkable. The testes are free of mass lesions, contusions, or other abnormalities.

GASTROINTESTINAL TRACT:
The esophagus is intact and lined by smooth, gray-white mucosa. The stomach contains no food. A perforating ulcer, 1.5 x 1.0 cm on the mucosal surface of the stomach and 0.6 x 0.6 cm on the serosal surface, is in the pyloric region of the stomach. The greater omentum is adherent to the serosal surface of the stomach and surrounds the perforation of the stomach wall. The abdominal cavity contains approximately 900 ml of purulent ascites and fibrinous material covering the intestines, liver, and spleen.
The duodenum, loops of small bowel, and colon are unremarkable. The appendix is present.

ADDITIONAL PROCEDURES

- Documentary photographs are taken by an OAFME photographer.
- Specimens retained for toxicologic testing and/or DNA identification are: blood, spleen, liver, lung, kidney, brain, bile, gastric contents, and psoas muscle.
- The dissected organs are forwarded with body.

ACLU Detainee DeathII ARMY MEDCOM 187

- Personal effects are released to the appropriate mortuary operations representatives.

MICROSCOPIC EXAMINATION

Selected portions of organs are retained in formalin, without preparation of histologic slides.

ACLU Detainee DeathII ARMY MEDCOM 188

OPINION

This believed to be 54 year old Iraqi male died from acute peritonitis (inflammation of the abdominal cavity) that was caused by an ulcer that perforated through the stomach wall. The gastric contents and secretions spilled into the abdominal cavity causing the inflammation and infection. The decedent was most likely septic (bacteria in the blood system) and that caused his dehydration and kidney failure. His kidney failure was manifested in his inability to form urine. Kidney failure would then cause acid/base derangements, which then caused a fatal cardiac arrhythmia. The manner of death is natural.

(b)(6)

(b)(6) **Examiner**

ACLU Detainee DeathII ARMY MEDCOM 189

CERTIFICATE OF DEATH *(OVERSEAS)*
Acte de décès *(D'Outre-Mer)*

NAME OF DECEASED *(Last, First, Middle) Nom du décédé (Nom et prénoms)*	GRADE Grade	BRANCH OF SERVICE Arme	SOCIAL SECURITY NUMBER Numéro de l'Assurance Sociale
BTB Abdullah, Saad, Mohammed		Iraq Civilian	

ORGANIZATION Organisation	NATION *(e.g., United States)* Pays	DATE OF BIRTH Date de naissance	SEX Sexe
Detainee in Iraq	Iraq	(b)(6) 1950	☑ MALE Masculin ☐ FEMALE Féminin

RACE Race	MARITAL STATUS État Civil	RELIGION Culte
☒ CAUCASOID Caucasique	☐ SINGLE Célibataire	☐ DIVORCED Divorcé
☐ NEGROID Negroide	☐ MARRIED Marié	☐ SEPARATED Séparé
☐ OTHER (Specify) Autre (Spécifier)	☐ WIDOWED Veuf	☐ PROTESTANT Protestant
		☐ CATHOLIC Catholique
		☐ JEWISH Juif
		☐ OTHER (Specify) Autre (Spécifier)

NAME OF NEXT OF KIN Nom du plus proche parent	RELATIONSHIP TO DECEASED Parenté du décédé avec le susdit
STREET ADDRESS Domicile à (Rue)	CITY OR TOWN AND STATE *(Include ZIP Code)* Ville (Code postal compris)

MEDICAL STATEMENT Déclaration médicale

CAUSE OF DEATH *(Enter only once cause per line)* Cause du décès (N'indiquer qu'une cause par ligne)		INTERVAL BETWEEN ONSET AND DEATH Intervalle entre l'attaque et le décès
DISEASE OR CONDITION DIRECTLY LEADING TO DEATH[1] Maladie ou condition directement responsable de la mort[1]	Acute Peritonitis secondary to Perforating Gastric Ulcer	
ANTECEDENT CAUSES Symptômes précurseurs de la mort — MORBID CONDITION, IF ANY, LEADING TO PRIMARY CAUSE Condition morbide, s'il y a lieu, menant à la cause primaire		
ANTECEDENT CAUSES Symptômes précurseurs de la mort — UNDERLYING CAUSE, IF ANY, GIVING RISE TO PRIMARY CAUSE Raison fondamentale, s'il y a lieu, ayant suscité la cause primaire		
OTHER SIGNIFICANT CONDITIONS[2] Autres conditions significatives[2]		

MODE OF DEATH Condition de décès	AUTOPSY PERFORMED Autopsie effectuée	CIRCUMSTANCES SURROUNDING DEATH DUE TO EXTERNAL CAUSES Circonstances de la mort suscitées par des causes extérieures
☒ NATURAL Mort naturelle	☑ YES Oui ☐ NO Non	
☐ ACCIDENT Mort accidentelle	MAJOR FINDINGS OF AUTOPSY Conclusions principales de l'autopsie	
☐ SUICIDE Suicide	NAME OF PATHOLOGIST Nom du pathologiste (b)(6)	
☐ HOMICIDE Homicide	DATE Date 28 Feb 2004	AVIATION ACCIDENT Accident d'Avion ☐ YES Oui ☑ NO Non

DATE OF DEATH *(Hour, day, month, year)* Date de décès *(Heure, le jour, le mois, l'année)*	PLACE OF DEATH Lieu de décès
(b)(6) 2004	Abu Ghraib Prison, Iraq

I HAVE VIEWED THE REMAINS OF THE DECEASED AND DEATH OCCURRED AT THE TIME INDICATED AND FROM THE CAUSES AS STATED ABOVE.
J'ai examiné les restes mortels du dé funt je conclus que le décès est survenu à l'heure indiquée et à, la suite des causes énumérées ci-dessus.

NAME OF MEDICAL OFFICER Nom du médicin militaire ou du médicin sanitaire	TITLE OR DEGREE Titre ou diplôme
(b)(6)	Medical Examiner
GRADE Grade (b)(6)	INSTALLATION OR ADDRESS Installation ou adresse Dover AFB, DE 19902
DATE Date 13 MAY 04	(b)(6)

[1] *State disease, injury or complication which caused death, but not mode of dying such as heart failure, etc.*
[2] *State conditions contributing to the death, but not related to the disease or condition causing death.*
[1] *Préciser la nature de la maladie, de la blessure ou de la complication qui a contribué à la mort, mais non la manière de mourir, telle qu'un arrêt du coeur, etc*
[2] *Préciser la condition qui a contribué à la mort, mais n'ayant aucun rapport avec la maladie ou à la condition qui a provoqué la mort.*

DD FORM 1 APR 77 2064 REPLACES DA FORM 3565, 1 JAN 72 AND DA FORM 3565-R (AAS), 24 SEP 75, WHICH ARE OBSOLETE.

ACLU Detainee DeathII ARMY MEDCOM 190

ARMED FORCES INSTITUTE OF PATHOLOGY
Office of the Armed Forces Medical Examiner
1413 Research Blvd., Bldg. 102
Rockville, MD 20850
1-800-944-7912

FINAL AUTOPSY EXAMINATION REPORT

Name: BTB Ahmed, Hassan Ekab
SSAN: N/A
Date of Birth: BTB 1943
Date of Death: (b)(6) 2004
Date of Autopsy: 28 FEB 2004
Date of Report: 29 JUN 2004

Autopsy No.: (b)(6)
AFIP No.: (b)(6)
Rank: Iraqi Civilian
Place of Death: Tikrit, Iraq
Place of Autopsy: BIAP Mortuary
Baghdad Airport, Iraq

Circumstances of Death: This believed to be 61 year old male Iraqi civilian was a detainee of the U.S. Armed Forces at the Detention Central Collection Facility, Tikrit, Iraq when he was discovered deceased in his bed when he failed to report to the morning head count procedure. The decedent reported a medical history of diabetes and renal disease at the time of his capture.

Authorization for Autopsy: Office of the Armed Forces Medical Examiner, IAW 10 USC 1471.

Identification: Identification is established by visual examination by CID agents. DNA testing was performed and is on file for comparison should exemplars become available.

CAUSE OF DEATH: Atherosclerotic Cardiovascular Disease

MANNER OF DEATH: Natural

ACLU Detainee DeathII ARMY MEDCOM 191

FINAL AUTOPSY DIAGNOSES:

I. Atherosclerotic Cardiovascular Disease
   1. Moderate calcified atherosclerosis of the right coronary artery (50% stenosis), the left circumflex (50% stenosis) and left anterior descending branches of the left coronary artery (50-75% stenosis).
   2. Moderate aortic atherosclerosis with bilateral renal artery take-off stenosis.
   3. Bilateral renal atrophy with intraparenchymal arteriole atherosclerosis and marked arterionephrosclerosis and cortical cysts.
   4. Cranial artery atherosclerosis of the vertebral, basilar, posterior communicating and middle cerebral arteries.

II. Mild to moderate decomposition.

III. Toxicology is positive for ethanol, acetone, 1-propanol and acetaldehyde (urine only) in the blood and urine. Drugs of abuse were not detected.

ACLU Detainee DeathII ARMY MEDCOM 192

EXTERNAL EXAMINATION

The body is that of a cachetic male Iraqi national. The body weighs approximately 130 pounds, is 69 ½ inches in length and appears the reported age of 61 years. The body temperature is ambient. Rigor is present to an equal degree in all extremities. Lividity is difficult to assess because of dark skin pigmentation but is present and fixed on the posterior surface of the body, except in areas exposed to pressure. There is mild to moderate decomposition of the body with areas of skin slippage on the posterior scalp, the right wrist and anterior right lower leg and marbling of the skin of the back, buttocks, posterior surface of the arms and legs, palms of the hands and the abdomen.

The scalp hair is black and gray and the decedent has frontal baldness. Facial hair consists of a full gray and black beard and mustache. The irides are brown. The corneae are slightly cloudy. The conjunctivae are free of injuries and hemorrhages. The sclerae are free of hemorrhages. The external auditory canals, external nares and oral cavity are free of foreign material and abnormal secretions. The nasal septum and skeleton is palpably intact. The lips are without evident injury. The teeth are natural and poor condition with multiple unrepaired caries. Examination of the neck reveals no evidence of injury. The hyoid bone and thyroid cartilage are intact.

The chest is free of injuries and deformities. A 3.3 x 1.2 cm oval scar is on the anterior left costal margin and a 3.2 x 2.3 cm oval scar is in the left upper quadrant of the abdomen. No injury of the ribs or sternum is evident externally. The abdomen is flat and free of palpable masses. The external genitalia are those of a normal circumcised adult male with bilateral descended testes. The testes are free of palpable masses. The buttocks and anus are unremarkable.

The extremities show injuries that will be described below. The fingernails are intact. An 11.5 x 4.5 cm area and an area of 7.0 x 3.0 cm of non-descript black ink writing is on the medial surface and lateral surface of the left knee, respectively. There is a paper identification tag affixed to the right wrist and right second toe.

The back has a 2.5 x 2.0 cm scar immediately right of midline in the thoracic region and a 2.5 x 2.0 cm oval scar immediately below the scar just described.

CLOTHING AND PERSONAL EFFECTS

The following clothing items and personal effects are present on the body at the time of autopsy:
A blue shirt, a green sweater, a white linen undergarment, and two white socks.

MEDICAL INTERVENTION

There is no medical intervention.

RADIOGRAPHS

Full body postmortem radiographs are obtained and demonstrates the following:
1. No long bone fractures
2. No foreign bodies

ACLU Detainee DeathII ARMY MEDCOM 193

EVIDENCE OF INJURY

The ordering of the following injuries is for descriptive purposes only, and is not intended to imply order of infliction or relative severity. All wound pathways are given relative to standard anatomic position.

A 2.4 x 1.4 cm crusted abrasion and a 1.5 x 1.4 cm crusted abrasion are on the forehead. A 1.0 x 0.5 cm abrasion is on the nose.

On the volar surface of the right forearm are multiple oval purple contusions that average 1.0 cm in diameter. A 1.5 x 0.4 cm crusted abrasion and a 1.2 x 1.2 cm crusted abrasion are on the medial and the lateral surface of the left forearm, respectively.
On the posterior surface of the left hand are a 2.5 x 1.5 cm purple contusion and a 1.5 x 1.0 cm purple contusion. There is a 1.8 x 1.7 cm crusted abrasion with surrounding contusion on the lateral surface of the left knee and a 1.5 x 1.0 cm crusted abrasion immediately below the left patella.

Over the spinous processes of the lumbar spine is a 1.8 x 1.1 cm contusion.

INTERNAL EXAMINATION

HEAD:
The galeal and subgaleal soft tissues of the scalp are free of injury. The calvarium is intact, as is the dura mater beneath it. There is congestion and pooling of blood over the posterior aspect of the brain from livor mortis. Clear cerebrospinal fluid surrounds the 1325 gm brain, which has unremarkable gyri and sulci. The brain parenchyma is soft and pink/red from refrigeration. Coronal sections demonstrate sharp demarcation between white and grey matter, without hemorrhage or contusive injury. The ventricles are of normal size. The basal ganglia, brainstem, cerebellum, and arterial systems are free of injury or other abnormalities. There are no skull fractures. The atlanto-occipital joint is stable. There is atherosclerosis of the vertebral, basilar and middle cerebral arteries.

NECK:
The anterior strap muscles of the neck are homogenous and red-brown, without hemorrhage. The thyroid cartilage and hyoid bone are intact. The larynx is lined by intact gray/white mucosa. The thyroid gland is symmetric and red-brown, without cystic or nodular change. The tongue is free of bite marks, hemorrhage, or other injuries.

BODY CAVITIES:
The ribs, sternum, and vertebral bodies are visibly and palpably intact. 50 ml of serosanguineous fluid are in each hemithorax. No excess fluid is in the pericardial or peritoneal cavities. The organs occupy their usual anatomic positions.

RESPIRATORY SYSTEM:
The right and left lungs weigh 750 and 725 gm, respectively. The external surfaces are smooth and deep red-purple. The pulmonary parenchyma is diffusely congested and edematous. No mass lesions or areas of consolidation are present.

ACLU Detainee DeathII ARMY MEDCOM 194

CARDIOVASCULAR SYSTEM:
The 390 gm heart is contained in an intact pericardial sac. The epicardial surface is smooth, with minimal fat investment. The coronary arteries are present in a normal distribution, with a right-dominant pattern. Cross sections of the vessels show moderate calcified atherosclerosis of the right coronary artery (50% stenosis), the left circumflex (50% stenosis) and left anterior descending branch of the left coronary artery (50-75% stenosis). The myocardium is homogenous, red-brown, and firm. The valve leaflets are thin and mobile. The walls of the left and right ventricles are 1.3 and 0.4 cm thick, respectively. The endocardium is smooth and glistening. The aorta gives rise to three intact and patent arch vessels. The renal arteries have moderate stenosis of their origins at the aorta from aortic atherosclerosis. The mesenteric vessels are unremarkable.

LIVER & BILIARY SYSTEM:
The 1125 gm liver has an intact, smooth capsule and a sharp anterior border. The parenchyma is tan-brown and congested, with the usual lobular architecture. No mass lesions or other abnormalities are seen. The gallbladder contains about 4 ml of green-black bile and no stones. The gallbladder mucosal surface is green and velvety. The extrahepatic biliary tree is patent.

SPLEEN:
The 80 gm spleen has a smooth, intact, red-purple capsule. The parenchyma is maroon and congested, with distinct Malpighian corpuscles.

PANCREAS:
The pancreas is soft and yellow-tan, with the usual lobular architecture. No mass lesions or other abnormalities are seen.

ADRENALS:
The right and left adrenal glands are symmetric, with bright yellow cortices and grey medullae. No masses or areas of hemorrhage are identified.

GENITOURINARY SYSTEM:
The right and left kidneys weigh 55 and 60 gm, respectively. The external surfaces are coarsely granular with multiple renal cortical cysts, ranging from 0.3 –1.0 cm in diameter. The cut surfaces are dark red-tan and congested, with uniformly thick cortices and sharp corticomedullary junctions. There is marked intra-renal atherosclerosis of the arterioles of the renal parenchyma. The pelves are unremarkable and the ureters are normal in course and caliber. White bladder mucosa overlies an intact bladder wall. The bladder contains approximately 100 ml of cloudy yellow urine. The prostate is normal in size, with lobular, yellow-tan parenchyma. The seminal vesicles are unremarkable. The testes are free of mass lesions, contusions, or other abnormalities.

GASTROINTESTINAL TRACT:
The esophagus is intact and lined by smooth, grey-white mucosa. The stomach contains approximately 500 ml of brown fluid and rare food particles. The gastric wall is intact.

ACLU Detainee DeathII ARMY MEDCOM 195

The greater curve of the stomach is densely adherent to the duodenum. The duodenum, loops of small bowel, and colon are otherwise unremarkable. The appendix is present.

ADDITIONAL PROCEDURES

- Documentary photographs are taken by OAFME photographer.
- Specimens retained for toxicologic testing and/or DNA identification are: blood, urine, spleen, liver, lung, kidney, brain, bile, gastric contents, and psoas muscle.
- The dissected organs are forwarded with body.
- Personal effects are released to the appropriate mortuary operations representatives.

MICROSCOPIC EXAMINATION

Selected portions of organs are retained in formalin, without preparation of histologic slides.

ACLU Detainee DeathII ARMY MEDCOM 196

OPINION

This believed to be 61 year old Iraqi male died from atherosclerotic cardiovascular disease. The mechanism of death is often cardiac arrhythmia secondary to the diseased myocardium and conduction system. The presence of systemic atherosclerosis and the marked renal changes, including renal atrophy, is suggestive of the decedent having diabetes mellitus. The manner of death is natural.

(b)(6)

(b)(6) Medical Examiner

ACLU Detainee DeathII ARMY MEDCOM 197

DEPARTMENT OF DEFENSE
ARMED FORCES INSTITUTE OF PATHOLOGY
WASHINGTON, DC 20306-6000

REPLY TO ATTENTION OF

AFIP: (b)(6)

TO:

OFFICE OF THE ARMED FORCES MEDICAL EXAMINER
ARMED FORCES INSTITUTE OF PATHOLOGY
WASHINGTON, DC 20306-6000

PATIENT IDENTIFICATION
AFIP Accessions Number Sequence
(b)(6)
Name
AHMED, HASSAN EKAB

SSAN: **Autopsy:** (b)(6)
Toxicology Accession #: (b)(6)
Report Date: MARCH 15, 2004

CONSULTATION REPORT ON CONTRIBUTOR MATERIAL

AFIP DIAGNOSIS **REPORT OF TOXICOLOGICAL EXAMINATION**

Condition of Specimens: GOOD
Date of Incident: **Date Received:** 3/3/2004

CYANIDE: There was no cyanide detected in the chest blood. The limit of quantitation for cyanide is 0.25 mg/L. Normal blood cyanide concentrations are less than 0.15 mg/L. Lethal concentrations of cyanide are greater than 3 mg/L.

VOLATILES: The **BLOOD AND URINE** were examined for the presence of ethanol (cutoff of 20 mg/dL), acetaldehyde, acetone, 2-propanol, 1-propanol, t-butanol, 2-butanol, iso-butanol and 1-butanol by headspace gas chromatography. The following volatiles were detected: (concentration(s) in mg/dL)

	Acetaldehyde	Ethanol	Acetone	1-Propanol
BLOOD		69	Trace	Trace
URINE	Trace	31	Trace	6

Trace = value greater than or equal to 1mg/dL, but less than 5 mg/dL

DRUGS: The **BLOOD** was screened for amphetamine, antidepressants, antihistamines, barbiturates, benzodiazepines, cannabinoids, cocaine, dextromethorphan, lidocaine, narcotic analgesics, opiates, phencyclidine, phenothiazines, sympathomimetic amines and verapamil by gas chromatography, color test or immunoassay. The following drugs were detected:

None were found.

(b)(6)
Office of the Armed Forces Medical Examiner

(b)(6)
Office of the Armed Forces Medical Examiner

ACLU Detainee DeathII ARMY MEDCOM 198

ARMED FORCES INSTITUTE OF PATHOLOGY
Office of the Armed Forces Medical Examiner
1413 Research Blvd., Bldg. 102
Rockville, MD 20850
1-800-944-7912

FINAL AUTOPSY REPORT

Name: Ibrahim, Nasef J.
SSAN: N/A
Date of Birth: (b)(6) 1941
Date of Death (b)(6) 2004
Date of Autopsy: 11 JAN 2004
Date of Report: 18 FEB 2004

Autopsy No.: (b)(6)
AFIP No.: (b)(6)
Rank: Status Unknown
Place of Death: Abu Ghraib, Iraq
Place of Autopsy: BIAP Mortuary, Baghdad, Iraq

Circumstances of Death: Iraqi detainee died while in U.S. custody.

Authorization for Autopsy: Office of the Armed Forces Medical Examiner, IAW 10 USC 1471

Identification: Identification by accompanying paperwork and wristband, both of which include a photograph and identification number (b)(6)

CAUSE OF DEATH: Atherosclerotic Cardiovascular Disease Resulting in Cardiac Tamponade

MANNER OF DEATH: Natural

ACLU Detainee DeathII ARMY MEDCOM 199

FINAL AUTOPSY DIAGNOSES:

I. **Atherosclerotic Cardiovascular Disease**

- A. **Hemopericardium (650-milliliters)**
- B. **Rupture of the anterior wall of the left ventricle**
- C. **Acute myocardial infarction**
- D. **Atherosclerosis of the coronary arteries, focally severe**
- E. **Arterionephrosclerosis**
- F. **Mild atherosclerosis of the aorta**

II. **Pleural and Pulmonary Adhesions**

III. **Enlarged, Nodular Prostate Gland**

IV. **Toxicology is negative for ethanol, cyanide, and drugs of abuse**

ACLU Detainee DeathII ARMY MEDCOM 200

EXTERNAL EXAMINATION

The remains are received clad in a long brown outer garment, a blue vest, a white undershirt, khaki colored pants (outer), a white, pajama type pants. An identification bracelet that includes the decedent's name, photograph, and detaince number is on the left wrist.

The body is that of a well-developed, well-nourished appearing, 67-inches, 180-pounds (estimated) male, whose appearance is consistent with the reported age of 63-years. Lividity is posterior and fixed, except in areas exposed to pressure. Marked facial congestion is present. Rigor is passing. The body temperature is that of the refrigeration unit.

The scalp is covered with gray-black hair with male pattern balding. The corneae are moderately opaque. The irides are hazel and the pupils are round and equal in diameter. The external auditory canals are free of abnormal secretions and foreign material. The earlobes are creased. The nose and maxillae are palpably stable. The teeth are natural and in poor condition, with several teeth partially or totally missing. Facial hair consists of a gray beard and mustache.

The neck is mobile and the trachea is midline. The chest is symmetric. The abdomen is protuberant. The genitalia are those of a normal adult, circumcised, male. The testes are descended and free of masses. Pubic hair is present in a normal distribution. The buttocks and anus are unremarkable.

The upper and lower extremities are symmetric and without clubbing or edema. Severe dry dermatitis involves both feet. The fingernails are intact. A ½-inch acrochordon is on the posterior right thigh. A 1 ½-inch scar is on the posterior right forearm. No tattoos or other significant identifying marks are present.

MEDICAL INTERVENTION

There is no evidence of medical intervention on the body at the time of the autopsy.

EVIDENCE OF INJURY

There is no evidence of significant recent injury noted at the autopsy.

INTERNAL EXAMINATION

HEAD:

The brain weighs 1450-grams. There is no epidural, subdural, or subarachnoid hemorrhage. Coronal sections demonstrate sharp demarcation between white and gray matter, without mass or contusive injury. The ventricles are of normal size. The basal ganglia, brainstem, cerebellum, and arterial systems are free of abnormalities. There are no skull fractures. No evidence of non-traumatic disease processes is noted.

ACLU Detainee DeathII ARMY MEDCOM 201

NECK:
The thyroid cartilage and hyoid bone are intact. The larynx is lined by intact white mucosa. The thyroid gland is slightly enlarged, symmetric, and red-brown, without cystic or nodular change. The tongue is free of bite marks, hemorrhage, or other injuries.

BODY CAVITIES:
The ribs, sternum, and vertebral bodies are visibly and palpably intact. There is no abnormal accumulation of fluid in the pleural or peritoneal cavity. Scattered adhesions involve both lungs and the chest wall. The organs occupy their usual anatomic positions. The thickness of the subcutaneous adipose tissue over the abdomen is 1 ¼-inches.

RESPIRATORY SYSTEM:
The right and left lungs weigh 850 and 620-grams, respectively. The external surfaces are deep red-purple with marked anthracotic mottling. The pulmonary parenchyma is diffusely congested and edematous, without significant emphysematous changes. No mass lesions or areas of consolidation are present. The pulmonary arteries are unremarkable.

CARDIOVASCULAR SYSTEM:
The 410-gram heart is contained in an intact pericardial sac. There are 650-milliliters of clotted blood in the pericardial sac. The epicardial surface is smooth, with minimal fat investment. A 1-centimeter in length, slit-like, irregular defect goes through the entire thickness of the anterior wall of the left ventricle, near the interventricular septum. A rim of hemorrhage surrounds this defect. The coronary arteries are present in a normal distribution, with a right-dominant pattern. Cross sections of the vessels show near complete occlusion of the mid portion of the left anterior descending coronary artery by atherosclerosis. The other coronary arteries have only mild atherosclerotic narrowing, up to 20%. The myocardium has patchy fibrosis. The valve leaflets are thin and mobile. The walls of the left and right ventricles are 1.3 and 0.4-centimeters thick, respectively. The interventricular septum is 1.4-centimeters thick. The endocardium is smooth. The aorta gives rise to three intact and patent arch vessels and has mild atherosclerosis. The renal and mesenteric vessels are unremarkable.

LIVER & BILIARY SYSTEM:
The 1640-gram liver has an intact, smooth capsule and a sharp anterior border. The parenchyma is tan-brown and congested, with the usual lobular architecture. No mass lesions or other abnormalities are seen. The gallbladder contains 12-milliliters of green-black bile and no stones. The mucosal surface is green and velvety. The extrahepatic biliary tree is patent.

SPLEEN:
The 320-gram spleen has a smooth, intact, red-purple capsule. The parenchyma is slightly soft, maroon and congested.

ACLU Detainee DeathII ARMY MEDCOM 202

PANCREAS:
The pancreas is and yellow-tan, with the usual lobular architecture and changes of early autolysis. No mass lesions or other abnormalities are seen.

ADRENAL GLANDS:
The right and left adrenal glands are symmetric, with yellow cortices, gray medullae, and autolytic changes. No masses or areas of hemorrhage are identified.

GENITOURINARY SYSTEM:
The right and left kidneys weigh 190 and 175-grams, respectively. The external surfaces are intact with numerous pits, scars, and the characteristic "flea-bitten" appearance associated with poorly controlled hypertension. A 4-centimeter simple cyst is within the cortex of the right kidney. The cut surfaces are red-tan and congested, with blunted corticomedullary junctions. The pelves are unremarkable and the ureters are normal in course and caliber. White bladder mucosa overlies an intact bladder wall. The urinary bladder contains 50-milliliters of dark yellow urine. The prostate gland is moderately enlarged, with lobular, yellow-tan parenchyma. The seminal vesicles are unremarkable. The testes are free of mass lesions, contusions, or other abnormalities.

GASTROINTESTINAL TRACT:
The esophagus is intact and lined by smooth, grey-white mucosa. The stomach contains approximately 40-milliliters of dark tan fluid and partially digested food. The gastric wall is intact. The duodenum, loops of small bowel, and colon are unremarkable. The appendix is present.

MUSCULOSKELETAL:
No non-traumatic abnormalities of muscle or bone are identified.

ADDITIONAL PROCEDURES

- Documentary photographs are taken by OAFME photographer (b)(6) USN
- Specimens retained for toxicologic testing and/or DNA identification are: vitreous fluid, cavity blood, bile, spleen, liver, lung, brain, kidney, urine, gastric contents, and psoas muscle
- The dissected organs are forwarded with body
- Personal effects and clothing are released to the mortuary personnel

MICROSCOPIC EXAMINATION

Selected portions of organs are retained in formalin, without preparation of histologic slides.

ACLU Detainee DeathII ARMY MEDCOM 203

OPINION

This 63-year-old male (b)(6) died as a result of atherosclerotic cardiovascular disease resulting in cardiac tamponade. The autopsy revealed hemopericardium, with a rupture of the free wall of the left ventricle and focally severe atherosclerosis of the coronary arteries. Toxicologic studies were negative for ethanol, cyanide, and drugs of abuse. The manner of death is natural.

(b)(6)

(b)(6) **Medical Examiner**

(b)(6)

ACLU Detainee DeathII ARMY MEDCOM 204

DEPARTMENT OF DEFENSE
ARMED FORCES INSTITUTE OF PATHOLOGY
WASHINGTON, DC 20306-6000

REPLY TO ATTENTION OF

AFIP-(b)(6)

TO:

OFFICE OF THE ARMED FORCES MEDICAL EXAMINER
ARMED FORCES INSTITUTE OF PATHOLOGY
WASHINGTON, DC 20306-6000

PATIENT IDENTIFICATION
AFIP Accessions Number Sequence
(b)(6)
Name
IBRAHIM, NASEF J.
SSAN: Autopsy (b)(6)
Toxicology Accession #: (b)(6)
Report Date: APRIL 6, 2004

CONSULTATION REPORT ON CONTRIBUTOR MATERIAL
AMENDED REPORT

AFIP DIAGNOSIS REPORT OF TOXICOLOGICAL EXAMINATION

Condition of Specimens: GOOD
Date of Incident: (b)(6) 2004 **Date Received:** 1/15/2004

VOLATILES: The **CAVITY BLOOD AND VITREOUS FLUID** were examined for the presence of ethanol at a cutoff of 20 mg/dL. No ethanol was detected.

CYANIDE: There was no cyanide detected in the blood. The limit of quantitation for cyanide is 0.25 mg/L. Normal blood cyanide concentrations are less than 0.15 mg/L. Lethal concentrations of cyanide are greater than 3 mg/L.

DRUGS: The **BLOOD** was screened for amphetamine, antidepressants, antihistamines, barbiturates, benzodiazepines, cannabinoids, cocaine, dextromethorphan, lidocaine, narcotic analgesics, opiates, phencyclidine, phenothiazines, sympathomimetic amines and verapamil by gas chromatography, color test or immunoassay. The following drugs were detected:

None were found.

(b)(6)
Office of the Armed Forces Medical Examiner

(b)(6)
Office of the Armed Forces Medical Examiner

ACLU Detainee DeathII ARMY MEDCOM 205

ARMED FORCES INSTITUTE OF PATHOLOGY
Office of the Armed Forces Medical Examiner
1413 Research Blvd., Bldg. 102
Rockville, MD 20850
1-301-319-0000

FINAL AUTOPSY EXAMINATION REPORT

Name: BTB RAKAD, Hassan Hadan
ISN: (b)(6)
Date of Birth: BTB (b)(6) 1931
Date of Death: (b)(6) 2005
Date/Time of Autopsy: 22 DEC 2005 @ 1200
Date of Report: 20 JUL 2006

Autopsy No.: (b)(6)
AFIP No.: (b)(6)
Rank: Iraqi Civilian Detainee
Place of Death: Abu Ghraib, Iraq
Place of Autopsy: Port Mortuary, Dover AFB, DE

Circumstances of Death: This 74-year-old Iraqi civilian male detainee was hospitalized for a non-reducible right inguinal hernia on 18 NOV 2005. Surgery was performed, and a long hospital course ensued with numerous complications that required ventilator support and blood transfusions. The patient has a remote history of mitral valve replacement with an artificial valve. In the final two days of his hospital course, the patient had a number of cardiac arrests where Advanced Cardiac Life Support protocols were performed. He expired on (b)(6) 2005 at 1820.

Authorization for Autopsy: Office of the Armed Forces Medical Examiner, IAW 10 USC 1471.

Identification: Presumptive identification is established based on identification bracelets and ISN. Fingerprints and DNA were taken to compare to exemplars when available.

CAUSE OF DEATH: **SEPSIS DUE TO BILATERAL LOBAR PNEUMONIA DUE TO RECENT INGUINAL HERNIA SURGERY**

MANNER OF DEATH: **NATURAL**

FINAL AUTOPSY DIAGNOSES:

I. Complications of Right Inguinal Hernia Repair

A. Bilateral lobar pneumonia
   1. Right lung weight 1,190-grams
      a. Complete consolidation
      b. Multiple abscesses in the inferior lower lobe of the right lung
   2. Left lung weight 1,270-grams, completely consolidated
   3. See attached Pulmonary Pathology consultation addendum (1) for complete details

B. Multiple punctate abscesses of both kidneys, ranging in size from 0.1-centimeters to 0.4-centimeters

C. Anasarca

D. Cerebral edema (brain weight 1,460-grams) without evidence of herniation

II. Other Natural Disease

A. Cardiovascular disease
   1. Cardiomegaly (heart weight 610-grams) with interstitial and patchy replacement fibrosis
   2. Remote history of mitral valve replacement (28-millimeter Medtronic-Hall prosthesis) and associated diffuse pulmonary dendriform ossification
   3. Focal moderate coronary atherosclerosis with calcification
   4. See attached Cardiovascular Pathology consultation addendum (2) for complete details

B. Left adrenal adenoma (bright yellow, 5.3 x 3.9-centimeters)

C. Right renal cortical cyst (1.5 x 1.2-centimeters)

D. Coarsely granular cortex of both kidneys

E. Moderate aortic atherosclerosis with focal ulceration in the abdominal aorta

F. Cholelithiasis (1.3-centimeter black calculi)

III. Evidence of Medical Therapy

A. Endotracheal tube (appropriately placed)

B. Left nasogastric tube (appropriately placed)

C. Right and left chest tubes in the 3rd intercostal spaces, mid-axillary line

D. Urinary bladder catheter

E. Triple-lumen intravenous line in the right subclavian region

F. Recent right inguinal surgical incision (stapled closed, 11.0 x 0.6-centimeters)

G. Electrocardiogram electrodes on the anterior torso

H. Multiple ecchymoses with central needle-stick marks on the abdomen

I. Fracture of the sternum at the level of the anterior 3rd ribs (resuscitation-related)

J. Fractures of the 4th through 6th anterior right ribs and the 2nd through 7th anterior left ribs (resuscitation-related)

K. Right radial arterial line

ACLU Detainee DeathII ARMY MEDCOM 207

IV. Toxicology

A. The blood and vitreous fluid are tested for ethanol and none is found.

B. The blood is screened for medications and drugs of abuse, and the following medications are found:

1. The blood contains 0.43 milligrams per liter of Diphenhydramine
2. The blood contains 1.3 milligrams per liter of Ephedrine

EXTERNAL EXAMINATION

The body is that of a well-developed, well-nourished appearing, 63-inch, and 174-pound male whose appearance is consistent with the reported age of 74 years. Lividity is fixed and posterior. Rigor is equal in all extremities and the temperature is that of the refrigeration unit.

The scalp is covered with gray-black hair in a normal distribution. The irides are brown and the pupils are round and equal in diameter. The external auditory canals are free of abnormal secretions and debris. The ears are unremarkable. The nares are patent and the lips are atraumatic. The nose and maxillae are palpably stable. The teeth appear natural and in fair condition.

The neck is straight, and the trachea is midline and mobile. The chest is symmetric with a well healed, 10 ½-inch, linear midline sternotomy incision. The lower back is remarkable for a 2 ½ x 2 ½-inch decubitis ulcer with a dressing. The abdomen is flat and atraumatic. Multiple ecchymoses with central needle-stick marks are present on the abdomen. There is a recent right inguinal surgical incision, 11.0 x 0.6-centimeters, which is stapled closed and without signs of drainage or infection. The genitalia are those of a normal adult male. The testes are descended and free of masses. A 2 x ¼-inch area of ulceration is present on the posterior scrotum. Pubic hair is present in a normal distribution. The buttocks and anus are unremarkable.

The upper and lower extremities are symmetric and without clubbing. Anasarca is present. There are three areas of ecchymosis on the posterior left lower extremity that range in size from 2 x1-inch to 4 ½ x 2-inches. There is a 2-inch linear scar on the medial right leg and a 1-inch puckered scar on the posterior lower left leg.

CLOTHING AND PERSONAL EFFECTS

The following clothing items and personal effects are present on the body at the time of autopsy:

- Hospital gown only

MEDICAL INTERVENTION

- Endotracheal tube (appropriately placed)
- Left nasogastric tube (appropriately placed)

ACLU Detainee DeathII ARMY MEDCOM 208

- Right and left chest tubes in the 3rd intercostal spaces, mid-axillary line
- Urinary bladder catheter
- Triple-lumen intravenous line in the right subclavian region
- Right radial arterial line
- Recent right inguinal surgical incision (stapled closed, 11.0 x 0.6-centimeters)
- Electrocardiogram electrodes on the anterior torso
- Multiple ecchymoses with central needle-stick mark on the abdomen
- Fracture of the sternum at the level of the anterior 3rd ribs (resuscitation-related)
- Fractures of the 4th through 6th anterior right ribs and the 2nd through 7th anterior left ribs (resuscitation-related)

RADIOGRAPHS

A complete set of postmortem radiographs is obtained and demonstrates the following:

- No long bone fractures are noted
- No metallic foreign bodies are noted (except medical devices)
- Anterior rib and sternal fractures (resuscitation-related)
- Sternal wires (remote sternotomy)
- Gallstone
- Pneumoperitoneum (secondary to recent surgery)
- Prosthetic mitral valve (remote repair)

EVIDENCE OF INJURY

There is no evidence of significant recent injury.

INTERNAL EXAMINATION

HEAD:
The galeal and subgaleal soft tissues of the scalp are free of injury. The calvarium is intact, as is the dura mater beneath it. Clear cerebrospinal fluid surrounds the 1,460-gram brain, which has slightly widened gyri and narrowed sulci, without evidence of uncal or tonsillar notching. Coronal sections demonstrate sharp demarcation between white and grey matter, without hemorrhage or contusive injury. The ventricles are of normal size. The basal ganglia, brainstem, cerebellum, and arterial systems are free of injury or other abnormalities. There are no skull fractures. The atlanto-occipital joint is stable.

NECK:
The anterior strap muscles of the neck are homogenous and red-brown, without hemorrhage. The thyroid cartilage and hyoid bone are intact. The larynx is lined by intact white mucosa. The thyroid gland is symmetric and red-brown, without cystic or nodular change. The tongue is free of bite marks, hemorrhage, or other injuries.

ACLU Detainee DeathII ARMY MEDCOM 209

BODY CAVITIES:
The vertebral bodies are visibly and palpably intact. The sternum is fractured at the level of the 3rd ribs, and has a remote midline sternotomy, with wires in place. The 4th through 6th anterior right ribs and the 2nd through 7th anterior left ribs are fractured. No excess fluid is in the pleural, pericardial, or peritoneal cavities. The organs occupy their usual anatomic positions.

RESPIRATORY SYSTEM:
The right and left lungs weigh 1,190 and 1,270-grams, respectively. The external surfaces are rough and deep red-purple. The pulmonary parenchyma is congested and edematous with diffuse calcifications. The right lung is consolidated, and multiple abscesses are noted in the inferior portion of the lower lobe. The left lung is completely consolidated. Representative microscopic sections are submitted for Pulmonary Pathology consultation (see Addendum 1 for complete details).

CARDIOVASCULAR SYSTEM:
The heart and pericardial sac weigh 610-grams and are entirely submitted for Cardiovascular Pathology consultation (see Addendum 2 for complete details). The aorta has moderate atherosclerosis with focal ulceration and gives rise to three intact and patent arch vessels. The renal and mesenteric vessels are unremarkable.

LIVER & BILIARY SYSTEM:
The 1,660-gram liver has an intact, smooth capsule and a sharp anterior border. The parenchyma is tan-brown and congested, with the usual lobular architecture. No mass lesions or other abnormalities are seen. The gallbladder contains a minute amount of green-black bile and a single 13-millimeter black-green gallstone. The mucosal surface is green and velvety. The extrahepatic biliary tree is patent.

SPLEEN:
The 420-gram spleen has a smooth, intact, red-purple capsule. The parenchyma is maroon and congested, with distinct Malpighian corpuscles.

PANCREAS:
The pancreas is firm and yellow-tan, with the usual lobular architecture. No mass lesions or other abnormalities are seen.

ADRENALS:
The right adrenal gland is autolyzed, with bright yellow cortices and grey medullae. No masses or areas of hemorrhage are identified. The left adrenal gland contains a 5.3 x 3.9-centimeter, well-circumscribed, bright yellow mass.

GENITOURINARY SYSTEM:
The right and left kidneys weigh 180 and 170-grams, respectively. The external surfaces are intact and coarsely pitted bilaterally. There are multiple, soft, yellow, punctate abscesses on the cortical surfaces of both kidneys which range in size from 0.1-

ACLU Detainee DeathII ARMY MEDCOM 210

centimeters to 0.4-centimeters. The cut surfaces are red-tan and congested, with uniformly thick cortices and sharp corticomedullary junctions. The right kidney contains a 1.5 x 1.2-centimeter, smooth-walled simple cyst. The pelves are unremarkable and the ureters are normal in course and caliber. Pink-grey bladder mucosa overlies an intact bladder wall. The bladder contains no urine. The prostate is normal in size, with lobular, yellow-tan parenchyma. The seminal vesicles are unremarkable. The testes are free of mass lesions, contusions, or other abnormalities.

GASTROINTESTINAL TRACT:
The esophagus is intact and lined by smooth, grey-white mucosa. The stomach contains no fluid; the gastric wall is intact. The duodenum, loops of small bowel and colon are unremarkable. The appendix is present.

MUSCULOSKELTAL SYSTEM:
There are no non-traumatic bone or joint abnormalities. Skeletal muscle development is normal.

MICROSCOPIC EXAMINATION

Portions of organs are retained in formalin, with preparation of selected histological slides.

LUNGS:

See the attached Pulmonary Pathology consultation Addendum (1) for complete details

HEART:

See the attached Cardiovascular Pathology consultation Addendum (2) for complete details.

SPLEEN:
No pathologic diagnosis.

LIVER:
Passive congestion is present, without hepatocyte necrosis.

SPERMATIC CORD:
Fibrosis and edema are noted. The vas deferens is normal.

SCROTAL SKIN:
Skin with granulation tissue is present; no abscess is noted.

LEFT ADRENAL GLAND:
A uniform population of benign-appearing cells is present, consistent with adrenal adenoma.

ACLU Detainee DeathII ARMY MEDCOM 211

ADDITIONAL PROCEDURES/REMARKS

- Documentary photographs are taken by AFMES staff photographers
- Specimens retained for toxicologic testing and/or DNA identification are: peripheral blood, vitreous fluid, gastric contents, bile, spleen, liver, lung, kidney, brain, adipose tissue, and psoas muscle
- The body is sutured closed without embalming, and the dissected organs are forwarded with the body
- No personal effects are present
- The following identifying body marks are present: Midline sternotomy scar (well-healed, 10 ½-inches), scar on the posterior left leg (puckered, 1-inch), scar on the anterior right leg (well-healed, 2-inches)

OPINION

This 74-year-old male, (BTB) (b)(6) died of sepsis due to bilateral lobar pneumonia due to recent inguinal hernia surgery. There was significant pre-existing cardiovascular disease to include a prior mitral valve replacement, moderate coronary artery disease and left ventricular hypertrophy due to hypertension. There was also pre-existing diffuse pulmonary dendriform ossification of both lungs, which was due to the prosthetic mitral valve. These pre-existing conditions likely contributed to the decedent's death. Toxicological testing was negative for ethanol and drugs of abuse. Ephedrine (a sympathetic stimulant) and Diphenhydramine (an antihistamine) were present in the blood at therapeutic levels. The manner of death is natural.

(b)(6)

(b)(6) Medical Examiner

(b)(6)

(b)(6) Medical Examiner

ACLU Detainee DeathII ARMY MEDCOM 212

ADDENDUM 1

Pulmonary Pathology Consultation:

USE INK OR BALL-POINT PEN ONLY 11 H&E SLIDES, 11 BLOCKS (b)(6)

CONSULTATIONS

AFIP ACCESSION NUMBER: (b)(6)

THIS IS A PERMANENT PART OF THE RECORD AND IS NOT TO BE REMOVED FROM THE FOLDER

PLEASE CIRCULATE AMONG THE FOLLOWING OFFICERS ---------> AND THEN RETURN TO THE REVIEWING OFFICER ----> Pulmonary Path

MEMO FROM REVIEWING OFFICER:
PLEASE SEE ATTACHED PAD
74 yo male with long hospital course, sepsis, pneumonia and MOSF. Lung sections show DAD and dystrophic calc. Please read and comment 15 May 06 (b)(6)
(DATE) (REVIEWING OFFICER)

DATE

22 May 06
- Acute and organizing diffuse alveolar damage
- Acute bronchopneumonia c abscess formation
- Pulmonary infarcts c thrombus formation
- Dendriform (racemose) ossification.

There is acute and organizing DAD, which can have a multitude of causes such as; Shock, toxic inhalation, drug, infection etc. The bronchopneumonia is probably 2° as are the infarctions. Dendriform ossification is usually seen in old women and is associated c fibrosis, bronchiectasis, amyloidosis as well as is likely in this case, c mitral stenosis.

(b)(6)

AFIP FORM 45 (20 JUN 79) PREVIOUS EDITIONS ARE OBSOLETE

MEDCOM 0213
ACLU Detainee Deathll ARMY MEDCOM 213

ADDENDUM 2

Cardiovascular Pathology Consultation:

PATIENT IDENTIFICATION
CAP (b)(6)
BTB (b)(6)
ME (b)(6) (b)(6)
May 1, 2006

REPLY TO ATTENTION OF
(b)(6)
1413 Research Blvd. Bldg. 102
Rockville, MD 20850

FINAL DIAGNOSIS

DIAGNOSIS: (b)(6) **Heart, post mortem examination:**

1. **Cardiomegaly (610 grams) with interstitial and patchy replacement fibrosis, left ventricle**
2. **Focal moderate coronary atherosclerosis with calcification**
3. **Status post 28 mm Medtronic-Hall mitral valve prosthesis**

History: 74-year-old Iraqi civilian male detainee hospitalized for a non-reducible right inguinal hernia, status post surgical repair with protracted hospital course and numerous complications including pneumonia; remote history of mitral valve replacement; subject expired secondary to sepsi(b)(6) 2005.

Heart: 610 grams; dense epicardial adhesions; closed foramen ovale, with adjacent sutures; oversewn right atrial appendage; concentric left ventricular hypertrophy: left ventricular cavity diameter 35 mm, left ventricular free wall thickness 17 mm, ventricular septum thickness 16 mm, right ventricle thickness 5 mm; 28 mm diameter Medtronic-Hall tilting disc mechanical prosthetic valve in mitral position, sutures intact, disc moves freely, no vegetations, leaks or other grossly evident structural defects; other valves and endocardium grossly unremarkable; no myocardial necrosis; posterior wall left ventricle shows focal scar; histologic sections show myocyte hypertrophy with subendocardial and perivascular interstitial fibrosis and patchy replacement fibrosis, lateral and posterior walls of left ventricle

Coronary arteries: Normal ostia; right dominance; moderate coronary atherosclerosis with calcification
Left anterior descending artery (LAD): 60% narrowing of mid LAD by fibrocalcific plaque
Right coronary artery (RCA): 40% narrowing of proximal RCA by fibrocalcific plaque

(b)(6)
Staff pathologist

Blocks made: 7 (5 heart, 2 coronary arteries)
Slides made: 9 (7H&E, 2 Movat)

ACLU Detainee DeathII ARMY MEDCOM 214

CERTIFICATE OF DEATH *(OVERSEAS)*
Acte dé décès (D'Outre-Mer)

NAME OF DECEASED *(Last, First, Middle)* Nom du décédé (Nom et prénoms)	GRADE Grade	BRANCH OF SERVICE Arme	SOCIAL SECURITY NUMBER Numéro de l'Assurance Sociale
BTB Rakad, Hassan, Hadan		Civilian	(b)(6)
ORGANIZATION Organisation	NATION *(e.g. United States)* Pays: Iraq	DATE OF BIRTH Date de naissance: (b)(6) 1931	SEX Sexe: [X] MALE [ ] FEMALE

RACE Raka		MARITAL STATUS Etat Civil			RELIGION Culte		
	CAUCASOID Caucasique		SINGLE Célibataire		DIVORCED Divorcé		PROTESTANT Protestant
	NEGROID Negriade		MARRIED Marié		SEPARATED Séparé		CATHOLIC Catholique
X	OTHER (Specify) Autre (Spécifier)		WIDOWED Veuf				JEWISH Juif
						X	OTHER (Specify) Autre (Spécifier)

NAME OF NEXT OF KIN Nom du plus proche parent	RELATIONSHIP TO DECEASED Parenté du décédé avec le sus
STREET ADDRESS Domicilié à (Rue)	CITY OR TOWN OR STATE *(Include Zip Code)* Ville (Code postal compris)

MEDICAL STATEMENT Déclaration médicale

CAUSE OF DEATH (Enter only one cause per line) Cause du décès (N'indiquer qu'une cause par ligne)		INTERVAL BETWEEN ONSET AND DEATH Intervalle entre l'attaque et le décès
DISEASE OR CONDITON DIRECTLY LEADING TO DEATH[1] Maladie ou condition directement responsable de la mort[1]	Sepsis due to bilateral lobar preumonia due to recent inguinal hernia repair	Days
ANTECEDENT CAUSES Symptômes précurseurs de la mort. — MORBID CONDITION, IF ANY, LEADING TO PRIMARY CAUSE Condition morbide, s'il y a lieu, menant à la cause primaire		
UNDERLYING CAUSE, IF ANY, GIVING RISE TO PRIMARY CAUSE Condition morbide, s'il y a lieu, menant à la cause primaire		
OTHER SIGNIFICANT CONDITIONS[2] Autres conditions significatives[2]		

MODE OF DEATH Condition de décès	AUTOPSY PERFORMED Autopsie effectuée [X] YES Oui [ ] NO Non	CIRCUMSTANCES SURROUNDING DEATH DUE TO EXTERNAL CAUSES Circonstances de la mort suscitées par des causes extérieures
X NATURAL Mort naturelle	MAJOR FINDINGS OF AUTOPSY Conclusions principales de l'autopsie	
ACCIDENT Mort accidentelle		
SUICIDE Suicide	NAME OF PATHOLOGIST Nom du pathologiste: (b)(6)	
HOMICIDE Homicide	(b)(6)	DATE Date: 22 December 2005
		AVIATION ACCIDENT Accident à Avion: [ ] YES Oui [X] NO Non

DATE OF DEATH (day, m... Date de décès ... jour, ...): (b)(6) 2005

I HAVE VIEWED THE REMAINS OF THE DECEASED AND DEATH OCCURRED AT THE TIME INDICATED AND FROM THE CAUSES AS STATED ABOVE.
J'ai examiné les restes mortels du dé funtel je conclus que le décès est survenu à l'heure indiquée et à la suite des causes énumérées ci-dessus.

NAME OF MEDICAL OFFICER Nom du médecin militaire ou du médecin sanitaire	TITLE OR DEGREE Titre ou diplômé
(b)(6)	Medical Examiner

GRADE Grade	INSTALLATION OR ADDRESS Installation ou adresse
(b)(6)	Dover AFB, Dover DE

DATE Date	
22DEC2005	(b)(6)

1 Terme disease, injury or constitution which ...
2 State conditions contributing to the death, but not related ...
3 Préciser la nature de la maladie, de la blessure ou de la ... tels qu'un arrêt du coeur, etc.
4 Préciser la condition qui a contribué à la mort, mais n'ayant aucun rapport avec la maladie ou à la condition qui a provoqué la mort.

DD FORM 1 APR 77 2064 REPLACES DA FORM 3565, 1 JAN 72 AND DA FORM 3565-R(PAS), 20 SEP 75, WHICH ARE OBSOLETE.

(REMOVE, REVERSE AND RE-INSERT CARBONS BEFORE COMPLETING THIS SIDE)

DISPOSITON OF REMAINS

NAME OF MORTICIAN PREPARING REMAINS	GRADE	LICENSE NUMBER AND STATE	OTHER

INSTALLATION OR ADDRESS	DATE	SIGNATURE

NAME OF CEMETERY OR CREMATORY	LOCATION OF CEMETERY OR CREMATORY

TYPE OF DISPOSITION	DATE OF DISPOSITION

REGISTRATION OF VITAL STATISTICS

REGISTRY *(Town and County)*	DATE REGISTERED	FILE NUMBER	
		STATE	OTHER

NAME OF FUNERAL DIRECTOR	ADDRESS

SIGNATURE OF AUTHORIZED INDIVIDUAL

DD FORM 2064, APR 1977 (BACK) *USAPA V1.00*

ACLU Detainee DeathII ARMY MEDCOM 216

ARMED FORCES INSTITUTE OF PATHOLOGY
Office of the Armed Forces Medical Examiner
1413 Research Blvd., Bldg. 102
Rockville, MD 20850
1-301-319-0000

FINAL AUTOPSY EXAMINATION REPORT

Name: (BTB) AL-ZUBAYDI, Muhammed Hamza
ISN: (b)(6)
Date of Birth: (BTB) (b)(6) 1938
Date of Death: (b)(6) 2005
Date/Time of Autopsy: 09 DEC 2005 @ 1200
Date of Report: 23 JUN 2006

Autopsy No.: (b)(6)
AFIP No. (b)(6)
Rank: Civilian Detainee
Place of Death: Abu Ghraib, Iraq
Place of Autopsy: Port Mortuary
Dover AFB, DE

Circumstances of Death: This 67-year-old Iraqi civilian detainee was admitted to the hospital on 20 NOV 2005 with chest pain and in respiratory distress. He was by report in heart failure, and on (b)(6) 2005 suffered a cardiac arrest. Advanced Cardiac Life Support was provided to no avail.

Authorization for Autopsy: Office of the Armed Forces Medical Examiner, IAW 10 USC 1471.

Identification: Presumptive identification is established by comparison of antemortem records and identification bands. A complete postmortem fingerprint examination was conducted and can be used to establish positive identification should exemplars become available.

CAUSE OF DEATH: **HYPERTENSIVE ATHERSCLEROTIC CARDIOVASCULAR DISEASE**

MANNER OF DEATH: **NATURAL**

ACLU Detainee DeathII ARMY MEDCOM 217

FINAL AUTOPSY DIAGNOSES

I. Hypertensive Atherosclerotic Cardiovascular Disease

A. Cardiomegaly (heart weight 560-grams; 358-grams to 438-grams expected for a body weight of 199-pounds) with biventricular dilated hypertrophy
B. Remote coronary artery bypass surgery with patent mammary artery graft to mid left anterior descending coronary artery
C. Severe aortic atherosclerosis with focally heavy calcification and ulceration
D. Severe coronary atherosclerosis with calcification, three vessel disease
E. Healed transmural infarction, posterior and septal left ventricle
F. Tricuspid regurgitation
G. Renal pitting and petechiae with arteriolosclerosis bilaterally

II. Other Natural Disease

A. Congestion of the lungs bilaterally (right lung weight 1040-grams, left lung weight 600-grams)
B. Bilateral pleural adhesions
C. Bilateral pleural effusions (right 400-milliliters, left 525-milliliters)
D. Microscopic evidence of pulmonary hypertension, including thickened pulmonary vasculature and interstitial fibrosis
E. Diffuse alveolar damage
F. Enlarged prostate gland with associated muscular hypertrophy of the bladder
G. Incidental nephrogenic rest
H. Passive central congestion of the liver with associated mild portal inflammation
I. Right adrenal myelolipoma
J. Smooth muscle tumor of uncertain malignant potential of the stomach

III. Other findings:

A. No internal or external evidence of recent trauma to head, trunk or extremities identified by complete autopsy and total body x-ray studies
B. No injuries of the neck identified (layer-by layer dissection of the neck performed)

IV. Early Changes of Decomposition

V. Evidence of Medical Therapy

A. Properly located endotracheal tube
B. Left nasogastric tube is in place
C. Triple-lumen balloon-tip catheter is in the left jugular vein
D. Right radial arterial line
E. Needle-stick marks are in the antecubital fosse bilaterally and in the right neck
F. Defibrillator abrasion is on the anterior right torso

IV. Toxicology

A. The blood and vitreous fluid are tested for ethanol and none is found

ACLU Detainee DeathII ARMY MEDCOM 218

B. The blood is tested for carbon monoxide and the level is less than 1%
C. The blood is tested for cyanide and none is found
D. The blood is screened for drugs of abuse and none are found

EXTERNAL EXAMINATION

The body is that of a well-developed, well-nourished appearing, 69 ½-inches, 199-pound obese white male whose appearance is consistent with the reported age of 67 years. Lividity is posterior and fixed. Rigor is equal in all extremities, and the temperature of the body is that of the refrigeration unit.

The scalp is covered with short gray hair, in a male-pattern baldness distribution. The irides are hazel, and the pupils are round and equal in diameter. There are no conjunctival petechiae. The external auditory canals are patent and clear. The ears are unremarkable. The nares are patent and the lips are atraumatic. The nose and maxillae are palpably stable. The teeth appear natural.

The neck is straight, and the trachea is midline and mobile. The chest is symmetric. There is a 7 ½-inch midline sternotomy scar. The abdomen is flat. There is a 13-inch surgical scar in the left inguinal region. The genitalia are those of a normal adult circumcised male. The testes are descended and free of masses. Pubic hair is present in a normal distribution. The buttocks and anus are unremarkable.

The upper and lower extremities are symmetric and without clubbing. Generalized edema and focal ecchymoses that are associated with medical therapy are present. Early changes of decomposition are present and evidenced by skin slippage on the lower back, posterior right arm and the scalp on the back of the head.

CLOTHING AND PERSONAL EFFECTS

The body is received nude, and no person effects accompany the remains.

MEDICAL INTERVENTION

G. There is a properly located endotracheal tube
H. A left nasogastric tube is in place
I. A triple-lumen balloon-tip catheter is in the left jugular vein
J. There is a right radial arterial line
K. Needle-stick marks are in the antecubital fosse bilaterally and in the right neck
L. A defibrillator abrasion is on the anterior right torso

RADIOGRAPHS

A complete set of postmortem radiographs is obtained and demonstrates the following:

- No skeletal trauma is identified

ACLU Detainee DeathII ARMY MEDCOM 219

- No metallic foreign bodies are identified

EVIDENCE OF INJURY

There is no evidence of recent trauma.

INTERNAL EXAMINATION

HEAD:
The galeal and subgaleal soft tissues of the scalp are free of injury. The calvarium is intact, as is the dura mater beneath it. Clear cerebrospinal fluid surrounds the 1,340-gram brain, which has unremarkable gyri and sulci. Coronal sections demonstrate sharp demarcation between white and grey matter, without hemorrhage or contusive injury. The ventricles are of normal size. The basal ganglia, brainstem, cerebellum, and arterial systems are free of injury or other abnormalities. There are no skull fractures. The atlanto-occipital joint is stable.

NECK:
The anterior strap muscles of the neck are homogenous and red-brown, without hemorrhage, as demonstrated by layer-wise dissection. The thyroid cartilage and hyoid bone are intact. The larynx is lined by intact white mucosa. The thyroid gland is symmetric and red-brown, without cystic or nodular change. The tongue is free of bite marks, hemorrhage, or other injuries.

BODY CAVITIES:
The ribs, sternum, and vertebral bodies are visibly and palpably intact. No excess fluid is in the pericardial or peritoneal cavities. The right pleural cavity contains 400-milliliters of serosanguinous fluid and the left pleural cavity contains 525-milliliters of serosanguinous fluid. There are pleural adhesions bilaterally. The pericardium is intact and is tightly adhered to the heart. The organs occupy their usual anatomic positions.

RESPIRATORY SYSTEM:
The right and left lungs weigh 1,040 and 600-grams, respectively. The external surfaces are roughened and deep red-purple. The pulmonary parenchyma is diffusely congested and edematous. The lower lobe of the left lung is consolidated. No mass lesions are identified in either lung.

CARDIOVASCULAR SYSTEM:
The 730-gram heart is contained in an intact pericardial sac. There is evidence of remote cardiac surgery, and the heart is submitted for Cardiovascular Pathology consultation (Addendum 1).

The aorta gives rise to three intact and patent arch vessels. Severe atherosclerosis with heavy calcification and ulceration is present along the entire length of the aorta. Atherosclerosis is also present in the renal and mesenteric vessels.

ACLU Detainee DeathII ARMY MEDCOM 220

LIVER & BILIARY SYSTEM:
The 2,250-gram liver has an intact, smooth capsule and a sharp anterior border. The parenchyma is tan-brown and congested, with the usual lobular architecture. No mass lesions or other abnormalities are seen. The gallbladder contains a minute amount of green-black bile and no stones. The mucosal surface is green and velvety. The extrahepatic biliary tree is patent.

SPLEEN:
The 210-gram spleen has a smooth, intact, red-purple capsule. The parenchyma is maroon and congested, with distinct Malpighian corpuscles.

PANCREAS:
The pancreas is firm and yellow-tan, with the usual lobular architecture. No mass lesions or other abnormalities are seen.

ADRENALS:
The left adrenal gland has a bright yellow cortices and grey medullae. The right adrenal gland is enlarged (2.0 x 2.0-centimeters), and is yellow and had yellow cut surfaces. No areas of hemorrhage are identified.

GENITOURINARY SYSTEM:
The right and left kidneys weigh 220 and 220-grams, respectively. The external surfaces are intact and pitted with scattered petechiae bilaterally. The cut surfaces are red-tan and congested, with uniformly thin cortices and sharp corticomedullary junctions. The pelves are unremarkable and the ureters are normal in course and caliber. White bladder mucosa that is focally hemorrhagic overlies an intact bladder wall. The bladder contains approximately 10-milliliters of yellow urine. The prostate is enlarged in size, with nodular, yellow-tan parenchyma. The seminal vesicles are unremarkable. The testes are free of mass lesions, contusions, or other abnormalities

GASTROINTESTINAL TRACT:
The esophagus is intact and lined by smooth, grey-white mucosa. The stomach contains approximately 10-milliliters of tan fluid. The gastric wall is intact, and a 1.0 x 1.0 x 1.0-centimeter mass arises from the stomach wall. The duodenum, loops of small bowel and colon are unremarkable. The appendix is absent.

MICROSCOPIC EXAMINATION

Cardiovascular System: See the Cardiovascular Pathology consultation (Addendum 1) for complete details.

Respiratory System: Sections of the lung demonstrate evidence of pulmonary hypertension, including thickened pulmonary vasculature (mild to moderated medial hypertrophy) and interstitial fibrosis. Anthracotic pigment and hemosiderin are present in

ACLU Detainee DeathII ARMY MEDCOM 221

Genitourinary System: There is marked arteriolosclerosis with focal glomerulosclerosis in both kidneys. An incidental nephrogenic rest is noted.

Hepatobiliary System: Passive central congestion of the liver and associated mild portal inflammation is present.

Endocrine System: Myelolipoma of the right adrenal.

Gastrointestinal System: Smooth muscle tumor of uncertain malignant potential of the stomach.

Spleen: Parenchymal congestion, otherwise unremarkable.

ACLU Detainee DeathII ARMY MEDCOM 222

ADDITIONAL PROCEDURES/REMARKS

- Documentary photographs are taken by AFMES photographers
- Specimens retained for toxicological testing and/or DNA identification are: vitreous fluid, heart blood, urine, gastric fluid, bile, spleen, liver, brain, lung, kidney, adipose tissue and psoas muscle
- The dissected organs are forwarded with the body and the body is sutured closed without embalming
- The following identifying body marks are present: Midline sternotomy incision (well-healed, 7 ½-inches), left lateral abdomen/groin incision (well-healed, 13-inches)

OPINION

This 67-year-old white male, (BTB) (b)(6) died as a result of hypertensive atherosclerotic cardiovascular disease. Cardiomegaly, severe three-vessel coronary artery disease, a history of bypass-grafting surgery, aortic atherosclerosis and a healed transmural myocardial infarction are all components of this diagnosis. Also, microscopic sections of the kidneys show arteriolosclerosis in the kidneys that is a histological manifestation of systemic hypertension. Pulmonary interstitial fibrosis and the microscopic evidence of pulmonary hypertension are directly related. Incidental findings at autopsy of the right adrenal myelolipoma and smooth muscle tumor of the stomach did not contribute to the cause of death. Toxicological testing for ethanol, drugs of abuse, carbon monoxide and cyanide was negative. The manner of death is natural.

(b)(6)

(b)(6) Medical Examiner

(b)(6)

(b)(6) Medical Examiner

(b)(6) 11 Jul 06

ACLU Detainee DeathII ARMY MEDCOM 223

ADDENDUM 1

Cardiovascular Pathology Consultation

FINAL DIAGNOSIS

DIAGNOSIS: (b)(6)

1. **Severe coronary atherosclerosis with calcification, three vessel disease**
2. **Patent mammary artery graft to mid left anterior descending artery**
3. **Healed transmural infarction, posterior and septal left ventricle**
4. **Cardiomegaly with biventricular hypertrophy**
5. **Tricuspid regurgitation**

History: 67 year old male Iraqi detainee admitted to hospital on 11/20/05 with chest pain and respiratory distress; subject developed heart failure and suffered a cardiac arrest on (b)(6) 05 and could not be resuscitated

Heart: 560 grams after removal of adherent pericardium and mediastinal soft tissues; diffuse fibrous pericardial adhesions; oversewn right atrial appendage; closed foramen ovale; dilated right atrium and right ventricle; left ventricular hypertrophy; left ventricular cavity diameter 35 mm, left ventricular free wall thickness 16 mm, ventricular septum thickness 18 mm, right ventricle thickness 6 mm; tricuspid regurgitation; thickened and redundant tricuspid valve leaflets, with dilated right atrium and right ventricle, and endocardial thickening under septal leaflet of valve; mild thickening of mitral valve leaflets along lines of closure; other valves unremarkable; endocardial thickening in left ventricular septum overlying healed transmural infarction that extends to anterior and posterior walls toward the apex; histologic sections show biventricular myocyte hypertrophy with subendocardial and perivascular interstitial fibrosis and patchy replacement fibrosis; transmural replacement fibrosis, posterior and septal left ventricle; basophilic degeneration of myocytes

Coronary arteries: Normal ostia; right dominance; severe calcific coronary atherosclerosis:

Left main coronary artery: 30% luminal narrowing with nodular calcification

Left anterior descending artery (LAD): 50% narrowing of proximal LAD and 90% narrowing of mid LAD by fibrocalcific plaque; mammary artery graft to mid LAD, patent anastomosis with mild intimal thickening and 30% luminal narrowing in run-off vessel; 80% narrowing of first diagonal artery by fibrocalcific plaque

Left circumflex artery (LCA): 60% narrowing of proximal LCA with nodular calcification and 70% narrowing of mid LCA by fibrocalcific plaque

Right coronary artery (RCA): 80% narrowing of proximal and distal RCA, and 75% narrowing of mid RCA by fibrocalcific plaque

(b)(6)

Staff Pathologist

Blocks made: 18 (5 heart, 13 coronary arteries)
Slides made: 31 (18 H&E, 13 Movat)

ACLU Detainee DeathII ARMY MEDCOM 224

CERTIFICATE OF DEATH *(OVERSEAS)*
Acte dé décès (D'Outre-Mer)

NAME OF DECEASED *(Last, First, Middle)* Nom du décédé (Nom et prénoms)	GRADE Grade	BRANCH OF SERVICE Arme	SOCIAL SECURITY NUMBER Numéro de l'Assurance Social
BTB Al-Zubaydi, Muhammed, Hamza		Civilian	(b)(6)
ORGANIZATION Organisation	NATION *(e.g. United States)* Pays: Iraq	DATE OF BIRTH Date de naissance: (b)(6) 1938	SEX Sexe: [X] MALE [ ] FEMALE

RACE Race		MARITAL STATUS État Civil			RELIGION Culte		
[ ]	CAUCASOID Caucasique	[ ]	SINGLE Célibataire	[ ] DIVORCED Divorcé	[ ]	PROTESTANT Protestant	[X] OTHER (Specify) Autre (Spécifier)
[ ]	NEGROID Negride	[ ]	MARRIED Marié	[ ] SEPARATED Séparé	[ ]	CATHOLIC Catholique	
[X]	OTHER (Specify) Autre (Spécifier)	[ ]	WIDOWED Veuf		[ ]	JEWISH Juif	

NAME OF NEXT OF KIN Nom du plus proche parent	RELATIONSHIP TO DECEASED Parenté du décédé avec le sus
STREET ADDRESS Domicilé à (Rue)	CITY OR TOWN OR STATE *(Include ZIP Code)* Ville (Code postal compris)

MEDICAL STATEMENT Déclaration médicale

	CAUSE OF DEATH (Enter only one cause per line) Cause du décès (N'indiquer qu'une cause par ligne)	INTERVAL BETWEEN ONSET AND DEATH Intervalle entre l'attaque et le décès
DISEASE OR CONDITON DIRECTLY LEADING TO DEATH [1] Maladie ou condition directement responsable de la mort.	Hypertensive Atherosclerotic Cardiovascular Disease	Years
ANTECEDENT CAUSES — MORBID CONDITION, IF ANY, LEADING TO PRIMARY CAUSE Condition morbide, s'il y a lieu, menant à la cause primaire		
Symptômes précurseurs de la mort — UNDERLYING CAUSE, IF ANY, GIVING RISE TO PRIMARY CAUSE Condition morbide, s'il y a lieu, menant à la cause primaire		
OTHER SIGNIFICANT CONDITIONS [2] Autres conditions significatives [2]		

MODE OF DEATH Condition de décès	AUTOPSY PERFORMED Autopsie effectuée [X] YES Oui [ ] NO Non	CIRCUMSTANCES SURROUNDING DEATH DUE TO EXTERNAL CAUSES Circonstances de la mort suscitées par des causes extérieures
[X] NATURAL Mort naturelle	MAJOR FINDINGS OF AUTOPSY Conclusions principales de l'autopsie	
[ ] ACCIDENT Mort accidentelle		
[ ] SUICIDE Suicide	NAME OF PATHOLOGIST Nom du pathologiste: (b)(6)	
[ ] HOMICIDE Homicide	SIGNATURE Signature	DATE Date: 9 December 2005
		AVIATION ACCIDENT Accident à Avion: [ ] YES Oui [X] NO Non

DATE OF DEATH *(day, month, year)* Date de décès (le jour, le mois, l'année)	PLACE OF DEATH Lieu de décès
(b)(6) 2005	

I HAVE VIEWED THE REMAINS OF THE DECEASED AND DEATH OCCURRED AT THE TIME INDICATED AND FROM THE CAUSES AS STATED ABOVE.
J'ai examiné les restes mortels du dé funtet je conclus que le décès est survenu à l'heure indiquée et à, la suite des causes énumérées ci-dessus.

NAME OF MEDICAL OFFICER Nom du médicin militaire ou du médicin sanitaire	TITLE OR DEGREE Titre ou diplôme
(b)(6)	Medical Examiner

GRADE Grade	INSTALLATION OR ADDRESS Installation ou adresse
(b)(6)	Dover AFB, Dover DE
DATE Date	SIGNATURE Signature

[1] State disease, injury or complication which caused death, but not mode of dying such as heart failure, ect.
[2] State conditions contributing to the death, but not related to the disease or condition causing death.
[1] Préciser la nature de la maladie, de la blessure ou de la complication qui a contribué à la mort, mais non la manière de mourir, tele qu 'un arrêt du coeur, etc
[2] Préciser le condition qui a contribué à la mort, mais n'ayant aucun rapport avec la maladie ou à la condition qui a provoqué la mort.

DD FORM 1 APR 77 **2064** REPLACES DA FORM 3565, 1 JAN 72 AND DA FORM 3565-R(PAS), 26 SEP 75, WHICH ARE OBSOLETE.

ACLU Detainee DeathII ARMY MEDCOM 225

(REMOVE, REVERSE AND RE-INSERT CARBONS BEFORE COMPLETING THIS SIDE)

DISPOSITON OF REMAINS

NAME OF MORTICIAN PREPARING REMAINS	GRADE	LICENSE NUMBER AND STATE	OTHER

INSTALLATION OR ADDRESS	DATE	SIGNATURE

NAME OF CEMETERY OR CREMATORY	LOCATION OF CEMETERY OR CREMATORY

TYPE OF DISPOSTION	DATE OF DISPOSTION

REGISTRATION OF VITAL STATISTICS

REGISTRY *(Town and Country)*	DATE REGISTERED	FILE NUMBER	
		STATE	OTHER

NAME OF FUNERAL DIRECTOR	ADDRESS

SIGNATURE OF AUTHORIZED INDIVIDUAL

DD FORM 2064, APR 1977 (BACK) *USAPA V1.00*

ACLU Detainee DeathII ARMY MEDCOM 226

ARMED FORCES INSTITUTE OF PATHOLOGY
Office of the Armed Forces Medical Examiner
1413 Research Blvd., Bldg. 102
Rockville, MD 20850
1-301-319-0000

FINAL AUTOPSY EXAMINATION REPORT

Name: ALUBAYDI, Tariq Sadig Abdul Jussain
ISN: (b)(6)
Date of Birth: (b)(6) 1940
Date of Death (b)(6) 2005
Date/Time of Autopsy: 12 NOV 2005 @ 1100
Date of Report: 30 MAR 2005

Autopsy No.: (b)(6)
AFIP No.: (b)(6)
Rank: Iraqi Civilian Detainee
Place of Death: Bucca, Iraq
Place of Autopsy: Port Mortuary
Dover AFB, DE

Circumstances of Death: This 65-year-old Iraqi male complained of chest pain and shortness of breath. He was transported to the Special Army Security Hospital Emergency Room where he suffered cardiopulmonary arrest. A full Advanced Cardiopulmonary Life Support protocol was conducted to no avail. A review of medical records reveals a myocardial infarction approximately 3 years ago and a history of asthma.

Authorization for Autopsy: Office of the Armed Forces Medical Examiner, IAW 10 USC 1471.

Identification: Identification bands establish presumptive identification. A full set of fingerprints is taken if exemplars become available for comparison.

CAUSE OF DEATH: **HYPERTENSIVE ATHEROSCLEROTIC CARDIOVASCULAR DISEASE COMPLICATED BY ACUTE ASTHMA WITH MUCOUS PLUGGING**

MANNER OF DEATH: **NATURAL**

ACLU Detainee DeathII ARMY MEDCOM 227

FINAL AUTOPSY DIAGNOSES:

I. **Hypertensive Atherosclerotic Cardiovascular Disease**
   A. Cardiomegaly with biventricular dilatation (heart weight 500 grams)
   B. Left ventricular hypertrophy (left ventricular free wall 1.6 centimeters)
   C. Coronary artery disease with focal calcification (luminal obstruction of all three major coronary arteries 50-75% by atherosclerotic plaque)
   D. Moderate calcific atherosclerosis of the abdominal aorta
   E. Evidence of heart failure by hemosiderin-laden macrophages in lung tissue

II. **Acute Asthma**
   A. Partial obstruction of the right and left main stem bronchi by secretions
   B. Luminal obstruction of smaller bronchi by secretions and eosinophilic infiltration into bronchial walls

III. **Nodular prostatic hypertrophy with associated hypertrophy and trabeculation of the bladder wall**

IV. **Evidence of Medical Therapy**
   A. An endotracheal tube is in the proper position
   B. An intravenous line is in the right antecubital fosse
   C. Needle stick marks are in the left antecubital fosse

V. **No evidence of physical abuse or recent trauma is present**

VI. **Toxicology**
   A. The blood and vitreous fluid are tested for ethanol and none is found.
   B. The urine is screened for drugs of abuse and none are found.
   C. The blood is tested for carboxyhemoglobin and cyanide and none are found.

ACLU Detainee DeathII ARMY MEDCOM 228

EXTERNAL EXAMINATION

The body is that of a well-developed, well-nourished appearing, 71-inch tall, 150-pound male whose appearance is consistent with the reported age of 65-years. Lividity is posterior, red and fixed. Rigor is equal in all extremities, and the temperature is that of the refrigeration unit.

The scalp is shaven, but the hair appears to have a normal distribution. The irides are brown, and the pupils are round and equal in diameter. The external auditory canals and ears are unremarkable. The nares are patent and the lips are atraumatic. The nose and maxillae are palpably stable. The teeth appear natural and in poor condition.

The neck is straight, and the trachea is midline and mobile. The chest is symmetric. The abdomen is flat. The genitalia are those of a normal adult male. The testes are descended and free of masses. Pubic hair is present in a normal distribution. The buttocks and anus are unremarkable.

The upper and lower extremities are symmetric and without clubbing or edema.

CLOTHING AND PERSONAL EFFECTS

The following clothing items and personal effects are present on the body at the time of autopsy:

- Yellow pants
- Yellow shirt
- White underpants
- Black and white scarf
- Red and green blanket

MEDICAL INTERVENTION

- An endotracheal tube is in the proper position.
- An intravenous line is in the right antecubital fosse.
- Needle stick marks are in the left antecubital fosse.

RADIOGRAPHS

A complete set of postmortem radiographs is obtained and demonstrates the following:

- No skeletal trauma is identified.
- No metallic foreign bodies are identified.

EVIDENCE OF INJURY

- There is no evidence of recent injury.

ACLU Detainee DeathII ARMY MEDCOM 229

INTERNAL EXAMINATION

HEAD:
The galeal and subgaleal soft tissues of the scalp are free of injury. The calvarium is intact, as is the dura mater beneath it. Clear cerebrospinal fluid surrounds the 1,240-gram brain, which has unremarkable gyri and sulci. Coronal sections demonstrate sharp demarcation between white and grey matter, without hemorrhage or contusive injury. The ventricles are of normal size. The basal ganglia, brainstem, cerebellum, and arterial systems are free of injury or other abnormalities. There are no skull fractures. The atlanto-occipital joint is stable.

NECK:
The anterior strap muscles of the neck are homogenous and red-brown, without hemorrhage. The thyroid cartilage and hyoid are intact. The larynx is lined by intact white mucosa. The thyroid is symmetric and red-brown, without cystic or nodular change. The tongue is free of bite marks, hemorrhage, or other injuries.

Incision and dissection of the posterior neck demonstrates no deep paracervical muscular injury and no cervical spine fractures.

BODY CAVITIES:
The ribs, sternum, and vertebral bodies are visibly and palpably intact. No excess fluid is in the pleural, pericardial, or peritoneal cavities. The organs occupy their usual anatomic positions.

RESPIRATORY SYSTEM:
The right and left lungs weigh 900 and 670-grams, respectively. The external surfaces are smooth and deep red-purple. The pulmonary parenchyma is diffusely congested and edematous. No mass lesions or areas of consolidation are present. Copious amounts of mucoid secretions are present in the mainstem bronchi and on the cut surfaces of the smaller bronchi.

CARDIOVASCULAR SYSTEM:
The 500-gram heart is contained in an intact pericardial sac. The epicardial surface is smooth, with minimal fat investment. The coronary arteries are present in a normal distribution, with a left-dominant pattern. Cross sections of the vessels show 50-75% luminal narrowing and focal calcifications. The myocardium is red-brown and firm with areas of fibrosis noted on the left ventricular free wall. The valve leaflets are thin and mobile. The walls of the left and right ventricles are 1.6 and 0.5-centimeters thick, respectively. Biventricular dilatation is present. The endocardium is smooth and glistening. The aorta gives rise to three intact and patent arch vessels, and moderate calcific atherosclerosis is present. The renal and mesenteric vessels are unremarkable.

ACLU Detainee DeathII ARMY MEDCOM 230

LIVER & BILIARY SYSTEM:
The 1,700-gram liver has an intact, smooth capsule and a sharp anterior border. The parenchyma is tan-brown and congested, with the usual lobular architecture. No mass lesions or other abnormalities are seen. The gallbladder contains a minute amount of green-black bile and no stones. The mucosal surface is green and velvety. The extrahepatic biliary tree is patent.

SPLEEN:
The 140-gram spleen has a smooth, intact, red-purple capsule. The parenchyma is maroon and congested, with distinct Malpighian corpuscles.

PANCREAS:
The pancreas is firm and yellow-tan, with the usual lobular architecture. No mass lesions or other abnormalities are seen.

ADRENALS:
The right and left adrenal glands are symmetric, with bright yellow cortices and grey medullae. No masses or areas of hemorrhage are identified.

GENITOURINARY SYSTEM:
The right and left kidneys weigh 150 and 130-grams, respectively. The external surfaces are intact and smooth. The cut surfaces are red-tan and congested, with uniformly thick cortices and sharp cortico-medullary junctions. The pelves are unremarkable and the ureters are normal in course and caliber. White bladder mucosa overlies an intact bladder wall that is remarkable for a trabeculated pattern. The bladder contains approximately 60-milliliters of yellow urine. The prostate is enlarged, with lobular, yellow-tan parenchyma in a nodular pattern. The seminal vesicles are unremarkable. The testes are free of mass lesions, contusions, or other abnormalities.

GASTROINTESTINAL TRACT:
The esophagus is intact and lined by smooth, grey-white mucosa. The stomach contains approximately 500-milliliters of tan-yellow fluid with food particles. The gastric wall is intact. The duodenum, loops of small bowel, and colon are unremarkable. The appendix is present.

MUSCULOSKELETAL SYSTEM:
Muscle development is normal. There are no skeletal abnormalities noted.

MICROSCOPIC EXAMINATION

Kidney: Sections demonstrate moderately diffuse arteriolosclerosis and focal segmental as well as global glomerulosclerosis.

Heart: Sections of the myocardium demonstrate patchy fibrosis with areas of confluence and enlarged myocytes. A section of one of the left papillary muscles demonstrates scarring.

ACLU Detainee DeathII ARMY MEDCOM 231

Coronary Arteries: Multiple sections of the coronary arteries show luminal narrowing ranging from 40 – 75% with focal calcifications.

Lung: Multiple sections of lung parenchyma show pulmonary congestion and hemosiderin-laden macrophages. There is mucous plugging of the bronchi with submucosal plasma cell and eosinophil infiltration.

ADDITIONAL PROCEDURES/REMARKS

- Documentary photographs are taken by OAFME staff photographers
- Specimens retained for toxicologic testing and/or DNA identification are: heart blood, vitreous fluid, gastric contents, urine, spleen, liver, lung, bile, kidney, brain, adipose tissue, and psoas muscle
- The body is sutured closed without embalming and the dissected organs are forwarded with the body
- Personal effects are released to the mortuary affairs representatives
- Identifying body marks are not present

ACLU Detainee DeathII ARMY MEDCOM 232

OPINION

This 65-year-old male, (b)(6) died as a result of hypertensive atherosclerotic cardiovascular disease complicated by acute asthma with mucous plugging. The medical history and circumstances support these diagnoses, as well as the gross and microscopic examinations at autopsy. Toxicology is negative for alcohol, drugs of abuse, carboxyhemoglobin and cyanide. There is no evidence of recent injury.

The manner of death is natural.

(b)(6)

(b)(6) Medical Examiner

(b)(6)

(b)(6) Medical Examiner

ACLU Detainee DeathII ARMY MEDCOM 233

DEPARTMENT OF DEFENSE
ARMED FORCES INSTITUTE OF PATHOLOGY
WASHINGTON, DC 20306-6000

REPLY TO ATTENTION OF

AFIP-(b)(6)

TO:

OFFICE OF THE ARMED FORCES MEDICAL EXAMINER
ARMED FORCES INSTITUTE OF PATHOLOGY
WASHINGTON, DC 20306-6000

PATIENT IDENTIFICATION
AFIP Accessions Number **Sequence**
(b)(6)
Name
ALUBAYDI, TARIG SADIG ABDUL

SSAN: **Autopsy:** (b)(6)
Toxicology Accession #: (b)(6)
Date Report Generated: November 17, 2005

CONSULTATION REPORT ON CONTRIBUTOR MATERIAL

AFIP DIAGNOSIS **REPORT OF TOXICOLOGICAL EXAMINATION**

Condition of Specimens: GOOD
Date of Incident: (b)(6) 2005 **Date Received:** 11/15/2005

CARBON MONOXIDE: The carboxyhemoglobin saturation in the blood was less than 1% as determined by spectrophotometry with a limit of quantitation of 1%. Carboxyhemoglobin saturations of 0-3% are expected for non-smokers and 3-10% for smokers. Saturations above 10% are considered elevated and are confirmed by gas chromatography.

CYANIDE: There was no cyanide detected in the blood. The limit of quantitation for cyanide is 0.25 mg/L. Normal blood cyanide concentrations are less than 0.15 mg/L. Lethal concentrations of cyanide are greater than 3 mg/L.

VOLATILES: The **BLOOD AND VITREOUS FLUID** were examined for the presence of ethanol at a cutoff of 20 mg/dL. No ethanol was detected.

DRUGS: The **URINE** was screened for acetaminophen, amphetamine, antidepressants, antihistamines, barbiturates, benzodiazepines, cannabinoids, chloroquine, cocaine, dextromethorphan, lidocaine, narcotic analgesics, opiates, phencyclidine, phenothiazines, salicylates, sympathomimetic amines and verapamil by gas chromatography, color test or immunoassay. The following drugs were detected:

None were found.

(b)(6)
Office of the Armed Forces Medical Examiner

(b)(6)
Office of the Armed Forces Medical Examiner

ACLU Detainee DeathII ARMY MEDCOM 234

CERTIFICATE OF DEATH *(OVERSEAS)*
Acte de décès *(D'Outre-Mer)*

NAME OF DECEASED-*(Last, First, Middle)* Nom du décédé (Nom et prénoms) ALI BAYDI, TARIQ	GRADE Grade	BRANCH OF SERVICE Arme	SOCIAL SECURITY NUMBER Numéro de l'Assurance Sociale (b)(6)
ORGANIZATION Organisation DETAINEE (b)(6)	NATIONALITY *(Place of birth)* Pays	DATE OF BIRTH Date de naissance A46 (b)(6)	SEX Sexe X MALE Masculin ☐ FEMALE Feminin

RACE Race	MARITAL STATUS Etat Civil		RELIGION Culte	
CAUCASOID Caucasique	SINGLE Celibataire	DIVORCED Divorce	PROTESTANT Protestant	OTHER *(Specify)* Autre *(Spécifiez)*
NEGROID Négroïde	MARRIED Marié		CATHOLIC Catholique	
OTHER *(Specify)* Autre *(Spécifiez)*	WIDOWED Veuf	SEPARATED Séparé	JEWISH Juif	

NAME OF NEXT OF KIN Nom du plus proche parent	RELATIONSHIP TO DECEASED Parenté du décédé avec le susnté
STREET ADDRESS Domicile a (Rue)	CITY OR TOWN AND STATE *(Include ZIP Code)* Ville (Code postal compris)

MEDICAL STATEMENT Declaration médicale

	CAUSE OF DEATH *(Enter only one cause per line)* Cause du décès (N'indiquer qu'une cause par ligne)	INTERVAL BETWEEN ONSET AND DEATH Intervalle entre l'attaque et le décès
DISEASE OR CONDITION DIRECTLY LEADING TO DEATH [1] Maladie ou condition directement responsable de la mort	MYOCARDIAL INFARCTION	30 MINUTES
ANTECEDENT CAUSES Symptômes précurseurs de la mort — MORBID CONDITION, IF ANY, LEADING TO PRIMARY CAUSE Condition morbide, s'il y a lieu, menant à la cause primaire		
ANTECEDENT CAUSES Symptômes précurseurs de la mort — UNDERLYING CAUSE, IF ANY, GIVING RISE TO PRIMARY CAUSE Raison fondamentale, s'il y a lieu, ayant suscité la cause primaire		
OTHER SIGNIFICANT CONDITIONS [2] Autres conditions significatives [2]		

MODE OF DEATH Condition de décès NATURAL Mort naturelle ACCIDENT Mort accidentelle SUICIDE Suicide HOMICIDE Homicide	AUTOPSY PERFORMED Autopsie effectuée ☐ YES Oui ☐ NO Non MAJOR FINDINGS OF AUTOPSY Conclusions principales de l'autopsie NAME OF PATHOLOGIST Nom du pathologiste SIGNATURE Signature	DATE Date	CIRCUMSTANCES SURROUNDING DEATH DUE TO EXTERNAL CAUSES Circonstances de la mort causées par des causes externes AVIATION ACCIDENT Accident d'Aviation ☐ YES Oui ☐ NO Non

DATE OF DEATH *(Hour, day, month, year)* (b)(6) 05	PLACE OF DEATH Lieu du décès CAMP BUCCA

I HAVE VIEWED THE REMAINS OF THE DECEASED AND DEATH OCCURRED AT THE TIME INDICATED AND FROM THE CAUSES AS STATED ABOVE
J'ai examiné les restes mortels du défunt et je conclus que le décès est survenu à l'heure indiquée et a la suite des causes énumérées ci-dessus

NAME OF MEDICAL OFFICER Nom du médecin militaire ou du medecin fonctionnaire (b)(6)	TITLE OR DEGREE Titre ou diplôme
SIGNATURE Signature (b)(6)	INSTALLATION OR ADDRESS Installation ou adresse CAMP BUCCA (b)(6)
DATE Date (b)(6) 05	

[1] *State disease, injury or complication which caused death. Do not enter mode of dying, such as cardiac arrest, respiratory arrest, shock or heart failure.*
[2] *State conditions contributing to the death but not related to the disease or condition causing it.*
[1] Préciser la nature de la maladie, de la blessure ou de la complication qui a causé la mort. Ne pas indiquer des modes de mourir, tels qu'un arrêt du cœur, etc.
[2] Préciser la condition qui a contribué à la mort, mais n'ayant aucun rapport avec la maladie ou l'état pathologique à provoqué la mort.

DD FORM 2064, APR 1977 REPLACES DA FORM 3565, 1 [illegible]

MEDCOM 0235
ACLU Detainee Death II ARMY MEDCOM 235

TAB

CERTIFICATE OF DEATH

For use of this form, see AR 190-8; the proponent agency is DCSPER

INTERNMENT SERIAL NUMBER

FROM:

TO:

(b)(6)

NAME (Last, first, MI) ALUBAYDI, TARIQ

GRADE

SERVICE NUMBER

NATIONALITY

POWER SERVED

PLACE OF CAPTURE/INTERNMENT AND DATE

PLACE OF BIRTH

DATE OF BIRTH

NAME, ADDRESS, AND RELATIONSHIP OF NEXT OF KIN

FIRST NAME OF FATHER

PLACE OF DEATH Camp Bucca Iraq

DATE OF DEATH (b)(6) 05

CAUSE OF DEATH probable acute MI

PLACE OF BURIAL

DATE OF BURIAL

IDENTIFICATION OF GRAVE

PERSONAL EFFECTS (To be filled in by Office of Deputy Chief of Staff for Personnel)

___ RETAINED BY DETAINING POWER

___ FORWARDED WITH DEATH CERTIFICATE TO (Specify)

___ FORWARDED SEPARATELY TO (Specify)

BRIEF DETAILS OF DEATH/BURIAL BY PERSON WHO CARED FOR THE DECEASED DURING ILLNESS OR DURING LAST MOMENTS (Doctor, Nurse, Minister of Religion, Fellow Internee). IF CREMATED, GIVE REASON. (If more space is required, continue on reverse side).

65yo detainee brought to ETR for collapse (no pulse) agonal breathing from compound. Pt unresponsive, cyanotic from neck up - no pulses - no spontaneous breaths CPR begun, intubated + ACLS protocol performed ultrasound no cardiac motion activity accuV 114 - pronounced 25 mins p̄ code begun. code meds epi 3mg, atropine 2mg, camp Bucca

DO NOT WRITE IN THIS SPACE

CERTIFIED A TRUE COPY

DATE (b)(6) 05

(b)(6)

SIGNATURE OF COMMANDING OFFICER

WITNESSES

SIGNATURE

ADDRESS

SIGNATURE

ADDRESS

DA FORM 2669-R, MAY 82

EDITION OF 1 JUL 63 IS OBSOLETE.

USAPPC V1.00

MEDCOM 0236

HOSPITAL REPORT OF DEATH

NAME AND LOCATION OF HOSPITAL

Instructions - Medical Officer in attendance will:
Prepare original copy only, Items 1 through 10 and sign Item 11. Print or type entries.
Send form, without delay to the Registrar or Administrative Officer of the Day, for necessary action and for preparation of required number of copies.

SECTION A - ATTENDING MEDICAL OFFICER'S REPORT

PERSONAL DATA

1. PATIENT DATA *(Patient's ward plate will be used to imprint identifying data if available)*

ALUBAYDI, TARIQ

(b)(6)

(b)(6)

Patient's name (Last, first, middle initial) Grade, Social Security Account No., Register Number and Ward Number

2. TIME OF DEATH *(Hour, day, month, year)*

(b)(6) 05

3. MEDICAL EXAMINER/ CORONER'S CASE ☐ YES ☒ NO

4. RELIGION

5. CHAPLAIN NOTIFIED ☐ YES ☒ NO

6. NAME, ADDRESS AND RELATIONSHIP OF RELATIVE OR FRIEND PRESENT AT DEATH

CAUSE OF DEATH

		APPROXIMATE INTERVAL BETWEEN ONSET AND DEATH
7a. DISEASE OR CONDITION DIRECTLY LEADING TO DEATH *(This does not mean the mode of dying, e.g., heart failure, asphyxia, etc. It means the disease, injury, or complication which caused death)*	DUE TO *(or as a consequence of)* MYOCARDIAL INFARCTION	30 MINUTES
7b. ANTECEDENT CAUSES *(Morbid conditions, if any, giving rise to the above cause, stating the underlying condition last)*	DUE TO *(or as a consequence of)* (1)	
	(2)	
8. OTHER SIGNIFICANT CONDITIONS CONTRIBUTING TO THE DEATH, BUT NOT RELATED TO THE DISEASE OR CONDITION CAUSING IT	a.	
	b.	

9. DATE (b)(6) 05

10. TYPED OR PRINTED NAME AND GRADE OF MEDICAL OFFICER IN ATTENDANCE (b)(6)

(b)(6)

SECTION B - ADMINISTRATIVE AC

TYPE OF ACTION	HOUR	DAY	MONTH	YEAR	INITIALS OF RESPONSIBLE OFFICER
12. TELEGRAM TO NEXT OF KIN OR OTHER AUTHORIZED PERSON					
13. POST ADJUTANT GENERAL NOTIFIED					
14. IMMEDIATE CO OF DECEASED NOTIFIED					
15. INFORMATION OFFICE NOTIFIED					
16. POST MORTUARY OFFICER NOTIFIED					
17. RED CROSS NOTIFIED					
18. OTHER *(Specify)*					
19.					

SECTION C - RECORD OF AUTOPSY

20. AUTOPSY PERFORMED *(If yes, give date and place)* ☐ YES ☒ NO

21. AUTOPSY ORDERED BY *(Signature)*

22. PROVISIONAL PATHOLOGICAL FINDINGS

23. DATE	24. TYPED NAME AND GRADE OF PHYSICIAN PERFORMING AUTOPSY	25. SIGNATURE OF PHYSICIAN PERFORMING AUTOPSY
26. DATE	27. TYPED NAME AND GRADE OF REGISTRAR	28. SIGNATURE OF REGISTRAR

DA FORM 3894, OCT 72 REPLACES DA FORM 8-257, 1 JAN 51, WHICH WILL BE USED. USAPA V2.01

MEDCOM 0237

ACLU Detainee DeathII ARMY MEDCOM 237

ARMED FORCES INSTITUTE OF PATHOLOGY
Office of the Armed Forces Medical Examiner
1413 Research Blvd., Bldg. 102
Rockville, MD 20850
1-800-774-8427

AUTOPSY EXAMINATION REPORT

Name: BTB Sardah, Muthor Nassar
ISN: (b)(6)
Date of Birth: BTB (b)(6) 1932
Date of Death (b)(6) 2005
Date/Time of Autopsy: 31 Oct 2005 @ 1200 hrs
Date of Report: 03 Jan 2006

Autopsy No.: (b)(6)
AFIP No.: (b)(6)
Rank: Civilian
Place of Death: Iraq
Place of Autopsy: Port Mortuary, Dover AFB, DE

Circumstances of Death: This elderly civilian detainee was, as reported, admitted to the SASH ICW on 10 Oct 2005 for dehydration, pneumonia and respiratory distress. On (b)(6) (b)(6 2005 he went into cardiac arrest and died despite Advanced Cardiac Life Support.

Authorization for Autopsy: Office of the Armed Forces Medical Examiner, IAW 10 USC 1471

Identification: Presumptive identification by accompanying paperwork and wrist band photographic identification

CAUSE OF DEATH: **Atherosclerotic Coronary Vascular Disease and Metastatic Large Cell Carcinoma of the Lung**

MANNER OF DEATH: **Natural**

ACLU Detainee DeathII ARMY MEDCOM 238

FINAL AUTOPSY DIAGNOSES:

I. Pulmonary System:
- A. Right Lung:
  1. Poorly differentiated adenocarcinoma, mixed subtype (Stage IV)
  2. Irregular white-gray tumor mass, 9 x 6 x 6-centimeter, in the right lower lung lobe that extends into the hilum of the right lung
  3. Peribronchiolar, perihilar and mediastinal lymph nodes are involved
- B. Left Lung: Metastatic poorly differentiated adenocarcinoma, mixed subtype (numerous up to 1-centimeter irregular tan tumor nodules)
- C. Respiratory bronchiolitis
- D. Emphysema
- E. Focal acute bronchopneumonia
- F. Pulmonary congestion (lung weights: left 910-grams; right 980-grams)
- G. Bilateral serous pleural effusions (200 ml bilaterally)
- H. Diaphragm: Fibrous pleural plaques

II. Reticuloendothelial System: Spleen, fibrous plaques (numerous small (up to 2mm) white plaques on the capsule of the spleen)

III. Cardiovascular System:
- A. Atherosclerotic Coronary Vascular Disease:
  1. 60% stenosis of the left anterior descending coronary artery by atherosclerotic plaque
  2. 80% stenosis of the left circumflex coronary artery by atherosclerotic plaque
  3. 50% stenosis of the right coronary artery by atherosclerotic plaque
- B. Cardiomegaly: Heart weight 390-grams (predicted normal heart weight for a male with a body weight of 110-pounds is 276-grams with a lower 95% confidence limit of 209-grams and an upper 95% confidence limit of 364-grams)
- C. Concentric hypertrophy of the left ventricle of the heart (septum 2.2-centimeters, left ventricle free wall 1.9-centimeters)
- D. Moderate Atherosclerosis of the Aorta

IV. Hepatobilliary System:
- A. Congested liver (Liver weight 1280-grams)

ACLU Detainee DeathII ARMY MEDCOM 239

V. Skin:
- A. Sacral erosion, 2 ½-inch, with associated 1-inch pressure contusions on the left and right buttocks
- B. Pedunculated nevus on the skin of the left axilla
- C. Erosion on the right elbow, 1/2-inch
- D. Erythematous patch on the right forearm

VI. Erosion of the oral mucosa

VII. Evidence of Injury:
- A. Abrasion on the right hip, 1/8-inch
- B. Contusion on the left forearm, 3/4-inch
- C. Abrasion on the center of the upper back, 1/8-inch
- D. Contusion on the left forearm, 1/8-inch

VIII. Post-mortem changes:
- A. Lividity is fixed on the posterior surface of the body except in areas exposed to pressure
- B. Rigor has passed
- C. Mild decomposition of the internal organs

IX. Post-mortem radiographs reveal no significant skeletal trauma

X. Toxicology (AFIP):
- A. CARBON MONOXIDE: The Carboxyhemoglobin saturation in the blood is less than 1%
- B. CYANIDE: There is no cyanide detected in the blood
- C. VOLATILES: No ethanol is detected in the blood and vitreous fluid
- D. DRUGS: There are no screened drugs of abuse or medications detected in the liver

ACLU Detainee DeathII ARMY MEDCOM 240

EXTERNAL EXAMINATION

The body is that of a thin 64-inches tall, 110-pounds elderly male. Lividity is fixed on the posterior surface of the body. Rigor has passed.

The scalp is covered with short gray hair in a normal distribution. The irides are hazel, and the pupils are round and equal in diameter. The external auditory canals and ears are unremarkable. The nares are patent and the lips are atraumatic. The nose and maxillae are palpably stable. The deceased has no upper teeth. The lower teeth are natural. There is an erosion on the palate.

The neck is straight, and the trachea is midline and mobile. The chest is symmetric. The abdomen is flat. The genitalia are those of a normal adult male. The testes are descended and free of masses. Pubic hair is present in a normal distribution. The buttocks and anus are unremarkable.

The upper and lower extremities are symmetric and without clubbing or edema.

There is a sacral erosion, 2 ½-inches, with associated 1-inch pressure contusions on the left and right buttocks, a ½-inch pedunculated nevus on the skin of the left axilla, a ½-inch erosion on the right elbow and an erythematous patch on the right forearm.

CLOTHING AND PERSONAL EFFECTS

The following clothing items and personal effects are present on the body at the time of autopsy:

- Blue shorts

MEDICAL INTERVENTION

- Orogastric tube (properly placed)
- Endotracheal tube (properly placed)
- 11 EKG leads on the torso, shoulders and ankles
- Automatic defibrillator pads on the right side of the chest (with underlying 4 x 4-inch superficial burn) and on the left side of the chest
- Triple lumen catheter in the right subclavian vein
- Intravenous access in the left antecubital fossa and on the right forearm
- Needle puncture sites with surrounding hematomas on the right arm, right hand and left arm

RADIOGRAPHS

A complete set of postmortem radiographs is obtained and demonstrates the following:

- No blunt force or penetrating skeletal injuries
- No metallic foreign objects are identified

ACLU Detainee DeathII ARMY MEDCOM 241

EVIDENCE OF INJURY

The ordering of the following injuries is for descriptive purposes only, and is not intended to imply order of infliction or relative severity.

- abrasion on the right hip, 1/8-inch
- contusion on the left forearm, 3/4-inch
- abrasion on the center of the upper back, 1/8-inch
- Contusion on the left forearm, 1/8-inch

INTERNAL EXAMINATION

HEAD:
The galeal and subgaleal soft tissues of the scalp are free of injury. The calvarium is intact, as is the dura mater beneath it. Clear cerebrospinal fluid surrounds the 1320-grams brain, which has unremarkable gyri and sulci. Coronal sections demonstrate sharp demarcation between white and gray matter, without hemorrhage or contusive injury. The ventricles are of normal size. The basal ganglia, brainstem, cerebellum, and arterial systems are free of injury or other abnormalities. There are no skull fractures. The atlanto-occipital joint is stable.

NECK:
The anterior strap muscles of the neck are homogenous and red-brown, without hemorrhage. The thyroid cartilage and hyoid are intact. The larynx is lined by intact white mucosa. The thyroid is symmetric and red-brown, without cystic or nodular change. The tongue is free of bite marks, hemorrhage, or other injuries.

BODY CAVITIES:
The ribs, sternum, and vertebral bodies are visibly and palpably intact. Both chest cavities contain 200-milliliters of serous fluid. The organs occupy their usual anatomic positions.

RESPIRATORY SYSTEM:
The right and left lungs weigh 980 and 910-grams, respectively. The external surfaces are smooth and deep red-purple. The pulmonary parenchyma is diffusely congested and edematous. There is a 9 x 6 x 6-inch irregular white, gray and black mass in the lower lobe of the right lung that extends into the hilum. Multiple irregular tan tumor nodules up to 1-centimeters in greatest dimension are in both lobes of the left lung. The mediastinal lymph nodes are enlarged (up to 1-inch) and their cut surfaces are white-gray, soft, and heterogenous. Contralateral mediastinal and hilar lymph nodes are involved. Both hemi-diaphragms are involved by 1-centimeter white plaques.

ACLU Detainee DeathII ARMY MEDCOM 242

CARDIOVASCULAR SYSTEM:
The 390-gram heart is contained in an intact pericardial sac. The epicardial surface is smooth, with minimal fat investment. The coronary arteries are present in a normal distribution. Cross sections of the vessels show 60% stenosis of the left anterior descending, 80% stenosis of the left circumflex and 50% stenosis of the right coronary artery by atherosclerotic plaque. The myocardium is homogenous, red-brown, and firm. The valve leaflets are thin and mobile. There is relatively concentric hypertrophy of the left ventricle and the walls of the left and right ventricles and septum are 1.9, 0.8 and 2.2-centimeters thick, respectively. The endocardium is smooth and glistening. The aorta gives rise to three intact and patent arch vessels. There is moderate atherosclerosis of the aorta. The renal and mesenteric vessels are unremarkable.

LIVER & BILIARY SYSTEM:
The 1280-gram liver has an intact, smooth capsule and a sharp anterior border. The parenchyma is tan-brown and congested, with the usual lobular architecture. No mass lesions or other abnormalities are seen. The gallbladder contains a minute amount of green-black bile and no stones. The mucosal surface is green and velvety. The extrahepatic biliary tree is patent.

SPLEEN:
The 150-gram spleen has a red-purple capsule with numerous (up to 2-millimeter) white plaques. The parenchyma is maroon and congested, with distinct Malpighian corpuscles.

PANCREAS:
The pancreas is firm and yellow-tan, with the usual lobular architecture. No mass lesions or other abnormalities are seen.

ADRENALS:
The right and left adrenal glands are symmetric, with bright yellow cortices and gray medullae. No masses or areas of hemorrhage are identified.

GENITOURINARY SYSTEM:
The right and left kidneys each weigh 130-grams. The external surfaces are intact and smooth. The cut surfaces are red-tan and congested, with uniformly thick cortices and sharp corticomedullary junctions. The pelves are unremarkable and the ureters are normal in course and caliber. White bladder mucosa overlies an intact bladder wall. The bladder contains approximately 50-milliliters of dark yellow urine. The prostate is normal in size, with lobular, yellow-tan parenchyma. The seminal vesicles are unremarkable. The testes are free of mass lesions, contusions, or other abnormalities.

GASTROINTESTINAL TRACT:
The esophagus is intact and lined by smooth, grey-white mucosa. The stomach contains approximately 20-milliliters of brown fluid. The gastric wall is intact. The duodenum, loops of small bowel, and colon are unremarkable. The appendix is present.

ACLU Detainee DeathII ARMY MEDCOM 243

ADDITIONAL PROCEDURES

1. Documentary photographs are taken by the OAFME.
2. Specimens retained for toxicologic testing and/or DNA identification are: Lung, blood, spleen, psoas muscle, bile, urine, vitreous, brain, kidney, liver, adipose and gastric fluid
3. The dissected organs are forwarded with body.
4. Identifying marks include: Scar on the right shoulder and (b)(6) tattoo (b)(6) (b)(6)

MICROSCOPIC EXAMINATION

HEART:
Myocardium (Slides-H, I, J) – increased inter-myocyte fibrosis

Left Anterior Descending Coronary Artery (Slide-K)– 60% stenosis by calcified atherosclerotic plaque

Right Coronary Artery (Slide-N) – 50% stenosis by calcified atherosclerotic plaque

Left Circumflex Coronary Artery (Slides-M, L) – calcified atherosclerotic plaque

MEDIASTINAL LYMPH NODES:
(Slide-C) Lymph node with widespread areas of necrosis and malignant epithelial cells that have large pleomorphic nuclei, prominent nucleoli and abundant eosinophilic cytoplasm

LUNGS:
Right Lung – (Slides-B, G) Tumor mass consisting of malignant epithelial tumor cells that have large pleomorphic nuclei, prominent nucleoli and moderate to abundant eosinophilic cytoplasm, the overall pattern is a large cell adenocarcinoma with some bronchoalveolar features. There is multi-focal necrosis and inflammation

Left Lung – (Slides-D, E) Tumor masses consisting of malignant epithelial tumor cells that have large pleomorphic nuclei, prominent nucleoli and moderate to abundant eosinophilic cytoplasm

DIAPHRAGM:
(Slide-F) Dense fibrosis and scant mesothelial cells that have large nuclei, prominent nucleoli and moderate eosinophilic cytoplasm

ACLU Detainee DeathII ARMY MEDCOM 244

SPLEEN:
(Slide-A) Dense fibrosis and scant mesothelial cells that have pleomorphic spindled nuclei, conspicuous nucleoli and moderate eosinophilic cytoplasm

PULMONARY PATHOLOGY CONSULTATION (AFIP):

The Pulmonary Pathology Department of the AFIP submitted the following report after reviewing the submitted material:

-Poorly differentiated adenocarcinoma, mixed subtype
-Acute bronchopneumonia
-Respiratory bronchiolitis and emphysema
-Fibrous pleural plaque

Sections of lung showing a poorly differentiated adenocarcinoma with lepidic, papillary, solid and acinar growth patterns. Pleural and capillary/lymphatic invasion are present. Metastatic tumor is identified in the left lung, peribronchiolar/perihilar and mediastinal lymph nodes. Emphysema and respiratory bronchiolitis are also present. RB is characterized by bronchiolocentric intraalveolar accumulations of macrophages containing dusty yellow-brown pigment, a finding typically associated with cigarette smoke. Focal acute bronchopneumonia is identified. On immunohistochemical studies, the tumor cells are immunoreactive for CK7, CK20 and TTF-1. Based on the light microscopic morphology we classify this tumor as poorly differentiated adenocarcinoma, mixed subtype. The immunophenotype is compatible with a lung primary. Sections of diaphragm and spleen show fibrous plaques. We noticed occasional atypical cells along the surface of the spleen and along the surface of the diaphragm plaque that we favor are mesothelial in origin (mesothelial hyperplasia). As there is metastatic disease in the left lung from what appears to be a right lung primary, the stage of this tumor is AJCC stage IV.

OPINION

This elderly Iraqi male died of atherosclerotic coronary vascular disease and metastatic large cell carcinoma of the lung. The toxicology screen is negative. The small abrasion on the right hip and upper back and the small contusion on the left forearm are minor and non-contributory to either the cause or manner of death. The manner of death is natural.

(b)(6)
(b)(6) Medical Examiner

(b)(6)
(b)(6) Medical Examiner

ACLU Detainee DeathII ARMY MEDCOM 245

CERTIFICATE OF DEATH *(OVERSEAS)*
Acte de décès (D'Outre-Mer)

NAME OF DECEASED *(Last, First, Middle)* Nom du décédé (Nom et prénoms)	GRADE Grade	BRANCH OF SERVICE Arme	SOCIAL SECURITY NUMBER Numéro de l'Assurance Social
BTB Sardah, Muthor, Nassar		Civilian	(b)(6)

ORGANIZATION Organisation	NATION *(e.g. United States)* Pays	DATE OF BIRTH Date de naissance	SEX Sexe
	Iraq	(b)(6) 1932	[X] MALE [ ] FEMALE

RACE Race		MARITAL STATUS État Civil			RELIGION Culte		
	CAUCASOID Caucasique		SINGLE Célibataire		DIVORCED Divorcé		PROTESTANT Protestant		OTHER (Specify) Autre (Spécifier)
	NEGROID Negroide		MARRIED Marié		SEPARATED Séparé		CATHOLIC Catholique	X	
X	OTHER (Specify) Autre (Spécifier)		WIDOWED Veuf				JEWISH Juif		

NAME OF NEXT OF KIN Nom du plus proche parent	RELATIONSHIP TO DECEASED Parenté du décédé avec le sus
STREET ADDRESS Domicilé à (Rue)	CITY OR TOWN OR STATE *(Include ZIP Code)* Ville (Code postal compris)

MEDICAL STATEMENT Déclaration médicale

	CAUSE OF DEATH (Enter only one cause per line) Cause du décès (N'indiquer qu'une cause par ligne)	INTERVAL BETWEEN ONSET AND DEATH Intervalle entre l'attaque et le décès
DISEASE OR CONDITON DIRECTLY LEADING TO DEATH [1] Maladie ou condition directement responsable de la mort.	Pending	Pending
ANTECEDENT CAUSES — MORBID CONDITION, IF ANY, LEADING TO PRIMARY CAUSE Condition morbide, s'il y a lieu, menant à la cause primaire		
Symptômes précurseurs de la mort. — UNDERLYING CAUSE, IF ANY, GIVING RISE TO PRIMARY CAUSE Condition morbide, s'il y a lieu, menant à la cause primaire		
OTHER SIGNIFICANT CONDITIONS [2] Autres conditions significatives [2]		

MODE OF DEATH Condition de décès	AUTOPSY PERFORMED Autopsie effectuée [X] YES Oui [ ] NO Non	CIRCUMSTANCES SURROUNDING DEATH DUE TO EXTERNAL CAUSES Circonstances de la mort suscitées par des causes extérieures
[ ] NATURAL Mort naturelle	MAJOR FINDINGS OF AUTOPSY Conclusions principales de l'autopsie	Mode of Death: Pending
[ ] ACCIDENT Mort accidentelle		Mode of Death : Pending
[ ] SUICIDE Suicide	NAME OF PATHOLOGIST Nom du pathologiste (b)(6)	
[ ] HOMICIDE Homicide	DATE Date 31 October 2005	AVIATION ACCIDENT Accident à Avion [ ] YES Oui [X] NO Non

DATE OF DEATH *(day, month, year)* Date de décès (le jour, le mois, l'année)	PLACE OF DEATH Lieu de décès
(b)(6) 2005	Iraq

I HAVE VIEWED THE REMAINS OF THE DECEASED AND DEATH OCCURRED AT THE TIME INDICATED AND FROM THE CAUSES AS STATED ABOVE.
J'ai examiné les restes mortels du dé funtet je conclus que le décès est survenu à l'heure indiquée et à, la suite des causes énumérées ci-dessus.

NAME OF MEDICAL OFFICER Nom du médicin militaire ou du médicin sanitaire	TITLE OR DEGREE Titre ou diplômé
(b)(6)	Medical Examiner

GRADE Grade	INSTALLATION OR ADDRESS Installation ou adresse
(b)(6)	Dover AFB, Dover DE
DATE Date 21 NOV 2005	(b)(6)

[1] State disease, injury or complication which caused death, but not mode of dying such as heart failure, etc.
[2] State conditions contributing to the death, but not related to the disease or condition causing death.
[1] Préciser la nature de la maladie, de la blessure ou de la complication qui a contribué à la mort, mais non le mumère de mourir, telle qu'un arrêt du coeur, etc
[2] Préciser la condition qui a contribué à la mort, mais n'ayant aucun rapport avec la maladie ou à la condition qui a provoqué la mort.

DD FORM 1 APR 77 **2064** REPLACES DA FORM 3565, 1 JAN 72 AND DA FORM 3565-R(PAS), 26 SEP 75, WHICH ARE OBSOLETE.

(REMOVE, REVERSE AND RE-INSERT CARBONS BEFORE COMPLETING THIS SIDE)

DISPOSITON OF REMAINS			
NAME OF MORTICIAN PREPARING REMAINS	GRADE	LICENSE NUMBER AND STATE	OTHER
INSTALLATION OR ADDRESS	DATE	SIGNATURE	
NAME OF CEMETERY OR CREMATORY	LOCATION OF CEMETERY OR CREMATORY		
TYPE OF DISPOSTION	DATE OF DISPOSTION		

REGISTRATION OF VITAL STATISTICS			
REGISTRY *(Town and Country)*	DATE REGISTERED	FILE NUMBER	
		STATE	OTHER
NAME OF FUNERAL DIRECTOR	ADDRESS		
SIGNATURE OF AUTHORIZED INDIVIDUAL			

DD FORM 2064, APR 1977 (BACK) *USAPA V1.00*

ACLU Detainee DeathII ARMY MEDCOM 247

ARMED FORCES INSTITUTE OF PATHOLOGY
Office of the Armed Forces Medical Examiner
1413 Research Blvd., Bldg. 102
Rockville, MD 20850
301-319-0000

AMENDED
AUTOPSY EXAMINATION REPORT

Name: BTB Mohamed-Ali, Monhnd, Ganim
IFN.: (b)(6)
Date of Birth: BTE(b)(6) 1987
Date of Death: (b)(6) 2005
Date of Autopsy: 19 October 2005
Date of Report: 20 October 2006

Autopsy No.: (b)(6)
AFIP No.: (b)(6)
Rank: CIV
Place of Death: Iraq
Place of Autopsy: Port Mortuary
Dover AFB, DE

Circumstances of Death: According to reports, this 18 year-old civilian detainee was captured by US Forces on 15 Sep 2005. During his detention he was diagnosed with an inner ear infection. Despite treatment the infection progressed to mastoiditis and brain abscess. It was determined that there was no chance of meaningful functional recovery and life support was discontinued after ethics committee review.

Authorization for Autopsy: Office of the Armed Forces Medical Examiner, IAW 10 USC 1471

Identification: Presumptive, based on attached mortuary tag.

CAUSE OF DEATH: Intracranial Abscess

MANNER OF DEATH: Natural

20 October 2006
This amended report is submitted to reflect the results of the Neuropathology Consultation. The opinion is amended accordingly. The remainder of the report remains unchanged.

(b)(6)
(b)(6) Medical Examiner

(b)(6)
(b)(6) Medical Examiner

ACLU Detainee DeathII ARMY MEDCOM 248

FINAL AUTOPSY DIAGNOSES

I. Central Nervous System:
   - A. Right-sided mastoiditis with adjacent temporal lobe abscess and focal subdural empyema
     1. Meningitis
   - B. Cerebral edema
   - C. Neuropathology consultation pending

II. Pulmonary System:
   - A. Bilateral pulmonary congestion and edema (Right 800-grams; Left 640-grams)

III. Gastrointestinal System:
   - A. Hemorrhagic Gastritis

IV. Skin:
   - A. Superficial healing ulceration and fissures of the mouth
   - B. Superficial sacral decubitus ulcer (¾ inch)
   - C. Red macular-papular rash on the upper chest

V. Evidence of Minor Injury:
   - A. Scattered abrasions and contusions of the lower torso and lower extremities

VI. Toxicology (AFIP):
   - A. CARBON MONOXIDE: The carboxyhemoglobin saturation in the blood is less than 1%.
   - B. CYANIDE: There is no cyanide detected in the blood.
   - C. VOLATILES: No ethanol is detected in the bile and vitreous fluid.
   - D. DRUGS: No screened drugs of abuse or medications are detected in the liver.

ACLU Detainee DeathII ARMY MEDCOM 249

EXTERNAL EXAMINATION

The body is that of a well-developed, well-nourished appearing, muscular, 66-inch tall, 129-pound male whose appearance is consistent with the reported age of 18 years. Lividity is present and fixed on the posterior surfaces of the body except in areas exposed to pressure. Rigor has passed. The body is cool to the touch.

The scalp is covered with medium length brown curly hair that has been shaved on the right side. The irides are brown, and the pupils are round and equal in diameter. The external auditory canals are free of any secretions. The ears are unremarkable. The nares are patent and the lips are red and have superficial ulceration and fissures. The nose and maxillae are palpably stable. The natural teeth appear in good condition.

The neck is straight, and the trachea is midline and mobile. The chest is symmetric. There is a red maculopapular rash on the center of the chest. The abdomen is flat. The genitalia are those of a normal adult male. The testes are descended and free of masses. Pubic hair is present in a normal distribution. The buttocks and anus are unremarkable. There is a 3/4-inch superficial ulcer on the skin overlying the sacrum.

The upper and lower extremities are symmetric and without clubbing or edema. A hospital tag is present on the left ankle. There is a 1-inch callus on the skin covering the left lateral malleolus.

CLOTHING AND PERSONAL EFFECTS

The body is received unclad draped in a white sheet.

MEDICAL INTERVENTION

- Intravenous puncture site in the right wrist
- Intravenous puncture in the right antecubital fossa with surrounding subcutaneous hemorrhage
- Intravenous puncture site below the left clavicle
- 1 ¼-inch stapled incision on the right temporal scalp with underlying burr hole
- 1 ¾-inch stapled incision on the right parietal scalp with underlying burr hole
- 1/8-inch sutured surgical incision on the right parietal scalp
- Scalp hair shaved on the right side of the head

RADIOGRAPHS

A complete set of postmortem radiographs shows no evidence of skeletal injury.

EVIDENCE OF INJURY

The ordering of the following minor injuries is for descriptive purposes only, and is not intended to imply order of infliction or relative severity.

ACLU Detainee DeathII ARMY MEDCOM 250

Head and neck:

- Abrasion of the right side of the nasal bridge, ¼ x 1/8-inch.

Torso:

- Contusion over the left iliac crest, 1 ½-inches
- Contusion over the right iliac crest, 2-inches
- Abrasion on the anterior left shoulder, 1/8-inch

Extremities:

- Abrasion on the distal anterior right thigh, ½-inch
- Abrasion on the anterior right knee, 1/8-inch
- Abrasion on the proximal anterior right leg, ½-inch
- Abrasion on the anterior distal right leg, 1-inch
- Abrasion on the anterior right ankle, ¼-inch
- Abrasion on the posterior distal right leg, 1 x ¼-inch
- Abrasion on the posterior distal right leg, ¼-inch
- Abrasion on the posterior right ankle, ¾ x ¼-inch
- Contusion on the distal anterior left thigh, ¼-inch
- Abrasion on the left knee, ¼-inch
- Abrasion on the anterior left ankle, 1 x ¾-inch
- Abrasion on the distal posterior left leg, 1/8-inch
- Abrasion on the distal posterior left leg, ½ x 1/8-inch
- Abrasion on the posterior left ankle, ¾ x ¼-inch

INTERNAL EXAMINATION

HEAD:
(See above "Medical Intervention")

The galeal and subgaleal soft tissues of the scalp are free of injury. The dura mater beneath the skull is intact except in the areas associated with therapeutic intervention. The cerebrospinal fluid is viscous and yellow. The 1840-gram brain is edematous with diffuse widening and flattening of gyri and narrowing of the sulci. There is a soft fluctuant mass in the right temporal lobe that on sectioning is identified as a 1 ¼-inch cavity filled with a purulent fluid. A thick coat of purulent exudate covers the base of the brain. There are no traumatic skull fractures. The inner ear is unroofed and the cut surface is soft, pale and friable (histologic sections are prepared). The atlanto-occipital joint is stable. The brain is submitted for neuropathology consultation after formalin fixation.

NECK:
The anterior neck is examined utilizing a separate anterior neck dissection. The anterior strap muscles of the neck are homogenous and red-brown, without hemorrhage. The thyroid cartilage and hyoid are intact. The larynx is lined by intact white mucosa. The thyroid is symmetric and

ACLU Detainee DeathII ARMY MEDCOM 251

red-brown, without cystic or nodular change. There is patchy erosion of the lateral left edge of the tongue.

BODY CAVITIES:
The ribs, sternum, and vertebral bodies are visibly and palpably intact. There is 50-milliliters of serous fluid in the pleural cavities. There is 200-milliliters of serous fluid in the peritoneum. The pericardial sac contains an 85-milliliter serous effusion. The internal organs occupy their usual anatomic positions.

RESPIRATORY SYSTEM:
The right and left lungs weigh 800-grams and 640-grams, respectively. The external surfaces are smooth and deep red-purple. The pulmonary parenchyma is diffusely congested and edematous. No mass lesions or areas of consolidation are present.

CARDIOVASCULAR SYSTEM:
The 390-gram heart is contained in an intact pericardial sac. The epicardial surface is smooth, with minimal fat investment. The coronary arteries are present in a normal distribution. The coronary arteries are widely patent. The myocardium is homogenous, red-brown, and firm. The valve leaflets are thin and mobile. The walls of the left and right ventricles are unremarkable. The endocardium is smooth and glistening. The aorta gives rise to three intact and patent arch vessels. The renal and mesenteric vessels are unremarkable.

LIVER & BILIARY SYSTEM:
The 2200-gram liver has an intact, smooth capsule and a sharp anterior border. The parenchyma is tan-brown and congested, with the usual lobular architecture. No mass lesions or other abnormalities are seen. The gallbladder contains a minute amount of green-black bile and no stones. The mucosal surface is green and velvety. The extrahepatic biliary tree is patent.

SPLEEN:
The 260-gram spleen has a smooth, intact, red-purple capsule. The parenchyma is maroon and congested, with distinct Malpighian corpuscles.

PANCREAS:
The pancreas is firm and yellow-tan, with the usual lobular architecture. No mass lesions or other abnormalities are seen.

ADRENALS:
The right and left adrenal glands are symmetric, with bright yellow cortices and grey medullae. No masses or areas of hemorrhage are identified.

GENITOURINARY SYSTEM:
The right and left kidneys weigh 200-grams and 190-grams, respectively. The external surfaces are intact and smooth. The cut surfaces are red-tan and congested, with uniformly thick cortices and sharp corticomedullary junctions. The pelves are unremarkable and the ureters are normal in course and caliber. White bladder mucosa overlies an intact bladder wall. The bladder contains approximately 60-milliliters of clear yellow urine. The prostate is normal in size, with lobular,

ACLU Detainee DeathII ARMY MEDCOM 252

yellow-tan parenchyma. The seminal vesicles are unremarkable. The testes are free of mass lesions, contusions, or other abnormalities.

GASTROINTESTINAL TRACT:
The esophagus is intact and lined by smooth, grey-white mucosa. The stomach contains approximately 20 cc of brown fluid. The gastric wall is intact. The duodenum, loops of small bowel, and colon are unremarkable. The appendix is present.

MUSCULOSKELETAL SYTEM:
Muscle development is normal. The skull is described under "Medical Intervention: above. No bone or joint abnormalities are noted.

MICROSCOPIC EXAMINATION

Middle Ear - Devitalized bone and bone marrow; acute and chronically inflamed low cuboidal epithelium compatible with the tympanic cavity.

NEUROPATHOLOGY CONSULTATION

In summary, this brain demonstrates subacute right temporal lobe abscess, diffuse subacute purulent meningo-cerebro-ventriculitis, a choroid plexitis, subacute hemorrhagic infarcts in the right superior frontal and cingulated gyri, and an acute hemorrhagic right occipital lobe infarct.

(A copy of the complete Neuropathology Consultation, which was prepared by (b)(6) (b)(6) Armed Forces Institute of Pathology, Department of Neuropathology and Opthalmic Pathogy, is maintained in the case file maintained by the Office of the Armed Forces Medical Examiner)

ADDITIONAL PROCEDURES

1. Documentary photographs are taken by OAFME photographers.
2. No trace evidence was collected.
3. Specimens retained for toxicologic testing and/or DNA identification are: blood, urine, vitreous, bile, CSF, gastric contents, lung, liver, spleen, kidney, muscle and adipose.
4. The dissected organs are forwarded with the body.
5. Personal effects are released to the appropriate mortuary operations representatives.
6. Identifying marks consist of scars on the posterior distal right forearm and anterior left wrist.

ACLU Detainee DeathII ARMY MEDCOM 253

OPINION

This 18 year-old male civilian detainee died of an intracranial (brain) abscess arising from a presumed inner ear infection with mastoiditis. Autopsy examination showed abscess formation in the right temporal lobe of the brain, deposition of purulent material on the inferior surfaces of the brain and purulent appearing CSF. Further, there was a diffuse subacute purulent meningo-cerebro-ventriculitis, a choroid plexitis, subacute hemorrhagic infarcts in the right superior frontal and cingulated gyri, and an acute hemorrhagic right occipital lobe infarct. The inner ear is unroofed and the cut surface is soft, pale and friable. There was no evidence of significant injury identified. The toxicology screen was negative. The manner of death is natural.

(b)(6)

(b)(6) Medical Examiner

(b)(6)

(b)(6) Medical Examiner

ACLU Detainee DeathII ARMY MEDCOM 254

CERTIFICATE OF DEATH *(OVERSEAS)*
Acte dé décès (D'Outre-Mer)

NAME OF DECEASED *(Last, First, Middle)* Nom du décédé (Nom et prénoms)	GRADE Grade	BRANCH OF SERVICE Arme	SOCIAL SECURITY NUMBER Numéro de l'Assurance Social
BTB Mohamed-Ali, Monhnd, Ganim		Civilian	(b)(6)
ORGANIZATION Organisation	NATION *(e.g. United States)* Pays: Iraq	DATE OF BIRTH Date de naissance	SEX Sexe: [X] MALE [ ] FEMALE

RACE Race		MARITAL STATUS État Civil			RELIGION Culte		
[X]	CAUCASOID Caucasique		SINGLE Célibataire		DIVORCED Divorcé		PROTESTANT Protestant
[ ]	NEGROID Negriode		MARRIED Marié		SEPARATED Séparé		CATHOLIC Catholique
[ ]	OTHER (Specify) Autre (Spécifier)		WIDOWED Veuf			[X]	JEWISH Juif
							OTHER (Specify) Autre (Spécifier)

NAME OF NEXT OF KIN Nom du plus proche parent	RELATIONSHIP TO DECEASED Parenté du décéde avec le sus
STREET ADDRESS Domicilié à (Rue)	CITY OR TOWN OR STATE *(Include ZIP Code)* Ville (Code postal compris)

MEDICAL STATEMENT Déclaration médicale

	CAUSE OF DEATH (Enter only one cause per line) Cause du décés (N'indiquer qu'une cause par ligne)	INTERVAL BETWEEN ONSET AND DEATH Intervalle entre l'attaque et le décés
DISEASE OR CONDITON DIRECTLY LEADING TO DEATH [1] Maladie ou condition directement responsable de la mort. [1]	Brain Abscess	Weeks
ANTECEDENT CAUSES Symptômes précurseurs de la mort. — MORBID CONDITION, IF ANY, LEADING TO PRIMARY CAUSE Condition morbide, s'il y a lieu, menant à la cause primaire	Ear infection	Weeks
UNDERLYING CAUSE, IF ANY, GIVING RISE TO PRIMARY CAUSE Condition morbide, s'il y a lieu, menant à la cause primaire		
OTHER SIGNIFICANT CONDITIONS [2] Autres conditions significatives [2]		

MODE OF DEATH Condition de décés	AUTOPSY PERFORMED Autopsie effectuée [X] YES Oui [ ] NO Non	CIRCUMSTANCES SURROUNDING DEATH DUE TO EXTERNAL CAUSES Circonstances de la mort suscitées par des causes extérieures
[X] NATURAL Mort naturelle	MAJOR FINDINGS OF AUTOPSY Conclusions principales de l'autopsie	
[ ] ACCIDENT Mort accidentelle		
[ ] SUICIDE Suicide	NAME OF PATHOLOGIST Nom du pathologiste: (b)(6)	
[ ] HOMICIDE Homicide	SIGNATURE Signature	DATE Date: 19 October 2005
		AVIATION ACCIDENT Accident à Avion: [ ] YES Oui [X] NO Non

DATE OF DEATH *(day, month, year)* (le jour, le mois, l'année)	PLACE OF DEATH Lieu de décés
(b)(6) 2005	Iraq

I HAVE VIEWED THE REMAINS OF THE DECEASED AND DEATH OCCURRED AT THE TIME INDICATED AND FROM THE CAUSES AS STATED ABOVE.
J'ai examiné les restes mortels du dé funtet je conclus que le décés est survenu à l'heure indiquée et à, la suite des causes énumérées ci-dessus.

NAME OF MEDICAL OFFICER Nom du médicin militaire ou du médicin sanitaire	TITLE OR DEGREE Titre ou diplômé
(b)(6)	Medical Examiner

GRADE Grade	INSTALLATION OR ADDRESS Installation ou adresse
(b)(6)	Dover AFB, Dover DE
DATE Date	SIGNATURE Signature

[1] State disease, injury or complication which caused death, but not mode of dying such as heart failure, ect.
[2] State conditions contributing to the death, but not related to the disease or condition causing death.
[1] Préciser la nature de la maladie, de la blessure ou de la complication qui a contribué à la mort, mais non la manière de mourir, telle qu 'un arrêt du coeur, etc
[2] Préciser la condition qui a contribué à la mort, mais n'ayant aucun rapport avec la maladie ou à la condition qui a provoqué la mort.

DD FORM 1 APR 77 **2064** REPLACES DA FORM 3565, 1 JAN 72 AND DA FORM 3565-R(PAS), 26 SEP 78, WHICH ARE OBSOLETE.

MEDCOM 0255

ACLU Detainee DeathII ARMY MEDCOM 255

(REMOVE, REVERSE AND RE-INSERT CARBONS BEFORE COMPLETING THIS SIDE)

DISPOSITON OF REMAINS

NAME OF MORTICIAN PREPARING REMAINS	GRADE	LICENSE NUMBER AND STATE	OTHER

INSTALLATION OR ADDRESS	DATE	SIGNATURE

NAME OF CEMETERY OR CREMATORY	LOCATION OF CEMETERY OR CREMATORY

TYPE OF DISPOSTION	DATE OF DISPOSTION

REGISTRATION OF VITAL STATISTICS

REGISTRY *(Town and Country)*	DATE REGISTERED	FILE NUMBER	
		STATE	OTHER

NAME OF FUNERAL DIRECTOR	ADDRESS

SIGNATURE OF AUTHORIZED INDIVIDUAL

DD FORM 2064, APR 1977 (BACK) *USAPA V1.00*

ACLU Detainee DeathII ARMY MEDCOM 256

ARMED FORCES INSTITUTE OF PATHOLOGY
Office of the Armed Forces Medical Examiner
1413 Research Blvd., Bldg. 102
Rockville, MD 20850
1-800-774-8427

AUTOPSY EXAMINATION REPORT

Name: BTB Al Zobaie, Elawy D.
ISN: (b)(6)
Date of Birth (b)(6) 1962
Date of Death (b)(6) 2005
Date of Autopsy: 15 OCT 2005
Date of Report: 19 DEC 2005

Autopsy No.: (b)(6)
AFIP No.: (b)(6)
Rank: Not Applicable
Place of Death: Camp Bucca, Iraq
Place of Autopsy: Port Mortuary,
Dover Air Force Base, Dover, DE

Circumstances of Death: According to witnesses this detainee was reading when he fell over and stopped breathing. Despite life saving measures he died about 30 minutes after being brought to medical attention.

Authorization for Autopsy: Office of the Armed Forces Medical Examiner, IAW 10 USC 1471

Identification: Presumptive identification is established by internment service number. Positive identification is pending adequate exemplars.

CAUSE OF DEATH: **Cardiomegaly**

MANNER OF DEATH: **Natural**

ACLU Detainee DeathII ARMY MEDCOM 257

FINAL AUTOPSY DIAGNOSES:

I. Cardiomegaly (heart weight 480 g; expected weight 340 g)

II. No evidence of trauma

III. Evidence of medical intervention includes a naso-gastric tube, a cut endotracheal tube, cardiac monitor leads on the chest and both arms, and an intravenous catheter in the left hand

IV. Post mortem changes consist of mild decomposition

V. Toxicology

A. Volatiles (heart blood and vitreous fluid): no ethanol detected

B. Screened drugs of abuse and medications (heart blood): none detected

ACLU Detainee DeathII ARMY MEDCOM 258

EXTERNAL EXAMINATION

The body is that of a well-developed, well-nourished appearing, muscular, 66 inch tall, 168 pounds male whose appearance is consistent with the reported age of 43 years. Lividity is present and fixed on the posterior surface and rigor is absent.

The scalp is covered with brown, straight, short hair in a normal distribution. Facial hair consists of a beard and moustache. The irides are brown, the corneae are hazy, both conjunctivae have scattered petechial hemorrhages, the sclerae are white and the pupils are round and equal in diameter. The external auditory canals are clear and the ears are unremarkable. The nares are patent and the lips are atraumatic. The nose and maxillae are palpably stable. The teeth appear natural and in good condition.

The neck is straight, and the trachea is midline and mobile. The chest is symmetric. The abdomen is flat. The genitalia are those of a normal adult male. The testes are descended and free of masses. Pubic hair is present in a normal distribution. The buttocks and anus are unremarkable.

The upper and lower extremities are symmetric and without clubbing or edema. A 1" scar is on the back of the left hand extending to the little finger.

CLOTHING AND PERSONAL EFFECTS

The following clothing items and personal effects are present on the body at the time of autopsy:

- yellow shorts
- cut yellow jumpsuit (2 pieces)
- black socks
- patterned blue blanket

MEDICAL INTERVENTION

Evidence of medical intervention consists of:

- nasogastric tube
- cut endotracheal tube
- cardiac monitor leads on the left side of the chest and both arms
- an intravenous catheter in the left hand

RADIOGRAPHS

A complete set of postmortem radiographs is obtained and demonstrates the following:

- No skeletal, soft tissue, or internal organ injuries

ACLU Detainee DeathII ARMY MEDCOM 259

EVIDENCE OF INJURY

There is no evidence of injury. Dissection into both wrists and the back reveal no soft tissue evidence of trauma.

INTERNAL EXAMINATION

HEAD:
The galeal and subgaleal soft tissues of the scalp are free of injury. The calvarium is intact, as is the dura mater beneath it. Clear cerebrospinal fluid surrounds the 1340 gm brain, which has unremarkable gyri and sulci. Coronal sections demonstrate sharp demarcation between white and gray matter, without hemorrhage or contusive injury. The ventricles are of normal size. The basal ganglia, brainstem, cerebellum, and arterial systems are free of injury or other abnormalities. There are no skull fractures. The atlanto-occipital joint is stable.

NECK:
The anterior strap muscles of the neck are homogenous and red-brown, without hemorrhage. The thyroid cartilage and hyoid are intact. The larynx is lined by intact white mucosa. The thyroid is symmetric and red-brown, without cystic or nodular change. The tongue is free of bite marks, hemorrhage, or other injuries.

BODY CAVITIES:
The ribs, sternum, and vertebral bodies are visibly and palpably intact. No excess fluid is in the pleural, pericardial, or peritoneal cavities. The organs occupy their usual anatomic positions.

RESPIRATORY SYSTEM:
The right and left lungs weigh 700 and 640 gm, respectively. The external surfaces are smooth and deep red-purple. The pulmonary parenchyma is diffusely congested and edematous. No mass lesions or areas of consolidation are present.

CARDIOVASCULAR SYSTEM:
The 480 gm heart is contained in an intact pericardial sac. See Consultation Report from Cardiovascular Pathology, Armed forces Institute of Pathology (CVPath), Washington, D.C. below.

ACLU Detainee DeathII ARMY MEDCOM 260

Consultation Report:

Diagnosis: (b)(6) Heart, post mortem examination: Morphologically normal heart. See comment.

Heart weight: 480 grams; normal epicardial fat; probe-patent foramen ovale; left ventricular cavity diameter 45 m; left ventricular free wall thickness 13 mm; ventricular septum thickness 14 mm; right ventricle thickness 4 mm; right ventricle slightly dilated; left atrium mildly dilated with slightly thickened endocardium; valves grossly unremarkable, mitral valve shows minimal myxoid changes; no gross myocardial necrosis or fibrosis; histologic sections show focal autolytic changes.

Coronary arteries: Normal ostia; right dominance; no gross coronary atherosclerosis.

Comment: While the contributor reports an expected heart weight of 340 grams, without a body weight we cannot make a determination regarding the presence of cardiomegaly. As no other cardiac cause of death was identified, it would be important to accurately assess cardiomegaly, as this may be the only pathologic finding in some cases of sudden death.

Signed: (b)(6) Cardiovascular Pathologist, 7 December 2005

LIVER & BILIARY SYSTEM:
The 1850 gm liver has an intact, smooth capsule and a sharp anterior border. The parenchyma is tan-brown and congested, with the usual lobular architecture. No mass lesions or other abnormalities are seen. The gallbladder contains neither bile nor stones. The mucosal surface is green and velvety. The extrahepatic biliary tree is patent.

SPLEEN:
The 250 gm spleen has a smooth, intact, red-purple capsule. The parenchyma is maroon and congested, with distinct Malpighian corpuscles.

PANCREAS:
The pancreas is firm and yellow-tan, with the usual lobular architecture. No mass lesions or other abnormalities are seen.

ADRENALS:
The right and left adrenal glands are symmetric, with bright yellow cortices and red-brown medullae. No masses or areas of hemorrhage are identified.

ACLU Detainee DeathII ARMY MEDCOM 261

GENITOURINARY SYSTEM:
The right and left kidneys weigh 190 and 180 gm, respectively. The external surfaces are intact and smooth. The cut surfaces are red-tan and congested, with uniformly thick cortices and sharp corticomedullary junctions. The pelves are unremarkable and the ureters are normal in course and caliber. White bladder mucosa overlies an intact bladder wall. The bladder contains approximately 50 cc of clear urine. The prostate is normal in size, with lobular, yellow-tan parenchyma. The seminal vesicles are unremarkable. The testes are free of mass lesions, contusions, or other abnormalities.

GASTROINTESTINAL TRACT:
The esophagus is intact and lined by smooth, grey-white mucosa. The stomach contains approximately 250 ml of brown viscous fluid. The gastric wall is intact. The duodenum, loops of small bowel, and colon are unremarkable. The appendix is present.

ADDITIONAL PROCEDURES

1. Documentary photographs are taken by OAFME staff.
2. Personal effects are released to the appropriate mortuary operations representatives.
3. Specimens retained for toxicologic testing and/or DNA identification are: vitreous, urine, blood, psoas, adipose, brain, lung, liver, spleen, kidney, and gastric contents
4. The dissected organs are forwarded with body.
5. Identifying marks include a 1" scar on the back of the left hand extending to the little finger.

MICROSCOPIC EXAMINATION

Brain: No significant pathology
Heart: No significant pathology
Lungs: Congestion and polymicrobial overgrowth; no significant pathology
Liver: Mild steatosis; no significant pathology
Pancreas: Autolysis; no significant pathology
Spleen: Congested; no significant pathology
Kidney: Autolysis; no significant pathology
Thyroid: No significant pathology

ACLU Detainee DeathII ARMY MEDCOM 262

OPINION

This Iraqi detainee (b)(6) died of cardiomegaly. His heart weighed 480 grams and the expected heart weight for his size (168 pounds) is 340 grams with a range of 300 to 380 grams. He did not have a clinical history of hypertension and no other pathology was identified at autopsy, however, a large heart is an electrically unstable heart and is susceptible to fatal arrhythmias. No traumatic injuries were identified at autopsy. Petechial hemorrhages noted in the conjunctivae are likely to be peri-mortem in nature and related to the developing cardiac failure. Toxicology tests for ethanol and screened drugs of abuse and medications are negative. The manner of death is natural.

(b)(6)

(b)(6) **Medical Examiner** (b)(6)

ACLU Detainee DeathII ARMY MEDCOM 263

DEPARTMENT OF DEFENSE
ARMED FORCES INSTITUTE OF PATHOLOGY
WASHINGTON, DC 20306-6000

REPLY TO ATTENTION OF

AFIP (b)(6)

TO:

OFFICE OF THE ARMED FORCES MEDICAL EXAMINER
ARMED FORCES INSTITUTE OF PATHOLOGY
WASHINGTON, DC 20306-6000

PATIENT IDENTIFICATION
AFIP Accessions Number Sequence
(b)(6)
Name
AL ZOBAIE, ELANY D.

SSAN: **Autopsy:** (b)(6)
Toxicology Accession #: (b)(6)
Date Report Generated: October 25, 2005

CONSULTATION REPORT ON CONTRIBUTOR MATERIAL

AFIP DIAGNOSIS **REPORT OF TOXICOLOGICAL EXAMINATION**

Condition of Specimens: GOOD
Date of Incident: **Date Received:** 10/20/2005

VOLATILES: The **HEART BLOOD AND VITREOUS FLUID** were examined for the presence of ethanol at a cutoff of 20 mg/dL. No ethanol was detected.

DRUGS: The **HEART BLOOD** was screened for amphetamine, antidepressants, antihistamines, barbiturates, benzodiazepines, cannabinoids, chloroquine, mefloquine, cocaine, dextromethorphan, lidocaine, narcotic analgesics, opiates, phencyclidine, phenothiazines, sympathomimetic amines and verapamil by gas chromatography, color test or immunoassay. The following drugs were detected:

None were found.

(b)(6)
Office of the Armed Forces Medical Examiner

(b)(6)
Office of the Armed Forces Medical Examiner

ACLU Detainee DeathII ARMY MEDCOM 264

CERTIFICATE OF DEATH (OVERSEAS)
Acte de décès (D'Outre-Mer)

NAME OF DECEASED (Last, First, Middle) Nom du décédé (Nom et prénoms)	GRADE Grade	BRANCH OF SERVICE Arme	SOCIAL SECURITY NUMBER Numéro de l'Assurance Social
BTB Al Zobaie, Elawy, Dakhel		Civilian	(b)(6)
ORGANIZATION Organisation	NATION (e.g. United States) Pays: Iraq	DATE OF BIRTH Date de naissance: (b)(6) 1962	SEX Sexe: [X] MALE [ ] FEMALE

RACE Race		MARITAL STATUS Situation			RELIGION Culte		
	CAUCASOID Caucasique		SINGLE Célibataire		DIVORCED Divorcé		PROTESTANT Protestant
	NEGROID Negroide		MARRIED Marié		SEPARATED Séparé		CATHOLIC Catholique
X	OTHER (Specify) Autre (Spécifier)		WIDOWED Veuf				JEWISH Juif

OTHER (Specify) Autre (Spécifier)	X

NAME OF NEXT OF KIN Nom du plus proche parent	RELATIONSHIP TO DECEASED Parenté du décédé avec le sus
STREET ADDRESS Domicile à (Rue)	CITY OR TOWN OR STATE (Include ZIP Code) Ville (Code postal compris)

MEDICAL STATEMENT Déclaration médicale

CAUSE OF DEATH (Enter only one cause per line) Cause du décès (N'indiquer qu'une cause par ligne)		INTERVAL BETWEEN ONSET AND DEATH Intervalle entre l'attaque et le décès
DISEASE OR CONDITION DIRECTLY LEADING TO DEATH [1] Maladie ou condition directement responsable de la mort	Pending	
ANTECEDENT CAUSES — MORBID CONDITION, IF ANY, LEADING TO PRIMARY CAUSE Condition morbide, s'il y a lieu, menant à la cause primaire		
Symptômes précurseurs de la mort — UNDERLYING CAUSE, IF ANY, GIVING RISE TO PRIMARY CAUSE Condition morbide, s'il y a lieu, menant à la cause primaire		
OTHER SIGNIFICANT CONDITIONS [2] Autres conditions significatives [3]		

MODE OF DEATH Condition du décès	AUTOPSY PERFORMED Autopsie effectuée	CIRCUMSTANCES SURROUNDING DEATH DUE TO EXTERNAL CAUSES Circonstances de la mort succédan par des causes extérieures
NATURAL Mort naturelle	[X] YES Oui [ ] NO Non	Mode of Death: Pending
ACCIDENT Mort accidentelle	MAJOR FINDINGS OF AUTOPSY Conclusions principales de l'autopsie	
SUICIDE Suicide	NAME OF PATHOLOGIST Nom du pathologiste: (b)(6)	
HOMICIDE Homicide	(b)(6) DATE Date: 15 October 2005	AVIATION ACCIDENT Accident d'Avion: [ ] YES Oui [X] NO Non

DATE OF DEATH (day, month, year) Date du décès (le jour, le mois, l'année): (b)(6) 2005 (b)(6)

PLACE OF DEATH Lieu du décès: Iraq

I HAVE VIEWED THE REMAINS OF THE DECEASED AND DEATH OCCURRED AT THE TIME INDICATED AND FROM THE CAUSES AS STATED ABOVE.
J'ai examiné les restes mortels du dé funt je constate que le décès est survenu à l'heure indiquée et à la suite des causes énumérées ci-dessus.

NAME OF MEDICAL OFFICER Nom du médecin militaire ou du médecin assistant	TITLE OR DEGREE Titre ou diplôme
(b)(6)	Medical Examiner

GRADE Grade	INSTALLATION OR ADDRESS Installation ou adresse
(b)(6)	Dover AFB, Dover DE

DATE Date: 15OCT05 (b)(6)

[1] State disease, injury or complication which caused death. Do not enter mode of dying, such as heart failure, asphyxia, etc.
[2] State condition contributory to the death, but not related to the disease or condition causing it.
[1] Indiquer la nature de la maladie, de la blessure ou de la complication qui a provoqué la mort. Ne pas se contenter d'indiquer le mode de décès, tels qu'un arrêt du cœur, etc.
[2] Indiquer les conditions qui ont contribué à la mort, mais n'ayant aucun rapport avec la maladie ou la condition qui provoqué la mort.

DD FORM 1 APR 77 2064 REPLACES DA FORM 3566, 1 JAN 72 AND DA FORM 3565-R(AS), 26 SEP 74, WHICH ARE OBSOLETE.

(REMOVE, REVERSE AND RE-INSERT CARBONS BEFORE COMPLETING THIS SIDE)

DISPOSITON OF REMAINS

NAME OF MORTICIAN PREPARING REMAINS	GRADE	LICENSE NUMBER AND STATE	OTHER

INSTALLATION OR ADDRESS	DATE	SIGNATURE

NAME OF CEMETERY OR CREMATORY	LOCATION OF CEMETERY OR CREMATORY

TYPE OF DISPOSTION	DATE OF DISPOSTION

REGISTRATION OF VITAL STATISTICS

REGISTRY *(Town and Country)*	DATE REGISTERED	FILE NUMBER	
		STATE	OTHER

NAME OF FUNERAL DIRECTOR	ADDRESS

SIGNATURE OF AUTHORIZED INDIVIDUAL

DD FORM 2064, APR 1977 (BACK) *USAPA V1.00*

ACLU Detainee DeathII ARMY MEDCOM 266

ARMED FORCES INSTITUTE OF PATHOLOGY
Office of the Armed Forces Medical Examiner
1413 Research Blvd., Bldg. 102
Rockville, MD 20850
1-301-319-0000

AUTOPSY EXAMINATION REPORT

Name: Hamad-Mashadani, Abid-Es
ISN #: (b)(6)
Date of Birth: Unknown
Date of Death (b)(6) 2005
Date of Autopsy: 07 OCT 2005
Date of Report: 29 MAR 2006

Autopsy No.: (b)(6)
AFIP No. (b)(6)
Rank: Civilian
Place of Death: 344Th Field Hospital, Iraq
Place of Autopsy: Port Mortuary
Dover AFB, Dover, DE

Circumstances of Death: The decedent was a civilian detainee who was transferred to the 344th Field Hospital from a detention facility where he had been complaining of abdominal pain, diarrhea and vomiting. Upon arrival he was noted to have a markedly elevated white blood cell count (41.5 x 10^3), elevated blood sugar (440mg/dl) and elevated liver function tests. He was taken to the operating room where an exploratory laparotomy and cholecystectomy was performed for gangrenous cholecystitis. Post-operatively his condition worsened and he became unresponsive to resuscitative attempts.

Authorization for Autopsy: Armed Forces Medical Examiner, per 10 U.S. Code 1471

Identification: Identification is established by identification tags present on the body

CAUSE OF DEATH: Complications of acute gangrenous cholecystitis

MANNER OF DEATH: Natural

FINAL AUTOPSY DIAGNOSES

I. Acute gangrenous cholecystitis (per report).
   A. Status post exploratory laparotomy with cholecystectomy.

II. Respiratory system:
   A. Bilateral pulmonary congestion and edema (right 830 gm, left 720 gm)
   B. Bilateral pleural effusions (right 120 ml, left 180 ml)
   C. Scattered fibrin micro-thrombi

III. No evidence of trauma

IV. Moderate decompositonal changes consisting of green discoloration of the abdomen and vascular marbling

V. Toxicology: Metoclopramide is present in the blood.

ACLU Detainee DeathII ARMY MEDCOM 267

EXTERNAL EXAMINATION

The remains are received unclad. An identification bracelet containing the decedent's name and detainee number is on the right wrist. The body is accompanied by clothing consisting of a white undershirt, a pair of green knit shorts, a pair of yellow slacks and a pair of blue shower shoes.

The body is that of a well-developed, well-nourished appearing, male that weighs 189-pounds, is 67-inches in length, whose appearance is consistent with the reported age of 60 years. Lividity is fixed on the posterior surface of the body except in areas exposed to pressure. Rigor has passed. The temperature of the body is that of the refrigeration unit.

The scalp is covered with 1-1/4" wavy grey-black hair with male pattern balding. The head and neck are moderately congested. The face is covered with a short black-grey beard and moustache. The eyelids are closed with 2-1/4 x 1/2" surgical tape. The corneae are hazy. The irides are dark and the pupils are round and equal in diameter. The external auditory canals are free of abnormal secretions and foreign material. The ears are unremarkable. The nares are patent and the lips are atraumatic. The nose and maxillae are palpably stable. The teeth are in poor condition with a number of teeth remotely absent.

The neck is mobile and the trachea is midline. There are multiple acrochordons on the right side of the neck, 1/16-1/8" in greatest dimension. The chest is symmetric. The abdomen is protuberant. The genitalia are those of a normal adult, circumcised, male. The testes are descended and free of masses. Pubic hair is present in a normal distribution. The buttocks and anus are unremarkable. Evidence of medical intervention is described below.

The upper and lower extremities are symmetric and without clubbing or edema. There is a 1-1/2 x 1/4" irregular, hypopigmented scar with a 2" vertical linear extension at the 12 o'clock position on the lateral right knee. There is a 1" raised callus over the right lateral malleolus. (b)(6) (b)(6) tattoo (b)(6)

MEDICAL INTERVENTION

- An endotracheal tube appropriately placed
- An intravascular catheter in the right antecubital fossa, secured with a clear occlusive dressing, with "9/30 #20" written above the device
- A 2" area of ecchymosis on the distal, volar surface of the right wrist with 3 venipuncture marks
- A 1-1/4" area of ecchymosis on the dorsum of the right hand
- A 2 x 2" gauze dressing in the left antecubital fossa
- Secured with sutures are a triple lumen catheter in the left groin and an intravascular catheter in the right groin
- A 4 x 4" gauze dressing overlying a Jackson-Pratt drain in the right abdominal wall with 26" of 1/4" diameter tubing attached to a reservoir containing 40-milliliters of blood
- A 12 x 4" gauze covering a midline abdominal incision

ACLU Detainee DeathII ARMY MEDCOM 268

- A vertically oriented 10 x 1"incision, 7/8" in depth and packed with gauze, overlying a sutured abdominal incision that extends from the xiphoid process to 2" below and to the left of the umbilicus

RADIOGRAPHS

A complete set of postmortem radiographs is obtained and demonstrates the previously described medical interventions. There is no evidence of recent trauma.

EVIDENCE OF INJURY

There is no evidence of significant recent injury noted at the time of autopsy.

INTERNAL EXAMINATION

BODY CAVITIES:

The sternum is visibly and palpably intact. No excess fluid is present in the pericardium. There are bilateral serous, pleural effusions (right - 120-milliliters, left - 180-milliliters). Scattered adhesions involve the left lung and the chest wall. There is 300-milliliters of blood and clot in the right upper quadrant of the abdominal cavity. The gallbladder is surgically absent. The remaining organs occupy their usual anatomic positions.

HEAD:
The galeal and subgaleal soft tissues of the scalp are free of injury. The calvarium is intact, as is the dura mater beneath it. Markings on the internal table of the calvarium for the right middle meningeal artery are more pronounced on the right side. Clear cerebrospinal fluid surrounds the 1370 gm brain, which has unremarkable gyri and sulci. Coronal sections demonstrate sharp demarcation between white and grey matter, without hemorrhage or contusive injury. The ventricles are of normal size. The basal ganglia, brainstem, cerebellum, and arterial systems are free of injury or other abnormalities. There are no skull fractures. The atlanto-occipital joint is stable.

NECK:
The anterior strap muscles of the neck are homogenous and red-brown, without hemorrhage. The thyroid cartilage and hyoid are intact. The larynx is lined by intact white mucosa. The thyroid is symmetric and red-brown, without cystic or nodular change. The tongue is free of bite marks, hemorrhage, or other injuries.

RESPIRATORY SYSTEM:
The right and left lungs weigh 830 and 720 grams, respectively. The external surfaces are smooth and deep red-purple. The pulmonary parenchyma is diffusely congested and edematous. No mass lesions or areas of consolidation are present.

CARDIOVASCULAR SYSTEM:
The 390-gram heart is contained in an intact pericardial sac. The epicardial surface is smooth, with minimal fat investment. The coronary arteries are present in a normal distribution, with a right-dominant pattern. There is mild atherosclerotic streaking at the ostia for the right coronary artery and the left anterior descending artery. Cross sections of the vessels show no evidence of significant

ACLU Detainee DeathII ARMY MEDCOM 269

atherosclerosis or thrombosis. The myocardium is homogenous, red-brown, and firm. The valve leaflets are thin and mobile. The walls of the left and right ventricles are 1.1and 0.2-centimeters thick, respectively. The endocardium is smooth and glistening. The aorta gives rise to three intact and patent arch vessels. The renal and mesenteric vessels are unremarkable.

LIVER & BILIARY SYSTEM:
The 1880-gram liver has an intact, smooth capsule and a sharp anterior border. There is a 5-centimeter laceration of the lateral right lobe of the liver, without vital reaction. In the region of the gallbladder fossa is a 9 x 6-centimeter friable, hemorrhagic area with an intact surgical drain. The gallbladder had been previously sent for surgical pathology consultation following the patient's cholecystectomy. A diagnosis of acute gangrenous cholecystitis is made by the consulting pathologist. The remaining, non-surgical parenchyma is tan-brown and congested, with the usual lobular architecture. No mass lesions or other abnormalities are seen. The extrahepatic biliary tree is patent.

SPLEEN:
The 280-gram spleen has a smooth, intact, red-purple capsule. The parenchyma is maroon and congested, with distinct Malpighian corpuscles.

PANCREAS:
The pancreas is firm and yellow-tan, with the usual lobular architecture. Fatty infiltrate is noted throughout the pancreas. No mass lesions or other abnormalities are seen.

ADRENALS:
The right and left adrenal glands are symmetric, with bright yellow cortices and grey medullae. No masses are identified.

GENITOURINARY SYSTEM:
The right and left kidneys each weigh 80-grams. The external surfaces are intact and smooth. There is a 0.4-centimeter, benign cortical cyst on the superior pole of the left kidney. The cut surfaces are red-tan and congested, with uniformly thick cortices and sharp corticomedullary junctions. The pelves are unremarkable and the ureters are normal in course and caliber. White bladder mucosa overlies an intact bladder wall. The bladder contains no urine. The prostate is normal in size, with lobular, yellow-tan parenchyma. The seminal vesicles are unremarkable. The testes are free of mass lesions, contusions, or other abnormalities.

GASTROINTESTINAL TRACT:
The esophagus is intact and lined by smooth, grey-white mucosa. The stomach contains approximately 50-milliliters of dark brown, flocculant liquid. The gastric wall is intact. The duodenum, loops of small bowel, and colon are unremarkable. The appendix is present.

ADDITIONAL PROCEDURES

1. Documentary photographs are taken by the OAFME staff photographer.
2. Specimens retained for toxicologic testing and/or DNA identification are: vitreous, blood, gastric contents, spleen, liver, lung, kidney, adipose tissue and psoas.
3. Personal effects are released to the appropriate mortuary operations representatives.

ACLU Detainee DeathII ARMY MEDCOM 270

MICROSCOPIC EXAMINATION

1. Cardiovascular (Slides: 6, 9, 11,12,13): No significant microscopic abnormalities
2. Lungs, right and left (Slides: 1-5): Focal pulmonary edema and vascular congestion with scattered fibrin micro-thrombi
3. Endocrine (Slides: 2-4, 10): No significant microscopic abnormalities are noted in the pancreas, thyroid gland and adrenal glands
4. Gastrointestinal (Slides: 2, 6-8): Liver with mild to moderate steatosis with cholestasis
5. Genitourinary (Slides: 1, 6-8): Kidney with moderate glomerulonephrosclerosis and hemorrhage into the renal tubules. Bladder and prostate are unremarkable
6. Brain (Slide: 13): No significant microscopic abnormalities

OPINION

This reported 60 year-old male, civilian detainee died of complications of acute gangrenous cholecystitis. According to reports and medical records, the decedent was admitted to the hospital following a few days of abdominal pain, diarrhea and vomiting. Laboratory studies upon admission included an elevated white blood cell count, elevated blood glucose and elevated liver function tests. He underwent an exploratory laparotomy and cholecystectomy for acute gangrenous cholecystitis. He remained unstable post-operatively and despite aggressive resuscitative efforts the patient succumbed to his illness.

Autopsy examination showed a friable, hemorrhagic surgical site with approximately 300 ml of adjacent blood and clot. Histologic examination showed findings suggestive of disseminated intravascular coagulation (DIC) in the lungs. DIC is a potentially life threatening thrombohemorrhagic disorder that can be seen in association with a number of serious medical and surgical disease processes. Postmortem toxicologic analysis revealed only the presence of the therapeutic agent metoclopramide in the blood (0.3 mg/L).

Complicated cholecystitis (eg. gangrene) has a reported mortality rate of 25%. If perforation occurs, the mortality rate increases to 60%.[1] The manner of death is natural.

(b)(6)

(b)(6) Medical Examiner

(b)(6)

(b)(6) Medical Examiner (b)(6)

[1] Santen, S. Cholecystitis and Biliary Colic. March 15, 2005. http://www.emedicine.com/EMERG/topic98.htm

ACLU Detainee DeathII ARMY MEDCOM 271

CERTIFICATE OF DEATH *(OVERSEAS)*

Acte dé décès (D'Outre-Mer)

NAME OF DECEASED *(Last, First, Middle)* Nom du décédé (Nom et prénoms)	GRADE Grade	BRANCH OF SERVICE Arme	SOCIAL SECURITY NUMBER Numéro de l'Assurance Social
BTB Hamid-Mashadani , Abid-Es,		Civilian	(b)(6)
ORGANIZATION Organisation	NATION *(e.g. United States)* Pays: Iraq	DATE OF BIRTH Date de naissance	SEX Sexe: [X] MALE [ ] FEMALE

RACE Rece		MARITAL STATUS État Civil			RELIGION Culte		
X	CAUCASOID Caucasique		SINGLE Célibataire		DIVORCED Divorcé		PROTESTANT Protestant		OTHER (Specify) Autre (Spécifier)
	NEGROID Negriode		MARRIED Marié		SEPARATED Séparé		CATHOLIC Catholique	X	
	OTHER (Specify) Autre (Spécifier)		WIDOWED Veuf				JEWISH Juif		

NAME OF NEXT OF KIN Nom du plus proche parent	RELATIONSHIP TO DECEASED Parenté du décède avec le sus
STREET ADDRESS Domicilé à (Rue)	CITY OR TOWN OR STATE *(Include ZIP Code)* Ville (Code postal compris)

MEDICAL STATEMENT Déclaration médicale

	CAUSE OF DEATH (Enter only one cause per line) Cause du décès (N'indiquer qu'une cause par ligne)	INTERVAL BETWEEN ONSET AND DEATH Intervalle entre l'attaque et le décès
DISEASE OR CONDITON DIRECTLY LEADING TO DEATH [1] Maladie ou condition directement responsable de la mort [1]	Complications of acute gangrenous cholecystitis.	Hours
ANTECEDENT CAUSES Symptômes précurseurs de la mort. MORBID CONDITION, IF ANY, LEADING TO PRIMARY CAUSE Condition morbide, s'il y a lieu, menant à la cause primaire		
UNDERLYING CAUSE, IF ANY, GIVING RISE TO PRIMARY CAUSE Condition morbide, s'il y a lieu, menant à la cause primaire		
OTHER SIGNIFICANT CONDITIONS [2] Autres conditions significatives [2]		

MODE OF DEATH Condition de décès	AUTOPSY PERFORMED Autopsie effectuée [X] YES Oui [ ] NO Non	CIRCUMSTANCES SURROUNDING DEATH DUE TO EXTERNAL CAUSES Circonstances de la mort suscitées par des causes extérieures
X NATURAL Mort naturelle	MAJOR FINDINGS OF AUTOPSY Conclusions principales de l'autopsie	
ACCIDENT Mort accidentelle	NAME OF PATHOLOGIST Nom du pathologiste: (b)(6)	
SUICIDE Suicide	SIGNATURE Signature	DATE Date: 7 October 2005
HOMICIDE Homicide		AVIATION ACCIDENT Accident à Avion: [ ] YES Oui [X] NO Non

DATE OF DEATH *(day, month, year)* Date de décès (le jour, le mois, l'année)	PLACE OF DEATH Lieu de décès
(b)(6) 2005 (b)(6)	Iraq

I HAVE VIEWED THE REMAINS OF THE DECEASED AND DEATH OCCURRED AT THE TIME INDICATED AND FROM THE CAUSES AS STATED ABOVE
J'ai examiné les restes mortels du dé funtet je conclus que le décès est survenu à l'heure indiquée et à, la suite des causes énumérées ci-dessus.

NAME OF MEDICAL OFFICER Nom du médicin militaire ou du médicin sanitaire	TITLE OR DEGREE Titre ou diplômé
(b)(6)	Medical Examiner

GRADE Grade	INSTALLATION OR ADDRESS Installation ou adresse
(b)(6)	Dover AFB, Dover DE
DATE Date	SIGNATURE Signature

[1] State disease, injury or complication which caused death, but not mode of dying such as heart failure, ect.
[2] State conditions contributing to the death, but not related to the disease or condition causing death.
[1] Préciser la nature de la maladie, de la blessure ou de la complication qui a contribué à le mort, mais non la manière de mourir, telle qu 'un arrêt du coeur, etc
[2] Préciser la condition qui a contribué à la mort, mais n'ayant aucun rapport avec la maladie ou à la condition qui a provoqué la mort.

DD FORM 1 APR 77 2064 REPLACES DA FORM 3565, 1 JAN 72 AND DA FORM 3565-R(PAS), 26 SEP 75, WHICH ARE OBSOLETE.

MEDCOM 0272

ACLU Detainee DeathII ARMY MEDCOM 272

(REMOVE, REVERSE AND RE-INSERT CARBONS BEFORE COMPLETING THIS SIDE)

DISPOSITON OF REMAINS

NAME OF MORTICIAN PREPARING REMAINS	GRADE	LICENSE NUMBER AND STATE	OTHER

INSTALLATION OR ADDRESS	DATE	SIGNATURE

NAME OF CEMETERY OR CREMATORY	LOCATION OF CEMETERY OR CREMATORY

TYPE OF DISPOSTION	DATE OF DISPOSTION

REGISTRATION OF VITAL STATISTICS

REGISTRY *(Town and Country)*	DATE REGISTERED	FILE NUMBER	
		STATE	OTHER

NAME OF FUNERAL DIRECTOR	ADDRESS

SIGNATURE OF AUTHORIZED INDIVIDUAL

DD FORM 2064, APR 1977 (BACK) *USAPA V1.00*

ACLU Detainee DeathII ARMY MEDCOM 273

ARMED FORCES INSTITUTE OF PATHOLOGY
Office of the Armed Forces Medical Examiner
1413 Research Blvd., Bldg. 102
Rockville, MD 20850
1-800-944-7912

AUTOPSY EXAMINATION REPORT

Name: BTB Qader, Tahseen
SSAN: (b)(6)
Date of Birth: Unknown
Date of Death: (b)(6) 2005
Date of Autopsy: 18 SEP 2005
Date of Report: 11 Nov 2005

Autopsy No.: (b)(6)
AFIP No. (b)(6)
Rank: Iraq Detainee
Place of Death: Iraq
Place of Autopsy: Port Mortuary, Dover AFB, DE

Circumstances of Death: This Iraqi male was a detainee in U.S. custody who was found unresponsive in a forward detainee holding area in Iraq. As reported, on the day he died the deceased had been feeling ill and had vomited once. Subsequently, he drank water, ate some food, and went to sleep. He was later found unresponsive in the holding area.

Authorization for Autopsy: Armed Forces Medical Examiner, per 10 U.S. Code 1471

Identification: No scientific identification is available. Circumstantial identification is by accompanying paperwork and a detainee number present on a label around the right ankle.

CAUSE OF DEATH: Acute Myocardial Infarction

MANNER OF DEATH: Natural

ACLU Detainee DeathII ARMY MEDCOM 274

FINAL AUTOPSY DIAGNOSES:

I. **Atherosclerotic Cardiovascular Disease:**
   A. **Multifocal acute and healed myocardial infarctions, circumferential left ventricle, associated with intramural coronary artery thromboemboli (see full Cardiovascular Pathology consultation)**
   B. **Focal severe coronary atherosclerosis, acute and healed plaque erosions with occlusive thrombosis extending from the left main coronary artery to mid left anterior descending artery**

II. **Pulmonary System:**
   A. **Markedly congested and firm lungs with moderate anthracosis (left lung – 750-grams; right lung – 790-grams)**
   B. **Extensive adhesions involving both lungs and the chest wall**

III. **A 1 ½-inch purple contused-abrasion over the left iliac crest and a 1 ½-inch purple contused-abrasion over the right iliac crest**

IV. **No evidence of significant recent injury**

V. **Early decomposition changes, including vascular marbling, green discoloration of the skin over the abdomen and early autolysis of the pancreas and adrenal glands**

VI. **TOXICOLOGY (AFIP):**
   A. **CARBON MONOXIDE: The Carboxyhemoglobin saturation in the blood is less than 1% as determined by spectrophotometry with a limit of quantitation of 1%**
   B. **VOLATILES: The blood and urine are examined for the presence of ethanol at a cutoff of 20-milligrams/deciliter. No ethanol is detected**
   C. **CYANIDE: There is no cyanide detected in the blood. The limit of quantitation for cyanide is 0.25-milligrams/liter**
   D. **URINE: The urine is screened for acetaminophen, amphetamine, antidepressants, antihistamines, barbiturates, benzodiazepines, cannabinoids, chloroquine, cocaine, dextromethorphan, lidocaine, narcotic analgesics, opiates, phencyclidine, phenothiazines, salicylates, sympathomimetic amines and verapamil by gas chromatography, color test or immunoassay and none are detected**

ACLU Detainee DeathII ARMY MEDCOM 275

EXTERNAL EXAMINATION

The remains are received with clothing and personal effects as noted below. The body is that of a well-developed, well-nourished appearing, 65 1/2-inches, 131- pounds male whose appearance is consistent with an estimated age of forty to fifty years. Lividity is present and fixed on the posterior surface of the body except in areas exposed to pressure. Rigor has passed and the temperature of the body is that of the refrigeration unit.

The scalp is covered with medium length, brown hair in a normal distribution. The irides are brown, and the pupils are round and equal in diameter. The external auditory canals are free of foreign material and abnormal secretions. The ears are unremarkable. The nares are patent and the lips are atraumatic. The nose and maxillae are palpably stable. The teeth are in fair condition.

The neck is straight, and the trachea is midline and mobile. The chest is symmetric. The abdomen is flat. The genitalia are those of a normal adult male. The testes are descended and free of masses. Pubic hair is present in a normal distribution. The buttocks and anus are unremarkable.

The upper and lower extremities are symmetric and without clubbing or edema.

Tattoos (b)(6)
(b)(6)

Encircling the right ankle is a piece of green tape that is inscribed with
(b)(6)

CLOTHING AND PERSONAL EFFECTS

The following clothing items and personal effects are present on the body at the time of autopsy:

- Off-white long white shirt
- White cloth pants
- Yellow t-shirt
- Red and blue "Nike" shorts
- Tan burlap bag
- Key chain with keys
- Watch
- Lighter
- Cigarettes
- 5000 Dinar banknote

MEDICAL INTERVENTION

There are no attached medical devices at the time of autopsy.

ACLU Detainee DeathII ARMY MEDCOM 276

RADIOGRAPHS

A complete set of postmortem radiographs is obtained and demonstrates an absence of acute skeletal trauma and metallic foreign bodies.

EVIDENCE OF INJURY

A 1 ½-inch purple contused-abrasion is on the area of the left iliac crest and a 1 ½-inch purple contused-abrasion on the area of the right iliac crest

INTERNAL EXAMINATION

HEAD:
The galeal and subgaleal soft tissues of the scalp are free of injury. The calvarium is intact, as is the dura mater beneath it. Clear cerebrospinal fluid surrounds the 1380-gram brain, which has unremarkable gyri and sulci. Coronal sections demonstrate sharp demarcation between white and grey matter, without hemorrhage or contusive injury. The ventricles are of normal size. The basal ganglia, brainstem, cerebellum, and arterial systems are free of injury or other abnormalities. There are no skull fractures. The atlanto-occipital joint is stable.

NECK:
The anterior strap muscles of the neck are homogenous and red-brown, without hemorrhage. The thyroid cartilage and hyoid are intact. The larynx is lined by intact white mucosa. The thyroid is symmetric and red-brown, without cystic or nodular change. The tongue is free of bite marks, hemorrhage, or other injuries.

BODY CAVITIES:
The ribs, sternum, and vertebral bodies are visibly and palpably intact. No excess fluid is in the pleural, pericardial, or peritoneal cavities. The organs occupy their usual anatomic positions.

RESPIRATORY SYSTEM:
The right and left lungs weigh 750-grams and 790-grams, respectively. The external surfaces are deep red-purple, with adhesions involving both lungs and the chest wall. The pulmonary parenchyma is markedly congested and firm with moderate anthracosis. No mass lesions or areas of consolidation are present.

CARDIOVASCULAR SYSTEM:
The 350-gram heart is contained in an intact pericardial sac. The epicardial surface is smooth, with minimal fat investment. The coronary arteries are present in a normal distribution, with a right-dominant pattern. Cross sections of the vessels show 75% narrowing of the left main coronary artery by atheromatous plaque, 90% narrowing of the left anterior descending coronary artery by atheromatous plaque and no significant luminal narrowing of the left circumflex artery and the right coronary artery. There is early myocardium decomposition with focal myocardial scar in the inferior posterior left ventricle. The valve leaflets are thin and mobile. The walls of the left and right ventricles are 10-millimeters and 5-millimeters thick, respectively. The endocardium is

ACLU Detainee DeathII ARMY MEDCOM 277

smooth and glistening. The aorta gives rise to three intact and patent arch vessels. The renal and mesenteric vessels are unremarkable. (See Cardiovascular Pathology consultation report)

LIVER & BILIARY SYSTEM:
The 1510-gram liver has an intact, smooth capsule and a sharp anterior border. The parenchyma is tan-brown and congested, with the usual lobular architecture. No mass lesions or other abnormalities are seen. The gallbladder contains 15-milliliterts of green-black bile and no stones. The mucosal surface is green and velvety. The extrahepatic biliary tree is patent.

SPLEEN:
The 340-gram spleen has a smooth, intact, red-purple capsule. The parenchyma is maroon and congested, with distinct Malpighian corpuscles.

PANCREAS:
The pancreas is yellow-tan, with the usual lobular architecture and early decomposition changes. No mass lesions or other abnormalities are seen.

ADRENALS:
The right and left adrenal glands are symmetric, with bright yellow cortices, grey medullae, and early decomposition changes. No masses or areas of hemorrhage are identified.

GENITOURINARY SYSTEM:
The right and left kidneys each weighed 180-grams. The external surfaces are intact and smooth. The cut surfaces are red-tan and congested, with uniformly thick cortices and sharp corticomedullary junctions. The pelves are unremarkable and the ureters are normal in course and caliber. White bladder mucosa overlies an intact urinary bladder wall. The bladder contains approximately 40-milliliters of dark yellow urine. The prostate gland is normal in size, with lobular, yellow-tan parenchyma. The seminal vesicles are unremarkable. The testes are free of mass lesions, contusions, or other abnormalities.

GASTROINTESTINAL TRACT:
The esophagus is intact and lined by smooth, grey-white mucosa. The stomach contains approximately 100-milliliters of pink fluid. The gastric wall is intact. The duodenum, loops of small bowel, and colon are unremarkable. The appendix is present.

ACLU Detainee DeathII ARMY MEDCOM 278

MICROSCOPIC EXAMINATION

Cardiovascular System (As per cardiovascular Pathology consultation):
Histological sections of the myocardium show multifocal areas of acute myocardial infarction of the anterior, lateral and posterior left ventricle, with coagulative necrosis, contraction bands and interstitial acute inflammatory infiltrates consisting predominately of neutrophils. Multiple intramural platelet-rich thromboemboli are also present and associated with multiple foci of granulation tissue and well-healed scars.

Histologic sections of the left main coronary artery show 75% narrowing by calcified fibroatheroma with healed plaque erosion showing proteoglycan-rich neointimal thickening and overlying acute erosion with occlusive platelet rich thrombus.

Histologic sections of the left anterior descending artery (LAD) show 90% narrowing of the proximal LAD by healed erosion with proteoglycan-rich neointimal thickening and overlying acute erosion and occlusive platelet-rich thrombus

Histologic sections of the left circumflex artery (LCA) show a platelet rich thromboembolus in the proximal LCA, but no significant luminal narrowing.

ADDITIONAL PROCEDURES/REMARKS

- Documentary photographs are taken by OAFME staff photographers.
- Specimens retained for toxicology testing and/or DNA identification are: heart blood, urine, vitreous fluid, spleen, liver, lung, brain, bile, gastric contents, kidney, adipose, and psoas muscle.
- The dissected organs are forwarded with the body.
- Selected portions of organs are retained in formalin.
- Personal effects are released to the appropriate mortuary operations representatives.
- Identifying marks include: tattoos and scars

ACLU Detainee Death|| ARMY MEDCOM 279

OPINION

This Iraqi male detainee died of an acute myocardial infarction. The autopsy disclosed evidence of severe atherosclerotic coronary artery disease, with changes of acute and remote infarcts present in the heart. The coronary arteries had focal severe atherosclerosis with an occlusive thrombosis extending from the left main coronary artery to the mid left anterior descending artery. Toxicology was negative for screened drugs of abuse, ethanol, and exposure to cyanide or carbon monoxide. The manner of death is natural.

(b)(6)

(b)(6) Medical Examiner

(b)(6)

(b)(6) Medical Examiner

ACLU Detainee DeathII ARMY MEDCOM 280

CERTIFICATE OF DEATH *(OVERSEAS)*
Acte de décès (D'Outre-Mer)

NAME OF DECEASED *(Last, First, Middle)* Nom du décédé (Nom et prénoms)	GRADE Grade	BRANCH OF SERVICE Arme	SOCIAL SECURITY NUMBER Numéro de l'Assurance Sociale
BTB Qader, Tahseen, Abdal		Civilian	(b)(6)
ORGANIZATION Organisation	NATION *(e.g. United States)* Pays: Iraq	DATE OF BIRTH Date de naissance	SEX Sexe: [X] MALE [ ] FEMALE

RACE Race		MARITAL STATUS État Civil			RELIGION Culte		
[X]	CAUCASOID Caucasique	[ ]	SINGLE Célibataire	[ ] DIVORCED Divorcé	[ ] PROTESTANT Protestant	[X]	OTHER (Specify) Autre (Spécifier)
[ ]	NEGROID Negroïde	[ ]	MARRIED Marié	[ ] SEPARATED Séparé	[ ] CATHOLIC Catholique		
[ ]	OTHER (Specify) Autre (Spécifier)	[ ]	WIDOWED Veuf		[ ] JEWISH Juif		

NAME OF NEXT OF KIN Nom du plus proche parent

RELATIONSHIP TO DECEASED Parenté du décédé avec le sus

STREET ADDRESS Domicile à (Rue)

CITY OR TOWN OR STATE *(Include ZIP Code)* Ville (Code postal compris)

MEDICAL STATEMENT Déclaration médicale

CAUSE OF DEATH (Enter only one cause per line) Cause du décès (N'indiquer qu'une cause par ligne)		INTERVAL BETWEEN ONSET AND DEATH Intervalle entre l'attaque et le décès
DISEASE OR CONDITON DIRECTLY LEADING TO DEATH[1] Maladie ou condition directement responsable de la mort.	Acute Myocardial Infarction	
ANTECEDENT CAUSES Symptômes précurseurs de la mort — MORBID CONDITION, IF ANY, LEADING TO PRIMARY CAUSE Condition morbide, s'il y a lieu, menant à la cause primaire		
ANTECEDENT CAUSES Symptômes précurseurs de la mort — UNDERLYING CAUSE, IF ANY, GIVING RISE TO PRIMARY CAUSE Condition morbide, s'il y a lieu, menant à la cause primaire		
OTHER SIGNIFICANT CONDITIONS[2] Autres conditions significatives[2]		

MODE OF DEATH Condition de décès		AUTOPSY PERFORMED Autopsie effectuée [X] YES Oui [ ] NO Non	CIRCUMSTANCES SURROUNDING DEATH DUE TO EXTERNAL CAUSES Circonstances de la mort suscitées par des causes extérieures
[X]	NATURAL Mort naturelle	MAJOR FINDINGS OF AUTOPSY Conclusions principales de l'autopsie	
[ ]	ACCIDENT Mort accidentelle		
[ ]	SUICIDE Suicide	NAME OF PATHOLOGIST Nom du pathologiste (b)(6)	
[ ]	HOMICIDE Homicide	(b)(6) DATE Date: 19 September 2005	AVIATION ACCIDENT Accident d'Avion: [ ] YES Oui [X] NO Non

DATE OF DEATH *(day, month, year)* Date du décès (le jour, le mois, l'année): (b)(6) 4 2005 (b)(6)

PLACE OF DEATH Lieu de décès: Tal Afar Iraq

I HAVE VIEWED THE REMAINS OF THE DECEASED AND DEATH OCCURRED AT THE TIME INDICATED AND FROM THE CAUSES AS STATED ABOVE
J'ai examiné les restes mortels du défunt je conclus que le décès est survenu à l'heure indiquée et à la suite des causes énumérées ci-dessus.

NAME OF MEDICAL OFFICER Nom du médicin militaire ou du médicin sanitaire	TITLE OR DEGREE Titre ou diplôme	GRADE Grade	INSTALLATION OR ADDRESS Installation ou adresse
(b)(6)	Medical Examiner	(b)(6)	Dover AFB, Dover DE (b)(6)

DATE Date: 3 JAN 2006

[1] State disease, injury or complication which caused death
[2] State conditions contributing to the death, but not related
[1] Préciser la nature de la maladie, de la blessure ou de la
[2] Préciser la condition qui a contribué à la mort, mais n'a

DD FORM 1 APR 77 2064 REPLACES DA

MEDCOM 0281

ACLU Detainee DeathII ARMY MEDCOM 281

(REMOVE, REVERSE AND RE-INSERT CARBONS BEFORE COMPLETING THIS SIDE)

DISPOSITON OF REMAINS

NAME OF MORTICIAN PREPARING REMAINS	GRADE	LICENSE NUMBER AND STATE	OTHER

INSTALLATION OR ADDRESS	DATE	SIGNATURE

NAME OF CEMETERY OR CREMATORY	LOCATION OF CEMETERY OR CREMATORY

TYPE OF DISPOSTION	DATE OF DISPOSTION

REGISTRATION OF VITAL STATISTICS

REGISTRY *(Town and Country)*	DATE REGISTERED	FILE NUMBER	
		STATE	OTHER

NAME OF FUNERAL DIRECTOR	ADDRESS

SIGNATURE OF AUTHORIZED INDIVIDUAL

DD FORM 2064, APR 1977 (BACK) *USAPA V1.00*

ACLU Detainee DeathII ARMY MEDCOM 282

ARMED FORCES INSTITUTE OF PATHOLOGY
Office of the Armed Forces Medical Examiner
1413 Research Blvd., Bldg. 102
Rockville, MD 20850
1-301-319-0000

AUTOPSY EXAMINATION REPORT

Name: BTB Hammed, Johar Nasir
Internment Serial Number (b)(6)
Date of Birth: Unknown
Date of Death: (b)(6) 2005
Date of Autopsy: 06 SEP 2005
Date of Report: 29 MAY 2006

Autopsy No.: (b)(6)
AFIP No.: (b)(6)
Rank: Civilian
Place of Death: Camp Anaconda, Iraq
Place of Autopsy: Port Mortuary
Dover AFB, DE

Circumstances of Death: This believed to be 65 year old Iraqi male civilian detainee died from an acute intracerebral hemorrhage that occurred on 29 AUG 2005, after being detained by American forces. According to the CID investigation of the decedent's death the decedent was detained in the early morning hours on 29 AUG 2005 and suffered some abrasions and contusions by offering moderate resistance during his apprehension. Upon arrival to the detention center at approximately 0730 hrs, the decedent was reported to be awake, alert and oriented. A detention center medical team evaluated the decedent approximately 3 hours after arrival and cleared him medically. At about noon the same day, the decedent entered a portable toilet under his own power and without difficulty. Upon exiting the toilet, the decedent was witnessed to stagger and appeared dis-oriented with slurring of his speech. The decedent was transported to the local medical facility for treatment of a suspected cerebrovascular accident (stroke). The decedent was diagnosed with an acute intracerebral bleed. The decedent was hospitalized for treatment and died on (b)(6) 06.

Authorization for Autopsy: Office of the Armed Forces Medical Examiner, IAW 10 USC 1471.

Identification: Presumptive identification is established by the internment serial number and accompanying records.

CAUSE OF DEATH: Acute Cerebrovascular Accident due to Amyloid Angiopathy

MANNER OF DEATH: Natural

ACLU Detainee DeathII ARMY MEDCOM 283

FINAL AUTOPSY DIAGNOSES:

I. Acute Intracerebral Hemorrhage

A. Acute Intracerebral Hemorrhage
1. An approximately 8 x 8 cm area of necrotic brain tissue in the right parietal lobe of the brain surrounds an intraventricular hematoma that extends to the inferior surface of the right cerebral hemisphere and is associated with approximately 30 to 40 ml of collectible subdural clotted blood and an additional 20 to 30 ml of subdural hematoma that is loosely adherent to the posterior dura mater and the superior surface of the tentorium cerebelli. The right cingulate gyrus is prominent and distorts the falx cerebri. The cerebellar tonsils are prominent. The basilar artery has minimal atherosclerosis and there are no gross aneurysms of the cerebral arteries.
2. Neuropathology consultation reveals an acute parenchymal hemorrhage of the right inferior temporal-occipital region due to amyloid angiopathy (see full consultation report below)

II. Blunt Force Injuries

A. Injuries of the Head
1. A 9.4 x 3.8 cm abraded contusion of the right cheek
2. A 4.0 x 1.0 cm area of purple discoloration of the inferior aspect of the right eye socket, probable contusion
3. A 1.4 x 1.0 cm abrasion with laceration of the lower left lip associated with a 2.0 x 2.0 cm ecchymosis of the buccal mucosa
4. A 5.2 x 2.3 cm contusion of the strap muscles of the left side of the neck, extends down to left side of thyroid cartilage
5. A 2.7 x 2.5 cm contusion of the lateral aspect of the right neck
6. An approximately 5.0 x 3.0 cm resolving subgaleal contusion (probable) of the left parietal scalp

B. Injuries of the Torso
1. Four contusions surround the right nipple, ranging in size from 0.3 x 0.3 cm to 4.6 x 2.5 cm
2. A 2.0 x 1.5 cm contusion is on the medial left chest
3. A 6.0 x 2.0 cm abraded contusion is on the right flank, overlying the anterior iliac crest
4. A 6.2 x 4.1 cm contusion is on the left buttock
5. A 1.5 x 1.0 cm contusion over the sternum, identified on dissection
6. A 2.2 x 1.2 cm contusion of the right chest wall, identified on dissection

ACLU Detainee DeathII ARMY MEDCOM 284

C. Injuries of the Extremities

1. A 2.4 x 1.4 cm contusion of the right shoulder
2. A 6.0 x 4.0 cm contusion of the left upper arm, over the left biceps
3. A 3.0 x 1.5 cm contusion of the lateral left forearm
4. A 0.5 x 0.3 cm abrasion of the posterior left wrist
5. A 2.5 x 1.0 cm abrasion on the medial aspect of the right wrist
6. A 0.4 x 0.4 cm crusted abrasion of the left fourth finger
7. A 1.5 x 1.0 cm abrasion of the left knee
8. A 2.5 x 1.5 cm area of abraded callused skin of the left knee
9. A 7.0 x 2.0 cm contusion of the medial aspect of the left ankle
10. A 10.8 x 0.9 cm abrasion of the anterior aspect of the left ankle extending to the left foot
11. A 4.0 x 2.0 cm area of abraded skin on the medial aspect of the left foot
12. A 1.5 x 1.5 cm and a 2.5 x 0.5 cm contusion of the left great toe
13. A 0.7 x 0.7 cm laceration of the medial aspect of the right foot

III. Injuries Suggestive of Wrist Restraint

1. A 2.8 x 0.2 cm patterned linear abrasion of the right wrist that is 0.5 cm apart from a parallel 2.0 x 0.2 cm linear abrasion of the right wrist
2. A 1.1 x 0.5 cm patterned linear abrasion of the anterior right wrist that is 0.5 cm apart from a linear 0.5 x 0.1 cm abrasion of the anterior right wrist
3. A 1.8 x 0.2 cm abrasion of the medial right wrist
4. A 1.2 x 0.2 cm abrasion of the medial right wrist

IV. Evidence of Probable Medical Intervention

1. A 7.0 x 3.0 cm ecchymosis of the anterior left forearm
2. A 7.0 x 3.0 cm ecchymosis of the posterior surface of the left hand
3. A 7.0 x 2.0 cm ecchymosis of the posterior right forearm
4. A 0.7 x 0.7 cm ecchymosis of the lateral right wrist
5. Segment of bio-occlusive dressing on the anterior left wrist

V. Other Autopsy Findings

1. Cardiomegaly (480 grams) with bilateral ventricular dilation
2. Mild atherosclerosis (25% stenosis) of the right coronary artery and minimal abdominal aortic atherosclerosis
3. Bilateral pulmonary edema
4. Liver hemangioma (2.0 x 1.5 cm)
5. Splenomegaly (1120 grams)
6. Renal cortical cyst (3.2 cm in diameter) and granular renal cortical surfaces
7. Moderate to severe trabeculation of the urinary bladder with diverticuli formation
8. Multiple prostatic concretions

ACLU Detainee DeathII ARMY MEDCOM 285

VI. Identifying Marks
1. A 4.0 x 0.3 cm horizontal scar of the left costal margin
2. A 2.1 x 1.0 cm seborrheic keratosis of the back
3. A 1.0 x 1.0 cm callus of the anterior surface of the right foot
4. Black ink writing on (b)(6)

VII. Toxicology is negative for ethanol, cyanide and screened drugs of abuse. The blood contains 0.22 mg/L of morphine and 2% carboxyhemoglobin (normal for non-smokers 0-3% and smokers 3-10%)

EXTERNAL EXAMINATION

The body is received wrapped in a white bed sheet and is that of a well-developed appearing 70 inch long, 161 pounds Iraqi National male whose appearance is consistent with the reported age of 65 years. Lividity is fixed along the left side of the body and posterior surface. Rigor is easily broken in the extremities.

The scalp is covered with gray with admixed black hair in a normal distribution with male patterned baldness. The medial conjunctiva of each eye is moderately edematous and slightly yellow. The irides are brown and the pupils are round and equal in diameter (6 mm). The external auditory canals are free of abnormal secretions. The ears are unremarkable. The nares are patent. The frenula of the lips are intact. The nose and maxillae are palpably stable. The facial hair consists of a gray and black mustache and a gray stubble beard. The teeth appear natural and in fair repair.

The neck is straight, and the trachea is midline and mobile. The chest is symmetric. There are several contusions of the chest described below. The abdomen is flat and free of any gross injuries. The genitalia are those of a circumcised, normal adult male. The testes are descended and free of masses. Pubic hair is present in a normal distribution. The buttocks and anus are unremarkable.

The upper and lower extremities are symmetric and without clubbing or edema. Injuries of the extremities are described below.

CLOTHING AND PERSONAL EFFECTS

The body is received for examination without clothing or personal effects

MEDICAL INTERVENTION

The following findings represent possible prior intravascular access sites:

1. A 7.0 x 3.0 cm ecchymosis of the anterior left forearm
2. A 7.0 x 3.0 cm ecchymosis of the posterior surface of the left hand
3. A 7.0 x 2.0 cm ecchymosis of the posterior right forearm
4. A 0.7 x 0.7 cm ecchymosis of the lateral right wrist

ACLU Detainee DeathII ARMY MEDCOM 286

5. A segment of bio-occlusive dressing on the anterior left wrist

RADIOGRAPHS

A complete set of postmortem radiographs is obtained and demonstrates neither acute or remote fractures nor any foreign bodies.

EVIDENCE OF INJURY

Blunt Force Trauma Injuries

Injuries of the Head:
A 9.4 x 3.8 cm abraded contusion is on the right cheek, immediately in front of the right ear. A 4.0 x 1.0 cm area of purple discoloration is along the inferior aspect of the right eye socket, representing a probable contusion. There is a 1.4 x 1.0 cm abrasion with a laceration of the lower left lip associated with a 2.0 x 2.0 cm ecchymosis of the buccal mucosa. This area is most likely secondary to blunt trauma, although the possibility of this injury being secondary to endotracheal intubation cannot be excluded. A 5.2 x 2.3 cm contusion of the strap muscles of the left side of the neck extends down to left side of thyroid cartilage. A 2.7 x 2.5 cm contusion is on the lateral aspect of the right neck. On the subgaleal membranes of the left parietal scalp is an approximately 5.0 x 3.0 cm area of a probable resolving contusion.

Injuries of the Torso:
Four contusions surround the right nipple, ranging in size from 0.3 x 0.3 cm to 4.6 x 2.5 cm. A 1.5 x 1.0 cm contusion is over the sternum and a 2.0 x 1.5 cm contusion is on the medial left chest. A 2.2 x 1.2 cm contusion of the right chest wall is revealed on examination of the intercostal muscles. A 6.0 x 2.0 cm abraded contusion is on the right flank, overlying the anterior iliac crest and a 6.2 x 4.1 cm contusion is on the left buttock.

Injuries of the Extremities:
A 2.4 x 1.4 cm contusion is on the right shoulder and a 6.0 x 4.0 cm contusion is on the left upper arm, over the left biceps muscle. A 3.0 x 1.5 cm contusion is on the lateral left forearm and there is a 0.5 x 0.3 cm abrasion of the posterior left wrist. A 0.4 x 0.4 cm crusted abrasion is on the left fourth finger. On the medial aspect of the right wrist is a 2.5 x 1.0 cm abrasion. On the left knee are a 1.5 x 1.0 cm abrasion of the left knee and a 2.5 x 1.5 cm area of abraded callused skin of the left knee. The left ankle and foot have a 7.0 x 2.0 cm contusion on the medial aspect of the left ankle, a 10.8 x 0.9 cm abrasion of the anterior aspect of the left ankle that extends the left foot, a 4.0 x 2.0 cm area of abraded skin is on the medial aspect of the left foot and a 1.5 x 1.5 cm and a 2.5 x 0.5 cm contusion of the left great toe. A 0.7 x 0.7 cm laceration is on the medial aspect of the right foot.

Injuries Suggestive of Wrist Restraint:
On the posterior surface of the right wrist is a 2.8 x 0.2 cm patterned linear abrasion that is 0.5 cm apart from a parallel 2.0 x 0.2 cm linear abrasion. A 1.1 x 0.5 cm patterned linear abrasion of the anterior right wrist is 0.5 cm apart from a linear 0.5 x 0.1 cm abrasion of the

ACLU Detainee DeathII ARMY MEDCOM 287

anterior right wrist. On the medial aspect of the right wrist are a 1.8 x 0.2 cm abrasion and a 1.2 x 0.2 cm abrasion.

INTERNAL EXAMINATION

HEAD:
The calvarium is intact, as is the dura mater beneath it. Bloody cerebrospinal fluid surrounds the 1420 gm brain. There are no skull fractures. The atlanto-occipital joint is stable.

An approximately 8 x 8 cm area of necrotic brain tissue in the right parietal lobe of the brain surrounds an intraventricular hematoma that extends to the inferior surface of the right cerebral hemisphere and is associated with approximately 30 to 40 ml of collectible subdural clotted blood and an additional 20 to 30 ml of subdural hematoma that is loosely adherent to the posterior dura mater and the superior surface of the tentorium cerebelli. The right cingulate gyrus is prominent and distorts the falx cerebri. The cerebellar tonsils are prominent. The basilar artery has minimal atherosclerosis and there are no gross aneurysms of the cerebral arteries. Neuropathology consultation reveals an acute parenchymal hemorrhage of the right inferior temporal-occipital region due to amyloid angiopathy (see full consultation report below)

NECK:
The thyroid cartilage and hyoid bone are intact. The larynx is lined by intact white mucosa. The thyroid gland is symmetric and red-brown, without cystic or nodular change. The tongue is free of bite marks, hemorrhage, or other injuries.

BODY CAVITIES:
The ribs, sternum, and vertebral bodies are visibly and palpably intact. No excess fluid is in the pleural, pericardial, or peritoneal cavities. The organs occupy their usual anatomic positions.

RESPIRATORY SYSTEM:
The right and left lungs weigh 990 and 930 gm, respectively. The external surfaces are smooth and deep red-purple. The pulmonary parenchyma is moderately to severely congested and edematous. No mass lesions or areas of consolidation are present.

CARDIOVASCULAR SYSTEM:
The 490 gm heart is contained in an intact pericardial sac. The epicardial surface is smooth, with minimal fat investment. The coronary arteries are present in a normal distribution, with a right-dominant pattern. Cross sections of the vessels show mild (25% stenosis) atherosclerosis of the right coronary artery. The left coronary artery and its branches are free of atherosclerosis. The myocardium is homogenous, red-brown, and soft. The left ventricle is grossly dilated. The valve leaflets are thin and mobile. The walls of the left and right ventricles are 1.2 and 0.2-cm thick, respectively. The endocardium is smooth and glistening. The aorta gives rise to three intact and patent arch vessels. The renal and mesenteric vessels are unremarkable.

ACLU Detainee DeathII ARMY MEDCOM 288

LIVER & BILIARY SYSTEM:
The 1930 gm liver is enlarged and has an intact, smooth capsule and a sharp anterior border. The parenchyma is tan-brown and congested, with the usual lobular architecture. A 2.0 x 1.5 cm area of the inferior portion of the right lobe of the liver is consistent with a hemangioma. The gallbladder contains a minute amount of green-black bile and no stones. The gallbladder mucosal surface is green and velvety. The extrahepatic biliary tree is patent.

SPLEEN:
The 1120 gm spleen is massively enlarged and has a smooth, intact, red-purple capsule. The parenchyma is maroon and congested, with distinct Malpighian corpuscles. There are no masses within the parenchyma.

PANCREAS:
The pancreas is firm and yellow-tan, with the usual lobular architecture. No mass lesions or other abnormalities are seen.

ADRENALS:
The right and left adrenal glands are symmetric, with bright yellow cortices and grey medullae. No masses or areas of hemorrhage are identified.

GENITOURINARY SYSTEM:
The right and left kidneys weigh 130 and 160 gm, respectively. The external surface of the right kidney is intact and smooth. The left kidney contains a 3.2 cm diameter simple cyst. The cut surfaces are red-tan and congested, with uniformly thick cortices and sharp corticomedullary junctions. The pelves are unremarkable and the ureters are normal in course and caliber. A white bladder mucosal overlies a severely trabeculated bladder wall that has several diverticuli. The bladder contains a scant amount of urine. The prostate is normal in size, with lobular, yellow-tan parenchyma and multiple concretions. The seminal vesicles are unremarkable. The testes are free of mass lesions, contusions, or other abnormalities.

GASTROINTESTINAL TRACT:
The esophagus is intact and lined by smooth, grey-white mucosa. The stomach contains approximately 80-90 ml of cloudy white liquid. The gastric wall is intact. The duodenum, loops of small bowel, and colon are unremarkable. The appendix is present.

ADDITIONAL PROCEDURES

- Documentary photographs are taken by an OAFME photographer.
- Specimens retained for toxicologic testing and/or DNA identification are: vitreous, blood, urine, spleen, lung, kidney, liver, bile, gastric contents, adipose and psoas muscle
- The dissected organs are forwarded with body
- Personal effects are released to the appropriate mortuary operations representatives

ACLU Detainee DeathII ARMY MEDCOM 289

CONSULTATIONS

Neuropathology Consultation (Department of Neuropathology, AFIP, Washington D.C.):

This case was reviewed in conference on 12 Apr 06.

We examined the 1365-gram formalin-fixed brain submitted in reference to this case. The brainstem and cerebellum have been artifactually displaced superiorly between the occipital lobes during fixation. Subdural hemorrhage is delicately attached to the dura near the occiput; however, membrane formation is not noted. Patchy subarachnoid hemorrhage is identified over both cerebral hemispheres, left greater than right. The leptomeninges of the interpeduncular cistern, brain stem, and cerebellum are free of hemorrhage. A 5.5 x 4.0 cm, hemorrhagic defect is present in the inferior surface of the right temporal-occipital lobes. Cerebral cortical contusions are not seen. The remainder of the cerebral cortex has an unremarkable gyral pattern. The cranial nerve stumps identified are unremarkable. The circle of Willis is dissected from the brain and shows an adult pattern without aneurysms, atherosclerosis, or sites of occlusion. There is mild displacement of the right cingulate gyrus to the left, but definite herniation is not identified. There is no evidence of uncal or tonsillar herniation. The brain stem and cerebellum are normal in size, shape, and consistency. Coronal sections of the cerebrum confirm the presence of the temporal-occipital lobe hemorrhage, which extends up to 3.0 cm into the white matter and periventricular region. Focal intraventricular extension is noted. Otherwise, the ventricular system is of normal size and shape. No other abnormalities are noted in the cerebral cortex, white matter, and deep gray matter nuclei. The substantia nigra and locus ceruleus are normally pigmented for age. The cerebral aqueduct is patent and free of blood. Transverse sections of the brain stem and cerebellum show no abnormalities. The fourth ventricle has the usual size and is free of blood. The spinal cord is not available for examination.

Summary of microscopic sections: 1. Left superior and middle frontal gyri. 2. Left inferior parietal lobule. 3. Left superior and middle temporal gyri. 4. Left cingulate gyrus. 5. Left hippocampus. 6. Left caudate and putamen. 7. Left putamen and globus pallidus. 8. Left thalamus. 9. Midbrain (right inked black). 10. Pons (right inked black). 11. Medulla (right inked black). 12. Left cerebellum. 13. Cervico-medullary junction (right inked black). 14. Right uncus. 15. Right inferior parietal lobule. 16. Right inferior parietal lobule. 17. Dura with hemorrhage. 18-20. Right inferior parietal lobule.

The tissue was processed in paraffin; a section prepared from each paraffin block was stained with H&E. Additional sections prepared from selected blocks were stained with an iron stain, Halls and immunohistochemical methods for β-amyloid.

Microscopic sections show acute hemorrhage in sections of cerebral cortex and white matter with associated neutrophils and occasional macrophages. White matter rarefaction, hypereosinophilic neurons, white matter vacuolation, foci of necrosis, thickened vessels and scattered axonal spheroids are identified adjacent to the hemorrhage. Immunohistochemical staining for β-amyloid highlights amyloid deposition within vessel walls, consistent with

ACLU Detainee DeathII ARMY MEDCOM 290

amyloid angiopathy. Acute subarachnoid hemorrhage is noted in several sections, confirming the findings described in the gross examination. Acute subdural hemorrhage without evidence of early organization or membrane formation is identified in the section of dura. The above features are consistent with an acute parenchymal hemorrhage most likely secondary to amyloid angiopathy with extension into the subarachnoid and subdural spaces. An associated acute infarct with accompanying edema is also present. Although the changes could be due to a hemorrhagic infarct with incidental amyloid angiopathy, the above interpretation is favored.

Sections of cerebral cortex also demonstrate numerous plaques, which are highlighted with immunohistochemical staining for β-amyloid. Sections of hippocampus exhibit scattered Hirano bodies and a few neurofibrillary tangles. These features represent non-specific neuro-degenerative changes.

Multiple sections, including those from the basal ganglia, are remarkable for arteriolosclerosis with associated perivascular hemosiderin-laden macrophages.

Diagnoses: Brain, autopsy: 1. Parenchymal hemorrhage, acute, right inferior temporal-occipital region, with associated acute infarction, subarachnoid hemorrhage and subdural hemorrhage.
2. Amyloid angiopathy.
3. Arteriolosclerosis.
4. Non-specific neurodegenerative changes

Thank you for submitting this case for study.

Signed b (b)(6) on 12 APR 06.

MICROSCOPIC EXAMINATION

Selected portions of organs, other than the brain (noted above) are retained in formalin, without preparation of histologic slides.

OPINION

This BTB 65 year old Iraqi National male died as a result of an acute cerebrovascular accident that is due to amyloid angiopathy. Amyloid is a proteinaceous material that is produced by the body and can accumulate in the viscera andor the blood vessels of the body and brain. In this particular case, the acute cerebral hemorrhage occurred in contemporary relationship to the decedent being detained by American forces. Review of investigative and medical records reveals that the decedent was awake and alert upon intake into the detainment facility. His blood pressure was mildly elevated (152/ 98 mmHg). It was documented he had blunt force trauma injuries consistent with being forcibly detained. At noon, approximately two hours after being medically evaluated and several hours after capture, the decedent was witnessed to stumble out of a port-a-john and then quickly became unresponsive. The decedent was determined to have an acute stroke, which was confirmed on

ACLU Detainee DeathII ARMY MEDCOM 291

CT scan. The decedent survived in the medical treatment facility approximately (b)(6) before succumbing to the stroke. The mechanism for the stroke is presumed to be the transient increase in blood pressure within a diseased cerebral arteriole, during the process of elimination while the decedent was in the latrine. There is no definitive evidence the blunt force trauma sustained during the capture of the decedent precipitated the stroke, therefore the manner of death is natural. The morphine (narcotic analgesic) and carboxyhemoglobin present in the blood did not contribute to the death.

(b)(6)

(b)(6) Medical Examiner

ACLU Detainee DeathII ARMY MEDCOM 292

CERTIFICATE OF DEATH *(OVERSEAS)*
Acte dé décès (D'Outre-Mer)

NAME OF DECEASED (Last, First, Middle) Nom du décédé (Nom et prénoms)	GRADE Grade	BRANCH OF SERVICE Arme	SOCIAL SECURITY NUMBER Numéro de l'Assurance Social
BTB Hammed, Johar,		Civilian	(b)(6)
ORGANIZATION Organisation	NATION *(e.g. United States)* Pays: Iraq	DATE OF BIRTH Date de naissance	SEX Sexe: [X] MALE [ ] FEMALE

RACE Race		MARITAL STATUS État Civil			RELIGION Culte		
[X]	CAUCASOID Caucasique	[ ]	SINGLE Célibataire	[ ] DIVORCED Divorcé	[ ] PROTESTANT Protestant	[X]	OTHER (Specify) Autre (Spécifier)
[ ]	NEGROID Negriode	[ ]	MARRIED Marié	[ ] SEPARATED Séparé	[ ] CATHOLIC Catholique		
[ ]	OTHER (Specify) Autre (Spécifier)	[ ]	WIDOWED Veuf		[ ] JEWISH Juif		

NAME OF NEXT OF KIN Nom du plus proche parent	RELATIONSHIP TO DECEASED Parenté du décédé avec le sus
STREET ADDRESS Domicilé à (Rue)	CITY OR TOWN OR STATE *(Include ZIP Code)* Ville (Code postal compris)

MEDICAL STATEMENT Déclaration médicale

CAUSE OF DEATH (Enter only one cause per line) Cause du décès (N'indiquer qu'une cause par ligne)		INTERVAL BETWEEN ONSET AND DEATH Intervalle entre l'attaque et le décès
DISEASE OR CONDITON DIRECTLY LEADING TO DEATH [1] Maladie ou condition directement responsable de la mort [1]	Acute Cerebrovascular Accident due to Amyloid Angiopathy	Hours
ANTECEDENT CAUSES Symptômes précurseurs de la mort. MORBID CONDITION, IF ANY, LEADING TO PRIMARY CAUSE Condition morbide, s'il y a lieu, menant à la cause primaire		
UNDERLYING CAUSE, IF ANY, GIVING RISE TO PRIMARY CAUSE Condition morbide, s'il y a lieu, menant à la cause primaire		
OTHER SIGNIFICANT CONDITIONS [2] Autres conditions significatives [2]		

MODE OF DEATH Condition de décès	AUTOPSY PERFORMED Autopsie effectuée [X] YES Oui [ ] NO Non	CIRCUMSTANCES SURROUNDING DEATH DUE TO EXTERNAL CAUSES Circonstances de la mort suscitées par des causes extérieures
[X] NATURAL Mort naturelle	MAJOR FINDINGS OF AUTOPSY Conclusions principales de l'autopsie	
[ ] ACCIDENT Mort accidentelle		
[ ] SUICIDE Suicide	NAME OF PATHOLOGIST Nom du pathologiste: (b)(6)	
[ ] HOMICIDE Homicide	SIGNATURE Signature	DATE Date: 6 September 2005
		AVIATION ACCIDENT Accident à Avion: [ ] YES Oui [X] NO Non

DATE OF DEATH *(day, month, year)* Date de décès (le jour, le mois, l'année)	PLACE OF DEATH Lieu de décès
(b)(6) 2005	Balad Iraq

I HAVE VIEWED THE REMAINS OF THE DECEASED AND DEATH OCCURRED AT THE TIME INDICATED AND FROM THE CAUSES AS STATED ABOVE
J'ai examiné les restes mortels du dé funtet je conclus que le décès est survenu à l'heure indiquée et à, la suite des causes énumérées ci-dessus.

NAME OF MEDICAL OFFICER Nom du médicin militaire ou du médicin sanitaire	TITLE OR DEGREE Titre ou diplômé
(b)(6)	Medical Examiner
GRADE Grade: (b)(6)	INSTALLATION OR ADDRESS Installation ou adresse: Dover AFB, Dover DE
DATE Date	SIGNATURE Signature

[1] State disease, injury or complication which caused death, but not mode of dying such as heart failure, ect.
[2] State conditions contributing to the death, but not related to the disease or condition causing death.
[1] Préciser la nature de la maladie, de la blessure ou de la complication qui a contribué à la mort, mais non la manière de mourir, telle qu 'un arrêt du coeur, etc.
[2] Préciser la condition qui a contribué à la mort, mais n'ayant aucun rapport avec la maladie ou à la condition qui a provoqué la mort.

DD FORM 1 APR 77 2064 REPLACES DA FORM 3565, 1 JAN 72 AND DA FORM 3565-R(PAS), 26 SEP 75, WHICH ARE OBSOLETE.

MEDCOM 0293

ACLU Detainee DeathII ARMY MEDCOM 293

(REMOVE, REVERSE AND RE-INSERT CARBONS BEFORE COMPLETING THIS SIDE)

DISPOSITON OF REMAINS

NAME OF MORTICIAN PREPARING REMAINS	GRADE	LICENSE NUMBER AND STATE	OTHER

INSTALLATION OR ADDRESS	DATE	SIGNATURE

NAME OF CEMETERY OR CREMATORY	LOCATION OF CEMETERY OR CREMATORY

TYPE OF DISPOSTION	DATE OF DISPOSTION

REGISTRATION OF VITAL STATISTICS

REGISTRY *(Town and Country)*	DATE REGISTERED	FILE NUMBER	
		STATE	OTHER

NAME OF FUNERAL DIRECTOR	ADDRESS

SIGNATURE OF AUTHORIZED INDIVIDUAL

DD FORM 2064, APR 1977 (BACK) *USAPA V1.00*

ACLU Detainee DeathII ARMY MEDCOM 294

ARMED FORCES INSTITUTE OF PATHOLOGY
Office of the Armed Forces Medical Examiner
1413 Research Blvd., Bldg. 102
Rockville, MD 20850
1-800-774-8427

AUTOPSY EXAMINATION REPORT

Name: BTB Munthir, Awad Hasan
Internment Serial Number (b)(6)
Date of Birth: 1985
Date of Death: (b)(6) 2005
Date of Autopsy: 24 AUG 2005
Date of Report: 26 OCT 2005

Autopsy No.: (b)(6)
AFIP No.: (b)(6)
Rank: Detainee
Place of Death: Abu Ghraib Prison, Iraq
Place of Autopsy: Port Mortuary
Dover AFB, DE

Circumstances of Death: This believed to be 20 year old Iraqi National was found suspended by his neck (hanging) with his hands tied behind his back in a shower stall while being detained in Abu Ghraib Prison, Iraq. The investigation of the circumstances surrounding the decedent's death indicates that shortly after being accounted for in the morning head count the decedent made his way to the communal shower area. Shortly thereafter, the decedent was discovered hanging by other detainees who alerted the guards. The responding guards initiated CPR after cutting the decedent down and removing the ligature from the decedent's neck. Despite the CPR and rescue attempts in the prison medical facility, the decedent was pronounced deceased. Interviews of the fellow detainees indicate the decedent was depressed about his capture and was "self-treating" his depression by segregating himself from the other detainees and continuously reading the Quaran. Some of the other detainees stated the decedent claimed to express a need to be nearer to his God. Scene investigation indicates there was no evidence of a struggle in or near the shower stall the decedent was found in.

Authorization for Autopsy: Office of the Armed Forces Medical Examiner, IAW 10 USC 1471.

Identification: Presumptive identification is established by the Internment Serial Number and prison records.

CAUSE OF DEATH: Asphyxia by Hanging

MANNER OF DEATH: Suicide

ACLU Detainee DeathII ARMY MEDCOM 295

FINAL AUTOPSY DIAGNOSES:

I. Asphyxia by Hanging

A. Injuries of the Neck

1. A 30.5 cm long dried brown ligature mark (furrow) of the neck is 6 ¼ inches below the top of the head at its end on the right side of the neck, 9 ¾ inches below the top of the head in the anterior midline of the neck and 7 ¼ inches below the top of the head at its end on the left side of the neck. The furrow width ranges from 0.7 cm (tapered end behind the right ear) to 1.5 cm (right side of the neck). Along the right side of the furrow is a 6.5 x 1.5 cm area of abrasion that contains two vertical 1.5 x 0.2 cm abrasions. The furrow is 0.2 cm deep on the anterior surface of the neck.

   Layer by layer neck examination of the neck demonstrates mild congestion of the anterior strap muscles of the neck immediately superior to the furrow and no fractures of the hyoid bone or thyroid cartilage. There are no petechiae of the sclera, eyelids, oral mucosa, tongue or legs. The frenula are intact.

2. A 4.5 x 3.5 cm area of multiple, superficial linear abrasions is in the posterior midline of the upper back, 11 ½ inches below the top of the head. The abrasions have a near vertical orientation.

II. Other Injuries

1. A 2.2 x 0.5 cm vertical abrasion is on the right flank
2. A 2.5 x 1.7 cm erythematous area is on the anterior surface of the left lower leg
3. A ecchymosis is on the parietal pleural surface of the left sixth rib and left seventh intercostal space

III. Other Findings

1. There are no gross injuries of the wrists or injuries of the underlying musculature

IV. Medical Intervention

1. Endotracheal intubation (in right mainstem bronchus)
2. Self adhesive electrocardiogram leads on the chest
3. Venipuncture sites on the right side of the neck (associated with underlying hematoma), right antecubital fossa, right forearm, and right femoral triangle.
4. Substernal puncture site associated with penetration of the posterior right ventricle, hemopericardium (50 ml), and hemoperitoneum (approximately 50 ml)

ACLU Detainee DeathII ARMY MEDCOM 296

V. No significant natural diseases identified, within limitations of the examination

VI. Identifying Marks

1. A tattoo (b)(6)
2. A tattoo
3. A tattoo
   (b)(6)
4. Three 1.2 cm in diameter circular scars are on the anterior surface of the left forearm
5. A 4.2 x 1.8 cm scar is on the anterior surface of the left lower leg and has palpable foreign bodies immediately below the skin (metallic fragments on x-ray)
6. Scattered scars on each knee
7. Linear scars on the chin and circular scar on the left cheek

VII. Toxicology is negative for ethanol and screened drugs of abuse.

ACLU Detainee DeathII ARMY MEDCOM 297

EXTERNAL EXAMINATION

The body is that of a well-developed, well-nourished appearing, muscular, 65 inch long, 119 pounds Iraqi male civilian whose appearance is consistent with the reported age of 20 years. Lividity is fixed along the posterior surface of the body with pressure bearing area pallor. Rigor is minimal and easily broken. Brown paper bags cover the hands.

The scalp is covered with black hair in a normal distribution. The irides are brown and the pupils are round and equal in diameter. The conjunctivae and sclera are free of petechiae. The external auditory canals are free of abnormal secretions. The ears are unremarkable. The nares are patent and the lips are atraumatic. The frenula are intact. The nose and maxillae are palpably stable. The teeth appear natural and in fair repair. The upper right central incisor (#8) is broken and has decay present. A 0.7 x 0.2 cm scar and a 2.4 x 0.2 cm scar are on the chin. On the left cheek is a 0.5 x 0.3 cm circular scar.

The neck is straight, and the trachea is midline and mobile. Injuries of the neck are described below. The chest is symmetric. The abdomen is flat. The genitalia are those of a normal uncircumcised adult male. The testes are descended and free of masses. Pubic hair is present in a normal distribution. The buttocks and anus are unremarkable.

The upper and lower extremities are symmetric and without clubbing or edema. The hands and fingers are free of injuries. The fingernails are roughly trimmed secondary to previous evidence collection by US Army CID. There is no gross evidence of ligature marks on the wrists. Areas of blue discoloration on the posterior surfaces of the left and right wrist range in size from 0.5 x 0.5 cm to 5.1 x 0.4 cm. Three-1.2 cm in diameter- circular scars are on the anterior surface of the left forearm. Incision examination of the these areas reveals the discoloration is confined to the skin. A 1.0 x 0.4 cm scar is on the proximal portion of the right knee and a 1.8 x 0.4 cm scar is on the lateral aspect of the right knee. On the left knee are scattered scars that range in size from 1.4 x 0.3 cm to 2.5 x 1.7 cm. A 4.2 x 1.8 cm scar is on the anterior aspect of the left lower leg and overlies a palpable bony deformity that corresponds to a healed remote fracture. The left leg is visibly shorter than the right leg. The hands, legs and feet are free of petechiae.

In addition to the scars noted above, identifying marks include a tattoo (b)(6)
(b)(6) tattoo (b)(6) tattoo (b)(6)
(b)(6)

CLOTHING AND PERSONAL EFFECTS

The decedent was received clad in a white t-shirt.

MEDICAL INTERVENTION

1. Endotracheal intubation (in right mainstem bronchus)
2. Self adhesive electrocardiogram leads on the chest
3. Venipuncture sites on the right side of the neck (associated with underlying hematoma), right antecubital fossa, right forearm, and right femoral triangle.

ACLU Detainee DeathII ARMY MEDCOM 298

4. Substernal puncture site associated with penetration of the posterior right ventricle, hemopericardium (50 ml), and hemoperitoneum (approximately 50 ml)

RADIOGRAPHS

A complete set of postmortem radiographs is obtained and demonstrate a remote, healed fracture of the left tibia and fibula with surrounding debris.

EVIDENCE OF INJURY

The ordering of the following injuries is for descriptive purposes only, and is not intended to imply order of infliction or relative severity.

Injuries of the Neck:
A 30.5 cm long dried brown ligature mark (furrow) of the neck is 6 ¼ inches below the top of the head at its end on the right side of the neck, 9 ¾ inches below the top of the head in the anterior midline of the neck and 7 ¼ inches below the top of the head at its end on the left side of the neck. The furrow width ranges from 0.7 cm (tapered end behind the right ear) to 1.5 cm (right side of the neck). Along the right side of the furrow is a 6.5 x 1.5 cm area of abrasion that contains two vertical 1.5 x 0.2 cm abrasions. The furrow is 0.2 cm deep on the anterior surface of the neck.

Layer by layer neck examination of the neck demonstrates mild congestion of the anterior strap muscles of the neck immediately superior to the furrow and no fractures of the hyoid bone or thyroid cartilage. There are no petechiae of the sclera, eyelids, oral mucosa, tongue or legs. The frenula are intact.

A 4.5 x 3.5 cm area of multiple, superficial linear abrasions is in the posterior midline of the upper back, 11 ½ inches below the top of the head. The abrasions have a near vertical orientation.

Injuries of the Torso
A 2.2 x 0.5 cm vertical abrasion is on the right flank. An ecchymosis is on the parietal pleural surface of the left sixth rib and left seventh intercostal space

Injuries of the Extremities
A 2.5 x 1.7 cm erythematous area is on the anterior surface of the left lower leg

INTERNAL EXAMINATION

HEAD:
The galeal and subgaleal soft tissues of the scalp are free of injury. The calvarium is intact, as is the dura mater beneath it. Clear cerebrospinal fluid surrounds the 1350 gm brain, which has unremarkable gyri and sulci. Coronal sections demonstrate sharp demarcation between white and grey matter, without hemorrhage or contusive injury. The ventricles are of normal size. The basal ganglia, brainstem, cerebellum, and arterial systems are free of

ACLU Detainee DeathII ARMY MEDCOM 299

injury or other abnormalities. The base of the brain is soft and minimally liquefied. There are no skull fractures. The atlanto-occipital joint is stable.

NECK:
The dissection of the neck is described above. The thyroid cartilage and hyoid bone are intact. The larynx is lined by intact white mucosa. The thyroid gland is symmetric and red-brown, without cystic or nodular change. The tongue is free of bite marks, hemorrhage, or other injuries.

BODY CAVITIES:
The ribs, sternum, and vertebral bodies are visibly and palpably intact. Excess fluid in the pleural and peritoneal cavities is described above. The organs occupy their usual anatomic positions.

RESPIRATORY SYSTEM:
The right and left lungs weigh 410 and 460 gm, respectively. The external surfaces are smooth and deep red-purple. The pulmonary parenchyma is diffusely congested and edematous, consistent with dependent livor. No mass lesions or areas of consolidation are present.

CARDIOVASCULAR SYSTEM:
The 270 gm heart is contained in an intact pericardial sac. The epicardial surface is smooth, with minimal fat investment. A puncture of the right ventricle is described above. The coronary arteries are present in a normal distribution, with a right-dominant pattern. Cross sections of the vessels show no atherosclerosis. The myocardium is homogenous, red-brown, and firm. The valve leaflets are thin and mobile. The walls of the left and right ventricles are 1.0 and 0.2-cm thick, respectively. The endocardium is smooth and glistening. The aorta gives rise to three intact and patent arch vessels. The renal and mesenteric vessels are unremarkable.

LIVER & BILIARY SYSTEM:
The 1500 gm liver has an intact, smooth capsule and a sharp anterior border. The parenchyma is tan-brown and congested, with the usual lobular architecture. No mass lesions or other abnormalities are seen. The gallbladder contains a minute amount of green-black bile and no stones. The gallbladder mucosal surface is green and velvety. The extrahepatic biliary tree is patent.

SPLEEN:
The 210 gm spleen has a smooth, intact, red-purple capsule. The parenchyma is maroon and congested, with distinct Malpighian corpuscles.

PANCREAS:
The pancreas is firm and yellow-tan, with the usual lobular architecture. No mass lesions or other abnormalities are seen.

ACLU Detainee DeathII ARMY MEDCOM 300

ADRENALS:
The right and left adrenal glands are symmetric, with bright yellow cortices and grey medullae. No masses or areas of hemorrhage are identified.

GENITOURINARY SYSTEM:
The right and left kidneys weigh 120 and 110 gm, respectively. The external surfaces are intact and smooth. The cut surfaces are red-tan and congested, with uniformly thick cortices and sharp corticomedullary junctions. The pelves are unremarkable and the ureters are normal in course and caliber. White bladder mucosa overlies an intact bladder wall. The bladder contains approximately 30 ml of cloudy urine. The prostate is normal in size, with lobular, yellow-tan parenchyma. The seminal vesicles are unremarkable. The testes are free of mass lesions, contusions, or other abnormalities.

GASTROINTESTINAL TRACT:
The esophagus is intact and lined by smooth, grey-white mucosa. The stomach contains approximately 10 ml of slightly red liquid. The gastric wall is intact. The duodenum, loops of small bowel, and colon are unremarkable. The appendix is present.

ADDITIONAL PROCEDURES

- Documentary photographs are taken by an OAFME photographer.
- Trace evidence and foreign material (sexual assault kit without oral swabs) is collected and given to SA (b)(6) USACID. Fingernail clippings were taken by USACID prior to transport to Dover AFB.
- Specimens retained for toxicologic testing and/or DNA identification are: vitreous, blood, urine, spleen, lung, liver, kidney, brain, bile, gastric contents, adipose tissue and psoas muscle
- The dissected organs are forwarded with body
- Personal effects are released to the appropriate mortuary operations representatives

MICROSCOPIC EXAMINATION

Selected portions of organs are retained in formalin, without preparation of histologic slides.

ACLU Detainee DeathII ARMY MEDCOM 301

OPINION

This believed to be 20 year Iraqi male civilian detainee died from mechanical asphyxia caused by hanging. Investigation information to date indicates the decedent was a young detainee that was depressed about his captivity and being separated from his new wife. He was a detainee for approximately 3 months prior to his death. An interview of an Iraqi associate of the decedent by USACID indicates the decedent was considered a "loner" and did not associate with other detainees. The decedent reportedly read the Quaran and desired to be closer to his god. The responding MPs did not report any history of struggle or violence at the scene. Autopsy examination revealed only injuries related to the hanging. The decedent's hands were loosely tied behind his back when discovered. It is possible for the decedent to have tied his own hands behind his back to prevent escape from the neck rope. Based on the autopsy and investigation, the manner of death is best classified as suicide.

If additional information becomes available, this case can be re-examined and the cause and manner of death changed if appropriate to do so.

(b)(6)

(b)(6) Medical Examiner

ACLU Detainee DeathII ARMY MEDCOM 302

DEPARTMENT OF DEFENSE
ARMED FORCES INSTITUTE OF PATHOLOGY
WASHINGTON, DC 20306-6000

REPLY TO ATTENTION OF

AFIP (b)(6)

PATIENT IDENTIFICATION
AFIP Accessions Number **Sequence**
(b)(6)

TO:

OFFICE OF THE ARMED FORCES MEDICAL EXAMINER
ARMED FORCES INSTITUTE OF PATHOLOGY
WASHINGTON, DC 20306-6000

Name
MUNTHIR, AWAD HASAN

SSAN: **Autopsy:** (b)(6)
Toxicology Accession #: (b)(6)
Date Report Generated: September 1, 2005

CONSULTATION REPORT ON CONTRIBUTOR MATERIAL

AFIP DIAGNOSIS **REPORT OF TOXICOLOGICAL EXAMINATION**

Condition of Specimens: GOOD
Date of Incident (b)(6) 2005 **Date Received:** 8/29/2005

VOLATILES: The **BLOOD AND URINE** were examined for the presence of ethanol at a cutoff of 20 mg/dL. No ethanol was detected.

DRUGS: The **URINE** was screened for amphetamine, antidepressants, antihistamines, barbiturates, benzodiazepines, cannabinoids, chloroquine, cocaine, dextromethorphan, lidocaine, narcotic analgesics, opiates, phencyclidine, phenothiazines, sympathomimetic amines and verapamil by gas chromatography, color test or immunoassay. The following drugs were detected:

None were found.

(b)(6)
Office of the Armed Forces Medical Examiner

(b)(6)
Office of the Armed Forces Medical Examiner

ACLU Detainee DeathII ARMY MEDCOM 303

CERTIFICATE OF DEATH *(OVERSEAS)*
Acta dé décès (D'Outre-Mer)

NAME OF DECEASED (Last, First, Middle) Nom du décédé (Nom et prénoms)	GRADE Grade	BRANCH OF SERVICE Arme	SOCIAL SECURITY NUMBER Numéro de l'Assurance Social
BTB Munthir, Awad, Hasan		Civilian	(b)(6)

ORGANIZATION Organisation	NATION (e.g. United States) Pays	DATE OF BIRTH Date de naissance	SEX Sexe
	Iraq		[X] MALE [ ] FEMALE

RACE Race		MARITAL STATUS État Civil			RELIGION Culte		
[X]	CAUCASOID Caucasique	[ ]	SINGLE Célibataire	[ ]	DIVORCED Divorcé	[ ] PROTESTANT Protestant	[X] OTHER (Specify) Autre (Spécifier) Muslim
[ ]	NEGROID Negroide	[ ]	MARRIED Marié	[ ]	SEPARATED Séparé	[ ] CATHOLIC Catholique	
[ ]	OTHER (Specify) Autre (Spécifier)	[ ]	WIDOWED Veuf			[ ] JEWISH Juif	

NAME OF NEXT OF KIN Nom du plus proche parent	RELATIONSHIP TO DECEASED Parenté du décédé avec le sus
STREET ADDRESS Domicilé á (Rue)	CITY OR TOWN OR STATE (Include ZIP Code) Ville (Code postal compris)

MEDICAL STATEMENT Déclaration médicale

	CAUSE OF DEATH (Enter only one cause per line) Cause du décès (N'indiquer qu'une cause par ligne)	INTERVAL BETWEEN ONSET AND DEATH Intervalle entre l'attaque et le décès
DISEASE OR CONDITON DIRECTLY LEADING TO DEATH [1] Maladie ou condition directement responsable de la mort.	Asphyxia by hanging	Minutes
ANTECEDENT CAUSES Symptômes précurseurs de la mort. — MORBID CONDITION, IF ANY, LEADING TO PRIMARY CAUSE Condition morbide, s'il y a lieu, menant à la cause primaire		
ANTECEDENT CAUSES Symptômes précurseurs de la mort. — UNDERLYING CAUSE, IF ANY, GIVING RISE TO PRIMARY CAUSE Condition morbide, s'il y a lieu, menant à la cause primaire		
OTHER SIGNIFICANT CONDITIONS [2] Autres conditions significatives		

MODE OF DEATH Condition du décès	AUTOPSY PERFORMED Autopsie effectuée	CIRCUMSTANCES SURROUNDING DEATH DUE TO EXTERNAL CAUSES
[ ] NATURAL Mort naturelle	[X] YES Oui [ ] NO Non	Circonstances de la mort suscitées par des causes extérieures
[ ] ACCIDENT Mort accidentelle	MAJOR FINDINGS OF AUTOPSY Conclusions principales de l'autopsie	Mode of Death: Pending
[ ] SUICIDE Suicide	NAME OF PATHOLOGIST Nom du pathologiste (b)(6)	
[ ] HOMICIDE Homicide	(b)(6) DATE Date 24 August 2005	AVIATION ACCIDENT Accident á Avion [ ] YES Oui [X] NO Non

DATE OF DEATH (Hour, day, month, year) Date du décès (Theure, le jour, le mois, l'annee)	PLACE OF DEATH Lieu de décès
(b)(6) 2005	Iraq

I HAVE VIEWED THE REMAINS OF THE DECEASED AND DEATH OCCURRED AT THE TIME INDICATED AND FROM THE CAUSES AS STATED ABOVE.
J'ai examiné les restes mortels du dé funtet je conclus que le décès est survenu á l'heure indiquée et á, la suite des causes énumérées ci-dessus.

NAME OF MEDICAL OFFICER Nom du médicin militaire ou du médicin sanitaire	TITLE OR DEGREE Titre ou diplômé
(b)(6)	Medical Examiner

GRADE Grade	INSTALLATION OR ADDRESS Installation ou adresse
(b)(6)	Dover AFB, Dover DE
DATE Date 16 SEP 05	(b)(6)

[1] State disease, injury or complication which caused death, but not mode of dying such as heart failure, ect.
[2] State conditions contributing to the death, but not related to the disease or condition causing death.
[1] Préciser la nature de la maladie, de la blessure ou de la complication qui a contribué à la mort, mais non la manière de mourir, telle qu'un arrêt du coeur, etc
[2] Préciser la condition qui a contribué à la mort, mais n'ayant aucun rapport avec la maladie ou à la condition qui a provoqué la mort

DD FORM 1 APR 77 2064 REPLACES DA FORM 3565, 1 JAN 72 AND DA FORM 3565-R(PA8), 26 SEP 75, WHICH ARE OBSOLETE.

ACLU Detainee DeathII ARMY MEDCOM 304

(REMOVE, REVERSE AND RE-INSERT CARBONS BEFORE COMPLETING THIS SIDE)

DISPOSITON OF REMAINS

NAME OF MORTICIAN PREPARING REMAINS	GRADE	LICENSE NUMBER AND STATE	OTHER

INSTALLATION OR ADDRESS	DATE	SIGNATURE

NAME OF CEMETERY OR CREMATORY	LOCATION OF CEMETERY OR CREMATORY

TYPE OF DISPOSTION	DATE OF DISPOSTION

REGISTRATION OF VITAL STATISTICS

REGISTRY *(Town and Country)*	DATE REGISTERED	FILE NUMBER	
		STATE	OTHER

NAME OF FUNERAL DIRECTOR	ADDRESS

SIGNATURE OF AUTHORIZED INDIVIDUAL

DD FORM 2064, APR 1977 (BACK) *USAPA V1.00*

ACLU Detainee DeathII ARMY MEDCOM 305

ARMED FORCES INSTITUTE OF PATHOLOGY
Office of the Armed Forces Medical Examiner
1413 Research Blvd., Bldg. 102
Rockville, MD 20850
1-800-944-7912

FINAL AUTOPSY EXAMINATION REPORT

Name: Atawi-Al Alwani, Ahmed Ismail
ISN: (b)(6)
Date of Birth: (b)(6) 1975
Date of Death (b)(6) 2005
Date of Autopsy: 04 August 2005
Date of Report: 24 October 2005

Autopsy No.: (b)(6)
AFIP No.: (b)(6)
Rank: CIV
Place of Death: Iraq
Place of Autopsy: Port Mortuary
Dover AFB, DE

Circumstances of Death: This 30 year old male civilian detainee was reportedly admitted to the Camp Bucca Security Hospital for complications of malaria.

Authorization for Autopsy: Office of the Armed Forces Medical Examiner, IAW 10 USC 1471.

Identification: Identification is established by identification tags present on the body.

CAUSE OF DEATH: Peritonitis due to small bowel perforation.

MANNER OF DEATH: Natural.

FINAL AUTOPSY DIAGNOSES

I. Gastrointestinal system:
A. Small bowel perforation.
1. Adjacent pseudocyst formation with rupture.
2. Ascites (4000 ml of feculent tan fluid).
3. Peritonitis.
B. Neoplastic mesenteric masses (2) adjacent to pseudocyst.
C. Moderate to severe hepatic steatosis.

II. Respiratory system:
A. Bilateral pulmonary congestion (right 800 gm, left 750 gm).
1. Bilateral pleural effusions (right 200 ml, left 100 ml).

III. No evidence of trauma.

IV. Toxicology: Lidocaine, mefloquine, chloroquine, metoclopramide, lorazepam, oxycodone and oxymorphone are present.

ACLU Detainee DeathII ARMY MEDCOM 306

EXTERNAL EXAMINATION

The body is that of a well-developed male that weighs 177 pounds, is 68 inches in length and appears compatable with the reported age of 30 years. Lividity is fixed on the posterior surface of the body except in areas exposed to pressure. Rigor has passed. The scalp hair is black. Facial hair consists of a black mustache and whisker stubble. The irides are dark. The corneae are cloudy. The conjunctivae are unremarkable. The sclerae are white. The external auditory canals, external nares and oral cavity are free of foreign material and abnormal secretions. The teeth are natural and in good condition. A ¼ inch scar is present on the right side of the chin. The neck is straight, and the trachea is midline and mobile. The chest is unremarkable. The abdomen is mildly protuberant. The fingernails are intact. The upper and lower extremities are symmetric. There are multiple scars on the anterior surface of the right knee. An identification tag is present on the left wrist, bearing the following information (b)(6)
DOB (b)(6) 1975". The genitalia are those of a normal adult male. There is a 4 x 4 inch area of discoloration with early pressure ulceration present on the superior aspect of the gluteal cleft.

EVIDENCE OF MEDICAL THERAPY

1. An endotracheal tube.
2. Nasogastric tube.
3. Foley catheter with drainage bag.
4. Healing therapeutic needle puncture site in the left antecubital fossa.
5. Monitor lead pads on the upper and mid chest and flanks, bilaterally.
6. Defibrillator pad on the left chest and the left back.

EVIDENCE OF INJURY

None.

INTERNAL EXAMINATION

BODY CAVITIES:

The sternum is visibly and palpably intact. No excess fluid is present in the pericardium. Approximately 200 ml of amber fluid is present in the right chest cavity and 100 ml in the left. The abdominal cavity contains approximately 4000 ml of tan feculent fluid. Yellow-tan fibrinous material covers multiple loops of the small bowel, omentum and portions of the liver. The organs occupy their usual anatomic positions.

HEAD:

The scalp is reflected. The calvarium of the skull is removed. The leptomeninges are thin and delicate. Coronal sections demonstrate sharp demarcation between white and grey matter. The ventricles are of normal size. The brain weighs 1420 gm. The atlanto-occipital joint is stable.

ACLU Detainee DeathII ARMY MEDCOM 307

NECK:

The anterior strap muscles of the neck are homogenous and red-brown, without hemorrhage. The thyroid cartilage and hyoid are intact. The larynx is lined by intact white mucosa. The thyroid is symmetric and red-brown. The tongue is free of bite marks, hemorrhage, or other injuries.

RESPIRATORY SYSTEM:

The right and left lungs weigh 800 and 750 gm, respectively. The external surfaces are smooth and deep red-purple. The pulmonary parenchyma is diffusely congested and edematous. No mass lesions or areas of consolidation are present.

CARDIOVASCULAR SYSTEM:

The 290 gm heart is contained in an intact pericardial sac. The epicardial surface is smooth, with minimal fat investment. The coronary arteries arise normally, follow the usual distribution and are widely patent without evidence of significant atherosclerosis or thrombosis. The myocardium is homogenous, red-brown, and firm. The valve leaflets are thin and mobile. The endocardium is smooth and glistening. The ascending aorta gives rise to three intact and patent arch vessels. The renal and mesenteric vessels are unremarkable.

LIVER & BILIARY SYSTEM:

The 2010 gm liver has an intact capsule and a sharp anterior border. The parenchyma is tan-brown and congested, with the usual lobular architecture. No mass lesions or other abnormalities are seen. The gallbladder contains approximately 10 ml of green-black bile. The mucosal surface is green and velvety. The extrahepatic biliary tree is patent.

SPLEEN:

The 290 gm spleen has a smooth, intact, red-purple capsule. The parenchyma is maroon and congested, with distinct Malpighian corpuscles.

PANCREAS:

The pancreas is soft and yellow-tan, with the usual lobular architecture. No mass lesions or other abnormalities are seen.

ADRENAL GLANDS:

The right and left adrenal glands are symmetric, with bright yellow cortices and grey medullae. No masses or areas of hemorrhage are identified.

GENITOURINARY SYSTEM:

The right kidney weighs 180 gm and the left 150 gm. The external surfaces are intact and smooth. The cut surfaces are red-tan and congested, with uniformly thick cortices and sharp corticomedullary junctions. The pelves are unremarkable and the ureters are normal in course

ACLU Detainee DeathII ARMY MEDCOM 308

and caliber. Tan bladder mucosa overlies an intact bladder wall. The bladder is empty. The prostate is normal in size, with lobular, yellow-tan parenchyma. The seminal vesicles are unremarkable. The testes are palpably free of mass lesions.

GASTROINTESTINAL TRACT:

The esophagus is lined by smooth, grey-white mucosa. The stomach is empty. The gastric wall is intact. The serosal surfaces of the small and large bowel are covered by tan-yellow fibrinous material. A fluid and fecal filled pseudocyst measuring 7 inches in greatest diameter is present just inferior and posterior to the stomach and adjacent to a portion of the duodenum. Reflection of the stomach reveals an area of rupture on the anterior surface of the pseudocyst. Dissection and further reflection show the pseudocyst to be in continuity with a perforation of the adjacent duodenum. Two solid mass lesions measuring 3 ½ x 2 inches and 2 ½ x 1 inch are present and appear to be arising from the region of the mesenteric root. The larger lesion is firmly adherent to the duodenum in the region of the perforation. The appendix is unremarkable.

MICROSCOPIC EXAMINATION

1. Heart (slide 1): No significant microscopic abnormalities.
2. Spleen (slide 2): No microscopic abnormality noted.
3. Kidneys (slide 4): Moderate arteriolosclerosis.
4. Liver (slide 2): Moderate to severe steatosis.
5. Brain (slide 5): No microscopic abnormality noted.
6. Lungs (slide 3): Pulmonary alveolar congestion.
7. Omentum: (slide 6): Acute serositis.
8. Abdominal masses (slides 7-10): Confluent areas of necrosis with intervening areas composed of atypical dyshesive cells with coarse nuclear chromatin and frequent plasmacytoid features. Occasional mitoses are present.
9. Region of perforation of the pseudocyst (slides 11,12): Fibroadipose tissue with fibrin deposition. acute inflammatory infiltration and granulation tissue formation.

ADDITIONAL PROCEDURES/REMARKS

- Documentary photographs are taken by the OAFME staff photographer.
- Specimens retained for toxicologic testing and/or DNA identification are: blood, vitreous, bile, gastric contents, kidney, lung, brain, spleen, liver, adipose and psoas muscle.
- Full body radiographs are obtained.
- The dissected organs are forwarded with the body.
- Personal effects are released to the attending investigative agency and appropriate mortuary operations representatives.

OPINION

This reported 30 year-old male civilian detainee died of peritonitis due to small bowel perforation. According to reports, the decedent was admitted to the hospital with a diagnosis of hepatic failure. Further workup showed an advanced stage of malaria. His clinical course was complicated by multi-system organ failure and he ultimately succumbed to septic shock on his (b)(6) hospital day.

ACLU Detainee DeathII ARMY MEDCOM 309

Autopsy examination showed 4 liters of feculent ascites and mesenteric mass lesions with adjacent small bowel perforation. It appears that initially the area of perforation was walled off forming a "pseudocystic" structure that ultimately ruptured. Initial microscopic examination of the mesenteric masses showed them to be neoplastic, however their exact etiology is pending specialty consultation. An addendum report will be issued upon its completion.

Postmortem toxicologic analysis revealed the presence of the therapeutic agents lidocaine, mefloquine, chloroquine, metoclopramide, oxycodone and oxymorphone in the urine. Lorazapam was present in the blood at a therapeutic level (0.26 mg/L).

The manner of death is natural.

(b)(6)

(b)(6) Medical Examiner

ACLU Detainee DeathII ARMY MEDCOM 310

CERTIFICATE OF DEATH *(OVERSEAS)*

Acte de décès (D'Outre-Mer)

NAME OF DECEASED *(Last, First, Middle)* Nom du décédé (Nom et prénoms)	GRADE Grade	BRANCH OF SERVICE Arme	SOCIAL SECURITY NUMBER Numéro de l'Assurance Social
BTB Atawi, Al, Alwani Ahmed		Civilian	(b)(6)

ORGANIZATION Organisation	NATION *(e.g, United States)* Pays	DATE OF BIRTH Date de naissance	SEX Sexe
	Iraq		[X] MALE [ ] FEMALE

RACE Race		MARITAL STATUS État Civil			RELIGION Culte		
[X]	CAUCASOID Caucasique	[ ]	SINGLE Célibataire	[ ] DIVORCED Divorcé	[ ]	PROTESTANT Protestant	[X] OTHER (Specify) Autre (Spécifier)
[ ]	NEGROID Negroide	[ ]	MARRIED Marié	[ ] SEPARATED Séparé	[ ]	CATHOLIC Catholique	
[ ]	OTHER (Specify) Autre (Spécifier)	[ ]	WIDOWED Veuf		[ ]	JEWISH Juif	

NAME OF NEXT OF KIN Nom du plus proche parent	RELATIONSHIP TO DECEASED Parenté du décédé avec le sus
STREET ADDRESS Domicilé à (Rue)	CITY OR TOWN OR STATE *(Include ZIP Code)* Ville (Code postal compris)

MEDICAL STATEMENT Déclaration médicale

	CAUSE OF DEATH (Enter only one cause per line) Cause du décès (N'indiquer qu'une cause par ligne)	INTERVAL BETWEEN ONSET AND DEATH Intervalle entre l'attaque et le décès
DISEASE OR CONDITON DIRECTLY LEADING TO DEATH [1] Maladie ou condition directement responsable de la mort.	Peritonitis due to small bowel perforation	Days
ANTECEDENT CAUSES Symptômes précurseurs de la mort. MORBID CONDITION, IF ANY, LEADING TO PRIMARY CAUSE Condition morbide, s'il y a lieu, menant à la cause primaire		
UNDERLYING CAUSE, IF ANY, GIVING RISE TO PRIMARY CAUSE Condition morbide, s'il y a lieu, menant à la cause primaire		
OTHER SIGNIFICANT CONDITIONS [2] Autres conditions significatives [2]		

MODE OF DEATH Condition de décès	AUTOPSY PERFORMED Autopsie effectuée [X] YES Oui [ ] NO Non	CIRCUMSTANCES SURROUNDING DEATH DUE TO EXTERNAL CAUSES Circonstances de la mort suscitées par des causes extérieures
[X] NATURAL Mort naturelle	MAJOR FINDINGS OF AUTOPSY Conclusions principales de l'autopsie	
[ ] ACCIDENT Mort accidentelle		
[ ] SUICIDE Suicide	NAME OF PATHOLOGIST Nom du pathologiste (b)(6)	
[ ] HOMICIDE Homicide	(b)(6) DATE Date 4 August 2005	AVIATION ACCIDENT Accident à Avion [ ] YES Oui [X] NO Non

DATE OF DEATH *(Hour, day, month, year)* Date de décès (Heure, le jour, le mois, l'année)	PLACE OF DEATH Lieu de décès
(b)(6) 2005	Iraq

I HAVE VIEWED THE REMAINS OF THE DECEASED AND DEATH OCCURRED AT THE TIME INDICATED AND FROM THE CAUSES AS STATED ABOVE
J'ai examiné les restes mortals du dé funtot je conclus que le décès est survenu à l'heure indiquée et à, la suite des causes énumérées ci-dessus.

NAME OF MEDICAL OFFICER Nom du médicin militaire ou du médicin sanitaire	TITLE OR DEGREE Titre ou diplômé
(b)(6)	Medical Examiner

GRADE Grade	INSTALLATION OR ADDRESS Installation ou adresse
(b)(6)	Dover AFB, Dover DE
DATE Date 15 Sep 05	(b)(6)

[1] State disease, injury or complication which caused death.
[2] State conditions contributing to the death, but not related to the disease or condition causing death.
[1] Préciser la nature de la maladie, de la blessure ou de la complication qui a contribué à la mort, mais non la manière de mourir, telle qu'un arrêt du coeur, etc.
[2] Préciser la condition qui a contribué à la mort, mais n'ayant aucun rapport avec la maladie ou à la condition qui a provoqué la mort.

DD FORM 1 APR 77 **2064** REPLACES DA FORM 3565, 1 JAN 72 AND DA FORM 3565-R(PAS), 26 SEP 75, WHICH ARE OBSOLETE.

(REMOVE, REVERSE AND RE-INSERT CARBONS BEFORE COMPLETING THIS SIDE)

DISPOSITON OF REMAINS

NAME OF MORTICIAN PREPARING REMAINS	GRADE	LICENSE NUMBER AND STATE	OTHER

INSTALLATION OR ADDRESS	DATE	SIGNATURE

NAME OF CEMETERY OR CREMATORY	LOCATION OF CEMETERY OR CREMATORY

TYPE OF DISPOSTION	DATE OF DISPOSTION

REGISTRATION OF VITAL STATISTICS

REGISTRY *(Town and Country)*	DATE REGISTERED	FILE NUMBER	
		STATE	OTHER

NAME OF FUNERAL DIRECTOR	ADDRESS

SIGNATURE OF AUTHORIZED INDIVIDUAL

DD FORM 2064, APR 1977 (BACK) *USAPA V1.00*

ACLU Detainee DeathII ARMY MEDCOM 312

ARMED FORCES INSTITUTE OF PATHOLOGY
Office of the Armed Forces Medical Examiner
1413 Research Blvd., Bldg. 102
Rockville, MD 20850
301-319-0000

FINAL AUTOPSY EXAMINATION REPORT

Name: BTB Adama, Kareem Maktoof
SSAN: (b)(6)
Date of Birth: (b)(6) 1959
Date of Death (b)(6) 2005
Date of Autopsy: 5 AUG 2005
Date of Report: 12 SEP 2005

Autopsy No.: (b)(6)
AFIP No. (b)(6)
Rank: Iraqi Detainee
Place of Death: Iraq
Place of Autopsy: Port Mortuary, Dover AFB, DE

Circumstances of Death: This 46-year-old male was an Iraqi detainee in U.S. custody who was found unresponsive in his prison cell on (b)(6) 2005. The man had been complaining of abdominal discomfort and refused to eat on the day he died.

Authorization for Autopsy: Armed Forces Medical Examiner, per 10 U.S. Code 1471

Identification: Circumstantial identification is by accompanying paperwork and an identification bracelet on the right wrist that displays a photo of the deceased as well as demographic information. A sample of DNA is retained as a matter of record.

CAUSE OF DEATH: Anomalous Right Coronary Artery Complicated by Atherosclerotic Cardiovascular Disease

MANNER OF DEATH: Natural

ACLU Detainee DeathII ARMY MEDCOM 313

FINAL AUTOPSY DIAGNOSES:

I. **Anomalous right coronary artery**

II. **Atherosclerotic Cardiovascular Disease, with up to 70% luminal narrowing of the left anterior descending coronary artery, 25-30% luminal narrowing of the left circumflex coronary artery, up to 60% luminal narrowing of the right coronary artery, and mild intimal thickening of the left main coronary artery**

III. **Cardiomegaly (Heart weight 480-grams); dilatation of the right atrium and right ventricle of the heart**

IV. **Abrasion of the medial right wrist. Contusion of the posterior left hand and left wrist. No other external or internal evidence of significant recent injury**

V. **Evidence of a healed fracture of the right femur, consistent with the history of injuries in a motor vehicle crash in 1983**

VI. **Early decomposition changes, including vascular marbling and green discoloration of soft tissue**

VII. **Toxicology is negative for ethanol and screened drugs of abuse. Blood carboxyhemoglobin and cyanide concentrations are not elevated. Blood and bile have small amounts of acetone and 2-propanol present.**

ACLU Detainee DeathII ARMY MEDCOM 314

EXTERNAL EXAMINATION

The remains are received clad in white undershorts and a partially cut away white overgarment. They consist of a well-developed, well-nourished, male. Early to moderate decomposition changes are present, including green discoloration of soft tissue and marbling of the vasculature. Livor is posterior and fixed, except in areas exposed to pressure. Rigor is present but passing. The body temperature is that of the refrigeration unit.

The scalp is covered with medium length, black hair in a normal distribution. The corneae are cloudy and the eyes have lost considerable turgor. The sclerae are unremarkable. The irides are brown and the pupils are round and equal in diameter. The teeth are natural and in fair condition. Facial hair consists of a black beard and mustache. There is marked suffusion of the soft tissue of the face and neck. A 1/8-inch pigmented nevis is on the posterior neck.

The neck is mobile and the trachea is midline. The chest is symmetric and unremarkable. The abdomen is protuberant but free of evidence of injury. A 1/8-inch nevis is on the right upper back. The external genitalia are those of a normal adult, circumcised, male. The testes are descended and free of masses. Pubic hair is present in a normal distribution. The buttocks and anus are remarkable only for a ¼-inch skin tag on the superior-medial right buttock. The upper and lower extremities are symmetric and without clubbing or edema. The fingernails are intact. A 16 x 1-inch-inch scar is on the lateral right thigh. There is a scar on the lateral, proximal left arm that is consistent with a remote vaccination.

An identification band on the right wrist has a picture of the decedent and (b)(6) (b)(6) No tattoos or other identifying body marks are noted.

MEDICAL INTERVENTION

Evidence of medical intervention includes an endotracheal tube that enters the right mainstem bronchus via the mouth, a Foley catheter in the urethra, and vascular access cut-down attempts on the medial aspect of both ankles

RADIOGRAPHS

A complete set of postmortem radiographs is obtained and demonstrates an absence of acute skeletal trauma and metallic foreign bodies. There is evidence of a remote fracture of the right femur that is now healed

EVIDENCE OF INJURY

On the posterior aspect of the right hand and right wrist is a 1 ½ x 1-inch area of ecchymosis. A ½ x ¼-inch abrasion is on the medial aspect of the right wrist. There is no other evidence of significant acute injury.

ACLU Detainee DeathII ARMY MEDCOM 315

INTERNAL EXAMINATION

HEAD:
The scalp, skull, and brain have no evidence of acute injury. There is some softening of the brain present, due to decomposition. The brain weighs 1350-grams and sectioning reveals no parenchymal injuries and no evidence of significant natural disease processes.

NECK:
The strap muscles of the anterior neck are homogenous and red-brown, without hemorrhage. The thyroid cartilage and hyoid bone are without injury. The tongue is unremarkable. The larynx is lined by intact white mucosa. The thyroid gland is symmetric and red-brown, without cystic or nodular change.

BODY CAVITIES:
The ribs, sternum, and vertebral bodies are visibly and palpably intact. Both pleural cavities contain 20-milliliters of decomposition fluid. There is no excess accumulation of fluid in the peritoneal cavity. There are 10-milliliters of decomposition fluid in the pericardial sac. The organs occupy their usual anatomic positions.

RESPIRATORY SYSTEM:
The right and left lungs weigh 800 and 670-grams, respectively, and are markedly congested. The external surfaces are red-purple, with moderate anthracotic pigment deposition. The pulmonary parenchyma is diffusely congested, without mass lesions or areas of consolidation. The pulmonary arteries are unremarkable.

CARDIOVASCULAR SYSTEM:
The 480-gram heart is contained in an intact pericardial sac. A formal Cardiovascular Pathology consultation is available as a separate document. In summary, the consultant demonstrated an anomalous right coronary artery with a high takeoff and a course that runs between the aortic and pulmonic roots. The coronary circulation is right dominant and there is moderate luminal narrowing by atherosclerosis, with the most severely affected vessel being the left anterior descending coronary artery per the consultant's report. Decomposition changes and myocyte hypertrophy are described on examination of histologic sections of myocardium as performed by the consultant. The aorta gives rise to three intact and patent arch vessels. The renal and mesenteric vessels are unremarkable.

LIVER & BILIARY SYSTEM:
The 1470-gram liver has an intact capsule and a sharp anterior border. The parenchyma is tan-brown and congested. No mass lesions or other abnormalities are noted. The gallbladder contains 25-milliliters of green-black bile and no stones. The mucosal surface is green and velvety. The extrahepatic biliary tree is patent.

SPLEEN:
The 40-gram spleen has a smooth, intact, red-purple capsule. The parenchyma is maroon, soft, congested, and exhibits early decomposition changes. A 1-centimeter accessory spleen is noted.

ACLU Detainee DeathII ARMY MEDCOM 316

PANCREAS:
The pancreas is soft and exhibits changes of decomposition. The usual lobular architecture is present. No mass lesions or other abnormalities are seen.

ADRENAL GLANDS:
The right and left adrenal glands are symmetric, with yellow cortices and gray medullae. Decomposition changes are prominent. No masses or areas of hemorrhage are identified.

GENITOURINARY SYSTEM:
The right and left kidneys weigh 100 and 130-grams, respectively. The external surfaces are intact and smooth. The cut surfaces are red-tan and congested, with uniformly thick cortices and distinct corticomedullary junctions. The pelves are unremarkable and the ureters are normal in course and caliber. White bladder mucosa overlies an intact bladder wall. The urinary bladder is empty. The prostate gland is normal in size, with lobular, yellow-tan parenchyma. The seminal vesicles are unremarkable. The testes are free of mass lesions, contusions, or other abnormalities.

GASTROINTESTINAL TRACT:
The esophagus is intact and lined by smooth, gray-white mucosa. The gastric wall is intact and lined by unremarkable mucosa. The stomach contains 20-milliliters of brown fluid. The duodenum, loops of small bowel, and colon are unremarkable. The appendix is present.

MUSCULOSKELETAL:
No non-traumatic abnormalities of muscle or bone are identified.

MICROSCOPIC EXAMINATION

Select portions of major organs are retained in formalin, with preparation of microscopic slides only for the examination of the heart (see Cardiovascular Pathology consultation).

ACLU Detainee DeathII ARMY MEDCOM 317

ADDITIONAL PROCEDURES/REMARKS

- Documentary photographs are taken by OAFME staff photographers
- Specimens retained for toxicologic testing and/or DNA identification are: heart blood, bile, brain, lung, kidney, liver, spleen, adipose tissue, and psoas muscle
- The dissected organs are forwarded with the body

OPINION

This male Iraqi detainee died as a result of an anomalous right coronary artery complicated by atherosclerotic cardiovascular disease. The abnormal anatomic course of the right coronary artery would be sufficient to account for death due to a fatal cardiac arrhythmia. The atherosclerosis noted at autopsy as well as the presence of an enlarged heart would make an arrhythmia even more likely. The only evidence of injury noted at autopsy was small abrasions and contusions that are consistent with the application of wrist restraints. The volatiles present on toxicologic studies are consistent with postmortem production due to decomposition. Test for exposure to cyanide and carbon monoxide were negative as was a drug screen. The manner of death is natural.

(b)(6)

(b)(6) **Medical Examiner**

ACLU Detainee DeathII ARMY MEDCOM 318

PATIENT IDENTIFICATION

(b)(6)

BTB ADAMA, Kareem Maktoof

(b)(6)

September 2, 2005

(b)(6)

1413 Research Blvd.
Bldg. 102
Rockville, MD 20850

FINAL DIAGNOSIS

DIAGNOSIS: (b)(6)

1. **Anomalous right coronary artery with high takeoff above commissure between left and right coronary cusps and proximal course between aortic and pulmonic roots**
2. **Moderate coronary atherosclerosis**

History: 46 year old Male Iraqi detainee found unresponsive in jail cell; recent complaints of abdominal discomfort

Heart: 480 grams, per autopsy protocol; dusky purple-gray discoloration of epicardial surface, predominantly right atrium and right ventricle; closed foramen ovale; normal left ventricular chamber dimensions: left ventricular cavity diameter 35 mm, left ventricular free wall thickness 9 mm, ventricular septum thickness 11 mm; dilatation of right atrium and right ventricle: right ventricle thickness 3 mm; unremarkable valves and endocardium; induration and transmural dark purple discoloration of right atrium and right ventricle; histologic sections show early post-mortem decomposition, mild left ventricular myocyte hypertrophy with patchy subendocardial interstitial fibrosis and fat deposition; sections of right ventricle show intracellular granular brown pigment consistent with formalin pigment, but no myocardial necrosis is seen

Coronary arteries: Right dominant circulation; anomalous right coronary artery with ostium located 15 mm above commissure between left and right coronary cusps, ostial ridge and proximal course between aortic and pulmonic roots;

Left main coronary artery: Mild intimal thickening

Left anterior descending artery (LAD): 40% luminal narrowing of proximal LAD by neointimal thickening; 70% narrowing of mid LAD by healed plaque erosion with smooth muscle rich neointimal thickening and focal intimal organizing fibrin deposition

Left circumflex artery (LCA): 25 to 30% narrowing of proximal and mid LCA by fibroatheroma

Right coronary artery (RCA): 50% narrowing of proximal RCA by healed erosion with organized and recanalized thrombus; 60% narrowing of mid RCA by fibroatheroma

Comment: The cause of death is attributed to the anomalous right coronary artery in conjunction with moderate atherosclerosis. The mechanism of death is likely arrhythmic.

ACLU Detainee DeathII ARMY MEDCOM 319

(b)(6) **ADAMA, Kareem Maktoof**



Anomalous right coronary artery

(b)(6)

Cardiovascular Pathologist

ıade: 18 (10 heart, 8 coronary arteries)
ıde: 26 (18 H&E, 8 Movat)

ACLU Detainee DeathII ARMY MEDCOM 320

(b)(6)

CERTIFICATE OF DEATH (OVERSEAS)

Acte dé décès (D'Outre-Mer)

NAME OF DECEASED (Last, First, Middle) Nom du décédé (Nom et prénoms)	GRADE Grade	BRANCH OF SERVICE Arme	SOCIAL SECURITY NUMBER Numéro de l'Assurance Social
BTB Adama, Kareem, Maktoof		Civilian	(b)(6)
ORGANIZATION Organisation	**NATION** (e.g. United States) Pays	**DATE OF BIRTH** Date de naissance	**SEX** Sexe
Iraqi Detainee	Iraq		[X] MALE [ ] FEMALE

RACE Race		MARITAL STATUS État Civil			RELIGION Culte		
[X]	CAUCASOID Caucasique	[ ]	SINGLE Célibataire	[ ] DIVORCED Divorcé	[ ] PROTESTANT Protestant	[X]	OTHER (Specify) Autre (Spécifier)
[ ]	NEGROID Negroide	[ ]	MARRIED Marié	[ ] SEPARATED Séparé	[ ] CATHOLIC Catholique		
[ ]	OTHER (Specify) Autre (Spécifier)	[ ]	WIDOWED Veuf		[ ] JEWISH Juif		

NAME OF NEXT OF KIN Nom du plus proche parent	RELATIONSHIP TO DECEASED Parenté du décédé avec le sus
STREET ADDRESS Domicilé à (Rue)	CITY OR TOWN OR STATE (Include ZIP Code) Ville (Code postal compris)

MEDICAL STATEMENT Déclaration médicale

CAUSE OF DEATH (Enter only one cause per line) Cause du décés (N'indiquer qu'une cause par ligne)			INTERVAL BETWEEN ONSET AND DEATH Intervalle entre l'attaque et le décés
DISEASE OR CONDITON DIRECTLY LEADING TO DEATH [1] Maladie ou condition directement responsable de la mort.		Anomalous Right Coronary Artery Complicated by Atherosclerotic Cardiovascular Disease	
ANTECEDENT CAUSES Symptômes précurseurs de la mort.	MORBID CONDITION, IF ANY, LEADING TO PRIMARY CAUSE Condition morbide, s'il y a lieu, menant à la cause primaire		
	UNDERLYING CAUSE, IF ANY, GIVING RISE TO PRIMARY CAUSE Condition morbide, s'il y a lieu, menant à la cause primaire		
OTHER SIGNIFICANT CONDITIONS [2] Autres conditions significatives [2]			

MODE OF DEATH Condition de décés	AUTOPSY PERFORMED Autopsie effectuée [X] YES Oui [ ] NO Non	CIRCUMSTANCES SURROUNDING DEATH DUE TO EXTERNAL CAUSES Circonstances de la mort suscitées par des causes extérieures
[X] NATURAL Mort naturelle	MAJOR FINDINGS OF AUTOPSY Conclusions principales de l'autopsie	
[ ] ACCIDENT Mort accidentelle		
[ ] SUICIDE Suicide	NAME OF PATHOLOGIST Nom du pathologiste (b)(6)	
[ ] HOMICIDE Homicide	(b)(6) DATE Date 4 August 2005	AVIATION ACCIDENT Accident à Avion [ ] YES Oui [X] NO Non

DATE OF DEATH (Hour, day, month, year) Date de décés (Heure, le jour, le mois, l'année)	PLACE OF DEATH Lieu de décés
(b)(6) 2005	Iraq

I HAVE VIEWED THE REMAINS OF THE DECEASED AND DEATH OCCURRED AT THE TIME INDICATED AND FROM THE CAUSES AS STATED ABOVE.
J'ai examiné les restes mortels du dé funt je conclus que le décés est survenu à l'heure indiquée et à, la suite des causes énumérées ci-dessus.

NAME OF MEDICAL OFFICER Nom du médicin militaire ou du médicin sanitaire	TITLE OR DEGREE Titre ou diplômé
(b)(6)	Medical Examiner

GRADE Grade	INSTALLATION OR ADDRESS Installation ou adresse
(b)(6)	Dover AFB, Dover DE
DATE Date 21 Sep 2005	(b)(6)

[1] State disease, injury or complication which caused death
[2] State conditions contributing to the death, but not related
[1] Préciser la nature de la maladie, de la blessure ou de la
[2] Préciser la condition qui a contribué à la mort, mais n'a

DD FORM 1 APR 77 2064 REPLACES DA

MEDCOM 0321

(REMOVE, REVERSE AND RE-INSERT CARBONS BEFORE COMPLETING THIS SIDE)

DISPOSITON OF REMAINS			
NAME OF MORTICIAN PREPARING REMAINS	GRADE	LICENSE NUMBER AND STATE	OTHER
INSTALLATION OR ADDRESS	DATE	SIGNATURE	
NAME OF CEMETERY OR CREMATORY	LOCATION OF CEMETERY OR CREMATORY		
TYPE OF DISPOSTION	DATE OF DISPOSTION		

REGISTRATION OF VITAL STATISTICS			
REGISTRY *(Town and Country)*	DATE REGISTERED	FILE NUMBER	
		STATE	OTHER
NAME OF FUNERAL DIRECTOR	ADDRESS		
SIGNATURE OF AUTHORIZED INDIVIDUAL			

DD FORM 2064, APR 1977 (BACK) ***USAPA V1.00***

ACLU Detainee DeathII ARMY MEDCOM 322

ARMED FORCES INSTITUTE OF PATHOLOGY
Office of the Armed Forces Medical Examiner
1413 Research Blvd., Bldg. 102
Rockville, MD 20850
1-800-944-7912

AUTOPSY EXAMINATION REPORT

Name: Unknown
SSAN: Not Applicable
Date of Birth: Unknown
Date of Death: (b)(6) 2005
Date of Autopsy: 09 JUL 2005
Date of Report: 31 AUG 2005

Autopsy No.: (b)(6)
AFIP No.: (b)(6)
Rank: Not Applicable
Place of Death: Haqlaniyah, Iraq
Place of Autopsy: Port Mortuary,
Dover Air Force Base, Dover, DE

Circumstances of Death: Iraqi Armed Forces and United States Marines detained this unknown individual for suspicious activity. He attempted to flee and, after verbal commands to stop were ignored, he was engaged with deadly force.

Authorization for Autopsy: Office of the Armed Forces Medical Examiner, IAW 10 USC 1471

Identification: Positive identification is pending.

CAUSE OF DEATH: **Multiple gunshot wounds**

MANNER OF DEATH: **Homicide**

ACLU Detainee DeathII ARMY MEDCOM 323

FINAL AUTOPSY DIAGNOSES:

I. Multiple gunshot wounds

A. Gunshot wound to the back (#1)
1. Entrance on the center of the back
2. No soot or stippling present
3. Injury to the skin; subcutaneous tissue; muscle; posterior aspect of the left 9th interspace; left lung; and antero-lateral aspects of the left 3rd, 4th, and 5th ribs
4. Exit on the left side of the chest
5. No bullet or fragments recovered
6. Direction: back to front, right to left, and upward
7. Associated injuries: penetrating injury of the left lung, fracture of the left 3rd, 4th, and 5th ribs

B. Gunshot wound to the back (#2)
1. Entrance on the left side of the back
2. No soot or stippling present
3. Injury to the skin, subcutaneous tissue, muscle, posterior-lateral aspect of the left 9th rib, left lung, heart, the anterior aspect of the left 1st interspace, and the left clavicle
4. Exit above the left clavicle
5. No bullet or fragments recovered
6. Direction: back to front, left to right, and upward
7. Associated injuries: fracture of the left 9th rib, penetrating injury of the left lung, pulpifaction of the heart, and fracture of the left clavicle

II. No natural disease identified within the limitations of the examination

III. No evidence of medical treatment

IV. Moderate decomposition

V. Toxicology
A. Alcohol
1. Kidney: trace acetaldehyde, 91 mg/dl ethanol, 6 mg/dl 1-propanol
2. Liver: 5 mg/dl acetaldehyde, 56 mg/dl ethanol, trace 1-propanol
B. Screened drugs of abuse and medications: none

ACLU Detainee DeathII ARMY MEDCOM 324

EXTERNAL EXAMINATION

The body is that of a well-developed, well-nourished appearing, muscular, 67 inch tall, 131 pounds Caucasoid male. Lividity is faint on the back and rigor is absent. Decomposition changes consist of diffuse skin slippage, marbling of the upper and lower extremities, diffuse putrefaction, and mummification of the fingers and toes.

The scalp is covered with short, straight brown hair in a normal distribution. Facial hair consists of a moustache and beard. An accumulation of insect eggs is present around the left eye. The irides are brown and the pupils are round and equal in diameter. The external auditory canals are clear. The ears are unremarkable. The nares are patent and the lips are atraumatic. The nose and maxillae are palpably stable. The teeth appear natural and in good condition.

The neck is straight, and the trachea is midline and mobile. The chest is symmetric; injuries of the chest are described below. The abdomen is flat. Injuries of the back are described below. The genitalia are those of a normal adult male. The testes are descended and free of masses. Pubic hair is present in a normal distribution. The buttocks and anus are unremarkable.

The upper and lower extremities are symmetric and without clubbing or edema.

CLOTHING AND PERSONAL EFFECTS

The following clothing items and personal effects are previously removed and submitted in a red plastic bag at the time of autopsy:

- two gray socks
- brown leather belt
- green briefs
- white long underwear pants
- black slacks
- tan tank top
- plaid shirt

Defects of the tank top and shirt are consistent with the underlying wounds.

MEDICAL INTERVENTION

There is no evidence of medical intervention.

RADIOGRAPHS

A complete set of postmortem radiographs is obtained and demonstrates the following:

- fracture of the left clavicle
- fractures of the left ribs 3 to 5

ACLU Detainee DeathII ARMY MEDCOM 325

EVIDENCE OF INJURY

The ordering of the following injuries is for descriptive purposes only, and is not intended to imply order of infliction or relative severity. All wound pathways are given relative to standard anatomic position.

I. Multiple gunshot wounds

A. Gunshot wound to the back (#1)
A gunshot entrance wound is on the center of the back, located 17" below the top of the head and 1/2" left of the posterior midline. The circular wound measures 1/8" in diameter with a 1/4" eccentric marginal abrasion on the 3 o'clock border. Soot and stippling are not present on the skin surrounding the wound. The wound path injures the skin, subcutaneous tissue, muscle, the posterior aspect of the left 9th interspace, the lower and upper lobes of the left lung, and the anterior aspects of the left 3rd, 4th, and 5th ribs. The bullet exits via a 3" x 2" irregular wound, located 13-1/2" below the top of the head and 3" left of the anterior midline. No bullet or fragments are recovered from the wound path. The wound path is directed back to front, right to left, and upward. Associated injuries include a penetrating injury of the left lung and fracture of the left 3rd, 4th, and 5th ribs.

B. Gunshot wound to the back (#2)
A gunshot entrance wound is on the left side of the back, located 20-1/2" below the top of the head and 5-1/2" left of the posterior midline. The circular wound measures 1/8" in diameter with a 1/4" eccentric marginal abrasion on the 5 to 6 o'clock border. Soot and stippling are not present on the skin surrounding the wound. The wound path injures skin, subcutaneous tissue, muscle, the posterior-lateral aspect of the left 9th rib, the lower lobe of the lung, the heart, the anterior aspect of the right 1st interspace, and the left clavicle. The bullet exits via a 3/4" x 1/2" irregular wound, located 7-1/2" below the top of the head and 4-1/2" left of the anterior midline. No bullet or fragments are recovered from the wound path. The wound path is directed back to front, left to right, and upward. Associated injuries include fracture of the left 9th rib, penetrating injury of the left lung, pulpifaction of the heart, and fracture of the left clavicle

INTERNAL EXAMINATION

HEAD:
The galeal and subgaleal soft tissues of the scalp are free of injury. The calvarium is intact, as is the dura mater beneath it. The brain weighs 1130 gm. The surface of the brain has mild to moderate putrefactive changes, however the gyri and sulci are otherwise unremarkable. Coronal sections demonstrate sharp demarcation between white and gray matter, without hemorrhage or contusive injury. The ventricles are of normal size. The basal ganglia, brainstem, cerebellum, and arterial systems are free of injury or other abnormalities. There are no skull fractures. The atlanto-occipital joint is stable.

ACLU Detainee DeathII ARMY MEDCOM 326

NECK:
The anterior strap muscles of the neck are homogenous and red-brown, without hemorrhage. The thyroid cartilage and hyoid are intact. The larynx is lined by intact white mucosa. The thyroid is symmetric and red-brown, without cystic or nodular change. The tongue is free of bite marks, hemorrhage, or other injuries.

BODY CAVITIES:
Injuries of the ribs have been described. The uninjured ribs, sternum, and vertebral bodies are visibly and palpably intact. No excess fluid is in the pleural, pericardial, or peritoneal cavities. The organs occupy their usual anatomic positions.

RESPIRATORY SYSTEM:
Injuries of the left lung have been described. The right and left lungs weigh 250 and 170 gm, respectively. The intact external surfaces are smooth with mild to moderate putrefaction. Putrefactive changes are also present on the cut surfaces of the lungs.

CARDIOVASCULAR SYSTEM:
Injury of the heart has been described. The heart weighs 180 gm. The epicardium is smooth with minimal fat investment. The myocardium has severe putrefactive changes and is soft. Injuries of the heart prevent further evaluation of the coronary arteries, heart valves, and chamber walls. The uninjured endocardium has putrefactive changes. The aorta gives rise to three intact and patent arch vessels. The renal and mesenteric vessels are unremarkable.

LIVER & BILIARY SYSTEM:
The 720 gm liver has an intact, smooth capsule and a sharp anterior border. The parenchyma is tan-brown and congested, with the usual lobular architecture. No mass lesions or other abnormalities are seen. The gallbladder contains no bile and no stones. The mucosal surface is green and velvety. The extrahepatic biliary tree is patent.

SPLEEN:
The 110 gm spleen has a smooth, intact, red-purple capsule. The parenchyma is maroon and congested, with distinct Malpighian corpuscles.

PANCREAS:
The pancreas is soft and yellow-tan, with the usual lobular architecture. No mass lesions or other abnormalities are seen.

ADRENALS:
The right and left adrenal glands are symmetric, with pale yellow cortices and soft red medullae. No masses or areas of hemorrhage are identified.

GENITOURINARY SYSTEM:
The right and left kidneys weigh 70 and 60 gm, respectively. The external surfaces are intact and smooth. The cut surfaces are red-tan and congested, with uniformly thick cortices and sharp corticomedullary junctions. The pelves are unremarkable and the

ACLU Detainee DeathII ARMY MEDCOM 327

ureters are normal in course and caliber. White bladder mucosa overlies an intact bladder wall. The bladder contains no urine. The prostate is normal in size, with lobular, yellow-tan parenchyma. The seminal vesicles are unremarkable. The testes are free of mass lesions, contusions, or other abnormalities.

GASTROINTESTINAL TRACT:
The esophagus is intact and lined by smooth, grey-white mucosa. The stomach contains approximately 100 ml of mixed solids and fluids. The gastric wall is intact. The duodenum, loops of small bowel, and colon are unremarkable. The appendix is present.

ADDITIONAL PROCEDURES

1. Documentary photographs are taken by OAFME staff.
2. Personal effects are released to the appropriate mortuary operations representatives.
3. Specimens retained for toxicologic testing and/or DNA identification are: gastric contents, brain, liver, psoas, lung, spleen, kidney, and adipose tissue.
4. The dissected organs are forwarded with body.

MICROSCOPIC EXAMINATION

Selected portions of organs are retained in formalin, without preparation of histologic slides.

ACLU Detainee DeathII ARMY MEDCOM 328

OPINION

This unknown individual died of multiple gunshot wounds. Severe wounds to the left lung and heart were sustained from two gunshot wounds to the back. No evidence of close range fire was present around the two wounds and no bullets or fragments were recovered from either wound path. Toxicology tests for alcohol suggest decomposition changes; tests for screened drugs of abuse and medications are negative. The manner of death is homicide. Since positive identification is pending, this report may be amended should this information become available.

(b)(6)

(b)(6) Medical Examiner

(b)(6)

(b)(6) Medical Examiner

ACLU Detainee DeathII ARMY MEDCOM 329

CERTIFICATE OF DEATH *(OVERSEAS)*

Acte de décès (D'Outre-Mer)

NAME OF DECEASED *(Last, First, Middle)* Nom du décédé (Nom et prénoms)	GRADE Grade	BRANCH OF SERVICE Arme	SOCIAL SECURITY NUMBER Numéro de l'Assurance Sociale
(b)(6)		Civilian	(b)(6)
ORGANIZATION Organisation	NATION *(e.g. United States)* Pays	DATE OF BIRTH Date de naissance	SEX Sexe
	Iraq		[X] MALE [ ] FEMALE

RACE Race		MARITAL STATUS État Civil			RELIGION Culte		
	CAUCASOID Caucasique		SINGLE Célibataire		DIVORCED Divorcé		PROTESTANT Protestant		OTHER (Specify) Autre (Spécifier)
	NEGROID Negroide		MARRIED Marié		SEPARATED Séparé		CATHOLIC Catholique	X	
X	OTHER (Specify) Autre (Spécifier)		WIDOWED Veuf				JEWISH Juif		

NAME OF NEXT OF KIN Nom du plus proche parent	RELATIONSHIP TO DECEASED Parenté du décédé avec le sus
STREET ADDRESS Domicilé à (Rue)	CITY OR TOWN OR STATE *(Include ZIP Code)* Ville (Code postal compris)

MEDICAL STATEMENT Déclaration médicale

	CAUSE OF DEATH (Enter only one cause per line) Cause du décès (N'indiquer qu'une cause par ligne)	INTERVAL BETWEEN ONSET AND DEATH Intervalle entre l'attaque et le décès
DISEASE OR CONDITON DIRECTLY LEADING TO DEATH [1] Maladie ou condition directement responsable de la mort.	Gunshot wounds to the back	Seconds to Minutes
ANTECEDENT CAUSES Symptômes précurseurs de la mort. MORBID CONDITION, IF ANY, LEADING TO PRIMARY CAUSE Condition morbide, s'il y a lieu, menant à la cause primaire		
ANTECEDENT CAUSES Symptômes précurseurs de la mort. UNDERLYING CAUSE IF ANY, GIVING RISE TO PRIMARY CAUSE Condition morbide, s'il y a lieu, menant à la cause primaire		
OTHER SIGNIFICANT CONDITIONS [2] Autres conditions significatives		

MODE OF DEATH Condition de décès	AUTOPSY PERFORMED Autopsie effectuée	CIRCUMSTANCES SURROUNDING DEATH DUE TO EXTERNAL CAUSES Circonstances de la mort suscitées par des causes extérieures
[ ] NATURAL Mort naturelle	[X] YES Oui [ ] NO Non	
[ ] ACCIDENT Mort accidentelle	MAJOR FINDINGS OF AUTOPSY Conclusions principales de l'autopsie	
[ ] SUICIDE Suicide	NAME OF PATHOLOGIST Nom du pathologiste (b)(6)	
[X] HOMICIDE Homicide	(b)(6)	

DATE Date	AVIATION ACCIDENT Accident d'Avion
9 July 2005	[ ] YES Oui [X] NO Non

DATE OF DEATH *(Hour, day, month, year)* Date du décès (l'heure, le jour, le mois, l'année)	PLACE OF DEATH Lieu de décès
(b)(6) 2005	Iraq

I HAVE VIEWED THE REMAINS OF THE DECEASED AND DEATH OCCURRED AT THE TIME INDICATED AND FROM THE CAUSES AS STATED ABOVE
J'ai examiné les restes mortels du défunt je conclus que le décès est survenu à l'heure indiquée et à, la suite des causes énumérées ci-dessus.

NAME OF MEDICAL OFFICER Nom du médecin militaire ou du médecin sanitaire	TITLE OR DEGREE Titre ou diplômé
(b)(6)	Medical Examiner

GRADE Grade	INSTALLATION OR ADDRESS Installation ou adresse
(b)(6)	Dover AFB, Dover DE
DATE Date 04 Oct 05	(b)(6)

[1] State disease, injury or complication which caused death.
[2] State conditions contributing to the death, but not relating the disease or condition causing death.
[1] Préciser la nature de la maladie, de la blessure ou de la complication qui a entraîné à la mort, mais non la manière de mourir, telle qu'un arrêt du coeur, etc
[2] Préciser la condition qui a contribué à la mort, mais n'ayant aucun rapport avec la maladie ou à la condition qui a provoqué la mort

DD FORM 1 APR 77 2064 REPLACES DA FORM 3565, 1 JAN 72 AND DA FORM 3565-R(PAS), 26 SEP 75, WHICH ARE OBSOLETE.

ARMED FORCES INSTITUTE OF PATHOLOGY
Office of the Armed Forces Medical Examiner
1413 Research Blvd., Bldg. 102
Rockville, MD 20850
1-800-944-7912

AUTOPSY EXAMINATION REPORT

Name: Sweidan, Adnan Mukhlef Swedan
ISN: (b)(6)
Date of Birth: Unknown
Date of Death: (b)(6) 2005

Autopsy No.: (b)(6)
AFIP No.: (b)(6)
Rank: Not Applicable
Place of Death: Theater Internment Facility, Camp Bucca, Iraq

Date of Autopsy: 22 MAY 2005
Date of Report: 14 JUL 2005

Place of Autopsy: Port Mortuary, Dover Air Force Base, Dover, DE

Circumstances of Death: This Iraqi detainee presented with difficulty breathing 6 weeks after a sub-total thyroidectomy.

Authorization for Autopsy: Office of the Armed Forces Medical Examiner, IAW 10 USC 1471

Identification: Identification made through the use of his assigned Internment Serial Number.

CAUSE OF DEATH: Complications of Thyroid Surgery

MANNER OF DEATH: Accident

FINAL AUTOPSY DIAGNOSES:

I. Complications of thyroid surgery
   A. Status post left hemithyroidectomy
   B. Retained foreign body within the surgical site
   C. Penetration of the trachea
   D. Occlusion of the trachea from portion of retained foreign body

II. Evidence of medical intervention present, including needle puncture marks in both ante-cubital fossae, gauze bandage around the left ante-cubital fossa, and a ¼" incision on the anterior midline of the neck.

III. Mild postmortem changes present

IV. Toxicology tests for alcohol and screened drugs of abuse and medications are negative

ACLU Detainee DeathII ARMY MEDCOM 332

EXTERNAL EXAMINATION

The body is that of a well-developed, well-nourished appearing, muscular, 68 inch tall, 141 pounds dark-skinned, Caucasoid male whose appearance is consistent with the reported age range of 30 to 40 years. Lividity is present and fixed on the posterior aspects of the body. Rigor is not present. The body is cold.

The scalp is covered with brown, straight hair of medium length in a normal distribution. The irides are brown, the corneae are hazy, the sclerae are white, and the pupils are round and equal in diameter. The external auditory canals are clear. The ears are unremarkable. Blood is present in the external nares and oral cavity. The lips are atraumatic. The nose and maxillae are palpably stable. The teeth appear natural and in good condition.

The neck is straight and the trachea is midline and mobile; an anterior midline 1/4" incision exudes pus when manipulated and an anterior midline 2-1/2" healed scar is below this incision. The chest is symmetric. The abdomen is protuberant. The genitalia are those of a normal adult male. The testes are descended and free of masses. Pubic hair is present in a normal distribution. The buttocks and anus are unremarkable.

The upper and lower extremities are symmetric and without clubbing or edema.

CLOTHING AND PERSONAL EFFECTS

The following clothing items and personal effects are present on the body at the time of autopsy:

- Green and blood-soaked towel wrapped around the waist

MEDICAL INTERVENTION

- Gauze bandage wrapped around the left arm
- Needle puncture marks in the right and left ante-cubital fossae
- 1/4" incision of the anterior midline of the neck

RADIOGRAPHS

A complete set of postmortem radiographs is obtained and demonstrates no significant injuries.

EVIDENCE OF INJURY

No significant traumatic injury is identified in the external and internal examinations.

ACLU Detainee DeathII ARMY MEDCOM 333

INTERNAL EXAMINATION

HEAD:
The galeal and subgaleal soft tissues of the scalp are free of injury. The calvarium is intact, as is the dura mater beneath it. Clear cerebrospinal fluid surrounds the 1640 gm brain, which has unremarkable gyri and sulci. Coronal sections demonstrate sharp demarcation between white and grey matter, without hemorrhage or contusive injury. The ventricles are of normal size. The basal ganglia, brainstem, cerebellum, and arterial systems are free of injury or other abnormalities. There are no skull fractures. The atlanto-occipital joint is stable.

NECK:
The anterior strap muscles of the neck are homogenous and red-brown, with mild edema of the strap muscles of the left side. The left lobe of the thyroid is absent and a blood-soaked surgical gauze is present in the area previously occupied by the thyroid lobe. The gauze penetrates into the lumen of the trachea through a 1.5 cm in diameter fistula involving the left lateral aspect of the cricoid cartilage. The gauze occludes the airway. The right thyroid lobe is present and unremarkable. The thyroid cartilage and hyoid are intact. The larynx is lined by intact white mucosa. The tongue is free of bite marks, hemorrhage, or other injuries.

BODY CAVITIES:
The ribs, sternum, and vertebral bodies are visibly and palpably intact. No excess fluid is in the pleural, pericardial, or peritoneal cavities. The organs occupy their usual anatomic positions.

RESPIRATORY SYSTEM:
The right and left lungs weigh 610 and 590 gm, respectively. The external surfaces are smooth and deep red-purple. The pulmonary parenchyma is diffusely congested and edematous. No mass lesions or areas of consolidation are present.

CARDIOVASCULAR SYSTEM:
The 350 gm heart is contained in an intact pericardial sac. The epicardial surface is smooth, with minimal fat investment. The coronary arteries are present in a normal distribution, with a right-dominant pattern. Cross sections of the vessels show no significant atherosclerosis. The myocardium is homogenous, red-brown, and firm. The valve leaflets are thin and mobile. The walls of the left and right ventricles are 1.1 and 0.4-cm thick, respectively. The endocardium is smooth and glistening. The aorta gives rise to three intact and patent arch vessels. The renal and mesenteric vessels are unremarkable.

LIVER & BILIARY SYSTEM:
The 1510 gm liver has an intact, smooth capsule and a sharp anterior border. The parenchyma is tan-brown and congested, with the usual lobular architecture. On sectioning, there is a 2 cm in diameter smooth-walled cyst with thin, cloudy fluid. The

ACLU Detainee DeathII ARMY MEDCOM 334

gallbladder contains a minute amount of green-black bile and no stones. The mucosal surface is green and velvety. The extrahepatic biliary tree is patent.

SPLEEN:
The 190 gm spleen has a smooth, intact, red-purple capsule. The parenchyma is maroon and congested, with distinct Malpighian corpuscles.

PANCREAS:
The pancreas is firm and yellow-tan, with the usual lobular architecture. No mass lesions or other abnormalities are seen.

ADRENALS:
The right and left adrenal glands are symmetric, with bright yellow cortices and grey medullae. No masses or areas of hemorrhage are identified.

GENITOURINARY SYSTEM:
The right and left kidneys weigh 90 and 100 gm, respectively. The external surfaces are intact and smooth. The cut surfaces are red-tan and congested, with uniformly thick cortices and sharp corticomedullary junctions. The pelves are unremarkable and the ureters are normal in course and caliber. White bladder mucosa overlies an intact bladder wall. The bladder contains approximately 10 cc of clear urine. The prostate is normal in size, with lobular, yellow-tan parenchyma. The seminal vesicles are unremarkable. The testes are free of mass lesions, contusions, or other abnormalities.

GASTROINTESTINAL TRACT:
The esophagus is intact and lined by smooth, grey-white mucosa. The stomach contains approximately 250 ml of mixed solids and fluids. The gastric wall is intact. The duodenum, loops of small bowel, and colon are unremarkable. The appendix is present.

ADDITIONAL PROCEDURES

1. Documentary photographs are taken by OAFME staff.
2. Trace evidence and foreign material are collected and given to investigating authorities.
3. Specimens retained for toxicologic testing and/or DNA identification are: vitreous, blood, bile, brain, lung, liver, spleen, kidney, adipose, psoas, and gastric contents.
4. The dissected organs are forwarded with body.
5. Personal effects are released to the appropriate mortuary operations representatives.
6. Identifying marks include: scars on the anterior midline of the neck, left shoulder blade (3), and left arm; hyperpigmentation of the left side of the chest; and hypopigmentation of the palm of the left hand.

MICROSCOPIC EXAMINATION

Selected portions of organs are retained in formalin, without preparation of histologic slides.

ACLU Detainee DeathII ARMY MEDCOM 335

OPINION

This Iraqi detainee (b)(6) died of complications from thyroid surgery. He developed hyperthyroidism from a goiter and had a partial thyroidectomy for treatment. A retained surgical sponge penetrated into the lumen of the trachea preventing adequate air exchange and leading to asphyxia. Toxicology tests for alcohol and screened drugs of abuse and medications are negative. The manner of death is accident.

(b)(6)

(b)(6) Medical Examiner

(b)(6)

(b)(6) Medical Examiner

ACLU Detainee DeathII ARMY MEDCOM 336

CERTIFICATE OF DEATH *(OVERSEAS)*
Acte dé décès (D'Outre-Mer)

NAME OF DECEASED *(Last, First, Middle)* Nom du décédé (Nom et prénoms)	GRADE Grade	BRANCH OF SERVICE Arme	SOCIAL SECURITY NUMBER Numéro de l'Assurance Social
BTB Sweidan, Al Habosi,		Civilian	(b)(6)
ORGANIZATION Organisation	NATION *(e.g. United States)* Pays: Iraq	DATE OF BIRTH Date de naissance	SEX Sexe: [X] MALE [ ] FEMALE

RACE Race		MARITAL STATUS État Civil			RELIGION Culte		
	CAUCASOID Caucasique		SINGLE Célibataire		DIVORCED Divorcé		PROTESTANT Protestant		OTHER (Specify) Autre (Spécifier)
	NEGROID Négroïde		MARRIED Marié		SEPARATED Séparé		CATHOLIC Catholique	X	
X	OTHER (Specify) Autre (Spécifier)		WIDOWED Veuf				JEWISH Juif		

NAME OF NEXT OF KIN Nom du plus proche parent	RELATIONSHIP TO DECEASED Parenté du décédé avec le sus
STREET ADDRESS Domicile à (Rue)	CITY OR TOWN OR STATE *(Include ZIP Code* Ville (Code postal compris)

MEDICAL STATEMENT Déclaration médicale

CAUSE OF DEATH (Enter only one cause per line) Cause du décès (N'indiquer qu'une cause par ligne)		INTERVAL BETWEEN ONSET AND DEATH Intervalle entre l'attaque et le décès
DISEASE OR CONDITON DIRECTLY LEADING TO DEATH[1] Maladie ou condition directement responsable de la mort.[1]	Complications from surgery	Days
ANTECEDENT CAUSES Symptômes précurseurs de la mort — MORBID CONDITION, IF ANY, LEADING TO PRIMARY CAUSE Condition morbide, s'il y a lieu, menant à la cause primaire		
ANTECEDENT CAUSES Symptômes précurseurs de la mort — UNDERLYING CAUSE, IF ANY, GIVING RISE TO PRIMARY CAUSE Condition morbide, s'il y a lieu, menant à la cause primaire		
OTHER SIGNIFICANT CONDITIONS[2] Autres conditions significatives[2]		

MODE OF DEATH Condition de décès	AUTOPSY PERFORMED Autopsie effectuée [X] YES Oui [ ] NO Non	CIRCUMSTANCES SURROUNDING DEATH DUE TO EXTERNAL CAUSES Circonstances de la mort suscitées par des causes extérieures
NATURAL Mort naturelle	MAJOR FINDINGS OF AUTOPSY Conclusions principales de l'autopsie	
X ACCIDENT Mort accidentelle		
SUICIDE Suicide	NAME OF PATHOLOGIST Nom du pathologiste (b)(6)	
HOMICIDE Homicide	(b)(6) DATE Date 22 May 2005	AVIATION ACCIDENT Accident à Avion [ ] YES Oui [X] NO Non

DATE OF DEATH *(Hour, day, month, year)* Date de décès (l'heure, le jour, le mois, l'année)	PLACE OF DEATH Lieu de décès
(b)(6) 2005	Iraq

I HAVE VIEWED THE REMAINS OF THE DECEASED AND DEATH OCCURRED AT THE TIME INDICATED AND FROM THE CAUSES AS STATED ABOVE.
J'ai examiné les restes mortels du dé funtot je conclus que le décès est survenu à l'heure indiquée et à, la suite des causes énumérées ci-dessus

NAME OF MEDICAL OFFICER Nom du médecin militaire ou du médecin sanitaire	TITLE OR DEGREE Titre ou diplômé
(b)(6)	Armed Forces Medical Examiner
GRADE Grade (b)(6)	INSTALLATION OR ADDRESS Installation ou adresse Dover AFB, Dover DE
DATE Date 04 OCT 05	(b)(6)

[1] State disease, injury or complication which caused dea
[2] State conditions contributing to the death, but not relat
[1] Préciser la nature de la maladie, de la blessure ou de l
[2] Préciser la condition qui a contribué à la mort, mais n'a ... du coeur, etc.

DD FORM 1 APR 77 2064 REPLACES DA FORM 3565, 1 JAN 72 AND DA FORM 3565-R(PAS), 26 SEP 75, WHICH ARE OBSOLETE.

MEDCOM 0337

(REMOVE, REVERSE AND RE-INSERT CARBONS BEFORE COMPLETING THIS SIDE)

DISPOSITON OF REMAINS			
NAME OF MORTICIAN PREPARING REMAINS	GRADE	LICENSE NUMBER AND STATE	OTHER
INSTALLATION OR ADDRESS	DATE	SIGNATURE	
NAME OF CEMETERY OR CREMATORY	LOCATION OF CEMETERY OR CREMATORY		
TYPE OF DISPOSTION	DATE OF DISPOSTION		

REGISTRATION OF VITAL STATISTICS			
REGISTRY *(Town and Country)*	DATE REGISTERED	FILE NUMBER	
		STATE	OTHER
NAME OF FUNERAL DIRECTOR	ADDRESS		
SIGNATURE OF AUTHORIZED INDIVIDUAL			

DD FORM 2064, APR 1977 (BACK) *USAPA V1.00*

ACLU Detainee DeathII ARMY MEDCOM 338

ARMED FORCES INSTITUTE OF PATHOLOGY
Office of the Armed Forces Medical Examiner
1413 Research Blvd., Bldg. 102
Rockville, MD 20850
1-800-944-7912

AUTOPSY EXAMINATION REPORT

Name: BTR Hachim, Ibrahim M.
Detainee #(b)(6)
Date of Birth: BTR 1950
Date of Death(b)(6) 2005
Date of Autopsy: 3 May 2005

Autopsy No.:(b)(6)
AFIP No.:(b)(6)
Rank: Civilian
Place of Death: Camp Bucca, Iraq
Place of Autopsy: Port Mortuary, Dover AFB, DE

Date of Report: 26 May 2005

Circumstances of Death: By report, this approximately 55 year-old civilian detainee at Camp Bucca, Iraq suddenly collapsed while eating breakfast. Medical personnel noticed eggs in the upper airway, which they removed during resuscitation attempts.(b)(6) reported during a medical screening that he was diabetic but by report there was no medical testing to confirm this and he had not received medication. He had apparently not eaten for three days prior to his collapse.

Authorization for Autopsy: Office of the Armed Forces Medical Examiner, IAW 10 USC 1471

Identification: Tentative identification by CID, postmortem fingerprint and dental examinations performed. Sample obtained for DNA analysis.

CAUSE OF DEATH: Arteriosclerotic cardiovascular disease

MANNER OF DEATH: Natural

ACLU Detainee DeathII ARMY MEDCOM 339

FINAL AUTOPSY DIAGNOSES:

I. Severe coronary arteriosclerosis
   A. Left main coronary artery with focal 75% stenosis
   B. Left anterior descending coronary artery with 80-90% proximal stenosis, 50-75% mid stenoses, and 80% stenosis of the proximal first diagonal branch
   C. Left circumflex coronary artery with 50% proximal stenosis and focal 75% mid stenosis
   D. Right coronary artery with 50-80% proximal stenoses, and 50-75% mid and distal stenoses
   E. Mild atherosclerosis of the coronary ostia
   F. Moderate-severe atherosclerotic plaque formation of the distal aorta, just proximal to the iliac bifurcation
   G. Mild cardiomegaly for weight (heart=400 grams, predicted=306 grams)
      1. Left ventricle=15 mm in thickness
   H. Pulmonary edema and congestion (combined weight=1250 grams)

II. No foreign body within the airway
   A. Less than 5 ml of granular liquid within the trachea
   B. Poor dentition

III. Mild atrophy of the brain
   A. Brain weight=1260 grams
   B. Mild ventricular enlargement

IV. Simple cortical cyst of the right kidney

V. Multi-nodular thyroid

VI. Anterior neck dissection negative for trauma

VII. Posterior thoracic and cervical dissection negative for trauma (bifid spinous processes of the cervical vertebrae)

ACLU Detainee DeathII ARMY MEDCOM 340

VIII. Minor healing abrasions of the anterior right leg and right cheek

IX. Mild decomposition consisting of cloudy corneae and early green discoloration of the cecum

X. History of diabetes by self report
A. No report of medication administration
B. Incomplete medical records

XI. Toxicology negative

ACLU Detainee DeathII ARMY MEDCOM 341

EXTERNAL EXAMINATION

The body is that of a thin, 69 inch, 150 pound elderly male whose appearance is consistent with the reported age of 55 years. Lividity is red-purple, posterior, and fixed. Rigor is easily broken.

The scalp is covered with short, gray-black hair in a normal distribution. Corneal clouding obscures the irides. The conjunctivae and sclera are markedly injected, however, there are no petechiae. There are bilateral earlobe creases (Frank's sign). The external auditory canals are unremarkable. The nares are patent and the lips are atraumatic. The nose and maxillae are palpably stable. The teeth appear in severe disrepair with absence of the majority of the upper dentition. There are no foreign bodies within the oropharynx.

The neck is straight, and the trachea is midline and mobile. The chest is symmetric. The abdomen is flat. The genitalia are those of a normal adult male. The testes are descended and free of masses. Pubic hair is present in a normal distribution. The buttocks and anus are unremarkable.

The upper and lower extremities are symmetric and without clubbing or edema.

CLOTHING AND PERSONAL EFFECTS

The body is received nude at the time of autopsy.

MEDICAL INTERVENTION

There are no attached medical devices at the time of autopsy.

RADIOGRAPHS

A complete set of postmortem radiographs is obtained and demonstrates no fractures or radiopaque foreign bodies.

EVIDENCE OF INJURY

On the right cheek is a small red abrasion and on the lower right leg near the ankle are several small healing red abrasions.

Dissection of the back and buttocks reveal no contusions.

INTERNAL EXAMINATION

HEAD:
The galeal and subgaleal soft tissues of the scalp are free of injury. The calvarium is intact, as is the dura mater beneath it. Clear cerebrospinal fluid surrounds the 1260 gm brain, which has unremarkable gyri and sulci. Coronal sections demonstrate sharp demarcation between white and grey matter, without hemorrhage or contusive injury. The ventricles are mildly enlarged. The basal ganglia, brainstem, cerebellum, and arterial systems are free of injury or other abnormalities. There are no skull fractures. The atlanto-occipital joint is stable.

ACLU Detainee DeathII ARMY MEDCOM 342

NECK:
Layer-wise dissection of the neck reveals the anterior strap muscles of the neck are homogenous and red-brown, without hemorrhage. The thyroid cartilage and hyoid are intact. The larynx is lined by intact white mucosa. The thyroid is nodular and red-brown without cystic change. The tongue is free of bite marks, hemorrhage, or other injuries.

Incision and dissection of the posterior neck demonstrates no deep paracervical muscular injury and no posterior cervical spine fractures. There is no hemorrhage or laxity of the spinal ligaments. The cervical spinous processes are bifid.

BODY CAVITIES:
The ribs, sternum, and vertebral bodies are visibly and palpably intact. No excess fluid is in the pleural, pericardial, or peritoneal cavities. The organs occupy their usual anatomic positions.

RESPIRATORY SYSTEM:
The right and left lungs weigh 670 and 580 gm, respectively. The external surfaces are smooth and deep red-purple. The pulmonary parenchyma is diffusely congested and edematous. No mass lesions or areas of consolidation are present. The mainstem bronchi and branches are free of obstruction.

CARDIOVASCULAR SYSTEM:
The 400 gm heart (predicted=306 grams for weight) is contained in an intact pericardial sac. The epicardial surface is smooth, with minimal fat investment. The coronary arteries are present in a normal distribution, with a right-dominant pattern. Cross sections of the vessels show mild atherosclerosis of the coronary ostia. The left main coronary artery has a focal 75% stenosis. The left anterior descending coronary artery has an 80-90% proximal stenosis, 50-75% mid stenoses, and an 80% stenosis of the proximal portion of the first diagonal branch. The left circumflex coronary artery has a 50% proximal stenosis and a focal 75% mid stenosis. The right coronary artery has 50-80% proximal stenoses and 50-75% mid and distal stenoses. The myocardium is homogenous, red-brown, and firm. The valve leaflets are thin and mobile. The walls of the left and right ventricles are 1.5 and 0.5-cm thick, respectively. The septum measures 1.8-cm in thickness. The endocardium is smooth and glistening. The aorta gives rise to three intact and patent arch vessels. There is severe calcific plaque formation of the distal aorta slightly proximal to the iliac bifurcation. The renal and mesenteric vessels are unremarkable.

LIVER & BILIARY SYSTEM:
The 1530 gm liver has an intact, smooth capsule and a sharp anterior border. The parenchyma is tan-brown and congested, with the usual lobular architecture. No mass lesions or other abnormalities are seen. The gallbladder contains a minute amount of

ACLU Detainee DeathII ARMY MEDCOM 343

green-black bile and no stones. The mucosal surface is green and velvety. The extrahepatic biliary tree is patent.

SPLEEN:
The 150 gm spleen has a smooth, intact, red-purple capsule. The parenchyma is maroon and congested, with distinct Malpighian corpuscles.

PANCREAS:
The pancreas is firm and yellow-tan, with the usual lobular architecture. No mass lesions or other abnormalities are seen.

ADRENALS:
The right and left adrenal glands are symmetric, with bright yellow cortices and grey medullae. No masses or areas of hemorrhage are identified.

GENITOURINARY SYSTEM:
The right and left kidneys weigh 190 and 220 gm, respectively. There is a simple cortical cyst of the right kidney. Otherwise, the external surfaces are intact and smooth. The cut surfaces are red-tan and congested, with uniformly thick cortices and sharp corticomedullary junctions. The pelves are unremarkable and the ureters are normal in course and caliber. White bladder mucosa overlies an intact bladder wall. The bladder contains approximately 10 ml of cloudy yellow urine. The prostate is normal in size, with lobular, yellow-tan parenchyma. The seminal vesicles are unremarkable. The testes are free of mass lesions, contusions, or other abnormalities.

GASTROINTESTINAL TRACT:
The esophagus is intact and lined by smooth, grey-white mucosa. The stomach contains approximately 30 ml of brown liquid. The gastric wall is intact. The duodenum, loops of small bowel, and colon are unremarkable. The appendix is present and unremarkable.

ADDITIONAL PROCEDURES

- Documentary photographs are taken by AFMES photographers
- Specimens retained for toxicologic testing and/or DNA identification are: vitreous, blood, urine, spleen, liver, lung, kidney, brain, bile, gastric, adipose and psoas
- The dissected organs are forwarded with the body
- Personal effects are released to the appropriate mortuary operations representatives

ACLU Detainee Death|| ARMY MEDCOM 344

MICROSCOPIC EXAMINATION

Coronary arteries: Sections show atheromatous stenoses corresponding with the gross impression.

Myocardium: Sections show a mild increase in perivascular and interstitial fibrosis. No acute ischemic changes are noted microscopically.

Lungs: Sections show vascular congestion and atelectasis.

Liver: Section shows mild increase in periportal fibrosis and focal periportal chronic inflammation

Kidney: Nodular Kimmilstiel-Wilson lesions are not noted. There is no inflammatory infiltrate.

TOXICOLOGY

Toxicologic analysis of blood was negative for carbon monoxide, cyanide, ethanol, and drugs of abuse.

VITREOUS

Glucose was reported as less than 10 mg/dL.

ACLU Detainee DeathII ARMY MEDCOM 345

OPINION

This elderly male civilian detainee died of severe arteriosclerotic coronary artery disease (hardening and blockage of the blood vessels supplying blood to the heart). Microscopic sections of the heart showed the blockages of the arteries and evidence of chronic myocardial ischemia. Toxicology was negative for ethanol and drugs of abuse. Carbon monoxide and cyanide were not detected.

Vitreous glucose was reported as less than 10 mg/dL, consistent with a long interval from death to time of testing.

Detailed examination of the internal organs as well as dissection of the back, anterior neck, and posterior neck did not reveal occult trauma.

Sudden collapse due to arteriosclerotic coronary artery disease is common and is frequently the initial presentation of underlying heart disease. The finding of food within the mouth at the time of the collapse is felt to be secondary to the collapse and not causal. There were no food particles impacted within the airway at the time of autopsy. Severe coronary artery disease and chronic ischemic changes of the heart were noted by visual and microscopic examination.

The manner of death is natural.

(b)(6)

(b)(6) **Medical Examiner**

ACLU Detainee DeathII ARMY MEDCOM 346

DEPARTMENT OF DEFENSE
ARMED FORCES INSTITUTE OF PATHOLOGY
WASHINGTON, DC 20306-6000

REPLY TO ATTENTION OF

AFIP (b)(6)

PATIENT IDENTIFICATION
AFIP Accessions Number Sequence
(b)(6)

TO:

OFFICE OF THE ARMED FORCES MEDICAL EXAMINER
ARMED FORCES INSTITUTE OF PATHOLOGY
WASHINGTON, DC 20306-6000

Name
HACHIM, IBRAHIM MOHAMAD (b)(6)

SSAN: **Autopsy:** (b)(6)
Toxicology Accession #: (b)(6)
Date Report Generated: May 12, 2005

CONSULTATION REPORT ON CONTRIBUTOR MATERIAL

AFIP DIAGNOSIS **REPORT OF TOXICOLOGICAL EXAMINATION**

Condition of Specimens: GOOD
Date of Incident: **Date Received:** 5/10/2005

CARBON MONOXIDE: The carboxyhemoglobin saturation in the blood was less than 1% as determined by spectrophotometry with a limit of quantitation of 1%. Carboxyhemoglobin saturations of 0-3% are expected for non-smokers and 3-10% for smokers. Saturations above 10% are considered elevated and are confirmed by gas chromatography.

CYANIDE: There was no cyanide detected in the blood. The limit of quantitation for cyanide is 0.25 mg/L. Normal blood cyanide concentrations are less than 0.15 mg/L. Lethal concentrations of cyanide are greater than 3 mg/L.

VOLATILES: The **BLOOD AND URINE** were examined for the presence of ethanol at a cutoff of 20 mg/dL. No ethanol was detected.

DRUGS: The **BLOOD** was screened for amphetamine, antidepressants, antihistamines, barbiturates, benzodiazepines, cannabinoids, chloroquine, cocaine, dextromethorphan, lidocaine, narcotic analgesics, opiates, phencyclidine, phenothiazines, sympathomimetic amines and verapamil by gas chromatography, color test or immunoassay. The following drugs were detected:

None were found.

(b)(6)
Office of the Armed Forces Medical Examiner

(b)(6)
Office of the Armed Forces Medical Examiner

ACLU Detainee DeathII ARMY MEDCOM 347

CERTIFICATE OF DEATH (OVERSEAS)
Acte de décès (D'Outre-Mer)

NAME OF DECEASED (Last, First, Middle) Nom du décédé (Nom et prénoms)	GRADE Grade	BRANCH OF SERVICE Arme	SOCIAL SECURITY NUMBER Numéro de l'Assurance Sociale
BTB Hachim, Ibrahim, Mohamad		Civilian	(b)(6)

ORGANIZATION Organisation	NATION (e.g., United States) Pays	DATE OF BIRTH Date de naissance	SEX Sexe
	Iraq	(b)(6) 1950	☑ MALE Masculin ☐ FEMALE Féminin

RACE Race	MARITAL STATUS État Civil		RELIGION Culte	
X CAUCASOID Caucasique	SINGLE Célibataire	DIVORCED Divorcé	PROTESTANT Protestant	OTHER (Specify) Autre (Spécifier)
NEGROID Negriode	MARRIED Marié	SEPARATED Séparé	CATHOLIC Catholique	
OTHER (Specify) Autre (Spécifier)	WIDOWED Veuf		JEWISH Juif	

NAME OF NEXT OF KIN Nom du plus proche parent	RELATIONSHIP TO DECEASED Parenté du décédé avec le susdit
STREET ADDRESS Domicile à (Rue)	CITY OR TOWN AND STATE (Include ZIP Code) Ville (Code postal compris)

MEDICAL STATEMENT Déclaration médicale

CAUSE OF DEATH (Enter only once cause per line) Cause du décès (N'indiquer qu'une cause par ligne)		INTERVAL BETWEEN ONSET AND DEATH Intervalle entre l'attaque et le décès
DISEASE OR CONDITION DIRECTLY LEADING TO DEATH[1] Maladie ou condition directement responsable de la mort.[1]	Arteriosclerotic Cardiovascular Disease (ASCVD)	Minutes
ANTECEDENT CAUSES Symptômes précurseurs de la mort — MORBID CONDITION, IF ANY, LEADING TO PRIMARY CAUSE Condition mortelle, s'il y a lieu, menant à la cause primaire		
ANTECEDENT CAUSES Symptômes précurseurs de la mort — UNDERLYING CAUSE, IF ANY, GIVING RISE TO PRIMARY CAUSE Raison fondamentale, s'il y a lieu, ayant suscité la cause primaire		
OTHER SIGNIFICANT CONDITIONS[2] Autres conditions significatives[2]		

MODE OF DEATH Condition de décès	AUTOPSY PERFORMED Autopsie effectuée ☑ YES Oui ☐ NO Non	CIRCUMSTANCES SURROUNDING DEATH DUE TO EXTERNAL CAUSES Circonstances de la mort suscitées par des causes extérieures
X NATURAL Mort naturelle	MAJOR FINDINGS OF AUTOPSY Conclusions principales de l'autopsie	
ACCIDENT Mort accidentelle		
SUICIDE Suicide	NAME OF PATHOLOGIST Nom du pathologiste (b)(6)	
HOMICIDE Homicide	(b)(6) — DATE Date 03 May 2005	AVIATION ACCIDENT Accident à Avion ☐ YES Oui ☑ NO Non

DATE OF DEATH (Hour, day, month, year) Date de décès (l'heure, le jour, le mois, l'année)	PLACE OF DEATH Lieu de décès
(b)(6) 2005	Iraq

I HAVE VIEWED THE REMAINS OF THE DECEASED AND DEATH OCCURRED AT THE TIME INDICATED AND FROM THE CAUSES AS STATED ABOVE.
J'ai examiné les restes mortels du dé funtel je conclus que le décès est survenu à l'heure indiquée et à la suite des causes énumérées ci-dessus.

NAME OF MEDICAL OFFICER	DEGREE Titre ou diplôme
(b)(6)	Medical Examiner

GRADE Grade	INSTALLATION OR ADDRESS Installation ou adresse
(b)(6)	Dover AFB, DE 19902
DATE Date 3 MAY 2005	(b)(6)

[1] State disease, injury or complication which c
[2] State conditions contributing to the death, b
[1] Préciser la nature de la maladie, de la blessure ou de la complication qui a contribué à la mort, mais non la manière de mourir, tels qu'un arrêt de la mort
[2] Préciser la condition qui a contribué à la mort, mais n'ayant aucun rapport avec la maladie ou à la condition qui a provoqué la mort.

DD FORM 1 APR 77 2064 REPLACES DA FORM 3565, 1 JAN 72 AND DA FORM 3565-R(PAS), 26 SEP 75, WHICH ARE OBSOLETE.

MEDCOM 0348

ARMED FORCES INSTITUTE OF PATHOLOGY
Office of the Armed Forces Medical Examiner
1413 Research Blvd., Bldg. 102
Rockville, MD 20850
1-800-944-7912

FINAL AUTOPSY EXAMINATION REPORT

Name: BTB Kadr, Mohammed M.
Detainee Number: (b)(6)
Date of Birth: (b)(6) 1976
Date of Death: (b)(6) 2005
Date of Autopsy: 3 MAY 2005
Date of Report: 24 MAY 2005

Autopsy No.: (b)(6)
AFIP No.: (b)(6)
Rank: Civilian/Detainee
Place of Death: Iraq
Place of Autopsy: Port Mortuary, Dover AFB, DE

Circumstances of Death: This 29-year-old Iraqi male was killed during an altercation at the Camp Bucca, Iraq detainee facility. According to the investigative information available, a fight had broken out between two groups of inmates.

Authorization for Autopsy: Armed Forces Medical Examiner, per 10 U.S. Code 1471

Identification: Presumptive identification is accomplished via accompanying paperwork and the detainee identification number provided. A postmortem dental examination and fingerprinting is performed and a DNA sample is taken during the autopsy, but antemortem specimens are not available for comparison.

CAUSE OF DEATH: Blunt Force Injuries of the Head and Sharp Force Injuries of the Neck

MANNER OF DEATH: Homicide

ACLU Detainee DeathII ARMY MEDCOM 349

FINAL AUTOPSY DIAGNOSES:

I. Blunt Force Injuries

A. Injuries of the Head

1. Deep stellate laceration of the scalp, with underlying comminuted fracture of the calvarium
2. Two linear lacerations of the scalp that extend to the skull
3. Multiple lacerations of the face
4. Comminuted fractures of the basilar skull, with lacerations of the inferior aspect of the brain and subarachnoid hemorrhage
5. Laceration over the left eye, associated with fractures of the left orbit and left zygomatic bone
6. Comminuted fracture of the left maxilla; lacerations of the alveolar tissue above teeth 9 and 10
7. Fracture of the mandible, associated with separation between teeth 24 and 25
8. Laceration/avulsion of the helix and lobe of the left ear

B. Injuries of the Torso

1. Large, horizontal abraded-contusions across the lower chest and upper abdomen
2. Multiple large contusions and abraded-contusions of the right upper chest, back, right flank, and right buttock
3. Multiple small contusions, abrasions, and contused-abrasions of the torso

C. Injuries of the Extremities

1. Multiple abrasions, contusions, and contused-abrasions of the upper extremities, becoming confluent in some locations
2. Multiple abrasions, contusions, and contused-abrasions of the lower extremities, becoming confluent in some locations

II. Sharp Force Injuries

A. Penetrating wound (stab wound) of the upper, lateral, left side of the neck through skin, subcutaneous tissue, and muscle (situated 7 ¼-inches below the top of the head and 6-inches left of the anterior midline; irregular 5/16-inch puncture wound)

B. Penetrating wound (stab wound) of the lower, anterior-lateral, left side of the neck through skin, subcutaneous tissue, and muscle, with transection of the external jugular vein (situated 10-inches below the top of the head and 1 ¾-inches left of the anterior midline; ¼-inch puncture wound)

ACLU Detainee DeathII ARMY MEDCOM 350

C. **Penetrating wound (stab wound) of the chin, though skin, subcutaneous tissue and muscle (situated 9 ½-inches below the top of the head and 1 ½-inches left of the anterior midline; 15/16 x ¾-inch curvilinear avulsion of skin and soft tissue)**

D. **Superficial cutting wound (1-inch in length) of the palm of the right hand**

II. **Atherosclerotic cardiovascular disease, focally moderate**

III. **Prominent steatosis of the liver**

IV. **Toxicology is negative for screened drugs of abuse, ethanol, and cyanide. The carboxyhemoglobin level is 4 percent.**

ACLU Detainee DeathII ARMY MEDCOM 351

EXTERNAL EXAMINATION

The remains are received clad only in blue shorts. A ball cap accompanies the body. The body is that of a well-developed, well-nourished appearing, 66-inches, 170-pounds male, whose appearance is consistent with the reported age of 29 years. Lividity is fixed on the posterior surface of the body, except in areas exposed to pressure. Rigor is present but passing and there are signs of early decomposition changes, including patchy blue-green discoloration of soft tissue and marbling. The body temperature is that of the refrigeration unit.

The scalp is covered by long (averages 7-inches), black hair. The corneae are cloudy. The sclerae are unremarkable, without petechial hemorrhages. The irides are brown and the pupils are round and equal in diameter. The head and face are remarkable for injuries that will be described. The teeth are natural and in fair condition, with injuries that will be described. Facial hair consists of a black mustache and beard stubble.

The neck is mobile and the trachea is midline. The chest is symmetric. The abdomen is scaphoid. The external genitalia are those of a normal adult, circumcised, male. The testes are descended and free of masses. Pubic hair is present in a normal distribution. The buttocks and anus are remarkable only for injuries that will be described.

The upper and lower extremities are symmetric and without clubbing or edema. The fingernails are intact. Identifying body marks include two circular areas of atrophic skin, each averaging 1 ¼-inches in diameter, on the posterior left leg and on the right lower back/flank. (b)(6) tattoo (b)(6)
(b)(6)

MEDICAL INTERVENTION

There is no evidence of medical intervention on the body at the time of the autopsy.

RADIOGRAPHS

Total body postmortem radiographs are obtained and demonstrate the injuries as described and no recoverable metallic foreign objects.

EVIDENCE OF INJURY

I. Multiple Blunt Force Injuries

A. Injuries of the Head and Neck

There is a 1 ¼-inch laceration on the left side of the forehead, above the left eye, that extends to underlying skull. A ½-inch laceration is over the right eye and inferior to the eyebrow. There is marked periorbital ecchymosis. A 1 ¼ x ½-inch abrasion is on the lower left side of the face with a small, irregular laceration of the adjacent upper lip and an additional ¼-inch laceration lateral to the abrasion. The skin above the upper lip is abraded. Three lacerations are on the occiput and top of the head. The largest is a 4 ¼ x 2 ½-inch stellate wound. The other wounds are two linear lacerations, 3-inches and 1 ½-inches in length. A 1 ½-inch jagged laceration has resulted in avulsive loss of part of the helix of the left ear. There is a 1 ¼-inch laceration involving the lower left ear that extends through the earlobe. Fractures of

ACLU Detainee DeathII ARMY MEDCOM 352

the left orbit and left zygomatic bone are noted. Comminuted fractures of the left maxilla are associated with lacerations of alveolar tissue above teeth 9 and 10. There is a displaced fracture of the mandible associated with separation between teeth 24 and 25. Reflection of the scalp reveals a 2 ½ x 2-inch area of subgaleal hemorrhage over the right temporal area and subgaleal hemorrhage covering the entire left temporal-parietal area. There is a ¼-inch laceration of the buccal aspect of the lower lip. Comminuted fractures involve both anterior fossae of the basilar skull, particularly on the left. There are fractures involving the right sphenoid wing and the left petrous ridge along with disruption of the sella area.

B. Injuries of the Torso

There is a 8 x 1 ½-inch pattern contusion on the right upper chest. A ¼-inch abrasion is on the mid upper chest/lower neck. There is a 3 x 1/8-inch abrasion on the left side of the chest. Inferior to that is a large area consisting of multiple punctate, superficial penetrating wounds and small abrasions. Three horizontally oriented, pattern contused-abrasions, each 8 x 1 ¼-inches, are on lower chest and abdomen. A 6 x 3-inch contused-abrasion is on the left upper back. There is a 1 ½ x 1/8-inch abrasion on the posterior right shoulder. A 1 ½ x 1-inch abrasion is on the right upper back. There is a 4 ½ x 4-inch contusion on the mid back, left of the posterior midline. A 7 ½ x 5-inch purple-red contusion is on the right mid back. There is a 6 x 4-inch contusion on the right lower back. A 3 ½ x 2-inch abraded-contusion is on the lower back, left of the posterior midline. Three contusions, up to 3 x ¾-inches in greatest dimensions, are on the right buttock. A 2 x 1-inch contusion is on the lateral left hip.

C. Injuries of the Extremities

There is a 3 ½ x 2-inch area of purple ecchymosis over the anterior right wrist. Multiple linear abraded-contusions, up to 2 ¾ x ½-inches in greatest dimensions, are on the posterior-lateral right arm. A 4 ½ x 2-inch abraded-contusion covers the posterior aspect of the right elbow. Two 1-inch contusions are on the posterior aspect of the right forearm. There is a 2 x 2 ½-inch contusion on the dorsal right hand. Nearly the entire anterior-lateral aspect of the left upper extremity is covered by ecchymosis. A 5 x 3-inch contusion is on the proximal, lateral left arm. Multiple small abrasions, up to ½-inch in greatest dimension, are on the posterior right upper extremity. Two abrasions, 1 ½ x ½-inches and ½ x ¼-inch, are on the posterior aspect of the right forearm.

Two abrasions and one abraded-contusion, up to 3 x 3-inches in greatest dimensions, are on the anterior aspect of the right lower extremity, beginning just above the knee. A 5 x 2-inch area of ecchymosis is on the lateral right thigh. There is a 3 x 2-inch contusion on the medial aspect of the left knee. Scattered small abrasions are on the anterior left leg. There is a 5 x 1 ½-inch contused-abrasion on that covers the left medial malleolus and adjacent areas of the left foot. A 3 x ½-inch abrasion is on the posterior-lateral left knee. There is a 2 x ½-inch abrasion on the proximal, posterior-lateral left leg.

ACLU Detainee DeathII ARMY MEDCOM 353

II. Sharp Force Injuries

A. Stab Wound of the Upper, Lateral Left Side of the Neck

There is an irregular stab wound to the upper, lateral, left side of the neck, situated 7 ¾-inches below the top of the head and 6-inches left of the anterior midline. The 5/16-inch puncture wound goes through skin, subcutaneous tissue, and muscle to a depth of approximately ¾-inch, without a distinct sharp or dull margin. The wound path is directed left to right and slightly front to back.

B. Stab Wound of the Lower, Anterior-Lateral, Left Side of the Neck

There is an irregular stab wound to the lower, anterior-lateral, left side of the neck, situated 10-inches below the top of the head and 1 ¾-inches left of the anterior midline. The ¼-inch puncture wound goes through skin, subcutaneous tissue, and muscle to a depth of approximately 1-inch, with transection of the external jugular vein. There is associated hemorrhage into the adjacent strap muscles of the left side of the neck. No sharp or dull margin can be appreciated. The wound path is directed left to right and slightly front to back.

C. Stab Wound of the Chin,

There is an irregular stab wound to the chin, situated 9 ½-inches below the top of the head and 1 ½-inches left of the anterior midline. The wound is a 15/16 x ¾-inch curvilinear avulsion of skin and subcutaneous tissue only.

D. Cutting Wound of the Right Hand

There is a superficial cutting wound on the palm of the right hand that is 1-inch in length and goes though skin and superficial subcutaneous tissue only

INTERNAL EXAMINATION

HEAD:

The scalp, skull and brain have the previously described injuries. The brain weighs 1340-grams. No non-traumatic abnormalities are noted. The atlanto-occipital joint is stable.

NECK:

The strap muscles of the anterior neck are homogenous and red-brown, with the previously described area of hemorrhage. The thyroid cartilage and hyoid bone are intact. The larynx is lined by intact white mucosa. The thyroid gland is symmetric and red-brown, without cystic or nodular change. The tongue has no contusions or other injuries.

BODY CAVITIES:

The sternum, and vertebral bodies are visibly and palpably intact. The rib injuries have been previously described. There is no excess accumulation of fluid in the left pleural or pericardial cavities. The organs occupy their usual anatomic positions.

ACLU Detainee DeathII ARMY MEDCOM 354

RESPIRATORY SYSTEM:
The right and left lungs weigh 570 and 410-grams, respectively, and are diffusely congested. The external surfaces are deep red-purple, with moderate anthracotic mottling. Sectioning reveals no mass lesions or areas of consolidation present. The pulmonary arteries are unremarkable.

CARDIOVASCULAR SYSTEM:
The 340-gram heart is contained in an intact pericardial sac. The epicardial surface has minimal fat investment. The coronary arteries are present in a normal distribution, with a right-dominant pattern. There is 50% luminal narrowing of the proximal left anterior descending coronary artery and 40% luminal narrowing of the left circumflex coronary artery. The right coronary artery is free of significant atherosclerosis. The thicknesses of the left ventricle, septum, and right ventricle are 1.2, 1.1, and 0.4-centimeters, respectively. Sectioning of the heart reveals normal appearing myocardium, chambers, and heart valves. The aorta gives rise to three intact and patent arch vessels. The renal and mesenteric vessels are unremarkable.

LIVER & BILIARY SYSTEM:
The 2510-gram liver is intact. The parenchyma is yellow-tan, greasy, and congested with the usual lobular architecture. No mass lesions or other non-traumatic abnormalities are noted. The gallbladder contains 2-milliliters of green-black bile and no stones. The mucosal surface is green and velvety. The extrahepatic biliary tree is patent.

SPLEEN:
The 90-gram spleen is uninjured. The parenchyma is maroon, firm, and slightly congested.

PANCREAS:
The pancreas is firm and yellow-tan, with the usual lobular architecture. No mass lesions or other abnormalities are seen.

ADRENAL GLANDS:
The right and left adrenal glands are symmetric, with bright yellow cortices and gray medullae. There are no areas of hemorrhage or masses identified.

GENITOURINARY SYSTEM:
The right and left kidneys weigh 120 and 130-grams, respectively. The external surfaces are intact and smooth. The cut surfaces are red-tan and slightly congested, with uniformly thick cortices and distinct corticomedullary junctions. The pelves are unremarkable and the ureters are normal in course and caliber. White bladder mucosa overlies an intact bladder wall. The urinary bladder contains 80-milliliters of light yellow urine. The prostate gland is normal in size, with lobular, yellow-tan parenchyma. The seminal vesicles are unremarkable. The testes are free of mass lesions, contusions, or other abnormalities.

ACLU Detainee DeathII ARMY MEDCOM 355

GASTROINTESTINAL TRACT:
The esophagus is intact and lined by smooth, gray-white mucosa. The gastric wall is intact. The stomach lumen contains 550-milliliters of partially digested food. The duodenum, loops of small bowel, and colon are unremarkable. The appendix is present.

MUSCULOSKELETAL:
No non-traumatic abnormalities of muscle or bone are identified.

ADDITIONAL PROCEDURES/REMARKS

- Documentary photographs are taken by OAFME staff photographers
- Specimens retained for toxicologic testing and/or DNA identification are: heart blood, spleen, liver, brain, lung, bile, kidney, urine, adipose tissue, gastric contents, and psoas muscle
- Full body radiographs are obtained and demonstrate the injuries as described
- Selected portions of organs are retained in formalin, without preparation of histologic slides
- The dissected organs are forwarded with the body
- Personal effects are released to the mortuary affairs representative

OPINION

This Iraqi male detainee died as a result of blunt force injuries of the head and sharp force injuries of the neck sustained in a fight with other detainees at Camp Bucca. In addition to the lethal injuries, he sustained multiple blunt force injuries of the torso and extremities. Toxicology was negative for screened drugs of abuse, ethanol, and cyanide. Carboxyhemoglobin levels were not elevated. The manner of death is homicide.

(b)(6)

(b)(6) **Medical Examiner** (b)(6)

ACLU Detainee DeathII ARMY MEDCOM 356

DEPARTMENT OF DEFENSE
ARMED FORCES INSTITUTE OF PATHOLOGY
WASHINGTON, DC 20306-6000

REPLY TO ATTENTION OF

AFIP-(b)(6)

TO:

OFFICE OF THE ARMED FORCES MEDICAL EXAMINER
ARMED FORCES INSTITUTE OF PATHOLOGY
WASHINGTON, DC 20306-6000

PATIENT IDENTIFICATION
AFIP Accessions Number **Sequence**
(b)(6)
Name
KADR, MOHAMMED (b)(6)

SSAN: **Autopsy:** (b)(6)
Toxicology Accession #: (b)(6)
Date Report Generated: May 12, 2005

CONSULTATION REPORT ON CONTRIBUTOR MATERIAL

AFIP DIAGNOSIS **REPORT OF TOXICOLOGICAL EXAMINATION**

Condition of Specimens: GOOD
Date of Incident (b)(6) 2005 **Date Received:** 5/10/2005

CARBON MONOXIDE: The carboxyhemoglobin saturation in the blood was 4% as determined by spectrophotometry with a limit of quantitation of 1%. Carboxyhemoglobin saturations of 0-3% are expected for non-smokers and 3-10% for smokers. Saturations above 10% are considered elevated and are confirmed by gas chromatography.

CYANIDE: There was no cyanide detected in the blood. The limit of quantitation for cyanide is 0.25 mg/L. Normal blood cyanide concentrations are less than 0.15 mg/L. Lethal concentrations of cyanide are greater than 3 mg/L.

VOLATILES: The **BLOOD AND URINE** were examined for the presence of ethanol at a cutoff of 20 mg/dL. No ethanol was detected.

DRUGS: The **URINE** was screened for amphetamine, antidepressants, antihistamines, barbiturates, benzodiazepines, cannabinoids, chloroquine, cocaine, dextromethorphan, lidocaine, narcotic analgesics, opiates, phencyclidine, phenothiazines, sympathomimetic amines and verapamil by gas chromatography, color test or immunoassay. The following drugs were detected:

None were found.

(b)(6)
Office of the Armed Forces Medical Examiner

(b)(6)
Office of the Armed Forces Medical Examiner

ACLU Detainee DeathII ARMY MEDCOM 357

CERTIFICATE OF DEATH (OVERSEAS)
Acte de décès (D'Outre-Mer)

NAME OF DECEASED (Last, First, Middle) Nom du décédé (Nom et prénoms)	GRADE Grade	BRANCH OF SERVICE Armée	SOCIAL SECURITY NUMBER Numéro de l'Assurance Sociale
BTB Kadr, Mohammed		Civilian	(b)(6)

ORGANIZATION Organisation	NATION (e.g., United States) Pays	DATE OF BIRTH Date de naissance	SEX Sexe
Iraqi Detainee	Iraq	(b)(6) 1976	☑ MALE Masculin ☐ FEMALE Féminin

RACE Race	MARITAL STATUS État Civil	RELIGION Culte
☒ CAUCASOID Caucasique	SINGLE Célibataire	DIVORCED Divorcé
NEGROID Negroïde	MARRIED Marié	PROTESTANT Protestant
OTHER (Specify) Autre (Spécifier)	WIDOWED Veuf	CATHOLIC Catholique
	SEPARATED Séparé	JEWISH Juif
		OTHER (Specify) Autre (Spécifier)

NAME OF NEXT OF KIN Nom du plus proche parent	RELATIONSHIP TO DECEASED Parenté du décédé avec le susdit
STREET ADDRESS Domicile à (Rue)	CITY OR TOWN AND STATE (Include ZIP Code) Ville (Code postal compris)

MEDICAL STATEMENT Déclaration médicale

CAUSE OF DEATH (Enter only one cause per line) Cause du décès (N'indiquer qu'une cause par ligne)			INTERVAL BETWEEN ONSET AND DEATH Intervalle entre l'attaque et le décès
DISEASE OR CONDITION DIRECTLY LEADING TO DEATH[1] Maladie ou condition directement responsable de la mort[1]		Blunt force injuries of the head & sharp force injuries of the neck	Seconds
ANTECEDENT CAUSES Symptômes précurseurs de la mort	MORBID CONDITION, IF ANY, LEADING TO PRIMARY CAUSE Condition morbide, s'il y a lieu, menant à la cause primaire		
	UNDERLYING CAUSE, IF ANY, GIVING RISE TO PRIMARY CAUSE Raison fondamentale, s'il y a lieu, ayant suscité la cause primaire		
OTHER SIGNIFICANT CONDITIONS[2] Autres conditions significatives[2]			

MODE OF DEATH Condition de décès	AUTOPSY PERFORMED Autopsie effectuée	CIRCUMSTANCES SURROUNDING DEATH DUE TO EXTERNAL CAUSES Circonstances de la mort survenues par cause extérieure
☐ NATURAL Mort naturelle	☑ YES Oui ☐ NO Non	
☐ ACCIDENT Mort accidentelle	MAJOR FINDINGS OF AUTOPSY Constatations principales de l'autopsie	
☐ SUICIDE Suicide	NAME OF PATHOLOGIST Nom du pathologiste (b)(6)	
☒ HOMICIDE Homicide	(b)(6)	DATE Date 03 May 2005

AVIATION ACCIDENT Accident d'Aviation ☐ YES Oui ☑ NO Non

DATE OF DEATH (Hour, day, month, year) Date du décès (heure, le jour, le mois, l'année)	PLACE OF DEATH Lieu de décès
(b)(6) 2005	Iraq

I HAVE VIEWED THE REMAINS OF THE DECEASED AND DEATH OCCURRED AT THE TIME INDICATED AND FROM THE CAUSES AS STATED ABOVE
J'ai examiné les restes mortels du défunt et constaté que le décès est survenu à l'heure indiquée et, à la suite des causes énumérées ci-dessus.

NAME OF MEDICAL OFFICER Nom du médecin militaire ou du médecin assermenté	TITLE OR DEGREE Titre ou diplôme
(b)(6)	Medical Examiner

GRADE Grade	INSTALLATION OR ADDRESS Installation ou adresse
(b)(6)	Dover AFB DE 19902
DATE Date 3 MAY 2005	(b)(6)

[1] State disease, injury or complication which directly caused death. Enter only one cause per line.
[2] State conditions contributing to the death, but not related to the disease or condition causing it.
[1] Préciser la cause de la maladie, de la blessure ou de la complication qui a directement causé la mort. N'indiquer qu'une cause par ligne.
[2] Préciser les conditions qui ont contribué à la mort, mais qui ne sont pas liées à la maladie ou à l'état morbide qui a causé la mort, etc.

DD FORM 1 APR 77 2064 REPLACES DA FORM 3565, 1 JAN 72 AND DA FORM 3565-R(PAS), 26 SEP 75, WHICH ARE OBSOLETE.

(REMOVE, REVERSE AND RE-INSERT CARBONS BEFORE COMPLETING THIS SIDE)

DISPOSITION OF REMAINS			
NAME OF MORTICIAN PREPARING REMAINS	GRADE	LICENSE NUMBER AND STATE	OTHER
INSTALLATION OR ADDRESS	DATE 5/3/2005	SIGNATURE	
NAME OF CEMETERY OR CREMATORY	LOCATION OF CEMETERY OR CREMATORY		
TYPE OF DISPOSITION		DATE OF DISPOSITION	

REGISTRATION OF VITAL STATISTICS			
REGISTRY *(Town and County)*	DATE REGISTERED	FILE NUMBER	
		STATE	OTHER
NAME OF FUNERAL DIRECTOR	ADDRESS		
SIGNATURE OF AUTHORIZED INDIVIDUAL			

DD FORM 2064, APR 1977 (BACK) USAPA V1.00

ACLU Detainee DeathII ARMY MEDCOM 359

ARMED FORCES INSTITUTE OF PATHOLOGY
Office of the Armed Forces Medical Examiner
1413 Research Blvd., Bldg. 102
Rockville, MD 20850
1-800-774-8427

AUTOPSY EXAMINATION REPORT

Name: BTB Ahmed, Raad Hikmet
Capture Tag No. (b)(6)
Date of Birth: Unknown
Date of Death (b)(6) 2005
Date of Autopsy: 26 MAR 2005
Date of Report: 24 OCT 2005

Autopsy No.: (b)(6)
AFIP No.: (b)(6)
Rank: Detainee
Place of Death: Camp Charlie, Iraq
Place of Autopsy: Port Mortuary
Dover AFB, DE

Circumstances of Death: This male Iraqi civilian was reportedly detained by Iraqi Police after coming to the police to report he and another detainee had been kidnapped and beaten up by a rival clan. The surviving detainee stated the Iraqi police physically assaulted the pair. The decedent and his associate were taken by US forces to Camp Charlie, which is controlled by Polish forces. The decedent was under Polish medical care receiving treatment for his injuries when he was pronounced deceased on (b)(6) 2005. The treatment for the injuries reportedly included intravenous fluids and antibiotics. The circumstances immediately preceding the decedent's death are still uncertain but may have included the removal of the intravenous catheters by the decedent. Polish authorities are not providing any additional information to US investigators.

Authorization for Autopsy: Office of the Armed Forces Medical Examiner, IAW 10 USC 1471.

Identification: Identification is presumptive based on capture tag number.

CAUSE OF DEATH: Undetermined

MANNER OF DEATH: Undetermined

FINAL AUTOPSY DIAGNOSES:

I. Blunt Force Injuries

A. Injuries of the Head
1. A 1.3 x 0.4 cm laceration on the vertex of the scalp.
2. A 6.0 x 2.3 cm subgaleal ecchymosis of the midline of the superior posterior parietal scalp
3. Patchy ecchymoses of the frontal scalp
4. Bilateral ecchymoses of the anterior strap muscles of the neck to the depth of the thyroid gland
5. Superficial ecchymosis of the thymus

B. Injuries of the Torso
1. A 4.5 x 3.5 cm ecchymosis over the anterior surface of the right acromion
2. Contusions of the left fifth and sixth intercostal spaces
3. A 8.0 x 7.0 cm contusion of the left lower quadrant of the abdomen that overlies a 10.0 x 8.0 cm contusion of the oblique muscles of the left lower quadrant of the abdomen
4. A 11.5 x 7.0 cm contusion of the right lower quadrant of the abdomen within an area of skin slippage
5. A 7.0 x 6.0 cm superficial contusion of the anterior surface of the upper lobe of the left lung
6. A 5.0 x 4.0 cm contusion of the lateral surface of the lower lobe of the right lung with yellow central portion.
7. Bilateral hemothorax (right 600 ml and left 50 ml)
8. An approximately 9.0 x 6.0 cm contusion of the right scapular area at the posterior surface of the ribs and a 7.0 x 6.0 cm area of contusion on the left scapular area at the posterior surface of the ribs
9. A 2.1 x 1.0 cm crusted area on the left flank

C. Injuries of the Extremities
1. A 5.0 x 2.5 cm area of abrasions on the lateral surface of the left forearm
2. A 3.8 x 0.4 cm crusted abrasion on the left knee

II. Other Injuries
1. A 23.7 x 19.8 cm area of discolored denuded skin with erythematous base and crust formation on the right scapula, consistent with healing burns of varying severity
2. A 22.1 x 9.6 cm area of discolored denuded skin with erythematous base and crust formation on the left scapula, consistent with healing burns of varying severity
3. A 15.1 x 1.5 cm linear area of denuded skin on the left scapula

ACLU Detainee DeathII ARMY MEDCOM 361

immediately inferior and lateral the above area, consistent with a patterned burn
4. A 15 x 5 cm area of scattered crusted abrasions on the central mid back
5. Crusted abrasions on the medial and lateral surfaces of the left wrist
6. Crusted abrasions of the medial, lateral and posterior surfaces of the right wrist
7. Superficial patterned abrasion of the medial right ankle
8. Two- 0.2 x 0.2 cm round abrasions with erythematous base that are 1.9 cm apart on the right palm, possible patterned injury
9. Ecchymoses of the posterior surface of the right upper arm, the right lower leg, the left lower leg and the right ankle are areas of purple discoloration that range in size from 2.5 x 1.5 cm to 7.0 x 3.0 cm.

III. Medical Intervention (possible resuscitation artifacts)
1. A 23.4 x 17.1 cm area of red/purple discolorations with multiple superimposed rectangular abrasions on the left chest.
2. A 9.5 x 8.5 cm rectangular abrasion on the right chest
3. Separation of the right 3rd-5th ribs from the costal cartilage, no associated ecchymoses
4. Separation of the left 3rd and 4th ribs from the costal cartilage, no associated ecchymoses
5. Fracture of the anterior aspect of the right and left second ribs, immediately lateral to the insertion into the costal cartilage
6. Punture marks in the antecubital fossae (two in right, one in left)

IV. Identifying marks
1. (b)(6) tattoo (b)(6)
2. tattoo
3. tattoo
(b)(6)
4. (b)(6) tattoos (b)(6)
(b)(6)
5. (b)(6) tattoos (b)(6)
(b)(6)
6. A horizontal scar on the right knee

V. No significant natural diseases identified, within limitations of the examination

VI. Mild decomposition

ACLU Detainee DeathII ARMY MEDCOM 362

VII. Cardiovascular pathology consultation
"Diagnosis: (b)(6) : Heart: Focal subendocardial contraction band necrosis and myocyte necrosis with associated mixed chronic inflammatory infiltrate consisting of macrophages and lymphocytes"

VIII. Neuropathology consultation
"Diagnosis: (b)(6) Brain, postmortem: Patchy acute neuronal injury. Autolysis with focal bacterial overgrowth"

IX. Toxicology is negative for ethanol and screened drugs of abuse.

X. Vitreous electrolytes are consistent with decomposition.

EXTERNAL EXAMINATION

The body is that of a well-developed well-nourished appearing 70 ½ inch long, 208 pound Iraqi male civilian. His age appears to be 30-40 years. Lividity is fixed posteriorly with pressure bearing area pallor. Rigor is waning and easily broken in the extremities. The is mild decomposition changes of the remains that include discoloration of the skin of the face, chest and back, marbling of the arms and areas of skin slippage on the neck, right shoulder, right abdominal wall and left thigh.

The scalp is covered with dark brown to black hair in a normal distribution. The irides are brown and the pupils are round and equal in diameter. The conjunctivae are congested but free of any petechiae. The external auditory canals are free of abnormal secretions. The ears are unremarkable. The nares are patent and the lips are atraumatic. The nose and maxillae are palpably stable. The frenula of the lips are intact. The teeth appear natural and in fair repair. The facial hair consists of a black beard and mustache.

An approximately 24 x 17 cm area of skin slippage and vesicle formation is on the right side of the neck and a 16 x 8 cm area of skin slippage and vesicle formation is on the left and anterior surface of the neck. A 21 x 16 cm area of skin slippage and vesicle formation is on the upper right chest. Each of these areas are consistent with decomposition.

The neck is straight, and the trachea is midline and mobile. The chest is symmetric. The abdomen is flat. The genitalia are those of a normal circumcised adult male. The testes are descended and free of masses. Pubic hair is present in a normal distribution. The right buttock has a 14 x 6 cm area of small-cratered scars and the left buttock has a 10 x 10 cm area of small-cratered scars. A pilonidal cyst is at the proximal tip of the natal cleft. The anus is unremarkable.

The upper and lower extremities are symmetric and without clubbing or edema.

Identifying marks include (b)(6) tattoo (b)(6)
(b)(6) tattoo (b)(6)

ACLU Detainee DeathII ARMY MEDCOM 363

(b)(6)

(b)(6) tattoos (b)(6) tattoo (b)(6)

(b)(6) A horizontal scar is on the right knee.

CLOTHING AND PERSONAL EFFECTS

The body is received with a pair of navy blue shorts with the label "G-AMMA" on the right front pocket. The right buttock of the shorts is mud covered.

MEDICAL INTERVENTION

1. A 23.4 x 17.1 cm area of red/purple discolorations with multiple superimposed rectangular abrasions on the left chest.
2. A 9.5 x 8.5 cm rectangular abrasion on the right chest
3. Separation of the right 3rd through 5th ribs from the costal cartilage, no associated ecchymoses
4. Separation of the left 3rd and 4th ribs from the costal cartilage, no associated ecchymoses
5. Fracture of the anterior aspect of the right and left second ribs, immediately lateral to the insertion into the costal cartilage
6. Punture marks in the antecubital fossae (two in right, one in left)

The above described injuries are consistent with attempted cardiopulmonary resuscitation including electrical defibrillation.

RADIOGRAPHS

A complete set of postmortem radiographs is obtained and demonstrates neither long bone fractures nor any foreign bodies.

EVIDENCE OF INJURY

The ordering of the following injuries is for descriptive purposes only, and is not intended to imply order of infliction or relative severity. All wound pathways are given relative to standard anatomic position.

Injuries of the Head:

On the vertex (top) of the head is a 1.3 x 0.4 cm laceration. A 6.0 x 2.3 cm subgaleal ecchymosis is in the midline of the superior posterior parietal scalp and there are scattered ecchymoses of the frontal scalp.

Anterior neck dissection reveals bilateral ecchymoses of the anterior strap muscles that penetrate down to the level of the thyroid gland. There are superficial ecchymoses of the thymus gland. Posterior neck dissection reveals congestion of the muscles consistent with livor mortis and no ecchymoses.

Injuries of the Torso:

On the left abdominal wall is an 8 x 7 cm red-green contusion that overlies a 10 x 8 cm contusion of the oblique muscles of the left lower quadrant of the abdomen. In the right lower quadrant of the abdomen is an 11.5 x 7.0 cm contusion that is within a 23 x 17 cm

ACLU Detainee DeathII ARMY MEDCOM 364

area of skin slippage. On the medial aspect of this contusion and outside the skin slippage is a 12 x 7 cm geometric shaped blue-black area.

A 23.7 x 19.8 cm area of discolored denuded skin with erythematous base and crust formation is on the right scapular area and a 22.1 x 9.6 cm area of discolored denuded skin with erythematous base and crust formation is on the left scapular area. Within the left scapular area is a 3.8 x 1.5 cm crusted patterned injury (rectangle). Immediately inferior and lateral to the area on the left scapula is a 15.1 x 1.5 cm linear area of denuded skin. These injuries are consistent with burns of varying severity in various stages of healing.

A 15 x 5 cm area of crusted abrasions is on the central back and a 2.1 x 1.0 cm crusted area of abrasion is on the left flank.

Internal examination reveals a 4.5 x 3.5 cm ecchymosis over the anterior surface of the right acromion and contusions of the left fifth and sixth ribs. A 7.0 x 6.0 cm superficial contusion is on the upper lobe of the left lung and a resolving 5.0 x 4.0 cm contusion is on the lateral surface of the lower lobe of the right lung. There is a 600 ml hemothorax on the right side and 50 ml on the left. Lateral to the large skin burns of the scapular areas are a 9.0 x 6.0 cm contusion of the right side that extends to the posterior surfaces of the ribs and a 7.0 x 6.0 cm contusion on the left side that also extends to posterior surfaces of the ribs.

Injuries of the Extremities
A 5.0 x 2.5 cm area of brush abrasions is on the lateral surface of the left forearm. Multiple crusted linear abrasions are on the medial and lateral surfaces of the left wrist and the medial, lateral and posterior surfaces of the right wrist. On the right palm are two 0.2 x 0.2 cm round abrasions that have erythematous bases and are 1.9 cm apart, representing a possible patterned injury. A 3.8 x 0.4 cm crusted abrasion is on the left knee and there is a superficial patterned abrasion on the medial right ankle.

INTERNAL EXAMINATION

HEAD:
The galeal and subgaleal soft tissues of the scalp are free of injury. The calvarium is intact, as is the dura mater beneath it. Clear cerebrospinal fluid surrounds the 1550 gm brain, which has unremarkable gyri and sulci. The brain is submitted for Neuropathology consultation (see report below). There are no skull fractures. The atlanto-occipital joint is stable.

NECK:
The anterior strap muscles of the neck are homogenous and red-brown. The posterior neck muscles are congested and there are no cervical spine fractures. The thyroid cartilage and hyoid bone are intact. The larynx is lined by intact white mucosa. The thyroid gland is symmetric and red-brown, without cystic or nodular change. The tongue is free of bite marks, hemorrhage, or other injuries.

ACLU Detainee DeathII ARMY MEDCOM 365

BODY CAVITIES:
Except where noted above, the ribs, sternum, and vertebral bodies are visibly and palpably intact. No excess fluid is in the pericardial or peritoneal cavities. The organs occupy their usual anatomic positions.

RESPIRATORY SYSTEM:
The right and left lungs weigh 720 and 690 gm, respectively. Except where noted above, the external surfaces are smooth and deep red-purple. The pulmonary parenchyma is congested and edematous. No mass lesions or areas of consolidation are present.

CARDIOVASCULAR SYSTEM:
The 420 gm heart is contained in an intact pericardial sac. The epicardial surface is smooth, with minimal fat investment. The coronary arteries are present in a normal distribution, with a right-dominant pattern. Cross sections of the vessels show no atherosclerosis. The myocardium is homogenous, red-brown, and firm. The heart is submitted for Cardiovascular Pathology consultation (see report below).

The aorta gives rise to three intact and patent arch vessels. The renal and mesenteric vessels are unremarkable.

LIVER & BILIARY SYSTEM:
The 2160 gm liver has an intact, smooth capsule and a sharp anterior border. The parenchyma is soft, tan-brown and congested, with the usual lobular architecture. No mass lesions or other abnormalities are seen. The gallbladder contains a minute amount of green-black bile and no stones. The gallbladder mucosal surface is green and velvety. The extrahepatic biliary tree is patent.

SPLEEN:
The 350 gm spleen has a smooth, intact, red-purple capsule. The parenchyma is maroon and congested, with distinct Malpighian corpuscles.

PANCREAS:
The pancreas is soft and yellow-tan, with the usual lobular architecture. No mass lesions or other abnormalities are seen.

ADRENALS:
The right and left adrenal glands are autolyzed. No masses or areas of hemorrhage are identified.

GENITOURINARY SYSTEM:
The right and left kidneys weigh 250 and 280 gm, respectively. The external surfaces are intact and smooth. The cut surfaces are red-tan and edematous, with uniformly thick cortices and sharp corticomedullary junctions. The pelves are unremarkable and the ureters are normal in course and caliber. White bladder mucosa overlies an intact bladder wall. The bladder contains scant urine. The prostate is normal in size, with lobular,

ACLU Detainee DeathII ARMY MEDCOM 366

yellow-tan parenchyma. The seminal vesicles are unremarkable. The testes are free of mass lesions, contusions, or other abnormalities.

GASTROINTESTINAL TRACT:
The esophagus is intact and lined by smooth, grey-white mucosa. The stomach contains approximately 30 ml of brown liquid. The gastric wall is intact. The duodenum, loops of small bowel, and colon are unremarkable. The appendix is present.

ADDITIONAL PROCEDURES

- Documentary photographs are taken by an OAFME photographer.
- Trace evidence and foreign material is not collected
- Specimens retained for toxicologic testing and/or DNA identification are: vitreous, blood (cardiac), kidney, spleen, lung, liver, bile, gastric contents, adipose tissue and psoas muscle
- The dissected organs are forwarded with body
- Personal effects are released to the appropriate mortuary operations representatives

Cardiovascular Pathology Consultation (Department of Cardiovascular Pathology, AFIP, Washington DC):

"DIAGNOSIS: (b)(6) **Heart: Focal subendocardial contraction band necrosis and myocyte necrosis with associated mixed chronic inflammatory infiltrate consisting of macrophages and lymphocytes.**

Clinical History: This male Iraqi civilian, age estimated at 25-40 years, was taken into US custody at Camp Charlie, Iraq on 3/19/05; he was pronounced deceased on (b)(6) 05; the circumstances of his death are under investigation.

Heart: 397 grams; normal epicardial fat; closed foramen ovale; left ventricular cavity diameter 2.8 cm, left ventricular free wall thickness 1.6 cm; ventricular septum thickness 1.5 cm; right ventricle thickness 0.4 cm, without gross scars or abnormal fat infiltrates; grossly unremarkable valves and endocardium; no gross myocardial fibrosis or necrosis; histologic sections show focal contraction band necrosis and myocyte necrosis with associated macrophage and lymphocytic infiltrates, predominantly in the subendocardium and interstitium.

Coronary arteries; normal ostia; right dominance; no gross coronary atherosclerosis

Comment: The cause and circumstances of the patient's initial collapse are unclear. The submitted clinical history indicates that the decedent may have received antemortem application of electrical current. We cannot rule out the possibility that electrical injury may have led to a ventricular arrhythmia if the clinical history is substantiated. There is no coronary disease to suggest an ischemic event. The subendocardial contraction band necrosis and mixed chronic inflammatory cell infiltrates are suggestive of catecholamine-induced injury that may be seen in the setting of resuscitation".

ACLU Detainee DeathII ARMY MEDCOM 367

Signed by (b)(6) Cardiovascular Pathologist on May 4, 2005 (original signature on file)

Neuropathology Consultation (Department of Neuropathology and Ophthalmic Pathology, AFIP, Washington DC):

(b)(6) Brain, postmortem: Patchy acute neuronal injury. Autolysis with focal bacterial overgrowth.

We examined the 1535-gram formalin fixed brain submitted in reference to this case. A small piece of the falx cerebri is included with the brain. This dura is without hematoma, thrombus or neoplasm. There is some opacification of the basal leptomeninges. No leptomeningeal hemorrhage is noted. The gyral pattern is normal; the gyri are swollen and compressed. No hemorrhage or contusion is identified. The cranial nerve stumps identified are unremarkable. The circle of Willis shows a normal configuration, with no aneurysm or malformation seen. No uncal, tonsillar, or subfalcine herniation is identified. The cerebellum, brainstem and uppermost cervical spinal cord are moderately swollen but normal in shape. Coronal sections of the cerebrum show no abnormalities of the cortex, white matter or deep gray matter nuclei. No focal lesions and no hemorrhages are identified. The ventricles are compressed and without hemorrhage. The substantia nigra and locus coeruleus are normally pigmented for patient age. Cut surfaces of the cerebellum, midbrain, pons, medulla and uppermost cervical spinal cord show no focal lesions and no hemorrhage. The aqueduct and IVth ventricle are patent and without hemorrhage. Gross photographs are taken (CD enclosed).

Summary of tissue sections: 1. Right superior/middle frontal gyrus. 2. Right inferior parietal lobe. 3. Right superior/middle temporal gyrus. 4. Right cingulate gyrus. 5. Right hippocampus. 6. Right caudate/putamen. 7. Left putamen/pallidum. 8. Right thalamus/hypothalamus at the mamillary bodies. 9. Substantia nigra/midbrain. 10. Pons. 11. Medulla. 12. Right cerebellum/dentate. 13. Uppermost cervical spinal cord. Tissue was processed in paraffin for histology; slides were stained with H&E. The material was reviewed in conference by staff of the Dept. of Neuropathology and Ophthalmic Pathology.

Scattered neurons throughout the cerebrum show pale eosinophilic discoloration consistent with acute neuronal injury. There are autolytic changes with scattered foci of bacterial overgrowth, associated mostly with small blood vessels. Features diagnostic for infection or neoplasm are not observed. No pathological hemorrhage is identified".

Signed by (b)(6) Staff Pathologist, Dept. of Neuropathology and Ophthalmic Pathology on April 22, 2005 (orginal signature on file).

MICROSCOPIC EXAMINATION

Skin of Back- Consistent with burns, first through third degree.

Abrupt transition from normal skin to an area with absence of the epidermis, subepidermal splitting, extensive coagulative necrosis of the papillary and reticular

ACLU Detainee DeathII ARMY MEDCOM 368

dermis, extensive nuclear debris and scattered inflammatory response, focal subepidermal abcesses destruction of some of the dermal appendages associated with mild vacuolization of the appendage glands. Bacterial colonization without inflammatory response.

Lung- Consistent with resolving contusion

An area of necrotic lung parenchyma with the presence of hemosiderin laden macrophages outlined by border of dilated blood-filled vessels with occasional microthrombi. Bacterial colonization without inflammatory response.

Selected portions of other organs are retained in formalin, without preparation of histologic slides.

OPINION

This Iraqi civilian male died while being treated for blunt force trauma injuries and burns of the back while detained in Polish custody. The events immediately preceding the death of the decedent are not provided and a specific mechanism of death was not determined from autopsy examination.

The current available information suggests the decedent was physically injured by a rival clan of Iraqis (decedent's account) or by Iraqi Police (decedent's associate's account). Autopsy examination indicates the presence of contusions (bruises), abrasions and internal injuries, as well as burns of the back that are of varying severity. The features of the injuries are consistent with the injuries occurring prior to the decedent's death.

Specific injuries further indicate the possible manner in which the decedent obtained these injuries. The ecchymoses of the neck muscles is suggestive of the decedent being restrained by the neck. Abrasions of the wrist and ankles are consistent with the decedent's hands and feet being previously restrained with unspecified instruments.

The minimal information available regarding the decedent's medical treatment in Polish custody suggests the decedent was in stable condition and receiving intravenous fluids and antibiotics. The decedent's death was sudden and apparently unexpected because there is evidence the Polish medical team tried vigorously to resuscitate the decedent. Expert consultation examinations of the heart and brain reveal no contributing factors to the death and only changes that can be attributed to resuscitation efforts.

It is possible the decedent died of complications of his injuries and thus homicide would be the manner of death, but without a complete history of the events immediately preceding his death, the apparent "stable" condition of the decedent prior to death and no specific mechanism determined by autopsy examination, an intervening mechanism of death cannot be ruled out. Therefore, the cause and manner of death is assigned as Undetermined.

ACLU Detainee DeathII ARMY MEDCOM 369

CERTIFICATE OF DEATH *(OVERSEAS)*
Acte de décès *(D'Outre-Mer)*

NAME OF DECEASED *(Last, First, Middle) Nom du décédé (Nom et prénoms)*	GRADE Grade	BRANCH OF SERVICE Arme	SOCIAL SECURITY NUMBER Numéro de l'Assurance Sociale
BTB Ahmed, Raad Hikmet		Iraqi Detainee	(b)(6)

ORGANIZATION Organisation	NATION *(e.g., United States)* Pays	DATE OF BIRTH Date de naissance	SEX Sexe
Detainee in Iraq (Camp Charlie)	Iraq		☑ MALE Masculin ☐ FEMALE Féminin

RACE Race	MARITAL STATUS État Civil	RELIGION Culte
☒ CAUCASOID Caucasique	☐ SINGLE Célibataire	☐ PROTESTANT Protestant
☐ NEGROID Negroide	☐ MARRIED Marié	☐ CATHOLIC Catholique
☐ OTHER (Specify) Autre (Spécifier)	☐ WIDOWED Veuf	☐ JEWISH Juif
	☐ DIVORCED Divorcé	☐ OTHER (Specify) Autre (Spécifier)
	☐ SEPARATED Séparé	

NAME OF NEXT OF KIN Nom du plus proche parent	RELATIONSHIP TO DECEASED Parenté du décédé avec le susdit
STREET ADDRESS Domicile à (Rue)	CITY OR TOWN AND STATE *(Include ZIP Code)* Ville (Code postal compris)

MEDICAL STATEMENT Déclaration médicale

CAUSE OF DEATH *(Enter only once cause per line)* Cause du décès (N'indiquer qu'une cause par ligne)			INTERVAL BETWEEN ONSET AND DEATH Intervalle entre l'attaque et le décès
DISEASE OR CONDITION DIRECTLY LEADING TO DEATH[1] Maladie ou condition directement responsable de la mort[1]		Pending investigation	
ANTECEDENT CAUSES Symptômes précurseurs de la mort	MORBID CONDITION, IF ANY, LEADING TO PRIMARY CAUSE Condition morbide, s'il y a lieu, menant à la cause primaire		
	UNDERLYING CAUSE, IF ANY, GIVING RISE TO PRIMARY CAUSE Raison fondamentale, s'il y a lieu, ayant suscité la cause primaire		
OTHER SIGNIFICANT CONDITIONS[2] Autres conditions significatives[2]			

MODE OF DEATH Condition du décès	AUTOPSY PERFORMED Autopsie effectuée ☑ YES Oui ☐ NO Non MAJOR FINDINGS OF AUTOPSY Conclusions principales de l'autopsie	CIRCUMSTANCES SURROUNDING DEATH DUE TO EXTERNAL CAUSES Circonstances de la mort suscitées par des causes extérieures
☐ NATURAL Mort naturelle		Mode of Death: Pending
☐ ACCIDENT Mort accidentelle		
☐ SUICIDE Suicide	NAME OF PATHOLOGIST Nom du pathologiste (b)(6)	
☐ HOMICIDE Homicide	(b)(6) DATE Date 26 Mar 2005	AVIATION ACCIDENT Accident d'Avion ☐ YES Oui ☑ NO Non

DATE OF DEATH *(Hour, day, month, year)* Date du décès *(l'heure, le jour, le mois, l'année)*	PLACE OF DEATH Lieu de décès
(b)(6) 2005	Camp Charlie, Iraq

I HAVE VIEWED THE REMAINS OF THE DECEASED AND DEATH OCCURRED AT THE TIME INDICATED AND FROM THE CAUSES AS STATED ABOVE
J'ai examiné les restes mortels du défunt je conclus que le décès est survenu à l'heure indiquée et à, la suite des causes énumérées ci-dessus.

NAME OF MEDICAL OFFICER Nom du médicin militaire ou du médicin sanitaire	TITLE OR DEGREE Titre ou diplômé
(b)(6)	Medical Examiner

GRADE Grade	INSTALLATION OR ADDRESS Installation ou adresse
(b)(6)	Dover AFB, DE 19902

DATE Date	
29 MAR 05	(b)(6)

[1] State disease, injury or complication which caused death, but not mode of dying such as heart failure, etc.
[2] State conditions contributing to the death, but not related to the disease or condition causing death.
[1] Préciser la nature de la maladie, de la blessure ou de la complication qui a contribué à la mort, mais non la manière de mourir, telle qu'un arrêt du coeur, etc
[2] Préciser la condition qui a contribué à la mort, mais n'ayant aucun rapport avec la maladie ou à la condition qui a provoqué la mort.

DD FORM 1 APR 77 2064 REPLACES DA FORM 3565, 1 JAN 72 AND DA AFORM 3565-R(PA5), 26 SEP 75, WHICH ARE OBSOLETE.

ACLU Detainee Deathll ARMY MEDCOM 370

(REMOVE, REVERSE AND RE-INSERT CARBONS BEFORE COMPLETING THIS SIDE)

DISPOSITION OF REMAINS			
NAME OF MORTICIAN PREPARING REMAINS	GRADE	LICENSE NUMBER AND STATE	OTHER
INSTALLATION OR ADDRESS	DATE	SIGNATURE	
NAME OF CEMETERY OR CREMATORY	LOCATION OF CEMETERY OR CREMATORY		
TYPE OF DISPOSITION		DATE OF DISPOSITION	

REGISTRATION OF VITAL STATISTICS			
REGISTRY *(Town and County)*	DATE REGISTERED	FILE NUMBER	
		STATE	OTHER
NAME OF FUNERAL DIRECTOR	ADDRESS		
SIGNATURE OF AUTHORIZED INDIVIDUAL			

DD FORM 2064, APR 1977 (BACK) USAPA V1.00

ACLU Detainee DeathII ARMY MEDCOM 371

ARMED FORCES INSTITUTE OF PATHOLOGY
Office of the Armed Forces Medical Examiner
1413 Research Blvd., Bldg. 102
Rockville, MD 20850
1-800-944-7912

FINAL AUTOPSY EXAMINATION REPORT

Name: BTR Al Khalaf, Majamey
ISN (b)(6)
Date of Birth: Unknown
Date of Death: (b)(6) 2005
Date of Autopsy: 15 MAR 2005
Date of Report: 09 JUN 2005

Autopsy No.: (b)(6)
AFIP No.: (b)(6)
Rank: Civilian
Place of Death: 82nd CSH, Tallil, Iraq
Place of Autopsy: Port Mortuary
Dover AFB, DE

Circumstances of Death: This Iraqi National male detainee of the US Forces suffered a myocardial infarction on 27 January 2005 while being held at Camp Bucca, Iraq. The decedent reported having chest pain and when evaluated at the clinic at Camp Bucca was found to have EKG changes consistent with an acute myocardial infarction. He was transferred to the 82nd Combat Support Hospital (CSH) in Tallil, Iraq, where according to the medical records provided, the infarction was confirmed and treatment for the infarction was initiated. Thrombolysis was not performed because of traumatic attempts at placing a foley catheter at Camp Bucca, which resulted in an actively bleeding site. The decedent had a chest x-ray consistent with heart failure pattern, which required intubation. During the decedent's hospitalization there were multiple trials of weaning him from the ventilator but all were unsuccessful. The decedent's blood pressure remained labile throughout his hospitalization. He received a tracheostomy and gastrostomy for extended care. On (b)(6) 2005, he possibly suffered another myocardial infarction and died despite emergent life saving efforts. The medical records of the last days of his hospitalization are not available for review. The decedent also has a reported history of poorly controlled adult onset diabetes mellitus.

Authorization for Autopsy: Office of the Armed Forces Medical Examiner, IAW 10 USC 1471.

Identification: Presumptive identification is established by the ISN (Internment Serial Number). Fingerprints and a DNA sample were taken for identification purposes should an exemplar become available.

CAUSE OF DEATH: Atherosclerotic Cardiovascular Disease

MANNER OF DEATH: Natural

ACLU Detainee DeathII ARMY MEDCOM 372

FINAL AUTOPSY DIAGNOSES:

I. Atherosclerotic Cardiovascular Disease

A. Atherosclerotic Cardiovascular Disease

1. Per Cardiovascular Pathology Consultation: "1) Cardiomegaly (582 grams) with left ventricular hypertrophy. 2) Severe coronary atherosclerosis with calcification, two vessel disease; occlusive organizing thrombus, mid left anterior descending artery. 3) Healing transmural myocardial infarction, left posterolateral wall. 4) Healed transmural myocardial infarction, apex, left anterior ventricular wall and septum." (See full consultation report below)
2. Moderate atherosclerosis of the aorta.
3. Moderate to severe atherosclerosis of the basilar artery and the Circle of Willis (cerebral arteries).
4. Finely granular cortical surfaces of the kidneys.

II. Other Autopsy Findings

1. Severe pulmonary edema with right pleural effusion (1500 ml of serosanguineous fluid).
2. Cholestasis with gallbladder wall thickening.
3. Bilateral renal cortical cysts (no greater than 0.4 cm in diameter)
4. Hemorrhagic mucosa of the trigone and lower urinary bladder
5. Anasarca associated with bilateral conjunctival edema, pitting edema of the extremities and digits and massive scrotal distention.
6. Crusted abrasions on the left chest, superior portion of the abdomen, left anterior costal margin, right thigh and right shoulder.
7. A 8 x 7 cm area of erythema on the inferior central abdominal wall
8. A 9.2 x 7.0 cm decubitus ulcer of the sacral area

III. Medical Intervention

1. Tracheostomy
2. Left chest tube (6th intercostal space) associated with dense but easily broken adhesions of the left parietal pleura to the left lung and thickening of the pleura
3. Prior left chest tube site (sutured skin incision and perforation of the 4th intercostal space)
4. Triple lumen catheter in left subclavian vein
5. Arterial catheter right radial artery

ACLU Detainee DeathII ARMY MEDCOM 373

6. Status post gastrostomy tube placement with stapled skin incision and associated with easily broken adhesions of the liver, stomach and transverse colon.
7. Foley catheterization of the urinary bladder
8. Status post cardiopulmonary resuscitation associated with fractures of the right fifth rib and left fourth and fifth ribs.
9. Self adhesive electrocardiogram lead on the left abdominal wall
10. Needle puncture site in the left antecubital fossa
11. Bio-occlusive dressing on posterior left thigh

IV. Mild decomposition with areas of vesicle formation and skin slippage on the scalp, face, left and right upper extremities, left abdomen, upper back, left thigh, and bilateral lower legs

V. Identifying Marks
1. (b)(6) tattoo (b)(6)
2. Hyperpigmented scar on the posterior surface of the right hand
3. Hyperpigmented areas of skin on the right lower abdominal quadrant

VI. Toxicology is negative for ethanol and drugs of abuse. Midazolam (a benzodiazepine) is in the blood (0.10 mg/L).

ACLU Detainee DeathII ARMY MEDCOM 374

EXTERNAL EXAMINATION

The unclad body is that of a well-developed, well-nourished appearing, 69 inch long, 243 pound Iraqi national male whose appearance is consistent with an age range of 40-50 years. Lividity is faint and fixed along the back. Rigor mortis is absent. There is mild anasarca. Early decomposition changes, which include vesicle formation and skin slippage, are on the scalp, the left side of the face and neck, the upper extremities, the left side of the abdomen, the upper back, the left thigh and lower legs.

The scalp is covered with curly black hair in a normal distribution. The irides are brown, and the pupils are round and equal in diameter. The conjunctivae are edematous and there is bilateral peri-orbital edema. The external auditory canals are free of abnormal excretions. The ears are unremarkable. The nares are patent and the lips are atraumatic. The nose and maxillae are palpably stable. The decedent is edentulous. The facial hair consists of a black and gray mustache and beard.

The neck is straight, and the trachea is midline and mobile. A tracheostomy tube is in place in the central anterior neck. The chest is symmetric. A 2.4 x 0.8 cm crusted abrasion is on the left chest. A 1.2 x 0.2 cm crusted abrasion is immediately below the left costal margin. On the upper central abdomen are four areas of abrasions with early skin slippage. The areas range from 1.2 x 0.3 cm to 2.0 x 0.3cm. The abdomen is globoid and without masses. An 8 x 7 cm area of erythema is on the skin of the inferior central abdomen. In the right lower quadrant of the abdomen are two areas of hyperpigmented skin (10 x 3 cm and 4 x 4 cm). The genitalia are those of a normal adult circumcised male. The testes are descended and free of masses. Pubic hair is present in a normal distribution. On the right upper back is a 2.4 x 0.7 cm crusted abrasion. Overlying the sacrum is a 9.2 x 7.0 cm decubitus ulcer. The buttocks and anus are unremarkable. A bio-occlusive dressing is attached to the posterior proximal left thigh.

The upper and lower extremities are symmetric and free of obvious deformities. On the anterior surface of the right thigh are a 5.3 x 2.5 cm area of scattered abrasions and a 3.8 x 1.5 cm area of crusted skin slippage.

CLOTHING AND PERSONAL EFFECTS

The following clothing items and personal effects accompanied the body at the time of autopsy:

A white "Cartier Paris" t-shirt, green scrub pants, "Madaen" sandals, green socks, an Iraqi garment and brown jacket.

MEDICAL INTERVENTION

1. Tracheostomy
2. Left chest tube (6th intercostal space) associated with dense but easily broken adhesions of the left parietal pleura to the left lung and thickening of the pleura
3. Prior left chest tube site (sutured skin incision and perforation of the 4th intercostal space)
4. Triple lumen catheter in left subclavian vein

ACLU Detainee DeathII ARMY MEDCOM 375

5. Arterial catheter right radial artery
6. Status post gastrostomy tube placement with stapled skin incision and associated with easily broken adhesions of the liver, stomach and transverse colon.
7. Foley catheterization of the urinary bladder
8. Status post cardiopulmonary resuscitation associated with fractures of the right fifth rib and left fourth and fifth ribs.
9. Self adhesive electrocardiogram lead on the left abdominal wall
10. Needle puncture site in the left antecubital fossa
11. Bio-occlusive dressing on posterior left thigh

RADIOGRAPHS

A complete set of postmortem radiographs is obtained and demonstrates no long bone fractures or masses. There are no foreign bodies except for the medical devices described above.

EVIDENCE OF INJURY

There are no acute injuries.

INTERNAL EXAMINATION

HEAD:
The galeal and subgaleal soft tissues of the scalp are free of injury. The calvarium is intact, as is the dura mater beneath it. Clear cerebrospinal fluid surrounds the 1490 gm brain, which has a dusky appearance and generalized softening of the parenchyma. The gyri and sulci are unremarkable. Coronal sections demonstrate sharp demarcation between white and grey matter, without hemorrhage or contusive injury. The ventricles are of normal size. The basal ganglia, brainstem, and cerebellum are free of injury or other abnormalities. There is moderate to severe atherosclerosis of the basilar artery and Circle of Willis (cerebral arteries). There are no skull fractures. The atlanto-occipital joint is stable.

NECK:
The anterior strap muscles of the neck are homogenous and red-brown, without hemorrhage. The thyroid cartilage and hyoid bone are intact and calcified. A tracheostomy is in the crico-thyroid membrane and is associated with a laceration of the isthmus of the thyroid gland. The larynx is lined by intact white mucosa. The thyroid gland is symmetric and red-brown, without cystic or nodular change. The edematous tongue is free of bite marks, hemorrhage, or other injuries.

BODY CAVITIES:
The ribs (except where noted above), sternum, and vertebral bodies are visibly and palpably intact. No excess fluid is in the pericardial cavity. The right hemithorax contains 1500 ml of bloody serous fluid. The left hemithorax has dense but easily broken adhesions between the left lung and the parietal pleura. The peritoneal cavity contains approximately 200 ml of brown and bilious fluid. The organs occupy their usual anatomic positions.

ACLU Detainee DeathII ARMY MEDCOM 376

RESPIRATORY SYSTEM:
The right and left lungs weigh 1130 and 1060 gm, respectively. The external surfaces are smooth and deep red-purple. The pulmonary parenchyma is severely congested and edematous. There are no areas of frank purulence. No mass lesions or areas of consolidation are present.

CARDIOVASCULAR SYSTEM:
The 610 gm heart is soft and contained in an intact pericardial sac. The epicardial surface is smooth, with minimal fat investment. The epicardial surface of the left ventricle has a dark speckled appearance. The coronary arteries are present in a normal distribution. Cross sections of the left coronary artery show severe atherosclerosis of the left anterior descending branch of the left coronary artery. See full Cardiac Pathology Consultation Report below.

The aorta gives rise to three intact and patent arch vessels. There is moderate ulcerated atherosclerosis throughout the course of the aorta. The renal and mesenteric vessels are unremarkable.

LIVER & BILIARY SYSTEM:
The 2260 gm liver has an intact, smooth capsule and a sharp anterior border. The parenchyma is tan-brown and congested, with the usual lobular architecture. No mass lesions or other abnormalities are seen. The gallbladder contains approximately 20-30 ml of viscous green-black bile and no stones. The gallbladder wall thickened and the mucosal surface is green and velvety. The extrahepatic biliary tree is patent.

SPLEEN:
The 330 gm spleen has a smooth, intact, red-purple capsule. The parenchyma is soft and liquified.

PANCREAS:
The pancreas is firm and yellow-tan, with the usual lobular architecture. No mass lesions or other abnormalities are seen.

ADRENALS:
The right and left adrenal glands are symmetric, with bright yellow cortices and grey autolyzed medullae.

GENITOURINARY SYSTEM:
The right and left kidneys weigh 230 gm each. The external surfaces are intact and are finely granular. Each kidney has several small cortical cysts, none of which are greater than 0.4 cm in diameter. The cut surfaces are red-tan and congested, with uniformly thick cortices and sharp corticomedullary junctions. The pelves are unremarkable and the ureters are normal in course and caliber. White bladder mucosa overlies an intact bladder wall that has area of hemorrhage surrounding and including the trigone. The bladder contains no urine. The prostate is normal in size, with lobular, yellow-tan parenchyma. The seminal

ACLU Detainee DeathII ARMY MEDCOM 377

vesicles are unremarkable. The testes are free of mass lesions, contusions, or other abnormalities.

GASTROINTESTINAL TRACT:
The esophagus is intact and lined by smooth, grey-white mucosa. The stomach contains approximately 120 ml of brown fluid. A gastrostomy tube perforates the gastric wall. The tube is patent. The duodenum, loops of small bowel, and colon are unremarkable. The appendix is present and unremarkable.

ADDITIONAL PROCEDURES

- Documentary photographs are taken by an OAFME photographer.
- Specimens retained for toxicologic testing and/or DNA identification are: vitreous, blood, urine, spleen, lung, kidney, liver, brain, bile, gastric contents, adipose tissue and psoas muscle.
- The dissected organs are forwarded with body
- Personal effects are released to the appropriate mortuary operations representatives

CONSULTATIONS

Cardiac Pathology Consultation (Department of Cardiovascular Pathology, AFIP, Washington D.C.):

"Diagnosis (b)(6) **: Heart:**

1. **Cardiomegaly with left ventricular hypertrophy**
2. **Severe coronary atherosclerosis with calcification, two vessel disease; occlusive organizing thrombus, mid left anterior descending artery**
3. **Healing transmural myocardial infarction, left posterolateral ventricular**
4. **Healed transmural myocardial infarction, apex, left anterior ventricular wall and septum**

Clinical history: This Iraqi National male detainee of the US Force suffered a myocardial infarction on (b)(6) 05 and was transferred to the hospital where he reportedly suffered another myocardial infarction on (b)(05 and died despite emergent live saving efforts.

Heart: 582 grams; normal epicardial fat; probe patent foramen ovale; left ventricular cavity diameter 5.5 cm, left ventricular free wall thickness 1.6 cm; ventricular septum thickness 1.7 cm; right ventricle thickness 0.3 cm, without gross scars or abnormal fat infiltrates; grossly unremarkable valves and endocardium; scarring of the left anterior ventricular wall and septum; circumferential scarring of the apex; posterolateral wall shows tan-gray softened areas; dilated aortic root; histologic sections show transmural replacement fibrosis of the left anterior ventricular wall and septum and the a transmural healing infarction of several weeks duration seen in the left posterolateral wall characterized by extensive granulation tissue formation with infiltration of numerous macrophages and lymphocytes

Coronary arteries; normal ostia; left dominance; severe coronary atherosclerosis with calcification
Left main coronary (LM): 40% luminal narrowing by fibroatheromatous plaque

ACLU Detainee DeathII ARMY MEDCOM 378

Left anterior descending artery (LAD): Partial wrap around LAD with up to 75% luminal narrowing by calcified fibroatheroma; occlusive organizing thrombus mid LAD; total occlusion of diagonal branch by calcified fibroatheroma
Left circumflex artery (LCA): 75% luminal narrowing of the distal LCA by calcified fibroatheroma
Right coronary artery (RCA): 30% luminal narrowing by fibroatheromatous plaque"

Signed by Renu Virmani, M.D. Cardiovascular Pathologist (Original signature of file in the OAFME).

MICROSCOPIC EXAMINATION

Except where noted above, selected portions of organs are retained in formalin, without preparation of histologic slides.

OPINION

This Iraqi National male detainee of the US Forces suffered a myocardial infarction on (b)(6) (b)(6) 2005 while being held at Camp Bucca, Iraq. His hospital course was complicated by continued blood pressure fluctuations and respiratory difficulties. Based on the examination of his heart there was extensive damage and scarring from two large infarctions (heart attacks), which resulted from severe atherosclerosis. The mechanism of death is most commonly an arrhythmia (irregular heart beat) arising in the damaged areas of the heart. The manner of death is natural.

(b)(6)

(b)(6) Medical Examiner

ACLU Detainee DeathII ARMY MEDCOM 379

CERTIFICATE OF DEATH *(OVERSEAS)*
Acte de décès *(D'Outre-Mer)*

NAME OF DECEASED *(Last, First, Middle)* Nom du décédé *(Nom et prénoms)*	GRADE Grade	BRANCH OF SERVICE Arme	SOCIAL SECURITY NUMBER Numéro de l'Assurance Sociale
BTB Majamey, Al Khalaf		Iraqi detainee	(b)(6)
ORGANIZATION Organisation: Iraqi Detainee at Camp Bucca	NATION *(e.g., United States)* Pays: Iraq	DATE OF BIRTH Date de naissance	SEX Sexe: ☑ MALE Masculin ☐ FEMALE Féminin

RACE Race	MARITAL STATUS État Civil		RELIGION Culte	
X CAUCASOID Caucasique	SINGLE Célibataire	DIVORCED Divorcé	PROTESTANT Protestant	OTHER (Specify) Autre (Spécifier)
NEGROID Negroide	MARRIED Marié	SEPARATED Séparé	CATHOLIC Catholique	X Muslim
OTHER (Specify) Autre (Spécifier)	WIDOWED Veuf		JEWISH Juif	

NAME OF NEXT OF KIN Nom du plus proche parent	RELATIONSHIP TO DECEASED Parenté du décédé avec le susdit
STREET ADDRESS Domicile à (Rue)	CITY OR TOWN AND STATE *(Include ZIP Code)* Ville *(Code postal compris)*

MEDICAL STATEMENT Déclaration médicale

CAUSE OF DEATH *(Enter only once cause per line)* Cause du décès (N'indiquer qu'une cause par ligne)		INTERVAL BETWEEN ONSET AND DEATH Intervalle entre l'attaque et le décès
DISEASE OR CONDITION DIRECTLY LEADING TO DEATH[1] Maladie ou condition directement responsable de la mort[1]	Atherosclerotic cardiovascular disease.	Weeks
ANTECEDENT CAUSES Symptômes précurseurs de la mort — MORBID CONDITION, IF ANY, LEADING TO PRIMARY CAUSE Condition morbide, s'il y a lieu, menant à la cause primaire		
ANTECEDENT CAUSES Symptômes précurseurs de la mort — UNDERLYING CAUSE, IF ANY, GIVING RISE TO PRIMARY CAUSE Raison fondamentale, s'il y a lieu, ayant suscité la cause primaire		
OTHER SIGNIFICANT CONDITIONS[2] Autres conditions significatives[2]		

MODE OF DEATH Condition de décès	AUTOPSY PERFORMED Autopsie effectuée ☑ YES Oui ☐ NO Non	CIRCUMSTANCES SURROUNDING DEATH DUE TO EXTERNAL CAUSES Circonstances de la mort suscitées par des causes extérieures
X NATURAL Mort naturelle	MAJOR FINDINGS OF AUTOPSY Conclusions principales de l'autopsie	
ACCIDENT Mort accidentelle		
SUICIDE Suicide	NAME OF PATHOLOGIST Nom du pathologiste: (b)(6)	
HOMICIDE Homicide	(b)(6) — DATE Date: 15 Mar 2005	AVIATION ACCIDENT Accident à Avion ☐ YES Oui ☑ NO Non

DATE OF DEATH *(Hour, day, month, year)* Date de décès *(l'heure, le jour, le mois, l'année)*	PLACE OF DEATH Lieu de décès
(b)(6) 2005	82nd CSH, Tallil, Iraq

I HAVE VIEWED THE REMAINS OF THE DECEASED AND DEATH OCCURRED AT THE TIME INDICATED AND FROM THE CAUSES AS STATED ABOVE.
J'ai examiné les restes mortels du dé funtet je conclus que le décès est survenu à l'heure indiquée et à la suite des causes énumérées ci-dessus.

NAME OF MEDICAL OFFICER Nom du médicin militaire ou du médicin sanitaire	TITLE OR DEGREE Titre ou diplômé
(b)(6)	Medical Examiner
GRADE Grade: (b)(6)	INSTALLATION OR ADDRESS Installation ou adresse: Dover AFB, DE 19902
DATE Date: 16 MAR 05	(b)(6)

[1] State disease, injury or complication which caused death, but not mode of dying such as heart failure, etc.
[2] State conditions contributing to the death, but not related to the disease or condition causing death.
[1] Préciser la nature de la maladie, de la blessure ou de la complication qui a contribué à la mort, mais non la manière de mourir, telle qu'un arrêt du coeur, etc.
[2] Préciser la condition qui a contribué à la mort, mais n'ayant aucun rapport avec la maladie ou à la condition qui a provoqué la mort.

DD FORM 1 APR 77 2064 REPLACES DA FORM 3565, 1 JAN [illegible] (PAS), 26 SEP 75, WHICH ARE OBSOLETE.

(REMOVE, REVERSE AND RE-INSERT CARBONS BEFORE COMPLETING THIS SIDE)

DISPOSITION OF REMAINS			
NAME OF MORTICIAN PREPARING REMAINS	GRADE	LICENSE NUMBER AND STATE	OTHER
INSTALLATION OR ADDRESS	DATE 3/15/2005	SIGNATURE	
NAME OF CEMETERY OR CREMATORY	LOCATION OF CEMETERY OR CREMATORY		
TYPE OF DISPOSITION		DATE OF DISPOSITION	

REGISTRATION OF VITAL STATISTICS			
REGISTRY *(Town and Country)*	DATE REGISTERED	FILE NUMBER	
		STATE	OTHER
NAME OF FUNERAL DIRECTOR	ADDRESS		
SIGNATURE OF AUTHORIZED INDIVIDUAL			

DD FORM 2064, APR 1977 (BACK) USAPA V1.00

ACLU Detainee DeathII ARMY MEDCOM 381

ARMED FORCES INSTITUTE OF PATHOLOGY
Office of the Armed Forces Medical Examiner
1413 Research Blvd., Bldg. 102
Rockville, MD 20850
1-800-944-7912

FINAL AUTOPSY EXAMINATION REPORT

Name: BTB Tawfeeek, Salmany
ISN (b)(6)
Date of Birth: (b)(6) 1977
Date of Death (b)(6) 2005
Date of Autopsy: 5 February 2005
Date of Report: 05 April 2005

Autopsy No.: (b)(6)
AFIP No. (b)(6)
Rank: Civilian
Place of Death: Iraq
Place of Autopsy: Army Mortuary
Camp Victory, Iraq

Circumstances of Death: This 27-year-old male was a civilian detainee who was shot during a prison disturbance.

Authorization for Autopsy: Office of the Armed Forces Medical Examiner, IAW 10 USC 1471.

Identification: Identification is established by means of the attached identification tags.

CAUSE OF DEATH: Gunshot wound of the head.

MANNER OF DEATH: Homicide.

FINAL AUTOPSY DIAGNOSES

I. Perforating gunshot wound of the head:
   A. Entry: right posterior parietal region of head
   B. No evidence of soot or gunpowder stippling is present on the skin around the entrance wound.
   C. Path: skin of right posterior parietal scalp, right posterior parietal region of the skull, right cerebral hemisphere of the brain, right parietal region of the skull.
   D. Projectile: yellow metal fragment recovered.
   E. Exit: right parietal region of the head.
   F. Direction: back to front and upwards.
   G. Associated injuries:
      1. Multiple linear fractures of the right parietal and vertex regions of the calvarium.
      2. Perforating laceration of the right cerebral hemisphere.
      3. Subgaleal hemorrhage in the biparietal and occipital regions.

ACLU Detainee DeathII ARMY MEDCOM 382

II. **Additional injuries:**
A. Circular abrasions on left lateral chest, left upper arm, right forearm and the left thigh.

III. **Toxicology: Negative.**

ACLU Detainee DeathII ARMY MEDCOM 383

EXTERNAL EXAMINATION

The body is that of a well-developed, well-nourished male that weighs approximately 182 pounds, is 67 inches in length and appears compatible with the reported age of 27 years. Lividity is fixed on the posterior surface of the body except in areas exposed to pressure. Rigor is complete. The scalp hair is black. Facial hair consists of a black beard and mustache. The irides are dark. The corneae are cloudy. The conjunctivae are unremarkable. The sclerae are white. The external auditory canals, external nares and oral cavity are free of foreign material and abnormal secretions. The teeth are natural and in good condition. The neck is straight and the trachea is midline and mobile. The chest is unremarkable. The abdomen is flat. The upper and lower extremities are symmetric. The numeral "2" is written on the dorsum of the right hand. The fingernails are intact. A 2 ½ x ½ inch band-like hyperkeratotic area is present on the dorsal surface of both feet. An identification tag is present on the right 1st toe bearing "BTB (b)(6) The genitalia are those of a normal adult male. The buttocks and anus are unremarkable.

CLOTHING AND PERSONAL EFFECTS

The following personal effects accompany the body:

1. A 5000 Dinar bank note.
2. A band with (b)(6) a photo and demographic information.

EVIDENCE OF MEDICAL THERAPY

1. An endotracheal tube.
2. A nasogastric tube.
3. Intravascular catheters are present in the left antecubital fossa and right inguinal region.
4. A therapeutic needle puncture site in the right antecubital fossa.
5. A Foley catheter.
6. Defibrillator pads on the right upper and left lateral chest.

EVIDENCE OF INJURY

The ordering of the following injuries is for descriptive purposes only, and is not intended to imply order of infliction or relative severity. All wound pathways are given relative to standard anatomic position.

Perforating gunshot wound of the head:

There is an atypical gunshot wound of entrance situated in the right posterior parietal region of the head located 1 ½ inches below the top of the head and 2 ¼ inches right of the posterior midline. The wound measures ¾ x 1/8 inch. There is eccentric marginal abrasion located infero-medially having an average width of 1/8 inch. No evidence of

ACLU Detainee DeathII ARMY MEDCOM 384

soot or gunpowder stippling is present on the skin around the entrance wound. The adjacent internally beveled skull defect measures ½ x ¼ inch. The wound path passes through the skin of the right posterior parietal scalp, right posterior parietal region of the skull, right cerebral hemisphere of the brain, right parietal region of the skull and the right parietal scalp. A stellate exit wound is present in the right parietal region of the head located on the top of the head, centered 2 ½ inches right of the anterior midline. The exit wound measures 4 ½ x 2 ½ inches. The trajectory of the gunshot wound is back to front and upward. A 1 mm yellow metal fragment is recovered from the right parietal subgaleal region. Associated with the gunshot wound are multiple linear fractures of the right parietal and vertex regions of the calvarium, perforating laceration of the right cerebral hemisphere and subgaleal hemorrhage in the biparietal and occipital regions.

Additional injury:

There are multiple circular abrasions averaging ¼ inch in diameter distributed as follows:

1. Left mandibular region of the face.
2. Left lateral surface of the chest (2).
3. Posterior surface of the right forearm.
4. Anterior surface of the left upper arm.
5. Posterior lateral surface of the left thigh.

INTERNAL EXAMINATION

HEAD:
(See above "Evidence of Injury").

The scalp is reflected. The calvarium of the skull is removed. The leptomeninges are thin and delicate. Coronal sections demonstrate sharp demarcation between the uninjured white and grey matter. The ventricles are of normal size. The brain weighs 1550 gm. The atlanto-occipital joint is stable.

NECK:

The anterior strap muscles of the neck are homogenous and red-brown, without hemorrhage. The thyroid cartilage and hyoid are intact. The larynx is lined by intact white mucosa. The thyroid is symmetric and red-brown. The tongue is free of bite marks, hemorrhage, or other injuries.

BODY CAVITIES:

The sternum is visibly and palpably intact. No excess fluid is present in the pericardial, pleural or peritoneal cavities. The organs occupy their usual anatomic positions.

ACLU Detainee DeathII ARMY MEDCOM 385

RESPIRATORY SYSTEM:

The right and left lungs weigh 385 and 291 gm, respectively. The external surfaces are smooth and deep red-purple. The pulmonary parenchyma is diffusely congested and edematous. No mass lesions or areas of consolidation are present.

CARDIOVASCULAR SYSTEM:

The 324 gm heart is contained in an intact pericardial sac. The epicardial surface is smooth, with minimal fat investment. The coronary arteries arise normally, follow the usual distribution and are widely patent without evidence of significant atherosclerosis or thrombosis. The myocardium is homogenous, red-brown, and firm. The valve leaflets are thin and mobile. The endocardium is smooth and glistening. The ascending aorta gives rise to three intact and patent arch vessels. The renal and mesenteric vessels are unremarkable.

LIVER & BILIARY SYSTEM:

The 1184 gm liver has an intact, smooth capsule and a sharp anterior border. The parenchyma is tan-brown and congested, with the usual lobular architecture. No mass lesions or other abnormalities are seen. The gallbladder contains less than 5 ml of green-black bile. The mucosal surface is green and velvety. The extrahepatic biliary tree is patent.

SPLEEN:

The 61 gm spleen has a smooth, intact, red-purple capsule. The parenchyma is maroon and congested, with distinct Malpighian corpuscles.

PANCREAS:

The pancreas is soft and yellow-tan, with the usual lobular architecture. No mass lesions or other abnormalities are seen.

ADRENALS:

The right and left adrenal glands are symmetric, with bright yellow cortices and grey medullae. No masses or areas of hemorrhage are identified.

GENITOURINARY SYSTEM:

The right kidney weighs 70 gm; the left 103 gm. The external surfaces are intact and smooth. The cut surfaces are red-tan and congested, with uniformly thick cortices and sharp corticomedullary junctions. The pelves are unremarkable and the ureters are normal in course and caliber. Tan bladder mucosa overlies an intact bladder wall. The bladder is empty. The prostate is normal in size, with lobular, yellow-tan parenchyma. The seminal

ACLU Detainee DeathII ARMY MEDCOM 386

vesicles are unremarkable. The testes are free of mass lesions, contusions, or other abnormalities.

GASTROINTESTINAL TRACT:

The esophagus is lined by smooth, grey-white mucosa. The stomach contains approximately 100 ml of tan gray flocculent material. The gastric wall is intact. The duodenum, loops of small bowel, colon, and appendix are unremarkable.

MICROSCOPIC EXAMINATION

Selected portions of organs are retained in formalin, without preparation of histologic slides.

ADDITIONAL PROCEDURES/REMARKS

- Documentary photographs are taken by OAFME staff photographer (b)(6) (b)(6)
- Specimens retained for toxicologic testing and/or DNA identification are: blood, vitreous, bile, gastric contents, spleen and liver.
- Full body radiographs are obtained and demonstrate the injuries as described. Scattered minute metallic fragments are seen radiographically in the region of the head wound.
- The dissected organs are forwarded with the body.
- The recovered metallic fragment is placed in a labeled container and released to the attending investigative agents.
- Personal effects are released to the appropriate mortuary operations representatives.

OPINION

This 27-year-old male civilian detainee died of a gunshot wound to the head. There was no evidence of close range firing on the skin around the entrance wound. The gunshot wound passed through the head causing extensive injury to the skull and brain. A single projectile fragment was recovered.

The manner of death is homicide.

(b)(6)

(b)(6) Medical Examiner

ACLU Detainee DeathII ARMY MEDCOM 387

(b)(6)

CERTIFICATE OF DEATH *(OVERSEAS)*
Acte de décès *(D'Outre-Mer)*

NAME OF DECEASED *(Last, First, Middle)* Nom du décédé (Nom et prénoms)	GRADE Grade	BRANCH OF SERVICE Arme	SOCIAL SECURITY NUMBER Numéro de l'Assurance Sociale
BTB Tawfeek, Salmany		Iraqi Detainee	(b)(6)

ORGANIZATION Organisation	NATION *(e.g., United States)* Pays	DATE OF BIRTH Date de naissance	SEX Sexe
	Iraq	(b)(6) 1977	☑ MALE Masculin ☐ FEMALE Féminin

RACE Race	MARITAL STATUS État Civil	RELIGION Culte
☐ CAUCASOID Caucasique	☐ SINGLE Célibataire	☐ PROTESTANT Protestant
☐ NEGROID Negroide	☐ MARRIED Marié	☐ CATHOLIC Catholique
☒ OTHER (Specify) Autre (Spécifier) Other	☐ WIDOWED Veuf	☐ JEWISH Juif
	☐ DIVORCED Divorcé	☐ OTHER (Specify) Autre (Spécifier)
	☐ SEPARATED Séparé	

NAME OF NEXT OF KIN Nom du plus proche parent	RELATIONSHIP TO DECEASED Parenté du décédé avec le susdit
STREET ADDRESS Domicile à (Rue)	CITY OR TOWN AND STATE *(Include ZIP Code)* Ville (Code postal compris)

MEDICAL STATEMENT Déclaration médicale

CAUSE OF DEATH *(Enter only once cause per line)* Cause du décès (N'indiquer qu'une cause par ligne)			INTERVAL BETWEEN ONSET AND DEATH Intervalle entre l'attaque et le décès
DISEASE OR CONDITION DIRECTLY LEADING TO DEATH [1] Maladie ou condition directement responsable de la mort [1]		Gunshot wound of the head	
ANTECEDENT CAUSES Symptômes précurseurs de la mort.	MORBID CONDITION, IF ANY, LEADING TO PRIMARY CAUSE Condition morbide, s'il y a lieu, menant à la cause primaire		
	UNDERLYING CAUSE, IF ANY, GIVING RISE TO PRIMARY CAUSE Raison fondamentale, s'il y a lieu, ayant suscité la cause primaire		
OTHER SIGNIFICANT CONDITIONS [2] Autres conditions significatives [2]			

MODE OF DEATH Condition de décès	AUTOPSY PERFORMED Autopsie effectuée	CIRCUMSTANCES SURROUNDING DEATH DUE TO EXTERNAL CAUSES Circonstances de la mort suscitées par des causes extérieures
☐ NATURAL Mort naturelle	☑ YES Oui ☐ NO Non	
☐ ACCIDENT Mort accidentelle	MAJOR FINDINGS OF AUTOPSY Conclusions principales de l'autopsie	
☐ SUICIDE Suicide	NAME OF PATHOLOGIST Nom du pathologiste (b)(6)	
☒ HOMICIDE Homicide	(b)(6)	

DATE Date	AVIATION ACCIDENT Accident d'Avion
05 Feb 2005	☐ YES Oui ☑ NO Non

DATE OF DEATH *(Hour, day, month, year)* Date du décès *(l'heure, le jour, le mois, l'année)*	PLACE OF DEATH Lieu du décès
(b)(6) 2005	Iraq

I HAVE VIEWED THE REMAINS OF THE DECEASED AND DEATH OCCURRED AT THE TIME INDICATED AND FROM THE CAUSES AS STATED ABOVE.
J'ai examiné les restes mortels du dé funter je conclus que le décès est survenu à l'heure indiquée et à, la suite des causes énumérées ci-dessus.

NAME OF MEDICAL OFFICER Nom du médicin militaire ou du médicin sanitaire	TITLE OR DEGREE Titre ou diplôme
(b)(6)	Medical Examiner

GRADE Grade	INSTALLATION OR ADDRESS Installation ou adresse
(b)(6)	Dover AFB, DE 19902

DATE Date 29 Mar 05 (b)(6)

[1] State disease, injury or complication which caused death, but not mode of dying such as heart failure, etc.
[2] State conditions contributing to the death, but not related to the disease or condition causing death.
[1] Préciser la nature de la maladie, de la blessure ou de la complication qui a contribué à la mort, mais non la manière de mourir, telle qu'un arrêt du coeur, etc
[2] Préciser la condition qui a contribué à la mort, mais n'ayant aucun rapport avec la maladie ou à la condition qui a provoqué la mort.

DD FORM 1 APR 77 2064 REPLACES DA FORM 3565, 1 JAN 72 AND DA FORM 3565-R(PAS), 26 SEP 75, WHICH ARE OBSOLETE.

MEDCOM 0388

ACLU Detainee DeathII ARMY MEDCOM 388

(REMOVE, REVERSE AND RE-INSERT CARBONS BEFORE COMPLETING THIS SIDE)

DISPOSITION OF REMAINS			
NAME OF MORTICIAN PREPARING REMAINS	GRADE	LICENSE NUMBER AND STATE	OTHER
INSTALLATION OR ADDRESS	DATE	SIGNATURE	
NAME OF CEMETERY OR CREMATORY	LOCATION OF CEMETERY OR CREMATORY		
TYPE OF DISPOSITION		DATE OF DISPOSITION	

REGISTRATION OF VITAL STATISTICS			
REGISTRY *(Town and Country)*	DATE REGISTERED	FILE NUMBER	
		STATE	OTHER
NAME OF FUNERAL DIRECTOR	ADDRESS		
SIGNATURE OF AUTHORIZED INDIVIDUAL			

DD FORM 2064, APR 1977 (BACK) USAPA V1.00

ACLU Detainee DeathII ARMY MEDCOM 389

ARMED FORCES INSTITUTE OF PATHOLOGY
Office of the Armed Forces Medical Examiner
1413 Research Blvd., Bldg. 102
Rockville, MD 20850
1-800-944-7912

FINAL AUTOPSY EXAMINATION REPORT

Name: BTB Abid, Ismail Hammed
ISN: (b)(6)
Date of Birth: (b)(6) 1976
Date of Death: (b)(6) 2005
Date of Autopsy: 5 February 2005
Date of Report: 29 March 2005

Autopsy No.: (b)(6)
AFIP No. (b)(6)
Rank: Civilian
Place of Death: Iraq
Place of Autopsy: Army Mortuary
Camp Victory, Iraq

Circumstances of Death: This 29-year-old male was a civilian detainee shot during a prison disturbance.

Authorization for Autopsy: Office of the Armed Forces Medical Examiner, IAW 10 USC 1471.

Identification: Identification is established by means of the attached identification tags.

CAUSE OF DEATH: Gunshot wound of the chest.

MANNER OF DEATH: Homicide.

ACLU Detainee DeathII ARMY MEDCOM 390

FINAL AUTOPSY DIAGNOSES

I. Perforating gunshot wound of the chest:
   A. Entry: left side of the back.
   B. No evidence of soot or gunpowder stippling is present on the skin around the entrance wound.
   C. Path: skin of the back, the left 8th rib, left lung, descending aorta, right lung, right 6th and 7th ribs, skin of the right chest.
   D. Exit: right lateral chest.
   E. Direction: left to right, back to front and upward.
   F. Associated injury:
      1. Fracture of the posterior lateral aspect of the left 8th rib.
      2. Fractures of the lateral aspect of the right 6th and 7th ribs.
      3. Perforating laceration of the descending aorta.
         a. Bilateral hemothoraces (right 500 ml, left 1000 ml).
      4. Esophageal laceration.
      5. Perforating laceration of the middle and lower lobes of the right lung.
      6. Perforating laceration of the lower lobe of the left lung.

II. No significant natural diseases identified, within limitations of the examination.

III. Toxicology: Negative.

EXTERNAL EXAMINATION

The body is that of a well-developed, well-nourished male that weighs approximately 181 pounds, is 67 inches in length and appears compatible with the reported age of 29 years. Lividity is fixed on the posterior surface of the body except in areas exposed to pressure. Rigor is complete. The scalp hair is black. A black beard and mustache are also present. The irides are dark. The corneae are cloudy. The conjunctivae are unremarkable. The sclerae are white. The external auditory canals, external nares and oral cavity are free of foreign material and abnormal secretions. The teeth are natural and in good condition. The neck is straight, and the trachea is midline and mobile. The chest shows evidence of injury to be further described below. The abdomen is flat. The fingernails are intact. The upper and lower extremities are symmetric. Identification tags are present on the 1st toe of each foot, bearing the name BTB (b)(6) The genitalia are those of a normal adult male. The buttocks and anus are unremarkable.

CLOTHING AND PERSONAL EFFECTS

The following clothing items and personal effects accompany the body:

1. A 1000 Dinar bank note.
2. An identification card in Arabic.

ACLU Detainee DeathII ARMY MEDCOM 391

3. A band with (b)(6) a photo and demographic information.

EVIDENCE OF MEDICAL THERAPY

1. An endotracheal tube.

EVIDENCE OF INJURY

The ordering of the following injuries is for descriptive purposes only, and is not intended to imply order of infliction or relative severity. All wound pathways are given relative to standard anatomic position.

Perforating gunshot wound of the chest:

There is a gunshot wound of entrance situated on the left side of the back located 18 ½ inches below the top of the head and 6 inches left of the posterior midline. The wound measures 1/8 inch. There is eccentric marginal abrasion ranging in width from 1/16 inch to 1/8 inch in the 3 to 12 o'clock position. A 1/16 inch laceration is located in the 2 o'clock position. No evidence of soot or gunpowder stippling is present on the skin around the entrance wound. The wound path passes through the skin of the back, the left 8th rib, left lung, descending aorta, right lung, right 6th and 7th ribs and skin of the right chest. An exit wound is present on the right side of the chest located 16 inches below the top of the head and 6 ½ inches right of the anterior midline. The exit wound measures ¾ x ¼ inch. The trajectory of the gunshot wound is left to right, back to front and upward. No projectile or projectile fragments are recovered from the wound track. Associated with the gunshot wound are fracture of the posterior lateral aspect of the left 8th rib, fractures of the lateral aspect of the right 6th and 7th ribs, perforating laceration of the descending aorta, bilateral hemothoraces (500 ml on the right and 1000 ml on the left), laceration of the esophagus, perforating lacerations of the middle and lower lobes of the right lung and perforating laceration of the lower lobe of the left lung.

INTERNAL EXAMINATION

HEAD:

The scalp is reflected. The calvarium of the skull is removed. The leptomeninges are thin and delicate. Coronal sections demonstrate sharp demarcation between white and grey matter. The ventricles are of normal size. The brain weighs 1508 gm. The atlanto-occipital joint is stable.

NECK:

The anterior strap muscles of the neck are homogenous and red-brown, without hemorrhage. The thyroid cartilage and hyoid are intact. The larynx is lined by intact white mucosa. The thyroid is symmetric and red-brown. The tongue is free of bite marks, hemorrhage, or other injuries.

ACLU Detainee DeathII ARMY MEDCOM 392

BODY CAVITIES:
(See above "Evidence of Injury")

The sternum is visibly and palpably intact. No excess fluid is present in the pericardial or peritoneal cavities. The organs occupy their usual anatomic positions.

RESPIRATORY SYSTEM:
(See above "Evidence of Injury")

The right and left lungs weigh 267 and 264 gm, respectively. The uninjured external surfaces are smooth and deep red-purple. The uninjured pulmonary parenchyma is diffusely congested and edematous. No mass lesions or areas of consolidation are present.

CARDIOVASCULAR SYSTEM:
(See above "Evidence of Injury")

The 350 gm heart is contained in an intact pericardial sac. The epicardial surface is smooth, with minimal fat investment. The coronary arteries arise normally, follow the usual distribution and are widely patent without evidence of significant atherosclerosis or thrombosis. The myocardium is homogenous, red-brown, and firm. The valve leaflets are thin and mobile. The endocardium is smooth and glistening. The ascending aorta gives rise to three intact and patent arch vessels. The renal and mesenteric vessels are unremarkable.

LIVER & BILIARY SYSTEM:

The 1295 gm liver has an intact, smooth capsule and a sharp anterior border. The parenchyma is tan-brown and congested, with the usual lobular architecture. No mass lesions or other abnormalities are seen. The gallbladder contains approximately 10 ml of green-black bile. The mucosal surface is green and velvety. The extrahepatic biliary tree is patent.

SPLEEN:

The 126 gm spleen has a smooth, intact, red-purple capsule. The parenchyma is maroon and congested, with distinct Malpighian corpuscles.

PANCREAS:

The pancreas is soft and yellow-tan, with the usual lobular architecture. No mass lesions or other abnormalities are seen.

ACLU Detainee DeathII ARMY MEDCOM 393

ADRENALS:

The right and left adrenal glands are symmetric, with bright yellow cortices and grey medullae. No masses or areas of hemorrhage are identified.

GENITOURINARY SYSTEM:

The right and left kidneys each weigh 122 gm. The external surfaces are intact and smooth. The cut surfaces are red-tan and congested, with uniformly thick cortices and sharp corticomedullary junctions. The pelves are unremarkable and the ureters are normal in course and caliber. Tan bladder mucosa overlies an intact bladder wall. The bladder contains approximately 10 ml of clear amber urine. The prostate is normal in size, with lobular, yellow-tan parenchyma. The seminal vesicles are unremarkable. The testes are free of mass lesions, contusions, or other abnormalities.

GASTROINTESTINAL TRACT:
(See above "Evidence of Injury")

The uninjured esophagus is lined by smooth, grey-white mucosa. The stomach contains approximately 60 ml of tan flocculent material. The gastric wall is intact. The duodenum, loops of small bowel, colon, and appendix are unremarkable.

MICROSCOPIC EXAMINATION

Selected portions of organs are retained in formalin, without preparation of histologic slides.

ADDITIONAL PROCEDURES/REMARKS

- Documentary photographs are taken by the OAFME staff photographer.
- Specimens retained for toxicologic testing and/or DNA identification are: blood, vitreous, bile, gastric contents, spleen, liver and urine.
- Full body radiographs are obtained. No definitive projectile or fragments are identified radiographically.
- The dissected organs are forwarded with the body.
- Personal effects are released to the attending investigative agency and appropriate mortuary operations representatives.

ACLU Detainee DeathII ARMY MEDCOM 394

OPINION

This 29-year-old male civilian detainee died of a gunshot wound to the chest. There was no evidence of close range firing on the skin around the entrance wound. The gunshot wound passed through the thoracic cavity causing hemorrhage and injury to internal organs. A projectile was not recovered.

The manner of death is homicide.

(b)(6)

(b)(6) Medical Examiner

ACLU Detainee DeathII ARMY MEDCOM 395

(b)(6)

CERTIFICATE OF DEATH *(OVERSEAS)*
Acte de décès *(D'Outre-Mer)*

NAME OF DECEASED *(Last, First, Middle)* Nom du décédé (Nom et prénoms)	GRADE Grade	BRANCH OF SERVICE Arme	SOCIAL SECURITY NUMBER Numéro de l'Assurance Sociale
BTB Hammed, Abid Ismail		Iraqi Detainee	(b)(6)

ORGANIZATION Organisation	NATION *(e.g., United States)* Pays	DATE OF BIRTH Date de naissance	SEX Sexe
	Iraq	(b)(6) 1976	☑ MALE Masculin ☐ FEMALE Féminin

RACE Race	MARITAL STATUS État Civil	RELIGION Culte
☐ CAUCASOID Caucasique	☐ SINGLE Célibataire	☐ DIVORCED Divorcé
☐ NEGROID Negroide	☐ MARRIED Marié	☐ SEPARATED Séparé
☒ OTHER (Specify) Autre (Spécifier) Other	☐ WIDOWED Veuf	☐ PROTESTANT Protestant ☐ CATHOLIC Catholique ☐ JEWISH Juif ☐ OTHER (Specify) Autre (Spécifier)

NAME OF NEXT OF KIN Nom du plus proche parent	RELATIONSHIP TO DECEASED Parenté du décédé avec le susdit
STREET ADDRESS Domicile à (Rue)	CITY OR TOWN AND STATE *(Include ZIP Code)* Ville (Code postal compris)

MEDICAL STATEMENT Déclaration médicale

CAUSE OF DEATH *(Enter only one cause per line)* Cause du décès (N'indiquer qu'une cause par ligne)			INTERVAL BETWEEN ONSET AND DEATH Intervalle entre l'attaque et le décès
DISEASE OR CONDITION DIRECTLY LEADING TO DEATH[1] Maladie ou condition directement responsable de la mort[1]		Gunshot wound of the chest	
ANTECEDENT CAUSES Symptômes précurseurs de la mort.	MORBID CONDITION, IF ANY, LEADING TO PRIMARY CAUSE Condition morbide, s'il y a lieu, menant à la cause primaire		
	UNDERLYING CAUSE, IF ANY, GIVING RISE TO PRIMARY CAUSE Raison fondamentale, s'il y a lieu, ayant suscité la cause primaire		
OTHER SIGNIFICANT CONDITIONS[2] Autres conditions significatives[2]			

MODE OF DEATH Condition de décès	AUTOPSY PERFORMED Autopsie effectuée	CIRCUMSTANCES SURROUNDING DEATH DUE TO EXTERNAL CAUSES Circonstances de la mort suscitées par des causes extérieures
☐ NATURAL Mort naturelle	☑ YES Oui ☐ NO Non	
☐ ACCIDENT Mort accidentelle	MAJOR FINDINGS OF AUTOPSY Conclusions principales de l'autopsie	
☐ SUICIDE Suicide	NAME OF PATHOLOGIST Nom du pathologiste (b)(6)	
☒ HOMICIDE Homicide	(b)(6) DATE Date 05 Feb 2005	AVIATION ACCIDENT Accident à Avion ☐ YES Oui ☑ NO Non

DATE OF DEATH *(Hour, day, month, year)* Date de décès *(l'heure, le jour, le mois, l'année)*	PLACE OF DEATH Lieu de décès
(b)(6) 2005	Iraq

I HAVE VIEWED THE REMAINS OF THE DECEASED AND DEATH OCCURRED AT THE TIME INDICATED AND FROM THE CAUSES AS STATED ABOVE.
J'ai examiné les restes mortels du dé funt et je conclus que le décès est survenu à l'heure indiquée et à, la suite des causes énumérées ci-dessus.

NAME OF MEDICAL OFFICER Nom du médicin militaire ou du médicin sanitaire	TITLE OR DEGREE Titre ou diplômé
(b)(6)	Medical Examiner

GRADE Grade	INSTALLATION OR ADDRESS Installation ou adresse
(b)(6)	Dover AFB DE 19902
DATE Date 29 Mar 05	(b)(6)

[1] State disease, injury or complication which caused death. Do not enter mode of dying, such as cardiac arrest, respiratory arrest, shock or heart failure.
[2] State conditions contributing to the death, but not related to the disease or condition causing death.
[1] Préciser la nature de la maladie, de la blessure ou de la complication qui a contribué à la mort, mais non la manière de mourir, telle qu'un arrêt du coeur, etc
[2] Préciser la condition qui a contribué à la mort, mais n'ayant aucun rapport avec la maladie ou à la condition qui a provoqué la mort.

DD FORM 1 APR 77 **2064** REPLACES DA FORM 3565, 1 JAN 72 AND DA FORM 3565-R(PAS), 26 SEP 75, WHICH ARE OBSOLETE.

ACLU Detainee DeathII ARMY MEDCOM 396

(REMOVE, REVERSE AND RE-INSERT CARBONS BEFORE COMPLETING THIS SIDE)

DISPOSITION OF REMAINS			
NAME OF MORTICIAN PREPARING REMAINS	GRADE	LICENSE NUMBER AND STATE	OTHER
INSTALLATION OR ADDRESS	DATE	SIGNATURE	
NAME OF CEMETERY OR CREMATORY	LOCATION OF CEMETERY OR CREMATORY		
TYPE OF DISPOSITION	DATE OF DISPOSITION		

REGISTRATION OF VITAL STATISTICS			
REGISTRY *(Town and Country)*	DATE REGISTERED	FILE NUMBER	
		STATE	OTHER
NAME OF FUNERAL DIRECTOR	ADDRESS		
SIGNATURE OF AUTHORIZED INDIVIDUAL			

DD FORM 2064, APR 1977 (BACK) USAPA V1.00

ACLU Detainee DeathII ARMY MEDCOM 397

ARMED FORCES INSTITUTE OF PATHOLOGY
Office of the Armed Forces Medical Examiner
1413 Research Blvd., Bldg. 102
Rockville, MD 20850
1-800-944-7912

AUTOPSY EXAMINATION REPORT

Name: Mousa Al Jbori, Mahmood Ismaeel Mosa
Interment Serial Number: (b)(6)
Date of Birth: (b)(6) 1967
Date of Death: (b)(6) 2005
Date of Autopsy: 5 February 2005
Date of Report: 14 March 2005

Autopsy No.: (b)(6)
AFIP No.: (b)(6)
Rank: Iraqi national, civilian
Place of Death: Bucca, Iraq
Place of Autopsy: Baghdad, Iraq

Circumstances of Death: This 38 year-old male civilian, presumed Iraqi national was in US custody at the Bucca detention facility in Iraq. By report, he was shot during a prison riot.

Authorization for Autopsy: The Armed Forces Medical Examiner, IAW 10 USC 1471.

Identification: Visual, per detention facility records; postmortem fingerprints and DNA profile obtained.

CAUSE OF DEATH: Gunshot Wound of the Torso

MANNER OF DEATH: Homicide

ACLU Detainee DeathII ARMY MEDCOM 398

FINAL AUTOPSY DIAGNOSES:

I. Penetrating Gunshot Wound of the Torso
   a. Indeterminate range entrance wound of posterior aspect (back) of left shoulder with no surrounding soot or stippling
   b. Wound path through skin and soft tissue of the upper left back, the left scapula, posterior aspect of the left chest wall through the 4th rib, left lower lung lobe, diaphragm, liver and stomach
   c. Wound associated with bilateral hemothoraces, 300 ml blood in the right pleural space and 1,000 ml blood in the left pleural space; hemopericardium, 100 ml blood; hemoperitoneum, 500 ml blood; fracture of the left scapula; fracture of the posterior lateral aspect of the left 4th rib; perforation of the left lower lung lobe and left hemidiaphragm; disruption of the left lobe of the liver; and multiple perforations of the stomach
   d. No exit wound present
   e. Multiple metallic fragments including a fragment of copper jacket and fragments of bullet core are recovered from within the stomach and submitted to US Army CID
   f. No evidence of close range fire on the skin
   g. Direction of wound path: Back to front, downward, and slightly left to right

II. No evidence of significant natural disease, within the limitations of the examination

III. No evidence of other significant injuries
   a. Minor abrasions of anterior aspect of left knee
   b. Minor contusion of back of left knee

IV. No evidence of restraint

V. Toxicology (AFIP)
   a. Volatiles: Blood and vitreous fluid negative for ethanol
   b. Drugs: Blood negative for screened medications and drugs of abuse

ACLU Detainee DeathII ARMY MEDCOM 399

EXTERNAL EXAMINATION

The body is that of a well-developed, well-nourished unclad Caucasian male. The body weighs approximately 160 pounds (estimated), is 68" in height and appears compatible with the reported age of 38 years. The body temperature is cold, that of the refrigeration unit. Rigor is present to an equal degree in all extremities. Lividity is present and fixed on the posterior surface of the body, except in areas exposed to pressure.

The scalp is covered with dark brown hair averaging 1.5 cm in length. Facial hair consists of a red brown beard and mustache. The irides are brown, and the corneae are slightly cloudy. The sclerae and conjunctivae are pale and free of petechiae. There are multiple freckles over the forehead. The earlobes are not pierced. The external auditory canals, external nares and oral cavity are free of foreign material and abnormal secretions. The nasal skeleton is palpably intact. The lips are without evident injury. The teeth are natural and in fair condition.

The neck is straight and the trachea is midline and mobile. The chest is symmetric and well developed. No injury of the ribs or sternum is evident externally. The abdomen is flat and soft. Healed surgical scars are not noted on the torso. The extremities are well developed with normal range of motion. There is a 1 x 0.3 cm scar on the right knee, and there is a 1 x 2 cm tan macule on the anterior aspect of the right thigh. The fingernails are intact. The soles of the feet are calloused, but they are clean and atraumatic. No tattoos are noted, and needle tracks are not observed. The external genitalia are those of a normal adult circumcised male. The testes are descended and free of masses. The pubic hair is shaved but present in a normal distribution. The buttocks and anus are unremarkable. An identification tag is on the right first toe.

EVIDENCE OF THERAPY

There is an endotracheal tube in place, and there is an intravenous catheter in the right antecubital fossa. There are two adhesive EKG tabs on the body, one on the upper anterior aspect of the right shoulder and one on the upper anterior aspect of the left shoulder. There are two adhesive defibrillator pads on the body, one on the upper anterior aspect of the right shoulder and one on the anterior lateral aspect of the left side of the chest. There is a "C" written on the back of the right hand in green ink.

EVIDENCE OF INJURY

The ordering of the following injuries is for descriptive purposes only and is not intended to imply order of infliction or relative severity. All wound pathways are given relative to standard anatomic position.

There is dried blood streaking on the back of the hands and confluent over the back of the body. The palms of the hands are free of blood. There are two abrasions, 0.2 cm in diameter and 1 x 0.2 cm on the left knee. There is a 3 x 2 cm faint purple contusion on the back of the left knee.

ACLU Detainee DeathII ARMY MEDCOM 400

Gunshot Wound of the Torso

There is an indeterminate range entrance gunshot wound of the posterior aspect of the left shoulder. The wound is round, 0.3 cm in diameter, with an eccentric marginal abrasion rim from 10 o'clock to 2 o'clock with a maximum width of 0.3 cm at the 12 o'clock position. The entrance wound is located 14 cm to the left of posterior midline and 28 cm beneath the top of the head, and there is no soot or stippling surrounding the wound.

The wound path perforates the skin and soft tissue of the upper left back and the left scapula, and enters the posterior aspect of the left chest cavity through the posterior lateral aspect of the 4th left rib. The wound perforates the left lower lung lobe, the left hemidiaphragm, the liver, and stomach.

The wound is associated with bilateral hemothoraces with 300 ml of blood in the right pleural cavity and 1,000 ml of blood in the left pleural cavity; a hemopericardium with 100 ml blood in the pericardial sac; and a hemoperitoneum with 500 ml of blood in the abdominal cavity. The wound is also associated with fractures of the left scapula and posterior lateral aspect of the left 4th rib, parenchymal defects of the left lower lung lobe and the left lobe of the liver; perforation of the diaphragm; multiple perforations of the stomach; and hemorrhage and soft tissue destruction along the wound path.

A fragment of copper jacket and multiple small metallic fragments of bullet core are recovered from within the stomach. No exit wound is present, and there is no evidence of close range fire on the skin. The direction of the wound path is from back to front, left to right, and downward.

INTERNAL EXAMINATION

BODY CAVITIES:
The body is opened by the usual thoraco-abdominal incision and the chest plate is removed. No adhesions are present in any of the body cavities. All body organs are present in the normal anatomical position. The vertebral bodies are visibly and palpably intact. The subcutaneous fat layer of the abdominal wall is 2 cm thick.

HEAD: (CENTRAL NERVOUS SYSTEM)
The scalp is reflected, and there is no skull fractures found. The calvarium of the skull is removed. The dura mater and falx cerebri are intact. There is no epidural or subdural hemorrhage present. The leptomeninges are thin and delicate. The cerebrospinal fluid is clear. The cerebral hemispheres are symmetrical. The structures at the base of the brain, including cranial nerves and blood vessels, are intact. Coronal sections through the cerebral hemispheres reveal no lesions, and there is no evidence of infection, tumor, or trauma. The ventricles are of normal size. Transverse sections through the brain stem and cerebellum are unremarkable. The dura is stripped from the basilar skull, and no fractures are found. The atlanto-occipital joint is stable. The brain weighs 1480 grams.

ACLU Detainee DeathII ARMY MEDCOM 401

NECK:
Examination of the soft tissues of the neck, including strap muscles, thyroid gland and large vessels, reveals no abnormalities. The anterior strap muscles of the neck are homogeneous and red-brown, without hemorrhage. The thyroid cartilage and hyoid bone are intact. The larynx is lined by intact white mucosa and is unobstructed. The thyroid gland is symmetric and red-brown, without cystic or nodular change. There is no evidence of infection, tumor, or trauma, and the airway is patent.

CARDIOVASCULAR SYSTEM:
The pericardial surfaces are smooth, glistening and unremarkable; the pericardial sac is free of significant fluid and adhesions. A moderate amount of epicardial fat is present. The coronary arteries arise normally, follow a right dominant distribution and are widely patent, without evidence of significant atherosclerosis or thrombosis. The chambers and valves exhibit the usual size-position relationship and are unremarkable. The myocardium is dark red-brown, firm and unremarkable; the atrial and ventricular septa are intact. The left ventricle is 1.1 cm in thickness and the right ventricle is 0.2 cm in thickness. The aorta and its major branches arise normally, follow the usual course and are widely patent, free of significant atherosclerosis and other abnormality. The venae cavae and their major tributaries return to the heart in the usual distribution and are free of thrombi. The heart weighs 278 grams.

RESPIRATORY SYSTEM:
The upper airway is clear of debris and foreign material; the mucosal surfaces are smooth, yellow-tan and unremarkable. The pleural surfaces are smooth, glistening and unremarkable bilaterally. The pulmonary parenchyma is red-purple, exuding a slight amount of bloody fluid. The injuries of the left lower lung lobe are as previously described. No other focal lesions are noted. The pulmonary arteries are normally developed, patent and without thrombus or embolus. The right lung weighs 383 grams; the left 237 grams.

LIVER & BILIARY SYSTEM:
The injuries of the liver are as previously described. The hepatic capsule is otherwise smooth, glistening and intact, covering dark red-brown, moderately congested parenchyma with no focal lesions noted. The gallbladder contains 3 ml of green-brown, mucoid bile; the mucosa is velvety and unremarkable. The extrahepatic biliary tree is patent, without evidence of calculi. The liver weighs 1169 grams.

ALIMENTARY TRACT:
The tongue is free of bite marks, hemorrhage, or other injuries. The esophagus is lined by gray-white, smooth mucosa. The injuries of the stomach are as previously described. The gastric mucosa is otherwise arranged in the usual rugal folds and the lumen contains a film of tan fluid. The small and large bowel are unremarkable. The pancreas has a normal pink-tan lobulated appearance and the ducts are clear. The appendix is present and is unremarkable.

ACLU Detainee DeathII ARMY MEDCOM 402

GENITOURINARY SYSTEM:
The renal capsules are smooth and thin, semi-transparent and strip with ease from the underlying smooth, red-brown cortical surfaces. The cortices are sharply delineated from the medullary pyramids, which are red-purple to tan and unremarkable. The calyces, pelves and ureters are unremarkable. White bladder mucosa overlies an intact bladder wall. The urinary bladder contains 60 ml of clear, yellow urine. The prostate gland is normal in size, with lobular, yellow-tan parenchyma. The seminal vesicles are unremarkable. The testes are free of mass lesions, contusions, or other abnormalities. The right kidney weighs 117 grams; the left 119 grams.

RETICULOENDOTHELIAL SYSTEM:
The spleen has a smooth, intact capsule covering red-purple, moderately firm parenchyma; the lymphoid follicles are unremarkable. The regional lymph nodes appear normal. The spleen weighs 59 grams.

ENDOCRINE SYSTEM:
The pituitary, thyroid and adrenal glands are unremarkable.

MUSCULOSKELETAL SYSTEM:
Muscle development is normal. No bone or joint abnormalities are noted.

MICROSCOPIC EXAMINATION

Selected portions of organs are retained in formalin, without preparation of histologic slides.

ADDITIONAL PROCEDURES

- Full body radiographs were obtained and reflect the injuries described above.
- Documentary photographs are taken by OAFME photographers
- Metallic fragments recovered are submitted to US Army CID
- Specimens retained for toxicologic testing and/or DNA identification are: vitreous fluid, femoral blood, heart blood, left chest cavity blood, urine, bile, liver and spleen
- The dissected organs are forwarded with the body
- Personal effects are released to the appropriate mortuary operations representative

ACLU Detainee DeathII ARMY MEDCOM 403

OPINION

This 38 year-old male Iraqi civilian in US custody died of a gunshot wound of the torso, which perforated his left lower lung and liver, causing internal bleeding. By report, he was shot during a prison riot at the Bucca detention facility.

The manner of death is homicide.

(b)(6)

(b)(6) Medical Examiner

ACLU Detainee DeathII ARMY MEDCOM 404

DEPARTMENT OF DEFENSE
ARMED FORCES INSTITUTE OF PATHOLOGY
WASHINGTON, DC 20306-6000

REPLY TO
ATTENTION OF

AFIP-(b)(6)

TO:

OFFICE OF THE ARMED FORCES MEDICAL EXAMINER
ARMED FORCES INSTITUTE OF PATHOLOGY
WASHINGTON, DC 20306-6000

PATIENT IDENTIFICATION
AFIP Accessions Number Sequence
(b)(6)
Name
MOUSA/AL JBORI, MAHMOOD I.
SSAN: **Autopsy:** (b)(6)
Toxicology Accession #: (b)(6)
Date Report Generated: February 24, 2005

CONSULTATION REPORT ON CONTRIBUTOR MATERIAL

AFIP DIAGNOSIS **REPORT OF TOXICOLOGICAL EXAMINATION**

Condition of Specimens: GOOD
Date of Incident (b)(6) 2005 **Date Received:** 2/16/2005

VOLATILES: The **BLOOD AND VITREOUS FLUID** were examined for the presence of ethanol at a cutoff of 20 mg/dL. No ethanol was detected.

DRUGS: The **BLOOD** was screened for amphetamine, antidepressants, antihistamines, barbiturates, benzodiazepines, cannabinoids, chloroquine, cocaine, dextromethorphan, lidocaine, narcotic analgesics, opiates, phencyclidine, phenothiazines, sympathomimetic amines and verapamil by gas chromatography, color test or immunoassay. The following drugs were detected:

None were found.

(b)(6)
Office of the Armed Forces Medical Examiner

(b)(6)
Office of the Armed Forces Medical Examiner

ACLU Detainee DeathII ARMY MEDCOM 405

05-0122

CERTIFICATE OF DEATH *(OVERSEAS)*
Acte de décès *(D'Outre-Mer)*

NAME OF DECEASED *(Last, First, Middle)* *Nom du décédé (Nom et prénoms)*	GRADE Grade	BRANCH OF SERVICE Arme	SOCIAL SECURITY NUMBER Numéro de l'Assurance Sociale
BTB Mousa Al Jbori, Mahmood, Ismaeel Mosa		Iraqi Detainee	(b)(6)

ORGANIZATION Organisation	NATION *(e.g., United States)* Pays	DATE OF BIRTH Date de naissance	SEX Sexe
	Iraq	(b)(6) 1967	☑ MALE Masculin ☐ FEMALE Féminin

RACE Race	MARITAL STATUS Etat Civil	RELIGION Culte
☐ CAUCASOID Caucasique	☐ SINGLE Célibataire	☐ DIVORCED Divorcé
☐ NEGROID Negroide	☐ MARRIED Marié	☐ SEPARATED Séparé
☒ OTHER (Specify) Autre (Spécifier) Other	☐ WIDOWED Veuf	☐ PROTESTANT Protestant ☐ CATHOLIC Catholique ☐ JEWISH Juif ☒ OTHER (Specify) Autre (Spécifier) Sunni-Islam

NAME OF NEXT OF KIN Nom du plus proche parent	RELATIONSHIP TO DECEASED Parenté du décédé avec le susdit
STREET ADDRESS Domicile à (Rue)	CITY OR TOWN AND STATE *(Include ZIP Code)* *Ville (Code postal compris)*

MEDICAL STATEMENT Déclaration médicale

CAUSE OF DEATH *(Enter only once cause per line)* Cause du décès (N'indiquer qu'une cause par ligne)		INTERVAL BETWEEN ONSET AND DEATH Intervalle entre l'attaque et le décès
DISEASE OR CONDITION DIRECTLY LEADING TO DEATH[1] Maladie ou condition directement responsable de la mort[1]	Gunshot wound of the torso	
ANTECEDENT CAUSES Symptômes précurseurs de la mort. — MORBID CONDITION, IF ANY, LEADING TO PRIMARY CAUSE Condition morbide, s'il y a lieu, menant à la cause primaire		
ANTECEDENT CAUSES Symptômes précurseurs de la mort. — UNDERLYING CAUSE, IF ANY, GIVING RISE TO PRIMARY CAUSE Raison fondamentale, s'il y a lieu, ayant suscité la cause primaire		
OTHER SIGNIFICANT CONDITIONS[2] Autres conditions significatives[2]		

MODE OF DEATH Condition de décès	AUTOPSY PERFORMED Autopsie effectuée ☑ YES Oui ☐ NO Non	CIRCUMSTANCES SURROUNDING DEATH DUE TO EXTERNAL CAUSES Circonstances de la mort suscitées par des causes extérieures
☐ NATURAL Mort naturelle	MAJOR FINDINGS OF AUTOPSY Conclusions principales de l'autopsie	
☐ ACCIDENT Mort accidentelle		
☐ SUICIDE Suicide	NAME OF PATHOLOGIST Nom du pathologiste (b)(6)	
☒ HOMICIDE Homicide	SIGNATURE Signature (b)(6) — DATE Date 05 Feb 2005	AVIATION ACCIDENT Accident à Avion ☐ YES Oui ☑ NO Non

DATE OF DEATH *(Hour, day, month, year)* Date du décès *(Heure, le jour, le mois, l'année)*	PLACE OF DEATH Lieu de décès
(b)(6) 2005	Iraq

I HAVE VIEWED THE REMAINS OF THE DECEASED AND DEATH OCCURRED AT THE TIME INDICATED AND FROM THE CAUSES AS STATED ABOVE.
J'ai examiné les restes mortels du dé lunter je conclus que le décès est survenu à l'heure indiquée et à, la suite des causes énumérées ci-dessus.

NAME OF MEDICAL OFFICER Nom du médecin militaire ou du médecin sanitaire	TITLE OR DEGREE Titre ou diplôme
(b)(6)	Medical Examiner

GRADE Grade	INSTALLATION OR ADDRESS Installation ou adresse
(b)(6)	Dover AFB, DE 19902
DATE Date 27 March 05	SIGNATURE (b)(6)

[1] State disease, injury or complication which caused death, but not mode or type of dying, such as heart failure, etc.
[2] State conditions contributing to the death, but not related to the disease or condition causing death.
[1] Préciser la nature de la maladie, de la blessure ou de la complication qui a contribué à la mort, mais non la manière de mourir, telle qu'un arrêt du coeur, etc.
[2] Préciser la condition qui a contribué à la mort, mais n'ayant aucun rapport avec la maladie ou à la condition qui a provoqué la mort.

DD FORM 1 APR 77 2064 REPLACES DA FORM 3565, 1 JAN 72 AND DA FORM 3565-R(PAD), 26 SEP 75, WHICH ARE OBSOLETE.

(REMOVE, REVERSE AND RE-INSERT CARBONS BEFORE COMPLETING THIS SIDE)

DISPOSITION OF REMAINS			
NAME OF MORTICIAN PREPARING REMAINS	GRADE	LICENSE NUMBER AND STATE	OTHER
INSTALLATION OR ADDRESS	DATE	SIGNATURE	
NAME OF CEMETERY OR CREMATORY	LOCATION OF CEMETERY OR CREMATORY		
TYPE OF DISPOSITION	DATE OF DISPOSITION		

REGISTRATION OF VITAL STATISTICS			
REGISTRY *(Town and Country)*	DATE REGISTERED	FILE NUMBER	
		STATE	OTHER
NAME OF FUNERAL DIRECTOR	ADDRESS		
SIGNATURE OF AUTHORIZED INDIVIDUAL			

DD FORM 2064, APR 1977 (BACK) **USAPA V1.00**

ACLU Detainee DeathII ARMY MEDCOM 407

ARMED FORCES INSTITUTE OF PATHOLOGY
Office of the Armed Forces Medical Examiner
1413 Research Blvd., Bldg. 102
Rockville, MD 20850
1-800-944-7912

AUTOPSY EXAMINATION REPORT

Name: Hamed Al Mu Farji, Khaleed Yassen Hamad
Intermernt Serial Number (b)(6)
Date of Birth: (b)(6) 1969
Date of Death (b)(6) 2005
Date of Autopsy: 5 February 2005
Date of Report: 14 March 2005

Autopsy No. (b)(6)
AFIP No. (b)(6)
Rank: Iraqi national, civilian
Place of Death: Bucca, Iraq
Place of Autopsy: Baghdad, Iraq

Circumstances of Death: This 36 year-old male civilian, presumed Iraqi national was in US custody at the Bucca detention facility in Iraq. By report, he was shot during a prison riot.

Authorization for Autopsy: The Armed Forces Medical Examiner, IAW 10 USC 1471.

Identification: Visual, per detention facility records; postmortem fingerprints and DNA profile obtained.

CAUSE OF DEATH: Gunshot Wound of the Head

MANNER OF DEATH: Homicide

ACLU Detainee DeathII ARMY MEDCOM 408

FINAL AUTOPSY DIAGNOSES:

I. Perforating Gunshot Wound of the Head
   a. Indeterminate range entrance wound of posterior aspect (back) of the head just below the hairline at posterior midline with no surrounding soot or stippling
   b. Wound path through skin and soft tissue of the lower occipital scalp at the superior base of the neck, the second cervical vertebra and spinal cord, nasopharynx and bridge of nose
   c. Wound associated with fractures of the second cervical vertebra, transection of the cervical spinal cord at the level of the second cervical vertebra, subarachnoid hemorrhage over the brain, and fractures of the nasal, ethmoid and maxillary bones
   d. Stellate exit wound present at the bridge of the nose
   e. No metallic projectiles recovered or evident radiographically
   f. No evidence of close range fire on the skin
   g. Direction of wound path: Back to front and upward

II. No evidence of significant natural disease, within the limitations of the examination

III. No evidence of other significant injuries
   a. Minor abrasions of forehead

IV. No evidence of restraint

V. Toxicology (AFIP)
   a. Volatiles: Heart blood and vitreous fluid negative for ethanol
   b. Drugs: Heart blood negative for screened medications and drugs of abuse

ACLU Detainee DeathII ARMY MEDCOM 409

EXTERNAL EXAMINATION

The body is that of a well-developed, well-nourished unclad Caucasian male. The body weighs approximately 160 pounds (estimated), is 69" in height and appears compatible with the reported age of 36 years. The body temperature is cold, that of the refrigeration unit. Rigor is present to an equal degree in all extremities. Lividity is present and fixed on the posterior surface of the body, except in areas exposed to pressure.

The scalp is covered with dark brown hair averaging 2 cm in length. Facial hair consists of a brown with grey beard and mustache. The irides are brown, and the corneae are slightly cloudy. The sclerae and conjunctivae are pale and free of petechiae. The earlobes are not pierced. The external auditory canals and oral cavity are free of foreign material and abnormal secretions. The lips are without evident injury. The teeth are natural and in fair condition.

The neck is straight and the trachea is midline and mobile. The chest is symmetric and well developed. No injury of the ribs or sternum is evident externally. The abdomen is flat and soft. Healed surgical scars are not noted on the torso. The extremities are well developed with normal range of motion. There is a 4 cm linear scar on the upper right shin, and there is a 5 cm linear scar on the back of the right calf. The fingernails are intact. The soles of the feet are calloused. No tattoos are noted, and needle tracks are not observed. The external genitalia are those of a normal adult circumcised male. The testes are descended and free of masses. The pubic hair is present in a normal distribution. The buttocks and anus are unremarkable. An identification tag is on the right first toe.

EVIDENCE OF THERAPY

There is an oropharyngeal airway in place, and there is an intravenous catheter in the left antecubital fossa. There is an "A" written on the back of the left hand in green ink.

EVIDENCE OF INJURY

The ordering of the following injuries is for descriptive purposes only and is not intended to imply order of infliction or relative severity. All wound pathways are given relative to standard anatomic position.

Gunshot Wound of the Head

There is an indeterminate range entrance gunshot wound of the posterior aspect of the head, just below the hairline. The wound is round, 0.2 cm in diameter, with an eccentric 0.1 cm marginal abrasion rim from the 3 o'clock to 6 o'clock position. The entrance wound is located in the posterior midline, 18 cm beneath the top of the head, and 1 cm beneath the edge of the hairline. There is no soot or stippling on the skin surrounding the wound.

ACLU Detainee DeathII ARMY MEDCOM 410

The wound path perforates the skin and soft tissue of the lower occipital scalp and upper posterior neck at the posterior midline, continues through the second cervical vertebra (axis) and cervical spinal cord, and through the nasopharynx just below the sphenoid sinus and cribiform plate, and exits through the nasal bones out the bridge of the nose directly between the eyes.

The wound is associated with fractures of the second cervical vertebra, complete transection of the cervical spinal cord at the level of the second cervical vertebra, diffuse subarachnoid hemorrhage over the brain, a film of subdural hemorrhage at the base of the brain, fractures of the maxillary, ethmoid and nasal bones, and hemorrhage and soft tissue destruction along the wound path.

There is a 3 x 3 cm stellate exit wound at the bridge of the nose, located on the anterior midline, 10 cm beneath the top of the head and directly between the eyes.

No metallic projectiles are recovered or evident radiographically, and there is no evidence of close range fire on the skin. The direction of the wound path is from back to front and upward.

INTERNAL EXAMINATION

BODY CAVITIES:
The body is opened by the usual thoraco-abdominal incision and the chest plate is removed. No adhesions or abnormal collections of fluid are present in any of the body cavities. All body organs are present in the normal anatomical position. The vertebral bodies are visibly and palpably intact. The subcutaneous fat layer of the abdominal wall is 2 cm thick.

HEAD: (CENTRAL NERVOUS SYSTEM)
The injuries of the head are as previously described. The scalp is reflected, and there are no other skull fractures found. The calvarium of the skull is removed. The dura mater and falx cerebri are intact. There is no epidural hemorrhage present. The leptomeninges are thin and delicate. The cerebral hemispheres are symmetrical. The structures at the base of the brain, including cranial nerves and blood vessels, are intact. Coronal sections through the cerebral hemispheres revealed no lesions, and there is no evidence of infection, tumor, or trauma. The ventricles are of normal size. Transverse sections through the brain stem and cerebellum are unremarkable. The dura is stripped from the basilar skull, and no fractures are found. The atlanto-occipital joint is stable. The brain weighs 1440 grams.

NECK:
Examination of the soft tissues of the anterior neck, including strap muscles, thyroid gland and large vessels, reveals no abnormalities. The anterior strap muscles of the neck are homogeneous and red-brown, without hemorrhage. The thyroid cartilage and hyoid bone are intact. The larynx is lined by intact white mucosa and is unobstructed. The thyroid gland is symmetric and red-brown, without cystic or nodular change. There is no evidence of infection, tumor, or trauma, and the airway is patent.

ACLU Detainee DeathII ARMY MEDCOM 411

CARDIOVASCULAR SYSTEM:
The pericardial surfaces are smooth, glistening and unremarkable; the pericardial sac is free of significant fluid and adhesions. A moderate amount of epicardial fat is present. The coronary arteries arise normally, follow a right dominant distribution and are widely patent, without evidence of significant atherosclerosis or thrombosis. The chambers and valves exhibit the usual size-position relationship and are unremarkable. The myocardium is dark red-brown, firm and unremarkable; the atrial and ventricular septa are intact. The left ventricle is 1.1 cm in thickness and the right ventricle is 0.2 cm in thickness. The aorta and its major branches arise normally, follow the usual course and are widely patent, free of significant atherosclerosis and other abnormality. The venae cavae and their major tributaries return to the heart in the usual distribution and are free of thrombi. The heart weighs 420 grams.

RESPIRATORY SYSTEM:
The upper airway is clear of debris and foreign material; the mucosal surfaces are smooth, yellow-tan and unremarkable. The pleural surfaces are smooth, glistening and unremarkable bilaterally. The pulmonary parenchyma is red-purple, exuding a slight amount of bloody fluid, and no focal lesions are noted. The pulmonary arteries are normally developed, patent and without thrombus or embolus. The right lung weighs 540 grams; the left 520 grams.

LIVER & BILIARY SYSTEM:
The hepatic capsule is smooth, glistening and intact, covering dark red-brown, moderately congested parenchyma with no focal lesions noted. The gallbladder contains 3 ml of green-brown, mucoid bile; the mucosa is velvety and unremarkable. The extrahepatic biliary tree is patent, without evidence of calculi. The liver weighs 1370 grams.

ALIMENTARY TRACT:
The tongue is free of bite marks, hemorrhage, or other injuries. The esophagus is lined by gray-white, smooth mucosa. The gastric mucosa is arranged in the usual rugal folds and the lumen contains approximately 500 ml of white thick liquid. The small and large bowel are unremarkable. The pancreas has a normal pink-tan lobulated appearance and the ducts are clear. The appendix is present and is unremarkable.

GENITOURINARY SYSTEM:
The renal capsules are smooth and thin, semi-transparent and strip with ease from the underlying smooth, red-brown cortical surfaces. The cortices are sharply delineated from the medullary pyramids, which are red-purple to tan and unremarkable. The calyces, pelves and ureters are unremarkable. White bladder mucosa overlies an intact bladder wall. The urinary bladder contains 15 ml of clear, yellow urine. The prostate gland is normal in size, with lobular, yellow-tan parenchyma. The seminal vesicles are unremarkable. The testes are free of mass lesions, contusions, or other abnormalities. The right kidney weighs 120 grams; the left 120 grams.

ACLU Detainee DeathII ARMY MEDCOM 412

RETICULOENDOTHELIAL SYSTEM:
The spleen has a smooth, intact capsule covering red-purple, moderately firm parenchyma; the lymphoid follicles are unremarkable. The regional lymph nodes appear normal. The spleen weighs 150 grams.

ENDOCRINE SYSTEM:
The pituitary, thyroid and adrenal glands are unremarkable.

MUSCULOSKELETAL SYSTEM:
Muscle development is normal. No bone or joint abnormalities are noted.

MICROSCOPIC EXAMINATION

Selected portions of organs are retained in formalin, without preparation of histologic slides.

ADDITIONAL PROCEDURES

- Full body radiographs were obtained and reflect the injuries described above.
- Documentary photographs are taken by OAFME photographers
- Specimens retained for toxicologic testing and/or DNA identification are: vitreous fluid, heart blood, urine, bile, liver, spleen, and gastric contents
- The dissected organs are forwarded with the body
- Personal effects are released to the appropriate mortuary operations representative

OPINION

This 36 year-old male Iraqi civilian in US custody died of a gunshot wound of the head, causing fractures of the 2nd cervical vertebra (axis) with transection of the cervical spinal cord. By report, he was shot during a prison riot at the Bucca detention facility.

The manner of death is homicide.

(b)(6)

(b)(6) Medical Examiner

ACLU Detainee DeathII ARMY MEDCOM 413

DEPARTMENT OF DEFENSE
ARMED FORCES INSTITUTE OF PATHOLOGY
WASHINGTON, DC 20306-6000

REPLY TO ATTENTION OF

AFIP- (b)(6)

PATIENT IDENTIFICATION
AFIP Accessions Number Sequence
(b)(6)

TO:

OFFICE OF THE ARMED FORCES MEDICAL EXAMINER
ARMED FORCES INSTITUTE OF PATHOLOGY
WASHINGTON, DC 20306-6000

Name
HAMED AL MU FARJI, KHALEED

SSAN: **Autopsy:** (b)(6)
Toxicology Accession #: (b)(6)
Date Report Generated: February 24, 2005

CONSULTATION REPORT ON CONTRIBUTOR MATERIAL

AFIP DIAGNOSIS **REPORT OF TOXICOLOGICAL EXAMINATION**

Condition of Specimens: GOOD
Date of Incident (b)(6) 2005 **Date Received:** 2/16/2005

VOLATILES: The **HEART BLOOD AND VITREOUS FLUID** were examined for the presence of ethanol at a cutoff of 20 mg/dL. No ethanol was detected.

DRUGS: The **HEART BLOOD** was screened for amphetamine, antidepressants, antihistamines, barbiturates, benzodiazepines, cannabinoids, chloroquine, cocaine, dextromethorphan, lidocaine, narcotic analgesics, opiates, phencyclidine, phenothiazines, sympathomimetic amines and verapamil by gas chromatography, color test or immunoassay. The following drugs were detected:

None were found.

(b)(6)
Office of the Armed Forces Medical Examiner

(b)(6)
Office of the Armed Forces Medical Examiner

ACLU Detainee DeathII ARMY MEDCOM 414

(b)(6)

CERTIFICATE OF DEATH (OVERSEAS)
Acte de décès (D'Outre-Mer)

NAME OF DECEASED (Last, First, Middle) Nom du décédé (Nom et prénoms)	GRADE Grade	BRANCH OF SERVICE Arme	SOCIAL SECURITY NUMBER Numéro de l'Assurance Sociale
BTB Hamed Al Mu Farji, Khaleed, Yassen Hamad		Iraqi Detainee	(b)(6)

ORGANIZATION Organisation	NATION (e.g., United States) Pays	DATE OF BIRTH Date de naissance	SEX Sexe
	Iraq	(b)(6) 1969	☑ MALE Masculin ☐ FEMALE Féminin

RACE Race		MARITAL STATUS État Civil			RELIGION Culte		
	CAUCASOID Caucasique		SINGLE Célibataire	DIVORCED Divorcé		PROTESTANT Protestant	OTHER (Specify) Autre (Spécifier)
	NEGROID Negroide		MARRIED Marié			CATHOLIC Catholique	✕ Sunni-Islam
✕	OTHER (Specify) Autre (Spécifier) Other		WIDOWED Veuf	SEPARATED Séparé		JEWISH Juif	

NAME OF NEXT OF KIN Nom du plus proche parent	RELATIONSHIP TO DECEASED Parenté du décédé avec le susdit
STREET ADDRESS Domicile à (Rue)	CITY OR TOWN AND STATE (Include ZIP Code) Ville (Code postal compris)

MEDICAL STATEMENT Déclaration médicale

CAUSE OF DEATH (Enter only once cause per line) Cause du décès (N'indiquer qu'une cause par ligne)			INTERVAL BETWEEN ONSET AND DEATH Intervalle entre l'attaque et le décès
DISEASE OR CONDITION DIRECTLY LEADING TO DEATH[1] Maladie ou condition directement responsable de la mort[1]		Gunshot wound of the head	
ANTECEDENT CAUSES Symptômes précurseurs de la mort	MORBID CONDITION, IF ANY, LEADING TO PRIMARY CAUSE Condition morbide, s'il y a lieu, menant à la cause primaire		
	UNDERLYING CAUSE, IF ANY, GIVING RISE TO PRIMARY CAUSE Raison fondamentale, s'il y a lieu, ayant suscité la cause primaire		
OTHER SIGNIFICANT CONDITIONS[2] Autres conditions significatives[2]			

MODE OF DEATH Condition de décès	AUTOPSY PERFORMED Autopsie effectuée ☑ YES Oui ☐ NO Non	CIRCUMSTANCES SURROUNDING DEATH DUE TO EXTERNAL CAUSES Circonstances de la mort suscitées par des causes extérieures
☐ NATURAL Mort naturelle	MAJOR FINDINGS OF AUTOPSY Conclusions principales de l'autopsie	
☐ ACCIDENT Mort accidentelle		
☐ SUICIDE Suicide	NAME OF PATHOLOGIST Nom du pathologiste (b)(6)	
✕ HOMICIDE Homicide	SIGNATURE (b)(6) DATE Date 05 Feb 2005	AVIATION ACCIDENT Accident d'Avion ☐ YES Oui ☑ NO Non

DATE OF DEATH (Hour, day, month, year) Date du décès (Heure, le jour, le mois, l'année)	PLACE OF DEATH Lieu du décès
(b)(6) 2005	Iraq

I HAVE VIEWED THE REMAINS OF THE DECEASED AND DEATH OCCURRED AT THE TIME INDICATED AND FROM THE CAUSES AS STATED ABOVE.
J'ai examiné les restes mortels du dé funtet je conclus que le décès est survenu à l'heure indiquée et à la suite des causes énumérées ci-dessus.

NAME OF MEDICAL OFFICER Nom du médicin militaire ou du médicin sanitaire	TITLE OR DEGREE Titre ou diplôme
(b)(6)	Medical Examiner

GRADE Grade	INSTALLATION OR ADDRESS Installation ou adresse
(b)(6)	Dover AFB, DE 19902
DATE Date 29 March 05	SIGNATURE (b)(6)

[1] State disease, injury or complication which caused death, but not mode of dying such as heart failure, etc.
[2] State conditions contributing to the death, but not related to the disease or condition causing death.
[1] Préciser la nature de la maladie, de la blessure ou de la complication qui a contribué à la mort, mais non la manière de mourir, telle qu'un arrêt du coeur, etc.
[2] Préciser la condition qui a contribué à la mort, mais n'ayant aucun rapport avec la maladie ou à la condition qui a provoqué la mort.

DD FORM 1 APR 77 2064 REPLACES DA FORM 3565, 1 JAN 72 AND DA FORM 3565-R(PASI), 26 SEP 75, WHICH ARE OBSOLETE.

MEDCOM 0415

ACLU Detainee DeathII ARMY MEDCOM 415

(REMOVE, REVERSE AND RE-INSERT CARBONS BEFORE COMPLETING THIS SIDE)

DISPOSITION OF REMAINS			
NAME OF MORTICIAN PREPARING REMAINS	GRADE	LICENSE NUMBER AND STATE	OTHER
INSTALLATION OR ADDRESS	DATE	SIGNATURE	
NAME OF CEMETERY OR CREMATORY	LOCATION OF CEMETERY OR CREMATORY		
TYPE OF DISPOSITION		DATE OF DISPOSITION	

REGISTRATION OF VITAL STATISTICS			
REGISTRY *(Town and Country)*	DATE REGISTERED	FILE NUMBER	
		STATE	OTHER
NAME OF FUNERAL DIRECTOR	ADDRESS		
SIGNATURE OF AUTHORIZED INDIVIDUAL			

DD FORM 2064, APR 1977 (BACK) USAPA V1.00

ACLU Detainee DeathII ARMY MEDCOM 416

ARMED FORCES INSTITUTE OF PATHOLOGY
Office of the Armed Forces Medical Examiner
1413 Research Blvd., Bldg. 102
Rockville, MD 20850
1-800-944-7912

FINAL AUTOPSY REPORT

Name: Mohammed Salun, Sohaib Mansoor
Intermemt Serial Number (b)(6)
Date of Birth: (b)(6) 1973
Date of Death (b)(6) 2005
Date of Autopsy: 04 February 2005
Date of Report: 12 April 2005

Autopsy No.: (b)(6)
AFIP No.: (b)(6)
Rank: Civilian, Iraqi national
Place of Death: Bucca, Iraq
Place of Autopsy: Baghdad, Iraq

Circumstances of Death: This 32 year-old male, presumed Iraqi national, civilian detainee was found unresponsive while in US custody at the Bucca detention facility in Iraq, and resuscitation efforts were unsuccessful.

Authorization for Autopsy: Office of the Armed Forces Medical Examiner, IAW 10 USC 1471

Identification: Visual, per detention facility records; postmortem fingerprints and DNA profile obtained.

CAUSE OF DEATH: Atherosclerotic cardiovascular disease

MANNER OF DEATH: Natural

ACLU Detainee DeathII ARMY MEDCOM 417

FINAL AUTOPSY DIAGNOSES:

I. Atherosclerotic cardiovascular disease (Cardiovascular Pathology consultation)
   a. Moderate coronary artery atherosclerosis
      i. Left anterior descending artery (LAD): 40% luminal narrowing of proximal LAD by pathologic intimal thickening with smooth muscle rich intimal proliferation
      ii. Left circumflex artery (LCA): 50% narrowing of proximal LCA by proximal intimal thickening
      iii. Right coronary artery (RCA): 60% narrowing of proximal to mid RCA by pathologic intimal thickening with smooth muscle rich neotintimal proliferation
   b. Mild dysplasia of atrioventricular nodal artery with increased fibrosis in branching bundle and crest of ventricular septum
   c. Heart, 395 gm

II. Diffuse hypoxic-ischemic changes of brain
   a. Brain, 1674 gm
   b. AFIP Neuropathology consultation
      i. Shrunken eosinophilic cytoplasm and indistinct nuclei and glia with pyknotic nuclei and eosinophilic cytoplasm in cerebral cortex, basal ganglia, hippocampal formation, brainstem and cerebellum

III. No evidence of significant injury
   a. No external or internal evidence of trauma

IV. No evidence of physical restraint

V. Early decompositional changes
   a. Mold growth over face and back of neck
   b. Green discoloration of upper abdomen
   c. Focal skin slippage
   d. Focal drying of fingers
   e. Dark discoloration of internal organs, including brain
   f. Decompositional fluid in bilateral pleural cavities, 50 ml each side

VI. Toxicology (AFIP)
   a. Volatiles: Blood negative for ethanol
   b. Drugs: Heart blood negative for screened medications and drugs of abuse

ACLU Detainee DeathII ARMY MEDCOM 418

EXTERNAL EXAMINATION

The body is that of a well-developed, well-nourished Caucasian male clad in a pair of black sweat pants with a white NBA logo and a pair of white boxer shorts. The body is received on top of a grey and red blanket with multiple loose medical devices including a suction container with apparent gastric contents, a white plastic board, a facial mask, a laryngoscope and a white wire. The body weighs approximately 180 pounds (estimated), is 72" in height and appears compatible with the reported age of 32 years. The body temperature is cold, that of the refrigeration unit. Rigor has dissipated, and the body is flaccid. Lividity is present and fixed on the posterior surface of the body, except in areas exposed to pressure.

The scalp is covered with dark brown hair in a normal distribution averaging 1.5 cm in length on the top and shorter on the sides. Facial hair consists of a dark brown beard and mustache. The irides are brown. The corneae are cloudy. The sclerae and conjunctivae are pale and free of petechiae. The earlobes are not pierced. The external auditory canals, external nares and oral cavity are free of foreign material and abnormal secretions. The nasal skeleton is palpably intact. The lips are without evident injury. The teeth are natural and in fair condition.

There are early decompositional changes including the previously described corneal clouding and loss of rigor. There are also multiple patches of white and green mold growth on face and back of the neck, the majority of which wipes free easily. There is green discoloration of the upper abdomen and dark drying of the fingers and hands. There is focal skin slippage around the ankles.

The neck is straight and the trachea is midline and mobile. The chest is symmetric and well developed. No injury of the ribs or sternum is evident externally. The abdomen is flat and soft. Healed surgical scars of the torso are not noted. The extremities are well developed with normal range of motion. The fingernails are intact. The soles of the feet are calloused and hyperkeratotic. There is a 4 cm scar on the left hand at the base of the thumb, and there is a 0.5 cm pustule on the back of the left upper thigh. No tattoos are noted, and needle tracks are not observed. The external genitalia are those of a normal adult circumcised male. The testes are descended and free of masses. Pubic hair is present in a normal distribution. The buttocks and anus are unremarkable. An identification tag is attached to the first toe on the right foot.

EVIDENCE OF THERAPY

There are a total of nine adhesive EKG pads on the body; one on the right shoulder, one on the left shoulder, one on the upper right side of the chest, five on the upper left side of the chest and one on the lower left side of the abdomen. There is an intravenous catheter in the right antecubital fossa, secured with white tape, and there is a second piece of white tape on the lower aspect of the upper right arm. There is no other evidence of medical intervention.

ACLU Detainee DeathII ARMY MEDCOM 419

EVIDENCE OF INJURY

On external examination of the body and internal examination of the head, chest and abdomen, there is no evidence of injury.

INTERNAL EXAMINATION

BODY CAVITIES:
The body is opened by the usual thoraco-abdominal incision and the chest plate is removed. Other than accumulation of decompositional fluid (50 ml dark fluid each pleural cavity), the pleural, pericardial, and peritoneal cavities are unremarkable. All body organs are present in the normal anatomical position. The vertebral bodies are visibly and palpably intact. The subcutaneous fat layer of the abdominal wall is 2 cm thick. There is no internal evidence of blunt force or penetrating injury to the thoraco-abdominal region.

HEAD: (CENTRAL NERVOUS SYSTEM)
The scalp is reflected, and there is no subgaleal hemorrhage or skull fractures found. The calvarium of the skull is removed. The dura mater and falx cerebri are intact. The brain is darkly discolored from decomposition, but there is no epidural or subdural hemorrhage present. The leptomeninges are thin and delicate. The cerebrospinal fluid is slightly dark but free of blood. The cerebral hemispheres are symmetrical. The structures at the base of the brain, including cranial nerves and blood vessels, are intact. Coronal sections through the cerebral hemispheres reveales no lesions, and there is no evidence of infection, tumor, or trauma. The ventricles are of normal size. Transverse sections through the brain stem and cerebellum are unremarkable. The dura is stripped from the basilar skull, and no fractures are found. The atlanto-occipital joint is stable. The brain weighs 1674 grams.

NECK:
Examination of the soft tissues of the neck, including strap muscles, thyroid gland and large vessels, reveals no abnormalities. The anterior strap muscles of the neck are homogeneous and red-brown, without hemorrhage. The thyroid cartilage and hyoid bone are intact. The larynx is lined by intact white mucosa and is unobstructed. The thyroid gland is symmetric and red-brown, without cystic or nodular change. There is no evidence of infection, tumor, or trauma, and the airway is patent. Incision and dissection of the posterior neck demonstrates no deep paracervical muscular injury, hemorrhage, or fractures of the dorsal spinous processes.

CARDIOVASCULAR SYSTEM:
The pericardial surfaces are smooth, glistening and unremarkable; the pericardial sac is free of significant fluid and adhesions. A moderate amount of epicardial fat is present. The coronary arteries arise normally, follow a right dominant distribution and are widely patent, without evidence of significant atherosclerosis or thrombosis. The chambers and valves exhibit the usual size-position relationship and are unremarkable. The myocardium is dark red-brown and unremarkable; the atrial and ventricular septa are intact. The left ventricle is 1.0 cm in thickness and the right ventricle is 0.2 cm in thickness. The aorta and its major branches arise normally, follow the usual course and are widely patent, free of significant

ACLU Detainee DeathII ARMY MEDCOM 420

atherosclerosis and other abnormality. The venae cavae and their major tributaries return to the heart in the usual distribution and are free of thrombi. The heart weighs 395 grams.

RESPIRATORY SYSTEM:
The upper airway is clear of debris and foreign material; the mucosal surfaces are smooth, yellow-tan and unremarkable. There are pleural adhesions involving the lower left lung lobe. The pleural surfaces are otherwise smooth, glistening and unremarkable bilaterally. The pulmonary parenchyma is red-purple, exuding a slight amount of bloody fluid; no focal lesions are noted. The pulmonary arteries are normally developed, patent and without thrombus or embolus. The right lung weighs 629 grams; the left 859 grams.

LIVER & BILIARY SYSTEM:
The hepatic capsule is smooth, glistening and intact, covering dark red-brown, moderately congested parenchyma with no focal lesions noted. The gallbladder contains less than 1 ml of green-brown, mucoid bile; the mucosa is velvety and unremarkable. The extrahepatic biliary tree is patent, without evidence of calculi. The liver weighs 1936 grams.

ALIMENTARY TRACT:
The tongue is free of bite marks, hemorrhage, or other injuries. The esophagus is lined by gray-white, smooth mucosa. The gastric mucosa is arranged in the usual rugal folds and the lumen contains 200 ml of semisolid digesting material including rice and pieces of orange. There are abdominal adhesions involving the right upper quadrant. The small and large bowel are otherwise unremarkable. The pancreas has a normal pink-tan lobulated appearance and the ducts are clear. The appendix is present and is unremarkable.

GENITOURINARY SYSTEM:
The renal capsules are smooth and thin, semi-transparent and strip with ease from the underlying smooth, red-brown cortical surfaces. The cortices are sharply delineated from the medullary pyramids, which are red-purple to tan and unremarkable. The calyces, pelves and ureters are unremarkable. White bladder mucosa overlies an intact bladder wall. The urinary bladder contains 5 ml of cloudy yellow urine. The prostate gland is normal in size, with lobular, yellow-tan parenchyma. The seminal vesicles are unremarkable. The testes are free of mass lesions, contusions, or other abnormalities. The right kidney weighs 170 grams; the left 175 grams.

RETICULOENDOTHELIAL SYSTEM:
The spleen has a smooth, intact capsule covering red-purple, moderately firm parenchyma; the lymphoid follicles are unremarkable. The regional lymph nodes appear normal. The spleen weighs 322 grams.

ENDOCRINE SYSTEM:
The pituitary, thyroid and adrenal glands are unremarkable.

MUSCULOSKELETAL SYSTEM:
Muscle development is normal. No bone or joint abnormalities are noted.

ACLU Detainee DeathII ARMY MEDCOM 421

MICROSCOPIC EXAMINATION

HEART: See "Cardiovascular Pathology Report" below.

LUNGS: The alveolar spaces and small air passages show evidence of autolysis. Where well preserved, the alveoli are expanded and contain no significant inflammatory component or edema fluid. There is evidence of peri-mortem food aspiration (no inflammatory reaction). The alveolar walls are thin and not congested. The arterial and venous vascular systems are normal. The peribronchial lymphatics are unremarkable.

LIVER: The hepatic architecture is intact. The portal areas show no increased inflammatory component or fibrous tissue. The hepatic parenchymal cells are well-preserved with no evidence of cholestasis, fatty metamorphosis, or sinusoidal abnormalities.

SPLEEN: The capsule and white pulp are unremarkable. There is minimal congestion of the red pulp.

ADRENALS: The cortical zones are distinctive, and the medullae are not remarkable.

KIDNEYS: The subcapsular zones are unremarkable. The glomeruli are mildly congested without cellular proliferation, mesangial prominence, or sclerosis. The tubules show autolysis but are unremarkable. There is no interstitial fibrosis or significant inflammation. There is no thickening of the walls of the arterioles or small arterial channels. The transitional epithelium of the collecting system is normal.

BRAIN: See "Neuropathology Report" below.

THYROID: Unremarkable.

TESTES: Unremarkable.

CARDIOVASCULAR PATHOLOGY REPORT

CV Path, (b)(6)

"**DIAGNOSIS:** (b)(6) **Moderate coronary artery atherosclerosis; mild dysplasia of atrioventricular nodal artery with increased fibrosis in branching bundle and crest of ventricular septum**

History: Approximately 32 year old male Iraqi detainee found dead in cot

Heart: 395 grams normal epicardial fat; closed foramen ovale; biventricular dilatation: left ventricular cavity diameter 45 mm, left ventricular free wall thickness 9 mm, ventricular septum thickness 9 mm; right ventricle thickness 4 mm, without gross scars or abnormal fat infiltrates; multiple anomalous delicate cordae in right ventricle between

ACLU Detainee DeathII ARMY MEDCOM 422

papillary muscles and free wall; fenestrated non-coronary cusp of aortic valve; other valves unremarkable; early myocardial decomposition, otherwise unremarkable; histologic sections show unremarkable myocardium

Coronary arteries: Normal ostia; right dominance; moderate atherosclerosis:
Left anterior descending artery (LAD): 40% luminal narrowing of proximal LAD by pathologic intimal thickening with smooth muscle rich intimal proliferation
Left circumflex artery (LCA): 50% narrowing of proximal LCA by pathologic intimal thickening
Right coronary artery (RCA): 60% narrowing of proximal to mid RCA by pathologic intimal thickening with smooth muscle rich neointimal proliferation

Conduction system: The sinoatrtial node and sinus nodal artery are histologically unremarkable. The compact atrioventricular (AV) node shows right downward displacement, and mildly increased fat and vascularity. The AV nodal artery is mildly dysplastic with predominantly medial thickening and adventitial fibrosis. Focal subendocaridal and perivascular interstitial fibrosis is present in the crest of the ventricular septum. The penetrating bundle is centrally located in the fibrous body and exhibits increased proteoglycan and decreased cellular components without inflammation. There are no discernible increased proteoglycan and fibrosis. The proximal bundle branches are intact and also demonstrate increased proteoglycan and decreased cellular components without inflammation. There are no discernable bypass tracts between the AV node and ventricular septum.

Comment: Histologic examination is suboptimal due to post-mortem decomposition; however, the dyplastic AV nodal artery and fibrosis in the branching bundle and crest of ventricular septum are not artifactual. Although the histologic findings would be more likely to produce bundle branch block, similar changes have been described in association with sudden cardiac death, likely due to ventricular arrhythmia. The etiology of the fibrosis is unclear, possibly due to small vessel narrowing or a resolved prior inflammatory condition."

NEUROPATHOLOGY REPORT

Department of Neuropathology and Ophthalmic Pathology, AFIP:

"We examined the multiple portions of fixed brain-tissue, measuring 20 x 15 x 2 cm in aggregate, submitted in reference to this case. This includes fragments consistent with cerebrum, cerebellum, brainstem and dura. No gross lesions are identified.

Histological sections submitted: 1. Cerebral cortex. 2. Medulla. 3. Medulla/uppermost cervical spinal cord. 4. Cerebellum. 5. Pons. 6. Cerebellum, dentate nucleus. 8. Basal ganglia. 9. Hippocampal area. 10. Dura.

ACLU Detainee DeathII ARMY MEDCOM 423

All sections were processed in paraffin; histological slides were stained with H & E. This material was reviewed in conference by staff in the Department of Neuropathology and Ophthalmic Pathology.

Histologic sections show neurons with shrunken eosinophilic cytoplasm and indistinct nuclei, and glia with pyknotic nuclei and eosinophilic cytoplasm, in cerebral cortex, basal ganglia, hippocampal formatin, brainstem and cerebellum. These cellular features are consistent with diffuse hypoxic-ischemic changes. The dura shows no diagnostic histologic changes."

ADDITIONAL PROCEDURES

- Documentary photographs are taken by OAFME photographers
- Specimens retained for toxicologic testing and/or DNA identification are: vitreous fluid, femoral blood, heart blood, urine, bile, spleen, liver, and gastric contents
- The dissected organs are forwarded with the body
- Personal effects are released to the appropriate mortuary operations representative

OPINION

This 32 year-old male Iraqi detainee died in US custody of atherosclerotic cardiovascular disease, with moderate coronary artery atherosclerosis (three vessel disease) and mild dysplasia of the atrioventricular nodal artery with increased fibrosis in the branching bundle and crest of the ventricular septum. Fibrosis within the heart, particularly around the conduction system may initiate cardiac arrhythmias. There is no evidence of any external or internal trauma or evidence of physical restraint. No other significant natural disease within the limitations of the autopsy was found, and toxicologic studies are negative.

The manner of death is natural.

(b)(6)

(b)(6) Medical Examiner

ACLU Detainee DeathII ARMY MEDCOM 424

DEPARTMENT OF DEFENSE
ARMED FORCES INSTITUTE OF PATHOLOGY
WASHINGTON, DC 20306-6000

REPLY TO ATTENTION OF

AFIP (b)(6)

PATIENT IDENTIFICATION
AFIP Accessions Number Sequence
(b)(6)

TO:

OFFICE OF THE ARMED FORCES MEDICAL EXAMINER
ARMED FORCES INSTITUTE OF PATHOLOGY
WASHINGTON, DC 20306-6000

Name
MOHAMMED SALAM, SOHAIB MANSOR

SSAN: **Autopsy:** (b)(6)
Toxicology Accession #: (b)(6)
Date Report Generated: February 27, 2005

CONSULTATION REPORT ON CONTRIBUTOR MATERIAL

AFIP DIAGNOSIS **REPORT OF TOXICOLOGICAL EXAMINATION**

Condition of Specimens: GOOD
Date of Inciden (b)(6) 2005 **Date Received:** 2/16/2005

VOLATILES: The **BLOOD** was examined for the presence of ethanol at a cutoff of 20 mg/dL. No ethanol was detected.

DRUGS: The **HEART BLOOD** was screened for amphetamine, antidepressants, antihistamines, barbiturates, benzodiazepines, cannabinoids, chloroquine, cocaine, dextromethorphan, lidocaine, narcotic analgesics, opiates, phencyclidine, phenothiazines, sympathomimetic amines and verapamil by gas chromatography, color test or immunoassay. The following drugs were detected:

None were found.

(b)(6)
Office of the Armed Forces Medical Examiner

(b)(6)
Office of the Armed Forces Medical Examiner

ACLU Detainee DeathII ARMY MEDCOM 425

(b)(6)

CERTIFICATE OF DEATH *(OVERSEAS)*
Acte de décès *(D'Outre-Mer)*

NAME OF DECEASED *(Last, First, Middle)* *Nom du décédé (Nom et prénoms)*	GRADE Grade	BRANCH OF SERVICE Arme	SOCIAL SECURITY NUMBER Numéro de l'Assurance Sociale
BTB Mohammed Salun, Sohaib, Mansoor		Iraqi Detainee	(b)(6)

ORGANIZATION Organisation	NATION *(e.g., United States)* Pays	DATE OF BIRTH Date de naissance	SEX Sexe
	Iraq (b)(6)	1973	☑ MALE Masculin ☐ FEMALE Féminin

RACE Race	MARITAL STATUS État Civil	RELIGION Culte
☐ CAUCASOID Caucasique	☐ SINGLE Célibataire	☐ PROTESTANT Protestant
☐ NEGROID Negroide	☐ MARRIED Marié	☐ CATHOLIC Catholique
☒ OTHER (Specify) Autre (Spécifier) Other	☐ WIDOWED Veuf	☐ JEWISH Juif
	☐ DIVORCED Divorcé	☐ OTHER (Specify) Autre (Spécifier)
	☐ SEPARATED Séparé	

NAME OF NEXT OF KIN Nom du plus proche parent	RELATIONSHIP TO DECEASED Parenté du décédé avec le susdit
STREET ADDRESS Domicile à (Rue)	CITY OR TOWN AND STATE *(Include ZIP Code)* *Ville (Code postal compris)*

MEDICAL STATEMENT Déclaration médicale

	CAUSE OF DEATH *(Enter only once cause per line)* Cause du décès (N'indiquer qu'une cause par ligne)	INTERVAL BETWEEN ONSET AND DEATH Intervalle entre l'attaque et le décès
DISEASE OR CONDITION DIRECTLY LEADING TO DEATH[1] Maladie ou condition directement responsable de la mort[1]	Pending	
ANTECEDENT CAUSES — MORBID CONDITION, IF ANY, LEADING TO PRIMARY CAUSE Condition morbide, s'il y a lieu, menant à la cause primaire		
Symptômes précurseurs de la mort — UNDERLYING CAUSE, IF ANY, GIVING RISE TO PRIMARY CAUSE Raison fondamentale, s'il y a lieu, ayant suscité la cause primaire		
OTHER SIGNIFICANT CONDITIONS[2] Autres conditions significatives[2]		

MODE OF DEATH Condition de décès: ☐ NATURAL Mort naturelle ☐ ACCIDENT Mort accidentelle ☐ SUICIDE Suicide ☐ HOMICIDE Homicide

AUTOPSY PERFORMED Autopsie effectuée ☑ YES Oui ☐ NO Non

MAJOR FINDINGS OF AUTOPSY Conclusions principales de l'autopsie

CIRCUMSTANCES SURROUNDING DEATH DUE TO EXTERNAL CAUSES Circonstances de la mort suscitées par des causes extérieures
Mode of Death: Pending

NAME OF PATHOLOGIST Nom du pathologiste (b)(6)

SIGNATURE (b)(6) DATE Date 04 Feb 2005

AVIATION ACCIDENT Accident à Avion ☐ YES Oui ☑ NO Non

DATE OF DEATH *(Hour, day, month, year)* Date de décès *(l'heure, le jour, le mois, l'année)*	PLACE OF DEATH Lieu de décès
	Iraq

I HAVE VIEWED THE REMAINS OF THE DECEASED AND DEATH OCCURRED AT THE TIME INDICATED AND FROM THE CAUSES AS STATED ABOVE.
J'ai examiné les restes mortels du dé funt je conclus que le décès est survenu à l'heure indiquée et à, la suite des causes énumérées ci-dessus.

NAME OF MEDICAL OFFICER Nom du médicin militaire ou du médicin sanitaire	TITLE OR DEGREE Titre ou diplômé
(b)(6)	Medical Examiner

GRADE Grade	INSTALLATION OR ADDRESS Installation ou adresse
(b)(6)	Dover AFB, DE 19902

DATE Date	SIGNATURE
24 March 05	(b)(6)

[1] *State disease, injury or complication which caused death, but not mode or dying such as heart failure, etc.*
[2] *State conditions contributing to the death, but not related to the disease or condition causing death.*
[1] *Préciser la nature de la maladie, de la blessure ou de la complication qui a contribué à la mort, mais non la manière de mourir, telle qu'un arrêt du coeur, etc.*
[2] *Préciser la condition qui a contribué à la mort, mais n'ayant aucun rapport avec la maladie ou à la condition qui a provoqué la mort.*

DD FORM 1 APR 77 2064 REPLACES DA FORM 3565, 1 JAN 72 AND DA FORM 3565-R(PAS), 26 SEP 75, WHICH ARE OBSOLETE.

MEDCOM 0426

ACLU Detainee DeathII ARMY MEDCOM 426

(REMOVE, REVERSE AND RE-INSERT CARBONS BEFORE COMPLETING THIS SIDE)

DISPOSITION OF REMAINS			
NAME OF MORTICIAN PREPARING REMAINS	GRADE	LICENSE NUMBER AND STATE	OTHER
INSTALLATION OR ADDRESS	DATE	SIGNATURE	
NAME OF CEMETERY OR CREMATORY	LOCATION OF CEMETERY OR CREMATORY		
TYPE OF DISPOSITION		DATE OF DISPOSITION	

REGISTRATION OF VITAL STATISTICS			
REGISTRY *(Town and Country)*	DATE REGISTERED	FILE NUMBER	
		STATE	OTHER
NAME OF FUNERAL DIRECTOR	ADDRESS		
SIGNATURE OF AUTHORIZED INDIVIDUAL			

DD FORM 2064, APR 1977 (BACK) **USAPA V1.00**

ACLU Detainee DeathII ARMY MEDCOM 427

ARMED FORCES INSTITUTE OF PATHOLOGY
Office of the Armed Forces Medical Examiner
1413 Research Blvd., Bldg. 102
Rockville, MD 20850
(301) 319-0000

FINAL AUTOPSY REPORT

Name: MUTLIB, Ali Hussein
Interment Serial (b)(6)
Date of Birth: (b)(6) 946
Date of Death (b)(6) 2006
Date of Autopsy: 11 DEC 2006 @ 1200
Date of Report: 28 FEB 2007

Autopsy No: (b)(6)
AFIP No (b)(6)
Place of Death: Camp Bucca, Iraq
Place of Autopsy: Dover AFB Port Mortuary, Delaware

Circumstances of Death: (b)(6) an Iraqi National male, was held as a detainee in Camp Bucca, Iraq. He was admitted to the Theater Interment Facility (TIF) on 17 November for heart and blood pressure problems. On (b)(6), (b)(6) became hypotensive and unresponsive. He expired despite cardiac resuscitative measures.

Authorization for Autopsy: Office of the Armed Forces Medical Examiner, in accordance with Title 10 US Code, Section 1471 (10 USC 1471).

Identification: Positive identification established by investigative agency

CAUSE OF DEATH: **Severe Atherosclerotic Cardiovascular Disease**

MANNER OF DEATH: **Natural**

ACLU Detainee DeathII ARMY MEDCOM 428

MUTLIB (b)(6)

AUTOPSY FINDINGS:

I. Severe Atherosclerotic Cardiovascular Disease
Heart: Cardiomegaly, 710 grams
Coronary arteries:
i. Left main coronary artery – 60% stenosis with concentric calcification
ii. Left anterior descending coronary artery – multifocal 95% stenosis
iii. Right coronary artery - multifocal 95% stenosis
Concentric left ventricular hypertrophy – left ventricular thickness – 2.5cm; septum 2.4 cm
Remote myocardial infarction, posterior-lateral left ventricle
Diffuse atherosclerosis of the abdominal aorta and iliac vessels with multiple erosive plaques

II. Lungs:
a. Marked bilateral pulmonary edema (combined weight 2220 grams)
b. Diffuse anthracotic pigment, pleura and parenchymal
c. Emphysema
d. Bronchopneumonia

III. Kidneys:
a. Marked arteriolonephrosclerosis (clinical history of hypertension)

IV. Brain:
a. Incidental arteriovenous malformation of the left pons, 0.5 cm

V. Toxicology:

- **VOLATILES**: The blood and vitreous fluid are examined for the presence of ethanol at a cutoff level of 20 mg/dL. No ethanol is detected.
- Peripheral blood contains less than 1% carboxyhemoglobin (COHgb) determined by spectrophotometry with a limit of quantitation of 1%. COHgb saturations of 0-3% are expected for non-smokers and 3-10% for smokers. Saturations above 10% are considered elevated and are confirmed by gas chromatography.
- There is no cyanide detected in the blood. The limit of quantitation for cyanide is 0.25 mg/L. Normal blood cyanide concentrations are less than 0.15 mg/L. Lethal concentrations of cyanide are greater than 3 mg/L.
- **DRUGS:** The blood is screened for acetaminophen, amphetamine, antidepressants, antihistamines, barbiturates, benzodiazepines, cannabinoids, chloroquine, cocaine, dextromethorphan, lidocaine, narcotic analgesics, opiates, phencyclidine, phenothiazines, salicylates, sympathomimetic amines and verapamil by gas chromatography, color test or immunoassay. The following drugs are detected:
  - Lidocaine is detected in the blood by gas chromatography and confirmed by gas chromatography/mass spectrometry
  - Acetaminophen is detected in the blood by color test and confirmed by immunoassay. The blood contains 17mg/L of acetaminophen as quantitated by immunoassay.

ACLU Detainee DeathII ARMY MEDCOM 429

EXTERNAL EXAMINATION

The body is that of a well-developed, well-nourished, 71-inch tall, 202 pound male. Lividity is fixed on the posterior aspect of the body. Rigor has passed and the temperature of the body is cold, that of the refrigerator.

The scalp is covered with gray hair, with frontal balding. Facial hair consists of a gray beard and mustache. The irides are hazel and the conjunctivae are cloudy. The pupils are round and equal in diameter. The external auditory canals are unremarkable. The ears lobes have prominent creases and are otherwise unremarkable. The nares are patent and the lips are atraumatic. The nose and maxillae are palpably stable. The teeth are natural.

The neck is straight, and the trachea is midline and mobile. The chest is symmetric. The abdomen is protuberant. The genitalia are those of a normal adult circumcised male. The testes are descended and free of masses. Pubic hair is present in a normal distribution. The buttocks and anus are unremarkable.

The upper and lower extremities are symmetric and without clubbing or edema.

CLOTHING AND PERSONAL EFFECTS

- The deceased is clad in a hospital gown. Personal effects do not accompany the body.

MEDICAL INTERVENTION

- Endotracheal intubation; intravenous access devices in the right neck and left groin; needle marks in both wrists; Foley catheter; cardiac monitor pads anterior chest; bandage covering surgical incision right knee (stapled closed)

RADIOGRAPHS

- A complete set of postmortem radiographs is obtained and demonstrates no acute injuries aside from those discussed in the evidence of injury

EVIDENCE OF INJURY

- External injuries consist of mid-sternal contusion and internal examination reveals fractures of lateral right ribs 2-7 and lateral left ribs 2-6 (injuries consistent with cardiopulmonary resuscitation)
- Two contusions on the posterior right calf and ankle, 2 ½ x 1 and 3 x 1-inches, respectively

ACLU Detainee DeathII ARMY MEDCOM 430

MUTLIB (b)(6)

INTERNAL EXAMINATION

HEAD: The galeal and subgaleal soft tissues of the scalp are free of injury. The calvarium is intact, as is the dura mater beneath it. Clear cerebrospinal fluid surrounds the 1340 gm brain, which has unremarkable gyri and sulci. Coronal sections demonstrate sharp demarcation between white and grey matter, without hemorrhage or contusive injury. The ventricles are of normal size. The basal ganglia, cerebellum, and arterial systems are free of injury or other abnormalities. Examination of the mid-section of the pons on the left side shows a 0.5cm area of apparent hemorrhage. There are no skull fractures. The atlanto-occipital joint is stable.

NECK: The anterior strap muscles of the neck are homogenous and red-brown, without hemorrhage. The thyroid cartilage and hyoid bone are intact. The larynx is lined by intact white mucosa. The thyroid is symmetric and red-brown, without cystic or nodular change. The tongue is free of bite marks, hemorrhage, or other injuries.

Incision and dissection of the posterior neck demonstrates no deep paracervical muscular injury and no cervical spine fractures.

BODY CAVITIES: Contusion of the sternum and rib fractures have been described. Otherwise, the ribs, sternum, and vertebral bodies are visibly and palpably intact. No excess fluid is in the pleural, pericardial or peritoneal cavities. The organs occupy their usual anatomic positions.

RESPIRATORY SYSTEM: The right and left lungs are markedly edematous and weigh 1100 and 1120 gm, respectively. The external surfaces are smooth and deep red-purple with marked anthracotic pigment deposition on the pleura and in the parenchyma. The pulmonary parenchyma is diffusely congested and edematous and displays emphysematous changes at the upper lobes.. No mass lesions or areas of consolidation are present.

CARDIOVASCULAR SYSTEM: The enlarged 710 gm heart is contained in an intact pericardial sac. The epicardial surface is smooth, with minimal fat investment. The coronary arteries are present in a normal distribution, with a right-dominant pattern. Cross sections of the vessels show 60% stenosis of the left main coronary artery; 95% multi-focal stenosis of the left anterior descending coronary artery and 95% stenosis of the right coronary artery. The myocardium is homogenous, red-brown, and firm. The valve leaflets are thin and mobile. The walls of the left and right ventricles are 2.5 and 1.0 cm thick, respectively. The endocardium is smooth and glistening. A 2 cm area of apparent fibrosis on the postero-lateral left ventricle is grossly consistent with remote myocardial infarction. The aorta shows marked erosive atherosclerosis along the entire length. The renal and mesenteric vessels are calcific with marked atherosclerosis.

LIVER & BILIARY SYSTEM: The 1970 gm liver has an intact, smooth capsule and a sharp anterior border. The parenchyma is tan-brown and congested, with the usual lobular architecture. No mass lesions or other abnormalities are seen. The gallbladder contains 25 ml of green-black bile and no stones. The mucosal surface is green and velvety. The extrahepatic biliary tree is patent.

MEDCOM 0431
ACLU Detainee DeathII ARMY MEDCOM 431

SPLEEN: The 190 gm spleen has a smooth, intact, red-purple capsule. The parenchyma is maroon and congested, with distinct Malpighian corpuscles.

PANCREAS: The pancreas is mildly autolytic but otherwise firm and yellow-tan, with the usual lobular architecture. No mass lesions or other abnormalities are seen.

ADRENALS: The right and left adrenal glands are symmetric, with yellow cortices and grey medullae. No masses or areas of hemorrhage are identified.

GENITOURINARY SYSTEM: The right and left kidneys are reduced in size and weigh 90 and 80 gm, respectively. The external surfaces are coarsely granular. The cut surfaces are red-tan and the corticomedullary junctions are poorly differentiated. The pelves are unremarkable and the ureters are normal in course and caliber. White bladder mucosa overlies an intact bladder wall. The bladder is empty. The prostate is normal in size, with lobular, yellow-tan parenchyma. The seminal vesicles are unremarkable. The testes are free of mass lesions, contusions, or other abnormalities.

GASTROINTESTINAL TRACT: The esophagus is intact and lined by smooth, gray-white mucosa. The stomach contains approximately 350 ml of brown fluid. The gastric wall is intact. The entire small and large intestines are examined along their entire length and the mucosa is unremarkable. The appendix is present.

MUSCULOSKELETAL: No evidence of chronic disease; incision of the soft tissues of the back, buttocks, thighs, legs and wrists show no evidence of injury.

MICROSCOPIC EXAMINATION

Selected portions of organs are retained in formalin and the following histologic slides are made:

#1, #2, and #4: Histologic sections of the coronary arteries confirm the gross descriptions
#3 and #5: Left Ventricle: multifocal fibrosis
#6. Cardiac septum: multifocal fibrosis
Right Ventricle: unremarkable
#7 and #8: Lung: bronchopneumonia; pulmonary edema; emphysematous change
#9: Liver: no pathologic diagnosis
#10: Kidney: hyaline arteriolosclerosis; diffuse fibrinoid necrosis of arterioles and hyperplasic arterolitis (onion-skin change); tubular atrophy, interstitial fibrosis and chronic inflammation; focal glomerular fibrosis
#11: Pons: arteriovenous malformation
Medulla: no pathologic diagnosis
#12: Cortex, brain: no pathologic diagnosis
#13: Aorta; marked calcific erosive atherosclerosis confirming the gross observations
#14: Left Ventricle (posterolateral): remote myocardial infarction

MEDCOM 0432
ACLU Detainee DeathII ARMY MEDCOM 432

ADDITIONAL PROCEDURES

- Documentary photographs are taken by the OAFME Photographer
- Identifying marks include a scars on the posterior right leg (calf)
- Specimens retained for toxicological testing and/or DNA identification are: vitreous fluid, blood, urine, spleen, liver, kidney, lung, brain, bile, gastric contents, psoas muscle and adipose tissue
- The dissected organs are forwarded with the body

OPINION

Based on these autopsy findings and the investigative information available to me, the cause of death of Iraqi detainee (b)(6) is severe three vessel atherosclerotic cardiovascular disease. The markedly enlarged heart shows histologic evidence of previous myocardial infarction (heart attack) and left ventricular hypertrophy. The left ventricle of the heart and the kidneys show both gross and microscopic changes consistent with long standing hypertension (high blood pressure). An incidental arteriovenous malformation of the brain (likely congenital), located in the pons, had no bearing on the cause of death. Toxicology examination is positive for acetaminophen and lidocaine, medications utilized in hospitalized care.

The manner of death is natural.

(b)(6)

Armed Forces Medical Examiner System

(b)(6)

ACLU Detainee DeathII ARMY MEDCOM 433

CERTIFICATE OF DEATH *(OVERSEAS)*
Acte de décès (D'Outre-Mer)

NAME OF DECEASED *(Last, First, Middle)* Nom du décédé (Nom et prénoms)	GRADE Grade	BRANCH OF SERVICE Arme	SOCIAL SECURITY NUMBER Numéro de l'Assurance Social
BTB Mutlib, Ali Hussein,		Civilian	(b)(6)

ORGANIZATION Organisation	NATION *(e.g. United States)* Pays	DATE OF BIRTH Date de naissance	SEX Sexe
	Iraq	1 January 1946	[X] MALE [ ] FEMALE

RACE Race		MARITAL STATUS État Civil				RELIGION Culte			
[X]	CAUCASOID Caucasique	[ ]	SINGLE Célibataire	[ ]	DIVORCED Divorcé	[ ]	PROTESTANT Protestant	[X]	OTHER (Specify) Autre (Spécifier)
[ ]	NEGROID Negriode	[ ]	MARRIED Marié	[ ]	SEPARATED Séparé	[ ]	CATHOLIC Catholique		
[ ]	OTHER (Specify) Autre (Spécifier)	[ ]	WIDOWED Veuf			[ ]	JEWISH Juif		

NAME OF NEXT OF KIN Nom du plus proche parent	RELATIONSHIP TO DECEASED Parenté du décédé avec le sus
STREET ADDRESS Domicilé à (Rue)	CITY OR TOWN OR STATE *(Include ZIP Code)* Ville (Code postal compris)

MEDICAL STATEMENT Déclaration médicale

CAUSE OF DEATH (Enter only one cause per line) Cause du décès (N'indiquer qu'une cause par ligne)			INTERVAL BETWEEN ONSET AND DEATH Intervalle entre l'attaque et le décès
DISEASE OR CONDITON DIRECTLY LEADING TO DEATH [1] Maladie ou condition directement responsable de la mort.		Arteriosclerotic Cardiovascular Disease	
ANTECEDENT CAUSES Symptômes précurseurs de la mort.	MORBID CONDITION, IF ANY, LEADING TO PRIMARY CAUSE Condition morbide, s'il y a lieu, menant à la cause primaire		
	UNDERLYING CAUSE, IF ANY, GIVING RISE TO PRIMARY CAUSE Condition morbide, s'il y a lieu, menant à la cause primaire		
OTHER SIGNIFICANT CONDITIONS [2] Autres conditions significatives [2]		hypertension, arteriolonephrosclerosis	

MODE OF DEATH Condition de décès	AUTOPSY PERFORMED Autopsie effectuée [X] YES Oui [ ] NO Non	CIRCUMSTANCES SURROUNDING DEATH DUE TO EXTERNAL CAUSES Circonstances de la mort suscitées par des causes extérieures
[X] NATURAL Mort naturelle	MAJOR FINDINGS OF AUTOPSY Conclusions principales de l'autopsie	
[ ] ACCIDENT Mort accidentelle		
[ ] SUICIDE Suicide	NAME OF PATHOLOGIST Nom du pathologiste (b)(6)	
[ ] HOMICIDE Homicide	SIGNATURE (b)(6) DATE Date 11 December 2006	AVIATION ACCIDENT Accident à Avion [ ] YES Oui [X] NO Non

DATE OF DEATH *(day, month, year)* Date de décès *(le jour, le mois, l'année)*	PLACE OF DEATH Lieu de décès
(b)(6) 2006	Iraq

I HAVE VIEWED THE REMAINS OF THE DECEASED AND DEATH OCCURRED AT THE TIME INDICATED AND FROM THE CAUSES AS STATED ABOVE.
J'ai examiné les restes mortels du dé funtet je conclus que le décès est survenu à l'heure indiquée et à, la suite des causes énumérées ci-dessus.

NAME OF MEDICAL OFFICER Nom du médicin militaire ou du médicin sanitaire	TITLE OR DEGREE Titre ou diplôme
(b)(6)	Medical Examiner

GRADE Grade	INSTALLATION OR ADDRESS Installation ou adresse
(b)(6)	Dover AFB, Dover DE
DATE Date 3/21/2007	SIGN (b)(6)

[1] State disease, injury or complication which caused death, but no
[2] State conditions contributing to the death, but not related to the
[1] Préciser la nature de la maladie, de la blessure ou de la complication qui a contribué à la mort, mais non la manière de mourir, telle qu 'un arrêt du coeur, etc
[2] Préciser la condition qui a contribué à la mort, mais n'ayant aucun rapport avec la maladie ou à la condition qui a provoqué la mort.

DD FORM 1 APR 77 2064 REPLACES DA FORM 3565, 1 JAN 72 AND DA FORM 3565-R(PAS), 26 SEP 76, WHICH ARE OBSOLETE.

ARMED FORCES INSTITUTE OF PATHOLOGY
Office of the Armed Forces Medical Examiner
1413 Research Blvd., Bldg. 102
Rockville, MD 20850
(301) 319-0000

AUTOPSY EXAMINATION REPORT

Name: Atiah. Khalifah Hamadi
ISN: (b)(6)
Date of Birth: (b)(6) 1959
Date of Death (b)(6) 2006
Date/Time of Autopsy: 06 DEC 2006/1100
Date of Report: 09 FEB 2006

Autopsy No.: (b)(6)
AFIP No.: (b)(6)
Rank: Detainee
Place of Death: Iraq
Place of Autopsy: Port Mortuary
Dover AFB, Dover, DE

Circumstances of Death: This 57-year-old, detainee was interned at Camp Remembrance, Iraq during Operation Iraqi Freedom. Investigative reports state that (b)(6) (b)(6) was admitted to the 21st Combat Support Hospital (CSH) with complaints of chest pain and was diagnosed with an acute myocardial infarction. On (b)(6) (b)(6) (b)(6) condition worsened and he became unresponsive. Aggressive attempts at resuscitation were unsuccessful.

Authorization for Autopsy: Office of the Armed Forces Medical Examiner, IAW 10 USC 1471

Identification: Presumptive identification by accompanying reports. A DNA sample is taken for profile purposes should an exemplar becomes available for positive identification.

CAUSE OF DEATH: Acute myocardial infarction

MANNER OF DEATH: Natural

FINAL AUTOPSY DIAGNOSES:

I. Natural disease diagnoses
   A. Atherosclerotic cardiovascular disease
      1. Acute thrombus middle circumflex coronary artery
      2. Luminal narrowing, 70% of the left main coronary artery
      3. Luminal narrowing; 80% of the proximal, 90% of the middle and 90% of the distal left anterior descending coronary artery
      4. Luminal narrowing; 60% of the proximal, 90% of the middle and near total occlusion (pinpoint lumen) of the distal right coronary arteries
      5. Diffuse arteriosclerotic and atherosclerotic plaque formation throughout the thoracic and abdominal aorta
      6. Calcific plaque formation and luminal narrowing of both renal arteries
      7. Acute and healed myocardial infarction involving the left ventricle
      8. Cardiomegaly (borderline); 450-grams (expected heart weight 344-grams, upper limit 439-grams)
   B. Bilateral atrophied and granular kidneys (right – 70-grams, left – 30-grams)
   C. Bilateral pulmonary edema (right lung – 640-grams, left lung – 670-grams)

II. Evidence of medical intervention
   A. Orotracheal tube, appropriately placed
   B. Angiocatheter sutured in the left subclavian vein
   C. Multiple (14) self-adhesive electrocardiogram electrodes affixed to the anterior chest, left arm and left thigh
   D. Urinary catheter
   E. Intravenous catheters in the dorsum of both distal forearms
   F. Multiple therapeutic puncture marks on the left neck and shoulder, right antecubital fossa, and right lower quadrant of the abdomen
   G. Identification bracelet on the right wrist printed with (b)(6)
   H. Hemorrhage into the superficial strap muscles and left lobe of the thyroid gland

III. Traumatic diagnoses
   A. Trauma of the head and neck
      1. No evidence of ligature marks or strangulation on the neck after external examination and layerwise anterior and posterior neck dissections
   B. Trauma of the torso
      1. Faint red contusion on the lower chest along the right anterior axillary line, 1 ½ x ½-inch
      2. Healing contusion on the lower chest along the left mid-clavicular line, 1 x ¾-inch
      3. Area of ecchymosis above the left anterior superior iliac spine associated with a therapeutic puncture, 2 1/8 x ¾-inches
      4. Contusion below the angle of the left scapula, 1 x ½-inches
      5. Superficial hemorrhage into the left middle trapezius and rhomboid muscles, 4 ½ x 1 ½-inches, without injury to the underlying paraspinal muscles

ACLU Detainee DeathII ARMY MEDCOM 436

6. No evidence of additional trauma after external examination and dissection of the subcutaneous tissues and muscles

C. Trauma of the extremities
1. Contusion of the right antecubital fossa associated with therapeutic punctures, 2 ½ x 1 ¼-inches
2. Contusion on the tip of the distal phalanx of the 1st digit of the right foot, 1/8-inch
3. Ecchymosis in the right popliteal fossa, 3 x 2 ½-inches
4. No evidence of additional trauma after external examination and dissection of the subcutaneous tissues and muscles

IV. Post-mortem changes
A. Lividity is fixed on the posterior surface of the body except in areas exposed to pressure
B. Rigor is present to an equal degree in all extremities
C. Greenish discoloration of the skin of the right lower quadrant of the abdomen

V. Toxicology results
A. Volatiles: The blood and vitreous fluid were examined for the presence of ethanol at a cutoff of 20 mg/dl. No ethanol was detected.
B. Drugs: The blood was screened for amphetamine, antidepressants, antihistamines, barbiturates, benzodiazepines, cannabinoids, chloroquine, cocaine, dextromethorphan, lidocaine, narcotic analgesics, opiates, phencyclidine, phenothiazines, sympathomimetic amines and verapamil by gas chromatography, color test or immunoassay:
1. Positive metoprolol: Metoprolol was detected in the blood by gas chromatography and confirmed by gas chromatography/mass spectrometry. The blood contained ½ mg/L of metoprolol as quantitated by gas chromatography/mass spectrometry.
C. Carbon Monoxide: The Carboxyhemoglobin saturation in the blood is less than 1% as determined by spectrophotometry with a limit of quantitation of 1%. Carboxyhemoglobin saturations of 0-3% are expected for non-smokers and 3-10% for smokers. Saturations above 10% are considered elevated and are confirmed by gas chromatography.
D. Cyanide: No cyanide is detected in the blood. The limit of quantitation for cyanide is 0.25 mg/L. Normal blood cyanide concentrations are less than 0.15mg/L. Lethal concentrations of cyanide are greater than 3 mg/L.

ACLU Detainee DeathII ARMY MEDCOM 437

EXTERNAL EXAMINATION

The body is that of a well-developed, well-nourished appearing adult male whose appearance is consistent with the reported age of 57-years. The remains are 69-inches in length, and weigh 182-pounds. Lividity is present and fixed on the posterior surface of the body, except in areas exposed to pressure. Rigor is present to an equal degree in all extremities. The temperature of the body is that of the refrigeration unit.

The scalp is covered with curly short black hair with gray at the temples and early male pattern baldness. The face has grey and brown stubble with a trim grey streaked black moustache. The irides are brown, the corneae hazy, and the pupils are round and equal in diameter. The sclera are white, the conjunctivae congested with no evidence of petechial hemorrhage. The external auditory canals are free of foreign material and abnormal secretions. The ears are unremarkable. The nares are patent and the lips are atraumatic. The nose and maxillae are palpably stable. The teeth appear natural and in poor condition. No evidence of trauma is noted on the head.

The neck is straight, and the trachea is midline and mobile. The chest is symmetric. The abdomen is flat. The genitalia are those of a normal adult circumcised male. The testes are descended and free of masses. Pubic hair is present in a normal male distribution. The buttocks and anus are unremarkable. No evidence of significant trauma is noted on the torso.

The upper and lower extremities are symmetric, without clubbing or edema. No evidence of significant trauma is noted on the extremities.

Identifying marks include the following:

- Multiple hypopigmented scars on the anterior left leg, up to ½-inch in greatest dimensions
- An obliquely oriented (along the 5 to 11 o'clock axis) elliptical scar on the interscapular skin of the back, 2 ½ x ½-inches
- A hyperpigmented scar on the medial border of the right scapula, ¾ x ½-inch
- A hypopigmented scar below the right gluteal crease, 2 x ½-inches
- Hyperkeratotic patch on the right lateral malleolus, 7/8 x ½-inches

CLOTHING AND PERSONAL EFFECTS

The following clothing items and personal effects accompanied the body to the mortuary at the time of autopsy:

- One pair yellow pajamas
- A light green quilted jacket
- A white short sleeve cotton tee shirt
- A pair of brown socks
- A knit ski cap
- Pair of brown shower shoes
- A single knit black glove

ACLU Detainee DeathII ARMY MEDCOM 438

MEDICAL INTERVENTION

- Orotracheal tube, appropriately placed
- Angiocatheter sutured in the left subclavian vein
- Multiple (14) self-adhesive electrocardiogram electrodes affixed to the anterior chest, left arm and left thigh
- Urinary catheter
- Intravenous catheters in the dorsum of both distal forearms
- Multiple therapeutic puncture marks on the left neck and shoulder, right antecubital fossa, and right lower quadrant of the abdomen
- Identification bracelet on the right wrist printed with (b)(6)
- Hemorrhage into the superficial strap muscles and left lobe of the thyroid gland

RADIOGRAPHS

A complete set of postmortem radiographs is obtained and demonstrate no evidence of significant trauma

EVIDENCE OF INJURY

The ordering of the following injuries is for descriptive purposes only, and is not intended to imply order of infliction or relative severity.

There is a faint red contusion on the lower chest along the right anterior axillary line measuring 1 ½ x ½-inch. On the lower chest along the left mid-clavicular line is a healing 1 x ¾-inch contusion. There is an area of ecchymosis measuring 2 1/8 x ¾-inches above the left anterior superior iliac spine associated with a therapeutic puncture. Injuries to the back include a superficial hemorrhage into the left middle trapezius and rhomboid muscles measuring 4 ½ x 1 ½-inchew without injury to the underlying paraspinal muscles.
Injuries to the extremities include a contusion, measuring 2 ½ x 1 ¼-inches, in the right antecubital fossa associated with therapeutic punctures. There is a contusion on the tip of the distal phalanx of the 1st digit of the right foot measuring 1/8-inch in diameter. In the right popliteal fossa is a 3 x 2 ½-inch area of ecchymosis.

INTERNAL EXAMINATION

HEAD:
The galeal and subgaleal soft tissues of the scalp are free of injury. The scalp is reflected. The calvarium is intact as is the dura mater beneath it. There are no epidural or subdural hemorrhages present. The leptomeninges are thin and delicate. Clear cerebrospinal fluid surrounds the 1280-gram brain, which has unremarkable gyri and sulci. The cerebral hemispheres are symmetrical and demonstrate mild vascular congestion. The structures at the base of the brain, including cranial nerves and blood vessels are intact. Coronal sections demonstrate sharp demarcation between white and grey matter, without hemorrhage or contusive injury. The ventricles are of normal size. The basal ganglia, brainstem, and cerebellum are free of injury or other abnormalities. The arterial systems

ACLU Detainee DeathII ARMY MEDCOM 439

are free of injury. Focal atherosclerotic plaques are noted in the basilar and vertebral arteries. The atlanto-occipital joint is stable.

NECK:
The anterior strap muscles of the neck are homogenous and red-brown. Focal hemorrhage is noted in the superficial left strap muscles and the left lobe of the thyroid gland and described under "Evidence of Medical Intervention". The thyroid cartilage and hyoid are intact. The larynx is lined by intact white mucosa. The thyroid is symmetric and red-brown, without cystic or nodular change. The tongue is free of bite marks, hemorrhage, or other injuries. Incision and layerwise dissection of the anterior and posterior neck demonstrates no evidence of trauma, deep paracervical muscular injury, or cervical spine fractures.

BODY CAVITIES:
The body is opened by the usual thoraco-abdominal incision and the chest plate is removed. No adhesions are present in any of the body cavities. There is a 30-milliliter collection of serosanguinous fluid in the right pleural cavity. The remaining body cavities have no abnormal collections of fluid. All body organs are present in the normal anatomic position. There is no internal evidence of blunt force or penetrating injury to the thoraco-abdominal region.

RESPIRATORY SYSTEM:
The upper airway is clear of debris and foreign material; the mucosal surfaces are smooth, yellow-tan and unremarkable. The pleural surfaces are smooth, glistening and unremarkable bilaterally. The external surfaces are smooth and dark red. The pulmonary parenchyma is diffusely congested, boggy red, and edematous, exuding moderate amounts of bloody fluid. No mass lesions or areas of consolidation are present. The right and left lungs weigh 640 and 670-grams, respectively.

CARDIOVASCULAR SYSTEM:
The pericardial surfaces are smooth, glistening and unremarkable; the pericardial sac is free of significant fluid or adhesions. The coronary arteries arise normally; follow the usual distribution in a right dominant pattern. Three vessel atherosclerotic coronary artery disease is present with luminal narrowing in the following distribution: left main coronary artery – 70%; left anterior descending coronary artery – proximal (80%), middle (90%), and distal (90%); right coronary artery – proximal (60%), middle (90%), and distal (near occlusion – pinpoint lumen); left circumflex coronary artery (90%) with acute thrombus formation in the middle segment of the vessel. Scarring and fibrosis is noted in the septum and posterior free wall of the left ventricle. The remainder of the myocardium is homogenous, red-brown, firm and unremarkable. The valve leaflets are thin and mobile. The walls of the left and right ventricles are 1.2 and 0.3-centimeters thick, respectively. The endocardium is smooth and glistening. The aorta and its major branches arise normally, follow the usual course and are widely patent. There are multiple calcific atherosclerotic plaques along the thoracic and abdominal aorta. There is calcific plaque formation and near occlusive luminal narrowing of both renal arteries. The venae cavae and its major tributaries return to the heart in the usual distribution and

ACLU Detainee DeathII ARMY MEDCOM 440

are free of thrombi. The mesenteric vessels are unremarkable. The heart weighs 450-grams (predicted heart weight 205-439-grams for a 181-pound man).

LIVER & BILIARY SYSTEM:
The hepatic capsule is smooth, glistening and intact, covering dark red-brown, moderately congested parenchyma with no focal lesions present. The gallbladder contains 50-milliliters of green-brown, bile; the mucosa was velvety and unremarkable. The extrahepatic biliary tree is patent, without evidence of calculi. The liver weighs 1960-grams.

SPLEEN:
The 300-gram spleen has a smooth, intact, red-purple capsule. The parenchyma is maroon and congested, with distinct Malpighian corpuscles.

PANCREAS:
The pancreas is firm and yellow-tan, with the usual lobular architecture. No mass lesions or other abnormalities are seen.

ADRENALS:
The right and left adrenal glands are symmetric, with bright yellow cortices and grey medullae. No masses or areas of hemorrhage are identified.

GENITOURINARY SYSTEM:
The right and left kidneys weigh 70 and 30-grams, respectively. The external surfaces are intact and granular. The cut surfaces are red-tan and congested, with uniformly thick cortices and blurring of the corticomedullary junctions. The pelves are unremarkable and the ureters are normal in course and caliber. White bladder mucosa overlies an intact bladder wall. The bladder contains no urine. The prostate is normal in size, with lobular, yellow-tan parenchyma. The seminal vesicles are unremarkable. The testes are free of mass lesions, contusions, or other abnormalities.

GASTROINTESTINAL TRACT:
The esophagus is intact and lined by smooth, grey-white mucosa. There is a 3 x 2 ½-inch area of hemorrhage of the mucosal surface in the fundus of the stomach. The stomach contains approximately 250-milliliters of thick brown fluid with fragments of partially digested food. The duodenum, loops of small bowel, and colon are unremarkable. The appendix is present.

MUSCULO-SKELETAL SYSTEM:
Muscle development is normal. No bone or joint abnormalities or injuries are noted.

ACLU Detainee DeathII ARMY MEDCOM 441

ADDITIONAL PROCEDURES

- Documentary photographs are taken by OAFME staff photographers
- Specimens retained for toxicologic testing and/or DNA identification are: heart blood, vitreous fluid, gastric contents, bile, spleen, liver, lung, kidney, brain, adipose tissue, and psoas muscle
- Full body radiographs are obtained and demonstrate the above findings
- Selected portions of organs are retained in formalin, histological slides are prepared of selected organs
- The dissected organs are forwarded with the body
- Personal effects are released to the mortuary affairs representatives

MICROSCOPIC EXAMINATION

Selected portions of organs are retained in formalin.

SLIDE SUMMARY:

1. Left anterior descending coronary artery
2. Right coronary artery
3. Circumflex coronary artery
4. Circumflex coronary artery with thrombus
5. Right ventricle
6. Septum
7. Left ventricle
8. Anterior left ventricle
9. Lateral left ventricle
10. Kidney, lung
11. Spleen, lung
12. Liver, lung
13. Kidney, lung
14. Aorta, lung

I. Cardiovascular (#1-9, 14): Histologic sections of the left anterior descending and right coronary arteries demonstrate at least 90% luminal narrowing by fibrocalcific plaques. Sections of the left circumflex coronary artery show acute rupture of a fibroatheroma with occlusive thrombus and greater then 90% luminal narrowing. Focal myocyte hypertrophy is seen in microscopic sections of the right ventricle and septum. Histologic sections of the left ventricle show the presence of contraction bands, a neutrophilic infiltrate, transmural replacement fibrosis, interstitial fibrosis, and focal myocyte hypertrophy. Fibrocalcific plaques are seen on microscopic evaluation of representative sections of the aorta.

II. Pulmonary (#10-14): Vascular congestion, no significant pathologic diagnosis

III. Liver (#12): Vascular congestion, no significant pathologic diagnosis

IV. Genitourinary (#10, 13): Kidneys demonstrate arteriosclerosis, focal glomerular sclerosis and focal tubular necrosis

V. Spleen (#11): Vascular congestion, no significant pathologic diagnosis

ACLU Detainee DeathII ARMY MEDCOM 442

OPINION

This 57-year-old detainee (b)(6) died of an Acute Myocardial Infarction. An acute thrombus was identified in the left circumflex coronary artery. Microscopic and gross examination of the heart demonstrated evidence of an acute and healed infarct. Severe coronary atherosclerosis of three vessels (left anterior descending, right and left circumflex coronary arteries) was noted both on gross and microscopic examination. His heart weighed 450-grams and the expected heart weight for his size (182-pounds) is 344-grams with an upper limit of 439-grams. No significant traumatic injuries were identified at autopsy. Toxicology tests for ethanol, screened drugs of abuse, carbon monoxide, and cyanide are negative. Supratherapeutic levels of metoprolol were detected in the blood. These levels are significantly below toxic or lethal levels and are unrelated to the cause and manner of death.

The manner of death is natural.

(b)(6)

(b)(6) Medical Examiner

(b)(6)

(b)(6) Medical Examiner

ACLU Detainee DeathII ARMY MEDCOM 443

CERTIFICATE OF DEATH *(OVERSEAS)*

Acte de décès (D'Outre-Mer)

NAME OF DECEASED *(Last, First, Middle)* Nom du décédé (Nom et prénoms)	GRADE Grade	BRANCH OF SERVICE Arme	SOCIAL SECURITY NUMBER Numéro de l'Assurance Social
BTB Atiah, Khalifah, Hamadi		Civilian	(b)(6)
ORGANIZATION Organisation	**NATION** *(e.g. United States)* Pays: Iraq	**DATE OF BIRTH** Date de naissance: (b)(6) 1959	**SEX** Sexe: [X] MALE [ ] FEMALE

RACE Race		MARITAL STATUS État Civil			RELIGION Culte		
X	CAUCASOID Caucasique		SINGLE Célibataire		DIVORCED Divorcé	PROTESTANT Protestant	OTHER (Specify) Autre (Spécifier)
	NEGROID Negroïde		MARRIED Marié		SEPARATED Séparé	CATHOLIC Catholique X	
	OTHER (Specify) Autre (Spécifier)		WIDOWED Veuf			JEWISH Juif	

NAME OF NEXT OF KIN Nom du plus proche parent	RELATIONSHIP TO DECEASED Parenté du décédé avec le sus
STREET ADDRESS Domicile à (Rue)	CITY OR TOWN OR STATE *(Include ZIP Code)* Ville (Code postal compris)

MEDICAL STATEMENT Déclaration médicale

CAUSE OF DEATH (Enter only one cause per line) Cause du décès (N'indiquer qu'une cause par ligne)			INTERVAL BETWEEN ONSET AND DEATH Intervalle entre l'attaque et le décès
DISEASE OR CONDITON DIRECTLY LEADING TO DEATH [1] Maladie ou condition directement responsable de la mort.		Acute myocardial infarction	Days
ANTECEDENT CAUSES Symptômes précurseurs de la mort.	MORBID CONDITION, IF ANY, LEADING TO PRIMARY CAUSE Condition morbide, s'il y a lieu, menant à la cause primaire	Atherosclerotic cardiovascular disease	
	UNDERLYING CAUSE, IF ANY, GIVING RISE TO PRIMARY CAUSE Condition morbide, s'il y a lieu, menant à la cause primaire		
OTHER SIGNIFICANT CONDITIONS [2] Autres conditions significatives [2]			

MODE OF DEATH Condition de décès		AUTOPSY PERFORMED Autopsie effectuée [X] YES Oui [ ] NO Non	CIRCUMSTANCES SURROUNDING DEATH DUE TO EXTERNAL CAUSES Circonstances de la mort suscitées par des causes extérieures
X	NATURAL Mort naturelle	MAJOR FINDINGS OF AUTOPSY Conclusions principales de l'autopsie	
	ACCIDENT Mort accidentelle		
	SUICIDE Suicide	NAME OF PATHOLOGIST Nom du pathologiste: (b)(6)	
	HOMICIDE Homicide	SIGNATURE Signature: (b)(6) DATE Date: 6 December 2006	AVIATION ACCIDENT Accident à Avion: [ ] YES Oui [X] NO Non

DATE OF DEATH *(day, month, year)* Date de décès (le jour, le mois, l'année)	PLACE OF DEATH Lieu de décès
(b)(6) 2006 (b)(6)	Baghdad Iraq

I HAVE VIEWED THE REMAINS OF THE DECEASED AND DEATH OCCURRED AT THE TIME INDICATED AND FROM THE CAUSES AS STATED ABOVE.
J'ai examiné les restes mortels du dé funtet je conclus que le décès est survenu à l'heure indiquée et à la suite des causes énumérées ci-dessus.

NAME OF MEDICAL OFFICER Nom du médecin militaire ou du médecin sanitaire	TITLE OR DEGREE Titre ou diplômé
(b)(6)	Medical Examiner

GRADE Grade	INSTALLATION OR ADDRESS Installation ou adresse
CDR	Dover AFB, Dover DE
DATE Date: 06 December 06	SIGNATURE: (b)(6)

[1] State disease, injury or complication which caused death, but not mode of dying such as heart failure, etc.
[2] State conditions contributing to the death, but not related to the disease or condition causing death.
[1] Préciser la nature de la maladie, de la blessure ou de la complication qui a contribué à la mort, mais non le mode de décès, telle qu'un arrêt du coeur, etc.
[2] Préciser la condition qui a contribué à la mort, mais n'ayant aucun rapport avec la maladie ou à la condition qui a provoqué la mort.

DD FORM 1 APR 77 2064 REPLACES DA FORM 3565, 1 JAN 72 AND DA FORM 3565-R(PAS), 26 SEP 75, WHICH ARE OBSOLETE.

ARMED FORCES INSTITUTE OF PATHOLOGY
Office of the Armed Forces Medical Examiner
1413 Research Blvd., Bldg. 102
Rockville, MD 20850
1-301-319-0000

AUTOPSY EXAMINATION REPORT

Name: BTB Muhammad Hamad, Bnayyan
Internment Serial No: (b)(6)
Date of Birth: (b)(6) 1931
Date of Death: (b)(6) 2006
Date/Time of Autopsy: 04 DEC 2006 @ 1200 hrs
Date of Report: 17 JAN 2007

Autopsy No.: (b)(6)
AFIP No.: (b)(6)
Rank: Detainee
Place of Death: Iraq
Place of Autopsy: Port Mortuary, Dover AFB, DE

Circumstances of Death: This 75 year-old elderly male civilian detainee suffered a prolonged hospitalization due to pneumonia and eventual septic and cardiogenic shock which progressed to multi-organ system failure. The ethics committee of the Camp Cropper TIF Hospital determined that continuation of treatment was not warranted due to futility. Accordingly, cardiac support (vasopressors) was withdrawn and the detainee expired.

Authorization for Autopsy: Office of the Armed Forces Medical Examiner, IAW 10 USC 1471

Identification: Presumptive identification based on accompanying paperwork

CAUSE OF DEATH: Acute and Organizing Diffuse Alveolar Damage

MANNER OF DEATH: Natural

ACLU Detainee DeathII ARMY MEDCOM 445

FINAL AUTOPSY DIAGNOSIS

I. Pulmonary System:
- **A. Acute and Organizing Diffuse Alveolar Damage (Lung Weights – Right 1880-grams; Left 1750-grams)**
- **B. Silico-anthracotic Nodules**
- **C. Bilateral Pleural Adhesions**
- **D. Bilateral Serous Pleural Effusions (Left 100-milliliters; Right 100-milliliters)**

II. Cardiovascular System:
- **A. Heart Weight 460-grams**
- **B. Serous Pericardial Effusion (50-milliliters)**
- **C. Mild Atherosclerosis of the Aorta**
- **D. Chronic Inflammation of the Epicardium**

III. Hepatobilliary System:
- **A. Passive Congestion (Liver Weight 1950-grams)**
- **B. Adhesions Between the Liver and Both Hemidiaphragms**
- **C. Mild Portal Triaditis and Fibrosis**

IV. Reticuloendothelial System:
- **A. Congestion of the Spleen (Spleen Weight 250-grams)**
- **B. Adhesions Between the Spleen and Multiple Loops of Bowel**

V. Gastrointestinal System: Abdominal Adhesions

VI. Genitourinary System:
- **A. Simple Cortical Cysts of Both Kidneys**
- **B. Mild Chronic Pyelonephritis**
- **C. Benign Nephrosclerosis (hyaline arteriolosclerosis)**

VII. Other Findings:
- **A. Anasarca**
  - **i. 250-milliters of ascites**
- **B. Multiple Decubitus Ulcers:**
  - **i. Right Forearm, ½-inch**
  - **ii. Right Buttock (4), Ranging From ¼-inch to 1-inch in Greatest Dimension**
  - **iii. Left Buttock (2), 2-inch and 2 ¾-inch**
  - **iv. Left Posterior Thigh (2), ¼-inch and ½-inch**
  - **v. Right Knee (2), 1-inch and 1 ½-inch**
  - **vi. Left Knee, 1-inch**
  - **vii. Right Leg, ½-inch**
  - **viii. Right Lateral Malleolus, ½-inch**
  - **ix. Left Lateral Malleolus, ½-inch**
- **C. Blister of the Right Heel**
- **D. Skin Tag: Right Shoulder**
- **E. Multiple Brown and White Macules on the Torso and Extremities**
- **F. Drying and Cracking of the Lips**
- **G. Drying and Cracking of the Plantar Surfaces of Both Feet**

VIII. Evidence of Significant Injury: None

IX. Evidence of Medical Intervention:

ACLU Detainee DeathII ARMY MEDCOM 446

A. Tracheostomy
B. EKG Leads on the Anterior Torso
C. Right Chest Tube
D. Percutaneous Endoscopic Gastrostomy
E. Stapled Vertical Incision of the Abdomen, 7-inches
F. Dressings:
   i. Buttocks (3)
   ii. Right Knee
   iii. Abdomen
   iv. Chest
   v. Neck
G. Foley Catheter
H. Arterial Line, Right Wrist
I. Intravenous Access, Right Subclavian
J. Multiple Needle Punctures:
   i. Left Subclavian (4)
   ii. Left Wrist (1)

X. Post-mortem Changes:
   A. Lividity is fixed on the posterior surface of the body except in areas exposed to pressure
   B. Rigor has passed
   C. Skin slippage

XI. Toxicology (AFIP):
   A. CARBON MONOXIDE: The carboxyhemoglobin saturation in the blood is 1%
   B. CYANIDE: No cyanide is detected in the blood
   C. VOLATILES: No ethanol is detected in the blood and vitreous fluid
   D. DRUGS: No screened drugs of abuse or medications are detected in the blood

ACLU Detainee DeathII ARMY MEDCOM 447

EXTERNAL EXAMINATION

The body is that of a well-developed, well-nourished appearing 68 ½-inch tall, 198-pounds male whose appearance is consistent with the reported age of 75-years. There is generalized edema of the torso and extremities. Lividity is fixed on the posterior surface of the body except in areas exposed to pressure. Rigor has passed. The body is cold to the touch. The body is lying on blue hospital chucks.

There is a male pattern baldness hair distribution. The irides are bown, and the pupils are round and equal in diameter. The external auditory canals and ears are unremarkable. The nares are patent and the lips are atraumatic. The nose and maxillae are palpably stable. The teeth appear natural with excess wear. The dentition is poor. The face is edematous. The lips are dry and cracked.

The neck is straight, and the trachea is midline and mobile. The chest is symmetric. The abdomen is protuberant. There is a ½-inch round scar on the lower abdomen. The genitalia are those of an adult male. The penis and scrotum are edematous. The testes are descended and free of masses. Pubic hair is present in a normal distribution. The anus is unremarkable.

Multiple decubitus ulcers are observed on the: right forearm, ½-inch; right buttock (4), ranging from ¼-inch to 1-inch in greatest dimension; left buttock (2), 2-inch and 2 ¾-inch; left posterior thigh (2), ¼-inch and ½-inch; right knee (2), 1-inch and 1 ½-inch; left knee, 1-inch; right leg, ½-inch; right lateral malleolus, ½-inch; and left lateral malleolus, ½-inch. One of the decubitus ulcers on the left buttock extends into the underlying muscle. There is a blister on the right heel, a skin tag on the right shoulder and multiple tan and white macules on the extremities and torso.

The upper and lower extremities are symmetric. The plantar surfaces of both feet are dry and cracked. (b)(6)

CLOTHING AND PERSONAL EFFECTS

The following clothing items and personal effects are present on the body at the time of autopsy: The body is received unclad. There is a green personal effects bag tied to the left wrist. The contents of the bag are documented photographically. The bag contains foreign and United States currency, personal papers, two photos and an identification bracelet

MEDICAL INTERVENTION

The following medical interventions are present on the body at the time of autopsy:

- Tracheostomy
- EKG Leads on the Anterior Torso
- Right Chest Tube
- Percutaneous Endoscopic Gastrostomy
- Stapled Vertical Incision of the Abdomen, 7-inches

ACLU Detainee DeathII ARMY MEDCOM 448

- Dressings:
  - Buttocks (3)
  - Right Knee
  - Abdomen
  - Chest
  - Neck
- Foley Catheter
- Arterial Line, Right Wrist
- Intravenous Access, Right Subclavian
- Multiple Needle Punctures:
  - Left Subclavian (4)
  - Left Wrist (1)

RADIOGRAPHS

A complete set of postmortem radiographs and computerized tomography scans are obtained and demonstrates the following:

- Consolidation of both lungs
- Pericardial effusion
- Contrast in the distal colon
- No blunt force or penetrating injuries are detected radiographically

EVIDENCE OF INJURY

There is no evidence of any significant injury.

INTERNAL EXAMINATION

HEAD:
The galeal and subgaleal soft tissues of the scalp are free of injury. The calvarium is intact, as is the dura mater beneath it. Clear cerebrospinal fluid surrounds the 1440-gram brain, which has unremarkable gyri and sulci. Coronal sections demonstrate sharp demarcation between white and grey matter, without hemorrhage or contusive injury. The ventricles are of normal size. The basal ganglia, brainstem, cerebellum, and arterial systems are free of injury or other abnormalities. There are no skull fractures. The atlanto-occipital joint is stable.

NECK:
The anterior strap muscles of the neck are homogenous and red-brown, without hemorrhage. The thyroid cartilage and hyoid are intact. The larynx is lined by intact white mucosa. The thyroid is symmetric and red-brown, without cystic or nodular change. The tongue is free of bite marks, hemorrhage, or other injuries.

BODY CAVITIES:
The ribs, sternum, and vertebral bodies are visibly and palpably intact. There is 100-millilters of serous fluid in both chest cavities, 50-milliliters of serous fluid in the pericardium and 250-milliliters of serous fluid in the peritoneum. The organs occupy their usual anatomic positions.

ACLU Detainee DeathII ARMY MEDCOM 449

RESPIRATORY SYSTEM:
The right and left lungs weigh 1880 and 1750-grams, respectively. There are dense adhesions between both lungs and the pleura and both hemidiaphragms. The external surfaces are rough, irregular and tan-brown. The pulmonary parenchyma is diffusely congested, edematous and firm. There are multiple areas of tan consolidation present in both lungs.

CARDIOVASCULAR SYSTEM:
The 460-gram heart is contained in an intact pericardial sac. The epicardial surface is smooth, with minimal fat investment. The coronary arteries are present in a normal distribution, with a right-dominant pattern. Cross sections of the vessels show wide patency. The myocardium is homogenous, red-brown, and firm. The valve leaflets are thin and mobile. The walls of the left and right ventricles are 1.1 and 0.4-centimeters thick, respectively. The endocardium is smooth and glistening. The aorta gives rise to three intact and patent arch vessels. There is mild atherosclerosis consisting of fatty streaks in the aorta. The renal and mesenteric vessels are unremarkable.

LIVER & BILIARY SYSTEM:
The 1950-gram liver has an intact, smooth capsule and a sharp anterior border. The parenchyma is tan-brown and congested, with the usual lobular architecture. The cut surface has a "nutmeg" appearance. No mass lesions or other abnormalities are seen. The gallbladder contains a 20-milliters of green-black bile and no stones. The mucosal surface is green and velvety. The extrahepatic biliary tree is patent. There are adhesions between the liver and both hemidiaphragms.

SPLEEN:
The 250-gram spleen has a smooth (in areas not involved by adhesions), intact, red-purple capsule. There are adhesions between the spleen and multiple loops of small bowel. The parenchyma is maroon and congested, with distinct Malpighian corpuscles.

PANCREAS:
The pancreas is firm and yellow-tan, with the usual lobular architecture. No mass lesions or other abnormalities are seen.

ADRENALS:
The right and left adrenal glands are symmetric, with bright yellow cortices and grey medullae. There is significant autolysis seen. No masses or areas of hemorrhage are identified.

GENITOURINARY SYSTEM:
The right and left kidneys each weigh 220-grams. The external surfaces are intact and granular. The cut surfaces are red-tan and congested, with uniformly thick cortices and sharp corticomedullary junctions. There are multiple smooth walled cortical cysts identified in both kidneys. The largest cyst measures 1 ½-centimeters in diameter. The pelves are unremarkable and the ureters are normal in course and caliber. The bladder

ACLU Detainee DeathII ARMY MEDCOM 450

mucosa overlies an intact bladder wall and is focally hyperemic. The bladder contains approximately 5-milliliters of clear yellow urine. The prostate is normal in size, with lobular, yellow-tan parenchyma. The seminal vesicles are unremarkable. The testes are free of mass lesions, contusions, or other abnormalities.

GASTROINTESTINAL TRACT:
The esophagus is intact and lined by smooth, grey-white mucosa. The stomach is empty and there is very mild erythema of the mucosal surface. The gastric wall is intact. The duodenum, loops of small bowel, and colon are unremarkable. There are multiple adhesions between the small bowel, colon and spleen. The appendix is present.

PULMONARY PATHOLOGY CONSULTATION (AFIP)

08 JAN 2007
-Acute organizing diffuse alveolar dmage
-Silico-anthracotic nodules
Lungs show mostly organizing diffuse alveolar damage with focal acute areas (hyaline membranes). As is typical of patients on a respirator, there is focal acute inflammation. No organisms are seen on GMS. Stains for CMV, adenovirus and herpes virus are negative.

MICROSCOPIC EXAMINATION

- Lung (Slides 1 through 5) See pulmonary pathology consultation.
- Kidney (Slide 6) There is a simple cortical cyst and mild chronic interstitial inflammation with occasional sclerotic glomeruli. A rare interstitial eosinophil is seen. Some of the tubules are distended and have atrophic epithelium and contain a pink granular material (mild "thyroidization"). There is a mild narrowing of the lumens of arterioles caused by thickening and hyalinization of their walls.
- Liver (Slide 7) There is congestion of the centrilobular sinusoids and peri-portal and portal chronic inflammation. Occasional acute inflammatory cells are seen. Mild fibrosis is seen.
- Spleen (Slide 8) The spleen is congested and otherwise unremarkable.
- Brain (Slide 9) There are no significant pathologic findings.
- Bladder/Prostate (Slide 10) There are no significant pathologic findings
- Heart (Slides 11 through 13) There are chronic inflammatory cells seen in the epicardial fat. Otherwise there are no significant pathologic findings.

ACLU Detainee DeathII ARMY MEDCOM 451

ADDITIONAL PROCEDURES

1. Documentary photographs are taken by OAFME staff photographers.
2. Full body radiographs are obtained and demonstrate no significant blunt force or penetrating trauma.
3. Specimens retained for toxicology testing and/or DNA identification are: Blood, vitreous fluid, bile, urine, brain, lung, liver, spleen, kidney, adipose tissue and psoas muscle
4. The dissected organs are forwarded with the body.
5. Selected portions of organs are retained in formalin. Histologic slides are prepared on: Lung, kidney, liver, spleen, brain, bladder and heart.
6. Personal effects are released to the appropriate mortuary operations representatives.
7. Identifying marks include: A tattoo on (b)(6) (b)(6)

OPINION

This 75 year-old male, BTB (b)(6) died of acute and organizing diffuse alveolar damage. The etiology of this condition is most likely the previously clinically diagnosed and treated pneumonia. Complications of these conditions included a clinical history of sepsis, shock and multi-organ system failure. Multiple decubitis ulcers were seen on external examination and are most likely due to prolonged hospitalization with a debilitating illness. The toxicology screen is negative for cyanide, ethanol, and screened drugs of abuse and medications. The carboxyhemoglobin saturation was not elevated. The manner of death is natural.

(b)(6)

(b)(6) Medical Examiner

(b)(6)

ACLU Detainee DeathII ARMY MEDCOM 452

CERTIFICATE OF DEATH *(OVERSEAS)*
Acte dé décès (D'Outre-Mer)

NAME OF DECEASED *(Last, First, Middle)* Nom du décédé (Nom et prénoms)	GRADE Grade	BRANCH OF SERVICE Arme	SOCIAL SECURITY NUMBER Numéro de l'Assurance Social
BTB Muhammad, Bnayyan,		Civilian	(b)(6)
ORGANIZATION Organisation	NATION *(e.g. United States)* Pays	DATE OF BIRTH Date de naissance	SEX Sexe
	Iraq	(b)(6) 1931	[X] MALE [ ] FEMALE

RACE Race		MARITAL STATUS État Civil			RELIGION Culte		
	CAUCASOID Caucasique		SINGLE Célibataire		DIVORCED Divorcé		PROTESTANT Protestant
	NEGROID Negriode		MARRIED Marié		SEPARATED Séparé		CATHOLIC Catholique
X	OTHER (Specify) Autre (Spécifier)		WIDOWED Veuf				JEWISH Juif

OTHER (Specify) Autre (Spécifier)
X

NAME OF NEXT OF KIN Nom du plus proche parent	RELATIONSHIP TO DECEASED Parenté du décède avec le sus
STREET ADDRESS Domicilé à (Rue)	CITY OR TOWN OR STATE *(Include Zip Code* Ville (Code postal compris)

MEDICAL STATEMENT Déclaration médicale

	CAUSE OF DEATH (Enter only one cause per line) Cause du décès (N'indiquer qu'une cause par ligne)	INTERVAL BETWEEN ONSET AND DEATH Intervalle entre l'attaque et le décès
DISEASE OR CONDITON DIRECTLY LEADING TO DEATH [1] Maladie ou condition directement responsable de la mort. [1]	Acute and Organizing Diffuse Alveolar Damage	
ANTECEDENT CAUSES — MORBID CONDITION, IF ANY, LEADING TO PRIMARY CAUSE Condition morbide, s'il y a lieu, menant à la cause primaire		
Symptômes précurseurs de la mort. — UNDERLYING CAUSE, IF ANY, GIVING RISE TO PRIMARY CAUSE Condition morbide, s'il y a lieu, menant à la cause primaire		
OTHER SIGNIFICANT CONDITIONS [2] Autres conditions significatives [2]	Decubitus Ulcers	

MODE OF DEATH Condition de décès		AUTOPSY PERFORMED Autopsie effectuée [X] YES Oui [ ] NO Non	CIRCUMSTANCES SURROUNDING DEATH DUE TO EXTERNAL CAUSES Circonstances de la mort suscitées par des causes extérieures
X	NATURAL Mort naturelle	MAJOR FINDINGS OF AUTOPSY Conclusions principales de l'autopsie	
	ACCIDENT Mort accidentelle		
	SUICIDE Suicide	NAME OF PATHOLOGIST Nom du pathologiste (b)(6)	
	HOMICIDE Homicide	SIGNATURE (b)(6) DATE Date 4 December 2006	AVIATION ACCIDENT Accident à Avion [ ] YES Oui [X] NO Non

DATE OF DEATH *(day, month, year)* Date de décès (le jour, le mois, l'année)	PLACE OF DEATH Lieu de décès
(b)(6) 2006	Iraq

I HAVE VIEWED THE REMAINS OF THE DECEASED AND DEATH OCCURRED AT THE TIME INDICATED AND FROM THE CAUSES AS STATED ABOVE.
J'ai examiné les restes mortels du dé funtet je conclus que le décès est survenu à l'heure indiquée et à, la suite des causes énumérées ci-dessus.

NAME OF MEDICAL OFFICER Nom du médicin militaire ou du médicin sanitaire	TITLE OR DEGREE Titre ou diplômé
(b)(6)	Medical Examiner
GRADE Grade (b)(6)	INSTALLATION OR ADDRESS Installation ou adresse Dover AFB, Dover DE
DATE Date 1/18/2007	SIGNATURE (b)(6)

[1] State disease, injury or complication which caused death, but not mode of dying such as heart failure, etc.
[2] State conditions contributing to the death, but not related to the disease or condition causing death.
[1] Préciser la nature de la maladie, de la blessure ou de la complication qui a contribué à la mort, mais non la manière de mourir, telle qu'un arrêt du coeur, etc
[2] Préciser la condition qui a contribué à la mort, mais n'ayant aucun rapport avec la maladie ou à la condition qui a provoqué la mort.

DD FORM 1 APR 77 2064 REPLACES DA FORM 3565, 1 JAN 72 AND DA FORM 3565-R(PAS), 26 SEP 75, WHICH ARE OBSOLETE.

MEDCOM 0453

ACLU Detainee DeathII ARMY MEDCOM 453

ARMED FORCES INSTITUTE OF PATHOLOGY
Office of the Armed Forces Medical Examiner
1413 Research Blvd., Bldg. 102
Rockville, MD 20850
(301) 319-0000

FINAL AUTOPSY REPORT

Name: MUHAISIN, Jamil
Iraqi National Detainee (b)(6)
Date of Birth (b)(6) 1937
Date of Death: (b)(6) 2006
Date of Autopsy: 04 DEC 2006 @ 1230
Date of Report: 16 JAN 2007

Autopsy No: (b)(6)
AFIP No: (b)(6)
Rank: Civilian
Place of Death: Camp Bucca, Iraq
Place of Autopsy: Dover AFB Port Mortuary, Delaware

Circumstances of Death: (b)(6) was a 69 year-old male, Iraqi National, held as a detainee in Camp Bucca, Iraq. He reportedly suffered a myocardial infarction on 23 November which was complicated by post-infarction arrhythmias. Despite advanced care including cardioversion and intubation he died on (b)(6) 2006.

Authorization for Autopsy: Office of the Armed Forces Medical Examiner, in accordance with Title 10 US Code, Section 1471 (10 USC 1471)

Identification: Identification established by investigative agency

CAUSE OF DEATH: **Atherosclerotic Cardiovascular Disease**

MANNER OF DEATH: **Natural**

MEDCOM 0454
ACLU Detainee DeathII ARMY MEDCOM 454

AUTOPSY DIAGNOSES:

I.

A.Heart:
Cardiomegaly, 540 grams
Calcific stenosis, 60% of the left main coronary artery
Calcific stenosis, 99% of the proximal left anterior descending coronary artery
Stenosis, 80% of the proximal right coronary artery
Acute myocardial infarction, left ventriculo-septum
Severe aortic atherosclerosis with plaque erosions

B. Lungs:
Marked bilateral pleural and intraparenchymal anthrocotic pigment deposition
Marked pulmonary edema (combined lung weight 2000 gm)
Bilateral pulmonary effusions; 500 ml right, 400 left
Acute bronchopulmonary and lobar pneumonia
Emphysema

C. Kidneys: Arteriolonephrosclerosis

D. Thyroid Gland: Follicular adenoma and nodular hyperplasia

E. Prostate Gland: Benign nodular hyperplasia

II. No external injuries

III. Evidence of medical treatment includes placement of a nasogastric tube; endotracheal tube intravascular devices in the left side of the neck, both antecubital fossae, left wrist and left groin; needle puncture marks with surrounding ecchymosis on the back of the right hand; cardiac monitor/defibrillator pads on the anterior chest and abdomen; a Foley catheter is in the penis

IV. Toxicological examination:

VOLATILES: The blood and vitreous fluid are negative for ethanol at a cutoff level of 20 mg/dL.

CARBON MONOXIDE: The carboxyhemoglobin (COHgb) saturation in the blood is less than 1% as determined by spectrophotometry with a limit of quantitation of 1%. Saturations above 10% are considered elevated and are confirmed by gas chromatography.

CYANIDE: There is no cyanide detected in the blood. The limit of quantitation for cyanide is 0.25 mg/L. Normal blood cyanide concentrations are less than 0.15 mg/L. Lethal concentrations of cyanide are greater than 3 mg/L.

DRUGS: The blood is screened for amphetamine, antidepressants, antihistamines, barbiturates, benzodiazepines, cannabinoids, chloroquine, cocaine, dextromethorphan,

ACLU Detainee DeathII ARMY MEDCOM 455

lidocaine, narcotic analgesics, opiates, phencyclidine, phenothiazines, sympathomimetic amines and verapamil by gas chromatography, color test or immunoassay. The following drugs are detected:

- Benzodiazepine, Midazolam, is detected in the blood by immunoassay and confirmed by gas chromatography/mass spectrometry. The blood contains 0.08 mg/L of Midazolam as quantitated by gas chromatography/mass spectrometry.

- Benzodiazepine, Alphahydroxymidazolam (a metabolite of Midazolam), is detected in the blood by gas chromatography and confirmed by gas chromatography/mass spectrometry. The blood contains 0.03 mg/L of Alphahydroxymidazolam as quantitated by gas chromatography/mass spectrometry.

- Benzodiazepine, (Lorazepam), is detected in the blood by gas chromatography/mass spectrometry. The blood contains 0.033 mg/L of Lorazepam as quantitated by gas chromatography/mass spectrometry.

- Lidocaine is detected in the blood by immunoassay and confirmed by gas chromatography/mass spectrometry.

EXTERNAL EXAMINATION

The body is that of a well-developed 67-inch tall, 164 pound Caucasian male whose appearance is consistent with the reported age of 69-years. Lividity is fixed on the posterior aspect of the body and rigor has passed. The temperature is cold, that of the refrigeration unit.

The scalp is covered with brown hair with frontal balding and temporal greying. Facial hair consists of a brown mustache. The irides are brown and the pupils are round and equal in diameter. The external auditory canals are free of foreign material. The ears are unremarkable. The nares are patent and the lips are atraumatic. The nose and maxillae are palpably stable. The teeth are natural.

The neck is straight, and the trachea is midline and mobile. The chest is symmetric. The abdomen is moderately protuberant. The genitalia are those of a normal adult circumcised male. The testes are descended and free of masses. Pubic hair is present in a normal distribution. The buttocks and anus are unremarkable.

The upper and lower extremities are symmetric and without clubbing or edema.

CLOTHING AND PERSONAL EFFECTS

The deceased is unclad and personal effects are not present on the body at the time of autopsy.

ACLU Detainee DeathII ARMY MEDCOM 456

MEDICAL INTERVENTION

Evidence of medical treatment includes placement of a nasogastric tube and endotracheal tube; intravascular devices in the left side of the neck, both antecubital fossae, left wrist and left groin; needle puncture marks with surrounding ecchymosis are on the back of the right hand; cardiac monitor/defibrillator pads on the anterior chest and abdomen; a Foley catheter is in the penis

RADIOGRAPHS

A complete set of postmortem radiographs is obtained and shows no acute injuries or abnormalities.

EVIDENCE OF INJURY

There are no external injuries.

INTERNAL EXAMINATION

HEAD: The galeal and subgaleal soft tissues of the scalp are free of injury. The calvarium is intact, as is the dura mater beneath it. Clear cerebrospinal fluid surrounds the 1320 gm brain, which has unremarkable gyri and sulci. Coronal sections demonstrate sharp demarcation between white and grey matter, without hemorrhage or contusive injury. The ventricles are of normal size. The basal ganglia, brainstem, cerebellum, and arterial systems are free of injury or other abnormalities. There are no skull fractures. The atlanto-occipital joint is stable.

NECK: The anterior strap muscles of the neck are homogenous and red-brown, without hemorrhage. The thyroid cartilage and hyoid are intact. The larynx is lined by intact white mucosa.

The thyroid gland is bilaterally enlarged and nodular with cystic changes, greater on the right than left. A well circumscribed 1 cm nodule is on the left lobe and frequent cysts, ranging in size from 1 to 2 cm, are present. The right lobe shows several cysts ranging from 1 to 3 cm in greatest dimension. A poorly defined 2 cm nodule is present and on sectioning contains dark brown fluid.

The tongue is free of bite marks, hemorrhage, or other injuries.

Incision and dissection of the posterior neck demonstrates no deep paracervical muscular injury and no cervical spine fractures. Longitudinal incisions of the back, buttocks, thighs, ankles and wrist show no evidence of injuries.

BODY CAVITIES: The ribs, sternum, and vertebral bodies are visibly and palpably intact. No excess fluid is in the pericardial or peritoneal cavities. The right chest cavity contains 500 ml of serosanguinous fluid and the left contains 400 ml of serosanguinous fluid. The organs occupy their usual anatomic positions.

ACLU Detainee DeathII ARMY MEDCOM 457

RESPIRATORY SYSTEM: The right and left lungs are grossly edematous and weigh 1140 and 860 gm, respectively. Bilateral pleural adhesions are easily broken with gentle dissection. The external surfaces are otherwise smooth and deep red-purple with marked deposition of anthracotic pigment on the pleura and within the lung parenchyma. The pulmonary parenchyma is markedly congested and edematous. No mass lesions or areas of consolidation are present.

CARDIOVASCULAR SYSTEM: The 540 gm heart is contained in an intact pericardial sac. The epicardial surface is smooth, with minimal fat investment. The coronary arteries are present in a normal distribution, with a right dominant pattern. Cross sections of the vessels show marked atherosclerosis:

- 99% (pinpoint lumen) calcific stenosis of the proximal left anterior descending coronary artery
- 80% calcific stenosis of the proximal to mid right coronary artery
- 60% calcific stenosis of the left coronary artery

The myocardium is homogenous, red-brown, and firm. The valve leaflets are thin and mobile. The walls of the left and right ventricles are 1.7 cm and 0.5 cm thick, respectively. The endocardium is smooth and glistening. A definitive area of myo-necrosis is not identified. The aorta shows marked erosive atherosclerosis along the thoracic and abdominal segments.

LIVER & BILIARY SYSTEM: The 1960 gm liver has an intact, smooth capsule and a sharp anterior border. The parenchyma is tan-brown and congested, with the usual lobular architecture. No mass lesions or other abnormalities are seen. The gallbladder contains 35 ml of green-black bile and no stones. The mucosal surface is green and velvety. The extrahepatic biliary tree is patent.

SPLEEN: The 260 gm spleen has a smooth, intact, red-purple capsule. The parenchyma is maroon and congested, with distinct Malpighian corpuscles.

PANCREAS: The pancreas is firm and yellow-tan, with the usual lobular architecture. No mass lesions or other abnormalities are seen.

ADRENALS: The right and left adrenal glands are symmetric, with yellow cortices and grey medullae. No masses or areas of hemorrhage are identified.

GENITOURINARY SYSTEM: The right and left kidneys are nodular; the right kidney weighs 160 gm and the left weighs 140 gm. The external surfaces are rough and granular and the capsules strip with difficulty from the cortical surfaces. The cut surfaces are red-tan and congested and the corticomedullary junctions are poorly demarcated. The pelves are unremarkable and the ureters are normal in course and caliber. White bladder mucosa overlies an intact bladder wall. The bladder is empty. The prostate is moderately enlarged, with lobular, yellow-tan parenchyma. A 1-cm, well circumscribed nodule occupies the right lobe. The seminal vesicles are unremarkable. The testes are free of mass lesions, contusions, or other abnormalities.

ACLU Detainee DeathII ARMY MEDCOM 458

GASTROINTESTINAL TRACT: The esophagus is intact and lined by smooth, grey-white mucosa. The stomach contains approximately 50 ml of dark brown fluid. The gastric wall is intact. The duodenum, loops of small intestine and colon are unremarkable. The appendix is present.

MICROSCOPIC EXAMINATION

Selected portions of organs are retained in formalin with preparation of the following histologic slides:

1. Brain: frontal cortex and hippocampus – no pathologic abnormality
2. Brain: pons - no pathologic abnormality
3. Brain: cerebellum - no pathologic abnormality
4. Thyroid gland, left – follicular adenoma, 1cm
5/6. Thyroid gland, right – nodular hyperplasia (adenomatous goiter); follicular adenoma, 0.5 cm
7. Prostate gland – benign prostatic hyperplasia
8. Coronary artery, proximal LAD – confirms the gross observation
9. Coronary arteries, left and right – confirms the gross observation
10. Heart, left ventricle: acute inflammation with myocyte necrosis and contraction bands
11. Hearts: septum - acute inflammation with myocyte necrosis and contraction bands
    right ventricle - no pathologic abnormality
12. Aorta: severe atherosclerosis
13. Liver: centro-lobular congestion
    Kidney: hyaline arteriolosclerosis; interstitial fibrosis
14/15. Lung: acute bronchopulmonary and lobar pneumonia; emphysematous change

ADDITIONAL PROCEDURES

- Documentary photographs are taken by the OAFME Photographer
- Specimens retained for toxicological testing and/or DNA identification are: vitreous fluid, blood, bile, liver, spleen, kidney, lung, brain, psoas muscle and gastric contents
- The dissected organs are forwarded with the body
- Personal effects are released to the appropriate mortuary operations representatives.

ACLU Detainee DeathII ARMY MEDCOM 459

Muhaisin (b)(6)

OPINION

Based on these autopsy findings and the investigative information available to me, the cause of death of (b)(6) is severe atherosclerotic cardiovascular disease complicated by an acute myocardial infarction and acute pneumonia. Additional incidental autopsy findings (non contributory to the cause of death) include a follicular adenoma and nodular hyperplasia of the thyroid gland and benign hypertrophy of the prostate gland. Toxicology findings show medications consistent with hospital care and resuscitation.

The manner of death is natural.

(b)(6)

Armed Forces Medical Examiner System

ACLU Detainee DeathII ARMY MEDCOM 460

CERTIFICATE OF DEATH *(OVERSEAS)*
Acte de décès (D'Outre-Mer)

NAME OF DECEASED *(Last, First, Middle)* Nom du décédé (Nom et prénoms)	GRADE Grade	BRANCH OF SERVICE Arme	SOCIAL SECURITY NUMBER Numéro de l'Assurance Social
BTB Muhaisin, Jamil,		Civilian	(b)(6)

ORGANIZATION Organisation	NATION *(e.g. United States)* Pays	DATE OF BIRTH Date de naissance	SEX Sexe
	Iraq		[X] MALE [ ] FEMALE

RACE Race		MARITAL STATUS État Civil			RELIGION Culte		
	CAUCASOID Caucasique		SINGLE Célibataire		PROTESTANT Protestant		OTHER (Specify) Autre (Spécifier)
	NEGROID Negriode		MARRIED Marié	DIVORCED Divorcé	CATHOLIC Catholique	X	
X	OTHER (Specify) Autre (Spécifier)		WIDOWED Veuf	SEPARATED Séparé	JEWISH Juif		

NAME OF NEXT OF KIN Nom du plus proche parent	RELATIONSHIP TO DECEASED Parenté du décédé avec le sus
STREET ADDRESS Domicilé à (Rue)	CITY OR TOWN OR STATE *(Include ZIP Code* Ville (Code postal compris)

MEDICAL STATEMENT Déclaration médicale

CAUSE OF DEATH (Enter only one cause per line) Cause du décès (N'indiquer qu'une cause par ligne)			INTERVAL BETWEEN ONSET AND DEATH Intervalle entre l'attaque et le décès
DISEASE OR CONDITON DIRECTLY LEADING TO DEATH [1] Maladie ou condition directement responsable de la mort.		Atherosclerotic Cardiovascular Disease	
ANTECEDENT CAUSES Symptômes précurseurs de la mort.	MORBID CONDITION, IF ANY, LEADING TO PRIMARY CAUSE Condition morbide, s'il y a lieu, menant à la cause primaire		
	UNDERLYING CAUSE, IF ANY, GIVING RISE TO PRIMARY CAUSE Condition morbide, s'il y a lieu, menant à la cause primaire		
OTHER SIGNIFICANT CONDITIONS [2] Autres conditions significatives [2]			

MODE OF DEATH Condition de décès		AUTOPSY PERFORMED Autopsie effectuée [X] YES Oui [ ] NO Non	CIRCUMSTANCES SURROUNDING DEATH DUE TO EXTERNAL CAUSES Circonstances de la mort suscitées par des causes extérieures
X	NATURAL Mort naturelle	MAJOR FINDINGS OF AUTOPSY Conclusions principales de l'autopsie	
	ACCIDENT Mort accidentelle		
	SUICIDE Suicide	NAME OF PATHOLOGIST Nom du pathologiste (b)(6)	
	HOMICIDE Homicide	SIGNATURE (b)(6) DATE Date 4 December 2006	AVIATION ACCIDENT Accident à Avion [ ] YES Oui [X] NO Non

DATE OF DEATH *(day, month, year)* Date de décès (le jour, le mois, l'année)	PLACE OF DEATH Lieu de décès
(b)(6) 2006	

I HAVE VIEWED THE REMAINS OF THE DECEASED AND DEATH OCCURRED AT THE TIME INDICATED AND FROM THE CAUSES AS STATED ABOVE.
J'ai examiné les restes mortels du dé funtet je conclus que le décès est survenu à l'heure indiquée et à, la suite des causes énumérées ci-dessus.

NAME OF MEDICAL OFFICER Nom du médecin militaire ou du médecin assimilé	TITLE OR DEGREE Titre ou diplômé
(b)(6)	Medical Examiner

GRADE Grade	INSTALLATION OR ADDRESS Installation ou adresse
(b)(6)	Dover AFB, Dover DE
DATE Date 12/27/2006	SIGNATURE (b)(6)

[1] State disease, injury or complication which caused death, but not mode of dying such as heart failure, etc.
[2] State conditions contributing to the death, but not related to the disease or condition causing death.
[1] Préciser la nature de la maladie, de la blessure ou de la complication qui a contribué à la mort, mais non la manière de mourir, telle qu'un arrêt du coeur, etc.
[2] Préciser la condition qui a contribué à la mort, mais n'ayant aucun rapport avec la maladie ou à la condition qui a provoqué la mort.

DD FORM 1 APR 77 2064 REPLACES DA FORM 3566, 1 JAN 72 AND DA FORM 3566-R(PAS), 26 SEP 75, WHICH ARE OBSOLETE.

MEDCOM 0461

ACLU Detainee DeathII ARMY MEDCOM 461

ARMED FORCES INSTITUTE OF PATHOLOGY
Office of the Armed Forces Medical Examiner
1413 Research Blvd., Bldg. 102
Rockville, MD 20850
1-301-319-0000

FINAL AUTOPSY EXAMINATION REPORT

Name: FURAYH AL MEHLAWY,
Muntasir Hamad
SSAN: (b)(6)
Date of Birth: (BTB) (b)(6) 1988
Date of Death (b)(6) 2006
Date/Time of Autopsy: 4 Nov 2006 @ 1000
Date of Report: 18 Jan 2007

Autopsy No.: (b)(6)
AFIP No. (b)(6)
Rank: Iraqi Civilian Detainee
Place of Death: Al Qailm, Iraq
Place of Autopsy: Port Mortuary, Dover AFB, DE

Circumstances of Death: This 18 year-old Iraqi Civilian Detainee was found unresponsive on his sleeping mat after reportedly being strangled by another detainee.

Authorization for Autopsy: Office of the Armed Forces Medical Examiner, IAW 10 USC 1471.

Identification: Presumptive identification is established by a wrist identification band. A DNA sample is taken for profile purposes if an exemplar becomes available for positive identification.

CAUSE OF DEATH: **ASPHYXIATION DUE TO LIGATURE STRANGULATION**

MANNER OF DEATH: **HOMICIDE**

ACLU Detainee DeathII ARMY MEDCOM 462

FINAL AUTOPSY DIAGNOSES

VI. Evidence of Ligature Strangulation
- A. There is a circumferential, discontinuous superficial patterned abrasion on the neck demonstrating 1/16-inch periodicity, directed horizontally
- B. The abrasion crosses the superior 1/3 of the thyroid cartilage 10 ½-inches below the top of the head and extends on both sides of the neck, passing 1 ¾-inches below both ears, and measuring up to ½-inch in width
- C. The layer-wise anterior neck dissection demonstrates hemorrhage in the deep musculature (cricothyroid muscles), bilaterally
- D. Associated injuries
  1. The hyoid bone and thyroid cartilage are intact
  2. The posterior neck dissection demonstrates no injury to the underlying soft tissue
  3. There is confluent petechiae in the valleculae of the larynx, bilaterally
  4. Petechiae are present on the mucosa of the lower lip and the right and left bulbar and inferior palpebral conjunctivae
  5. Congestion of both lungs (right lung 600-grams, left lung 500-grams) and froth in both mainstem bronchi

II. No significant natural disease is identified within the limitations of this examination

III. There is no evidence of medical therapy

IV. Identifying Body Marks or Tattoos
- A. Scar, left upper chest, 1-inch
- B. Scar, left elbow, 1-inch

V. There is no evidence of physical abuse

VI. Toxicology (AFIP)
- A. Volatiles: No ethanol is detected in the blood and bile
- B. Drugs: No drugs of abuse or medications are detected in the blood
- C. Carbon Monoxide: The carboxyhemoglobin saturation in the blood is less than 1%
- D. Cyanide: No cyanide is detected in the blood

ACLU Detainee DeathII ARMY MEDCOM 463

EXTERNAL EXAMINATION

The body is that of a well-developed, well-nourished appearing, muscular, 70-inch, 126-pound male whose appearance is consistent with the reported age of 18 years. Lividity is fixed and posterior (except in areas exposed to pressure), rigor is absent, and the temperature is that of the refrigeration unit.

The scalp is covered with 3-inch brown hair in a normal distribution. The irides are brown, the corneae are cloudy and the pupils are round and equal in diameter. There are petechiae in both inferior palpebral conjunctivae and on both bulbar conjunctivae. The external auditory canals are clear, and the ears are unremarkable. The nares are patent. There are petechiae on the mucosa of the lower lip. The nose and maxillae are palpably stable. The teeth appear natural and in good condition.

The neck is straight, and the trachea is midline and mobile. The chest is symmetric with a 1-inch scar on the upper left chest. The abdomen is flat with greenish discoloration. The genitalia are those of a normal adult circumcised male. The testes are descended and free of masses. Pubic hair is present in a normal distribution. The posterior torso is unremarkable. The buttocks and anus are unremarkable.

The upper and lower extremities are symmetric and without clubbing or edema. There is a 1-inch scar on the left elbow.

CLOTHING AND PERSONAL EFFECTS

The following clothing items and personal effects are present on the body at the time of autopsy:

- Orange shirt and pants
- White boxer shorts
- White T-shirt

MEDICAL INTERVENTION

- There is no evidence of medical intervention

RADIOGRAPHS

A complete set of postmortem radiographs is obtained and demonstrates the following:

- No fractures or metallic foreign bodies are identified

ACLU Detainee DeathII ARMY MEDCOM 464

EVIDENCE OF INJURY

There is a circumferential, discontinuous superficial patterned abrasion on the neck demonstrating 1/16-inch periodicity that is directed horizontally. The abrasion crosses the superior one-third of the thyroid cartilage 10 ½-inches below the top of the head and then extends on both sides of the neck, passing 1 ¾-inches below each ear, measuring up to ½-inch in width. The layer-wise anterior neck dissection demonstrated hemorrhage in the deep musculature (cricothyroid muscles), bilaterally. The hyoid bone and thyroid cartilage were intact. The posterior neck dissection demonstrated no injury to the underlying soft tissue. The valleculae of the larynx demonstrate confluent petechiae, bilaterally. Petechiae were present on the inner lower lip, both sclerae, and both inferior conjunctivae.

INTERNAL EXAMINATION

HEAD AND CENTRAL NERVOUS SYSTEM:
The galeal and subgaleal soft tissues of the scalp are free of injury. The calvarium is intact, as is the dura mater beneath it. Clear cerebrospinal fluid surrounds the 1530-gram brain, which has unremarkable gyri and sulci. Coronal sections demonstrate sharp demarcation between white and grey matter, without hemorrhage or contusive injury. The ventricles are of normal size. The basal ganglia, brainstem, cerebellum, and arterial systems are free of injury or other abnormalities. There are no skull fractures. The atlanto-occipital joint is stable.

NECK:
See "Evidence of Injury," above. The thyroid gland is symmetric and red-brown, without cystic or nodular change. The tongue is free of bite marks, hemorrhage, or other injuries.

BODY CAVITIES:
The ribs, sternum, and vertebral bodies are visibly and palpably intact. No excess fluid is in the pleural, pericardial, or peritoneal cavities. The organs occupy their usual anatomic positions.

RESPIRATORY SYSTEM:
The right and left lungs weigh 600 and 500-grams, respectively. The external surfaces are smooth and deep red-purple. There is froth in both mainstem bronchi. The pulmonary parenchyma is diffusely congested and edematous. No mass lesions or areas of consolidation are present.

CARDIOVASCULAR SYSTEM:
The 300-gram heart is contained in an intact pericardial sac. The epicardial surface is smooth, with minimal fat investment. The coronary arteries are present in a normal distribution, with a right-dominant pattern. Cross sections of the vessels show no luminal narrowing. The myocardium is homogenous, red-brown, and firm. The valve leaflets are thin and mobile. The walls of the left and right ventricles are 0.6 and 0.2-cm thick, respectively. The endocardium is smooth and glistening. The aorta gives rise to three intact and patent arch vessels. The renal and mesenteric vessels are unremarkable.

ACLU Detainee DeathII ARMY MEDCOM 465

LIVER & BILIARY SYSTEM:
The 1500-gram liver has an intact, smooth capsule and a sharp anterior border. The parenchyma is tan-brown and congested, with the usual lobular architecture. No mass lesions or other abnormalities are seen. The gallbladder contains 2-milliliters of green-black bile and no stones. The mucosal surface is green and velvety. The extrahepatic biliary tree is patent.

SPLEEN:
The 100-gram spleen has a smooth, intact, red-purple capsule. The parenchyma is maroon and congested, with distinct Malpighian corpuscles.

PANCREAS:
The pancreas is firm and yellow-tan, with the usual lobular architecture. No mass lesions or other abnormalities are seen.

ADRENALS:
The right and left adrenal glands are symmetric, with bright yellow cortices and grey medullae. No masses or areas of hemorrhage are identified.

GENITOURINARY SYSTEM:
The right and left kidneys weigh 100-grams each. The external surfaces are intact and smooth. The cut surfaces are red-tan and congested, with uniformly thick cortices and sharp corticomedullary junctions. The pelves are unremarkable and the ureters are normal in course and caliber. Gray-pink bladder mucosa overlies an intact bladder wall. The bladder contains no urine. The prostate is normal in size, with lobular, yellow-tan parenchyma. The seminal vesicles are unremarkable. The testes are free of mass lesions, contusions, or other abnormalities.

GASTROINTESTINAL TRACT:
The esophagus is intact and lined by smooth, gray-white mucosa. The stomach contains approximately 400-milliliters of semi-solid food material. The gastric wall is intact. The duodenum, loops of small bowel and colon are unremarkable. The appendix is absent.

MUSCULOSKELETAL SYSTEM:
There are no bone or joint abnormalities. Skeletal muscle development is normal. Superficial posterior incisions of the torso and extremities are negative for soft tissue hemorrhage.

ACLU Detainee DeathII ARMY MEDCOM 466

MICROSCOPIC EXAMINATION

Selected portions of organs are retained in formalin, with preparation of histological slides of the following organs: heart, lung, liver, kidney, and brain. The findings are:

1. Lungs: Pulmonary edema and vascular congestion
   Heart: No significant microscopic abnormalities
2. Kidney and Liver: No significant microscopic abnormalities
3. Brain: No significant microscopic abnormalities

ADDITIONAL PROCEDURES

- Documentary photographs are taken by OAFME staff photographers
- Specimens retained for toxicologic testing and/or DNA identification are: vitreous humor, blood, spleen, liver, bile, gastric contents, kidney, lung, brain, adipose tissue and psoas
- The dissected organs are forwarded with body
- Personal effects are released to the appropriate mortuary operations representatives

OPINION

This 18 year-old Iraqi detainee died as a result of asphyxiation due to ligature strangulation. There was a circumferential, discontinuous superficial patterned abrasion on the neck. The anterior neck dissection demonstrated hemorrhage in the deep musculature (cricothyroid muscles), bilaterally. The hyoid bone and thyroid cartilage were intact. The posterior neck dissection demonstrated no injury to the underlying soft tissue. The valleculae of the larynx demonstrated hemorrhage bilaterally. Petechiae were present on the mucosa of the lower lip, both sclerae, and both inferior eyelids. There was no evidence of physical abuse. Microscopic studies were non-contributory to the cause of death. Toxicology studies were negative for ethanol and drugs of abuse. The manner of death is homicide.

(b)(6)

(b)(6) Medical Examiner

(b)(6)

(b)(6) Medical Examiner

(b)(6)

ACLU Detainee DeathII ARMY MEDCOM 467

CERTIFICATE OF DEATH *(OVERSEAS)*
Acte dé décès (D'Outre-Mer)

NAME OF DECEASED *(Last, First, Middle)* Nom du décédé (Nom et prénoms)	GRADE Grade	BRANCH OF SERVICE Arme	SOCIAL SECURITY NUMBER Numéro de l'Assurance Social
BTB Furayh Al Mehlaw, Muntasir, Hamad		Civilian	(b)(6)

ORGANIZATION Organisation	NATION *(e.g. United States)* Pays	DATE OF BIRTH Date de naissance	SEX Sexe
	Iraq	(b)(6) 1988	[X] MALE [ ] FEMALE

RACE Race		MARITAL STATUS État Civil			RELIGION Culte		
	CAUCASOID Caucasique		SINGLE Célibataire		DIVORCED Divorcé		PROTESTANT Protestant		OTHER (Specify) Autre (Spécifier)
	NEGROID Negroide		MARRIED Marié		SEPARATED Séparé		CATHOLIC Catholique	X	Muslim
X	OTHER (Specify) Autre (Spécifier)		WIDOWED Veuf				JEWISH Juif		

NAME OF NEXT OF KIN Nom du plus proche parent	RELATIONSHIP TO DECEASED Parenté du décédé avec le sus
STREET ADDRESS Domicilé à (Rue)	CITY OR TOWN OR STATE *(Include ZIP Code* Ville (Code postal compris)

MEDICAL STATEMENT Déclaration médicale

CAUSE OF DEATH (Enter only one cause per line) Cause du décès (N'indiquer qu'une cause par ligne)		INTERVAL BETWEEN ONSET AND DEATH Intervalle entre l'attaque et le décès
DISEASE OR CONDITON DIRECTLY LEADING TO DEATH[1] Maladie ou condition directement responsable de la mort[1]	Asphyxia due to ligature strangulation	Minutes
ANTECEDENT CAUSES Symptômes précurseurs de la mort — MORBID CONDITION, IF ANY, LEADING TO PRIMARY CAUSE Condition morbide, s'il y a lieu menant à la cause primaire		
UNDERLYING CAUSE, IF ANY, GIVING RISE TO PRIMARY CAUSE Condition morbide, s'il y a lieu menant à la cause primaire		
OTHER SIGNIFICANT CONDITIONS[2] Autres conditions significatives[2]		

MODE OF DEATH Condition de décès	AUTOPSY PERFORMED Autopsie effectuée [X] YES Oui [ ] NO Non	CIRCUMSTANCES SURROUNDING DEATH DUE TO EXTERNAL CAUSES Circonstances de la mort suscitées par des causes extérieures
NATURAL Mort naturelle	MAJOR FINDINGS OF AUTOPSY Conclusions principales de l'autopsie	
ACCIDENT Mort accidentelle		
SUICIDE Suicide	NAME OF PATHOLOGIST Nom du pathologiste (b)(6)	
X HOMICIDE Homicide	SIG (b)(6)	DATE Date 4 November 2006 — AVIATION ACCIDENT Accident à Avion [ ] YES Oui [X] NO Non

DATE OF DEATH *(day, month, y* Date de décès (le jour, le mois, l'année)	u de décès
(b)(6) 2006	Al Qailm Iraq

I HAVE VIEWED THE REMAINS OF THE DECEASED AND DEATH OCCURRED AT THE TIME INDICATED AND FROM THE CAUSES AS STATED ABOVE.
J'ai examiné les restes mortels du dé funtet je conclus que le décès est survenu à l'heure indiquée et à la suite des causes énumérées ci-dessus

NAME OF MEDICAL OFFICER Nom du médecin médecin ou du médecin spécialiste	TITLE OR DEGREE Titre ou diplômé
(b)(6)	Medical Examiner

GRADE Grade	INSTALLATION OR ADDRESS Installation ou adresse
(b)(6)	Dover AFB, Dover DE

DATE Date	SIGNATU
9 NOV 06	(b)(6)

[1] State disease, injury or complication which caused death, but not mo
[2] State conditions contributing to the death, but not related to the disea
[1] Préciser la nature de la maladie, de la blessure ou de la complication
[2] Préciser la condition qui a contribué à la mort, mais n'ayant aucun rapport avec la maladie ou à la condition qui a provoqué la mort

DD FORM 1 APR 77 2064 REPLACES DA FORM 3565, 1 JAN 72 AND DA FORM 3565-R(PAS), 26 SEP 75, WHICH ARE OBSOLETE.

ARMED FORCES INSTITUTE OF PATHOLOGY
Office of the Armed Forces Medical Examiner
1413 Research Blvd., Bldg. 102
Rockville, MD 20850
(301) 319-0000

FINAL AUTOPSY REPORT

Name: HAMID, Fadil Jadua
Interment Serial (b)(6)
Date of Birth: (b)(6) 1978
Date of Death (b)(6) 2006
Date of Autopsy: 25 OCT 2006 @ 1230
Date of Report: 14 FEB 2007

Autopsy No: (b)(6)
AFIP No (b)(6)
Place of Death: Camp Bucca, Iraq
Place of Autopsy: Dover AFB Port Mortuary, Delaware

Circumstances of Death: (b)(6) was a 28 year-old male, Iraqi National, held as a detainee in Camp Bucca, Iraq. He was discovered unresponsive in his room by cellmates. Resuscitation efforts, including advanced life support measures, were unsuccessful by medical personnel and he was pronounced dead at 1048 (b)(6) 2006.

Authorization for Autopsy: Office of the Armed Forces Medical Examiner, in accordance with Title 10 US Code, Section 1471 (10 USC 1471).

Identification: Positive identification established by investigative agency

CAUSE OF DEATH: **Probable Cardiac Arrhythmia Secondary to Concentric Left Ventricular Hypertrophy**

MANNER OF DEATH: **Natural**

AUTOPSY FINDINGS:

I. A. Heart: 470 grams
Concentric left ventricular hypertrophy (see cardiac consultation page 5)
Coronary arteries widely patent

B. Lungs:
Bilateral pulmonary edema (combined weight 1450 grams)

C. No external injuries

MEDCOM 0469
ACLU Detainee DeathII ARMY MEDCOM 469

II. Toxicological Examination:

- VOLATILES: The blood and urine are negative for ethanol at a cutoff level of 20 mg/dL.
- Peripheral blood contains less than 1% carboxyhemoglobin (COHgb) determined by spectrophotometry with a limit of quantitation of 1%. COHgb saturations of 0-3% are expected for non-smokers and 3-10% for smokers. Saturations above 10% are considered elevated and are confirmed by gas chromatography.
- There is no cyanide detected in the blood. The limit of quantitation for cyanide is 0.25 mg/L. Normal blood cyanide concentrations are less than 0.15 mg/L. Lethal concentrations of cyanide are greater than 3 mg/L.
- DRUGS: The blood is screened for acetaminophen, amphetamine, antidepressants, antihistamines, barbiturates, benzodiazepines, cannabinoids, chloroquine, cocaine, dextromethorphan, lidocaine, narcotic analgesics, opiates, phencyclidine, phenothiazines, salicylates, sympathomimetic amines and verapamil by gas chromatography, color test or immunoassay. The following drug is detected:
    - Lidocaine is detected in the blood by gas chromatography and confirmed by gas chromatography/mass spectrometry.

EXTERNAL EXAMINATION

The body is that of a well-developed, well-nourished, 70 ½-inches tall, 178 pound Caucasian male who appears older than his reported age of 28 years. Lividity is marked and fixed on the posterior aspect of the body. Rigor is passing and the temperature is cold, that of the refrigerator. An identification tag is around the right great toe.

The scalp is covered with black hair in a normal distribution. Facial hair consists of a black beard. The irides are brown and the pupils are round and equal in diameter. The external auditory canals are clear. The ears are unremarkable. The nares are patent and the lips are atraumatic. The nose and maxillae are palpably stable. The teeth are natural.

The neck is straight, and the trachea is midline and mobile. The chest is symmetric. The abdomen is flat. The genitalia are those of a normal adult circumcised male. The testes are descended and free of masses. Pubic hair is present in a normal distribution. The buttocks and anus are unremarkable.

The upper and lower extremities are symmetric and without clubbing or edema.

CLOTHING AND PERSONAL EFFECTS

The following clothing items are present on the body at the time of autopsy:

- Yellow colored boxer shorts
- Yellow colored t-shirt
- Yellow colored long pants
- Personal effects are not present with the body

ACLU Detainee DeathII ARMY MEDCOM 470

MEDICAL INTERVENTION

- Endotracheal intubation
- Intravenous catheters in the right arm and groin
- Foley catheter in the penis
- Cardiac monitor pad on the left upper back

RADIOGRAPHS

- A complete set of postmortem radiographs is obtained and demonstrates no traumatic injuries.

EVIDENCE OF INJURY

There are no external injuries.

INTERNAL EXAMINATION

HEAD: The galeal and subgaleal soft tissues of the scalp are free of injury. The calvarium is intact, as is the dura mater beneath it. There are no skull fractures. Clear cerebrospinal fluid surrounds the 1630gm brain, which has unremarkable gyri and sulci. The atlanto-occipital joint is stable.

The brain is referred for consultation at the AFIP Neuropathology Department and their report follows:

We examined the 1630 gram formalin-fixed brain submitted in reference to this case. Some unremarkable cerebral dura is received; no dural hemorrhage or sinus thrombosis is seen. The leptomeninges are clear with slight congestion; no exudate or hemorrhage is identified. The cerebral hemispheres are symmetric, with mildly compressed gyri that are normal in configuration. No softening or contusion is identified. The cranial nerve stumps are unremarkable. The circle of Willis has a normal configuration. No aneurysm, atherosclerosis, or occlusion is found in the intracranial arteries. The brain stem and cerebellum are externally normal. No subfalcial, transtentorial, or tonsillar herniation is seen. Coronal sections of cerebrum show no abnormalities in cortex, white matter, or deep gray matter nuclei. The lateral and 3rd ventricles are grossly normal. The hippocampi are symmetric and normal in size.

ACLU Detainee DeathII ARMY MEDCOM 471

Horizontal sections of the brain stem and cerebellum reveal unremarkable cut surfaces. The substantia nigra and locus ceruleus are normally pigmented. The aqueduct is patent. The 4th ventricle is grossly normal. The spinal cord is not available for examination.

Histological sections: 1. Right superior/middle frontal gyri (superior inked black). 2. Right interior parietal lobule. 3. Right superior/middle temporal gyri at level of mamillary bodies (superior inked black). 4. Bilateral cingulated gyri (left inked black). 5. Right calcarine fissure with basal occipital gyri. 6. Right hippocampus at level of mamillary bodies. 7. Right hippocampus at level of lateral geniculate nucleus. 8. Right caudate/putamen with basal forebrain. 9. Right putamen/pallidum. 10. Bilateral thalamus/hypothalamus at level of mamillary bodies (left inked black). 11. Right thalamus at subthalamic nucleus. 12. Midbrain with substantia nigra (left inked black).13. Pons (left inked black). 14. Medulla (left inked black). 15. Right cerebellum with dentate nucleus and folia. 16. Medullary-cervical junction (left inked black). 17. Left hippocampus at level of lateral geniculate nucleus. All tissue sections were processed in paraffin; sections were stained with H&E. This material was reviewed in conference by staff of the Department of Neuropathology and Ophthalmic Pathology.

Histological sections show scattered areas of acute neuronal injury in the deeper layers of the cerebral cortex, deep grapy matter nuclei, hippocampi (CA1 and dentate gyrus)., and cerebellum (Purkinje cells). Hippocampal sclerosis is not identified. A single small focus of perivascular chronic inflammatory cells is noted in the right hippocampus at the level of the mamillary body. Some scattered blood vessels throughout the brain have small numbers of perivascular hemosiderin-laden macrophages.

The brain shows acute neuronal injury, a non-specific finding that is commonly associated with hypoxic-ischemic change. Features diagnostic for malformation, storage disease, infection or neoplasm are not identified. No contusion or acute hemorrhage is seen.

NECK: The anterior strap muscles of the neck are homogenous and red-brown, without hemorrhage. The thyroid cartilage and hyoid bone are intact. The larynx is lined by intact white mucosa. The thyroid is symmetric and red-brown, without cystic or nodular change. The tongue is free of bite marks, hemorrhage, or other injuries.

Incision and dissection of the posterior neck demonstrates no deep paracervical muscular injury and no cervical spine fractures.

BODY CAVITIES: The ribs, sternum, and vertebral bodies are visibly and palpably intact. No excess fluid is in the pleural, pericardial or peritoneal cavities. The organs occupy their usual anatomic positions.

RESPIRATORY SYSTEM: The right and left lungs are markedly edematous and weigh 730 and 720 gm, respectively. The external surfaces are smooth and deep red-purple. The pulmonary parenchyma is diffusely congested and edematous. No mass lesions or areas of consolidation are present.

ACLU Detainee DeathII ARMY MEDCOM 472

CARDIOVASCULAR SYSTEM: The 470 gm heart is mildly enlarged and is contained in an intact pericardial sac. The heart is referred for consultation at the CV Path Institute and their report follows:

DIAGNOSIS: (b)(6) **Concentric left ventricular hypertrophy**

Heart: 470 grams (predicted normal value 350 grams, upper limit 463 grams for a 178lbs man); normal epicardial fat; closed foramen ovale; concentric left ventricular hypertrophy: left ventricular cavity diameter 35mm, left ventricular free wall thickness 15mm, ventricular septum thickness 17mm, right ventricle thickness 5mm, without gross scars or abnormal fat infiltrates; grossly unremarkable valves and endocardium; no gross myocardial fibrosis or necrosis; histologic sections show mild left ventricular myocyte hypertrophy, otherwise unremarkable.

Coronary arteries: Normal ostia; right dominance; no gross atherosclerosis

Conduction system: The sinoatrial node and nodal artery are unremarkable. The compact atrioventricular (AV) node shows mild fragmentation within the central fibrous body, without inflammation, necrosis, increased fat or proteoglycan. The penetrating bundle is centrally located and unremarkable. The left proximal bundle branch is intact and unremarkable. The right bundle branch is not seen in these sections. There are no discernible bypass tracts between the AV node and ventricular septum. There is no dysplasia of the AV nodal artery.

LIVER & BILIARY SYSTEM: The 1820 gm liver has an intact, smooth capsule and a sharp anterior border. The parenchyma is tan-brown and congested, with the usual lobular architecture. No mass lesions or other abnormalities are seen. The gallbladder contains 5 ml of green-black bile and no stones. The mucosal surface is green and velvety. The extrahepatic biliary tree is patent.

SPLEEN: The 250 gm spleen has a smooth, intact, red-purple capsule. The parenchyma is maroon and congested, with distinct Malpighian corpuscles.

PANCREAS: The pancreas is firm and yellow-tan, with the usual lobular architecture. No mass lesions or other abnormalities are seen.

ADRENALS: The right and left adrenal glands are symmetric, with bright yellow cortices and grey medullae. No masses or areas of hemorrhage are identified.

GENITOURINARY SYSTEM: The right and left kidneys weigh 170 and 160 gm, respectively. The external surfaces are intact and smooth. The cut surfaces are red-tan and congested, with uniformly thick cortices and sharp corticomedullary junctions. The pelves are unremarkable and the ureters are normal in course and caliber. White bladder mucosa overlies an intact bladder wall. The bladder is empty. The prostate gland is normal in size, with lobular, yellow-tan

ACLU Detainee DeathII ARMY MEDCOM 473

parenchyma. The seminal vesicles are unremarkable. The testes are free of mass lesions, contusions, or other abnormalities.

GASTROINTESTINAL TRACT: The esophagus is intact and lined by smooth, grey-white mucosa. The stomach contains approximately 90 ml of brown partially digested food. The gastric wall is intact. The duodenum, loops of small bowel and colon are unremarkable. The appendix is present.

MUSCULOSKELETAL:
No traumatic abnormalities or hemorrhage of subcutaneous tissue, muscle or bone are identified. Nontraumatic abnormalities are not identified.

ADDITIONAL PROCEDURES

- Documentary photographs are taken by the OAFME Photographer
- Identifying marks include a tattoo (b)(6) (b)(6)
- Specimens retained for toxicological testing and/or DNA identification are: vitreous fluid, blood, urine, spleen, liver, kidney, lung, bile, gastric contents, and psoas muscle.
- The dissected organs are forwarded with the body

MICROSCOPIC EXAMINATION

Selected portions of organs are retained in formalin with preparation of the following histologic slides:
Heart: see cardiac consultation page 5
Brain: see neuropathology consultation pages 3/4
1. Liver: sinusoidal and centrolobular congestion, otherwise no pathologic abnormality
2/3. Lung: focally marked alveolar congestion, otherwise no pathologic abnormality
4. Kidney: vascular congestion, otherwise no pathologic abnormality
5. Spleen and Adrenal Gland: no pathologic abnormality
6. Pancreas: mild autolysis, otherwise no pathologic abnormality

MEDCOM 0474
ACLU Detainee DeathII ARMY MEDCOM 474

OPINION

Based on these autopsy findings and the investigative information available to me, the cause of death of this Iraqi detainee (b)(6) is probable cardiac arrhythmia secondary to concentric left ventricular hypertrophy. Left ventricular hypertrophy is associated with cardiac arrhythmias and sudden death. Additional autopsy findings include marked pulmonary congestion and generalized congestion of the liver, spleen and kidneys; findings consistent with a fatal cardiac arrhythmia. There are no signs of external or internal trauma. Toxicology testing is positive for lidocaine; a drug used in cardiac resuscitation attempts, and is otherwise negative for ethanol or screened drugs of abuse. The manner of death is natural.

(b)(6)

Armed Forces Medical Examiner Systen (b)(6)

ACLU Detainee DeathII ARMY MEDCOM 475

CERTIFICATE OF DEATH *(OVERSEAS)*
Acte dé décès (D'Outre-Mer)

NAME OF DECEASED *(Last, First, Middle)* Nom du décédé (Nom et prénoms)	GRADE Grade	BRANCH OF SERVICE Arme	SOCIAL SECURITY NUMBER Numéro de l'Assurance Social
BTB Hamid, Fadil, Jadua		Civilian	(b)(6)
ORGANIZATION Organisation	**NATION** *(e.g. United States)* Pays	**DATE OF BIRTH** Date de naissance	**SEX** Sexe
	Iraq	(b)(6) 1978	[X] MALE [ ] FEMALE

RACE Race		MARITAL STATUS État Civil		RELIGION Culte	
[X]	CAUCASOID Caucasique	[ ]	SINGLE Célibataire	[ ]	PROTESTANT Protestant
[ ]	NEGROID Negriode	[ ]	MARRIED Marié	[ ]	CATHOLIC Catholique
[ ]	OTHER (Specify) Autre (Spécifier)	[ ]	WIDOWED Veuf	[ ]	JEWISH Juif
		[ ]	DIVORCED Divorcé	[X]	OTHER (Specify) Autre (Spécifier)
		[ ]	SEPARATED Séparé		

NAME OF NEXT OF KIN Nom du plus proche parent	RELATIONSHIP TO DECEASED Parenté du décède avec le sus
STREET ADDRESS Domicilié à (Rue)	CITY OR TOWN OR STATE *(Include ZIP Code)* Ville (Code postal compris)

MEDICAL STATEMENT Déclaration médicale

	CAUSE OF DEATH (Enter only one cause per line) Cause du décès (N'indiquer qu'une cause par ligne)	INTERVAL BETWEEN ONSET AND DEATH Intervalle entre l'attaque et le décès
DISEASE OR CONDITON DIRECTLY LEADING TO DEATH[1] Maladie ou condition directement responsable de la mort[1]	Probable cardiac arrthymia secondary to concentric left ventricular hypertrophy	Minutes
ANTECEDENT CAUSES — MORBID CONDITION, IF ANY, LEADING TO PRIMARY CAUSE Condition morbide, s'il y a lieu, menant à la cause primaire		
Symptômes précurseurs de la mort — UNDERLYING CAUSE, IF ANY, GIVING RISE TO PRIMARY CAUSE Condition morbide, s'il y a lieu, menant à la cause primaire		
OTHER SIGNIFICANT CONDITIONS[2] Autres conditions significatives[2]		

MODE OF DEATH Condition de décès	AUTOPSY PERFORMED Autopsie effectuée	CIRCUMSTANCES SURROUNDING DEATH DUE TO EXTERNAL CAUSES Circonstances de la mort suscitées par des causes extérieures
[X] NATURAL Mort naturelle	[X] YES Oui [ ] NO Non	
[ ] ACCIDENT Mort accidentelle	MAJOR FINDINGS OF AUTOPSY Conclusions principales de l'autopsie	
[ ] SUICIDE Suicide	NAME OF PATHOLOGIST Nom du pathologiste (b)(6)	
[ ] HOMICIDE Homicide	SIGNATURE Signature (b)(6) — DATE Date 25 October 2006	AVIATION ACCIDENT Accident à Avion [ ] YES Oui [X] NO Non

DATE OF DEATH *(day, month, year)* Date du décès (le jour, le mois, l'année) (b)(6) 2006 — Camp Bucca, Qasr Iraq

I HAVE VIEWED THE REMAINS OF THE DECEASED AND DEATH OCCURRED AT THE TIME INDICATED AND FROM THE CAUSES AS STATED ABOVE.
J'ai examiné les restes mortels du dé funtet je conclus que le décès est survenu à l'heure indiquée et à, la suite des causes énumérées ci-dessus.

NAME OF MEDICAL OFFICER Nom du médicin militaire ou du médicin sanitaire	TITLE OR DEGREE Titre ou diplômé
(b)(6)	Medical Examiner

GRADE Grade	INSTALLATION OR ADDRESS Installation ou adresse
(b)(6)	Dover AFB, Dover DE
DATE Date 2/28/2007	SI (b)(6)

[1] State disease, injury or complication which caused death, but
[2] State conditions contributing to the death, but not related to the
[1] Préciser la nature de la maladie, de la blessure ou de la complication qui a contribué à la mort, mais non la manière de mourir, telle qu'un arrêt du coeur, etc
[2] Préciser la condition qui a contribué à la mort, mais n'ayant aucun rapport avec la maladie ou à la condition qui a provoqué la mort.

DD FORM 1 APR 77 2064 REPLACES DA FORM 3565, 1 JAN 72 AND DA FORM 3565-R(PAS), 26 SEP 75, WHICH ARE OBSOLETE.

ARMED FORCES INSTITUTE OF PATHOLOGY
Office of the Armed Forces Medical Examiner
1413 Research Blvd., Bldg. 102
Rockville, MD 20850
1-301-319-0000

FINAL AUTOPSY EXAMINATION REPORT

Name: (BTB) HAZZAA AL DOULAIMEE, (b)(6)
SSAN: (b)(6)
Date of Birth: (BTB (b)(6) 1982
Date of Death: (b)(6) 2006
Date/Time of Autopsy: 17 OCT 2006 @ 1700
Date of Report: 17 NOV 2006

Autopsy No.: (b)(6)
AFIP No.: (b)(6)
Rank: Iraqi Civilian Detainee
Place of Death: Camp Bucca, Iraq
Place of Autopsy: BIAP Mortuary, Baghdad, Iraq

Circumstances of Death: This 24-year-old Iraqi Civilian Detainee sustained a gunshot wound from U.S. Army soldiers during a firefight on 30 SEP 2006. He was resuscitated, received surgery and was stabilized prior to his transfer to Camp Bucca. He was ambulating with assistance and making progress when he was found unresponsive in his room, and could not be resuscitated.

Authorization for Autopsy: Office of the Armed Forces Medical Examiner, IAW 10 USC 1471.

Identification: Presumptive identification is established by a wrist identification band. A DNA sample is taken for profile purposes if an exemplar becomes available for positive identification.

CAUSE OF DEATH: **GUNSHOT WOUND OF THE BACK COMPLICATED BY PULMONARY EMBOLISM**

MANNER OF DEATH: **HOMICIDE**

ACLU Detainee DeathII ARMY MEDCOM 477

FINAL AUTOPSY DIAGNOSES

I. Gunshot Wound of the Back

A. Entrance Wound
   1. Location: On the lower right back, 25-inches below the top of the head and 4-inches right of the posterior midline of the back in the anatomic position
   2. Dimensions: An ovoid entrance wound measuring ¼ x 3/16-inch with eccentric marginal abrasion up to ¼-inch on the lateral border

B. Wound Path: Skin and subcutaneous tissue of the lower right back, muscles of the lower right back, the spinous process of the 4th lumbar vertebra (fractured), muscles of the lower left back, subcutaneous tissue and skin of the upper left buttock

C. Exit Wound
   1. Location: On the upper left buttock, 29-inches below the top of the head, 38 ½-inches above the heel and 7-inches left of the posterior midline of the back in the anatomic position
   2. Dimensions: An ovoid defect measuring 3 ¼ x 2 ½-inches, consistent with a debrided exit wound; packing material is present surrounding the exit wound

D. Recovered: No bullet or bullet fragments are recovered; multiple radio-opaque metallic fragments of no evidentiary value are observed radiographically in the region of the left buttock

E. Direction: Slightly back to front, right to left and slightly downward

F. Associated Injuries
   1. A non-obstructive thromboembolus with valve markings and tributary casts is located at the bifurcation of the right and left pulmonary arteries ("saddle embolus"); multiple small obstructive thromboemboli are noted in the smaller branches of the right and left pulmonary arteries
   2. Deep venous thromboses in the deep veins of the right and left legs
   3. Bleeding into the wound tract

II. No significant natural diseases or pre-existing conditions are identified, within the limitations of this examination.

III. Evidence of Medical Therapy

A. A closed, 9-inch surgical incision is on the abdominal midline

B. A medical dressing and packing are present on the lower right back

C. A vacuum drain and a 3-inch closed surgical incision with packing is on the lower left back

D. Needle stick marks are on the right subclavian region

IV. Post-Mortem Changes

A. Rigor is passing and equal in all extremities

B. Livor is posterior and fixed except in areas exposed to pressure

C. Marbling is present in areas of livor

ACLU Detainee DeathII ARMY MEDCOM 478

D. Corneal clouding, bilaterally

V. Identifying Body Marks

A. Tattoo on (b)(6)
(b)(6)

B. Multiple irregular scars on the right back in a 3 ½ x ¼-inch area and ranging in size from punctate to ½ x ¼-inch

VI. There is no evidence of physical abuse

A. Layer-wise anterior neck dissection is negative for trauma
B. Incision and dissection of the posterior neck demonstrates no deep paracervical muscular injury and no cervical spine fractures
C. No petechiae are present on the conjunctivae or oral mucosa
D. External examination is negative for trauma
E. Radiographic skeletal survey is negative for trauma

VII. Toxicology

A. The blood and urine are tested for ethanol and none is found.
B. The urine is screened for medications and drugs of abuse and the following medications are detected:
   1. Oxymorphone (a narcotic analgesic) is detected in the urine, but is not present in the blood.
   2. Oxycodone (a narcotic analgesic) is detected in the urine, but is not present in the blood.

EXTERNAL EXAMINATION

The body is that of a well-developed, well-nourished appearing, 67-inch, 150-pounds (estimated) male whose appearance is consistent with the reported age of 24-years. Lividity is posterior and fixed with marbling in areas of lividity. Rigor is passing and equal in all extremities, and the temperature of the body is cold to touch.

The scalp is covered with black hair in a normal distribution; facial hair consists of a full beard and moustache. The irides are brown, the corneae cloudy, the conjunctivae pink without petechiae and the pupils are round and equal in diameter. The external auditory canals are patent and free of foreign material. The ears are unremarkable. The nares are patent and the lips are atraumatic. The nose and maxillae are palpably stable. The teeth appear natural.

The neck is straight, and the trachea is midline and mobile. The chest is symmetric. The abdomen is remarkable for a closed, 9-inch midline surgical incision. Injury to the posterior torso is described below (see "Evidence of Injury.") The genitalia are those of a normal adult male. The testes are descended and free of masses. Pubic hair is present in a normal distribution. The buttocks and anus are unremarkable.

ACLU Detainee DeathII ARMY MEDCOM 479

The upper and lower extremities are symmetric and without clubbing or edema.

CLOTHING AND PERSONAL EFFECTS

The body is received unclothed and without personal effects.

MEDICAL INTERVENTION

- A closed, 9-inch surgical incision is on the abdominal midline
- A medical dressing and packing are present on the lower right back
- A vacuum drain and a 3-inch closed surgical incision with packing is on the lower left back
- Needle stick marks are on the right subclavian region

RADIOGRAPHS

A complete set of postmortem radiographs is obtained and demonstrates the following:

- No long bone fractures
- No rib or skull fractures
- No fractures of the bones of the hands or feet
- Fracture of the spinous process of the 4th lumbar vertebra
- Multiple small radio-opaque metallic fragments are observed in the region of the left buttock

EVIDENCE OF INJURY

The ordering of the following injuries is for descriptive purposes only, and is not intended to imply order of infliction or relative severity. All wound pathways are given relative to standard anatomic position.

Gunshot Wound of the Back

A gunshot entrance wound is on the lower right back, 25-inches below the top of the head and 4-inches right of the posterior midline of the back in the anatomic position. The ovoid entrance wound measures ¼ x 3/16-inch with eccentric marginal abrasion up to ¼-inch on the lateral border. The wound path perforates the skin and subcutaneous tissue of the lower right back, muscles of the lower right back, the spinous process of the 4th lumbar vertebra (fractured), muscles of the lower left back, subcutaneous tissue and skin of the upper left buttock. The bullet exited via an ovoid defect measuring 3 ¼ x 2 ½-inches (consistent with a debrided exit wound; packing material is present surrounding the exit wound) and located on the upper left buttock, 29-inches below the top of the head, 38 ½-inches above the heel and 7-inches left of the posterior midline of the back in the anatomic position. No bullet or bullet fragments are recovered; multiple radio-opaque metallic fragments of no evidentiary value are observed radiographically in the

ACLU Detainee DeathII ARMY MEDCOM 480

region of the left buttock. The wound path is directed slightly back to front, right to left and slightly downward.

Associated with the wound path is bleeding into the wound tract; a non-obstructive thromboembolus with valve markings and tributary casts is located at the bifurcation of the right and left pulmonary arteries ("saddle embolus") with multiple small obstructive thromboemboli noted in the smaller branches of the right and left pulmonary arteries, and deep venous thromboses in the deep veins of the right and left legs.

INTERNAL EXAMINATION

HEAD AND CENTRAL NERVOUS SYSTEM:
The galeal and subgaleal soft tissues of the scalp are free of injury. The calvarium is intact, as is the dura mater beneath it. Clear cerebrospinal fluid surrounds the 1,340-gram brain, which has unremarkable gyri and sulci. Coronal sections demonstrate sharp demarcation between white and gray matter, without hemorrhage or contusive injury. The ventricles are of normal size. The basal ganglia, brainstem, cerebellum, and arterial systems are free of injury or other abnormalities. There are no skull fractures. The atlanto-occipital joint is stable.

NECK:
Layer-wise dissection of the anterior strap muscles of the neck reveals homogenous and red-brown tissue without hemorrhage. The thyroid cartilage and hyoid bone are intact. The larynx is lined by intact white mucosa. The thyroid gland is symmetric and red-brown, without cystic or nodular change. The tongue is free of bite marks, hemorrhage, or other injuries.

Incision and dissection of the posterior neck demonstrates no deep paracervical muscular injury and no cervical spine fractures.

BODY CAVITIES:
The ribs and sternum are visibly and palpably intact. No excess fluid is in the pleural, pericardial, or peritoneal cavities. The organs occupy their usual anatomic positions.

RESPIRATORY SYSTEM:
The right and left lungs weigh 540 and 400-grams, respectively. The external surfaces are smooth and deep red-purple. The pulmonary parenchyma is diffusely congested and edematous. No mass lesions or areas of consolidation are present. Multiple small occlusive thromboemboli are noted in the smaller branches of the right and left pulmonary arteries.

CARDIOVASCULAR SYSTEM:
The 350-gram heart is contained in an intact pericardial sac. The epicardial surface is smooth, with minimal fat investment. The coronary arteries are present in a normal distribution, with a right-dominant pattern. Cross sections of the vessels show no luminal narrowing. The myocardium is homogenous, red-brown, and firm. The valve leaflets are

ACLU Detainee DeathII ARMY MEDCOM 481

thin and mobile. The walls of the left and right ventricles are 1.2 and 0.5-centimeters thick, respectively. The endocardium is smooth and glistening. Upon opening the pulmonary artery while *in situ*, a non-occlusive thromboembolus with valve markings and tributary casts is located at the bifurcation of the right and left pulmonary arteries ("saddle embolus"). The aorta gives rise to three intact and patent arch vessels. The renal and mesenteric vessels are unremarkable.

LIVER & BILIARY SYSTEM:
The 1,870-gram liver has an intact, smooth capsule and a sharp anterior border. The parenchyma is tan-brown and congested, with the usual lobular architecture. No mass lesions or other abnormalities are seen. The gallbladder contains a minute amount of green-black bile and no stones. The mucosal surface is green and velvety. The extrahepatic biliary tree is patent.

SPLEEN:
The 290-gram spleen has a smooth, intact, red-purple capsule. The parenchyma is maroon and congested, with distinct Malpighian corpuscles.

PANCREAS:
The pancreas is firm and yellow-tan, with the usual lobular architecture. No mass lesions or other abnormalities are seen.

ADRENALS:
The right and left adrenal glands are symmetric, with bright yellow cortices and gray medullae. No masses or areas of hemorrhage are identified.

GENITOURINARY SYSTEM:
The right and left kidneys weigh 150 and 180-grams, respectively. The external surfaces are intact and smooth. The cut surfaces are red-tan and congested, with uniformly thick cortices and sharp cortico-medullary junctions. The pelves are unremarkable and the ureters are normal in course and caliber. Gray-pink bladder mucosa overlies an intact bladder wall. The bladder contains approximately 75-milliliters of yellow urine. The prostate is normal in size, with lobular, yellow-tan parenchyma. The seminal vesicles are unremarkable. The testes are free of mass lesions, contusions, or other abnormalities.

GASTROINTESTINAL TRACT:
The esophagus is intact and lined by smooth, gray-white mucosa. The stomach contains approximately25-milliliters of tan fluid. The gastric wall is intact. The duodenum, loops of small bowel and colon are unremarkable. The appendix is present.

MUSCULOSKELETAL SYSTEM:
There is no non-traumatic bone or joint abnormalities. Skeletal muscle development is normal.

ACLU Detainee DeathII ARMY MEDCOM 482

MICROSCOPIC EXAMINATION

Selected portions of organs are retained in formalin, without preparation of histological slides.

ADDITIONAL PROCEDURES/REMARKS

- Documentary photographs are taken by AFMES staff photographers
- Specimens retained for toxicologic testing and/or DNA identification are: heart blood, vitreous fluid, gastric contents, urine, bile, spleen, liver, lung, kidney, brain, adipose tissue, and psoas muscle
- Full body radiographs are obtained and demonstrate the skeletal trauma described above and the presence of multiple small metallic foreign bodies surrounding the exit wound
- Projectiles are not recovered
- Selected portions of organs are retained in formalin, without preparation of histological slides
- The dissected organs are forwarded with the body

ACLU Detainee DeathII ARMY MEDCOM 483

OPINION

This 24-year-old Iraqi civilian detainee (b)(6) died of a gunshot of the back he sustained while in a firefight with U.S. Army personnel. He was stabilized and transported to a medical facility where he was ambulating with assistance when he was found unresponsive in his hospital bed. Aggressive resuscitation was to no avail. The gunshot entrance wound was located on the right lower back, and passed through the skin and soft tissue of the lower right back, the spinous process of the 4th lumbar vertebra and the soft tissue of the left lower back before exiting the upper left buttock. There was no evidence of close range fire, nor were any of the projectile fragments that were observed radiographically recovered. A significant complication of this gunshot wound was multiple occlusive and non-occlusive thromboemboli in the pulmonary arteries. Toxicological testing was negative for ethanol, and positive for the narcotic analgesics Oxycodone and Oxymorphone in the urine but not in the blood. The manner of death is homicide.

(b)(6)

(b)(6) Medical Examiner (b)(6)

ACLU Detainee DeathII ARMY MEDCOM 484

CERTIFICATE OF DEATH *(OVERSEAS)*
Acte de décès *(D'Outre-Mer)*

NAME OF DECEASED *(Last, First, Middle)* Nom du décédé (Nom et prénoms)	GRADE Grade	BRANCH OF SERVICE Arme	SOCIAL SECURITY NUMBER Numéro de l'Assurance Social
BTB Hazzaa Al Doulai, Ezaldin, Awanad		Civilian	(b)(6)

ORGANIZATION Organisation	NATION *(e.g, United States)* Pays	DATE OF BIRTH Date de naissance	SEX Sexe
	Iraq	(b)(6) 1982	[X] MALE [ ] FEMALE

RACE Race		MARITAL STATUS État Civil			RELIGION Culte		
	CAUCASOID Caucasique		SINGLE Célibataire		DIVORCED Divorcé		PROTESTANT Protestant		OTHER (Specify) Autre (Spécifier)
	NEGROID Negroide		MARRIED Marié		SEPARATED Séparé		CATHOLIC Catholique	X	Muslim
X	OTHER (Specify) Autre (Spécifier)		WIDOWED Veuf				JEWISH Juif		

NAME OF NEXT OF KIN Nom du plus proche parent	RELATIONSHIP TO DECEASED Parenté du décédé avec le sus
STREET ADDRESS Domicilé à (Rue)	CITY OR TOWN OR STATE *(Include ZIP Code* Ville (Code postal compris)

MEDICAL STATEMENT Déclaration médicale

	CAUSE OF DEATH *(Enter only one cause per line)* Cause du décès (N'indiquer qu'une cause par ligne)	INTERVAL BETWEEN ONSET AND DEATH Intervalle entre l'attaque et le décès
DISEASE OR CONDITON DIRECTLY LEADING TO DEATH [1] Maladie ou condition directement responsable de la mort.	Gunshot wound of the back complicated by pulmonary embolism.	Days
ANTECEDENT CAUSES Symptômes précurseurs de la mort. — MORBID CONDITION, IF ANY, LEADING TO PRIMARY CAUSE Condition morbide, s'il y a lieu, menant à la cause primaire		
ANTECEDENT CAUSES Symptômes précurseurs de la mort. — UNDERLYING CAUSE, IF ANY, GIVING RISE TO PRIMARY CAUSE Condition morbide, s'il y a lieu, menant à la cause primaire		
OTHER SIGNIFICANT CONDITIONS [2] Autres conditions significatives [2]		

MODE OF DEATH Condition de décès	AUTOPSY PERFORMED Autopsie effectuée [X] YES Oui [ ] NO Non	CIRCUMSTANCES SURROUNDING DEATH DUE TO EXTERNAL CAUSES Circonstances de la mort suscitées par des causes extérieures
[ ] NATURAL Mort naturelle	MAJOR FINDINGS OF AUTOPSY Conclusions principales de l'autopsie	
[ ] ACCIDENT Mort accidentelle		
[ ] SUICIDE Suicide	NAME OF PATHOLOGIST Nom du pathologiste (b)(6)	
[X] HOMICIDE Homicide	SIGNATURE Signature (b)(6) — DATE Date 17 October 2006	AVIATION ACCIDENT Accident à Avion [ ] YES Oui [X] NO Non

DATE OF DEATH *(day, month, year)* Date de décès (le jour, le mois, l'année)	PLACE OF DEATH Lieu de décès
(b)(6) 2006 (b)(6)	Camp Bucca Iraq

I HAVE VIEWED THE REMAINS OF THE DECEASED AND DEATH OCCURRED AT THE TIME INDICATED AND FROM THE CAUSES AS STATED ABOVE
J'ai examiné les restes mortels du dé funtet je conclus que le décès est survenu à l'heure indiquée et à, la suite des causes énumérées ci-dessus.

NAME OF MEDICAL OFFICER Nom du médecin militaire ou du médecin sanitaire	TITLE OR DEGREE Titre ou diplôme
(b)(6)	Medical Examiner

GRADE Grade	INSTALLATION OR ADDRESS Installation ou adresse
(b)(6)	Baghdad, Iraq
DATE Date 1/9/2007	SIGNATURE Signature (b)(6)

[1] State disease, injury or complication which caused death, but not mode of dying such as heart failure, etc.
[2] State conditions contributing to the death, but not related to the disease or condition causing death.
[1] Préciser la nature de la maladie, de la blessure ou de la complication qui a contribué à la mort, mais non la manière de mourir, telle qu'un arrêt du coeur, etc.
[2] Préciser la condition qui a contribué à la mort, mais n'ayant aucun rapport avec la maladie ou à la condition qui a provoqué la mort.

DD FORM 1 APR 77 2064 — REPLACES DA FORM 3565, 1 JAN 72 AND DA FORM 3566-R(PAS), 26 SEP 75, WHICH ARE OBSOLETE.

ARMED FORCES INSTITUTE OF PATHOLOGY
Office of the Armed Forces Medical Examiner
1413 Research Blvd., Bldg. 102
Rockville, MD 20850
1-301-319-0000

FINAL AUTOPSY EXAMINATION REPORT

Name: (BTB) ABBASS AL-ZUBAIDI, Naiim Mohammed
Autopsy No.: (b)(6)
ISN: (b)(6)
AFIP No.: (b)(6)
Date of Birth: (BTB (b)(6) 1942
Rank: Iraqi Civilian Detainee
Date of Death: (b)(6) 2006
Place of Death: Camp Cropper, Iraq
Date/Time of Autopsy: 15 OCT 2006 @ 1000
Place of Autopsy: BIAP Mortuary, Baghdad, Iraq
Date of Report: 19 JAN 2007

Circumstances of Death: This 64-year-old Iraqi male was a detainee at Camp Cropper, Iraq and undergoing treatment for tuberculosis. He had no other known medical problems. He was found unresponsive, and although ACLS protocol resuscitation was initiated, he expired.

Authorization for Autopsy: Office of the Armed Forces Medical Examiner, IAW 10 USC 1471.

Identification: Presumptive identification is established by a wrist identification band. A DNA sample is taken for profile purposes if an exemplar becomes available for positive identification.

CAUSE OF DEATH: **HYPERTENSIVE AND ARTERIOSCLEROTIC CARDIOVASCULAR DISEASE**

MANNER OF DEATH: **NATURAL**

ACLU Detainee DeathII ARMY MEDCOM 486

FINAL AUTOPSY DIAGNOSES

I. Cardiovascular Disease

A. Coronary artery disease
   1. Luminal narrowing (75%)of the left main coronary artery
   2. Luminal narrowing (90%)of the re-canalized left anterior descending coronary artery with calcification
   3. Luminal narrowing (90%)of the left circumflex coronary artery with calcification
   4. Luminal narrowing (>90%)of the right coronary artery with calcification, evidence of plaque rupture and fresh thrombus formation
   5. Remote left posterior wall and septal infarction

B. Cardiomegaly (heart weight 510-grams)
C. Aortic atherosclerosis with ulceration and calcification
D. Focal, diffuse glomerulosclerosis and arteriolosclerosis of the kidneys

II. Other Findings

A. Right renal calculi: Four irregular, green-brown calculi are recovered from the renal pelvis, and range in size from 0.3 to 0.5-centimeters
B. Prostatic hypertrophy: The prostate is enlarged in size, 5.0 x 3.0 x 3.0-centimeters (no discrete nodules are identified), with associated muscular hypertrophy of the bladder
C. Bullae of the right and left upper lobes of the lungs
D. Pulmonary congestion
E. Mild to moderate pulmonary emphysema
F. Multiple lung and hilar lymph node sections are negative for mycobacterial infection (see Attachment 1 for complete details)

III. Evidence of Medical Therapy

A. A properly located endotracheal tube
B. An intravenous line inserted in the right antecubital fossa
C. A surgical-type mask covering the nose and mouth
D. Rib fractures: anterior right 6th rib and anterior left 2nd through 6th ribs

IV. Post-Mortem Changes

A. Livor is posterior and fixed except in areas exposed to pressure
B. Rigor has passed (absent) in all extremities
C. The body is cold to touch

V. Identifying Body Marks

A 0.7 x 0.5-centimeter brown papule is on the left groin

VI. No evidence of physical abuse

VII. Toxicology

A. The blood and urine are tested for ethanol and none is found.

ACLU Detainee DeathII ARMY MEDCOM 487

B. The urine is screened for medications and drugs of abuse; Ethambutol (an antimycobacterial medication) is detected in the urine but is not quantitated in the blood.

EXTERNAL EXAMINATION

The body is that of a well-developed, well-nourished appearing, 70 ½-inch and 150-pound (estimated) male whose appearance is consistent with the reported age of 64-years. Lividity is posterior and fixed. Rigor is absent (passed), and the temperature is cold to touch.

The scalp is covered with gray hair in a normal distribution; facial hair consists of a moustache. The irides are hazel, the corneae are cloudy and the pupils are round and equal in diameter. The external auditory canals are patent and free of foreign material. The ears are unremarkable. The nares are patent and the lips are atraumatic. The nose and maxillae are palpably stable. The teeth appear natural and in fair condition.

The neck is straight, and the trachea is midline and mobile. The chest is symmetric. The abdomen is flat. The genitalia are those of a normal adult male. The testes are descended and free of masses. Pubic hair is present in a normal distribution. The buttocks and anus are unremarkable. There is a 0.7 x 0.5-centimeter soft brown papule in the left inguinal fold.

The upper and lower extremities are symmetric and without clubbing or edema. The fingernails are trimmed and intact.

CLOTHING AND PERSONAL EFFECTS

The following clothing items and personal effects are present on the body at the time of autopsy:

- Yellow top
- Yellow pants
- White boxer shorts

MEDICAL INTERVENTION

- A properly located endotracheal tube
- An intravenous line inserted in the right antecubital fossa
- A surgical-type mask covering the nose and mouth
- Rib fractures: anterior right 6th rib and anterior left 2nd through 6th ribs

ACLU Detainee DeathII ARMY MEDCOM 488

RADIOGRAPHS

A complete set of postmortem radiographs is obtained and demonstrates the following:

- No fractures of the skull, axial skeleton, or long bones
- No metallic foreign bodies other than medical therapy

EVIDENCE OF INJURY

There is no evidence of recent, significant injury.

INTERNAL EXAMINATION

HEAD AND CENTRAL NERVOUS SYSTEM:
The galeal and subgaleal soft tissues of the scalp are free of injury. The calvarium is intact, as is the dura mater beneath it. Clear cerebrospinal fluid surrounds the 1,240-gram brain, which has unremarkable gyri and sulci. Coronal sections demonstrate sharp demarcation between white and gray matter, without hemorrhage or contusive injury. The ventricles are of normal size. The basal ganglia, brainstem, and cerebellum are free of injury or other abnormalities. There is mild atherosclerosis of the arteries at the base of the brain. There are no skull fractures. The atlanto-occipital joint is stable.

NECK:
By layer-wise dissection, the anterior strap muscles of the neck are homogenous and red-brown, without hemorrhage. The thyroid cartilage and hyoid bone are intact. The larynx is lined by intact white mucosa. The thyroid gland is symmetric and red-brown, without cystic or nodular change. The tongue is free of bite marks, hemorrhage, or other injuries.

BODY CAVITIES:
The sternum and vertebral bodies are visibly and palpably intact. Injuries to the ribs are described above (see "Medical Intervention," above). No excess fluid is in the pleural, pericardial, or peritoneal cavities. The organs occupy their usual anatomic positions.

RESPIRATORY SYSTEM:
The right and left lungs weigh 840 and 725-grams, respectively. The external surfaces are smooth and deep red-purple. Bullae are grossly identifiable in the apices of both lungs. The pulmonary parenchyma is diffusely congested and edematous. No mass lesions or areas of consolidation are present.

CARDIOVASCULAR SYSTEM:
The 510-gram heart is contained in an intact pericardial sac. The epicardial surface is smooth, with moderate fat investment. The coronary arteries are present in a normal distribution, with a right-dominant pattern. Cross sections of the vessels show moderate to marked luminal narrowing of the left main coronary artery and severe luminal narrowing of the left anterior descending and left circumflex coronary arteries. The

ACLU Detainee DeathII ARMY MEDCOM 489

lumen of the right coronary artery appears to be of a pinpoint diameter. All of the coronary arteries are focally calcified. The myocardium is homogenous, red-brown, and firm except in the posterior left ventricle and posterior septum where there is a dense white scar. The valve leaflets are thin and mobile. The walls of the left and right ventricles are 1.2 and 0.3-centimeters thick, respectively. The endocardium is smooth and glistening. The aorta gives rise to three intact and patent arch vessels and has multiple atherosclerotic plaques and ulceration with calcification along the entire length. The renal and mesenteric vessels are unremarkable.

LIVER & BILIARY SYSTEM:
The 1,440-gram liver has an intact, smooth capsule and a sharp anterior border. The parenchyma is tan-brown and congested, with the usual lobular architecture. No mass lesions or other abnormalities are seen. The gallbladder contains 2-milliliters of green-black bile and no stones. The mucosal surface is green and velvety. The extrahepatic biliary tree is patent.

SPLEEN:
The 130-gram spleen has a smooth, intact, red-purple capsule. The parenchyma is maroon and congested, with distinct lymphoid follicles.

PANCREAS:
The pancreas is autolytic and saponified, with the usual lobular architecture. No mass lesions or other abnormalities are seen.

ADRENALS:
The right and left adrenal glands are autolytic and symmetric, with bright yellow cortices and gray medullae. No masses or areas of hemorrhage are identified.

GENITOURINARY SYSTEM:
The right and left kidneys weigh 200 and 160-grams, respectively. The external surfaces are intact and smooth. The cut surfaces are red-tan and congested, with uniformly thick cortices and sharp cortico-medullary junctions. The pelvis of the right kidney contains four irregular brown stones which range in size from 0.3 to 0.5-centimeters; the left kidney pelvis is unremarkable. Both ureters are normal in course and caliber. Gray-pink bladder mucosa overlies an intact, hypertrophic bladder wall with trabeculae. The bladder contains approximately 30-milliliters of cloudy yellow urine. The prostate is enlarged, with cysts containing viscous brown fluid and yellow-tan parenchyma. The seminal vesicles are unremarkable. The testes are free of mass lesions, contusions, or other abnormalities.

GASTROINTESTINAL TRACT:
The esophagus is intact and lined by smooth, gray-white mucosa. The stomach contains approximately 200-milliliters of brown-green fluid with food particles. The gastric wall is intact. The duodenum, loops of small bowel and colon are unremarkable. The appendix is present.

ACLU Detainee DeathII ARMY MEDCOM 490

MUSCULOSKELETAL SYSTEM:
There is no non-traumatic bone or joint abnormalities. Skeletal muscle development is normal. Superficial incisions of the posterior torso and extremities are negative for soft tissue trauma.

MICROSCOPIC EXAMINATION

Selected portions of organs are retained in formalin, with preparation of selected histological slides.

RESPIRATORY SYSTEM

Lung (Slides 1-5): Multiple sections are examined which demonstrate mild interstitial fibrosis and macrophages with anthracotic pigment. Mild to moderate emphysematous changes and vascular congestion are noted. Special stains fail to demonstrate mycobacteria (see Attachment 1 for complete details).
Hilar lymph node (Slide 6): Anthracotic pigment is present in macrophages; otherwise an unremarkable lymph node. Special stains fail to demonstrate mycobacteria (see Attachment 1 for complete details).

GENITOURINARY SYSTEM

Seminal Vesicle (Slide 7): Cystic dilatation and inspissation of secretions
Kidneys (Slides 8 and 9): Focal, diffuse glomerulosclerosis and arteriolosclerosis. Mild, focal chronic inflammation and focal calcification is present.

CARDIOVASCULAR SYSTEM

Left ventricular myocardium and scar (Slide 10): Hypertrophic myocytes with enlarged nuclei, interstitial fibrosis and dense endocardial-based scar.
Left main coronary artery (Slide 11): Luminal narrowing (75%) by intimal hypertrophy, cholesterol clefts and chronic inflammation.
Left anterior descending coronary artery (Slide 12): Luminal narrowing (90%) by intimal hypertrophy, cholesterol clefts and chronic inflammation. Recanalization of the artery and focal calcification are also present.
Left circumflex coronary artery (Slide 13): Luminal narrowing (90%) by intimal hypertrophy, cholesterol clefts and chronic inflammation.
Right coronary artery (Slide 14): Luminal narrowing (>90%) by intimal hypertrophy, cholesterol clefts and chronic inflammation. Plaque rupture with hemorrhage into the media and fresh thrombus formation are noted.

ADDITIONAL PROCEDURES/REMARKS

- Documentary photographs are taken by AFMES staff photographers

ACLU Detainee DeathII ARMY MEDCOM 491

- Specimens retained for toxicologic testing and/or DNA identification are: heart blood, vitreous fluid, gastric contents, urine, bile, spleen, liver, lung, kidney, brain, adipose tissue, and psoas muscle
- Full body radiographs are obtained and demonstrate the absence of skeletal trauma and the absence of metallic foreign bodies
- Selected portions of organs are retained in formalin, with preparation of histological slides
- The dissected organs are forwarded with the body
- Personal effects are released to the mortuary affairs representatives

OPINION

This 64-year-old Iraqi civilian detainee (b)(6) died of hypertensive and arteriosclerotic cardiovascular disease. The observed cardiomegaly, microscopic evidence of cardiac hypertrophy and the microscopic changes in the kidneys are typical of this condition. There is evidence of a remote myocardial infarction, as well as a fresh thrombus in the right coronary artery. It was reported that he was being treated for tuberculosis, but no microscopic evidence of this disease was observed. Toxicological testing for ethanol was negative. Ethambutol (an antimycobacterial medication) was detected in the urine but not quantitated in the blood. There is no evidence of physical abuse. The rib fractures are most likely an artifact of cardiopulmonary resuscitation. The manner of death is natural.

(b)(6)

(b)(6) Medical Examiner

ACLU Detainee DeathII ARMY MEDCOM 492

CERTIFICATE OF DEATH *(OVERSEAS)*

Acte dé décès (D'Outre-Mer)

NAME OF DECEASED *(Last, First, Middle)* Nom du décédé (Nom et prénoms)	GRADE Grade	BRANCH OF SERVICE Arme	SOCIAL SECURITY NUMBER Numéro de l'Assurance Social
BTB-Abbass Al Zubaid, Najim, Mohammed		Civilian	(b)(6)

ORGANIZATION Organisation	NATION *(e.g. United States)* Pays	DATE OF BIRTH Date de naissance	SEX Sexe
	Iraq	(b)(6) 1942	[X] MALE [ ] FEMALE

RACE Race		MARITAL STATUS État Civil			RELIGION Culte		
[X]	CAUCASOID Caucasique	[ ]	SINGLE Célibataire	[ ] DIVORCED Divorcé	[ ]	PROTESTANT Protestant	[X] OTHER (Specify) Autre (Spécifier) Muslim
[ ]	NEGROID Negroide	[ ]	MARRIED Marié	[ ] SEPARATED Séparé	[ ]	CATHOLIC Catholique	
[ ]	OTHER (Specify) Autre (Spécifier)	[ ]	WIDOWED Veuf		[ ]	JEWISH Juif	

NAME OF NEXT OF KIN Nom du plus proche parent	RELATIONSHIP TO DECEASED Parenté du décède avec le sus
STREET ADDRESS Domicilé à (Rue)	CITY OR TOWN OR STATE *(Include ZIP Code)* Ville (Code postal compris)

MEDICAL STATEMENT Déclaration médicale

	CAUSE OF DEATH (Enter only one cause per line) Cause du décès (N'indiquer qu'une cause par ligne)	INTERVAL BETWEEN ONSET AND DEATH Intervalle entre l'attaque et le décès
DISEASE OR CONDITON DIRECTLY LEADING TO DEATH [1] Maladie ou condition directement responsable de la mort [1]	Hypertensive and Arteriosclerotic Cardiovascular Disease	Years
ANTECEDENT CAUSES Symptômes précurseurs de la mort. MORBID CONDITION, IF ANY, LEADING TO PRIMARY CAUSE Condition morbide, s'il y a lieu, menant à la cause primaire		
UNDERLYING CAUSE, IF ANY, GIVING RISE TO PRIMARY CAUSE Condition morbide, s'il y a lieu, menant à la cause primaire		
OTHER SIGNIFICANT CONDITIONS [2] Autres conditions significatives [2]		

MODE OF DEATH Condition de décès	AUTOPSY PERFORMED Autopsie effectuée [X] YES Oui [ ] NO Non	CIRCUMSTANCES SURROUNDING DEATH DUE TO EXTERNAL CAUSES Circonstances de la mort suscitées par des causes extérieures
[X] NATURAL Mort naturelle	MAJOR FINDINGS OF AUTOPSY Conclusions principales de l'autopsie	
[ ] ACCIDENT Mort accidentelle		
[ ] SUICIDE Suicide	NAME OF PATHOLOGIST Nom du pathologiste (b)(6)	
[ ] HOMICIDE Homicide	SIGNA (b)(6) DATE Date 15 October 2006	AVIATION ACCIDENT Accident à Avion [ ] YES Oui [X] NO Non

DATE OF DEATH *(day, month, year)* Date de décès (le jour, le mois, l'année)	PLACE OF DEATH Lieu de décès
(b)(6) 2006 (b)(6)	Iraq

I HAVE VIEWED THE REMAINS OF THE DECEASED AND DEATH OCCURRED AT THE TIME INDICATED AND FROM THE CAUSES AS STATED ABOVE.
J'ai examiné les restes mortels du dé funt et je conclus que le décès est survenu à l'heure indiquée et à, la suite des causes énumérées ci-dessus.

NAME OF MEDICAL OFFICER Nom du médicin militaire ou du médicin sanitaire	TITLE OR DEGREE Titre ou diplômé
(b)(6)	Medical Examiner

GRADE Grade	INSTALLATION OR ADDRESS Installation ou adresse
(b)(6)	Baghdad, Iraq
DATE Date 2/8/2007	SIG (b)(6)

[1] State disease, injury or complication which caused death, but not mode of dying such as heart failure, ect.
[2] State conditions contributing to the death, but not related to the disease or condition causing death.
[1] Préciser la nature de la maladie, de la blessure ou de la complication qui a contribué à la mort, mais non la manière de mourir, telle qu 'un arrêt du coeur, etc.
[2] Préciser la condition qui a contribué à la mort, mais n'ayant aucun rapport avec la maladie ou à la condition qui a provoqué la mort.

DD FORM 1 APR 77 **2064** REPLACES DA FORM 3565, 1 JAN 72 AND DA FORM 3565-R(PAS), 26 SEP 75, WHICH ARE OBSOLETE.

ARMED FORCES INSTITUTE OF PATHOLOGY
Office of the Armed Forces Medical Examiner
1413 Research Blvd., Bldg. 102
Rockville, MD 20850
301-319-0000

FINAL AUTOPSY EXAMINATION REPORT

Name: BTB Humaidi, Al Jughayfi Haskim Humoud Autopsy No.: (b)(6)
SSAN: (b)(6) AFIP No. (b)(6)
Date of Birth (b)(6) 1970 Rank: CIV
Date of Death (b)(6) 2006 Place of Death: Hadithah, Iraq
Date and time of Autopsy: 01 OCT 2006 0930 Place of Autopsy: Port Mortuary
Date of Report: 07 MAR 2007 Dover AFB, Dover DE

Circumstances of Death: Apprehended by Iraqi police on (b)(6) 2006. Once there he was interrogated throughout the night. The victim was later found dead in his cell.

Authorization for Autopsy: Office of the Armed Forces Medical Examiner, IAW 10 USC 1471

Identification: Presumptive.

CAUSE OF DEATH: Multiple blunt force injuries.

MANNER OF DEATH: Homicide.

FINAL AUTOPSY DIAGNOSES

I. Injuries of the head and neck:
   A. Depressed skull fracture of right parietal temporal region of the calvarium.
   B. Galeal and subgaleal hemorrhage in the frontal and right parietal regions.
   C. Multiple facial contusions, abrasions and lacerations.

II. Injuries of the torso:
   A. Discontinuous and patterned contusions of the entire posterior torso involving the posterior neck, back and buttocks.
      1. Near confluent subcutaneous and intramuscular hemorrhage of the above areas.

III. Injuries of the extremities:
   A. Contusions, abrasions and subcutaneous hemorrhage of the dorsal surfaces of the hands and upper arms, bilaterally.
   B. Multiple lacerations and contusions of the anterior surfaces of both lower legs.

IV. Additional findings:
   A. Bilateral pulmonary congestion (right 510 grams, left 600 grams).

ACLU Detainee DeathII ARMY MEDCOM 494

V. No significant natural diseases identified, within limitations of the examination.

VI. Toxicology: Negative.

ACLU Detainee DeathII ARMY MEDCOM 495

EXTERNAL EXAMINATION

The body is that of a nude male weighing 165 pounds, measuring 71 inches in length and appearing compatible with the reported age of 36 years. The body temperature is cool after refrigeration. Rigor is passing. Injury of the posterior surfaces (to be further described below) precludes an accurate assessment of lividity.

The scalp hair is black. Facial hair consists of a black mustache and beard. The irides are dark. The corneae are cloudy. The sclerae are unremarkable. The external auditory canals, external nares and oral cavity are free of foreign material and abnormal secretions. The nasal skeleton is palpably intact. The teeth appear natural and in fair condition.

The neck is straight, and the trachea is midline and mobile. The chest is symmetric. No evidence of injury of the ribs or the sternum is evident externally. The abdomen is flat. The extremities show evidence of injury to be described below. Scars are present on the posterior surfaces of both elbows (right 1 1/8 inch, left 1 inch). Plastic bags cover both hands. The fingernails are intact. The external genitalia are those of a normal adult male. The buttocks show evidence of injury to be described below. The anus is unremarkable.

CLOTHING AND PERSONAL EFFECTS

The body is received unclothed. The following items accompany the body:

1. A pair of brown sandals.
2. A pair of white boxer shorts.
3. A gray tunic.
4. A U.S. flag kerchief.

EVIDENCE OF INJURY

Head and neck:

A 1 ½ x ½ inch contusion is present on the right frontal scalp. A patterned abrasion consisting of two parallel linear abrasions is present on the right cheek measuring 1 1/8 inch (superior) and 2 inches (inferior) and separated by 3/8 inch. A ¼ inch laceration is present on the nasal bridge. There is a ½ inch laceration at the lateral margin of the left eyebrow. A ½ x ¼ inch contusion is present on the mucosal surface of the right upper lip. There is a 2 x 1 ½ inch contusion on the right lateral surface of the neck. Internal examination shows galeal and subgaleal hemorrhage in the frontal (1 ¼ x 1 inches) and right parietal temporal (superior 1 3/8 x ½ inches, inferior 2 x 2 inches) regions. There is a depressed fracture (1 ½ x ¾ inches) in the right temporal region of the calvarium. Intramuscular hemorrhage is present focally in the right sternocleidomastoid muscle and the deep muscles of the right side of the neck.

ACLU Detainee DeathII ARMY MEDCOM 496

Torso:

A 5/16 x ¼ inch superficial penetrating injury is present in the mid clavicular region of the left shoulder. There is a 4 x 1 ¼ inch contusion of the right mid chest. There are multiple confluent and discontinuous areas of ecchymosis involving the entire back, posterior surfaces of the neck, shoulders, flanks and buttocks, bilaterally. Commingled with the areas of ecchymosis are numerous patterned contusions consisting of parallel linear contusions ranging in length from 1 inch to 5 inches, measuring 1/16 inch to ¼ inch in width and separated by a distance ranging from 1/8 inch to 3/8 inch. A patterned contusion (as described above) measuring 6 x ½ inch is present on the left lateral chest wall. Internal examination revealed intercostal muscle hemorrhage of the posterior chest wall (right 5 intercostal space, left 6th to 9th intercostal spaces). Incision and reflection of the skin of the back shows confluent and discontinuous intramuscular hemorrhage of the back and buttocks, bilaterally.

Extremities:

There is an 8 x 3 inch contusion of the lateral surface of the right upper arm. Within this area are two patterned contusions consisting of two parallel linear contusions measuring 1 ½ inches (superior) and 2 ½ inches (inferior), with an average width of 1/8 inch and separated by ¼ inch. A 9 ½ x 3 inch contusion is present on the dorsal surface of the right forearm, wrist and hand. A ½ x ¼ inch laceration is present on the posterior surface of the right elbow. Located lateral to this is a 1/8 inch superficial penetrating injury. There is a discontinuous contusion involving the lateral and dorsal surface of the entire left upper extremity. There are subungual hematomas of the left index and middle fingers. There is discontinuous contusion of the anterior surface of the right lower thigh, knee and lower leg measuring approximately 12 x 4 inches. Multiple lacerations ranging in length from 1/8 to ¼ inch are present on the anterior surface of the right lower leg. Multiple contusions are present on the posterior surfaces of the right lower thigh, knee and upper leg covering an area measuring 7 x 3 inches. Multiple contusions (area 16 x 5 inches) are present on the lateral and anterior surfaces of the left thigh, knee and lower leg. An irregular ¾ x ½ inch laceration is present on the anterior surface of the left knee. There is a patterned contusion consisting of parallel linear contusions on the lateral surface of the left thigh measuring 12 inches in length, averaging 1/8 inch in width and separated by a distance of ¼ inch. A patterned contusion consisting of two parallel linear contusions (2 ¼ x 1/8 inches) separated by 1/8 inch is present on the posterior surface of the left knee. Incision of the extremities reveals intramuscular hemorrhage in the posterior aspects of the shoulders, forearms and hands, bilaterally. There is also hemorrhage in the lateral aspect of the right ankle and the posterior surface of the left lower leg.

INTERNAL EXAMINATION

BODY CAVITIES:
(See above "Evidence of Injury")

The body is opened by the usual thoraco-abdominal incision and the chest plate is removed. Scattered pleural adhesions are present in the left chest cavity. All body organs are present in normal anatomical position. The subcutaneous fat layer of the abdominal wall is ½ inch thick.

ACLU Detainee DeathII ARMY MEDCOM 497

HEAD (CENTRAL NERVOUS SYSTEM):
(See above "Evidence of Injury")

The scalp is reflected. The calvarium of the skull is removed. The dura mater and falx are intact. There is no epidural or subdural hemorrhage present. The leptomeninges are thin and delicate. The cerebral hemispheres are symmetrical. The structures at the base of the brain, including cranial nerves and blood vessels are intact. Coronal sections through the cerebral hemispheres reveal no lesions. Transverse sections through the brainstem and cerebellum are unremarkable. The brain weighs 1580 gm.

NECK:
(See above "Evidence of Injury")

Layerwise dissection of the uninjured anterior strap muscles of the neck show them to be homogenous and red-brown. The thyroid cartilage and hyoid are intact. The larynx is lined by intact white mucosa. The thyroid is symmetric and red-brown, without cystic or nodular change. The tongue is free of bite marks, hemorrhage, or other injuries.

RESPIRATORY SYSTEM:

The right and left lungs weigh 510 gm and 600 gm, respectively. The external surfaces are smooth and deep red-purple. The pulmonary parenchyma is red-purple, exuding slight to moderately amounts of blood and frothy fluid. No mass lesions or areas of consolidation are present.

CARDIOVASCULAR SYSTEM:

The 370 gm heart is contained in an intact pericardial sac. The epicardial surface is smooth, with minimal fat investment. The coronary arteries arise normally, follow the usual distribution and are widely patent, without evidence of significant atherosclerosis or thrombosis. The myocardium is homogenous, red-brown, and firm; the atrial and ventricular septa are intact. The aorta gives rise to three intact and patent arch vessels. The vena cava and its major tributaries return to the heart in the usual distribution. The renal and mesenteric vessels are unremarkable.

LIVER & BILIARY SYSTEM:

The 1220 gm liver has an intact, smooth capsule and a sharp anterior border. The parenchyma is tan-brown and congested, with the usual lobular architecture. No mass lesions or other abnormalities are seen. The gallbladder contains approximately 9 ml of bile. The mucosal surface is green and velvety. The extrahepatic biliary tree is patent.

SPLEEN:

The 120 gm spleen has a smooth, intact, red-purple capsule. The parenchyma is maroon and congested, with distinct Malpighian corpuscles.

ACLU Detainee DeathII ARMY MEDCOM 498

PANCREAS:

The pancreas is firm and yellow-tan, with the usual lobular architecture. No mass lesions or other abnormalities are seen.

ADRENALS GLANDS:

The right and left adrenal glands are symmetric, with bright yellow cortices and grey medullae. No masses or areas of hemorrhage are identified.

GENITOURINARY SYSTEM:

The right and left kidneys weigh 110 gm and 120 gm, respectively. The external surfaces are intact and smooth. The cut surfaces are red-tan and congested, with uniformly thick cortices and sharp corticomedullary junctions. The pelves are unremarkable and the ureters are normal in course and caliber. Tan bladder mucosa overlies an intact bladder wall. The bladder contains less than 5 ml of cloudy yellow urine. The prostate is normal in size, with lobular, yellow-tan parenchyma. The seminal vesicles are unremarkable. The testes are free of mass lesions, contusions, or other abnormalities.

GASTROINTESTINAL TRACT:

The esophagus is intact and lined by smooth, grey-white mucosa. The stomach contains approximately 100 ml of liquid material. The gastric wall is intact. The duodenum, loops of small bowel and colon are unremarkable. The appendix is unremarkable.

MUSCULOSKELETAL SYSTEM:
(See above "Evidence of Injury")

Muscle development is normal. No evidence of non-traumatic bone or joint abnormalities is noted.

RADIOLOGIC EXAMINATION

No evidence of metallic foreign bodies is identified.

ADDITIONAL PROCEDURES/REMARKS

- Documentary photographs are taken by the OAFME staff photographers.
- Specimens retained for toxicologic testing and/or DNA identification are: blood, gastric contents, vitreous, bile, lung, liver, brain, kidney, spleen, adipose tissue and psoas muscle.
- Selected portions of organs are retained in formalin, without preparation of histologic slides.
- The dissected organs are forwarded with the body.
- Personal effects are released to the appropriate mortuary operations representatives.

ACLU Detainee DeathII ARMY MEDCOM 499

OPINION

This 36 year old male civilian died as the result of multiple blunt force injuries. According to reports, the decedent was subjected to prolonged interrogation before being found unresponsive. Autopsy examination revealed a depressed skull fracture and extensive subcutaneous hemorrhage of the posterior body surfaces. The manner of death is homicide.

(b)(6)

(b)(6) **Medical Examiner** (b)(6)

ACLU Detainee DeathII ARMY MEDCOM 500

CERTIFICATE OF DEATH *(OVERSEAS)*
Acte de décès (D'Outre-Mer)

NAME OF DECEASED *(Last, First, Middle)* Nom du décédé (Nom et prénoms)	GRADE Grade	BRANCH OF SERVICE Arme	SOCIAL SECURITY NUMBER Numéro de l'Assurance Social
BTB Humaidi, Al Jughayfi Haskim H,		Civilian	NA
ORGANIZATION Organisation	**NATION** *(e.g. United States)* Pays: Iraq	**DATE OF BIRTH** Date de naissance	**SEX** Sexe: [X] MALE [ ] FEMALE

RACE Race		MARITAL STATUS État Civil		RELIGION Culte	
[X]	CAUCASOID Caucasique	[ ]	SINGLE Célibataire	[ ]	PROTESTANT Protestant
[ ]	NEGROID Negroide	[ ]	MARRIED Marié	[ ]	CATHOLIC Catholique
[ ]	OTHER (Specify) Autre (Spécifier)	[ ]	WIDOWED Veuf	[ ]	JEWISH Juif
		[ ]	DIVORCED Divorcé	[X]	OTHER (Specify) Autre (Spécifier)
		[ ]	SEPARATED Séparé		

NAME OF NEXT OF KIN Nom du plus proche parent	RELATIONSHIP TO DECEASED Parenté du décédé avec le sus
STREET ADDRESS Domicile à (Rue)	**CITY OR TOWN OR STATE** *(Include ZIP Code)* Ville (Code postal compris)

MEDICAL STATEMENT Déclaration médicale

CAUSE OF DEATH (Enter only one cause per line) Cause du décès (N'indiquer qu'une cause par ligne)			INTERVAL BETWEEN ONSET AND DEATH Intervalle entre l'attaque et le décès
DISEASE OR CONDITON DIRECTLY LEADING TO DEATH [1] Maladie ou condition directement responsable de la mort.		Multiple blunt force injuries	
ANTECEDENT CAUSES Symptômes précurseurs de la mort	MORBID CONDITION, IF ANY, LEADING TO PRIMARY CAUSE Condition morbide, s'il y a lieu, menant à la cause primaire		
	UNDERLYING CAUSE, IF ANY, GIVING RISE TO PRIMARY CAUSE Condition morbide, s'il y a lieu, menant à la cause primaire		
OTHER SIGNIFICANT CONDITIONS [2] Autres conditions significatives [2]			

MODE OF DEATH Condition de décès	AUTOPSY PERFORMED Autopsie effectuée [X] YES Oui [ ] NO Non	CIRCUMSTANCES SURROUNDING DEATH DUE TO EXTERNAL CAUSES Circonstances de la mort suscitées par des causes extérieures
[ ] NATURAL Mort naturelle	MAJOR FINDINGS OF AUTOPSY Conclusions principales de l'autopsie	
[ ] ACCIDENT Mort accidentelle		
[ ] SUICIDE Suicide	NAME OF PATHOLOGIST Nom du pathologiste: (b)(6)	
[X] HOMICIDE Homicide	(b)(6)	DATE Date: 1 October 2006
		AVIATION ACCIDENT Accident à Avion: [ ] YES Oui [X] NO Non

DATE OF DEATH *(day, month, year)* Date de décès (le jour, le mois, l'année)	PLACE OF DEATH Lieu de décès
(b)(6) 2006	Hadithah Iraq

I HAVE VIEWED THE REMAINS OF THE DECEASED AND DEATH OCCURRED AT THE TIME INDICATED AND FROM THE CAUSES AS STATED ABOVE
J'ai examiné les restes mortels du défunt et je conclus que le décès est survenu à l'heure indiquée et à la suite des causes énumérées ci-dessus.

NAME OF MEDICAL OFFICER Nom du médecin militaire ou du médecin assistant	TITLE OR DEGREE Titre ou diplôme
(b)(6)	Medical Examiner
GRADE Grade: (b)(6)	**INSTALLATION OR ADDRESS** Installation ou adresse: Dover AFB, Dover DE
DATE Date: 01 Oct 06	(b)(6)

[1] State disease, injury or complication which caused death.
[2] State conditions contributing to the death but not related to the cause given condition causing death.
[1] Préciser la nature de la maladie, de la blessure ou de la complication qui a contribué à la mort, mais non la manière de mourir, telle qu'un arrêt du cœur, etc.
[2] Préciser la condition qui a contribué à la mort, mais n'ayant aucun rapport avec la maladie ou à la condition qui a provoqué la mort.

DD FORM 1 APR 77 2064 REPLACES DA FORM 3565, 1 JAN 72 AND DA FORM 3565-R(PAS), 26 SEP 75, WHICH ARE OBSOLETE.

ARMED FORCES INSTITUTE OF PATHOLOGY
Office of the Armed Forces Medical Examiner
1413 Research Blvd., Bldg. 102
Rockville, MD 20850
1-301-319-0000

AUTOPSY EXAMINATION REPORT

Name: BTB Mussa/Muhammed, Amer (b)(6)
ISN: (b)(6)
Date of Birth: (b)(6) 1969
Date of Death: (b)(6) 2006
Date/Time of Autopsy: 28 JUL 2006 @ 1200 hrs
Date of Report: 15 AUG 2006

Autopsy No.: (b)(6)
AFIP No.: (b)(6)
Rank: Civilian Detainee
Place of Death: Iraq
Place of Autopsy: Port Mortuary, Dover AFB, DE

Circumstances of Death: This 37 year-old civilian was a detainee at the Theater Internment Facility, Camp Bucca, Iraq when, as reported, he was found by other detainees lying on his back, unresponsive, in an empty detainee barracks building. The detainee was bleeding from his nose, mouth and eye areas. A string was secured tightly around his neck. Emergency medical service personal arrived and found no pulse or respirations. The detainee was transported to the Theater Internment Facility hospital. Attempts to revive the detainee were made. Despite those attempts the detainee died and was pronounced dead by the Chief of Emergency Medicine at the Hospital.

Authorization for Autopsy: Office of the Armed Forces Medical Examiner, IAW 10 USC 1471

Identification: Presumptive identification is made by examination of accompanying paperwork and ID tags

CAUSE OF DEATH: Ligature Strangulation

MANNER OF DEATH: Homicide

ACLU Detainee DeathII ARMY MEDCOM 502

PRELIMINARY AUTOPSY DIAGNOSIS

I. Ligature Strangulation:
   - A. Circumferential ligature furrow with only slight upward deviation
   - B. Focal hemorrhage of both thyrohyoid muscles
   - C. Focal Hemorrhage into the soft tissues surrounding the left superior horn of the thyroid cartilage
   - D. Fracture of the left superior horn of the thyroid cartilage
   - E. Petechial hemorrhages of the conjunctiva of the right lower eyelid

II. Other Injuries:
   - A. Contusion of the left side of the tongue, ¼-inch
   - B. Contusion of the right side of the face, medial to the right eye, 1 x ¼-inch, with associated swelling of the soft tissues surrounding the right eye
   - C. Subscleral hemorrhage of the right eye
   - D. Yellow-orange abrasion of the right ankle, ½-inch
   - E. Remote healing fracture of the distal left ulna

III. Medical Intervention:
   - A. Combitube (properly placed)
   - B. Intravenous access: Right groin
   - C. Urethral catheter

IV. Post-mortem changes:
   - A. Lividity is fixed on the posterior surface of the body except in areas exposed to pressure
   - B. Rigor is passing
   - C. Faint green discoloration of the right lower quadrant of the abdomen
   - D. Skin slippage on the face and neck

V. No natural disease is identified within the limits of the examination

VI. Toxicology (AFIP):
   - A. VOLATILES: No ethanol is detected in the blood and urine
   - B. DRUGS: Mirtazapine is detected in the urine and blood (0.08 mg/L). No other screened medications or drugs of abuse are detected in the urine
   - C. CARBON MONOXIDE: The carboxyhemoglobin saturation in the blood is 1%
   - D. CYANIDE: No cyanide is detected in the blood

ACLU Detainee DeathII ARMY MEDCOM 503

EXTERNAL EXAMINATION

The body is that of a well-developed, well-nourished appearing, muscular, 72-inch tall, 186-pounds male whose appearance is consistent with the reported age of 37-years. Lividity is fixed on the posterior surface of the body except in areas exposed to pressure. Rigor is passing, and the skin is cold to touch.

The scalp is covered with short black, hair in a normal distribution. There are two ½-inch scars on the vertex of the scalp and a ¼-inch area of thick rough skin on the center of the forehead. There is a black moustache. The irides are brown, and the pupils are round and equal in diameter. There are scattered petechial hemorrhages of the conjunctiva of the right lower eyelid. The external auditory canals are unremarkable. The ears are unremarkable. The nares are patent and the lips are atraumatic. The nose and maxillae are palpably stable. The teeth appear natural and in good condition. A mild amount of skin slippage is noted on the neck and nose.

The neck is described under "Evidence of Injury". The chest is symmetric. The abdomen is flat. The genitalia are those of a normal adult male. The testes are descended and free of masses. Pubic hair is present in a normal distribution. The buttocks and anus are unremarkable.

The upper and lower extremities are symmetric and without clubbing or edema.

There is a 3-inch oblique scar of the right side of the upper abdomen and lower chest. There is a faint green discoloration of the left lower abdominal skin. There are scars that measure 1 x ½-inch on both shins. There is a 1 x ½-inch scar on the posterior-medial aspect of the left thigh. The heals of both feet are dry and cracked.

CLOTHING AND PERSONAL EFFECTS

The following clothing items and personal effects are present on the body at the time of autopsy: The body is received unclad. Accompanying the body is a pair of white underwear.

MEDICAL INTERVENTION

- Combitube (properly placed)
- Intravenous access: Right groin
- Urethral catheter

RADIOGRAPHS

A complete set of postmortem radiographs is obtained and demonstrates the following:

- A healing fracture of the left ulna
- Trauma to the right orbit with soft tissue swelling and displacement of the lens of the globe
- Fluid in the trachea and main bronchi

ACLU Detainee DeathII ARMY MEDCOM 504

EVIDENCE OF INJURY

Ligature Strangulation: There is a 16-inch circumferential, tan-brown, continuous ligature furrow on the skin of the neck that is directed in a predominant horizontal direction with only slight upward deviation. On the anterior aspect of the neck there are two furrows that converge and co-mingle into one furrow on the posterior neck. On the anterior neck the ligature furrows cross below the thyroid cartilage 11-inches below the top of the head and along the superior third of the thyroid cartilage 10-inches below the top of the head. Both of the furrows on the anterior neck extend slightly superiorly on both sides of the neck, passing 3 ½-inches below the right ear, and 3 ½-inches below the left ear. The highest point of the furrow is on the posterior neck, located 8 ½-inches below the top of the head, and on the posterior midline. The width of the furrow ranges from 1/16 to 1/8-inch. The anterior neck dissection shows focal hemorrhage into both thyrohyoid muscles and into the soft tissues surrounding the left superior horn of the thyroid cartilage. The left superior horn of the thyroid cartilage is fractured. The hyoid bone is intact. There are associated petechial hemorrhages of the conjunctiva of the right lower eyelid.

Other Injuries: There is a ¼-inch contusion on the left side of the tongue. Medial to the right eye is a 1 x ¼-inch contusion with associated swelling of the soft tissues surrounding the right eye and displacement of the lens of the globe of the right eye. There is subscleral hemorrhage of the right eye. On the right ankle is a ½-inch yellow-orange abrasion. There is a remote healing fracture of the distal left ulna.

INTERNAL EXAMINATION

HEAD:
The galeal and subgaleal soft tissues of the scalp are free of injury. The calvarium is intact, as is the dura mater beneath it. Clear cerebrospinal fluid surrounds the 1690-gram brain, which has unremarkable gyri and sulci. Coronal sections demonstrate sharp demarcation between white and grey matter, without hemorrhage or contusive injury. The ventricles are of normal size. The basal ganglia, brainstem, cerebellum, and arterial systems are free of injury or other abnormalities. There are no skull fractures. The atlanto-occipital joint is stable.

NECK:
See "Evidence of Injury". The larynx is lined by intact white mucosa. The thyroid is symmetric and red-brown, without cystic or nodular change.

BODY CAVITIES:
The ribs, sternum, and vertebral bodies are visibly and palpably intact. No excess fluid is in the pleural, pericardial, or peritoneal cavities. The organs occupy their usual anatomic positions.

ACLU Detainee DeathII ARMY MEDCOM 505

RESPIRATORY SYSTEM:
The right and left lungs weigh 1000 and 860-grams, respectively. The external surfaces are smooth and deep red-purple. The pulmonary parenchyma is diffusely congested and edematous. No mass lesions or areas of consolidation are present.

CARDIOVASCULAR SYSTEM:
The 480-gram heart is contained in an intact pericardial sac. The epicardial surface is smooth, with minimal fat investment. The coronary arteries are present in a normal distribution, with a right-dominant pattern. The coronary arteries are patent. The myocardium is homogenous, red-brown, and firm. The valve leaflets are thin and mobile. The walls of the left and right ventricles are 1.0 and 0.3-centimeters thick, respectively. The endocardium is smooth and glistening. The aorta gives rise to three intact and patent arch vessels. The renal and mesenteric vessels are unremarkable.

LIVER & BILIARY SYSTEM:
The 2100-gram liver has an intact, smooth capsule and a sharp anterior border. The parenchyma is tan-brown and congested, with the usual lobular architecture. No mass lesions or other abnormalities are seen. The gallbladder contains a minute amount of green-black bile and no stones. The mucosal surface is green and velvety. The extrahepatic biliary tree is patent.

SPLEEN:
The 170-gm spleen has a smooth, intact, red-purple capsule. The parenchyma is maroon and congested, with distinct Malpighian corpuscles.

PANCREAS:
The pancreas is firm and yellow-tan, with the usual lobular architecture. No mass lesions or other abnormalities are seen.

ADRENALS:
The right and left adrenal glands are symmetric, with bright yellow cortices and grey medullae. No masses or areas of hemorrhage are identified.

GENITOURINARY SYSTEM:
The right and left kidneys weigh 160 and 170-grams, respectively. The external surfaces are intact and smooth. The cut surfaces are red-tan and congested, with uniformly thick cortices and sharp corticomedullary junctions. The pelves are unremarkable and the ureters are normal in course and caliber. White bladder mucosa overlies an intact bladder wall. The bladder contains scant yellow urine. The prostate is normal in size, with lobular, yellow-tan parenchyma. The seminal vesicles are unremarkable. The testes are free of mass lesions, contusions, or other abnormalities.

GASTROINTESTINAL TRACT:
The esophagus is intact and lined by smooth, grey-white mucosa. The stomach contains approximately 100-milliliters of partially digested food. The gastric wall is intact. The duodenum, loops of small bowel, and colon are unremarkable. The appendix is present.

ACLU Detainee DeathII ARMY MEDCOM 506

ADDITIONAL PROCEDURES

1. Documentary photographs are taken by OAFME staff photographers.
2. Full body radiographs are obtained and demonstrate the injuries as described as well as fluid in the trachea and main bronchi and central consolidation of both lungs.
3. Specimens retained for toxicology testing and/or DNA identification are: blood, vitreous fluid, bile, urine, liver, lung, spleen, brain, kidney, adipose, muscle and gastric contents
4. The dissected organs are forwarded with the body.
5. Selected portions of organs are retained in formalin, without preparation of histological slides.
7. Identifying marks include: Two scars on the scalp, a callus on the center of the forehead, one scar on the left side of the abdomen and one scar on each leg.

MICROSCOPIC EXAMINATION

Selected portions of organs are retained in formalin, without preparation of histologic slides.

ACLU Detainee DeathII ARMY MEDCOM 507

OPINION

This 37 year-old male died of ligature strangulation. As reported he was found by other detainees unresponsive in an empty detainee barracks building with a string secured tightly around his neck. A predominately horizontal ligature furrow with underlying fracture of the thyroid cartilage and hemorrhage into both thyrohyoid muscles was evident at autopsy. Further, there were blunt force injuries of the right side of the face. The toxicology screen was negative for cyanide, drugs of abuse and ethanol. The carboxyhemoglobin saturation is 1%. Mirtazapine is detected in the urine and blood. The manner of death is homicide.

(b)(6)

(b)(6) Medical Examiner

(b)(6)

ACLU Detainee DeathII ARMY MEDCOM 508

ARMED FORCES INSTITUTE OF PATHOLOGY
Office of the Armed Forces Medical Examiner
1413 Research Blvd., Bldg. 102
Rockville, MD 20850
1-301-319-0000

FINAL AUTOPSY EXAMINATION REPORT

Name: (BTB) SHADAD, Hishim
ISN: (b)(6)
Date of Birth: (BTB (b)(6) 1966
Date of Death: (b)(6) 2006
Date/Time of Autopsy: 17 JUL 2006 @ 090
Date of Report: 30 NOV 2006

Autopsy No.: (b)(6)
AFIP No.: (b)(6)
Rank: Iraqi Civilian Detainee
Place of Death: Abu Ghraib, Iraq
Place of Autopsy: Port Mortuary, Dover AFB, DE

Circumstances of Death: This 40-year-old Iraqi male sustained gunshot wounds on 08 JUN 2006 under unknown circumstances. He was initially treated in an Iraqi hospital with chest tubes and fluid resuscitation. While being transported by a civilian ambulance, he was detained and transported to 10th CSH for treatment. While there, he underwent surgery, and it was discovered that he was an anti-Iraqi fighter. He was transferred to the intensive care unit of the 21st CSH (BCCF) where he remained until his death from complications of his wounds, including sepsis and multi-organ system failure.

Authorization for Autopsy: Office of the Armed Forces Medical Examiner, IAW 10 USC 1471.

Identification: Presumptive identification is based on hospital records and identification bands. A postmortem fingerprint examination is conducted for comparison to exemplars should they become available.

CAUSE OF DEATH: **COMPLICATIONS OF GUNSHOT WOUND OF THE TORSO**

MANNER OF DEATH: **HOMICIDE**

ACLU Detainee DeathII ARMY MEDCOM 509

FINAL AUTOPSY DIAGNOSES

I. Gunshot Wound of the Torso

A. Entrance Wound: On the left chest, 20-inches below the top of the head and 6 ¼-inches left of the anterior midline of the torso in the anatomic position is a 1 ¼ x ½-inch wound with rounded, soft granulating edges. Marginal abrasion, soot or stipple are not appreciated
B. Wound Path: Skin and subcutaneous tissue of the left chest, muscle, the inferior aspect of the lateral left 5th rib (fractured), (by report) the lower lobe of the left lung, the left hemidiaphragm, the stomach, the transverse colon, the liver and the right 6th and 7th costal cartilage (fractured) (no exit wound)
C. Recovered: No bullet or bullet fragments are recovered
D. Direction: Left to right and downward (by report)
E. Associated Injuries: Abdominal organ injuries (cannot be assessed due to prolonged hospitalization)

II. Complications of Gunshot Wound of the Torso

A. Pulmonary congestion, edema and focal consolidation, bilateral (Right lung 1,530-grams, Left lung 1,390-grams)
B. Pleural effusion, bilateral (100-milliliters of serosanguinous fluid in both pleural cavities)
C. Pericardial effusion (50-milliliters of serosanguinous fluid)
D. Peritoneal effusion (500-milliliters of serosanguinous fluid)
E. Peripheral edema
F. Heart failure with associated biventricular dilatation
G. Dense adhesions of the large and small bowel
H. Transverse skin ulceration, 11 x 1/8-inch
I. Decubitis ulcer, mid lower back, 1 ½ x ¾-inch
J. Scrotal ulcer, 1 ½ x1-inch
K. Gram-negative sepsis (by review of medical records)

III. Post-Mortem Changes

A. Lividity is posterior and fixed
B. Rigor is passing and equal in all extremities
C. Focal areas of epidermal blistering and skin slippage

IV. Evidence of Medical Therapy

A. Recent tracheostomy inferior to the cricoid cartilage
B. Right nasogastric tube
C. Right and left chest tubes (by report)
D. Right subclavian intravenous line
E. Right radial arterial line
F. Urinary bladder catheter
G. Open abdominal incision, 13 ½ x 9-inches, covered by a medical dressing
H. Medical dressing over sacral area
I. Medical dressing on left foot

ACLU Detainee DeathII ARMY MEDCOM 510

J. Electrocardiogram electrodes on anterior torso and anterior thighs
K. Multiple drain sites on the anterior torso

V. There is no evidence of physical abuse

VI. Toxicology

A. The blood and vitreous fluid are tested for ethanol and none is found.
B. The blood is tested for cyanide and none is found.
C. The carboxyhemoglobin saturation in the blood is less than 1%.
D. The blood is screened for medications and drugs of abuse and the following medications were detected:
   1. The blood contains 0.13 milligrams per liter of midazolam (a benzodiazepine tranquilizer)
   2. The blood contains 0.33 milligrams per liter of 1-hydroxymidazolam (a metabolite of midazolam)
   3. The blood contains 0.05 milligrams per liter of diphenhydramine (an antihistamine)
   4. The blood contains 3.2 milligrams per liter of metoclopramide (an antiemetic)
   5. The blood contains 0.039 milligrams per liter of fentanyl (a narcotic analgesic)

EXTERNAL EXAMINATION

The body is that of a well-developed, well-nourished appearing, 69 ½-inch, and 227-pound male whose appearance is consistent with the reported age of 40-years. Lividity is posterior and fixed, rigor is passing and equal in all extremities, and the body temperature is cold to touch. There is generalized body and extremity edema.

The scalp is covered with short black hair in a normal distribution. The irides are brown, the corneae are cloudy and the pupils are round and equal in diameter. The external auditory canals are patent and free of foreign material. The ears are unremarkable. The nares are patent and the lips are atraumatic. The nose and maxillae are palpably stable. The teeth appear natural and in fair condition.

The neck is straight, and the trachea is midline and mobile with evidence of medical therapy. The chest is symmetric; injuries to the chest are described below (see "Evidence of Injury"). Multiple surgical drain sites are scattered over the lateral right and left abdomen and range in size from 3/8 x 1/8-inch to 1 ¼ x ½-inch. The abdominal midline bears an open surgical incision measuring 13 ½ x 9-inches with granulating edges and visible loops of small and large bowel. The lower abdomen also has a transverse, 11 x 1/8-inch skin ulcer. The posterior torso is remarkable for skin slippage and a 1 ½ x ¾-inch decubitis ulcer on the mid lower back. The genitalia are those of a normal adult male. The scrotum has a 1 ½ x 1-inch ulcer with a hemorrhagic base. The testes are descended and free of masses. Pubic hair is present in a normal distribution. The buttocks and anus are unremarkable.

ACLU Detainee DeathII ARMY MEDCOM 511

The upper and lower extremities are symmetric and without clubbing. There is a ¾ x ¼-inch healing abrasion in the right popliteal fossa. There is a 3 ½ x 2 ¼-inch bulla on the anterior left ankle. There is generalized edema and focal skin slippage is noted on both upper and lower extremities.

CLOTHING AND PERSONAL EFFECTS

The body is received nude without clothing or personal effects.

MEDICAL INTERVENTION

- Recent tracheostomy inferior to the cricoid cartilage
- Right nasogastric tube
- Right and left chest tubes (by report)
- Right subclavian intravenous line
- Right radial arterial line
- Urinary bladder catheter
- Open abdominal incision, 13 ½ x 9-inches, with granulating edges, covered by a medical dressing
- Medical dressing over sacral area
- Medical dressing on left foot
- Electrocardiogram electrodes on anterior torso and anterior thighs
- Multiple drain sites on the anterior torso

RADIOGRAPHS

A complete set of postmortem radiographs is obtained and demonstrates the following:

- Right 6th rib fracture
- Left 5th rib fracture
- Multiple surgical staples in the abdomen
- No metallic fragments (other than medical devices) are identified
- No long bone fractures are identified
- No skull fractures are identified

ACLU Detainee DeathII ARMY MEDCOM 512

EVIDENCE OF INJURY

The ordering of the following injuries is for descriptive purposes only, and is not intended to imply order of infliction or relative severity. All wound pathways are given relative to standard anatomic position.

Gunshot Wound of the Torso

On the left chest, 20-inches below the top of the head and 6 ¼-inches left of the anterior midline of the torso in the anatomic position is a 1 ¼ x ½-inch entrance wound with rounded, soft granulating edges. Marginal abrasion, soot or stipple are not appreciated due to prolonged hospitalization.

The bullet injured skin and subcutaneous tissue of the left chest, muscle, the inferior aspect of the lateral left 5th rib (fractured), the lower lobe of the left lung (by report), the left hemidiaphragm (surgically repaired), the stomach (surgically repaired), the transverse colon (surgically repaired), the liver (by report) and the right 6th and 7th costal cartilage (fractured). There is no exit wound and no bullet or bullet fragments are recovered. The wound path is directed slightly back to front, left to right and downward.

Associated with the gunshot wound of the torso are sepsis and multi-organ system failure during his prolonged hospitalization.

INTERNAL EXAMINATION

HEAD:
The galeal and subgaleal soft tissues of the scalp are free of injury. The calvarium is intact, as is the dura mater beneath it. Clear cerebrospinal fluid surrounds the 1,530-gram brain, which appears slightly edematous with widened gyri and narrowed sulci. Coronal sections demonstrate sharp demarcation between white and grey matter, without hemorrhage or contusive injury. The ventricles are of normal size. The basal ganglia, brainstem, cerebellum, and arterial systems are free of injury or other abnormalities. There are no skull fractures. The atlanto-occipital joint is stable.

NECK:
Layer-wise dissection of the anterior strap muscles of the neck reveals homogenous and red-brown muscle, without hemorrhage except in the area of the tracheostomy. The thyroid cartilage and hyoid bone are intact. The larynx is lined by intact white mucosa except in the area of the tracheostomy. The thyroid gland is symmetric and red-brown, without cystic or nodular change. The tongue is free of bite marks, hemorrhage, or other injuries.

BODY CAVITIES:
The sternum and vertebral bodies are visibly and palpably intact. Injuries to the ribs are noted above (see "Evidence of Injury"). The right and left pleural cavities contain 100-

ACLU Detainee DeathII ARMY MEDCOM 513

milliliters of serosanguinous fluid each, the pericardial sac contains 50-milliliters of serosanguinous fluid and the peritoneal cavity contains 500-milliliters of serosanguinous fluid. The organs occupy their usual anatomic positions except where slightly distorted by surgical intervention.

RESPIRATORY SYSTEM:
The right and left lungs weigh 1,530 and 1,390-grams, respectively. The external surfaces are rough and deep red-purple with loose adhesions. The pulmonary parenchyma is diffusely congested and focally consolidated. No mass lesions are identified.

CARDIOVASCULAR SYSTEM:
The 350-gram heart is contained in an intact pericardial sac. The epicardial surface is smooth, with minimal fat investment. The coronary arteries are present in a normal distribution, with a right-dominant pattern. Cross sections of the vessels show no luminal narrowing. The myocardium is homogenous, red-brown, and firm. The valve leaflets are thin and mobile. The walls of the left and right ventricles are 0.9 and 0.4-centimeters thick, respectively; biventricular dilatation is present. The endocardium is smooth and glistening. The aorta gives rise to three intact and patent arch vessels. The renal and mesenteric vessels are unremarkable.

LIVER & BILIARY SYSTEM:
The 2,770-gram liver has an intact, smooth capsule and a sharp anterior border. The parenchyma is tan-brown and congested, with the usual lobular architecture. No mass lesions or other abnormalities are seen. The gallbladder contains a minute amount of green-black bile and no stones. The mucosal surface is green and velvety. The extrahepatic biliary tree is patent.

SPLEEN:
The 420-gram spleen has a smooth, intact, red-purple capsule. The parenchyma is soft, maroon and congested, with indistinct Malpighian corpuscles.

PANCREAS:
The pancreas has autolytic changes, with the usual lobular architecture. No mass lesions or other abnormalities are seen.

ADRENALS:
The right and left adrenal glands are symmetric, with autolytic changes. No masses are identified.

GENITOURINARY SYSTEM:
The right and left kidneys weigh 160 and 170-grams, respectively. The external surfaces are intact and smooth. The cut surfaces are red-tan and congested, with uniformly thick cortices and sharp cortico-medullary junctions. The pelves are unremarkable and the ureters are normal in course and caliber. Gray-pink bladder mucosa overlies an intact bladder wall. The bladder contains no urine. The prostate is normal in size, with lobular,

ACLU Detainee DeathII ARMY MEDCOM 514

yellow-tan parenchyma. The seminal vesicles are unremarkable. The testes are free of mass lesions, contusions, or other abnormalities.

GASTROINTESTINAL TRACT:
The esophagus is intact and lined by smooth, gray-white mucosa. The stomach is densely adhesed to multiple loops of large and small bowel and contains approximately 60-milliliters of brown fluid. The gastric wall is intact with a surgical repair. The duodenum, loops of small bowel and colon are remarkable for dense adhesions between the loops of small bowel and the large bowel; multiple surgically repaired enterotomies are identified, but the dense adhesions may mask possible perforations and/or obstructions. The appendix is present.

MUSCULOSKELETAL SYSTEM:
There is no non-traumatic bone or joint abnormalities. Skeletal muscle development is normal.

MICROSCOPIC EXAMINATION

Selected portions of organs are retained in formalin, without preparation of histological slides.

ADDITIONAL PROCEDURES/REMARKS

- Documentary photographs are taken by AFMES staff photographers
- Specimens retained for toxicologic testing and/or DNA identification are: heart blood, vitreous fluid, gastric contents, spleen, liver, lung, bile, kidney, brain, adipose tissue, and psoas muscle
- The dissected organs are forwarded with the body
- The body is sutured closed without embalming
- The following identifying body marks are present: Tattoos (b)(6)

(b)(6)

ACLU Detainee DeathII ARMY MEDCOM 515

OPINION

This 40-year-old Iraqi male civilian detainee, (BTB) (b)(6) died as a result of a gunshot wound of the torso he sustained under uncertain circumstances. He expired after a 30-day hospital course that was complicated by sepsis and multi-organ system failure. The wound pathway is reconstructed from the autopsy findings and hospital records and passes through the lateral left chest, the lower lobe of the left lung, the left hemidiaphragm, the stomach, the large bowel, the liver, and the right upper abdominal wall. The bullet did not exit the body; no bullet or bullet fragments were recovered during the autopsy, nor were any bullet or bullet fragments reportedly recovered during surgeries. Toxicological testing found therapeutic levels of a benzodiazepine, an antihistamine, an antiemetic and a narcotic analgesic in the blood. The manner of death is homicide.

(b)(6)

(b)(6) Medical Examiner

(b)(6)

(b)(6) Medical Examiner

(b)(6)

ACLU Detainee DeathII ARMY MEDCOM 516

CERTIFICATE OF DEATH *(OVERSEAS)*
Acte dé décès (D'Outre-Mer)

NAME OF DECEASED *(Last, First, Middle)* Nom du décédé (Nom et prénoms)	GRADE Grade	BRANCH OF SERVICE Arme	SOCIAL SECURITY NUMBER Numéro de l'Assurance Social
BTB Shadad, Hishim,		Civilian	(b)(6)
ORGANIZATION Organisation	**NATION** *(e.g. United States)* Pays	**DATE OF BIRTH** Date de naissance	**SEX** Sexe
	Iraq	(b)(6) 1966	[X] MALE [ ] FEMALE

RACE Race		MARITAL STATUS État Civil				RELIGION Culte			
	CAUCASOID Caucassique		SINGLE Célibataire		DIVORCED Divorcé		PROTESTANT Protestant		OTHER (Specify) Autre (Spécifier)
	NEGROID Negriode		MARRIED Marié		SEPARATED Séparé		CATHOLIC Catholique	X	
X	OTHER (Specify) Autre (Spécifier)		WIDOWED Veuf				JEWISH Juif		

NAME OF NEXT OF KIN Nom du plus proche parent	RELATIONSHIP TO DECEASED Parenté du décéde avec le sus
STREET ADDRESS Domicilé à (Rue)	CITY OR TOWN OR STATE *(Include ZIP Code)* Ville (Code postal compris)

MEDICAL STATEMENT Déclaration médicale

	CAUSE OF DEATH *(Enter only one cause per line)* Cause du décés (N'indiquer qu'une cause par ligne)	INTERVAL BETWEEN ONSET AND DEATH Intervalle entre l'attaque et le décés
DISEASE OR CONDITON DIRECTLY LEADING TO DEATH [1] Maladie ou condition directement responsable de la mort. [1]	Complications of Gunshot Wound to the Torso	Weeks
ANTECEDENT CAUSES Symptômes précurseurs de la mort. MORBID CONDITION, IF ANY, LEADING TO PRIMARY CAUSE Condition morbide, s'il y a lieu, menant à la cause primaire		
UNDERLYING CAUSE, IF ANY, GIVING RISE TO PRIMARY CAUSE Condition morbide, s'il y a lieu, menant à la cause primaire		
OTHER SIGNIFICANT CONDITIONS [2] Autres conditions significatives [2]		

MODE OF DEATH Condition de décés	AUTOPSY PERFORMED Autopsie effectuée [X] YES Oui [ ] NO Non	CIRCUMSTANCES SURROUNDING DEATH DUE TO EXTERNAL CAUSES Circonstances de la mort suscitées par des causes extérieures
[ ] NATURAL Mort naturelle	MAJOR FINDINGS OF AUTOPSY Conclusions principales de l'autopsie	
[ ] ACCIDENT Mort accidentelle		
[ ] SUICIDE Suicide	NAME OF PATHOLOGIST Nom du pathologiste (b)(6)	
[X] HOMICIDE Homicide	SIGNATURE Signature	DATE Date 17 July 2006
		AVIATION ACCIDENT Accident à Avion [ ] YES Oui [X] NO Non

DATE OF DEATH *(day, month, year)* Date de décés (le jour, le mois, l'année)	PLACE OF DEATH Lieu de décés
(b)(6) 2006	Iraq

I HAVE VIEWED THE REMAINS OF THE DECEASED AND DEATH OCCURRED AT THE TIME INDICATED AND FROM THE CAUSES AS STATED ABOVE
J'ai examiné les restes mortels du dé funtet je conclus que le décès est survenu à l'heure indiquée et à, la suite des causes énumérées ci-dessus.

NAME OF MEDICAL OFFICER Nom du médicin militaire ou du médicin sanitaire	TITLE OR DEGREE Titre ou diplômé
(b)(6)	Medical Examiner

GRADE Grade	INSTALLATION OR ADDRESS Installation ou adresse
(b)(6)	Dover AFB, Dover DE
DATE Date	SIGNATURE Signature

[1] State disease, injury or complication which caused death, but not mode of dying such as heart failure, ect.
[2] State conditions contributing to the death, but not related to the disease or condition causing death.
[1] Préciser la nature de la maladie, de la blessure ou de la complication qui a contribué à la mort, mais non la manière de mourir, telle qu 'un arrêt du coeur, etc
[2] Préciser la condition qui a contribué à la mort, mais n'ayant aucun rapport avec la maladie ou à la condition qui a provoqué la mort.

DD FORM 1 APR 77 2064 REPLACES DA FORM 3565, 1 JAN 72 AND DA FORM 3565-R(PAS), 26 SEP 75, WHICH ARE OBSOLETE.

CERTIFICATE OF DEATH *(OVERSEAS)*
Acte de decès (D'Outre-Mer)

NAME OF DECEASED (Last, First, Middle) / Nom du décédé (Nom et prénoms)	GRADE / Grade	BRANCH OF SERVICE / Arme	SOCIAL SECURITY NUMBER / Numéro de l'Assurance Sociale
BTB Hamed, Salah, Safak		Civilian	(b)(6)
ORGANIZATION / Organisation	NATION (e.g. United States) / Pays: Iraq	DATE OF BIRTH / Date de naissance: (b)(6) 1969	SEX / Sexe: [X] MALE [ ] FEMALE

RACE / Race	MARITAL STATUS / Etat Civil	RELIGION / Culte
[ ] CAUCASOID / Caucasique	[ ] SINGLE / Celibataire	[ ] PROTESTANT / Protestant
[ ] NEGROID / Negroïde	[ ] MARRIED / Mariée	[ ] CATHOLIC / Catholique
[X] OTHER (Specify) / Autre (Spécifier)	[ ] WIDOWED / Veuf	[ ] JEWISH / Juif
	[ ] DIVORCED / Divorce	[X] OTHER (Specify) / Autre (Spécifier)
	[ ] SEPARATED / Séparé	

NAME OF NEXT OF KIN / Nom du plus proche parent	RELATIONSHIP TO DECEASED / Parenté du décédé avec le sujet
STREET ADDRESS / Domicile à l'Ruel	CITY OR TOWN OR STATE / Include ZIP Code / Ville (Code postal compris)

MEDICAL STATEMENT **Declaration medicale**

CAUSE OF DEATH / Enter only one cause per line. / Cause du décès (Ne indiquer qu'une cause par ligne)		INTERVAL BETWEEN ONSET AND DEATH / Intervalle entre l'attaque et le décès
DISEASE OR CONDITION DIRECTLY LEADING TO DEATH / Maladie ou condition directement responsable de la mort	Complications of gunshot wound of abdomen and right leg	
ANTECEDENT CAUSES / Symptômes ou prémonitions de la mort: MORBID CONDITION, IF ANY, LEADING TO PRIMARY CAUSE / Condition morbide, s'il y a lieu, menant à la cause primaire		
UNDERLYING CAUSE, IF ANY, GIVING RISE TO PRIMARY CAUSE / Condition morbide, s'il y a lieu, menant à la cause primaire		
OTHER SIGNIFICANT CONDITIONS / Autres conditions signifiantes		

MODE OF DEATH / Condition de décès	AUTOPSY PERFORMED / Autopsie effectuée: [X] YES / Oui [ ] NO / Non	CIRCUMSTANCES SURROUNDING DEATH DUE TO EXTERNAL CAUSES / Circonstances de la mort suscitées par des causes extérieures
[ ] NATURAL / Mort naturelle	MAJOR FINDINGS AT AUTOPSY / Conclusions principales de l'autopsie	
[ ] ACCIDENT / Mort accidentelle		
[ ] SUICIDE / Suicide	NAME OF PATHOLOGIST / Nom du pathologiste: (b)(6)	
[X] HOMICIDE / Homicide	(b)(6)	DATE / Date: 11 July 2006
		AVIATION ACCIDENT / Accident à l'avion: [ ] YES / Oui [X] NO / Non

DATE OF DEATH (day, month, year) / Date du décès (Le jour, le mois, l'année)	PLACE OF DEATH / Lieu de décès
(b)(6) 2006	

I HAVE VIEWED THE REMAINS OF THE DECEASED AND DEATH OCCURRED AT THE TIME INDICATED AND FROM THE CAUSES AS STATED ABOVE
J'ai examiné les restes mortels du de feu et le décès est survenu à l'heure indiquée et à la suite des causes énumérées ci-dessus

NAME OF MEDICAL OFFICER / Nom du médecin militaire ou du médecin sanitaire	TITLE OR DEGREE / Titre ou diplôme
(b)(6)	Medical Examiner

GRADE / Grade	INSTALLATION OR ADDRESS / Installation ou adresse
(b)(6)	Dover AFB, Dover DE
DATE / Date: 04 Oct 06	(b)(6)

[illegible]

DD FORM 1 APR 77 2064 REPLACES DA FORM 3565, 1 JAN 72 AND DA FORM 3565-R(PAS), 26 SEP 75, WHICH ARE OBSOLETE.

ARMED FORCES INSTITUTE OF PATHOLOGY
Office of the Armed Forces Medical Examiner
1413 Research Blvd., Bldg. 102
Rockville, MD 20850
1-301-319-0000

FINAL AUTOPSY REPORT

Name: Al Zahrani, Yasir T.
Detainee Number: (b)(6)
Date of Birth (b)(6) 1984
Date of Death (b)(6) 2006
Date of Autopsy: 10 June 2006 @ 1830
Date of Report: 02 August 2006

Autopsy No.: (b)(6)
AFIP No.: (b)(6)
Rank: Detainee
Place of Death: Detainee Facility, Guantanamo Bay, Cuba
Place of Autopsy: Naval Hospital Guantanamo Bay, Cuba

Circumstances of Death: This 21 year-old detainee, by report, was found hanging in his secure cell at the detainee confinement facility at approximately 0020 on (b)(6) 2006. Medical resuscitation was unsuccessful and he was declared dead at 0150. In the medical record it states he was unresponsive, pulse-less, apneic, with fixed and dilated pupils, and in rigor mortis when he arrived at the detention clinic at 0048.

Authorization for Autopsy: Office of the Armed Forces Medical Examiner, IAW 10 USC 1471

Identification: Detention records. Fingerprints and DNA sample obtained.

Personnel present for the autopsy:

1. Special Agent (b)(6) Naval Criminal Investigative Service (NCIS)
2. (b)(6) Autopsy Assistant
3. (b)(6) Medical Photographer
4. (b)(6) Medical Examiner Investigator
5. (b)(6) Medical Examiner (b)(6)

CAUSE OF DEATH: Hanging

MANNER OF DEATH: Suicide

ACLU Detainee DeathII ARMY MEDCOM 519

Final Anatomic Diagnoses

I. Hanging
   A. Circumferential dried abrasion collar around the neck
   B. Diffuse hemorrhage into the muscles of the neck
   C. Hyoid bone intact
   D. Tardieu spots on the dorsum of the feet

II. Hands and feet bound by cotton-like material

III. Soft tissue hemorrhage lateral left wrist

III. No significant natural disease processes identified

IV. Status Post attempted resuscitation with intubation and cricoid pressure.

IV. Toxicology –Negative

ACLU Detainee DeathII ARMY MEDCOM 520

EXTERNAL EXAMINATION

The body, received wrapped in a white sheet, is that of a well-developed, well-nourished appearing, muscular, 67 inches in length, 151 pound (per medical record as of 21 May 2006), white male whose appearance is consistent with the reported age of 21 years. Lividity is posterior and fixed, rigor is equal and fixed in all extremities, and the temperature is that of the refrigeration unit (34-39 degrees Fahrenheit).

The head and neck are wrapped with a blue plastic pad secured with tape. The scalp is covered with black hair in a normal distribution. The irides are brown. The sclerae and conjunctivae are congested and free of petechiae. The external auditory canals are unremarkable. The ears are unremarkable. The nares are patent and the lips are atraumatic. The nose and maxillae are palpably stable. The teeth appear in good condition. Facial hair consists of a full beard and mustache.

The neck is straight, and the trachea is midline and mobile. The chest is symmetric. The abdomen is flat. The genitalia are those of a normal adult circumcised male. The testes are descended and free of masses. Pubic hair is present in a normal distribution. The buttocks and anus are unremarkable.

The upper and lower extremities are symmetric and without clubbing or edema. Strips of bed-sheet-like material tied into knots loosely bind the hands and feet. SA (b)(6) has taken these bindings into custody. There are two round scars, 1 inch and ¾ inch in diameter on the back of the right leg. There is another ½ x ¾ inch scar proximal to the round scars on the leg. There is a ¼ inch scar on the back of the left thigh.

CLOTHING AND PERSONAL EFFECTS

The following clothing items and personal effects are present on the body at the time of autopsy:

None

MEDICAL INTERVENTION

Evidence of medical intervention includes:

- Nasal Airway
- Oral-gastric tube, appropriately located
- Orally placed endotracheal tube, appropriately located
- Intravenous catheter with attached tubing bag of intravenous solution, left antecubital fossa
- Urinary bladder catheter and attached bag
- Multiple electrocardiogram pads on the chest
- Puncture marks, left forearm and left and right antecubital fossae

ACLU Detainee DeathII ARMY MEDCOM 521

RADIOGRAPHS

A complete set of postmortem radiographs is obtained and are consistent with the findings described below.

EVIDENCE OF INJURY

The ordering of the following injuries is for descriptive purposes only, and is not intended to imply order of infliction or relative severity. All wound pathways are given relative to standard anatomic position.

Evidence of Hanging

There is a circumferential dried abrasion furrow around the neck. The furrow is irregular with the width varying from 1/8 to 1 inch. Within the furrow the skin is imprinted with a very fine weave type pattern. The furrow is located 11 ½ inches below the top of the head at the anterior midline, 10 inches below the top of the head at the level of the left auditory meatus, and 10 inches below the top of the head at the level of the right auditory meatus. The anterior portion of the furrow is located below the thyroid cartilage. The furrow becomes less well defined and forms an inverted "v" on the back of the head, 5 ¾ inches below the top of the head and 1 inch to the left of the posterior midline. On the left side of the anterior neck there are additional well-defined and superficial abrasions adjacent to the main furrow, 1/8 to 1¼ inches in length. Encircling the neck are two segments of cotton-like material consistent with a T-shirt. The material has been cut or torn and tied with knots. Distal to the knots there are strips of material that have been cut leaving four loose ends per piece of material. SA (b)(6) has taken the material into custody.

Additional items are submitted by NCIS that were recovered from the cell of the decedent. Included are three segments of braided white t-shirt like material. One has a knot at one end and the other end is cut. The material is cut through two segments of the braiding near the knotted end. There is smaller loop of the same material tied with a knot and looped around the first segment. The third portion of braided material has one end cut and the other end is a loop that is secured by similar material wrapped around the two braided segments. Also submitted is another portion of white t-shirt like material that has been cut or torn into an elongated segment. The material is tied with a knot leaving two loose ends.

Internally, there are multiple hemorrhages throughout the anterior neck soft tissue:

1. Medial right sternocleidomastoid muscle, 1 x ¼ inch
2. Deep right sternocleidomastoid muscle, ¾ x ¼ inch
3. Anterior left sternocleidomastoid muscle, (2) each ½ inch in diameter
4. Deep left sternocleidomastoid muscle, ½ x ¼ inch
5. Left sternothyroid muscle, ¼ x ¼ inch
6. Left thyrohyoid membrane, ½ x 3/8 inches
7. Left longus capitus muscle, ¾ x ¼ inch

ACLU Detainee DeathII ARMY MEDCOM 522

The posterior neck is free of hemorrhage into the soft tissue.

There are faint tardieu spots on the ankles and dorsal surface of the feet.

Additional Injuries

There is a 1 ½ x ½ inch area of soft tissue hemorrhage in the subcutaneous tissue of the lateral aspect of the left wrist (in the anatomic position).

INTERNAL EXAMINATION

HEAD:
The galeal and subgaleal soft tissues of the scalp are free of injury. The calvarium is intact, as is the dura mater beneath it. Clear cerebrospinal fluid surrounds the 1300 gm brain, which has unremarkable gyri and sulci. Coronal sections demonstrate sharp demarcation between white and grey matter, without hemorrhage or contusive injury. The ventricles are of normal size. The basal ganglia, brainstem, cerebellum, and arterial systems are free of injury or other abnormalities. There are no skull fractures. The atlanto-occipital joint is stable.

NECK:
Injuries of the anterior strap muscles have been described. The thyroid cartilage and hyoid are intact. The larynx is lined by intact white mucosa. The thyroid is symmetric and red-brown, without cystic or nodular change. The tongue is free of bite marks, hemorrhage, or other injuries.

BODY CAVITIES:
The ribs, sternum, and vertebral bodies are visibly and palpably intact. No excess fluid is in the pleural, pericardial, or peritoneal cavities. The organs occupy their usual anatomic positions.

RESPIRATORY SYSTEM:
The right and left lungs weigh 600 and 700 gms, respectively. The external surfaces are smooth and deep red-purple. The pulmonary parenchyma is diffusely congested and edematous. No mass lesions or areas of consolidation are present.

CARDIOVASCULAR SYSTEM:
The 230 gm heart is contained in an intact pericardial sac. The epicardial surface is smooth, with minimal fat investment. The ostium for the left anterior descending coronary artery and circumflex artery arise separately from the left coronary cusp; there is no left main coronary artery. The right coronary artery arises normally and is the dominant artery to the posterior myocardium. Cross sections of the vessels show no significant atherosclerosis. The myocardium is homogenous, red-brown, and firm. The valve leaflets are thin and mobile. The walls of the left and right ventricles are 1.2 and 0.3 cm thick, respectively. The endocardium is smooth and glistening. The aorta gives

ACLU Detainee DeathII ARMY MEDCOM 523

rise to three intact and patent arch vessels. The renal and mesenteric vessels are unremarkable.

LIVER & BILIARY SYSTEM:
The 1300 gm liver has an intact, smooth capsule and a sharp anterior border. The parenchyma is tan-brown and congested, with the usual lobular architecture. No mass lesions or other abnormalities are seen. The gallbladder contains 3 ml of green-black bile and no stones. The mucosal surface is green and velvety. The extrahepatic biliary tree is patent.

SPLEEN:
The 215 gm spleen has a smooth, intact, red-purple capsule. The parenchyma is maroon and congested, with indistinct Malpighian corpuscles.

PANCREAS:
The pancreas is soft and yellow-tan, with the usual lobular architecture. No mass lesions or other abnormalities are seen.

ADRENALS:
The right and left adrenal glands are symmetric, with bright yellow cortices and grey medullae. No masses or areas of hemorrhage are identified.

GENITOURINARY SYSTEM:
The right and left kidneys weigh 128 and 120 gms, respectively. The external surfaces are intact and smooth. The cut surfaces are red-tan and congested, with uniformly thick cortices and sharp corticomedullary junctions. The pelves are unremarkable and the ureters are normal in course and caliber. White bladder mucosa overlies an intact bladder wall. The bladder is empty. Twenty-five ml of urine is recovered from the urinary catheter/bag. The prostate is normal in size, with lobular, yellow-tan parenchyma. The seminal vesicles are unremarkable. The testes are free of mass lesions, contusions, or other abnormalities.

GASTROINTESTINAL TRACT:
The esophagus is intact and lined by smooth, grey-white mucosa. The stomach contains approximately 150 cc of brown, partially digested food particles. The gastric wall is intact. The duodenum, loops of small bowel and colon are unremarkable. The appendix is present.

MUSCULOSKELETAL SYSTEM
Muscle development is normal. No non-traumatic bone or joint abnormalities are noted.

ACLU Detainee DeathII ARMY MEDCOM 524

ADDITIONAL PROCEDURES

- Documentary photographs are taken by (b)(6)
- Evidence collected is seized by NCIS agent (b)(6)
- Specimens retained for toxicologic testing and/or DNA identification are: vitreous, central blood, peripheral blood, urine, spleen, kidney, lung, liver, brain, bile, gastric contents, adipose, and psoas muscle
- The dissected organs are forwarded with body

MICROSCOPIC EXAMINATION

1. Skin, dorsum of left foot: In the area corresponding to one of the grossly described tardieu spots, there is hemorrhage surrounding the superficial blood vessels without inflammation.

2. Kidney – Reviewed in consultation with The Department of Renal Pathology. There is autolysis of the proximal tubules with relative preservation of the glomeruli and distal collecting system. Adjacent to several glomeruli are collections of micro calcifications in the tubular lumens of uncertain etiology. There is also tubular simplification of the glomeruli with mild increase in the mesangial matrix. There is no significant inflammation or other abnormalities.

3. Heart: Section of left ventricle is unremarkable.

4. Spleen: Autolysis, otherwise unremarkable.

5. Lung: No pathologic description.

6. Liver: Focal centrilobular steatosis. No significant portal or parenchymal inflammation.

7. Brain, cerebral cortex: No pathologic description.

8. Thyroid: Autolysis

9. Adrenal: No pathologic description. Majority of tissue is unremarkable cortex with a single focus of medulla.

10. Testis: No pathologic description.

ACLU Detainee DeathII ARMY MEDCOM 525

TOXICOLOGY

1. Carbon Monoxide: The blood carboxyhemoglobin was less than 1% (normal 0-3%).

2. Ethanol: The blood and vitreous were negative for ethanol at a cutoff of 20 mg/dL.

3. Cyanide: There was no cyanide detected in the blood.

4. The urine was negative for screened medications and drugs of abuse.

ACLU Detainee DeathII ARMY MEDCOM 526

OPINION

This 21 year-old detainee died of hanging. The decedent was discovered hanging from a braided ligature tied through the steel mesh wall near the ceiling of his cell. According to reports, he was found with his hands and feet loosely bound by bed-sheet like material. A suicide note was found in his pocket. Hemorrhage in the left wrist may be the result of the standard operating procedure to shackle prisoners anytime they leave their cells. Hemorrhage into the neck muscles may be the result of the hanging or an artifact of cricoid pressure applied in the effort to intubate the decedent during the resuscitation attempt. Calcifications seen in kidneys are of uncertain etiology but did not contribute to the cause or manner of death. Toxicology studies were negative. After an extensive investigation there is no evidence to suggest that anyone else was involved in this death. Based on the information available, the manner of death is suicide.

(b)(6)

(b)(6)

(b)(6) Medical Examiner

ACLU Detainee DeathII ARMY MEDCOM 527

DEPARTMENT OF DEFENSE
ARMED FORCES INSTITUTE OF PATHOLOGY
WASHINGTON, DC 20306-6000

REPLY TO ATTENTION OF

AFIP (b)(6)

TO:

OFFICE OF THE ARMED FORCES MEDICAL EXAMINER
ARMED FORCES INSTITUTE OF PATHOLOGY
WASHINGTON, DC 20306-6000

PATIENT IDENTIFICATION
AFIP Accessions Number Sequence
(b)(6)
Name
ALZAHRANI, YASIR TALA

SSAN: **Autopsy:** (b)(6)
Toxicology Accession #: (b)(6)
Date Report Generated: June 19, 2006

CONSULTATION REPORT ON CONTRIBUTOR MATERIAL

AFIP DIAGNOSIS **REPORT OF TOXICOLOGICAL EXAMINATION**

Condition of Specimens: GOOD
Date of Incident (b)(6) 2006 **Date Received:** 6/12/2006

CARBON MONOXIDE: The carboxyhemoglobin saturation in the blood was less than 1% as determined by spectrophotometry with a limit of quantitation of 1%. Carboxyhemoglobin saturations of 0-3% are expected for non-smokers and 3-10% for smokers. Saturations above 10% are considered elevated and are confirmed by gas chromatography.

VOLATILES: The **BLOOD AND VITREOUS FLUID** were examined for the presence of ethanol at a cutoff of 20 mg/dL. No ethanol was detected.

CYANIDE: There was no cyanide detected in the blood. The limit of quantitation for cyanide is 0.25 mg/L. Normal blood cyanide concentrations are less than 0.15 mg/L. Lethal concentrations of cyanide are greater than 3 mg/L.

DRUGS: The **URINE** was screened for acetaminophen, amphetamine, antidepressants, antihistamines, barbiturates, benzodiazepines, cannabinoids, chloroquine, cocaine, dextromethorphan, lidocaine, narcotic analgesics, opiates, phencyclidine, phenothiazines, salicylates, sympathomimetic amines and verapamil by gas chromatography, color test or immunoassay. The following drugs were detected:

None were found.

(b)(6)
Office of the Armed Forces Medical Examiner

(b)(6)
Office of the Armed Forces Medical Examiner

ACLU Detainee DeathII ARMY MEDCOM 528

CERTIFICATE OF DEATH *(OVERSEAS)*

Acte de décès (D'Outre-Mer)

NAME OF DECEASED (Last, First, Middle) Nom du décédé (Nom et prénoms)	GRADE Grade	BRANCH OF SERVICE Arme	SOCIAL SECURITY NUMBER Numéro de l'Assurance Social
BTB ALZAHRANI, YASIR TALAL, ABDALI		Civilian	(b)(6)
ORGANIZATION Organisation	**NATION** (e.g. United States) Pays: Saudi Arabia	**DATE OF BIRTH** Date de naissance: (b)(6) 1984	**SEX** Sexe: [X] MALE [ ] FEMALE

RACE Race		MARITAL STATUS État Civil			RELIGION Culte		
	CAUCASOID Caucasique		SINGLE Célibataire		DIVORCED Divorcé		PROTESTANT Protestant
	NEGROID Negroide		MARRIED Marié		SEPARATED Séparé		CATHOLIC Catholique
X	OTHER (Specify) Autre (Spécifier) Saudi Arabia		WIDOWED Veuf				JEWISH Juif

	OTHER (Specify) Autre (Spécifier)
X	Muslim

NAME OF NEXT OF KIN Nom du plus proche parent	RELATIONSHIP TO DECEASED Parenté du décédé avec le sus
STREET ADDRESS Domicile à (Rue)	CITY OR TOWN OR STATE (Include ZIP Code) Ville (Code postal compris)

MEDICAL STATEMENT Déclaration médicale

	CAUSE OF DEATH (Enter only one cause per line) Cause du décès (N'indiquer qu'une cause par ligne)	INTERVAL BETWEEN ONSET AND DEATH Intervalle entre l'attaque et le décès
DISEASE OR CONDITON DIRECTLY LEADING TO DEATH [1] Maladie ou condition directement responsable de la mort.	Hanging	Minutes
ANTECEDENT CAUSES — MORBID CONDITION, IF ANY, LEADING TO PRIMARY CAUSE Condition morbide, s'il y a lieu, menant à la cause primaire		
Symptômes précurseurs de la mort. — UNDERLYING CAUSE, IF ANY, GIVING RISE TO PRIMARY CAUSE Condition morbide, s'il y a lieu, menant à la cause primaire		
OTHER SIGNIFICANT CONDITIONS [2] Autres conditions significatives [2]		

MODE OF DEATH Condition de décès		AUTOPSY PERFORMED Autopsie effectuée [X] YES Oui [ ] NO Non	CIRCUMSTANCES SURROUNDING DEATH DUE TO EXTERNAL CAUSES Circonstances de la mort suscitées par des causes extérieures
	NATURAL Mort naturelle	MAJOR FINDINGS OF AUTOPSY Conclusions principales de l'autopsie	
	ACCIDENT Mort accidentelle		
X	SUICIDE Suicide	NAME OF PATHOLOGIST Nom du pathologiste: (b)(6)	
	HOMICIDE Homicide	SIGNATURE: (b)(6) DATE Date: 11 June 2006	AVIATION ACCIDENT Accident à Avion: [ ] YES Oui [X] NO Non

DATE OF DEATH (day, month, year) Date de décès (le jour, le mois, l'année)	PLACE OF DEATH Lieu de décès
(b)(6) 2006	Guantanamo Bay Dentention Facility Cuba

I HAVE VIEWED THE REMAINS OF THE DECEASED AND DEATH OCCURRED AT THE TIME INDICATED AND FROM THE CAUSES AS STATED ABOVE
J'ai examiné les restes mortels du dé funtet je conclus que le décès est survenu à l'heure indiquée et à, la suite des causes énumérées ci-dessus.

NAME OF MEDICAL OFFICER Nom du médicin militaire ou du médicin sanitaire	TITLE OR DEGREE Titre ou diplôme	GRADE Grade	INSTALLATION OR ADDRESS Installation ou adresse	DATE Date	SIGN
(b)(6)	(b)(6) Medical Examiner	(b)(6)	Rockville, MD	01 AUG 06	(b)(6)

[1] State disease, injury or complication which caused death, but no
[2] State conditions contributing to the death, but not related to the disease or complication causing death.
[1] Préciser la nature de la maladie, de la blessure ou de la complication qui a contribué à la mort, mais non la manière de mourir, telle qu'un arrêt du coeur, etc
[2] Préciser la condition qui a contribué à la mort, mais n'ayant aucun rapport avec la maladie ou à la condition qui a provoqué la mort.

DD FORM 1 APR 77 2064 REPLACES DA FORM 3666, 1 JAN 72 AND DA FORM 3666-R(PAS), 26 SEP 75, WHICH ARE OBSOLETE.

ARMED FORCES INSTITUTE OF PATHOLOGY
Office of the Armed Forces Medical Examiner
1413 Research Blvd., Bldg. 102
Rockville, MD 20850
1-301-319-0000

FINAL AUTOPSY REPORT

Name: Ahmed, Ali Abdullah
Detainee Number: (b)(6)
Date of Birth: (b)(6) 1969
Date of Death (b)(6) 2006

Autopsy No.: (b)(6)
AFIP No.: (b)(6)
Rank: Detainee
Place of Death: Detention Facility, Guantanamo Bay, Cuba

Date of Autopsy: 11 June 2006 @ 0730
Date of Report: 01 August 2006

Place of Autopsy: Naval Hospital Guantanamo Bay, Cuba

Circumstances of Death: This 37 year-old detainee, by report, was found hanging in his secure cell at the detainee confinement facility at approximately 0020 on (b)(6) 2006. A suicide note was recovered from his shirt pocket. He was found with his feet and hands loosely bound and his face covered with a white cloth mask. Medical resuscitation was unsuccessful and he was declared dead at 0115. In the medical record it states he was unresponsive, pulse-less, apneic, with fixed and dilated pupils, and in rigor mortis when he arrived at the detention clinic at 0058. The medical report also states that the decedent had a piece of cotton-like material in his mouth and upper pharynx that was removed by medical personnel and seized by Naval Criminal Investigative Service.

Authorization for Autopsy: Office of the Armed Forces Medical Examiner, IAW 10 USC 1471

Identification: Detention records. Fingerprints and DNA sample obtained.

Personnel present for the autopsy:

1. Special Agent (b)(6) Naval Criminal Investigative Service
2. (b)(6) Autopsy Assistant
3. (b)(6) Medical Photographer
4. (b)(6) Medical Examiner Investigator
5. (b)(6) Medical Examiner (b)(6)

CAUSE OF DEATH: Hanging

MANNER OF DEATH: Suicide

ACLU Detainee DeathII ARMY MEDCOM 530

Final Autopsy Diagnoses

I. Hanging
   A. Dried abrasion collar anterior/lateral neck
   B. Scattered hemorrhage into the muscles of the neck
   C. Tardieu-like spots on the legs

II. Other Injuries
   A. Contusion, dorsum of left foot
   B. Healing abrasions (2), anterior left leg

III. Feet bound by cotton-like material

IV. Ligature encircling the abdomen

V. Natural disease processes/findings
   A. Scalp dermatitis
   B. Accessory spleen at the tip of the appendix
   C. Varicocele of the right testis
   D. Mild, focal chronic thyroiditis

VI. Artifact: Hyoid bone fracture, left side, during removal, no associated hemorrhage

VI. Toxicology – negative

ACLU Detainee DeathII ARMY MEDCOM 531

EXTERNAL EXAMINATION

The body, received wrapped in a white sheet, is that of a well-developed, well-nourished appearing, muscular, 68 inches in length, 165 pounds (per medical record as of 06 June 2006), white male whose appearance is consistent with the reported age of 37 years. Lividity is posterior and fixed, rigor is beginning to pass equally in all extremities, and the temperature is that of the refrigeration unit (34-39 degrees Fahrenheit).

The head and neck are wrapped with a blue plastic pad secured with tape. The scalp is covered with black hair in a normal distribution. The irides are brown. The sclerae and conjunctivae are congested but free of petechiae. The external auditory canals are unremarkable. The ears are unremarkable. The nares are patent and the lips are atraumatic. The nose and maxillae are palpably stable. The teeth appear in good condition with a fracture of the lower left anterior incisor. Facial hair consists of a full beard and mustache. On the back of the head there are multiple round to irregular skin lesions with red-brown margins and central clearing.

The neck is straight, and the trachea is midline and mobile. The chest is symmetric. The abdomen is flat. There is a rope-like ligature around the abdomen. It consists of white, cotton-like material, consistent with a T-shirt. The material has been torn into a strip and rolled into several layers. The material is secured with a knot that, when received, is over the left side of the anterior abdomen. Distal to the knot the material are two loose ends that appear to have been cut. The genitalia are those of a normal adult circumcised male. The testes are descended and free of masses. The pubic hair is shaved. The buttocks and anus are unremarkable.

The upper and lower extremities are symmetric and without clubbing or edema. The feet are bound by thin, white cotton-like material consistent with a T-shirt tied with knots. SA (b)(6) has taken these bindings into custody. The hands are bound with surgical towels and secured with string.

CLOTHING AND PERSONAL EFFECTS

The following clothing items and personal effects are present on the body at the time of autopsy:

- Khaki colored short sleeve pull over shirt
- White T-shirt
- Khaki colored pants
- Khaki colored shorts over the pants

MEDICAL INTERVENTION

Evidence of medical intervention includes:

- Nasal Airway

ACLU Detainee DeathII ARMY MEDCOM 532

- Intravenous catheter with attached tubing bag of intravenous solution, right antecubital fossa
- Defibrillator pad on the upper right chest. A second pad is on the shirt.
- Multiple electrocardiogram pads on the chest, abdomen, and left arm
- Puncture mark on the dorsum of the right hand
- Identification tags tied to the right wrist and right great toe

RADIOGRAPHS

A complete set of postmortem radiographs is obtained and are consistent the findings described below.

EVIDENCE OF INJURY

The ordering of the following injuries is for descriptive purposes only, and is not intended to imply order of infliction or relative severity. All wound pathways are given relative to standard anatomic position.

Evidence of Hanging

There is dried abrasion furrow on the neck. The furrow is regular with the width varying from 1/4 to ½ inch. Within the furrow the skin is imprinted with a very fine weave type pattern. The furrow is located 11 inches below the top of the head and below the thyroid cartilage at the anterior midline, 8 inches below the top of the head at the level of the left auditory meatus, and 8 inches below the top of the head at the level of the right auditory meatus. Behind the ears the furrow continues to course posteriorly and superiorly where it becomes less well defined and terminates 1 inch posterior to the right ear and 2 ½ inches posterior to the left ear.

Naval Criminal Investigative Service (NCIS) Agents present four pieces of material that were recovered from the floor of the cell of the decedent. Three are braided white cotton-like material. One of these has a knot at one end and the other end is cut. Encircling the knotted end is a knotted short loop of the same material. The second segment of this material has a loop at one end and the other end is cut. The third piece of material is a white cotton-like material with torn or cut defects. The evidence is minimally handled, photographed and returned to NCIS.

On both legs, tardieu-like spots encircle the legs. These spots commence 4 inches below the knees and extend distal for six inches terminating above the ankles. Similar spots are on the posterior thighs.

Internally, there are scattered hemorrhages throughout the anterior neck muscles:

1. Medial left sternocleidomastoid muscle, ¾ x 3/8 inches
2. Right thyrohyoid muscle ¾ x ½

ACLU Detainee DeathII ARMY MEDCOM 533

The remainder of the anterior and posterior neck is free of hemorrhage into the soft tissue.

Additional Injuries

There is a ½ inch round contusion on the dorsum of the left foot. There are two, less than 1/8 inch in diameter healing abrasions on the anterior left leg.

Artifact

There is a fracture of the left side of the hyoid bone, anterior to the lesser horn, that occurred during the removal of the neck organs. The surrounding soft tissue is free of hemorrhage.

INTERNAL EXAMINATION

HEAD:
The galeal and subgaleal soft tissues of the scalp are free of injury. The calvarium is intact, as is the dura mater beneath it. Clear cerebrospinal fluid surrounds the 1450 gm brain, which has unremarkable gyri and sulci. Coronal sections demonstrate sharp demarcation between white and grey matter, without hemorrhage or contusive injury. The ventricles are of normal size. The basal ganglia, brainstem, cerebellum, and arterial systems are free of injury or other abnormalities. There are no skull fractures. The atlanto-occipital joint is stable.

NECK:
The anterior strap muscles of the neck are homogenous and red-brown, without additional abnormalities. The thyroid cartilage is intact. The larynx is lined by intact white mucosa. The thyroid is symmetric and red-brown, without cystic or nodular change. The tongue is free of bite marks, hemorrhage, or other injuries.

BODY CAVITIES:
The ribs, sternum, and vertebral bodies are visibly and palpably intact. No excess fluid is in the right pleural, pericardial, or peritoneal cavities. The organs occupy their usual anatomic positions.

RESPIRATORY SYSTEM:
The right and left lungs weigh 500 and 450 gms, respectively. The external surfaces are smooth and deep red-purple. The pulmonary parenchyma is diffusely congested and edematous. No mass lesions or areas of consolidation are present.

CARDIOVASCULAR SYSTEM:
The 250 gm heart is contained in an intact pericardial sac. The epicardial surface is smooth, with minimal fat investment. The coronary arteries are present in a normal distribution, with a right-dominant pattern. Cross sections of the vessels show no

ACLU Detainee DeathII ARMY MEDCOM 534

significant atherosclerosis. The myocardium is homogenous, red-brown, and firm. The valve leaflets are thin and mobile. The walls of the left and right ventricles are 1.5 and 0.4 cm thick, respectively. The endocardium is smooth and glistening. The aorta gives rise to three intact and patent arch vessels. The renal and mesenteric vessels are unremarkable.

LIVER & BILIARY SYSTEM:
The 1450 gm liver has an intact, smooth capsule and a sharp anterior border. The parenchyma is tan-brown and congested, with the usual lobular architecture. No mass lesions or other abnormalities are seen. The gallbladder contains 3 ml of green-black bile and no stones. The mucosal surface is green and velvety. The extrahepatic biliary tree is patent.

SPLEEN:
The 130 gm spleen has a smooth, intact, red-purple capsule. The parenchyma is maroon and diffluent.

PANCREAS:
The pancreas is soft and yellow-tan, with the usual lobular architecture. No mass lesions or other abnormalities are seen.

ADRENALS:
The right and left adrenal glands are symmetric, with bright yellow cortices and grey medullae. No masses or areas of hemorrhage are identified.

GENITOURINARY SYSTEM:
The right and left kidneys weigh 148 and 145 gms, respectively. The external surfaces are intact and smooth. The cut surfaces are red-tan and congested, with uniformly thick cortices and sharp corticomedullary junctions. The pelves are unremarkable and the ureters are normal in course and caliber. White bladder mucosa overlies an intact bladder wall. The bladder contains 25 ml of bloody urine. The prostate is normal in size, with lobular, yellow-tan parenchyma. The seminal vesicles are unremarkable. The testes are free of mass lesions or contusions. There is a fluid filled sac around the right testis.

GASTROINTESTINAL TRACT:
The esophagus is intact and lined by smooth, grey-white mucosa. The stomach contains approximately 150 cc of brown, partially digested food particles. The gastric wall is intact. The duodenum, loops of small bowel, and colon are unremarkable. The appendix is present. There is a 0.5 cm in diameter accessory spleen on the tip of the appendix.

MUSCULOSKELETAL SYSTEM
Muscle development is normal. No additional bone or joint abnormalities are noted. There is no soft tissue hemorrhage or injury of the chest, back, abdomen or extremities.

ACLU Detainee DeathII ARMY MEDCOM 535

ADDITIONAL PROCEDURES

- Documentary photographs are taken by (b)(6)
- Evidence collected is seized by NCIS agent (b)(6)
- Specimens retained for toxicologic testing and/or DNA identification are: vitreous, central blood, peripheral blood, urine, spleen, kidney, lung, liver, brain, bile, gastric contents, adipose, and psoas muscle
- The dissected organs are forwarded with body

MICROSCOPIC EXAMINATION

1. Heart: Section of left ventricle is unremarkable.

2. Spleen: Autolysis, otherwise unremarkable.

3. Kidney: Autolysis of the proximal tubules with relative preservation of the glomeruli and distal collecting system. Multi-focal clacifications of the distal tubules.

4. Brain: Section of hippocampus is unremarkable.

5. Lungs: Congestion with intralveolar fluid and postmortem bacterial colonization.

6. Liver: No pathologic description.

7. Adrenal: No pathologic description.

8. Testis: No pathologic description.

9. Thyroid: Two foci of chronic inflammation, otherwise unremarkable.

10. Scalp: This specimen was reviewed in consultation with the Department of Dermatopathology. Microscopic sections and gross photographs were examined. The clinical images are suggestive of possible tinea capitis vs. other types of dermatitis such as seborrheic dermatitis and psoriasis. While tinea is favored, the only fungal elements identified are occasional pityrosporum.

TOXICOLOGY

1. Carbon Monoxide: The carboxyhemoglobin was less than 1% (normal 0-3%).

2. Ethanol: The blood and vitreous fluid were negative for ethanol at a cutoff of 20 mg/dL.

3. Cyanide: The blood was negative for cyanide at a cutoff of 0.25mg/L

4. The blood was negative for screened medications and drugs of abuse.

ACLU Detainee DeathII ARMY MEDCOM 536

OPINION

This 37 year-old detainee died of hanging. He was found hanging in his secure cell. Toxicology studies are negative. Based on the investigative information as of this date, there is no evidence of anyone else being involved with this death. Unusual tardieu-like spots on the legs and thighs may represent post-mortem artifact. The medical record from the time of resuscitation documents that a tooth broke during an intubation attempt. Also based on the medical documentation of the remains during the attempted resuscitation, the decedent had been dead for at least a couple of hours prior to the discovery of his body. Based on currently available information, the manner of death is suicide.

(b)(6)

(b)(6) **Medical Examiner** (b)(6)

ACLU Detainee DeathII ARMY MEDCOM 537

DEPARTMENT OF DEFENSE
ARMED FORCES INSTITUTE OF PATHOLOGY
WASHINGTON, DC 20306-6000

REPLY TO ATTENTION OF

AFIP-(b)(6)

TO:

OFFICE OF THE ARMED FORCES MEDICAL EXAMINER
ARMED FORCES INSTITUTE OF PATHOLOGY
WASHINGTON, DC 20306-6000

PATIENT IDENTIFICATION
AFIP Accessions Number Sequence
(b)(6)

Name
AHMED, ALI ABDULLAH

SSAN: **Autopsy:** (b)(6)
Toxicology Accession #: (b)(6)
Date Report Generated: June 16, 2006

CONSULTATION REPORT ON CONTRIBUTOR MATERIAL

AFIP DIAGNOSIS **REPORT OF TOXICOLOGICAL EXAMINATION**

Condition of Specimens: GOOD
Date of Incident (b)(6) 2006 **Date Received:** 6/12/2006

CARBON MONOXIDE: The carboxyhemoglobin saturation in the blood was less than 1% as determined by spectrophotometry with a limit of quantitation of 1%. Carboxyhemoglobin saturations of 0-3% are expected for non-smokers and 3-10% for smokers. Saturations above 10% are considered elevated and are confirmed by gas chromatography.

VOLATILES: The **PERIPHERAL BLOOD AND VITREOUS FLUID** were examined for the presence of ethanol at a cutoff of 20 mg/dL. No ethanol was detected.

CYANIDE: There was no cyanide detected in the blood. The limit of quantitation for cyanide is 0.25 mg/L. Normal blood cyanide concentrations are less than 0.15 mg/L. Lethal concentrations of cyanide are greater than 3 mg/L.

DRUGS: The **BLOOD** was screened for acetaminophen, amphetamine, antidepressants, antihistamines, barbiturates, benzodiazepines, cannabinoids, chloroquine, mefloquine, cocaine, dextromethorphan, lidocaine, narcotic analgesics, opiates, phencyclidine, phenothiazines, salicylates, sympathomimetic amines and verapamil by gas chromatography, color test or immunoassay. The following drugs were detected:

None were found.

(b)(6)
(b)(6) Medical Examiner

(b)(6)
(b)(6) Medical Examiner

ACLU Detainee DeathII ARMY MEDCOM 538

CERTIFICATE OF DEATH *(OVERSEAS)*

Acte dé décès (D'Outre-Mer)

NAME OF DECEASED *(Last, First, Middle)* Nom du décédé (Nom et prénoms)	GRADE Grade	BRANCH OF SERVICE Arme	SOCIAL SECURITY NUMBER Numéro de l'Assurance Social
BTB AHMED, ALI ABDULLAH,		Civilian	(b)(6)
ORGANIZATION Organisation	**NATION** *(e.g, United States)* Pays	**DATE OF BIRTH** Date de naissance	**SEX** Sexe
	Yemen	(b)(6) 1969	[X] MALE [ ] FEMALE

RACE Race		MARITAL STATUS État Civil			RELIGION Culte		
	CAUCASOID Caucasique		SINGLE Célibataire		DIVORCED Divorcé		PROTESTANT Protestant
	NEGROID Negriode		MARRIED Marié		SEPARATED Séparé		CATHOLIC Catholique
X	OTHER (Specify) Autre (Spécifier)		WIDOWED Veuf				JEWISH Juif

OTHER (Specify) Autre (Spécifier)	
X	Muslim

NAME OF NEXT OF KIN Nom du plus proche parent	RELATIONSHIP TO DECEASED Parenté du décédé avec le sus
STREET ADDRESS Domicilié à (Rue)	**CITY OR TOWN OR STATE** *(Include ZIP Code* Ville (Code postal compris)

MEDICAL STATEMENT Déclaration médicale

CAUSE OF DEATH (Enter only one cause per line) Cause du décès (N'indiquer qu'une cause par ligne)		INTERVAL BETWEEN ONSET AND DEATH Intervalle entre l'attaque et le décès
DISEASE OR CONDITON DIRECTLY LEADING TO DEATH [1] Maladie ou condition directement responsable de la mort [1]	Hanging	Minutes
ANTECEDENT CAUSES Symptômes précurseurs de la mort. MORBID CONDITION, IF ANY, LEADING TO PRIMARY CAUSE Condition morbide, s'il y a lieu, menant à la cause primaire		
UNDERLYING CAUSE, IF ANY, GIVING RISE TO PRIMARY CAUSE Condition morbide, s'il y a lieu, menant à la cause primaire		
OTHER SIGNIFICANT CONDITIONS [2] Autres conditions significatives [2]		

MODE OF DEATH Condition de décès		AUTOPSY PERFORMED Autopsie effectuée [X] YES Oui [ ] NO Non	CIRCUMSTANCES SURROUNDING DEATH DUE TO EXTERNAL CAUSES Circonstances de la mort suscitées par des causes extérieures
	NATURAL Mort naturelle	MAJOR FINDINGS OF AUTOPSY Conclusions principales de l'autopsie	
	ACCIDENT Mort accidentelle		
X	SUICIDE Suicide	NAME OF PATHOLOGIST Nom du pathologiste (b)(6)	
	HOMICIDE Homicide	SIGNATURE Signature	DATE Date 11 June 2006

AVIATION ACCIDENT Accident à Avion [ ] YES Oui [X] NO Non

DATE OF DEATH *(day, month, year)* Date de décès (le jour, le mois, l'année)	PLACE OF DEATH Lieu de décès
(b)(6) 2006	Guantanamo Bay Detention Facility Cuba

I HAVE VIEWED THE REMAINS OF THE DECEASED AND DEATH OCCURRED AT THE TIME INDICATED AND FROM THE CAUSES AS STATED ABOVE.
J'ai examiné les restes mortels du dé funtet je conclus que le décès est survenu à l'heure indiquée et à, la suite des causes énumérées ci-dessus.

NAME OF MEDICAL OFFICER Nom du médicin militaire ou du médicin sanitaire	TITLE OR DEGREE Titre ou diplômé
(b)(6)	(b)(6) Medical Examiner
GRADE Grade (b)(6)	**INSTALLATION OR ADDRESS** Installation ou adresse Rockville, MD
DATE Date	**SIGNATURE** Signature

[1] State disease, injury or complication which caused death, but not mode of dying such as heart failure, ect.
[2] State conditions contributing to the death, but not related to the disease or condition causing death.
[1] Préciser la nature de la maladie, de la blessure ou de la complication qui a contribué à la mort, mais non la manière de mourir, telle qu 'un arrêt du coeur, etc
[2] Préciser la condition qui a contribué à la mort, mais n'ayant aucun rapport avec la maladie ou à la condition qui a provoqué la mort.

DD FORM 1 APR 77 2064 REPLACES DA FORM 3565, 1 JAN 72 AND DA FORM 3565-R(PAS), 28 SEP 78, WHICH ARE OBSOLETE.

MEDCOM 0539

ACLU Detainee DeathII ARMY MEDCOM 539

ARMED FORCES INSTITUTE OF PATHOLOGY
Office of the Armed Forces Medical Examiner
1413 Research Blvd., Bldg. 102
Rockville, MD 20850
1-301-319-0000
FINAL AUTOPSY REPORT

Name: Alutaybi, Mani Shaman Turki
Detainee Number: (b)(6)
Date of Birth: (b)(6) 1976
Date of Death (b)(6) 2006

Autopsy No.: (b)(6)
AFIP No.: (b)(6)
Rank: Detainee
Place of Death: Detention Facility, Guantanamo Bay, Cuba

Date of Autopsy: 11 June 2006 @ 1100
Date of Report: 31 July 2006

Place of Autopsy: Naval Hospital Guantanamo Bay, Cuba

Circumstances of Death: This 30 year-old detainee was found hanging in his secured cell at the detainee confinement facility at approximately 0020 on (b)(6) 2006. A suicide note was found in his pocket. By report, he was found with his legs and hands loosely bound, and a mask like material covering his face. Medical resuscitation was unsuccessful and he was declared dead at 0115. In the medical record it states he was unresponsive, pulse-less, apneic, with fixed and dilated pupils, and in rigor mortis when he arrived at the detention clinic at 0053.

The medical history is remarkable for a "donkey-kick" to the chest several years before he was placed into detention. This injury resulted several broken ribs.

Authorization for Autopsy: Office of the Armed Forces Medical Examiner, IAW 10 USC 1471

Identification: Detention records. Fingerprints and DNA sample obtained.

Personnel present for the autopsy:

1. Special Agent (b)(6) Naval Criminal Investigative Service
2. (b)(6) Autopsy Assistant
3. (b)(6) Medical Photographer
4. (b)(6) Medical Examiner Investigator
5. (b)(6) Medical Examiner (b)(6)

CAUSE OF DEATH: Hanging

MANNER OF DEATH: Suicide

ACLU Detainee DeathII ARMY MEDCOM 540

Final Autopsy Diagnoses

I. Hanging
   A. Circumferential dried abrasion collar around the neck
   B. Soft tissue of the neck free of hemorrhage

II. Additional Injuries – Abrasion, left elbow

II. Natural disease processes/findings - None

III. Toxicology – Negative

ACLU Detainee DeathII ARMY MEDCOM 541

EXTERNAL EXAMINATION

The body, received wrapped in sheet, is that of a well-developed, well-nourished appearing, muscular, 67 ½ inches in length, 119 pounds (per medical record as of 06 June 2006), white male whose appearance is consistent with the reported age of 30 years. Lividity is posterior and fixed, rigor is no longer present, and the temperature is that the refrigeration unit (34-39 degrees Fahrenheit).

The head and neck are wrapped with a blue plastic pad secured with tape. The scalp is covered with black hair in a normal distribution. The irides are brown. The sclerae and conjunctivae are congested and free of petechiae. The external auditory canals are unremarkable. The ears are unremarkable. The nares are patent and the lips are atraumatic. The nose and maxillae are palpably stable. The teeth appear in good condition. Facial hair consists of a full beard and mustache.

The neck is straight, and the trachea is midline and mobile. The chest is symmetric and flat to concave. The abdomen is flat. The genitalia are those of a normal adult circumcised male. The testes are descended and free of masses. The pubic hair is shaved. The buttocks and anus are unremarkable.

The upper and lower extremities are symmetric and without clubbing or edema. On the dorsum of the right hand is a ½ x up to ¼ inch scar. There three healing eschars on the posterior-lateral side of the lower left leg. There are 1 ¼ x 1 inch scars on the anterior left and right legs. On the right knee is a ½ inch scar. The hands and feet are bound with surgical towels and secured with string.

CLOTHING AND PERSONAL EFFECTS

The following clothing items and personal effects are present on the body at the time of autopsy:

- Khaki colored short sleeve pull over shirt
- Khaki colored pants

MEDICAL INTERVENTION

Evidence of medical intervention includes:

- Intravenous catheter with attached tubing bag of intravenous solution, inserted into the left antecubital fossa
- Defibrillator pads on the upper right and lower left chest.
- Multiple electrocardiogram pads on the chest and abdomen
- Identification tags tied to the right wrist and right great toe

RADIOGRAPHS

A complete set of postmortem radiographs is obtained and are consistent the findings described below.

ACLU Detainee DeathII ARMY MEDCOM 542

EVIDENCE OF INJURY

The ordering of the following injuries is for descriptive purposes only, and is not intended to imply order of infliction or relative severity. All wound pathways are given relative to standard anatomic position.

Evidence of Hanging

There is a dried abrasion furrow around the neck. The furrow is regular with the width varying from 1/4 to ½ inch. Within the furrow the skin is imprinted with a very fine weave type pattern. The furrow is located 11 ½ inches below the top of the head and over the lower margin of the thyroid cartilage at the anterior midline; 9 inches below the top of the head at the level of the left auditory meatus; and 9 inches below the top of the head at the level of the right auditory meatus. The furrow angles upward on the back of the neck and forms an inverted "v" with the apex 6 ¼ inches from the top of the head. On the left side of the front of the neck the furrow becomes faint and round with a 1 inch diameter. On the front of the neck, 1/4 inch inferior to the abrasion furrow is a 2-inch horizontal, linear area of hypopigmentation. Along the superior border of the furrow, over the thyroid cartilage, there are two, 1/8 inch in diameter, superficial skin defects that represent skin cuts during the shaving of the neck for documentation of the furrow. Naval Criminal Investigative Service (NCIS) Agents present several pieces of material that were recovered from the floor of the cell of the decedent. Three are braided white cotton-like material. One of these has a loop at one end and the other is cut. The second has two cut ends. A third has a loop at one end and a knot at the other end. There are also two white cotton-like material portions consistent with a T-shirt. Both have been cut or torn and each has two knots. Additionally submitted are several strips of white cotton-like material consistent with a bedsheet that have knots and have been tied together. The evidence is minimally handled, photographed and returned to NCIS.

By layer dissection, there is no hemorrhage into the soft tissue of the anterior or posterior neck.

Additional Injuries

There is a ¼ inch abrasion on the left elbow.

INTERNAL EXAMINATION

HEAD:
The galeal and subgaleal soft tissues of the scalp are free of injury. The calvarium is intact, as is the dura mater beneath it. Clear cerebrospinal fluid surrounds the 1500 gm brain, which has unremarkable gyri and sulci. Coronal sections demonstrate sharp demarcation between white and grey matter, without hemorrhage or contusive injury. The ventricles are of normal size. The basal ganglia, brainstem, cerebellum, and arterial systems are free of injury or other abnormalities. There are no skull fractures. The atlanto-occipital joint is stable.

ACLU Detainee DeathII ARMY MEDCOM 543

NECK:
The anterior strap muscles of the neck are homogenous and red-brown, without abnormalities. The thyroid cartilage and hyoid are intact. There is dark colored area, ¾ x ½ inch, involving the right side of the thyroid cartilage that extends through the cartilage. The larynx is lined by intact white mucosa. The thyroid is symmetric and red-brown, without cystic or nodular change. The tongue is free of bite marks, hemorrhage, or other injuries.

BODY CAVITIES:
The ribs, sternum, and vertebral bodies are visibly and palpably intact. No excess fluid is in the right pleural, pericardial, or peritoneal cavities. The organs occupy their usual anatomic positions.

RESPIRATORY SYSTEM:
The right and left lungs each weigh 650. The external surfaces are smooth and deep red-purple. The pulmonary parenchyma is diffusely congested and edematous. No mass lesions or areas of consolidation are present.

CARDIOVASCULAR SYSTEM:
The 250 gm heart is contained in an intact pericardial sac. The epicardial surface is smooth, with minimal fat investment. The coronary arteries are present in a normal distribution, with a right-dominant pattern. Cross sections of the vessels show no significant atherosclerosis. The myocardium is homogenous, red-brown, and firm. The valve leaflets are thin and mobile. The walls of the left and right ventricles are 1.1 and 0.3 cm thick, respectively. The endocardium is smooth and glistening. The aorta gives rise to three intact and patent arch vessels. The renal and mesenteric vessels are unremarkable.

LIVER & BILIARY SYSTEM:
The 1150 gm liver has an intact, smooth capsule and a sharp anterior border. The parenchyma is tan-brown and congested, with the usual lobular architecture. No mass lesions or other abnormalities are seen. The gallbladder is empty. The mucosal surface is green and velvety. The extrahepatic biliary tree is patent.

SPLEEN:
The 145 gm spleen has a smooth, intact, red-purple capsule. The parenchyma is maroon and diffluent.

PANCREAS:
The pancreas is soft and yellow-tan, with the usual lobular architecture. No mass lesions or other abnormalities are seen.

ADRENALS:
The right and left adrenal glands are symmetric, with bright yellow cortices and grey medullae. No masses or areas of hemorrhage are identified.

ACLU Detainee DeathII ARMY MEDCOM 544

GENITOURINARY SYSTEM:
The right and left kidneys weigh 130 and 150 gms, respectively. The external surfaces are intact and smooth. The cut surfaces are red-tan and congested, with uniformly thick cortices and sharp corticomedullary junctions. The pelves are unremarkable and the ureters are normal in course and caliber. White bladder mucosa overlies an intact bladder wall. The bladder contains 50 ml of clear yellow urine. The prostate is normal in size, with lobular, yellow-tan parenchyma. The seminal vesicles are unremarkable. The testes are free of mass lesions, contusions, or other abnormalities.

GASTROINTESTINAL TRACT:
The esophagus is intact and lined by smooth, grey-white mucosa. The stomach contains approximately 500 cc of brown, partially digested food particles including white and green vegetable material. The gastric wall is intact. The duodenum, loops of small bowel, and colon are unremarkable. The appendix is present.

MUSCULOSKELETAL SYSTEM
Muscle development is normal. No bone or joint abnormalities are noted. There is no soft tissue hemorrhage or injury of the chest, back, abdomen or extremities.

ADDITIONAL PROCEDURES

- Documentary photographs are taken by (b)(6)
- Evidence collected is seized by NCIS agent (b)(6)
- Specimens retained for toxicologic testing and/or DNA identification are: vitreous, central blood, peripheral blood, urine, spleen, kidney, lung, liver, brain, gastric contents, adipose, and psoas muscle
- The dissected organs are forwarded with body

MICROSCOPIC EXAMINATION

1. Thyroid cartilage – Reviewed in consultation with the department of Head and Neck Pathology. A section of the thyroid cartilage from the area that grossly appeared discolored is histologically normal. There is no hemorrhage on the surface or in the cartilage. Head and Neck pathology opines that the gross impression does not relate to any abnormality.

2. Liver: No pathologic description

3. Heart: No pathologic description

4. Kidney: Autolysis of the proximal tubules with relative preservative of the glomeruli and distal collecting system. Otherwise, no pathologic description.

5. Lung: Airspace edema fluid, bacterial overgrowth and focal fibrosis

6. Testis: No pathologic description

ACLU Detainee DeathII ARMY MEDCOM 545

7. Spleen: No pathologic description

8. Adrenal: No pathologic description

9. Brain (Cortex): No pathologic description

10. Thyroid: No pathologic description

TOXICOLOGY

1. The blood carboxyhemoglobin level was less than 1% (normal 0-3%)
2. The blood and vitreous fluid were negative for ethanol at a cutoff of 20 mg/dL
3. The blood was negative for cyanide at a cutoff of 0.25 mg/L
4. The urine was negative screened medications and drugs of abuse

OPINION

This 30 year-old detainee died of hanging. By report, he was discovered in his secure cell suspended by the neck by braided segments of material. The description of the body during the attempted resuscitation indicates that the death occurred at least a couple of hours before he was discovered. The toxicology screen was negative. Based on the information available at this time, the manner of death is Suicide.

(b)(6)

(b)(6)

(b)(6) Medical Examiner

ACLU Detainee DeathII ARMY MEDCOM 546

DEPARTMENT OF DEFENSE
ARMED FORCES INSTITUTE OF PATHOLOGY
WASHINGTON, DC 20306-6000

REPLY TO ATTENTION OF

AFIP (b)(6)

TO:

OFFICE OF THE ARMED FORCES MEDICAL EXAMINER
ARMED FORCES INSTITUTE OF PATHOLOGY
WASHINGTON, DC 20306-6000

PATIENT IDENTIFICATION
AFIP Accessions Number Sequence
(b)(6)

Name
ALUTAYBI, MANI SHAMANI

SSAN: **Autopsy:** (b)(6)
Toxicology Accession #: (b)(6)
Date Report Generated: June 19, 2006

CONSULTATION REPORT ON CONTRIBUTOR MATERIAL

AFIP DIAGNOSIS **REPORT OF TOXICOLOGICAL EXAMINATION**

Condition of Specimens: GOOD
Date of Incident (b)(6) 2006 **Date Received:** 6/12/2006

CARBON MONOXIDE: The carboxyhemoglobin saturation in the blood was less than 1% as determined by spectrophotometry with a limit of quantitation of 1%. Carboxyhemoglobin saturations of 0-3% are expected for non-smokers and 3-10% for smokers. Saturations above 10% are considered elevated and are confirmed by gas chromatography.

VOLATILES: The **BLOOD AND VITREOUS FLUID** were examined for the presence of ethanol at a cutoff of 20 mg/dL. No ethanol was detected.

CYANIDE: There was no cyanide detected in the blood. The limit of quantitation for cyanide is 0.25 mg/L. Normal blood cyanide concentrations are less than 0.15 mg/L. Lethal concentrations of cyanide are greater than 3 mg/L.

DRUGS: The **URINE** was screened for acetaminophen, amphetamine, antidepressants, antihistamines, barbiturates, benzodiazepines, cannabinoids, chloroquine, cocaine, dextromethorphan, lidocaine, narcotic analgesics, opiates, phencyclidine, phenothiazines, salicylates, sympathomimetic amines and verapamil by gas chromatography, color test or immunoassay. The following drugs were detected:

None were found.

(b)(6)
(b)(6) Medical Examiner

(b)(6)
(b)(6) Medical Examiner

ACLU Detainee DeathII ARMY MEDCOM 547

CERTIFICATE OF DEATH *(OVERSEAS)*

Acte de décès (D'Outre-Mer)

NAME OF DECEASED *(Last, First, Middle)* Nom du décédé (Nom et prénoms)	GRADE Grade	BRANCH OF SERVICE Arme	SOCIAL SECURITY NUMBER Numéro de l'Assurance Social
BTB ALUTAYBI, MANI SHAMAN, TURKI		Civilian	(b)(6)

ORGANIZATION Organisation	NATION *(e.g. United States)* Pays	DATE OF BIRTH Date de naissance	SEX Sexe
	Saudi Arabia	(b)(6) 1976	[X] MALE [ ] FEMALE

RACE Race		MARITAL STATUS État Civil			RELIGION Culte		
	CAUCASOID Caucasique		SINGLE Célibataire		DIVORCED Divorcé		PROTESTANT Protestant
	NEGROID Negroide		MARRIED Marié		SEPARATED Séparé		CATHOLIC Catholique
X	OTHER (Specify) Autre (Spécifier) Saudi Arabia		WIDOWED Veuf				JEWISH Juif

OTHER (Specify) Autre (Spécifier)	
X	Muslim

NAME OF NEXT OF KIN Nom du plus proche parent	RELATIONSHIP TO DECEASED Parenté du décédé avec le sus

STREET ADDRESS Domicilé à (Rue)	CITY OR TOWN OR STATE *(Include ZIP Code)* Ville (Code postal compris)

MEDICAL STATEMENT Déclaration médicale

	CAUSE OF DEATH (Enter only one cause per line) Cause du décès (N'indiquer qu'une cause par ligne)	INTERVAL BETWEEN ONSET AND DEATH Intervalle entre l'attaque et le décès
DISEASE OR CONDITON DIRECTLY LEADING TO DEATH [1] Maladie ou condition directement responsable de la mort.	Hanging	Minutes
ANTECEDENT CAUSES — MORBID CONDITION, IF ANY, LEADING TO PRIMARY CAUSE Condition morbide, s'il y a lieu, menant à la cause primaire		
Symptômes précurseurs de la mort. — UNDERLYING CAUSE, IF ANY, GIVING RISE TO PRIMARY CAUSE Condition morbide, s'il y a lieu, menant à la cause primaire		
OTHER SIGNIFICANT CONDITIONS [2] Autres conditions significatives [2]		

MODE OF DEATH Condition de décès	AUTOPSY PERFORMED Autopsie effectuée	CIRCUMSTANCES SURROUNDING DEATH DUE TO EXTERNAL CAUSES Circonstances de la mort suscitées par des causes extérieures
[ ] NATURAL Mort naturelle	[X] YES Oui [ ] NO Non	
[ ] ACCIDENT Mort accidentelle	MAJOR FINDINGS OF AUTOPSY Conclusions principales de l'autopsie	
[X] SUICIDE Suicide	NAME OF PATHOLOGIST Nom du pathologiste (b)(6)	
[ ] HOMICIDE Homicide	SIGNATURE Signature	DATE Date 11 June 2006

AVIATION ACCIDENT Accident à Avion [ ] YES Oui [X] NO Non

DATE OF DEATH *(day, month, year)* Date de décès (le jour, le mois, l'année)	PLACE OF DEATH Lieu de décès
(b)(6) 2006	Guantanamo Bay Detention Facility Cuba

I HAVE VIEWED THE REMAINS OF THE DECEASED AND DEATH OCCURRED AT THE TIME INDICATED AND FROM THE CAUSES AS STATED ABOVE.
J'ai examiné les restes mortels du dé funtet je conclus que le décès est survenu à l'heure indiquée et à, la suite des causes énumérées ci-dessus.

NAME OF MEDICAL OFFICER Nom du médicin militaire ou du médicin sanitaire	TITLE OR DEGREE Titre ou diplômé
(b)(6)	(b)(6) Medical Examiner

GRADE Grade	INSTALLATION OR ADDRESS Installation ou adresse
(b)(6)	
DATE Date	SIGNATURE Signature

[1] State disease, injury or complication which caused death, but not mode of dying such as heart failure, ect.
[2] State conditions contributing to the death, but not related to the disease or condition causing death.
[1] Préciser la nature de la maladie, de la blessure ou de la complication qui a contribué à la mort, mais non la manière de mourir, telle qu 'un arrêt du coeur, etc.
[2] Préciser la condition qui a contribué à la mort, mais n'ayant aucun rapport avec la maladie ou à la condition qui a provoqué la mort.

DD FORM 1 APR 77 **2064** REPLACES DA FORM 3565, 1 JAN 72 AND DA FORM 3565-R(PAS), 26 SEP 75, WHICH ARE OBSOLETE.

ARMED FORCES INSTITUTE OF PATHOLOGY
Office of the Armed Forces Medical Examiner
1413 Research Blvd., Bldg. 102
Rockville, MD 20850
301-319-0000

AUTOPSY EXAMINATION REPORT

Name: BTB Awad, Hashim Ibrahim
SSAN: Not Applicable
Date of Birth: Unknown (BTB 52 years)
Date of Death: (b)(6) 2006
Date of Autopsy: 08 JUN 2006 @ 1300
Date of Report: 06 JUL 2006

Autopsy No.: (b)(6)
AFIP No.: (b)(6)
Rank: Civilian
Place of Death: Hamdani, Iraq
Place of Autopsy: Port Mortuary,
Dover Air Force Base, Dover, DE

Circumstances of Death: Investigation reports that United States Military Personnel detained this Iraqi civilian, bound him with flexible cuffs, and shot him multiple times at different ranges of fire.

Authorization for Autopsy: Office of the Armed Forces Medical Examiner, IAW 10 USC 1471

Identification: Presumptive identification is established by accompanying documentation and photographs.

CAUSE OF DEATH: **Multiple Gunshot Wounds**

MANNER OF DEATH: **Homicide**

ACLU Detainee DeathII ARMY MEDCOM 549

FINAL AUTOPSY DIAGNOSES:

I. Multiple gunshot wounds
- A. Gunshot wound of the forehead
  - 1. Combined entrance and exit on the right side of the forehead
    - a. Dimensions: 1/2" x 1/4"
    - b. Location: 2-1/2" below the top of the head and 2" right of the anterior midline
    - c. No soot or definite stippling identified around the wound
  - 2. Injuries: Keyhole-type defect of the frontal bone of the skull
  - 3. No bullet or fragments recovered from the wound
  - 4. Direction: left to right
- B, C. Gunshot wounds of the head
  - 1. Entrances (2) on the right side of the face
    - a. Dimensions:
      - i. Gunshot wound "B": 1/4" x 1/8"
      - ii. Gunshot wound "C": 3/8" x 1/4"
    - b. Locations:
      - i. Gunshot wound "B": 4-1/2" below the top of the head and 2-1/4" right of the anterior midline
      - ii. Gunshot wound "C": 5-1/4" below the top of the head and 2-3/4" right of the anterior midline
    - c. No soot or definite stippling identified around the entrance wounds
  - 2. Injuries to the maxillae, base of the skull, and calvarium (comminuted fractures)
  - 3. Exits on the right and posterior aspects of the head
    - a. Dimensions: 3" x 3" and 5" x 3"
    - b. Locations: 1/2" and 4" below the top of the head and 3-1/2" right of the anterior midline and 2-1/2" left of the posterior midline
  - 4. Recovered: irregular metal fragments from the head and a cone-shaped metal fragment from the soft tissues of the posterior scalp
  - 5. Direction: front to back
  - 6. Associated injuries: comminuted fracture of the mandible

ACLU Detainee DeathII ARMY MEDCOM 550

D. Gunshot wound of the face
   1. Entrance on the left side of the face
      a. Dimensions: 1/4" in diameter with an eccentric marginal abrasion measuring up to 1/8" on the twelve to three o'clock border
      b. Location: 5-1/4" below the top of the head and 4" left of the anterior midline
      c. No soot or stippling identified around the entrance wound
   2. Injuries to the underlying soft tissues
   3. Exit left side of the face, in front of the ear
      a. Dimensions: 1/2" x 1/4"
      b. Location: 5" below the top of the head and 5" left of the anterior midline
   4. No bullets or fragments recovered from the wound
   5. Direction: front to back, right to left, and upward

E. Gunshot wound of the neck
   1. Wounds on the left side of the neck
      a. Left side of the neck, below the lower jaw
         i. Dimensions: 3/8" x 1/4" with a concentric 1/16" marginal abrasion
         ii. Location: 8" below the top of the head and 4-3/4" left of the anterior midline
      b. Inferior left side of the neck
         i. Dimensions: 1/4" x 1/8" with an eccentric marginal abrasion measuring up to 1/8" on the one o'clock border
         ii. Location: 10" below the top of the head and 2-3/4" left of the anterior midline
      c. No soot or stippling identified around the entrance wound
   2. Injuries to the underlying soft tissues
   3. No bullets or fragments recovered from the wound
   4. Direction: indeterminate

ACLU Detainee DeathII ARMY MEDCOM 551

F, G. Gunshot wounds of the chest
- 1. Entrances (2) on the lateral right aspect of the chest
  - a. Dimensions:
    - i. Gunshot wound "F": 1/4" x 1/8"
    - ii. Gunshot wound "G": 1/8" in diameter
  - b. Location:
    - i. Gunshot wound "F": 16-1/4" below the top of the head and 8" right of the anterior midline
    - ii. Gunshot wound "G": 16-1/2" below the top of the head and 9-3/4" right of the anterior midline
  - c. No soot or stippling identified around the entrances wounds
- 2. Injuries to the lateral aspect of the right eighth rib and posterior aspect of the right ninth intercostals space, right lung, pericardium, aorta, left lung, the posterior aspects of left ribs two through five, and left scapula
- 3. Recovered: metal fragments from the right lung, pericardium, right clavicle and sternal notch, soft tissues of the chest, and left side of the back (no associated exit wound)
- 4. Direction: front to back, right to left, and upward

H. Gunshot wound of the abdomen and chest
- 1. Entrance on the right upper quadrant of the abdomen
  - a. Dimensions: 3/16" x 1/8"
  - b. Location: 24" below the top of the head and 2-1/4" right of the anterior midline
  - c. No soot or stippling identified around the entrance wound
- 2. Injuries to the liver, small intestine, diaphragm, and left lung
- 3. Recovered: metal fragments from the small intestine, soft tissue around the xiphoid process, and left lung (no associated exit wound)
- 4. Direction: front to back, right to left, and upward

I. Gunshot wound of the right buttock and pelvis
- 1. Entrance on the right buttock
  - a. Dimensions: 1/8" in diameter
  - b. Location: 34" above the bottom of the heel and 4-1/4" right of the posterior midline
  - c. No soot or stippling identified around the entrance wound
- 2. Injuries to the right pubic bone and acetabulum (comminuted fractures)
- 3. Recovered: Metal fragments from the soft tissues of the left pelvis, left buttock, and right sacro-iliac joint (no associated exit wound)
- 4. Direction: back to front, right to left

ACLU Detainee DeathII ARMY MEDCOM 552

J. Gunshot wound of the anterior right forearm
   1. Wounds on the central and medial anterior aspects of the right forearm
      a. Dimensions:
         i. Central wound: 1/4" x 1/8" with an eccentric marginal abrasion measuring up to 1/16" on the six o'clock border
         ii. Medial wound: 1/8" in diameter with an eccentric marginal abrasion measuring up to 1/8" on the five o'clock border
      b. Locations:
         i. Central wound: 8-3/4" below the top of the elbow and at the anterior midline of the right upper extremity
         ii. Medial wound: 6-3/4" below the top of the elbow and 1-1/2" medial of the anterior midline of the right upper extremity
      c. No soot or stippling identified around either wound
   2. Injuries to the underlying soft tissues
   3. No bullet or fragments recovered from the wound path
   4. Direction: indeterminate

K. Gunshot wound of the posterior right thigh
   1. Entrance on the posterior right thigh
      a. Dimensions: 1/8" in diameter with 1/16" concentric marginal abrasion
      b. Location: 28-3/4" above the bottom of the heel and 2" lateral of the posterior midline of the right lower extremity
      c. No soot or stippling identified around the entrance wound
   2. Injuries to the underlying soft tissues
   3. Exit on the medial right thigh
      a. Dimensions: 9" x 2"
      b. Location: 24" above the bottom of the heel and 4" medial of the posterior midline of the right lower extremity
   4. No bullet or fragments recovered from the wound path
   5. Direction: back to front, right to left

II. Other injuries
   A. Superficial penetrating injury of the forehead (1/8" in greatest dimension)
   B. Cluster of abrasions of the face (punctate to 1/16" in greatest dimension, covering an area of 1/4" x 1/8")
   C. Laceration (1/16") of the chest with marginal abrasion (1/8" on the three o'clock border)

ACLU Detainee DeathII ARMY MEDCOM 553

III. Natural disease and pre-existing conditions
   A. Healed fracture of the left femur with fixation wires (2) present
   B. Changes consistent with decubitus ulcer of the back
   C. No other significant natural disease identified within the limitations of the examination

IV. No evidence of medical intervention

V. Advanced decomposition

VI. Toxicology
   A. Volatiles (liver): no ethanol detected
   B. Screened drugs of abuse and medications (liver): none detected

ACLU Detainee DeathII ARMY MEDCOM 554

EXTERNAL EXAMINATION

The body is that of a 59 inches, 64 pounds, Caucasoid male. Lividity cannot be assessed due to decomposition changes. Rigor has passed. The temperature is that of the refrigeration unit. Decomposition changes consist of adipocere predominantly involving the right upper and lower extremities and the anterior torso and mummification predominantly involving the left upper and lower extremities and posterior torso.

The head is deformed from maceration; injuries of the head and face are described below. The scalp is covered with gray-brown hair in a normal distribution. The right eye is collapsed. The left is brown, the cornea is cloudy, the conjunctiva is pale white, and the sclera is white. The right ear is not identified. The left external auditory canal is clear; injury of the left ear is described below. Facial features of the nose and mouth are deformed by maceration. Most teeth are missing. The neck is straight and the trachea is midline.

The chest is symmetric and the abdomen is flat. Injuries of the chest and abdomen are described below. The penis is flat and macerated. The macerated scrotum has an open defect and the testes are not identified. The back is symmetric with a 4" x 3" defect packed with gauze on the lower back. Injuries of the back are described below. Two blind defects with macerated edges, 1" and 1-1/2" in greatest dimension, are on the lateral aspect of the right buttock. The anus is unremarkable.

The upper extremities are symmetric. There is a 1" x 1/2" blind defect with macerated edges of the posterior right shoulder. The lower extremities are disarticulated at the knee joints, bilaterally. Injuries of the extremities are described below.

CLOTHING AND PERSONAL EFFECTS

The following clothing items and personal effects are present on the body at the time of autopsy:

- Soiled white sheet wrapped around the body
- Black plastic bag wrapped around the head
- White sheet wrapped as a belt around the waist
- Tan plastic bag covering the skin defect of the back

MEDICAL INTERVENTION

There is no evidence of medical intervention, other than the gauze packing of the skin defect of the back.

ACLU Detainee DeathII ARMY MEDCOM 555

RADIOGRAPHS

A complete set of postmortem radiographs is obtained and demonstrates the following:

- Fragmentation of the calvarium, maxillae, and mandible with crushing of the skull including a right facial defect
- Metallic fragments in the occipital area
- Metal fragments in the right parasternal line and sternal notch
- Metal fragments anterior to the sacrum and a bullet tip inferior to the left sacroiliac joint
- Comminuted fractures of the right pubic bone and acetabulum with associated minute metal fragments
- Bilateral disarticulation of the knee joints
- Fracture of the left scapula
- Multiple metal fragments posterior to the left hemithorax
- Multiple comminuted fractures of the posterior left ribs
- Prior surgery on proximal left femur with two fixation wires at the level of the lesser trochanter with a lucent defect in the medullary bone from the greater trochanter distally through the diaphysis

EVIDENCE OF INJURY

The ordering of the following injuries is for descriptive purposes only, and is not intended to imply order of infliction or relative severity. All wound pathways are given relative to standard anatomic position.

I. Multiple gunshot wounds

A. Gunshot wound of the forehead
A combined gunshot entrance and exit wound is on the forehead located 2-1/2" below the top of the head and 2" right of the anterior midline. The ovoid wound measures 1/2" x 1/4". No soot or definite stippling are identified around the wound (see other injuries, below). The wound path involves the skin and subcutaneous tissue, and the skull, leaving a "keyhole" type defect with inward beveling on the left side of the defect and outward beveling on the right side of the defect. No bullet or fragments are recovered from the wound path. The wound path is directed left to right. Decomposition prevents further evaluation of injuries of the brain.

B, C. Gunshot wounds of the head
A gunshot entrance wound (gunshot wound "B") is on the right side of the face, below the eye, located 4-1/2" below the top of the head and 2-1/4" right of the anterior midline. The ovoid wound measures 1/4" x 1/8". No soot or definite stippling are identified around the entrance wound (see other injuries, below). A gunshot entrance wound (gunshot wound "C") is on the right cheek, located 5-1/4" below the top of the head and 2-3/4" right of the anterior midline. The ovoid wound measures 3/8" x 1/4". Soot or stippling are not present. The wound paths involve skin, subcutaneous tissue, the skull

ACLU Detainee DeathII ARMY MEDCOM 556

(comminuted fractures of both maxilla, base of the skull, and calvarium), and the brain. Two exit wounds are identified: one exit wound, measuring 3" x 3", is on the right side of the head, located 1/2" below the top of the head and 3-1/2" right of the anterior midline; another exit wound, measuring 5" x 3", is on the posterior aspect of the head, 4" below the top of the head and 2-1/2" left of the posterior midline. Small, irregular yellow metal fragments are recovered from inside the head and a small, cone-shaped, gray metal fragment is recovered from the soft tissues of the posterior scalp. The wound paths are directed front to back. Associated injuries include a comminuted fracture of the mandible. Decomposition prevents further evaluation of injuries of the brain.

D. Gunshot wound of the face
A gunshot entrance wound is on the left side of the face, located 5-1/4" below the top of the head and 4" left of the anterior midline. The circular wound measures 1/4" in diameter with an eccentric marginal abrasion measuring up to 1/8" on the twelve to three o'clock border. Soot or stippling are not present. The wound path involves skin and subcutaneous tissues only. A 1/2" x 1/4" lacerated exit wound is on the left side of the face in front of the ear, located 5" below the top of the head and 5" left of the anterior midline. No bullet or fragments are recovered from the wound path. The wound path is directed front to back, right to left, and upward.

E. Gunshot wound of the neck
Two gunshot wounds are on the left side of the neck, just below the lower jaw and on the inferior aspect of the neck. The wound below the jaw is located 8" below the top of the head and 4-3/4" left of the anterior midline. The ovoid wound measures 3/8" x 1/4" with a concentric 1/16" marginal abrasion. The wound on the inferior aspect of the neck is located 10" below the top of the head and 2-3/4" left of the anterior midline. The ovoid wound measures 1/4" x 1/8" with an eccentric marginal abrasion measuring up to 1/8" on the one o'clock border. Soot or stippling are not present around either wound. The wounds are connected by a path involving the skin and subcutaneous tissues. No bullet or fragments are recovered from the wound path. The direction of the wound path is indeterminate.

F, G. Gunshot wounds of the chest
A gunshot entrance wound (Gunshot wound "F") is on the lateral right side of the chest, located 16-1/4" below the top of the head and 8" right of the anterior midline. The ovoid wound measure 1/4" x 1/8". Soot or stippling are not present. A gunshot entrance wound (Gunshot wound "G") is on the lateral right side of the chest, located 16-1/2" below the top of the head and 9-3/4" right of the anterior midline. The circular wound measures 1/8" in diameter. Soot or stippling are not present. The wound paths involve the lateral aspect of the eighth right rib (fractured), the right ninth intercostals space, the lower lobe of the right lung, the pericardium, the aorta, the upper lobe of the left lung, the posterior aspects of left ribs two through five (fractured), and the left scapula (fractured). Irregular yellow metal fragments are recovered from the right lung. Irregular gray metal fragments are recovered from the pericardium. A small, cone-shaped gray metal fragment is recovered from the right clavicle and an irregular gray metal fragment is recovered from the sternal notch. A small, cone-shaped yellow metal fragment is recovered from the soft

ACLU Detainee DeathII ARMY MEDCOM 557

tissues of the chest. Multiple irregular yellow and gray metal fragments and a small, cone-shaped yellow metal fragment are recovered from the left side of the back. The wound paths are directed front to back, right to left, and upward.

H. Gunshot wound of the abdomen and chest
A gunshot entrance wound is on the abdomen, located 24" below the top of the head and 2-1/4" right of the anterior midline. The ovoid wound measures 3/16" x 1/8". Soot or stippling are not present. The wound path involves skin, subcutaneous tissue, muscle, the right lobe of the liver (pulpifaction), small intestine, the diaphragm, and the lower lobe of the left lung. An irregular yellow metal fragment is recovered from the soft tissues around the xiphoid process, an irregular gray metal fragment is recovered from the small intestine, and a small, cone-shaped, yellow metal fragment is recovered from the lower lobe of the left lung. The wound path is directed front to back, right to left, and upward.

I. Gunshot wound of the right buttock and pelvis
A gunshot entrance wound is on the right buttock, located 34" above the bottom of the heel and 4-1/4" right of the posterior midline. The circular wound measures 1/8" in diameter. Soot or stippling are not present. The wound path involves skin, subcutaneous tissue, muscle, and the right pubic bone and acetabulum (comminuted fractures). A small, cone-shaped gray metal fragment and a small, cone-shaped yellow metal fragment are recovered from the left buttock; an irregular gray metal fragment is recovered from the soft tissues of the left pelvis; and an irregular yellow metal fragment is recovered from the right sacroiliac joint. The wound path is directed back to front and right to left.

J. Gunshot wound of the anterior right forearm
Gunshot wounds are on the central and medial anterior aspects of the right forearm. The central wound is located 8-3/4" below the top of the elbow and at the anterior midline of the right upper extremity. The medial wound is located 6-3/4" below the top of the elbow and 1-1/2" medial to the anterior midline of the right upper extremity. The central wound measures 1/4" x 1/8" with an eccentric marginal abrasion measuring up to 1/16" on the six o'clock border. The medial wound measures 1/8" in diameter with an eccentric marginal abrasion measuring up to 1/8" on the five o'clock border. Soot or stippling are not present around either wound. The wounds are connected by a path involving the skin, subcutaneous tissues, and muscle. No bullet or fragments are recovered from the wound path. The direction of the wound path is indeterminate.

K. Gunshot wound of the posterior right thigh
A gunshot entrance wound is on the posterior right thigh, located 28-3/4" above the bottom of the heel and 2" lateral of the posterior midline of the right lower extremity. The circular wound measures 1/8" in diameter with a concentric 1/16" marginal abrasion. The wound path involves the skin, subcutaneous tissue, and muscle. A 9" x 2" exit wound is on the medial right thigh, located 24" above the bottom of the heel and 4' medial of the posterior midline of the right lower extremity. No bullet or fragments are recovered from the wound path. The wound path is directed back to front and right to left.

ACLU Detainee DeathII ARMY MEDCOM 558

II. Other injuries

A 1/8" blackened, abraded superficial penetrating injury is on the forehead 1/8" medial to gunshot wound "A". A cluster of punctate to 1/16" blackened abrasions are on the face inferior to gunshot wound "B", covering area of 1/4" x 1/8". On the chest, 18" below the top of the head and 1/4" right of the anterior midline is a 1/16" laceration with a 1/8" abrasion on the three o'clock border. This laceration has no connection to any of the gunshot wound paths.

INTERNAL EXAMINATION

HEAD:
Injuries of the head and brain have been discussed (see Evidence of Injury, above). The brain weighs 80 grams. Decomposition prevents further evaluation of the brain. The atlanto-occipital joint is stable.

NECK:
Injuries of the neck have been described (see Evidence of Injury, above). The anterior strap muscles of the neck are gray-brown and soft, without hemorrhage. The thyroid cartilage and hyoid are intact. The internal surface of the larynx is unremarkable. The thyroid is soft and shriveled. The tongue is free of bite marks, hemorrhage, or other injuries.

BODY CAVITIES:
Injuries of the ribs and diaphragm have been described. No excess fluid is in the pleural, pericardial, or peritoneal cavities. The organs occupy their usual anatomic positions.

RESPIRATORY SYSTEM:
Injuries of the lungs have been described (see Evidence of Injury, above). The right and left lungs weigh 140 and 100 gm, respectively. The external surfaces are smooth and gray-black. The pulmonary parenchyma is soft and gray black. No non-traumatic lesions are identified.

CARDIOVASCULAR SYSTEM:
Injuries of the pericardium and aorta have been described (see Evidence of Injury, above). The heart weighs 150 gm. The epicardial surface is dull gray. The coronary arteries are present in a normal distribution, however the circumflex artery is not definitively identified. Sectioning reveals patent vessels. The myocardium is tan-brown and soft. The valves are free of lesions. The endocardium is dull and gray. The uninjured aorta gives rise to three intact and patent arch vessels. The renal and mesenteric vessels are unremarkable.

ACLU Detainee DeathII ARMY MEDCOM 559

LIVER & BILIARY SYSTEM:
Injury of the liver has been described (see Evidence of Injury, above). The liver weighs 270 gm. The uninjured liver parenchyma is soft and dark brown. No non-traumatic lesions are identified. The gallbladder is empty, but otherwise unremarkable.

SPLEEN:
The 40 gm spleen has a smooth, intact, purple-gray capsule. The liquefied parenchyma is gray-black.

PANCREAS:
The pancreas is soft and yellow-gray. No mass lesions or other abnormalities are seen.

ADRENALS:
The right and left adrenal glands are symmetric, with dark yellow cortices and gray-brown medullae. No masses or areas of hemorrhage are identified.

GENITOURINARY SYSTEM:
The right and left kidneys both weigh 10 gm. The external surfaces are gray-black and soft. The cut surfaces are gray-black, with poorly defined corticomedullary junctions. The pelves are unremarkable and the ureters are normal in course and caliber. Gray bladder mucosa overlies an intact bladder wall. The bladder contains no urine. The prostate is gray and soft. The seminal vesicles are not identified. The testes are not identified.

GASTROINTESTINAL TRACT:
Injury of the small intestine has been described (see Evidence of Injury, above). The esophagus is not identified. The stomach is thin, gray-black and empty. The colon is gray-black, but otherwise unremarkable. The appendix is not identified.

MUSCULOSKELETAL:
A callous and two fixation wires surround a healed fracture of the left femur. Dissection of the skin and soft tissues of the ankles and wrists reveals no hemorrhage or other injury.

ACLU Detainee DeathII ARMY MEDCOM 560

ADDITIONAL PROCEDURES AND COMMENTS

1. Documentary photographs are taken by AFMES staff.
2. Personal effects are released to the appropriate mortuary operations representatives.
3. Specimens retained for toxicologic testing and/or DNA identification are: spleen, lung, liver, and kidney.
4. The dissected organs are forwarded with body.
5. Trace evidence and foreign material are collected and submitted to Catherine Winslow, Special Agent, Naval Criminal Investigative Service.
6. (b)(6) Medical Examiner, (b)(6) (b)(6), served as an independent observer and assisted in the performance of this autopsy.

MICROSCOPIC EXAMINATION

Skin sections of areas around the gunshot wounds of the forehead and right cheek demonstrate denuded epidermis, collagen breakdown, and multiple foci of microbial overgrowth. There is no evidence of carbonaceous deposition indicative of close range firing.

ACLU Detainee DeathII ARMY MEDCOM 561

OPINION

This Iraqi Civilian (b)(6) died of multiple gunshot wounds. A gunshot wound of the forehead (gunshot wound "A") produced a "keyhole" type defect of the skull directed from left to right with no bullet or fragments recovered from the wound; however a keyhole defect suggests that at least a fragment of the bullet entered the skull, but this fragment may have exited or been associated with the wounds of the head (gunshot wounds "B" and "C"). Gunshot wounds of the head (gunshot wounds "B" and "C") entered the right side of the face to injure the skull and brain with an associated fracture of the mandible (lower jaw bone); metal fragments were recovered from the head and scalp; the wound paths were directed front to back. A gunshot wound of the face (gunshot wound "D") entered the left side of the face and exited just anterior to the ear, injuring the underlying soft tissues; no bullets or fragments were recovered from the wound path, which was directed front to back, right to left, and upward. A gunshot wound of the neck (gunshot wound "E") had wounds just below the jaw and on the inferior aspect of the neck, injuring the underlying soft tissues; no bullets or fragments were recovered from the wound path, the direction of which could not be determined. Gunshot wounds of the chest (gunshot wounds "F" and "G") entered the lateral right side of the chest to injure ribs, both lungs, the pericardium (sac surrounding the heart), the aorta (main artery of the body), and the left scapula (shoulder blade); metal fragments were recovered from the right lung, pericardium, right clavicle (collar bone) and sternal notch (space above the breast bone), the soft tissues of the chest, and the left side of the back; the direction of the wound paths were directed front to back, right to left, and upward. A gunshot wound of the abdomen and chest (gunshot wound "H") entered the upper abdomen to injure the liver, intestine, diaphragm, and left lung; metal fragments were recovered from the intestine, the soft tissues around the xiphoid process (lower aspect of the breastbone), and the left lung; the wound path was directed front to back, right to left, and upward. A gunshot wound of the right buttock and pelvis (gunshot wound "I") entered the right buttock to injure the right side of the pelvic girdle (pubic bone and acetabulum); metal fragments were recovered from the soft tissues of the left side of the pelvis, left buttock, and right sacro-iliac joint; the wound path was directed back to front and right to left. A gunshot wound of the anterior right forearm (gunshot wound "J") had wounds on the central and medial aspects of the anterior forearm with involvement of the underlying soft tissues; no bullets or fragments were recovered from the wound path, the direction of which could not be determined. A gunshot wound of the posterior right thigh (gunshot wound "K") entered the posterior aspect of the right thigh, injured the underlying soft tissues, and exited the medial right thigh; no bullets or fragments were recovered from the wound path, which was directed back to front and right to left. None of the gunshot wounds had definitive evidence of contact, close, or intermediate range fire, however lesions of the face were suspicious for stippling, evidence of close to intermediate range of fire or an intermediate target. A superficial penetrating injury near the forehead gunshot wound (gunshot wound "A") and a cluster of abrasions near one of the gunshot wounds of the right side of the face (gunshot wound "B") have no definitive soot or stippling (evidence of contact, close, or intermediate range gunfire) either by gross examination or on histology. These injuries are likely the result of intermediary targets. Finally, a laceration of the chest was not associated with any of

ACLU Detainee DeathII ARMY MEDCOM 562

the gunshot wounds of the torso. Dissection into the skin and soft tissues of the wrists and ankles revealed no hemorrhage or other injury, which might be expected if the individual was bound. However, considering the reported use of flexible cuffs and the degree of decomposition, the absence of such a finding may not be specific enough to exclude that the individual was bound. A defect in the back packed with gauze is consistent with a decubitus ulcer and the left femur had a healed fracture with fixation wires. These two findings suggest the individual had some degree of difficulty with ambulation. Toxicology tests for ethanol and screened drugs of abuse and medications are negative. The manner of death is homicide.

(b)(6)

(b)(6) **Medical Examiner**

ACLU Detainee DeathII ARMY MEDCOM 563

DEPARTMENT OF DEFENSE
ARMED FORCES INSTITUTE OF PATHOLOGY
WASHINGTON, DC 20306-6000

REPLY TO ATTENTION OF

AFIP (b)(6)

PATIENT IDENTIFICATION
AFIP Accessions Number Sequence
(b)(6)

TO:

OFFICE OF THE ARMED FORCES MEDICAL EXAMINER
ARMED FORCES INSTITUTE OF PATHOLOGY
WASHINGTON, DC 20306-6000

Name
AWAD, HASHIM

SSAN: **Autopsy** (b)(6)
Toxicology Accession #: (b)(6)
Date Report Generated: June 19, 2006

CONSULTATION REPORT ON CONTRIBUTOR MATERIAL

AFIP DIAGNOSIS **REPORT OF TOXICOLOGICAL EXAMINATION**

Condition of Specimens: MARKED PUTREFACTION
Date of Incident: **Date Received:** 6/13/2006

VOLATILES: The **LIVER** was examined for the presence of ethanol at a cutoff of 20 mg/dL. No ethanol was detected.

DRUGS: The **LIVER** was screened for amphetamine, antidepressants, antihistamines, barbiturates, benzodiazepines, cannabinoids, chloroquine, mefloquine, cocaine, dextromethorphan, lidocaine, narcotic analgesics, opiates, phencyclidine, phenothiazines, sympathomimetic amines and verapamil by gas chromatography, color test or immunoassay. The following drugs were detected:

None were found.

(b)(6)
(b)(6) **Medical Examiner**

(b)(6)
(b)(6) **Medical Examiner**

ACLU Detainee DeathII ARMY MEDCOM 564

CERTIFICATE OF DEATH *(OVERSEAS)*

Acte dé décès (D'Outre-Mer)

NAME OF DECEASED *(Last, First, Middle)* Nom du décédé (Nom et prénoms)	GRADE Grade	BRANCH OF SERVICE Arme	SOCIAL SECURITY NUMBER Numéro de l'Assurance Social
BTB Awad, Hashim,		Civilian	

ORGANIZATION Organisation	NATION *(e.g, United States)* Pays	DATE OF BIRTH Date de naissance	SEX Sexe
	Iraq		☐ MALE ☐ FEMALE

RACE Race		MARITAL STATUS État Civil		RELIGION Culte	
X	CAUCASOID Caucasique		SINGLE Célibataire		DIVORCED Divorcé
	NEGROID Negroide		MARRIED Marié		SEPARATED Séparé
	OTHER (Specify) Autre (Spécifier)		WIDOWED Veuf		PROTESTANT Protestant
					CATHOLIC Catholique
					JEWISH Juif
				X	OTHER (Specify) Autre (Spécifier)

NAME OF NEXT OF KIN Nom du plus proche parent	RELATIONSHIP TO DECEASED Parenté du décéde avec le sus
STREET ADDRESS Domicilé à (Rue)	CITY OR TOWN OR STATE *(Include ZIP Code* Ville (Code postal compris)

MEDICAL STATEMENT Déclaration médicale

	CAUSE OF DEATH (Enter only one cause per line) Cause du décès (N'indiquer qu'une cause par ligne)	INTERVAL BETWEEN ONSET AND DEATH Intervalle entre l'attaque et le décés
DISEASE OR CONDITON DIRECTLY LEADING TO DEATH [1] Maladie ou condition directement responsable de la mort. [1]	Multiple gunshot wounds	
ANTECEDENT CAUSES Symptômes précurseurs de la mort. — MORBID CONDITION, IF ANY, LEADING TO PRIMARY CAUSE Condition morbide, s'il y a lieu, menant à la cause primaire		
ANTECEDENT CAUSES Symptômes précurseurs de la mort. — UNDERLYING CAUSE, IF ANY, GIVING RISE TO PRIMARY CAUSE Condition morbide, s'il y a lieu, menant à la cause primaire		
OTHER SIGNIFICANT CONDITIONS [2] Autres conditions significatives [2]		

MODE OF DEATH Condition de décès		AUTOPSY PERFORMED Autopsie effectuée ☒ YES Oui ☐ NO Non	CIRCUMSTANCES SURROUNDING DEATH DUE TO EXTERNAL CAUSES Circonstances de la mort suscitées par des causes extérieures
	NATURAL Mort naturelle	MAJOR FINDINGS OF AUTOPSY Conclusions principales de l'autopsie	
	ACCIDENT Mort accidentelle		
	SUICIDE Suicide	NAME OF PATHOLOGIST Nom du pathologiste (b)(6)	
X	HOMICIDE Homicide	SIGNATURE Signature	DATE Date 8 June 2006

AVIATION ACCIDENT Accident à Avion ☐ YES Oui ☒ NO Non

DATE OF DEATH *(day, month, year)* Date de décés (le jour, le mois, l'année)	PLACE OF DEATH Lieu de décés
(b)(6) 2006	

I HAVE VIEWED THE REMAINS OF THE DECEASED AND DEATH OCCURRED AT THE TIME INDICATED AND FROM THE CAUSES AS STATED ABOVE.
J'ai examiné les restes mortels du dé funtet je conclus que le décès est survenu à l'heure indiquée et à, la suite des causes énumérées ci-dessus.

NAME OF MEDICAL OFFICER Nom du médecin militaire ou du médecin sanitaire	TITLE OR DEGREE Titre ou diplômé
(b)(6)	Medical Examiner

GRADE Grade	INSTALLATION OR ADDRESS Installation ou adresse
(b)(6)	Dover AFB, Dover DE
DATE Date	SIGNATURE Signature

[1] State disease, injury or complication which caused death, but not mode of dying such as heart failure, ect.
[2] State conditions contributing to the death, but not related to the disease or condition causing death.
[1] Préciser la nature de la maladie, de la blessure ou de la complication qui a contribué à la mort, mais non la manière de mourir, telle qu 'un arrêt du coeur, etc
[2] Préciser la condition qui a contribué à la mort, mais n'ayant aucun rapport avec la maladie ou à la condition qui a provoqué la mort.

DD FORM 1 APR 77 2064 REPLACES DA FORM 3565, 1 JAN 72 AND DA FORM 3565-R(PAS), 26 SEP 75, WHICH ARE OBSOLETE.

ARMED FORCES INSTITUTE OF PATHOLOGY
Office of the Armed Forces Medical Examiner
1413 Research Blvd., Bldg. 102
Rockville, MD 20850
301-319-0000

FINAL AUTOPSY REPORT

Name: BTB ISMAIL, Ibrahim
SSAN (b)(6)
Date of Birth: (b)(6) 1967 (38 years)
Date of Death (b)(6) 2006
Date of Autopsy: 10 JUN 2006, 1100 hours
Date of Report: 16 AUG 2006

Autopsy No.: (b)(6)
AFIP No.: (b)(6)
Rank: Civilian, Iraqi Detainee
Place of Death: Abu Ghraib, Iraq
Place of Autopsy: BIAB Mortuary
Baghdad, Iraq

Circumstances of Death: (b)(6) is an Iraqi detainee, who was shot in the abdomen approximately three weeks prior to his demise. The circumstances surrounding the shooting are unknown at this time. The first entry in his available medical records, 25 May 06, did not address his initial admission or treatment prior to admission to Abu Ghraib Hospital. He developed Sepsis syndrome (Acinetobacter, E-coli, Enterobacter and Candida albicans), Acute Respiratory Distress Syndrome (ARDS) and multi-organ system failure, and died on (b)(6) 06.

Authorization for Autopsy: Office of the Armed Forces Medical Examiner, IAW 10 USC 1471

Identification: Identified by transport documents.

CAUSE OF DEATH: Complications of Gunshot Wound (s) to the abdomen

MANNER OF DEATH: Homicide

ACLU Detainee DeathII ARMY MEDCOM 566

FINAL AUTOPSY DIAGNOSES:

I. Gunshot Wound (s) to the Torso:

a. No medical records or investigation reports are available at this time.

II. Evidence of Medical Intervention: Medical records starting 25 May 06 until expired (b)(6) 06, with evidence of surgical intervention and prolonged hospital care.

a. Tracheotomy tube
b. Multiple sites of chest tubes
c. Colostomy
d. IV lines
e. Midline abdominal surgical defect.

III. Identifying Marks: (b)(6)
(b)(6)

IV. Natural Diseases: Multi-organ failure and ARDS, consistent with complications of a GSW of the abdomen. No other natural diseases identified within the limitations of the autopsy examination.

V. Evidence: None collected during autopsy.

VI. Toxicology: No testing requested. Patient was hospitalized for approximately three weeks prior to his demise.

VII. Autopsy: Performed in Iraq By (b)(6)
(b)(6) Examination started at 1000 hours and concluded at 1200 hours, on 10 June 2006.

EXTERNAL EXAMINATION

The unclad body is that of a well-developed, well-nourished male whose appearance is consistent with an estimated age of 38 years. Lividity is present and fixed on the posterior surface of the body except in areas exposed to pressure. Rigor and temperature of the body are deemed of no forensic significance.

The head and neck reveal no evidence of trauma. The scalp and mustache hair is black. The irides are brownish, and the pupils are round and equal in diameter. The external auditory canals are unremarkable. The nares are patent. The lips and mouth are unremarkable on external examination. The teeth are in fair condition. The neck is unremarkable except for a tracheotomy tube inserted in the midline, and properly positioned.
The chest reveals multiple bilateral incisions (2 on each side), consistent with the site of chest tubes. The abdomen is slightly protuberant (mild obesity), with a large anterior

ACLU Detainee DeathII ARMY MEDCOM 567

defect, extending from the xiphoid process to the pubic area, consistent with a non-healed exploratory laparotomy surgical incision. The abdominal defect reveals a severely adhesed internal abdominal organs. A colostomy opening and colostomy bag are noted of the right lower abdominal quadrant. A 4 x 3 ½" defect, of unknown etiology, is noted of the left mid abdomen, exposing underlying internal organs/intestines. The external genitalia are those of a normal circumcised adult male. The testes are descended and free of masses. Pubic hair is present in a normal distribution. The buttocks and anus are unremarkable. The back reveals skin slippage and two large decubitus ulcers (bed sores), but no evidence of trauma.

The upper and lower extremities are symmetric and reveal moderate edema. No evidence of trauma is noted.

Two large scars are noted of the anterior surface of both thighs, extending from the inguinal area down to the knees. No tattoos, other major scars or identifying marks are noted.

CLOTHING AND PERSONAL EFFECTS

None received.

MEDICAL INTERVENTION

The deceased spent almost three weeks under medical care. The body reveals evidence of extensive medical treatment. There are: Nasogastric tube, tracheotomy tube, multiple sites of chest tubes, a non-healed abdominal exploratory laparotomy incision, colostomy bag, and a urinary catheter.

RADIOGRAPHS

Full-body radiographs are obtained for documentation. No skeletal fractures or evidence of projectiles/foreign bodies are noted.

EVIDENCE OF INJURIES

The deceased had a history of gunshot wound, not otherwise specified. Medical history of his initial admission and the early surgical procedures are requested, but not received as of the date of this report.

ACLU Detainee DeathII ARMY MEDCOM 568

INTERNAL EXAMINATION

HEAD:
The scalp and subgaleal soft tissues reveal no evidence of trauma. The skull is opened revealing intact dura mater. No intracranial hemorrhage or trauma is noted. Clear cerebrospinal fluid surrounds the 1510-gram brain, which has unremarkable gyri and sulci, but for mild cerebral edema. Coronal sections demonstrate sharp demarcation between white and grey matter, without hemorrhage or contusive injury. The ventricles are of normal size. The basal ganglia, brainstem, cerebellum, and arterial systems are free of injury or other abnormalities. The skull is unremarkable with no cranial or basal fractures. The atlanto-occipital joint is stable.

NECK:
The anterior strap muscles of the neck are homogenous and red-brown, with no lacerations or hemorrhage. The thyroid cartilage and hyoid bone are intact and unremarkable. The pharynx is unremarkable and is lined by intact mucosa. The thyroid gland is symmetric and red-brown, without cystic or nodular change. The tongue is unremarkable. The cervical spine and spinal cord are intact.

BODY CAVITIES:
The pleural and pericardial cavities are unremarkable, with no evidence of trauma or excessive fluid. The abdominal cavity reveals severe adhesions and firm fat necrosis precluding definitive evaluation. The small and large bowels are encased in a firm mass of fat necrosis and fibrous adhesions. The major abdominal organs occupy their usual anatomic positions.

RESPIRATORY SYSTEM:
The right and left lungs weigh 1780-grams and 1850-grams, respectively. The external surfaces are smooth and free of adhesions, with no apparent evidence of firearm injuries. Both lungs are extremely heavy and firm. Serial sections reveals extensive consolidation of all lobes with diffuse oozing of yellowish purulent material from the cut surfaces, consistent with pneumonia and ARDS.

CARDIOVASCULAR SYSTEM:
The pericardial sac is intact. The heart is intact and enlarged, cardiomegaly, and weighs 490-grams. The heart is otherwise essentially unremarkable. The epicardial surface is smooth, with minimal fat investment. The coronary arteries are present in a normal distribution. Cross sections of the vessels show no luminal narrowing or abnormality. Serial sectioning of the myocardium reveals focally mottled cut surfaces, suggestive of possible recent ischemia, but with no clear indication of remote or recent infarctions. The valve leaflets are thin and mobile. The walls of the left and right ventricles are 1.7 cm and 0.5 cm thick, respectively. The endocardium is smooth and glistening. The aorta gives rise to three intact and patent arch vessels. The aorta and major blood vessels are unremarkable.

ACLU Detainee DeathII ARMY MEDCOM 569

LIVER & BILIARY SYSTEM:
The 2260-gram liver has an intact, smooth capsule and a sharp anterior border. The parenchyma is mottled tan-brown with a nutmeg appearance. No mass lesions or other abnormalities are seen. The gallbladder contains dark green bile and no stones. The mucosal surface is green and velvety. The extrahepatic biliary tree is patent.

SPLEEN:
The 230-gram spleen has a smooth, intact, red-purple capsule. The parenchyma is maroon and congested, with distinct Malpighian corpuscles and no significant abnormality.

PANCREAS:
The pancreas is severely adhesed to the small and large bowel mass and could not be definitely evaluated.

ADRENAL GLANDS:
The right and left adrenal glands are autolysed, but otherwise unremarkable. Sections through both glands reveal yellow cortices and grey medullae. No masses or areas of hemorrhage are identified.

GENITOURINARY SYSTEM:
The right and left kidneys each weigh 220-grams. The external surfaces are intact and smooth. The cut surfaces are red-tan and congested, with mottled cut surfaces and mild loss of normal cortico-medullary demarcation. The pelves are unremarkable and the ureters are normal in course and caliber. Smooth bladder mucosa overlies an intact urinary bladder wall. The bladder wall is slightly hemorrhagic from the placed catheter. The prostate gland is normal in size, with lobular, yellow-tan parenchyma. The seminal vesicles are unremarkable. The testes are free of mass lesions, contusions, or other abnormalities.

GASTROINTESTINAL TRACT:
The esophagus is intact and is lined by smooth grayish mucosa. The stomach is unremarkable. The gastric wall is intact lined by sloughing autolysed mucosa. The duodenum, small and large bowels are completely encased in a firm mass precluding definitive evaluation.

MICROSCOPIC EXAMINATION

Representative sections of all major organs are obtained and placed in formalin for storage and microscopic examination if needed in the future.

ACLU Detainee DeathII ARMY MEDCOM 570

ADDITIONAL PROCEDURES

1. Full body radiographs are obtained and reveal no skeletal injuries or foreign metal fragments.
2. The dissected organs are forwarded with the body.
3. Documentary photographs of the body are obtained.
4. No body fluids or tissue samples are submitted for toxicological testing (the deceased was hospitalized for approximately three weeks prior to his demise).

OPINION

(b)(6) a 38 year-old Iraqi civilian detainee, died from complications of a gunshot wound(s). No medical records of the initial presentation and surgical management are available for review. The available medical records reveal a down hill hospital course culminating in his demise, three weeks after his injuries, from ARDS and multi-organ failure. Toxicological testing deemed of no importance and no specimens were submitted for testing. Manner of death is homicide.

(b)(6)

(b)(6) **Medical Examiner**

(b)(6)

(b)(6) **Medical Examiner**

ACLU Detainee DeathII ARMY MEDCOM 571

CERTIFICATE OF DEATH *(OVERSEAS)*
Acte de décès (D'Outre-Mer)

NAME OF DECEASED (Last, First, Middle) Nom du décédé (Nom et prénoms)	GRADE Grade	BRANCH OF SERVICE Arme	SOCIAL SECURITY NUMBER
BTB Ismail, Ibrahim,		Civilian	(b)(6)

ORGANIZATION Organisation	NATION (e.g. United States) Pays	DATE OF BIRTH Date de naissance	SEX Sexe
	Iraq	(b)(6) 1976	[X] MALE [ ] FEMALE

RACE Race		MARITAL STATUS Etat Civil		RELIGION Culte	
[ ]	CAUCASOID Caucasique	[ ]	SINGLE Célibataire	[ ]	PROTESTANT Protestant
[ ]	NEGROID Negroide	[ ]	MARRIED Marié	[ ]	CATHOLIC Catholique
[X]	OTHER (Specify) Autre (Spécifier)	[ ]	WIDOWED Veuf	[ ]	JEWISH Juif
		[ ]	DIVORCED Divorcé	[X]	OTHER (Specify) Autre (Spécifier)
		[ ]	SEPARATED Séparé		

NAME OF NEXT OF KIN Nom du plus proche parent	RELATIONSHIP TO DECEASED Parenté du décédé avec le sus
STREET ADDRESS Domicile à (Rue)	CITY OR TOWN OR STATE (Include ZIP Code Ville (Code postal compris)

MEDICAL STATEMENT Déclaration médicale

CAUSE OF DEATH (Enter only one cause per line) Cause du décès (N'indiquer qu'une cause par ligne)			INTERVAL BETWEEN ONSET AND DEATH Intervalle entre l'attaque et le décès
DISEASE OR CONDITON DIRECTLY LEADING TO DEATH [1] Maladie ou condition directement responsable de la mort		Complications of gunshot wound(s) to the abdomen	
ANTECEDENT CAUSES Symptômes précurseurs de la mort	MORBID CONDITION, IF ANY, LEADING TO PRIMARY CAUSE Condition morbide, s'il y a lieu, menant à la cause primaire		
	UNDERLYING CAUSE, IF ANY, GIVING RISE TO PRIMARY CAUSE Condition morbide, s'il y a lieu, menant à la cause primaire		
OTHER SIGNIFICANT CONDITIONS [2] Autres conditions significatives			

MODE OF DEATH Condition de décès	AUTOPSY PERFORMED Autopsie effectuée [X] YES Oui [ ] NO Non	CIRCUMSTANCES SURROUNDING DEATH DUE TO EXTERNAL CAUSES Circonstances de la mort suscitées par des causes extérieures
[ ] NATURAL Mort naturelle	MAJOR FINDINGS OF AUTOPSY Conclusions principales de l'autopsie	
[ ] ACCIDENT Mort accidentelle		
[ ] SUICIDE Suicide	NAME OF PATHOLOGIST Nom du pathologiste (b)(6)	
[X] HOMICIDE Homicide	(b)(6) DATE Date 10 June 2006	AVIATION ACCIDENT Accident d'Avion [ ] YES Oui [X] NO Non

DATE OF DEATH (day, month, year) Date du décès (le jour, le mois, l'année)	PLACE OF DEATH Lieu du décès
(b)(6) 2006	Iraq

I HAVE VIEWED THE REMAINS OF THE DECEASED AND DEATH OCCURRED AT THE TIME INDICATED AND FROM THE CAUSES AS STATED ABOVE
J'ai examiné les restes mortels du dé funt et je conclus que le décès est survenu à l'heure indiquée et à la suite des causes énumérées ci-dessus

NAME OF MEDICAL OFFICER Nom du médecin militaire ou du médecin sanitaire	TITLE OR DEGREE Titre ou diplôme
(b)(6)	Medical Examiner

GRADE Grade	INSTALLATION OR ADDRESS Installation ou adresse
(b)(6)	BIAP, Iraq
DATE Date 18 Oct 06	(b)(6)

[1] Si la disease, injury or complication which caused death
[2] State conditions contributing to the death, but not related to the disease or condition causing death
[1] Préciser la nature de la maladie, de la blessure ou de la complication qui a contribué à la mort, mais non la maladie de manière, telle qu'un arrêt du cœur, etc.
[2] Préciser la condition qui a contribué à la mort, mais n'ayant aucun rapport avec la maladie ou à la condition qui a provoqué la mort

DD FORM 1 APR 77 2064 REPLACES DA FORM 3565, 1 JAN 72 AND DA FORM 3565-R(PAS), 26 SEP 75, WHICH ARE OBSOLETE.

ACLU Detainee DeathII ARMY MEDCOM 572

ARMED FORCES INSTITUTE OF PATHOLOGY
Office of the Armed Forces Medical Examiner
1413 Research Blvd., Bldg. 102
Rockville, MD 20850
301-319-0000

FINAL AUTOPSY EXAMINATION REPORT

Name: BTB Faisel, Ghazi al-Duri
CID: (b)(6)
Date of Birth: (b)(6) 1940
Date of Death (b)(6) 2006
Date/Time of Autopsy: 04 June 2006/1130
Date of Report: 22 May 2007

Autopsy No.: (b)(6)
AFIP No. (b)(6)
Rank: CIV
Place of Death: Iraq
Place of Autopsy: Port Mortuary
Dover AFB, Dover DE

Circumstances of Death: This 66 year old male civilian detainee reportedly collapsed while exiting the latrine.

Authorization for Autopsy: Office of the Armed Forces Medical Examiner, IAW 10 USC 1471

Identification: Presumptive, according to ID band.

CAUSE OF DEATH: Complications of atrial and ventricular myocardial fibrosis.

MANNER OF DEATH: Natural.

FINAL AUTOPSY DIAGNOSES

I. Focal and diffuse atrial and ventricular fibrosis.

II. Moderate aortic atherosclerosis.

III. Bilateral pulmonary congestion and edema (right 960 gm, left 790 gm).

IV. Evidence of injury:
- A. Non-displaced fracture of the cervical vertebrae (C5/6 disk space).
- B. Contusion (2 x ¾ inches) of the right forehead.
- C. Contusion (1 ½ x 1 ¼ inches) of the right infraorbital region of the face.
- D. Laceration (3/8 inch) of the nasal bridge.
- E. Abrasion (1 ¼ x ¾ inch) of the posterior surface of the left forearm.

V. Toxicology: Nordiazepam present in the blood; elevated blood levels of aluminum.

ACLU Detainee DeathII ARMY MEDCOM 573

EXTERNAL EXAMINATION

The body is that of a well-developed male weighing 190 pounds, measuring 68 inches in length and appearing compatible with the reported age of 66 years. The body temperature is cool after refrigeration. Rigor is passing. Lividity is fixed and present predominately on the posterior surfaces of the body, except in areas exposed to pressure.

There is male pattern baldness. The remaining scalp hair is brown gray. Facial hair consists of a mostly gray beard and mustache. The irides are brown. The corneae are cloudy. The conjuctivae are unremarkable. The sclerae are congested. The external auditory canals, external nares and oral cavity are free of foreign material and abnormal secretions. The nasal skeleton is palpably intact. The teeth appear natural and in fair condition.

The neck is straight, and the trachea is midline and mobile. The chest is symmetric. No evidence of injury of the ribs or the sternum is evident externally. The abdomen is flat. The fingernails are intact. The extremities show evidence of injury to be described below. A (b)(6) tattoo (b)(6) (b)(6) tattoo (b)(6) (b)(6) tattoo (b)(6) (b)(6) tattoo (b)(6) (b)(6) (b)(6) A circular scar is present on the right buttock measuring ¾ inch. A ¼ inch scar is present on the medial surface of the right lower leg. A ¾ inch circular scar is present on the posterior lateral surface of the right lower leg. The external genitalia are those of a normal adult male. A 1 ¼ inch cystic lesion is present on the right mid back. The buttocks and anus are unremarkable.

CLOTHING AND PERSONAL EFFECTS

1. A pair of black slippers.
2. White boxer style shorts.
3. Red pants.

EVIDENCE OF INJURY

Head and neck:

A 2 x ¾ inch abraded contusion is present on the right forehead. There is a 1 ½ x 1 ¼ inch abraded contusion present in the right infraorbital region. A 3/8 inch laceration is present on the nasal bridge. A 1 x ¾ inch contusion is present in the right posterior parietal region of the scalp. Galeal hemorrhage is present in the right frontal region. A non-displaced fracture of the anterior cervical vertebrae with surrounding intramuscular hemorrhage is present at the C5/6 disk space. The adjacent spinal cord shows no gross evidence of injury.

Extremities:

There is a 1 ¼ x ¾ inch abrasion present on the dorsal surface of the left forearm.

EVIDENCE OF MEDICAL THERAPY

None.

ACLU Detainee DeathII ARMY MEDCOM 574

INTERNAL EXAMINATION

BODY CAVITIES:
The body is opened by the usual thoraco-abdominal incision and the chest plate is removed. No adhesions or abnormal collections of fluid are present in any of the body cavities. All body organs are present in normal anatomical position. The subcutaneous fat layer of the abdominal wall is 1 ½ inches thick. There is no evidence of blunt force or penetrating injury to the thoraco-abdominal region. Longitudinal incisions of the posterior surfaces of the torso, upper and lower extremities show no evidence of recent injury.

HEAD (CENTRAL NERVOUS SYSTEM):
(See above "Evidence of Injury")

The scalp is reflected. The calvarium of the skull is removed. The dura mater and falx are intact. There is no epidural or subdural hemorrhage present. The leptomeninges are thin and delicate. The cerebral hemispheres are symmetrical. The structures at the base of the brain, including cranial nerves and blood vessels are intact. After fixation, coronal sections through the cerebral hemispheres reveal no lesions. Transverse sections through the brainstem and cerebellum are unremarkable. The brain weighs 1380 gm.

NECK:
(See above "Evidence of Injury")

Layer-wise examination of the anterior and posterior strap muscles of the neck show them to be homogenous red-brown and without hemorrhage. The thyroid cartilage and hyoid are intact. The larynx is lined by intact white mucosa. The thyroid is symmetric and red-brown, without cystic or nodular change. The tongue is free of bite marks, hemorrhage, or other injuries.

RESPIRATORY SYSTEM:
The right and left lungs weigh 960 gm and 790 gm, respectively. The external surfaces are smooth and deep red-purple. The pulmonary parenchyma is moderately congested and edematous. No mass lesions or areas of consolidation are present.

CARDIOVASCULAR SYSTEM:
The 480 gm heart is contained in an intact pericardial sac. The epicardial surface is smooth, with minimal fat investment. The coronary arteries arise normally, follow the usual distribution, and are without evidence of significant atherosclerosis or thrombosis. The myocardium is homogenous, red-brown, and firm; the atrial and ventricular septa are intact. The aorta gives rise to three intact and patent arch vessels. There are moderate atherosclerotic changes at the iliac bifurcation. The vena cava and its major tributaries return to the heart in the usual distribution. The renal and mesenteric vessels are unremarkable.

LIVER & BILIARY SYSTEM:
The 1670 gm liver has an intact, smooth capsule and a sharp anterior border. The parenchyma is tan-brown and congested, with the usual lobular architecture. No mass lesions or other abnormalities are seen. The gallbladder is empty. The mucosal surface is green and velvety. The extrahepatic biliary tree is patent.

SPLEEN:
The 240 gm spleen has a smooth, intact, red-purple capsule. The parenchyma is maroon and congested, with distinct Malpighian corpuscles.

ACLU Detainee DeathII ARMY MEDCOM 575

PANCREAS:
The pancreas is firm and yellow-tan, with the usual lobular architecture. No mass lesions or other abnormalities are seen.

ADRENALS GLANDS:
The right and left adrenal glands are symmetric, with bright yellow cortices and grey medullae. No masses or areas of hemorrhage are identified.

GENITOURINARY SYSTEM:
The right and left kidneys each weigh 180 gm. The external surfaces are intact and smooth. The cut surfaces are red-tan and congested, with uniformly thick cortices and sharp corticomedullary junctions. The pelves are unremarkable and the ureters are normal in course and caliber. Tan bladder mucosa overlies an intact bladder wall. The bladder is empty. The prostate is normal in size, with lobular, yellow-tan parenchyma. The seminal vesicles are unremarkable. The testes are free of mass lesions, contusions, or other abnormalities.

GASTROINTESTINAL TRACT:
The esophagus is intact and lined by smooth, grey-white mucosa. The stomach contains approximately 50 ml of liquid material. The gastric wall is intact. The duodenum, loops of small bowel and colon are unremarkable. The appendix is not identified.

MUSCULOSKELETAL SYSTEM:
(See above "Evidence of Injury")

Muscle development is normal. No evidence of non-traumatic bone or joint abnormalities is noted.

RADIOLOGIC EXAMINATION

Full body radiographs are obtained and reveal a metallic fragment in the right lower leg.

MICROSCOPIC EXAMINATION

1. Heart (slides 1-right coronary artery, right ventricle; 2-left ventricular posterior wall; 3-left ventricular lateral wall; 4-left ventricular anterior wall; 5-septum): mild coronary atherosclerosis (1); patchy subendocardial (2) and interstitial fibrosis (4).
    a. Conduction system
        i. Region of the sino-atrial (SA) node, slides 11,12: marked, predominately interstitial atrial fibrosis, mild thickening of the SA nodal artery, unremarkable appearing SA node.
        ii. Region of the atrioventricular (AV) node, slides 13-17: focal replacement fibrosis near the crest of the ventricular septum (13), mild thickening of AV nodal artery, AV node without significant microscopic abnormality (16).
2. Brain (slides 6,7): focal cerebrovascular intimal thickening (7).
3. Spleen (slide 8): no significant microscopic abnormality.
4. Liver (slide 8): congestion.
5. Lungs (slide 9): congestion with patchy pulmonary edema and atelectasis.
6. Kidneys (slide 10): autolysis.

ACLU Detainee DeathII ARMY MEDCOM 576

ADDITIONAL PROCEDURES

- Documentary photographs are taken by the OAFME staff photographers.
- Specimens retained for toxicologic testing and/or DNA identification are: blood, bile, gastric contents, vitreous, lung, liver, kidney, spleen, adipose tissue and psoas muscle.
- The heart, brain and selected portions of organs are retained in formalin.
- Personal effects are released to the appropriate mortuary operations representatives.

OPINION

According to reports, this 66 year old male Civilian detainee reportedly collapsed while exiting the latrine. He was unresponsive to resuscitative efforts and was ultimately pronounced dead. Additional medical information or history was not available.

Autopsy examination showed contusions of the right side of the face and scalp and laceration of the bridge of the nose. Examination of the neck revealed a non-displaced fracture without apparent cord injury. No evidence of additional significant injury was identified. Radiologic examination showed the presence of a metallic fragment in the right lower leg, consistent with remote injury. Microscopic examination of the heart showed both atrial and ventricular fibrosis. Routine postmortem toxicological examination showed the presence of nordiazepam (blood 0.029 mg/l). Extended testing for heavy metals showed elevated levels of aluminum in the blood. Levels for arsenic and cadmium were not elevated and uranium and lead were below detection limits.

Although the exact etiology of the myocardial fibrosis is uncertain, the interstitial pattern and the degree of atrial involvement are suggestive of amyloid. Special stains (Congo red) were equivocal, however. Whatever the cause, lethal cardiac arrhythmia is a significant complication associated with myocardial fibrosis. In the current case, both the circumstances and autopsy findings are consistent with collapse following a cardiac event. The facial and neck injuries were most consistent with a terminal fall. Postmortem toxicological testing showed low levels of a metabolite of the therapeutic agent Valium. Elevated levels of aluminum have been associated with neurotoxicity[1], but the significance of this finding in the current case is uncertain.

In summary, this decedent most likely died of complications (lethal cardiac arrhythmia) of cardiac myocardial fibrosis. The manner of death is natural.

(b)(6)

(b)(6) Medical Examiner (b)(6)

[1] http://en.wikipedia.org/wiki/Aluminium

ACLU Detainee DeathII ARMY MEDCOM 577

CERTIFICATE OF DEATH *(OVERSEAS)*
Acte de décès (D'Outre-Mer)

NAME OF DECEASED *(Last, First, Middle)* Nom du décédé (Nom et prénoms)	GRADE Grade	BRANCH OF SERVICE Arme	SOCIAL SECURITY NUMBER Numéro de l'Assurance Social
BTB Faisel, Ghazi, Al-Duri		Civilian	(b)(6)

ORGANIZATION Organisation	NATION *(e.g. United States)* Pays	DATE OF BIRTH Date de naissance	SEX Sexe
	Iraq	(b)(6) 1940	[X] MALE [ ] FEMALE

RACE Race		MARITAL STATUS État Civil			RELIGION Culte		
[X]	CAUCASOID Caucasique	[ ]	SINGLE Célibataire	[ ] DIVORCED Divorcé	[ ]	PROTESTANT Protestant	[ ] OTHER (Specify) Autre (Spécifier)
[ ]	NEGROID Negroide	[ ]	MARRIED Marié	[ ] SEPARATED Séparé	[ ]	CATHOLIC Catholique	[X]
[ ]	OTHER (Specify) Autre (Spécifier)	[ ]	WIDOWED Veuf		[ ]	JEWISH Juif	

NAME OF NEXT OF KIN Nom du plus proche parent	RELATIONSHIP TO DECEASED Parenté du décédé avec le sus
STREET ADDRESS Domicilé à (Rue)	CITY OR TOWN OR STATE *(Include ZIP Code)* Ville (Code postal compris)

MEDICAL STATEMENT Déclaration médicale

	CAUSE OF DEATH (Enter only one cause per line) Cause du décès (N'indiquer qu'une cause par ligne)	INTERVAL BETWEEN ONSET AND DEATH Intervalle entre l'attaque et le décès
DISEASE OR CONDITON DIRECTLY LEADING TO DEATH [1] Maladie ou condition directement responsable de le mort [1]	Complications of atrial and ventricular myocardial fibrosis	Unknown
ANTECEDENT CAUSES Symptômes précurseurs de la mort. MORBID CONDITION, IF ANY, LEADING TO PRIMARY CAUSE Condition morbide, s'il y a lieu. menant à la cause primaire		
UNDERLYING CAUSE, IF ANY, GIVING RISE TO PRIMARY CAUSE Condition morbide, s'il y a lieu. menant à la cause primaire		
OTHER SIGNIFICANT CONDITIONS [2] Autres conditions significatives [2]		

MODE OF DEATH Condition de décès	AUTOPSY PERFORMED Autopsie effectuée [X] YES Oui [ ] NO Non	CIRCUMSTANCES SURROUNDING DEATH DUE TO EXTERNAL CAUSES Circonstances de la mort suscitées par des causes extérieures
[X] NATURAL Mort naturelle	MAJOR FINDINGS OF AUTOPSY Conclusions principales de l'autopsie	
[ ] ACCIDENT Mort accidentelle		
[ ] SUICIDE Suicide	NAME OF PATHOLOGIST Nom du pathologiste (b)(6)	
[ ] HOMICIDE Homicide	SIGNATURE (b)(6) DATE Date 4 June 2006	AVIATION ACCIDENT Accident à Avion [ ] YES Oui [X] NO Non

DATE OF DEATH *(day, month, year)* Date de décès (le jour, le mois, l'année)	PLACE OF DEATH Lieu de décès
(b)(6) 2006	Iraq

I HAVE VIEWED THE REMAINS OF THE DECEASED AND DEATH OCCURRED AT THE TIME INDICATED AND FROM THE CAUSES AS STATED ABOVE.
J'ai examiné les restes mortels du dé funtet je conclus que le décès est survenu à l'heure indiquée et à, la suite des causes énumérées ci-dessus.

NAME OF MEDICAL OFFICER Nom du médicin militaire ou du médicin sanitaire	TITLE OR DEGREE Titre ou diplômé
(b)(6)	Medical Examiner

GRADE Grade	INSTALLATION OR ADDRESS Installation ou adresse
(b)(6)	Dover AFB, Dover DE
DATE Date 6/1/2007	SIGNATURE (b)(6)

[1] State disease, injury or complication which caused death, but not mode of dying such as heart failure, etc.
[2] State conditions contributing to the death, but not related to the disease or condition causing death.
[1] Préciser la nature de la maladie, de la blessure ou de la complication qui a contribué à la mort, mais non la manière de mourir, telle qu 'un arrêt du coeur, etc
[2] Préciser la condition qui a contribué à la mort, mais n'ayant aucun rapport avec la maladie ou à la condition qui a provoqué la mort.

DD FORM 1 APR 77 2064 REPLACES DA FORM 3565, 1 JAN 72 AND DA FORM 3565-R(PAS), 26 SEP 75, WHICH ARE OBSOLETE.

MEDCOM 0578

ACLU Detainee DeathII ARMY MEDCOM 578

CERTIFICATE OF DEATH *(OVERSEAS)*
Acte dé décès (D'Outre-Mer)

NAME OF DECEASED *(Last, First, Middle)* Nom du décédé (Nom et prénoms)	GRADE Grade	BRANCH OF SERVICE Arme	SOCIAL SECURITY NUMBER Numéro de l'Assurance Social
BTB Salman, Tha'ir, Kaduri		Civilian	(b)(6)

ORGANIZATION Organisation	NATION *(e.g. United States)* Pays	DATE OF BIRTH Date de naissance	SEX Sexe
	Iraq	(b)(6) 1953	[X] MALE [ ] FEMALE

RACE Race		MARITAL STATUS État Civil			RELIGION Culte		
	CAUCASOID Caucasique		SINGLE Célibataire		DIVORCED Divorcé		PROTESTANT Protestant		OTHER (Specify) Autre (Spécifier)
	NEGROID Negriode		MARRIED Marié		SEPARATED Séparé		CATHOLIC Catholique	X	
X	OTHER (Specify) Autre (Spécifier)		WIDOWED Veuf				JEWISH Juif		

NAME OF NEXT OF KIN Nom du plus proche parent	RELATIONSHIP TO DECEASED Parenté du décédé avec le sus
STREET ADDRESS Domicilé à (Rue)	CITY OR TOWN OR STATE *(Include ZIP Code)* Ville (Code postal compris)

MEDICAL STATEMENT **Déclaration médicale**

	CAUSE OF DEATH (Enter only one cause per line) Cause du décès (N'indiquer qu'une cause par ligne)	INTERVAL BETWEEN ONSET AND DEATH Intervalle entre l'attaque et le décès
DISEASE OR CONDITON DIRECTLY LEADING TO DEATH [1] Maladie ou condition directement responsable de la mort. [1]	Occlusive Atherosclerotic/Thrombotic Coronary Artery Disease	Unknown
ANTECEDENT CAUSES Symptômes précurseurs de la mort. MORBID CONDITION, IF ANY, LEADING TO PRIMARY CAUSE Condition morbide, s'il y a lieu, menant à la cause primaire		
UNDERLYING CAUSE, IF ANY, GIVING RISE TO PRIMARY CAUSE Condition morbide, s'il y a lieu, menant à la cause primaire		
OTHER SIGNIFICANT CONDITIONS [2] Autres conditions significatives [2]		

MODE OF DEATH Condition de décès	AUTOPSY PERFORMED Autopsie effectuée	CIRCUMSTANCES SURROUNDING DEATH DUE TO EXTERNAL CAUSES Circonstances de la mort suscitées par des causes extérieures
X NATURAL Mort naturelle	[X] YES Oui [ ] NO Non	
ACCIDENT Mort accidentelle	MAJOR FINDINGS OF AUTOPSY Conclusions principales de l'autopsie	
SUICIDE Suicide	NAME OF PATHOLOGIST Nom du pathologiste (b)(6)	
HOMICIDE Homicide	SIGNATURE Signature	DATE Date 4 June 2006

AVIATION ACCIDENT Accident à Avion [ ] YES Oui [X] NO Non

DATE OF DEATH *(day, month, year)* Date de décès (le jour, le mois, l'année)	PLACE OF DEATH Lieu de décès
(b)(6) 2006	Iraq

I HAVE VIEWED THE REMAINS OF THE DECEASED AND DEATH OCCURRED AT THE TIME INDICATED AND FROM THE CAUSES AS STATED ABOVE.
J'ai examiné les restes mortels du dé funt je conclus que le décès est survenu à l'heure indiquée et à, la suite des causes énumérées ci-dessus.

NAME OF MEDICAL OFFICER Nom du médicin militaire ou du médicin sanitaire	TITLE OR DEGREE Titre ou diplômé
(b)(6)	Medical Examiner
GRADE Grade (b)(6)	INSTALLATION OR ADDRESS Installation ou adresse Dover AFB, Dover DE
DATE Date	SIGNATURE Signature

[1] State disease, injury or complication which caused death, but not mode of dying such as heart failure, ect.
[2] State conditions contributing to the death, but not related to the disease or condition causing death.
[1] Préciser la nature de la maladie, de la blessure ou de la complication qui a contribué à la mort, mais non la manière de mourir, telle qu 'un arrêt du coeur, etc
[2] Préciser la condition qui a contribué à la mort, mais n'ayant aucun rapport avec la maladie ou à la condition qui a provoqué la mort.

DD FORM 1 APR 77 2064 REPLACES DA FORM 3565, 1 JAN 72 AND DA FORM 3565-R(PAS), 26 SEP 75, WHICH ARE OBSOLETE.

ARMED FORCES INSTITUTE OF PATHOLOGY
Office of the Armed Forces Medical Examiner
1413 Research Blvd., Bldg. 102
Rockville, MD 20850
1-301-319-0000
(FAX 1-301-319-0635)

FINAL AUTOPSY REPORT

Name: ALI, Ismael Hamid
ISN: (b)(6)
Date of Birth: (b)(6) 1974 (32 years)
Date of Death: (b)(6) 2006
Date of Autopsy: 04 JUN 1100 hours
Date of Report: 08 JUL 2006

Autopsy No. (b)(6)
AFIP No.: (b)(6)
Rank: Civilian Iraqi Detainee
Place of Death: Iraq (Camp Bucca)
Place of Autopsy: Dover Port Mortuary

Circumstances of Death:
(b)(6) is a 32 year-old civilian Iraqi detainee at the Theater Internment Facility at Camp Bucca, Iraq who collapsed while playing volleyball. He was unresponsive to oral commands and made gurgling sounds. He was not breathing and was pulseless with fixed and dilated pupils when received at the nearest medical facility. Basic and advanced cardiac (CPR/ACLS) life support measures were unsuccessful.

Authorization for Autopsy: Office of the Armed Forces Medical Examiner, IAW 10 USC 1471

Identification:
(b)(6) was identified by detention camp wrist bracelet, toe tags and transportation documents. A muscle sample is collected for DNA comparison if needed.

CAUSE OF DEATH:
Arrhythmogenic Right Ventricular Dysplasia

MANNER OF DEATH:
Natural

ACLU Detainee DeathII ARMY MEDCOM 580

FINAL AUTOPSY DIAGNOSIS:

I. A. Cardiovascular System:

- Cardiomegaly, mild, 480 grams.
- Heart is submitted for further specialized examination at the Armed Forces Institute of Pathology.
  - Arrhythmogenic right ventricular dysplasia.
  - Coronary arteries with no significant pathological changes.

B. Respiratory System:

- Pulmonary edema, extensive, right lung 1730 grams and left lung 1270 grams.
- Frothy fluid fills the trachea and major bronchi.

C. Other Body Systems:

- Passive congestion of liver, spleen and kidneys.

D. Injuries

- A longitudinal superficial abrasion is noted on the posterior surface of the proximal right forearm.
- No evidence of other blunt or shape force trauma.

II: Evidence of Medical Intervention:

a. Endotracheal tube, properly positioned.
b. Gastric tube.
c. Multiple IV lines into both anticubital fossae.
d. Urinary catheter, properly positioned.
e. EKG pads.
f. Automatic Defibrillator Pads (2) on the torso.

III. Evidence Collection: none

IV. Identification Marks:

- A tattoo (b)(6)
  (b)(6)
- (b)(6) tattoos (b)(6)
  (b)(6)
- A tattoo (b)(6)
- Multiple scars are noted of chin and both distal thighs.

VI. Toxicology:

- Negative.
- Carboxyhemoglobin saturation in the blood is 2% (0-3% saturation is expected in non-smokers).
- Cyanide, negative.
- No evidence of ethanol, screened medications or drugs of abuse.

ACLU Detainee DeathII ARMY MEDCOM 581

EXTERNAL EXAMINATION

The unclad body is that of a well-developed, well-nourished male. The body weighs 197 pounds, is 72" in height and appears compatible with the reported age of 32 years. The body is cold. Rigor is present to an equal degree in all extremities. Lividity is present and fixed on the posterior surface of the body, except in areas exposed to pressure. The scalp hair is Black and has a Black mustache. The irides are brown. The corneae are dull. The conjunctivae are slightly congested. The sclerae are unremarkable. The external auditory canals, external nares and oral cavity are free of foreign material and abnormal secretions. The nasal skeleton is palpably intact. The lips are without evident injury, and reveal postmortem drying. The teeth are natural and in good condition. Examination of the neck revealed no evidence of injury. The chest is unremarkable. No injury of the ribs or sternum is evident externally. The abdomen is unremarkable. No major surgical scars are noted. The extremities show no evidence of remote or recent trauma. The fingernails are intact. Tattoos (b)(6)
(b)(6 A skin tag is noted behind the right ear. The external genitalia are those of a normal adult circumcised male. The posterior torso is without note.

EVIDENCE OF THERAPY

Endotracheal tube and gastric tube, properly positioned, multiple IV lines into both anticubital fossae, urinary catheter, properly positioned, EKG pads and Automatic Defibrillator Pads. .

EVIDENCE OF INJURY

No evidence of major trauma, recent or remote, is identified. An abrasion is noted on the back of the right forearm. Minor scars are noted on the distal thigh, bilaterally.

INTERNAL EXAMINATION

BODY CAVITIES:
The body is opened by the usual thoraco-abdominal incision and the chest plate is removed. No adhesions are noted of the body cavities. 200 ml of effusion fluid are present in each of the right and left pleural cavities and in the pericardial cavity. No excess fluid is seen in the peritoneal cavity. All body organs are present in the normal anatomical position. There is no internal evidence of blunt force or penetrating injury to the thoraco-abdominal region.

HEAD: (CENTRAL NERVOUS SYSTEM)
The scalp is reflected. The calvarium of the skull is removed. The dura mater and falx cerebri are intact. There is no epidural or subdural hemorrhage present. The leptomeninges are thin and delicate. The brain weighs 1470 grams. The cerebral hemispheres are symmetrical. The structures at the base of the brain, including cranial nerves and blood vessels, are intact. Coronal sections through the cerebral hemispheres revealed no lesions.

ACLU Detainee DeathII ARMY MEDCOM 582

Transverse sections through the brain stem and cerebellum are unremarkable. No significant pathological changes are noted.

NECK:
Examination of the soft tissues of the neck, including strap muscles, thyroid gland and large vessels, reveals no abnormalities. The hyoid bone and larynx are intact.

CARDIOVASCULAR SYSTEM:
The pericardial surfaces are smooth, glistening and unremarkable; the pericardial sac is free of significant fluid and adhesions. The heart weighs 480 grams. The aorta and its major branches and the venae cavae and their major tributaries follow the usual distribution and are grossly unremarkable. The heart is fixed in formalin and submitted for further studies. (Please see the Cardiovascular Consultation Report below).

RESPIRATORY SYSTEM:
The upper airway is clear of debris and foreign material, but reveals presence of frothy fluid; the mucosal surfaces are smooth, yellow-tan and unremarkable. The pleural surfaces are smooth, glistening and unremarkable bilaterally. The pulmonary parenchyma is red-purple, exuding excessive amounts of edematous fluid; no focal lesions are noted. The pulmonary arteries are normally developed, patent and without thrombus or embolus. The right lung weighs 1370 grams; the left 1270 grams.

LIVER & BILIARY SYSTEM:
The hepatic capsule is smooth, glistening and intact, covering dark red-brown, markedly congested parenchyma with no focal lesions noted. The gallbladder contains dark green mucoid bile; the mucosa is velvety and unremarkable. No stone present. The extrahepatic biliary tree is patent, without evidence of calculi. The liver weighs 2060 grams.

ALIMENTARY TRACT:
The tongue exhibits no evidence of recent injury. The esophagus is lined by gray-white, smooth mucosa. The gastric mucosa is arranged in the usual rugal folds and the lumen contains greenish fluid. The gastric mucosa is congested with no ulceration. The small and large bowels are unremarkable. The pancreas has a normal pink-tan lobulated appearance and the ducts are clear. The appendix is present and grossly unremarkable.

GENITOURINARY SYSTEM:
The renal capsules are smooth and thin, semi-transparent and strip with ease from the underlying smooth, red-brown cortical surfaces. The cortices are sharply delineated from the medullary pyramids, which are red-purple to tan and unremarkable. The calyces, pelves and ureters are unremarkable. The urinary bladder contains no urine (urinary catheter is in place); the mucosa is gray-tan and unremarkable. The right kidney weighs 150 grams; the left 170 grams.

ACLU Detainee DeathII ARMY MEDCOM 583

RETICULOENDOTHELIAL SYSTEM:
The spleen has a smooth, intact capsule covering red-purple, moderately firm parenchyma; the lymphoid follicles are unremarkable. The regional lymph nodes appear normal. The spleen weighs 260 grams.

ENDOCRINE SYSTEM:
The pituitary, thyroid and adrenal glands are unremarkable.

MUSCULOSKELETAL SYSTEM:
Muscle development is normal. No bone or joint abnormalities are noted.

ADDITIONAL PROCEDURES

1. Documentary photographs are taken by an OAFME photographer.
2. Full body radiographs document absence of skeletal injuries or evidence of trauma.
3. Specimens retained for toxicological and/or DNA identification are: blood, vitreous fluid, bile, urine, gastric contents and tissue samples from liver, lung, kidney, spleen, brain, psoas muscle and adipose tissue.
4. Representative sections of organs are retained in formalin for microscopic examination if needed in the future.
5. Clothing, personal effects and military gear are released to the appropriate mortuary operations representative.

CARDIOVASCULAR CONSULT

DIAGNOSIS: Arrhythmogenic Right Ventricular Dysplasia

History: 32 year old male Iraqi detainee who collapsed while playing volleyball.

Heart: 480 grams; normal epicardial fat; closed foramen ovale; normal left ventricular chamber dimensions: left ventricular cavity diameter 40 mm, left ventricular free wall thickness 12 mm, ventricular septum thickness 14 mm.; right ventricular dilatation with fibrofatty replacement, focal transmural scarring, and coarsely trabeculated endocardial surface with focal thickening; mildly thickened and redundant mitral valve leaflets; small fenestration, left coronary cusp of aortic valve; transmural scars, anterior and posterior right ventricle; histological sections show transmural fibrofatty replacement of right ventricle with focal attenuation and vacuolization of myocardial fibers, and rare foci of single cell necrosis with lymphohistiocytic infiltrates; unremarkable left ventricular myocardium.

Coronary Arteries: Normal ostia; right dominance; no gross atherosclerosis

ACLU Detainee DeathII ARMY MEDCOM 584

OPINION

(b)(6) a 32 year-old Iraqi detainee, who collapsed while playing volleyball at an internment facility, died from cardiac arrhythmia secondary to "arrhythmogenic right ventricular dysplasia. Examination of the heart revealed fibrofatty replacement, transmural scarring and fenestration of the right ventricle. There was no evidence of recent or remote trauma. Toxicological studies were negative for ethanol, screened medications and drugs of abuse. Manner of death is "natural".

(b)(6)

(b)(6) Medical Examiner

ACLU Detainee DeathII ARMY MEDCOM 585

DEPARTMENT OF DEFENSE
ARMED FORCES INSTITUTE OF PATHOLOGY
WASHINGTON, DC 20306-6000

REPLY TO ATTENTION OF

AFIP-(b)(6)

PATIENT IDENTIFICATION
AFIP Accessions Number **Sequence**
(b)(6)

TO:

OFFICE OF THE ARMED FORCES MEDICAL EXAMINER
ARMED FORCES INSTITUTE OF PATHOLOGY
WASHINGTON, DC 20306-6000

Name
ALI, ISMAEL HAMID

SSAN: **Autopsy:** (b)(6)
Toxicology Accession #: (b)(6)
Date Report Generated: June 12, 2006

CONSULTATION REPORT ON CONTRIBUTOR MATERIAL

AFIP DIAGNOSIS **REPORT OF TOXICOLOGICAL EXAMINATION**

Condition of Specimens: GOOD
Date of Incident (b)(6) 2006 **Date Received:** 6/6/2006

CARBON MONOXIDE: The carboxyhemoglobin saturation in the blood was 2% as determined by spectrophotometry with a limit of quantitation of 1%. Carboxyhemoglobin saturations of 0-3% are expected for non-smokers and 3-10% for smokers. Saturations above 10% are considered elevated and are confirmed by gas chromatography.

VOLATILES: The **HEART BLOOD AND URINE** were examined for the presence of ethanol at a cutoff of 20 mg/dL. No ethanol was detected.

CYANIDE: There was no cyanide detected in the heart blood. The limit of quantitation for cyanide is 0.25 mg/L. Normal blood cyanide concentrations are less than 0.15 mg/L. Lethal concentrations of cyanide are greater than 3 mg/L.

DRUGS: The **URINE** was screened for acetaminophen, amphetamine, antidepressants, antihistamines, barbiturates, benzodiazepines, cannabinoids, chloroquine, cocaine, dextromethorphan, lidocaine, narcotic analgesics, opiates, phencyclidine, phenothiazines, salicylates, sympathomimetic amines and verapamil by gas chromatography, color test or immunoassay. The following drugs were detected:

None were found.

(b)(6)
Office of the Armed Forces Medical Examiner

(b)(6)
Office of the Armed Forces Medical Examiner

ACLU Detainee DeathII ARMY MEDCOM 586

CERTIFICATE OF DEATH *(OVERSEAS)*
Acte de décès (D'Outre-Mer)

NAME OF DECEASED *(Last, First, Middle)* Nom du décédé (Nom et prénoms)	GRADE Grade	BRANCH OF SERVICE Arme	SOCIAL SECURITY NUMBER Numéro de l'Assurance Sociale
BTB Ali, Ismael, Hamid		Civilian	(b)(6)

ORGANIZATION Organisation	NATION *(e.g. United States)* Pays	DATE OF BIRTH Date de naissance	SEX Sexe
	Iraq	(b)(6) 1974	[X] MALE [ ] FEMALE

RACE Race		MARITAL STATUS État Civil			RELIGION Culte		
	CAUCASOID Caucasique		SINGLE Célibataire		DIVORCED Divorcé		PROTESTANT Protestant		OTHER (Specify) Autre (Spécifier)
	NEGROID Negroide		MARRIED Marié		SEPARATED Séparé		CATHOLIC Catholique	X	
X	OTHER (Specify) Autre (Spécifier)		WIDOWED Veuf				JEWISH Juif		

NAME OF NEXT OF KIN Nom du plus proche parent	RELATIONSHIP TO DECEASED Parenté du décédé avec le sus
STREET ADDRESS Domicile à (Rue)	CITY OR TOWN OR STATE *(Include ZIP Code)* Ville (Code postal compris)

MEDICAL STATEMENT Déclaration médicale

CAUSE OF DEATH (Enter only one cause per line) Cause du décès (N'indiquer qu'une cause par ligne)		INTERVAL BETWEEN ONSET AND DEATH Intervalle entre l'attaque et le décès
DISEASE OR CONDITON DIRECTLY LEADING TO DEATH [1] Maladie ou condition directement responsable de la mort.	Arrhythmogenic Right Ventricular Dysplasia	Unknown
ANTECEDENT CAUSES Symptômes précurseurs de la mort. — MORBID CONDITION, IF ANY, LEADING TO PRIMARY CAUSE Condition morbide, s'il y a lieu, menant à la cause primaire		
ANTECEDENT CAUSES Symptômes précurseurs de la mort. — UNDERLYING CAUSE, IF ANY, GIVING RISE TO PRIMARY CAUSE Condition morbide, s'il y a lieu, menant à la cause primaire		
OTHER SIGNIFICANT CONDITIONS [2] Autres conditions significatives [2]		

MODE OF DEATH Condition de décès	AUTOPSY PERFORMED Autopsie effectuée	CIRCUMSTANCES SURROUNDING DEATH DUE TO EXTERNAL CAUSES Circonstances de la mort suscitées par des causes extérieures
[X] NATURAL Mort naturelle	[X] YES Oui [ ] NO Non	
[ ] ACCIDENT Mort accidentelle	MAJOR FINDINGS OF AUTOPSY Conclusions principales de l'autopsie	
[ ] SUICIDE Suicide	NAME OF PATHOLOGIST (b)(6)	
[ ] HOMICIDE Homicide	(b)(6) DATE Date 4 June 2006	AVIATION ACCIDENT Accident d'Avion [ ] YES Oui [X] NO Non

DATE OF DEATH *(day, month, year)* Date de décès (le jour, le mois, l'année)	PLACE OF DEATH Lieu du décès
(b)(6) 2006	Iraq

I HAVE VIEWED THE REMAINS OF THE DECEASED AND DEATH OCCURRED AT THE TIME INDICATED AND FROM THE CAUSES AS STATED ABOVE.
J'ai examiné les restes mortels du dé funtat je conclus que le décès est survenu à l'heure indiquée et à, la suite des causes énumérées ci-dessus.

NAME OF MEDICAL OFFICER Nom du médicin militaire ou du médicin sanitaire	TITLE OR DEGREE Titre ou diplômé
(b)(6)	Medical Examiner
GRADE Grade (b)(6)	INSTALLATION OR ADDRESS Installation ou adresse Dover AFB, Dover DE (b)(6)
DATE Date 24 Jul 06	

[1] State disease, injury or complication which caused
[2] State conditions contributing to the death, but not re
[1] Préciser la nature de la maladie, de la blessure ou de la complication qui a contribué à la mort, mais non la maladie du mourir, telle qu'un arrêt du coeur, etc
[2] Préciser la condition qui a contribué à la mort, mais n'ayant aucun rapport avec la maladie ou à la condition qui a provoqué la mort.

DD FORM 1 APR 77 2064 REPLACES DA FORM 3565, 1 JAN 72 AND DA FORM 3565-R(PAS), 26 SEP 75, WHICH ARE OBSOLETE.

ARMED FORCES INSTITUTE OF PATHOLOGY
Office of the Armed Forces Medical Examiner
1413 Research Blvd., Bldg. 102
Rockville, MD 20850
1-301-319-0000

AUTOPSY EXAMINATION REPORT

Name: BTB Lohaybi, Monder Mahmoud
(b)(6)
ISN: (b)(6)
Date of Birth: (b)(6) 1944
Date of Death: (b)(6) 2006
Date/Time of Autopsy: 11 APR 2006 @ 1100 hrs
Date of Report: 26 JUN 2006

Autopsy No.: (b)(6)
AFIP No.: (b)(6)
Rank: Civilain
Place of Death: Iraq
Place of Autopsy: Port Mortuary, Dover AFB, DE

Circumstances of Death: This 62 year-old detainee was found unresponsive and brought to the 344th Field Medical Hospital. Despite treatment the detainee expired. The deceased is reported as having a past medical history significant for smoking and diabetes mellitus.

Authorization for Autopsy: Office of the Armed Forces Medical Examiner, IAW 10 USC 1471

Identification: Presumptive identification from examination of accompanying paperwork and wrist identification bracelet. Post-mortem fingerprints, dental charting and DNA obtained.

CAUSE OF DEATH: Hypertrophic and Arteriosclerotic Cardiovascular Disease

MANNER OF DEATH: Natural

ACLU Detainee DeathII ARMY MEDCOM 588

FINAL AUTOPSY DIAGNOSIS

I. Cardiovascular System:
   - A. Cardiomegaly: Heart weight 770-grams (predicted normal heart weight for a male with a body weight of 164-pounds is 295-grams with a lower 95% confidence limit of 202-grams and an upper 95% confidence limit of 432-grams)
   - B. Atherosclerotic Coronary Artery Disease:
     1. 90% stenosis of the left anterior descending coronary artery by atherosclerotic plaque
     2. 75% stenosis of the left circumflex coronary artery by atherosclerotic plaque
     3. 75% stenosis of the right coronary artery by atherosclerotic plaque
   - C. Remote Myocardial Infarction: 2.5-centimeter scar in the anterior wall of the left ventricle that extends to the apex

II. Pulmonary System: Pulmonary edema and congestion (Lung weights: right 780-grams; left 720-grams)

III. Genitourinary System: Benign Nephrosclerosis

IV. Hepatobilliary System: Status post cholecystectomy

V. No significant injuries identified

VI. Minor Injuries: Abrasions (4) of the left side of the face ranging in greatest dimension from ¼-inch to 1 ¾-inches

VII. Post-mortem changes:
   - A. Lividity is fixed on the posterior surface of the body except in areas exposed to pressure
   - B. Rigor has passed
   - C. Moderate decomposition of the internal organs
   - D. Skin slippage on the left ankle

VIII. Toxicology (AFIP):
   - A. CARBON MONOXIDE: The carboxyhemoglobin hemoglobin saturation is 1%.
   - B. VOLATILES: There is no ethanol detected in the blood and vitreous fluid.
   - C. CYANIDE: There is no cyanide detected in the blood.
   - D. DRUGS: No screened drugs of abuse or medications are detected in the urine.

ACLU Detainee DeathII ARMY MEDCOM 589

EXTERNAL EXAMINATION

The body is that of a well-developed, well-nourished appearing, 72-inch tall, 164-pounds male whose appearance is consistent with the reported age of 61-years. Lividity is present on the posterior surface of the body except in areas exposed to pressure. Rigor has passed.

The scalp is covered with short gray and black hair with male pattern blading. The irides are dark and the cornea are opacified. The external auditory canals and ears are unremarkable. The nares are patent and the lips are atraumatic. The is red-brown purge fluid in the nares. The nose and maxillae are palpably stable. The mouth is edentulous. There is post-mortem skin slippage on the left side of the face.

The neck is straight, and the trachea is midline and mobile. The chest is symmetric. The abdomen is flat. The genitalia are those of a normal adult male. The testes are descended and free of masses. Pubic hair is present in a normal distribution. The anus is unremarkable. There are areas of gray/brown discoloration without underlying hemorrhage on the left and right buttocks.

There is green discoloration on the chest and abdomen. There is a 5-inch vertical surgical scar on the center of the upper abdomen and a 4-inch oblique incision on the right side of the abdomen.

The upper and lower extremities are symmetric and without clubbing or edema. There is a 1/8-inch scar on the right elbow. There is postmortem skin slippage on the left ankle. There is an orange/yellow post-mortem abrasion on the right hand.

CLOTHING AND PERSONAL EFFECTS

The following clothing items and personal effects are present on the body at the time of autopsy:

- A yellow jump-suit
- Two pairs of white briefs
- One white sock
- Wrapped in a green sheet

MEDICAL INTERVENTION

- Endotracheal Intubation
- Intravenous access (right forearm)

RADIOGRAPHS

A complete set of postmortem radiographs is obtained and demonstrates the following:

- Calcified coronary arteries
- Calcified external iliac and femoral arteries
- Internal fixation plate (right tibia)

ACLU Detainee DeathII ARMY MEDCOM 590

EVIDENCE OF INJURY

No significant injuries are identified.

INTERNAL EXAMINATION

HEAD:
The galeal and subgaleal soft tissues of the scalp are free of injury. The calvarium is intact, as is the dura mater beneath it. Clear cerebrospinal fluid surrounds the 1500-gram brain, which has unremarkable gyri and sulci. Coronal sections demonstrate sharp demarcation between white and grey matter, without hemorrhage or contusive injury. The ventricles are of normal size. The basal ganglia, brainstem, cerebellum, and arterial systems are free of injury or other abnormalities. There are no skull fractures. The atlanto-occipital joint is stable.

NECK:
The anterior strap muscles of the neck are homogenous and red-brown, without hemorrhage. The thyroid cartilage and hyoid are intact. The larynx is lined by intact white mucosa. The thyroid is symmetric and red-brown, without cystic or nodular change. The tongue is free of bite marks, hemorrhage, or other injuries.

BODY CAVITIES:
The ribs, sternum, and vertebral bodies are visibly and palpably intact. No excess fluid is in the pleural, pericardial, or peritoneal cavities. The organs occupy their usual anatomic positions.

RESPIRATORY SYSTEM:
The right and left lungs weigh 780 and 720-grams, respectively. The external surfaces are smooth and deep red-purple. The pulmonary parenchyma is diffusely congested and edematous. No mass lesions or areas of consolidation are present.

CARDIOVASCULAR SYSTEM:
The 770-gram heart is contained in an intact pericardial sac. The epicardial surface is smooth, with moderate fat investment. The coronary arteries are present in a normal distribution, with a right-dominant pattern. Cross sections of the vessels show 90% stenosis of the left anterior descending coronary artery, 75% stenosis of the left circumflex coronary artery and 75% stenosis of the right coronary artery by calcified atherosclerotic plaques. There is a 2.5-centimeter trans-mural tan-white fibrous scar in the anterior wall of the left ventricle that extends to the apex. The valve leaflets are thin and mobile. The walls of the left and right ventricles are 0.9 and 0.3-centimeters thick, respectively. The endocardium is smooth and glistening. The aorta gives rise to three intact and patent arch vessels and exhibits mild atherosclerosis. The renal and mesenteric vessels are unremarkable.

ACLU Detainee DeathII ARMY MEDCOM 591

LIVER & BILIARY SYSTEM:
The 1800-gram liver has an intact, smooth capsule and a sharp anterior border. The parenchyma is tan-brown and congested, with the usual lobular architecture. No mass lesions or other abnormalities are seen. The gallbladder is not identified and is replaced by numerous adhesions. The extrahepatic biliary tree is patent.

SPLEEN:
The 240-gram spleen is encased with numerous adhesions. The parenchyma is maroon and congested, with distinct Malpighian corpuscles.

PANCREAS:
The pancreas is firm and yellow-tan, with the usual lobular architecture. No mass lesions or other abnormalities are seen.

ADRENALS:
The right and left adrenal glands are symmetric, with bright yellow cortices and grey medullae. No masses or areas of hemorrhage are identified.

GENITOURINARY SYSTEM:
The right and left kidneys weigh 200 and 180-grams, respectively. The external surfaces are granular. The cut surfaces are red-tan and congested, with uniformly thick cortices and sharp corticomedullary junctions. The pelves are unremarkable and the ureters are normal in course and caliber. White bladder mucosa overlies an intact bladder wall. The bladder contains approximately 30-milliliters of clear yellow urine. The prostate is normal in size, with lobular, yellow-tan parenchyma. The seminal vesicles are unremarkable. The testes are free of mass lesions, contusions, or other abnormalities.

GASTROINTESTINAL TRACT:
The esophagus is intact and lined by smooth, grey-white mucosa. The stomach contains scant brown fluid. The gastric wall is intact. The duodenum, loops of small bowel, and colon are unremarkable. The appendix is not identified.

MICROSCOPIC EXAMINATION

Selected portions of organs are retained in formalin, without preparation of histologic slides.

ACLU Detainee DeathII ARMY MEDCOM 592

ADDITIONAL PROCEDURES

1. Documentary photographs are taken by OAFME staff photographers.
2. Full body radiographs are obtained. No blunt force or penetrating injuries are identified. No metallic foreign objects are identified.
3. Specimens retained for toxicology testing and/or DNA identification are: blood, vitreous fluid, urine, liver, spleen, brain, lung, kidney, muscle and adipose.
4. The dissected organs are forwarded with the body.
5. Personal effects are released to the appropriate mortuary operations representatives.
6. Identifying marks include: Two surgical scars on the abdomen.

OPINION

This 62 year-old male died of hypertrophic and arteriosclerotic cardiovascular disease. The heart weighed 770-grams. There was evidence of a remote myocardial infraction in the anterior wall of the left ventricle, significant pulmonary congestion and edema and benign nephrosclerosis. Cross sectioning of the coronary arteries exhibited 90% stenosis of the left anterior descending coronary artery, 75% stenosis of the left circumflex coronary artery and 75% stenosis of the right coronary artery by calcified atherosclerotic plaques. The abrasions of the left side of the face are consistent with injuries sustained during a terminal collapse. The toxicology screen is negative. The manner of death is natural.

(b)(6)

(b)(6) Medical Examiner

(b)(6)

(b)(6) Medical Examiner

ACLU Detainee DeathII ARMY MEDCOM 593

CERTIFICATE OF DEATH *(OVERSEAS)*
Acte de décès (D'Outre-Mer)

NAME OF DECEASED *(Last, First, Middle)* Nom du décédé (Nom et prénoms)	GRADE Grade	BRANCH OF SERVICE Arme	SOCIAL SECURITY NUMBER Numéro de l'Assurance Social
BTB Lohaybi, Monder Mahmoud, Abdulka		Civilian	(b)(6)

ORGANIZATION Organisation	NATION *(e.g. United States)* Pays	DATE OF BIRTH Date de naissance	SEX Sexe
	Iraq	(b)(6) 1944	[X] MALE [ ] FEMALE

RACE Race		MARITAL STATUS État Civil			RELIGION Culte		
	CAUCASOID Caucasique		SINGLE Célibataire		DIVORCED Divorcé		PROTESTANT Protestant		OTHER (Specify) Autre (Spécifier)
	NEGROID Negroide		MARRIED Marié		SEPARATED Séparé		CATHOLIC Catholique	X	
X	OTHER (Specify) Autre (Spécifier)		WIDOWED Veuf				JEWISH Juif		

NAME OF NEXT OF KIN Nom du plus proche parent	RELATIONSHIP TO DECEASED Parenté du décédé avec le sus
STREET ADDRESS Domicilé à (Rue)	CITY OR TOWN OR STATE *(Include ZIP Code)* Ville (Code postal compris)

MEDICAL STATEMENT Déclaration médicale

	CAUSE OF DEATH (Enter only one cause per line) Cause du décès (N'indiquer qu'une cause par ligne)	INTERVAL BETWEEN ONSET AND DEATH Intervalle entre l'attaque et le décès
DISEASE OR CONDITON DIRECTLY LEADING TO DEATH [1] Maladie ou condition directement responsable de la mort.	Hypertrophic Arteriosclerotic Cardiovascular Disease	
ANTECEDENT CAUSES — MORBID CONDITION, IF ANY, LEADING TO PRIMARY CAUSE Condition morbide, s'il y a lieu, menant à la cause primaire	History of Diabetes Mellitus and smoking	
Symptômes précurseurs de la mort — UNDERLYING CAUSE, IF ANY, GIVING RISE TO PRIMARY CAUSE Condition morbide, s'il y a lieu, menant à la cause primaire		
OTHER SIGNIFICANT CONDITIONS [2] Autres conditions significatives [2]		

MODE OF DEATH Condition de décès	AUTOPSY PERFORMED Autopsie effectuée	CIRCUMSTANCES SURROUNDING DEATH DUE TO EXTERNAL CAUSES Circonstances de la mort suscitées par des causes extérieures
X NATURAL Mort naturelle	[X] YES Oui [ ] NO Non	
ACCIDENT Mort accidentelle	MAJOR FINDINGS OF AUTOPSY Conclusions principales de l'autopsie	
SUICIDE Suicide	NAME OF PATHOLOGIST Nom du pathologiste: (b)(6)	
HOMICIDE Homicide	SIGNATURE Signature	DATE Date: 11 April 2006
		AVIATION ACCIDENT Accident à Avion: [ ] YES Oui [X] NO Non

DATE OF DEATH *(day, month, year)* Date du décès (le jour, le mois, l'année)	PLACE OF DEATH Lieu de décès
(b)(6) 2006	Iraq

I HAVE VIEWED THE REMAINS OF THE DECEASED AND DEATH OCCURRED AT THE TIME INDICATED AND FROM THE CAUSES AS STATED ABOVE.
J'ai examiné les restes mortels du dé funtet je conclus que le décès est survenu à l'heure indiquée et à, la suite des causes énumérées ci-dessus.

NAME OF MEDICAL OFFICER Nom du médicin militaire ou du médicin sanitaire	TITLE OR DEGREE Titre ou diplômé
(b)(6)	Medical Examiner

GRADE Grade	INSTALLATION OR ADDRESS Installation ou adresse
(b)(6)	Dover AFB, Dover DE
DATE Date	SIGNATURE Signature

[1] State disease, injury or complication which caused death, but not mode of dying such as heart failure, ect.
[2] State conditions contributing to the death, but not related to the disease or condition causing death.
[1] Préciser la nature de la maladie, de la blessure ou de la complication qui a contribué à la mort, mais non la manière de mourir, telle qu 'un arrêt du coeur; etc
[2] Préciser la condition qui a contribué à la mort, mais n'ayant aucun rapport avec la maladie ou à la condition qui a provoqué la mort.

DD FORM 1 APR 77 2064 REPLACES DA FORM 3565, 1 JAN 72 AND DA FORM 3565-R(PAS), 28 SEP 75, WHICH ARE OBSOLETE.

MEDCOM 0594

ACLU Detainee DeathII ARMY MEDCOM 594

ARMED FORCES INSTITUTE OF PATHOLOGY
Office of the Armed Forces Medical Examiner
1413 Research Blvd., Bldg. 102
Rockville, MD 20850
301-319-0000

FINAL AUTOPSY EXAMINATION REPORT

Name: BTB Daraj, Rasoul Jabal
ISN: (b)(6)
Date of Birth: (b)(6) 1981
Date of Death (b)(6) 2006
Date/Time of Autopsy: 29 March 2006/0900
Date of Report: 04 October 2006

Autopsy No. (b)(6)
AFIP No. (b)(6)
Rank: CIV
Place of Death: Iraq
Place of Autopsy: Port Mortuary
Dover AFB, Dover DE

Circumstances of Death: This 25 year old male civilian detainee reportedly sustained head injury as the result of an assault by fellow inmates.

Authorization for Autopsy: Office of the Armed Forces Medical Examiner, IAW 10 USC 1471

Identification: Presumptive, according to hospital band.

CAUSE OF DEATH: Complications of blunt force head injuries.

MANNER OF DEATH: Homicide.

FINAL AUTOPSY DIAGNOSES

I. Blunt force injuries:
   A. Injuries of the head and neck:
      1. Left-sided depressed skull fracture (per report).
      2. Subacute left-sided subdural hematoma.
      3. Subacute contusions in the left middle parietal and lateral occipital lobes.
      4. Multiple healing (sutured) lacerations of the left parietal, occipital and vertex regions of the scalp.
      5. Abrasion (1 inch) of the left lateral surface of the neck.
   B. Injuries of the torso:
      1. Fracture of the right acromion.
         a. Subcutaneous and intramuscular hemorrhage of the anterior surface of the right shoulder.
      2. Hemorrhage of the proximal portion of the right spermatic cord.
   C. Injuries of the extremities:
      1. Multiple healing (sutured) lacerations of the posterior surface of the left forearm.
      2. Healing lacerations (2) of the left lower leg.
      3. Multiple contusions of the right leg.

ACLU Detainee DeathII ARMY MEDCOM 595

II. Additional findings:
   A. Subacute meningocerebroventriculitis with early abscess formation.
   B. Multifocal acute to subacute cerebral infarcts.
   C. Diffuse acute hypoxic/ischemic neuronal injury.
   D. Status post left hemicraniectomy.
   E. Status post ventriculostomy placement.
   F. Bilateral pulmonary congestion (right 860 gm, left 740 gm).

III. Toxicology: Morphine and midazolam are present in the blood. Metoclopramide is present only in the urine.

ACLU Detainee DeathII ARMY MEDCOM 596

EXTERNAL EXAMINATION

The body is that of a well-developed, thin appearing male. The body weighs 133 pounds, is 68 inches in length and appears compatible with the reported age of 25 years. The body temperature is cool after refrigeration. Rigor is present to an equal degree in all extremities. Lividity is fixed and present predominately on the posterior surfaces of the body, except in areas exposed to pressure.

The scalp hair is black. A 15 inch curvilinear stapled incision extends from the left frontal region posteriorly through the right occipital region to the left temporal region, terminating just anterior to the left external ear. Facial hair consists of a black beard. The irides are brown. The corneae are cloudy. The conjuctivae are unremarkable. The sclerae are white. The external auditory canals, external nares and oral cavity are free of foreign material and abnormal secretions. The nasal skeleton is palpably intact. The teeth appear natural and in fair condition.

The neck is straight, and the trachea is midline and mobile. The chest is symmetric. No evidence of injury of the ribs or the sternum is evident externally. The abdomen is flat. A healing 5 inch vertical incision is present on the right side of the abdomen. The fingernails are intact. The extremities show evidence of injury to be described below. (b)(6) tattoo (b)(6) (b)(6) Multiple scars are present on the posterior surface of the left elbow (area 4 ½ x 2 inches) and the dorsal surface of the left hand (2 ¾ x 2 inches). The external genitalia are those of a normal adult male. The posterior torso is without note. The buttocks and anus are unremarkable.

EVIDENCE OF INJURY

Head and neck:

A healing, sutured 1 inch laceration is present in the right temporal region (posterior to right external ear) of the scalp. A healing 1 ½ inch laceration is present in the left parietal region of the scalp. There are multilple, healing confluent lacerations in the left occipital region of the scalp covering an area measuring 1 ¼ x 1 inch. There are multiple healing, sutured lacerations in the central vertex occipital region of the scalp, covering an area measuring 4 ½ x 2 ¼ inches. A linear 1 inch abrasion is on the left lateral surface of the neck. Internal examination reveals a left-sided subacute subdural hematoma.

Torso:

A ½ inch abrasion is present on the posterior surface of the left shoulder. There are multiple irregular healing lesions on the upper and lower back ranging in size from 1/8 to ¾ inch. Internal examination shows focal intramuscular and subcutaneous hemorrhage in the right upper chest and infraclavicular regions. There is hemorrhage in the region of the right spermatic cord.

Extremities:

There are multiple healing abrasions and sutured lacerations on the dorsal surface of the left upper arm and forearm covering an area measuring 2 ½ x 1 inch, ranging in size from 1/8 to ½ inch. A ¾ inch ill defined contusion is on the dorsal surface of the left wrist. There are multiple healing abrasions on the

ACLU Detainee DeathII ARMY MEDCOM 597

dorsal surface of the left hand and index finger ranging in size from 1/16 to 3/16 inch. A focal ¼ inch subcutaneous hematoma is present on the palmar surface of the left middle finger. Incision of the left wrist reveals focal subcutaneous hemorrhage in the ulnar region. There is a 6 x 3 inch discontinuous contusion on the anterior surface of the right lower leg. There are two healing lacerations on the medial surface of the left lower leg and the medial surface of the left ankle (¼ inch each).

EVIDENCE OF MEDICAL THERAPY

Evidence of medical therapy consists of:

1. Intracranial catheter with tubing and drainage bag.
2. Intravascular catheters in the left subclavian region, the right wrist and the left forearm.
3. A foley catheter.
4. Probable therapeutic puncture site on the dorsal surface of the right foot.
5. Status post left hemi-craniectomy with shunt catheter placement.
6. Left parietal portion of skull placed in abdomen.

INTERNAL EXAMINATION

HEAD:
(See above "Evidence of Medical Therapy" and "Evidence of Injury")

The staples are removed and the entire scalp is reflected. The posterior portion of the surgical flap (approximately 2 ¾ x 2 inches) is dark and appears devitalized. The remaining calvarium is removed. The 1720 gm brain is placed in fixative pending consultative review. No skull fractures are noted. The atlanto-occipital joint is stable.

NECK:
The anterior strap muscles of the neck are homogenous and red-brown, without hemorrhage. The thyroid cartilage and hyoid are intact. The larynx is lined by intact white mucosa. The thyroid is symmetric and red-brown, without cystic or nodular change. The tongue is free of bite marks, hemorrhage, or other injuries.

BODY CAVITIES:
The ribs, sternum, and vertebral bodies are visibly and palpably intact. No excess fluid is in the pericardial, pleural or peritoneal cavities. The organs occupy their usual anatomic positions. There is no internal evidence of blunt force or penetrating injury to the thoraco-abdominal region.

RESPIRATORY SYSTEM:
The right and left lungs weigh 860 gm and 740 gm, respectively. The external surfaces are smooth and deep red-purple. The pulmonary parenchyma is moderately congested and edematous. No mass lesions or areas of consolidation are present.

CARDIOVASCULAR SYSTEM:
The 460 gm heart is contained in an intact pericardial sac. The epicardial surface is smooth, with minimal fat investment. The coronary arteries arise normally, follow the usual distribution and are

ACLU Detainee DeathII ARMY MEDCOM 598

widely patent, without evidence of significant atherosclerosis or thrombosis. The myocardium is homogenous, red-brown, and firm; the atrial and ventricular septa are intact. The aorta gives rise to three intact and patent arch vessels. The vena cava and its major tributaries return to the heart in the usual distribution. The renal and mesenteric vessels are unremarkable.

LIVER & BILIARY SYSTEM:
The 1620 gm liver has an intact, smooth capsule and a sharp anterior border. The parenchyma is tan-brown and congested, with the usual lobular architecture. No mass lesions or other abnormalities are seen. The gallbladder contains approximately 5 ml of green-black bile and no stones. The mucosal surface is green and velvety. The extrahepatic biliary tree is patent.

SPLEEN:
The 170 gm spleen has a smooth, intact, red-purple capsule. The parenchyma is maroon and congested, with distinct Malpighian corpuscles.

PANCREAS:
The pancreas is firm and yellow-tan, with the usual lobular architecture. No mass lesions or other abnormalities are seen.

ADRENALS GLANDS:
The right and left adrenal glands are symmetric, with bright yellow cortices and grey medullae. No masses or areas of hemorrhage are identified.

GENITOURINARY SYSTEM:
The right and left kidneys weigh 170 gm and 160 gm, respectively. The external surfaces are intact and smooth. The cut surfaces are red-tan and congested, with uniformly thick cortices and sharp corticomedullary junctions. The pelves are unremarkable and the ureters are normal in course and caliber. Tan bladder mucosa overlies an intact bladder wall. The bladder is empty. The urine collection bag contains 200 ml of cloudy yellow urine. The prostate is normal in size, with lobular, yellow-tan parenchyma. The seminal vesicles are unremarkable. The testes are free of mass lesions, contusions, or other abnormalities.

GASTROINTESTINAL TRACT:
The esophagus is intact and lined by smooth, grey-white mucosa. The stomach contains approximately 250 ml of dark green liquid material. The gastric wall is intact. The duodenum, loops of small bowel, colon and appendix are unremarkable.

MUSCULOSKELETAL SYSTEM:
Muscle development is normal. No bone or joint abnormalities are noted.

CONSULTATIVE REPORT

Neuropathology Consultation:

The dura is remarkable for adherent surgical material and blood clot in the left frontoparietal region; two additional foci of subdural hemorrhage are noted in the right parietal region. Thick purulent

ACLU Detainee DeathII ARMY MEDCOM 599

exudates are identified on the surfaces of the cerebral hemispheres, on the basilar surface of the cerebrum, on the ventral surface of the midbrain and on the cerebellar vermis. A 1.5 x 1 cm soft area associated with an overlying purulent exudate is noted in the inferior left temporal lobe. Both cerebral hemispheres exhibit diffuse gyral flattening and sulcal narrowing. A 3.2 x 3 cm area of contusion and laceration is identified in the left superior parietal lobe. A similar 3 x 3 cm lesion is present in the lateral left occipital lobe. A white plastic catheter, 0.3 cm in diameter, is identified in the left middle frontal gyrus. The circle of Willis has a normal adult configuration without aneurysms, significant atherosclerosis, or occlusions.

Coronal sections of the cerebrum show a cortical ribbon of normal thickness, well demarcated from subjacent white matter. There is a diffuse dusk discoloration of the cerebral cortex. The left parietal and occipital lobe contusions are confirmed; subjacent wedge-shaped hemorrhagic infarcts, extending up to 4 cm into the white matter, are associated with each contusion. The brain is edematous and soft. A slight right to left shift is identified that focally compresses the right ventricular system more than the left. Definite cingulate gyrus herniation is not identified. The ventricular system is filled with a purulent exudate with the left side containing more than the right. The shunt catheter is noted within the ventricular system. The basal ganglia, thalami, and hypothalamus are unremarkable. Other than the previously described purulent exudate, transverse sections of the cerebellum and brainstem are unremarkable. The substantia nigra and locus ceruleus are normally pigmented for age. The aqueduct is slit-like. The spinal cord is not submitted, but the uppermost cervical cord and cervicomedullary junction are unremarkable.

Microscopic sections of meninges demonstrate patchy acute and chronic inflammation with multifocal abscess formation; several leptomeningeal vessels have inflammatory cells within their walls, consistent with a secondary vasculitis. Foci of hemorrhage, surgical material, and granulation tissue are also noted in the leptomeninges. Extensive perivascular and parenchymal acute/chronic inflammation and gliosis are present in several regions of the cerebrum. A large collection of neutrophils associated with necrosis is noted in the section from the left parietal periventricular region, consistent with early abscess formation. Special stains for microorganisms reveal a mixture of short gram-positive coccobacilli and acid-fast bacteria that are interpreted as contaminants. Multiple foci of rarefaction, vacuolation, lipid-and hemosiderin-laden macrophages, hypereosinophilic neurons, acute hemorrhage and subacute inflammation are identified, consistent with multifocal acute to subacute cerebral and pontine infarcts. Numerous hypereosinophilic neurons are identified in the cerebral cortex, deep gray matter, hippocampus, brainstem, and cerebellum consistent with diffuse acute hypoxic/ischemic neuronal injury. The subdural hemorrhage consists of intact and degenerating erythrocytes adjacent to the dura matter and a well-formed fibrous layer on the arachnoid side. Many pigment-laden macrophages are present. These changes are consistent with a subacute subdural hematoma.

In summary, the above changes are consistent with a subacute meningocerebroventriculitis with early abscess formation, subacute contusions in the left middle parietal and lateral occipital lobes, multifocal acute to subacute infarcts, diffuse acute hypoxic/ischemic neuronal injury, and a left subacute subdural hematoma; the subdural most likely occurred at the time of initial trauma with a secondary component occurring as a result of medical intervention.

ACLU Detainee DeathII ARMY MEDCOM 600

RADIOLOGIC EXAMINATION

Full body radiographs are obtained revealing, in addition to above, fracture of the acromion of the right scapula. No evidence of non-therapeutic metallic foreign bodies is identified.

ADDITIONAL PROCEDURES

- Documentary photographs are taken by the OAFME staff photographers.
- Specimens retained for toxicologic testing and/or DNA identification are: blood, bile, gastric contents, urine, vitreous, lung, liver, kidney, spleen, adipose tissue and psoas muscle.
- Selected portions of organs are retained in formalin.
- Personal effects are released to the appropriate mortuary operations representatives.

OPINION

According to reports this 25 year old male detainee sustained a depressed skull fracture as the result of an assault by fellow inmates. During his hospitalization, he underwent a left-sided craniectomy for decompression followed by placement of an intraventricular cathether for subsequent hydrocephalus. His clinical course was complicated by gram negative meningitis and multiple cerebral infarcts. He ultimately sucuumbed to complications of his head injuries on his 13th hospital day. Postmortem toxicological examination showed only the presence of the therapeutic agents morphine (blood 0.63 mg/L), midazolam (blood 0.09 mg/L) and metoclopramide (detected in urine only). The manner of death is homicide.

This case was reviewed in consultation with Department of Neuropathology. Their written consultation is incorporated into the above report.

(b)(6)

(b)(6) Medical Examiner

ACLU Detainee DeathII ARMY MEDCOM 601

CERTIFICATE OF DEATH *(OVERSEAS)*

Acte de décès (D'Outre-Mer)

NAME OF DECEASED (Last, First, Middle) Nom du décédé (Nom et prénoms)	GRADE Grade	BRANCH OF SERVICE Arme	SOCIAL SECURITY NUMBER Numéro de l'Assurance Sociale
BTB Daraj, Rasoul, Jabal		Civilian	(b)(6)
ORGANIZATION Organisation	**NATION** (e.g. United States) Pays: Iraq	**DATE OF BIRTH** Date de naissance: (b)(6) 1981	**SEX** Sexe: [X] MALE [ ] FEMALE

RACE Race		MARITAL STATUS État Civil			RELIGION Culte		
[ ]	CAUCASOID Caucasique	[ ]	SINGLE Célibataire	[ ] DIVORCED Divorcé	[ ]	PROTESTANT Protestant	[X] OTHER (Specify) Autre (Spécifier)
[ ]	NEGROID Negroïde	[ ]	MARRIED Marié	[ ] SEPARATED Séparé	[ ]	CATHOLIC Catholique	
[X]	OTHER (Specify) Autre (Spécifier)	[ ]	WIDOWED Veuf		[ ]	JEWISH Juif	

NAME OF NEXT OF KIN Nom du plus proche parent	RELATIONSHIP TO DECEASED Parenté du décédé avec le sus
STREET ADDRESS Domicile à (Rue)	CITY OR TOWN OR STATE (Include ZIP Code) Ville (Code postal compris)

MEDICAL STATEMENT Déclaration médicale

CAUSE OF DEATH (Enter only one cause per line) Cause du décès (N'indiquer qu'une cause par ligne)			INTERVAL BETWEEN ONSET AND DEATH Intervalle entre l'attaque et le décès
DISEASE OR CONDITON DIRECTLY LEADING TO DEATH [1] Maladie ou condition directement responsable de la mort		Complications of blunt force head injuries	
ANTECEDENT CAUSES Symptômes précurseurs de la mort	MORBID CONDITION, IF ANY, LEADING TO PRIMARY CAUSE Condition morbide, s'il y a lieu, menant à la cause primaire		
	UNDERLYING CAUSE, IF ANY, GIVING RISE TO PRIMARY CAUSE Condition morbide, s'il y a lieu, menant à la cause primaire		
OTHER SIGNIFICANT CONDITIONS [2] Autres conditions significatives [3]			

MODE OF DEATH Condition de décès	AUTOPSY PERFORMED Autopsie effectuée [X] YES Oui [ ] NO Non	CIRCUMSTANCES SURROUNDING DEATH DUE TO EXTERNAL CAUSES Circonstances de la mort ausortées par des causes extérieures
[ ] NATURAL Mort naturelle	MAJOR FINDINGS OF AUTOPSY Conclusions principales de l'autopsie	
[ ] ACCIDENT Mort accidentelle		
[ ] SUICIDE Suicide	NAME OF PATHOLOGIST Nom du pathologiste: (b)(6)	
[X] HOMICIDE Homicide	SIGNATURE: (b)(6) DATE Date: 29 March 2006	AVIATION ACCIDENT Accident d'Avion [ ] YES Oui [X] NO Non

DATE OF DEATH (day, month, year) Date de décès (le jour, le mois, l'année)	PLACE OF DEATH Lieu de décès
(b)(6) 2006	Iraq

I HAVE VIEWED THE REMAINS OF THE DECEASED AND DEATH OCCURRED AT THE TIME INDICATED AND FROM THE CAUSES AS STATED ABOVE.
J'ai examiné les restes mortels du défunt je conclus que le décès est survenu à l'heure indiquée et à la suite des causes énumérées ci-dessus

NAME OF MEDICAL OFFICER Nom du médecin militaire ou du médecin sanitaire	TITLE OR DEGREE Titre ou diplôme
(b)(6)	Medical Examiner

GRADE Grade	INSTALLATION OR ADDRESS Installation ou adresse
(b)(6)	Dover AFB, Dover DE
DATE Date: 4/17/06	SIGNATURE: (b)(6)

[1] State disease, injury or complication which caused death, but not mod
[2] State conditions contributing to the death, but not related to the disease or condition causing death.
[3] Préciser la nature de la maladie, de la blessure ou de la complication qui a contribué à la mort, mais n'ayant aucun rapport avec la maladie ou la condition qui a provoqué la mort.

DD FORM 1 APR 77 2064 REPLACES DA FORM 3566, 1 JAN 72 AND DA FORM 3565-R(PAS), 26 SEP 75, WHICH ARE OBSOLETE.

ACLU Detainee DeathII ARMY MEDCOM 602

ARMED FORCES INSTITUTE OF PATHOLOGY
Office of the Armed Forces Medical Examiner
1413 Research Blvd., Bldg. 102
Rockville, MD 20850
1-301-319-0000

AUTOPSY EXAMINATION REPORT

Name: BTB Muhyi, Talib, Umar
ISN: (b)(6)
Date of Birth: (b)(6) 1982
Date of Death: (b)(6) 2006
Date/Time of Autopsy: 25 MAR 2006 @ 1100 hrs
Date of Report: 19 MAY 2006

Autopsy No.: (b)(6)
AFIP No.: (b)(6)
Rank: Detainee
Place of Death: Iraq
Place of Autopsy: Port Mortuary, Dover AFB, DE

Circumstances of Death: This 24 year-old detainee was, as reported, noted to have decreased urine output at about 1315 hrs, (b)(6) 2006. The detainee was transported by ambulance to the 344TH Emergency Trauma Room by ambulance. He arrived not breathing and his pupils were fixed and dilated. He had a past medical history significant for poorly controlled Type I diabetes mellitus (HgBA1C=10.4%). Despite treatment provided the detainee expired.

Authorization for Autopsy: Office of the Armed Forces Medical Examiner, IAW 10 USC 1471

Identification: Circumstantial identification by examination of accompanying paperwork.

CAUSE OF DEATH: Complications of Diabetes Mellitus (Diabetic Ketoacidosis)

MANNER OF DEATH: Natural

ACLU Detainee DeathII ARMY MEDCOM 603

FINAL AUTOPSY DIAGNOSIS

I. Renal System:
   - A. Glomerular changes consistent with diffuse diabetic glomerulosclerosis.
   - B. Hyaline arteriolosclerosis.
   - C. Severe autolysis.

II. Cardiovascular System:
   - A. Morphologically normal heart (Heart Weight – 310-grams)

III. Pulmonary System:
   - A. Pulmonary Congestion and Edema (Lung Weights: Right – 690-grams; Left – 670-grams)
   - B. Bilateral Serous Pleural Effusions (Right – 50-milliliters; Left – 50-milliliters)

IV. Hepatobilliary System:
   - A. Liver:
     1. Congestion
     2. Mild steatosis
     3. Increased lipofuscin pigment

V. Endocrine System:
   - A. Adrenal: No pathologic disease
   - B. Pancreas: Focal periductal fibrosis and autolysis

VI. Serous Ascites: 100-milliliters

VII. No significant injuries are identified.

VIII. Minor Injuries: Abrasion of the left side of the face, ¼-inch

IX. Toxicology (AFIP):
   - A. CARBON MONOXIDE: The Carboxyhemoglobin saturation in the blood is less than 1%.
   - B. CYANIDE: There is no cyanide detected in the blood.
   - C. VOLATILES: Acetone and 2-propanol are detected in the blood and vitreous fluid (concentrations in mg/dL).

	Actetone	2-Propanol
Blood	29	17
Vitreous Fluid	42	Trace

   - D. DRUGS: No screened drugs of abuse or medications are detected in the urine.

X. Vitreous Electrolytes (WRAMC): Sodium – 115 mmol/L, Potasium – not able to obtain results, Chloride – 88 mmol/L, Glucose – 10 mg/dL, BUN 37 mg/dL and Creatinine 11.0 mg/dL

ACLU Detainee DeathII ARMY MEDCOM 604

EXTERNAL EXAMINATION

The body is that of a well-developed, well-nourished appearing, 66-inch tall, 140-pounds male whose appearance is consistent with the reported age of 24-years. Lividity is present on the posterior surface of the body except in areas exposed to pressure. Rigor is passing and present only in the lower extremities.

The scalp is covered with brown hair in a normal distribution. Facial hair consists of a moustache and beard. The irides are brown, and the pupils are round and equal in diameter. The external auditory canals and ears are unremarkable. The nares are patent and the lips are atraumatic. The nose and maxillae are palpably stable. The teeth appear natural.

The neck is straight, and the trachea is midline and mobile. The chest is symmetric. The abdomen is flat. The genitalia are those of a normal adult male. The testes are descended and free of masses. Pubic hair is present in a normal distribution. The buttocks and anus are unremarkable.

The upper and lower extremities are symmetric and without clubbing or edema.

The skin of the hands and feet is wrinkled.

CLOTHING AND PERSONAL EFFECTS

The following clothing items and personal effects are present on the body at the time of autopsy:

- Yellow jump suit (wet)
- Tan shirt (cut down the front and wet))

MEDICAL INTERVENTION

- Nasogastric tube in the left nostril
- Endotracheal intubation
- One EKG lead on the torso
- Intravenous access in the right antecubital fossa
- A needle puncture on the right wrist

RADIOGRAPHS

A complete set of postmortem radiographs is obtained and demonstrates the following:

- No blunt force or penetrating injuries are identified

EVIDENCE OF INJURY

No significant injuries are identified. There is no evidence of blunt force or penetrating injuries of the torso or extremities. There are no significant blunt force or penetrating injuries of the head and neck. There is no evidence of torture.
Minor Injury: There is a 1/4 –inch abrasion of the left side of the face.

ACLU Detainee DeathII ARMY MEDCOM 605

INTERNAL EXAMINATION

HEAD:
The galeal and subgaleal soft tissues of the scalp are free of injury. The calvarium is intact, as is the dura mater beneath it. Clear cerebrospinal fluid surrounds the 1400-gram brain, which has unremarkable gyri and sulci. Coronal sections demonstrate sharp demarcation between white and grey matter, without hemorrhage or contusive injury. The ventricles are of normal size. The basal ganglia, brainstem, cerebellum, and arterial systems are free of injury or other abnormalities. There are no skull fractures. The atlanto-occipital joint is stable.

NECK:
The anterior strap muscles of the neck are homogenous and red-brown, without hemorrhage. The thyroid cartilage and hyoid are intact. The larynx is lined by intact white mucosa. The thyroid is symmetric and red-brown, without cystic or nodular change. The tongue is free of bite marks, hemorrhage, or other injuries.

BODY CAVITIES:
The ribs, sternum, and vertebral bodies are visibly and palpably intact. There is 50-milliliters of serous fluid in both chest cavities and 100-milliliters of serous ascites. The organs occupy their usual anatomic positions.

RESPIRATORY SYSTEM:
The right and left lungs weigh 690 and 670-grams, respectively. The external surfaces are smooth and deep red-purple. The pulmonary parenchyma is diffusely congested and edematous. No mass lesions or areas of consolidation are present.

CARDIOVASCULAR SYSTEM:
The 310-gm heart is contained in an intact pericardial sac. The epicardial surface is smooth, with minimal fat investment. The aorta gives rise to three intact and patent arch vessels. The renal and mesenteric vessels are unremarkable. (See Cardiovascular Pathology Consultation Report)

LIVER & BILIARY SYSTEM:
The 1540-gram liver has an intact, smooth capsule and a sharp anterior border. The parenchyma is tan-brown and congested, with the usual lobular architecture. No mass lesions or other abnormalities are seen. The gallbladder contains 20-milliliters of green-black bile and no stones. The mucosal surface is green and velvety. The extrahepatic biliary tree is patent.

SPLEEN:
The 80-gram spleen has a smooth, intact, red-purple capsule. The parenchyma is maroon and congested, with distinct Malpighian corpuscles.

ACLU Detainee DeathII ARMY MEDCOM 606

PANCREAS:
The pancreas is soft, tan and is moderately decomposed. No mass lesions or other abnormalities are seen.

ADRENALS:
The right and left adrenal glands are symmetric, with bright yellow cortices and grey medullae. No masses or areas of hemorrhage are identified.

GENITOURINARY SYSTEM:
The right and left kidneys weigh 190 and 180-grams, respectively. The external surfaces are intact and slightly granular in appearance. The cut surfaces are red-tan and congested, with uniformly thick cortices and sharp corticomedullary junctions. The pelves are unremarkable and the ureters are normal in course and caliber. White bladder mucosa overlies an intact bladder wall. The bladder contains approximately 280-milliliters of clear yellow urine. The prostate is normal in size, with lobular, yellow-tan parenchyma. The seminal vesicles are unremarkable. The testes are free of mass lesions, contusions, or other abnormalities.

GASTROINTESTINAL TRACT:
The esophagus is intact and lined by smooth, grey-white mucosa. The stomach contains approximately 100-milliliters of brown fluid. The gastric wall is intact. The duodenum, loops of small bowel, and colon are unremarkable. The appendix is present.

HEPATOPATHOLOGY CONSULTATION

13 April 2006
Liver: Congestion, mild steatosis, increased lipofuscin pigment. There is nothing to suggest any significant liver disease.
(b)(6)

ENDOCRINE PATHOLOGY CONSULTATION

14 April 2006
Adrenal: No pathologic disease.
Pancreas: Pancreas is mostly autolytic. In the areas in which the tissue is not involved *(by autolysis)* there are no significant abnormalities. There is focal peri-ductal fibrosis. This finding is not related to his clinical condition.
(b)(6)

ACLU Detainee DeathII ARMY MEDCOM 607

RENAL PATHOLOLOGY CONSULTATION

24 April 2006
Kidneys:

1. Glomerular changes consistent with diffuse diabetic glomerulosclerosis. The capillary walls are thick; special stains and EM may exclude immune complex glomerulonephritis (membranous glomerulonephritis).
2. Hyaline arteriolosclerosis.
3. Severe autolysis.

In view of the clinical data (Type I diabetes) the glomerular and vascular changes are consistent with diabetes.

(b)(6)

CARIOVASCULAR PATHOLOGY CONSULTATION

28 April 2006
DIAGNOSIOS: (b)(6) Morphologically normal heart

History: 24 year old Iraqi detainee with Type I diabetes and reported decreased urine output; transported to emergency room, arrived in full arrest and could not be resuscitated

Heart: 310-grams; normal epicardial fat; probe patent foramen ovale; normal left ventricular chamber dimensions; left ventricular cavity diameter 30-millimeters, left ventricular free wall thickness 10-millimeters, ventricular septum thickness 13-millimeters; right ventricular dilation: right ventricle thickness 3-millimeters, without gross scars or fat infiltrates; grossly normal valves and endocardium; no gross myocardial fibrosis or necrosis; histologic sections show focal epicardial and subepicardial lymphocytic infiltrates in the anterior and lateral left ventricle without myocyte necrosis or scarring, and a single small focus of subendocardial replacement fibrosis in the lateral left ventricle

Coronary arteries: Normal ostia; left dominance; no gross Atherosclerosis

Conduction system: The sinoatrial node and sinus nodal artery are unremarkable. The compact atrioventricular (AV) node is intact without inflammation, increased fat or vascularity. The penetrating bundle is centrally located within the fibrous body and is unremarkable. The proximal left bundle branch is intact; the right bundle branch is not seen in the section. There are no discrete bypass tracts between the AV node and ventricular septum. The AV nodal artery and its branches show no dysplasia.

Comment: The significance of a small focus of subepicardial chronic inflammation is unknown, as is a single focus of subendocardial fibrosis. In the absence of any other demonstrable cause of death, arrythmia on the basis of coronary vasospasm or ion channelopathy cannot be excluded.

(b)(6)
Cardiovascular Pathologist

ACLU Detainee DeathII ARMY MEDCOM 608

MICROSCOPIC EXAMINATION

- Liver: congestion, mild steatosis, increased lipofuscin pigment
- Adrenal: representative sections are histologically unremarkable
- Pancreas: extensive autolysis with focal peri-ductal fibrosis
- Kidneys: extensive autolysis with hyaline arteriolosclerosis and glomerular capillary basement membrane thickening
- Spleen: congestion, otherwise histologically unremarkable
- Lungs: multiple representative sections show vascular congestion and mild focal anthracotic pigment deposition, focal atelectasis, focal hemorrhage without hemosiderin laden macrophages (likely artefact)
- Brain: representative sections are histologically unremarkable

ADDITIONAL PROCEDURES

1. Documentary photographs are taken by OAFME staff photographers.
2. Full body radiographs are obtained and demonstrate no injuries.
3. Specimens retained for toxicology testing and/or DNA identification are: blood, vitreous, urine, bile, liver, spleen, brain, kidney, lung, adipose tissue, muscle and gastric contents
4. The dissected organs are forwarded with the body.
5. Selected portions of organs are retained in formalin.
7. Identifying marks include: Scars on the left foot and left knee.

ACLU Detainee DeathII ARMY MEDCOM 609

OPINION

This 24 year old male died of complications of diabetes mellitus (diabetic ketoacidosis). The deceased had a medical history significant for poorly controlled Type I diabetes and there was a clinical impression of diabetic ketoacidosis in Iraq. The kidneys exhibited changes that are consistent with a history of diabtetes. The heart was morphologically normal. There was no evidence of significant physical injury. The toxicology screen was significant for acetone in the blood (29-mg/dL) and vitreous fluid (42-mg/dL) and 2-propanol in the blood (17-mg/dL) and vitreous fluid (trace). The vitreous glucose was 10-mg/dL and this level was most likely effected by post-mortem metabolism. The remainder of the toxicology screen is negative. There were no significant physical injuries identified at autopsy. The manner of death is natural (b)(6)

(b)(6)

(b)(6) **Medical Examiner**

(b)(6)

(b)(6) **Medical Examiner** (b)(6)

ACLU Detainee DeathII ARMY MEDCOM 610

DEPARTMENT OF DEFENSE
ARMED FORCES INSTITUTE OF PATHOLOGY
WASHINGTON, DC 20306-6000

REPLY TO ATTENTION OF

AFIP (b)(6)

TO:

OFFICE OF THE ARMED FORCES MEDICAL EXAMINER
ARMED FORCES INSTITUTE OF PATHOLOGY
WASHINGTON, DC 20306-6000

PATIENT IDENTIFICATION
AFIP Accessions Number Sequence (b)(6)
Name MUHYI, TALIB UMAR
SSAN: **Autopsy:** (b)(6)
Toxicology Accession #: (b)(6)
Date Report Generated: April 3, 2006

CONSULTATION REPORT ON CONTRIBUTOR MATERIAL

AFIP DIAGNOSIS **REPORT OF TOXICOLOGICAL EXAMINATION**

Condition of Specimens: GOOD
Date of Incident: **Date Received:** 3/30/2006

CARBON MONOXIDE: The carboxyhemoglobin saturation in the blood was less than 1% as determined by spectrophotometry with a limit of quantitation of 1%. Carboxyhemoglobin saturations of 0-3% are expected for non-smokers and 3-10% for smokers. Saturations above 10% are considered elevated and are confirmed by gas chromatography.

CYANIDE: There was no cyanide detected in the blood. The limit of quantitation for cyanide is 0.25 mg/L. Normal blood cyanide concentrations are less than 0.15 mg/L. Lethal concentrations of cyanide are greater than 3 mg/L.

VOLATILES: The **BLOOD AND VITREOUS FLUID** were examined for the presence of ethanol (cutoff of 20 mg/dL), acetaldehyde, acetone, 2-propanol, 1-propanol, t-butanol, 2-butanol, iso-butanol and 1-butanol by headspace gas chromatography. The following volatiles were detected: (concentration(s) in mg/dL)

	Acetone	2-Propanol
BLOOD	29	17
VITREOUS FLUID	42	Trace

Trace = value greater than or equal to 1mg/dL, but less than 5 mg/dL

ACLU Detainee DeathII ARMY MEDCOM 611

DEPARTMENT OF DEFENSE
ARMED FORCES INSTITUTE OF PATHOLOGY
WASHINGTON, DC 20306-6000

REPLY TO
ATTENTION OF

REPORT OF TOXICOLOGICALM EXAMINATION (CONT – MUHYI, TALIB UMAR):

DRUGS: The **URINE** was screened for acetaminophen, amphetamine, antidepressants, antihistamines, barbiturates, benzodiazepines, cannabinoids, chloroquine, cocaine, dextromethorphan, lidocaine, narcotic analgesics, opiates, phencyclidine, phenothiazines, salicylates, sympathomimetic amines and verapamil by gas chromatography, color test or immunoassay. The following drugs were detected:

None were found.

(b)(6)

Office of the Armed Forces Medical Examiner

(b)(6)

Office of the Armed Forces Medical Examiner

ACLU Detainee DeathII ARMY MEDCOM 612

CERTIFICATE OF DEATH *(OVERSEAS)*
Acte de décès (D'Outre-Mer)

NAME OF DECEASED *(Last, First, Middle)* Nom du décédé (Nom et prénoms)	GRADE Grade	BRANCH OF SERVICE Arme	SOCIAL SECURITY NUMBER Numéro de l'Assurance Social
BTB Muhyi, Talib, Umar		Civilian	(b)(6)
ORGANIZATION Organisation	NATION *(e.g. United States)* Pays: Iraq	DATE OF BIRTH Date de naissance	SEX Sexe: [X] MALE [ ] FEMALE

RACE Race		MARITAL STATUS Etat Civil			RELIGION Culte		
	CAUCASOID Caucasique		SINGLE Célibataire		DIVORCED Divorcé		PROTESTANT Protestant
	NEGROID Negrode		MARRIED Marié		SEPARATED Séparé		CATHOLIC Catholique
X	OTHER (Specify) Autre (Spécifier)		WIDOWED Veuf				JEWISH Juif
						X	OTHER (Specify) Autre (Spécifier)

NAME OF NEXT OF KIN Nom du plus proche parent	RELATIONSHIP TO DECEASED Parenté du décédé avec le sus
STREET ADDRESS Domicilé à (Rue)	CITY OR TOWN OR STATE *(Include ZIP Code)* Ville (Code postal compris)

MEDICAL STATEMENT Déclaration médicale

CAUSE OF DEATH (Enter only one cause per line) Cause du décès (N'indiquer qu'une cause par ligne)		INTERVAL BETWEEN ONSET AND DEATH Intervalle entre l'attaque et le décès
DISEASE OR CONDITON DIRECTLY LEADING TO DEATH[1] Maladie ou condition directement responsable de la mort[1]	Complications of Diabetes Mellitis (Diabetic Ketoacidosis)	
ANTECEDENT CAUSES Symptômes précurseurs de la mort — MORBID CONDITION, IF ANY, LEADING TO PRIMARY CAUSE Condition morbide, s'il y a lieu menant à la cause primaire		
UNDERLYING CAUSE, IF ANY, GIVING RISE TO PRIMARY CAUSE Condition morbide, s'il y a lieu menant à la cause primaire		
OTHER SIGNIFICANT CONDITIONS[2] Autres conditions significatives[2]		

MODE OF DEATH Condition de décès	AUTOPSY PERFORMED Autopsie effectuée [X] YES Oui [ ] NO Non	CIRCUMSTANCES SURROUNDING DEATH DUE TO EXTERNAL CAUSES Circonstances de la mort suscitées par des causes extérieures
X NATURAL Mort naturelle	MAJOR FINDINGS OF AUTOPSY Conclusions principales de l'autopsie	
ACCIDENT Mort accidentelle		
SUICIDE Suicide	NAME OF PATHOLOGIST Nom du pathologiste (b)(6)	
HOMICIDE Homicide	(b)(6) DATE Date 25 March 2006	AVIATION ACCIDENT Accident à Avion [ ] YES Oui [X] NO Non

DATE OF DEATH *(day, month, year)* Date de décès *(le jour, le mois, l'année)*	PLACE OF DEATH Lieu de décès
(b)(6) 2006	

I HAVE VIEWED THE REMAINS OF THE DECEASED AND DEATH OCCURRED AT THE TIME INDICATED AND FROM THE CAUSES AS STATED ABOVE
J'ai examiné les restes mortels du dé funtet je conclus que le décès est survenu à l'heure indiquée et à la suite des causes énumérées ci-dessus

NAME OF MEDICAL OFFICER Nom du médecin métaire ou du médecin sanitaire	TITLE OR DEGREE Titre ou diplômé
(b)(6)	Medical Examiner

GRADE Grade	INSTALLATION OR ADDRESS Installation ou adresse
(b)(6)	Dover AFB, Dover DE
DATE Date 05 Oct 06	(b)(6)

[1] State disease, injury or complication which caused dea
[2] State conditions contributing to the death, but not related to the disease or condition causing death
[1] Préciser la nature de la maladie, de la blessure ou de la complication qui a contribué à la mort, mais non la manière de mourir telle qu'un arrêt du coeur, etc
[2] Préciser la condition qui a contribué à la mort, mais n'ayant aucun rapport avec la maladie ou à la condition qui a provoqué la mort

DD FORM 1 APR 77 2064 REPLACES DA FORM 3565, 1 JAN 72 AND DA FORM 3565-R(PAS), 26 SEP 75, WHICH ARE OBSOLETE.

ARMED FORCES INSTITUTE OF PATHOLOGY
Office of the Armed Forces Medical Examiner
1413 Research Blvd., Bldg. 102
Rockville, MD 20850
1-301-319-0000

AUTOPSY EXAMINATION REPORT

Name: BTB Muhyi, Talib, Umar
ISN: (b)(6)
Date of Birth: (b)(6) 1982
Date of Death (b)(6) 2006
Date/Time of Autopsy: 25 MAR 2006 @ 1100 hrs
Date of Report: 19 MAY 2006

Autopsy No.: (b)(6)
AFIP No.: (b)(6)
Rank: Detainee
Place of Death: Iraq
Place of Autopsy: Port Mortuary, Dover AFB, DE

Circumstances of Death: This 24 year-old detainee was, as reported, noted to have decreased urine output at about 1315 hrs (b)(6) 2006. The detainee was transported by ambulance to the 344TH Emergency Trauma Room by ambulance. He arrived not breathing and his pupils were fixed and dilated. He had a past medical history significant for poorly controlled Type I diabetes mellitus (HgBA1C=10.4%). Despite treatment provided the detainee expired.

Authorization for Autopsy: Office of the Armed Forces Medical Examiner, IAW 10 USC 1471

Identification: Circumstantial identification by examination of accompanying paperwork.

CAUSE OF DEATH: Complications of Diabetes Mellitus (Diabetic Ketoacidosis)

MANNER OF DEATH: Natural

ACLU Detainee DeathII ARMY MEDCOM 614

FINAL AUTOPSY DIAGNOSIS

I. Renal System:
   A. Glomerular changes consistent with diffuse diabetic glomerulosclerosis.
   B. Hyaline arteriolosclerosis.
   C. Severe autolysis.

II. Cardiovascular System:
   A. Morphologically normal heart (Heart Weight – 310-grams)

III. Pulmonary System:
   A. Pulmonary Congestion and Edema (Lung Weights: Right – 690-grams; Left – 670-grams)
   B. Bilateral Serous Pleural Effusions (Right – 50-milliliters; Left – 50-milliliters)

IV. Hepatobilliary System:
   A. Liver:
      1. Congestion
      2. Mild steatosis
      3. Increased lipofuscin pigment

V. Endocrine System:
   A. Adrenal: No pathologic disease
   B. Pancreas: Focal periductal fibrosis and autolysis

VI. Serous Ascites: 100-milliliters

VII. No significant injuries are identified.

VIII. Minor Injuries: Abrasion of the left side of the face, ¼-inch

IX. Toxicology (AFIP):
   A. CARBON MONOXIDE: The Carboxyhemoglobin saturation in the blood is less than 1%.
   B. CYANIDE: There is no cyanide detected in the blood.
   C. VOLATILES: Acetone and 2-propanol are detected in the blood and vitreous fluid (concentrations in mg/dL).

	Actetone	2-Propanol
Blood	29	17
Vitreous Fluid	42	Trace

   D. DRUGS: No screened drugs of abuse or medications are detected in the urine.

X. Vitreous Electrolytes (WRAMC): Sodium – 115 mmol/L, Potasium – not able to obtain results, Chloride – 88 mmol/L, Glucose – 10 mg/dL, BUN 37 mg/dL and Creatinine 11.0 mg/dL

ACLU Detainee DeathII ARMY MEDCOM 615

EXTERNAL EXAMINATION

The body is that of a well-developed, well-nourished appearing, 66-inch tall, 140-pounds male whose appearance is consistent with the reported age of 24-years. Lividity is present on the posterior surface of the body except in areas exposed to pressure. Rigor is passing and present only in the lower extremities.

The scalp is covered with brown hair in a normal distribution. Facial hair consists of a moustache and beard. The irides are brown, and the pupils are round and equal in diameter. The external auditory canals and ears are unremarkable. The nares are patent and the lips are atraumatic. The nose and maxillae are palpably stable. The teeth appear natural.

The neck is straight, and the trachea is midline and mobile. The chest is symmetric. The abdomen is flat. The genitalia are those of a normal adult male. The testes are descended and free of masses. Pubic hair is present in a normal distribution. The buttocks and anus are unremarkable.

The upper and lower extremities are symmetric and without clubbing or edema.

The skin of the hands and feet is wrinkled.

CLOTHING AND PERSONAL EFFECTS

The following clothing items and personal effects are present on the body at the time of autopsy:

- Yellow jump suit (wet)
- Tan shirt (cut down the front and wet))

MEDICAL INTERVENTION

- Nasogastric tube in the left nostril
- Endotracheal intubation
- One EKG lead on the torso
- Intravenous access in the right antecubital fossa
- A needle puncture on the right wrist

RADIOGRAPHS

A complete set of postmortem radiographs is obtained and demonstrates the following:

- No blunt force or penetrating injuries are identified

EVIDENCE OF INJURY

No significant injuries are identified. There is no evidence of blunt force or penetrating injuries of the torso or extremities. There are no significant blunt force or penetrating injuries of the head and neck. There is no evidence of torture.
Minor Injury: There is a 1/4 –inch abrasion of the left side of the face.

ACLU Detainee DeathII ARMY MEDCOM 616

INTERNAL EXAMINATION

HEAD:
The galeal and subgaleal soft tissues of the scalp are free of injury. The calvarium is intact, as is the dura mater beneath it. Clear cerebrospinal fluid surrounds the 1400-gram brain, which has unremarkable gyri and sulci. Coronal sections demonstrate sharp demarcation between white and grey matter, without hemorrhage or contusive injury. The ventricles are of normal size. The basal ganglia, brainstem, cerebellum, and arterial systems are free of injury or other abnormalities. There are no skull fractures. The atlanto-occipital joint is stable.

NECK:
The anterior strap muscles of the neck are homogenous and red-brown, without hemorrhage. The thyroid cartilage and hyoid are intact. The larynx is lined by intact white mucosa. The thyroid is symmetric and red-brown, without cystic or nodular change. The tongue is free of bite marks, hemorrhage, or other injuries.

BODY CAVITIES:
The ribs, sternum, and vertebral bodies are visibly and palpably intact. There is 50-milliliters of serous fluid in both chest cavities and 100-milliliters of serous ascites. The organs occupy their usual anatomic positions.

RESPIRATORY SYSTEM:
The right and left lungs weigh 690 and 670-grams, respectively. The external surfaces are smooth and deep red-purple. The pulmonary parenchyma is diffusely congested and edematous. No mass lesions or areas of consolidation are present.

CARDIOVASCULAR SYSTEM:
The 310-gm heart is contained in an intact pericardial sac. The epicardial surface is smooth, with minimal fat investment. The aorta gives rise to three intact and patent arch vessels. The renal and mesenteric vessels are unremarkable. (See Cardiovascular Pathology Consultation Report)

LIVER & BILIARY SYSTEM:
The 1540-gram liver has an intact, smooth capsule and a sharp anterior border. The parenchyma is tan-brown and congested, with the usual lobular architecture. No mass lesions or other abnormalities are seen. The gallbladder contains 20-milliliters of green-black bile and no stones. The mucosal surface is green and velvety. The extrahepatic biliary tree is patent.

SPLEEN:
The 80-gram spleen has a smooth, intact, red-purple capsule. The parenchyma is maroon and congested, with distinct Malpighian corpuscles.

ACLU Detainee DeathII ARMY MEDCOM 617

PANCREAS:
The pancreas is soft, tan and is moderately decomposed. No mass lesions or other abnormalities are seen.

ADRENALS:
The right and left adrenal glands are symmetric, with bright yellow cortices and grey medullae. No masses or areas of hemorrhage are identified.

GENITOURINARY SYSTEM:
The right and left kidneys weigh 190 and 180-grams, respectively. The external surfaces are intact and slightly granular in appearance. The cut surfaces are red-tan and congested, with uniformly thick cortices and sharp corticomedullary junctions. The pelves are unremarkable and the ureters are normal in course and caliber. White bladder mucosa overlies an intact bladder wall. The bladder contains approximately 280-milliliters of clear yellow urine. The prostate is normal in size, with lobular, yellow-tan parenchyma. The seminal vesicles are unremarkable. The testes are free of mass lesions, contusions, or other abnormalities.

GASTROINTESTINAL TRACT:
The esophagus is intact and lined by smooth, grey-white mucosa. The stomach contains approximately 100-milliliters of brown fluid. The gastric wall is intact. The duodenum, loops of small bowel, and colon are unremarkable. The appendix is present.

HEPATOPATHOLOGY CONSULTATION

13 April 2006
Liver: Congestion, mild steatosis, increased lipofuscin pigment. There is nothing to suggest any significant liver disease.
(b)(6)

ENDOCRINE PATHOLOGY CONSULTATION

14 April 2006
Adrenal: No pathologic disease.
Pancreas: Pancreas is mostly autolytic. In the areas in which the tissue is not involved *(by autolysis)* there are no significant abnormalities. There is focal peri-ductal fibrosis. This finding is not related to his clinical condition.
(b)(6)

ACLU Detainee DeathII ARMY MEDCOM 618

RENAL PATHOLOLOGY CONSULTATION

24 April 2006
Kidneys:

1. Glomerular changes consistent with diffuse diabetic glomerulosclerosis. The capillary walls are thick; special stains and EM may exclude immune complex glomerulonephritis (membranous glomerulonephritis).
2. Hyaline arteriolosclerosis.
3. Severe autolysis.

In view of the clinical data (Type I diabetes) the glomerular and vascular changes are consistent with diabetes.

(b)(6)

CARIOVASCULAR PATHOLOGY CONSULTATION

28 April 2006
DIAGNOSIOS: (b)(6) Morphologically normal heart

History: 24 year old Iraqi detainee with Type I diabetes and reported decreased urine output; transported to emergency room, arrived in full arrest and could not be resuscitated

Heart: 310-grams; normal epicardial fat; probe patent foramen ovale; normal left ventricular chamber dimensions; left ventricular cavity diameter 30-millimeters, left ventricular free wall thickness 10-millimeters, ventricular septum thickness 13-millimeters; right ventricular dilation: right ventricle thickness 3-millimeters, without gross scars or fat infiltrates; grossly normal valves and endocardium; no gross myocardial fibrosis or necrosis; histologic sections show focal epicardial and subepicardial lymphocytic infiltrates in the anterior and lateral left ventricle without myocyte necrosis or scarring, and a single small focus of subendocardial replacement fibrosis in the lateral left ventricle

Coronary arteries: Normal ostia; left dominance; no gross Atherosclerosis

Conduction system: The sinoatrial node and sinus nodal artery are unremarkable. The compact atrioventricular (AV) node is intact without inflammation, increased fat or vascularity. The penetrating bundle is centrally located within the fibrous body and is unremarkable. The proximal left bundle branch is intact; the right bundle branch is not seen in the section. There are no discrete bypass tracts between the AV node and ventricular septum. The AV nodal artery and its branches show no dysplasia.

Comment: The significance of a small focus of subepicardial chronic inflammation is unknown, as is a single focus of subendocardial fibrosis. In the absence of any other demonstrable cause of death, arrythmia on the basis of coronary vasospasm or ion channelopathy cannot be excluded.

(b)(6)
Cardiovascular Pathologist

ACLU Detainee DeathII ARMY MEDCOM 619

MICROSCOPIC EXAMINATION

- Liver: congestion, mild steatosis, increased lipofuscin pigment
- Adrenal: representative sections are histologically unremarkable
- Pancreas: extensive autolysis with focal peri-ductal fibrosis
- Kidneys: extensive autolysis with hyaline arteriolosclerosis and glomerular capillary basement membrane thickening
- Spleen: congestion, otherwise histologically unremarkable
- Lungs: multiple representative sections show vascular congestion and mild focal anthracotic pigment deposition, focal atelectasis, focal hemorrhage without hemosiderin laden macrophages (likely artefact)
- Brain: representative sections are histologically unremarkable

ADDITIONAL PROCEDURES

1. Documentary photographs are taken by OAFME staff photographers.
2. Full body radiographs are obtained and demonstrate no injuries.
3. Specimens retained for toxicology testing and/or DNA identification are: blood, vitreous, urine, bile, liver, spleen, brain, kidney, lung, adipose tissue, muscle and gastric contents
4. The dissected organs are forwarded with the body.
5. Selected portions of organs are retained in formalin.
7. Identifying marks include: Scars on the left foot and left knee.

ACLU Detainee DeathII ARMY MEDCOM 620

OPINION

This 24 year old male died of complications of diabetes mellitus (diabetic ketoacidosis). The deceased had a medical history significant for poorly controlled Type I diabetes and there was a clinical impression of diabetic ketoacidosis in Iraq. The kidneys exhibited changes that are consistent with a history of diabtetes. The heart was morphologically normal. There was no evidence of significant physical injury. The toxicology screen was significant for acetone in the blood (29-mg/dL) and vitreous fluid (42-mg/dL) and 2-propanol in the blood (17-mg/dL) and vitreous fluid (trace). The vitreous glucose was 10-mg/dL and this level was most likely effected by post-mortem metabolism. The remainder of the toxicology screen is negative. There were no significant physical injuries identified at autopsy. The manner of death is natural. (b)(6)

(b)(6)

(b)(6) **Medical Examiner**

(b)(6)

(b)(6) **Medical Examiner** (b)(6)

ACLU Detainee DeathII ARMY MEDCOM 621

DEPARTMENT OF DEFENSE
ARMED FORCES INSTITUTE OF PATHOLOGY
WASHINGTON, DC 20306-6000

REPLY TO ATTENTION OF

AFIP (b)(6)

TO:

OFFICE OF THE ARMED FORCES MEDICAL EXAMINER
ARMED FORCES INSTITUTE OF PATHOLOGY
WASHINGTON, DC 20306-6000

PATIENT IDENTIFICATION
AFIP Accessions Number **Sequence**
(b)(6)
Name
MUHYI, TALIB UMAR

SSAN: **Autopsy:** (b)(6)
Toxicology Accession #: (b)(6)
Date Report Generated: April 3, 2006

CONSULTATION REPORT ON CONTRIBUTOR MATERIAL

AFIP DIAGNOSIS **REPORT OF TOXICOLOGICAL EXAMINATION**

Condition of Specimens: GOOD
Date of Incident: **Date Received:** 3/30/2006

CARBON MONOXIDE: The carboxyhemoglobin saturation in the blood was less than 1% as determined by spectrophotometry with a limit of quantitation of 1%. Carboxyhemoglobin saturations of 0-3% are expected for non-smokers and 3-10% for smokers. Saturations above 10% are considered elevated and are confirmed by gas chromatography.

CYANIDE: There was no cyanide detected in the blood. The limit of quantitation for cyanide is 0.25 mg/L. Normal blood cyanide concentrations are less than 0.15 mg/L. Lethal concentrations of cyanide are greater than 3 mg/L.

VOLATILES: The **BLOOD AND VITREOUS FLUID** were examined for the presence of ethanol (cutoff of 20 mg/dL), acetaldehyde, acetone, 2-propanol, 1-propanol, t-butanol, 2-butanol, iso-butanol and 1-butanol by headspace gas chromatography. The following volatiles were detected: (concentration(s) in mg/dL)

	Acetone	2-Propanol
BLOOD	29	17
VITREOUS FLUID	42	Trace

Trace = value greater than or equal to 1mg/dL, but less than 5 mg/dL

ACLU Detainee DeathII ARMY MEDCOM 622

DEPARTMENT OF DEFENSE
ARMED FORCES INSTITUTE OF PATHOLOGY
WASHINGTON, DC 20306-6000

REPLY TO
ATTENTION OF

REPORT OF TOXICOLOGICALM EXAMINATION (CONT – MUHYI, TALIB UMAR):

DRUGS: The **URINE** was screened for acetaminophen, amphetamine, antidepressants, antihistamines, barbiturates, benzodiazepines, cannabinoids, chloroquine, cocaine, dextromethorphan, lidocaine, narcotic analgesics, opiates, phencyclidine, phenothiazines, salicylates, sympathomimetic amines and verapamil by gas chromatography, color test or immunoassay. The following drugs were detected:

None were found.

(b)(6)

Office of the Armed Forces Medical Examiner

(b)(6)

Office of the Armed Forces Medical Examiner

ACLU Detainee DeathII ARMY MEDCOM 623

CERTIFICATE OF DEATH *(OVERSEAS)*
Acte de décès (D'Outre-Mer)

NAME OF DECEASED (Last, First, Middle) Nom du décédé (Nom et prénoms)	GRADE Grade	BRANCH OF SERVICE Arme	SOCIAL SECURITY NUMBER Numéro de l'Assurance Social
BTB Muhyi, Talib, Umar		Civilian	(b)(6)

ORGANIZATION Organisation	NATION (e.g. United States) Pays	DATE OF BIRTH Date de naissance	SEX Sexe
	Iraq		[X] MALE [ ] FEMALE

RACE Race		MARITAL STATUS Etat Civil			RELIGION Culte		
	CAUCASOID Caucasique		SINGLE Célibataire		DIVORCED Divorce		PROTESTANT Protestant		OTHER (Specify) Autre (Spécifier)
	NEGROID Negroide		MARRIED Marié		SEPARATED Séparé		CATHOLIC Catholique	X	
X	OTHER (Specify) Autre (Spécifier)		WIDOWED Veuf				JEWISH Juif		

NAME OF NEXT OF KIN Nom du plus proche parent	RELATIONSHIP TO DECEASED Parenté du décédé avec le sus
STREET ADDRESS Domicile à (Rue)	CITY OR TOWN OR STATE (Include ZIP Code) Ville (Code postal compris)

MEDICAL STATEMENT Déclaration médicale

	CAUSE OF DEATH (Enter only one cause per line) Cause du décès (N'indiquer qu'une cause par ligne)	INTERVAL BETWEEN ONSET AND DEATH Intervalle entre l'attaque et le décès
DISEASE OR CONDITON DIRECTLY LEADING TO DEATH [1] Maladie ou condition directement responsable de la mort	Complications of Diabetes Mellitis (Diabetic Ketoacidosis)	
ANTECEDENT CAUSES Morbid condition, if any, leading to primary cause. Condition morbide, s'il y a lieu, menant à la cause primaire		
Symptômes précurseurs de la mort — Underlying cause if any, giving rise to primary cause. Condition morbide, s'il y a lieu, menant à la cause primaire		
OTHER SIGNIFICANT CONDITIONS [2] Autres conditions significatives [2]		

MODE OF DEATH Condition de décès	AUTOPSY PERFORMED Autopsie effectuée [X] YES Oui [ ] NO Non	CIRCUMSTANCES SURROUNDING DEATH DUE TO EXTERNAL CAUSES Circonstances de la mort suscitées par des causes extérieures
[X] NATURAL Mort naturelle	MAJOR FINDINGS OF AUTOPSY Conclusions principales de l'autopsie	
[ ] ACCIDENT Mort accidentelle		
[ ] SUICIDE Suicide	NAME OF PATHOLOGIST Nom du pathologiste (b)(6)	
[ ] HOMICIDE Homicide	(b)(6) DATE Date 25 March 2006	AVIATION ACCIDENT Accident d'Avion [ ] YES Oui [X] NO Non

DATE OF DEATH (day, month, year) (le jour, le mois, l'année)	PLACE OF DEATH Lieu de décès
(b)(6) 2006	

I HAVE VIEWED THE REMAINS OF THE DECEASED AND DEATH OCCURRED AT THE TIME INDICATED AND FROM THE CAUSES AS STATED ABOVE
J'ai examiné les restes mortels du défunt et je conclus que le décès est survenu à l'heure indiquée et à la suite des causes énumérées ci-dessus

NAME OF MEDICAL OFFICER Nom du médecin traitant ou du médecin constant	TITLE OR DEGREE Titre ou diplôme
(b)(6)	Medical Examiner

GRADE Grade	INSTALLATION OR ADDRESS Installation ou adresse
(b)(6)	(b)(6)
DATE Date 05 OCT 06	

[1] State disease, injury or complication which caused death
[2] State conditions contributing to the death, but not return
[1] Préciser la nature de la maladie, de la blessure ou de la complication qui a contribué à la mort, mais non la manière de mourir telle qu'un arrêt du coeur, etc.
[2] Préciser la condition qui a contribué à la mort, mais n'ayant aucun rapport avec la maladie ou à la condition qui a provoqué la mort

DD FORM 1 APR 77 2064 REPLACES DA FORM 3566, 1 JAN 72 AND DA FORM 3566-R(PAS), 26 SEP 75, WHICH ARE OBSOLETE.

ARMED FORCES INSTITUTE OF PATHOLOGY
Office of the Armed Forces Medical Examiner
1413 Research Blvd., Bldg. 102
Rockville, MD 20850
1-301-319-0000

FINAL AUTOPSY REPORT

Name: Hammid, Raad Kairy
ISN: (b)(6)
Date of Birth: (b)(6) 1979
Date of Death (b)(6) 2006
Date of Autopsy: 20 Feb 2006
Date of Report: 1 May 2006

Autopsy No. (b)(6)
AFIP No.: (b)(6)
Rank: Civilian, Iraqi
Place of Death: Baghdad, Iraq
Place of Autopsy: Dover AFB/Port Mortuary

Circumstances of Death: Iraqi civilian detainee within the Baghdad central confinement facility hospital ICU died after developing new onset seizures and subsequent documentation of severe brain edema with reported areas of intra parenchymal hemorrhage.

Authorization for Autopsy: Office of the Armed Forces Medical Examiner, IAW 10 USC 1471

Identification: Identification tags on the body.

CAUSE OF DEATH: Hypoxic-ischemic encephalopathy due to meningoencephalitis of unknown origin

MANNER OF DEATH: Natural

ACLU Detainee DeathII ARMY MEDCOM 625

FINAL AUTOPSY DIAGNOSES:

I. Hypoxic-ischemic encephalopathy with meningoencephalitis of unknown origin
   a. Severe brain edema with uncal and cerebellar tonsil herniation
   b. Clinical diagnosis of encephalitis with new onset seizures
   c. Generalized body edema and severe pulmonary edema and congestion
   d. Bilateral adrenal gland hemorrhage and necrosis

II. Bronchopneumonia with thick airway mucous secretions

III. Bladder mucosa petechiae, Foley catheter in place

IV. Right lower lip, inner surface, contusion, ½ inch

V. No evidence of other significant natural disease or trauma

VI. Identifying Marks, none

VII. Property on the body at the time of autopsy examination, none

VIII. Toxicology:

   a. Carbon Monoxide: 1% carboxyhemoglobin saturation
   b. Cyanide: None detected
   c. Volatiles: No ethanol detected
   d. Drugs: None of the screened for drugs/substances were detected

EXTERNAL EXAMINATION

The body is that of a well-developed, well-nourished appearing, muscular, Iraqi, male, 69.5 inches tall, 174 pounds whose appearance is consistent with the reported age of 27 years. Postmortem lividity is purple red and fixed on the posterior surfaces of the body except in areas previously exposed to pressure. Rigor is dissipating and the body is cold to touch.

The scalp is covered with black curly hair in a normal distribution. The irides are brown and the pupils are round and equal in diameter. The external auditory canals are patent. The ears are otherwise unremarkable. The nares are patent and the lips are well developed. The nose and maxillae are palpably stable. The teeth appear natural and in adequate repair.

ACLU Detainee DeathII ARMY MEDCOM 626

The neck is straight, and the trachea is midline and mobile. The chest is symmetric. The abdomen is flat. The genitalia are those of a normal adult male. The testes are descended and free of palpable masses. Pubic hair is present in a normal distribution. The buttocks and anus are unremarkable.

The upper and lower extremities are symmetric and without clubbing or edema. No significant blunt force or penetrating trauma is evident. The body and extremities have generalized edema particularly the right thigh and hands. The hands have a black gritty substance possibly fingerprint ink or other similar material.

CLOTHING AND PERSONAL EFFECTS

The following clothing items and personal effects are present on the body at the time of autopsy:

- None

MEDICAL INTERVENTION

- Nasal gastric tube, appropriate positioning
- Endotracheal tube, appropriate positioning
- Cardiac monitor pads, usual locations
- Indwelling intravenous catheters:
  - Right antecubital fossa
  - Right and left inguinal areas
- Foley catheter, appropriate positioning

RADIOGRAPHS

A complete set of postmortem radiographs is obtained and demonstrates no metal or fractures.

EVIDENCE OF INJURY

The inner surface of the right side of the lower lip has a ½ inch contusion. No other injuries were identified

INTERNAL EXAMINATION

HEAD:
The galeal and subgaleal soft tissues of the scalp are free of injury. The calvarium is intact, as is the dura mater beneath it. No meningitis is appreciated grossly. Clear cerebrospinal fluid surrounds the 1420 gm brain, with flat gyri and narrowed sulci. There is uncal herniation and clear cerebellar tonsil herniation and necrosis. No subdural or subarachnoid hemorrhage is present. The arterial system appears free of abnormality. The transverse and sigmoid sinuses have thrombosis bilaterally. There are no skull fractures. The atlanto-occipital joint is stable. The brain is otherwise fixed for neuropathology consultation at the Armed Forces Institute of Pathology, which provided a separate consultation report.

ACLU Detainee DeathII ARMY MEDCOM 627

NECK:
The anterior strap muscles of the neck are homogenous and red-brown, without hemorrhage. The thyroid cartilage and hyoid bone are intact. The larynx is lined by intact white mucosa. The thyroid is symmetric and red-brown, without cystic or nodular change. The tongue is free of bite marks, hemorrhage, or other injuries. Dissection of the upper posterior neck to the level of C2/3 demonstrates no paracervical muscular injury and no cervical spine fractures at this level.

BODY CAVITIES:
The ribs, sternum, and vertebral bodies are visibly and palpably intact. The left pleural cavity contains approximately 200 ml of serosanguinous fluid. The right pleural cavity contains a small volume of similar fluid. The pericardial and peritoneal cavities do not contain an increase in fluid. The organs occupy their usual anatomic positions.

RESPIRATORY SYSTEM:
The right and left lungs weigh 940 and 840 gm, respectively. The external surfaces are smooth and deep red-purple. The pulmonary parenchyma is diffusely congested and edematous. No mass lesions are evident. The right lower lobe is consolidated and the right and left large and small airways contain thick yellow tan mucoid secretions. These secretions focally obstruct or plug the peripheral airways.

CARDIOVASCULAR SYSTEM:
The 420 gm heart is contained in an intact pericardial sac. The epicardial surface is smooth, with minimal fat investment. The coronary arteries are present in a normal distribution, with a right-dominant pattern. Cross sections of the vessels show no significant atherosclerosis. The myocardium is homogenous, red-brown, and firm. The valve leaflets are thin and mobile. The walls of the left and right ventricles are 1.5 and 0.6 -cm thick, respectively. The endocardium is smooth and glistening. The aorta gives rise to three intact and patent arch vessels. The renal and mesenteric vessels are unremarkable.

LIVER & BILIARY SYSTEM:
The 2270 gm liver has an intact, smooth capsule and a sharp anterior border. The parenchyma is tan-brown and congested, with the usual lobular architecture. No mass lesions or other abnormalities are seen. The gallbladder contains a minute amount of green-black bile and no stones. The mucosal surface is green and velvety. The extrahepatic biliary tree is patent.

SPLEEN:
The 280 gm spleen has a smooth, intact, red-purple capsule. The parenchyma is maroon and congested, with distinct Malpighian corpuscles.

PANCREAS:
The pancreas is firm and yellow-tan, with the usual lobular architecture. No mass lesions or other abnormalities are seen.

ACLU Detainee DeathII ARMY MEDCOM 628

ADRENALS:
The right and left adrenal glands are hemorrhagic, 30 grams each, with autolysis and necrotic purple brown medullae. No masses are identified.

GENITOURINARY SYSTEM:
The right and left kidneys weigh 180 and 210 gm, respectively. The external surfaces are intact and smooth. The cut surfaces are red-tan and congested, with uniformly thick cortices and sharp corticomedullary junctions. The pelves are unremarkable and the ureters are normal in course and caliber. White bladder mucosa overlies an intact bladder wall. The bladder mucosa has scattered petechiae. The bladder is empty. The prostate is normal in size, with lobular, yellow-tan parenchyma. The seminal vesicles are unremarkable. The testes are free of mass lesions, contusions, or other abnormalities.

GASTROINTESTINAL TRACT:
The esophagus is intact and lined by dark autolyzed mucosa. The stomach contains approximately 50 cc of greenish brown semi-liquid material. The gastric wall is intact. The duodenum, loops of small bowel, and colon are unremarkable. The appendix is present.

ADDITIONAL PROCEDURES

- Documentary photographs are taken by OAFME photographer.
- No trace evidence or foreign material is collected.
- Specimens retained for toxicologic testing and/or DNA identification are: vitreous, blood, spleen, liver, brain, kidney, lung, bile, gastric, skin/adipose tissue and psoas.
- The dissected organs are forwarded with body.
- Personal effects are released to the appropriate mortuary operations representatives.

MICROSCOPIC EXAMINATION

Selected portions of organs are retained in formalin. Selected small tissue pieces are processed for histologic slides as described below. These slides have been examined and there are no additional significant pathologic findings other than those confirmed and listed in the final diagnosis or internal examination sections of this report.

Block List:

1,2 Myocardium	3 Testicle and myocardium
4,5 Lung	6 Liver
7 Lung	8 Kidney
9 Spleen	10 Lung
11 Dura	12/13 Adrenal gland

ACLU Detainee DeathII ARMY MEDCOM 629

OPINION

This 27 year-old Iraqi, male, civilian, detainee, died of hypoxic-ischemic encephalopathy due to meningoencephalitis of unknown origin. The brain was examined by the Neuropathology, Environmental and Infectious Disease Sciences, and the Hematopathology Departments of the Armed Forces Institute of Pathology, Washington, DC (Separate reports). The manner of death is natural.

(b)(6)

(b)(6) **Medical Examiner** (b)(6)

ACLU Detainee DeathII ARMY MEDCOM 630

CERTIFICATE OF DEATH *(OVERSEAS)*

Acte de décès (D'Outre-Mer)

NAME OF DECEASED *(Last, First, Middle)* Nom du décédé (Nom et prénoms)	GRADE Grade	BRANCH OF SERVICE Arme	SOCIAL SECURITY NUMBER Numéro de l'assurance Sociale
Hammid, Raad, Kairy		Civilian	(b)(6)
ORGANIZATION Organisation	**NATION** *(e.g. United States)* Pays: Iraq	**DATE OF BIRTH** Date de naissance: (b)(6) 1979	**SEX** Sexe: [X] MALE [ ] FEMALE

RACE Race		MARITAL STATUS Etat Civil			RELIGION Culte		
[X]	CAUCASOID Caucasique	[ ]	SINGLE Célibataire	[ ] DIVORCED Divorcé	[ ]	PROTESTANT Protestant	[ ] OTHER (Specify) Autre (Spécifier)
[ ]	NEGROID Negroide	[ ]	MARRIED Marié	[ ] SEPARATED Séparé	[ ]	CATHOLIC Catholique	[X]
[ ]	OTHER (Specify) Autre (Spécifier)	[ ]	WIDOWED Veuf		[ ]	JEWISH Juif	

NAME OF NEXT OF KIN Nom du plus proche parent	RELATIONSHIP TO DECEASED Parenté du décédé avec le sus
STREET ADDRESS Domicile à (Rue)	CITY OR TOWN OR STATE *(Include ZIP Code)* Ville (Code postal compris)

MEDICAL STATEMENT Déclaration médicale

CAUSE OF DEATH (Enter only one cause per line) Cause du décès (N'indiquer qu'une cause par ligne)		INTERVAL BETWEEN ONSET AND DEATH Intervalle entre l'attaque et le décès
DISEASE OR CONDITON DIRECTLY LEADING TO DEATH [1] Maladie ou condition directement responsable de la mort	Determination Pending	Days
ANTECEDENT CAUSES — MORBID CONDITION IF ANY, LEADING TO PRIMARY CAUSE Condition morbide, s'il y a lieu, menant à la cause primaire		
Symptômes précurseurs de la mort — UNDERLYING CAUSE, IF ANY, GIVING RISE TO PRIMARY CAUSE Condition morbide, s'il y a lieu, menant à la cause primaire		
OTHER SIGNIFICANT CONDITIONS [2] Autres conditions significatives [2]		

MODE OF DEATH Condition de décès	AUTOPSY PERFORMED Autopsie effectuée [X] YES Oui [ ] NO Non	CIRCUMSTANCES SURROUNDING DEATH DUE TO EXTERNAL CAUSES Circonstances de la mort suscitées par des causes extérieures
[ ] NATURAL Mort naturelle	MAJOR FINDINGS OF AUTOPSY Conclusions principales de l'autopsie	Mode of Death : Pending
[ ] ACCIDENT Mort accidentelle	(b)(6)	
[ ] SUICIDE Suicide	NAME OF PATHOLOGIST Nom du pathologiste: (b)(6)	
[ ] HOMICIDE Homicide	20 February 2006	AVIATION ACCIDENT Accident d'Avion [ ] YES Oui [X] NO Non

DATE OF DEATH *(day, month, year)* Date de décès (le jour, le mois, l'année)	PLACE OF DEATH Lieu de décès
(b)(6) 2006	

I HAVE VIEWED THE REMAINS OF THE DECEASED AND DEATH OCCURRED AT THE TIME INDICATED AND FROM THE CAUSES AS STATED ABOVE
J'ai examiné les restes mortels du défunt je conclus que le décès est survenu à l'heure indiquée et à la suite des causes énumérées ci-dessus

NAME OF MEDICAL OFFICER Nom du médecin légiste ou du médecin sanitaire	TITLE OR DEGREE Titre ou diplôme
(b)(6)	Medical Examiner

GRADE Grade	INSTALLATION OR ADDRESS Installation ou adresse
(b)(6)	Dover AFB, Dover DE
DATE Date: 11 APR 06	**SIGNATURE** Signature

[1] State disease, injury or complication which caused death, but not mode of dying such as heart failure, etc
[2] State conditions contributing to the death, but not related to the disease or condition causing death
[1] Préciser la nature de la maladie, de la blessure ou de la complication qui a contribué à la mort, mais non le manière de mourir, telle qu'un arrêt du coeur, etc
[2] Préciser la condition qui a contribué à la mort, mais n'ayant aucun rapport avec la maladie ou à la condition qui a provoqué la mort

DD FORM 1 APR 77 **2064** REPLACES DA FORM 3565, 1 JAN 72 AND DA FORM 3566-R(PAS), 25 SEP 75, WHICH ARE OBSOLETE.

ARMED FORCES INSTITUTE OF PATHOLOGY
Office of the Armed Forces Medical Examiner
1413 Research Blvd., Bldg. 102
Rockville, MD 20850
1-301-319-0000

AUTOPSY EXAMINATION REPORT

Name: GHADBAN, Talib E.
ISN: (b)(6)
Date of Birth: not known
Date of Death: (b)(6) 2006
Date of Autopsy: 15 JAN 2006 at 0930
Date of Report: 13 MAR 2006

Autopsy No.: (b)(6)
AFIP No.: (b)(6)
Rank: not applicable
Place of Death: Baghdad, Iraq
Place of Autopsy: Port Mortuary
Dover AFB, DE

Circumstances of Death: Decedent admitted to the 344th Field Hospital on 31 Dec 05 complaining of being light-headed. On 02 Jan 06, the detainee is reported to have suffered a stroke with subsequent severe brain swelling. Distorted brain anatomy was seen in imaging studies (CT scan). Detainee was removed from respirator on 7 Jan 06, 0800, but feeding tube kept in place. Detainee pronounced at 1123 (b)(6) 06.

Authorization for Autopsy: Office of the Armed Forces Medical Examiner, IAW 10 USC 1471

Identification: Presumptive identification by assigned ISN.

CAUSE OF DEATH: ATHEROSCLEROTIC CEREBRAL VASCULAR DISEASE

MANNER OF DEATH: NATURAL

ACLU Detainee DeathII ARMY MEDCOM 632

AUTOPSY DIAGNOSES

I. Central Nervous System:
- A. Acute infarction of the right cerebral hemisphere in territory of the right middle cerebral artery; the histologic appearance is consistent with infarct that has been approximately one week or less in duration
- B. Subfalcine and transtentorial herniation
- C. Thrombus, organizing, right middle cerebral artery; atherosclerotic and arteriolosclerotic vascular disease

II. Cardiovascular Pathology:
- A. Cardiomegaly 400 grams, predicted normal 310 grams for 138 pound male
- B. Mildly thickened and redundant tricuspid valve
- C. Focal microscopic subepicardial scarring, of unknown significance
- D. Left anterior descending artery: 30% luminal narrowing by pathologic intimal thickening
- E. Right coronary artery: 30% luminal narrowing by pathologic intimal thickening
- F. There is focal microscopic subepicardial scarring, the significance of which is unknown

III. Nephrosclerosis with granular renal surface appearance, focal infarct of left kidney and bilateral cortical thinning

IV. Evidence of Medical Intervention
- A. Nasogastric feeding tube appropriately positioned
- B. Intravenous access site in left femoral crease
- C. Evidence of intravenous access sites in left and right antecubital fossae
- D. Foley urinary catheter
- E. EKG pads on right shoulder and left leg
- F. Treated decubitus ulcer on right back

V. Toxicology:
- A. Blood is negative for carboxyhemoglobin (carbon monoxide)
- B. Blood and urine are negative for ethanol
- C. Blood is negative for cyanide
- D. Urine is negative for screened drugs of abuse
- E. Urine is positive for lidocaine
- F. Urine is positive for lorazepam

ACLU Detainee DeathII ARMY MEDCOM 633

EXTERNAL EXAMINATION

The clothed body is that of a normally developed, adequately nourished, 65-1/2-inches, 138 pounds, Caucasian male whose appearance is consistent with an age range extending from the mid-to-late sixth through seventh decades. Lividity is posterior and fixed, rigor is passing, and the temperature is that of the refrigeration unit.

The scalp is covered with medium length black-graying hair, distributed in a male balding pattern, and a black-gray mustache and stubble beard. There is no evidence of cranio-facial trauma. The corneae are opacified, the underlying irides are brown, and the pupils are round and equal. The sclerae are slightly injected. The external auditory canals are clear. The ears are unremarkable. The nares are patent and the lips are atraumatic. The nose and maxillae are palpably stable. The lower jaw is edentulous; numerous teeth of the upper jaw are missing and those present are markedly worn.

The neck is straight, and the trachea is midline and mobile. The chest is symmetric. A circumscribed circular area of erythema over the right epigastrium measures 1 inch in diameter. The abdomen is slightly protuberant but without mass or fluid wave. The genitalia are those of a normal circumcised adult male. The testes are descended and free of masses. Pubic hair is present in a normal distribution. There is a 1/2 inch resolving contusion on the right side of the upper back. There are two circumscribed areas of erythema on the right side of the mid-back. A 2-1/2 inch circumscribed area of hyperpigmentation is present at the superior aspect of the gluteal crease. The buttocks and anus are unremarkable.

The upper and lower extremities are symmetric and without clubbing. There is a resolving, 1/2 inch contusion on the volar surface of the right forearm. Circumscribed hyperpigmented areas are present on the dorsal surfaces of both right and left hands. The skin of the hands is mildly edematous and the finger nail beds are cyanotic. The skin of the legs, from the soles of the feet to the level of the knees is darker brown than the skin of the remaining body surface.

MEDICAL INTERVENTION

A nasogastric feeding tube is positioned through the left naris. There is evidence of previous intravascular access in the antecubital fossae bilaterally, as well as in the left femoral crease. A urinary catheter is positioned through the urethra. EKG pads are present on the right shoulder and left leg. A healing decubitus ulcer measuring 2-1/4 x 1 inch, with a gel dressing placed over it, is present on the left side of the back along the lateral scapular border. A plastic coated hospital identification bracelet printed with the decedent's name encircles the left wrist.

RADIOGRAPHS

A complete set of postmortem radiographs is obtained and demonstrates an absence of skeletal trauma and metallic foreign bodies

ACLU Detainee DeathII ARMY MEDCOM 634

INTERNAL EXAMINATION

HEAD (See Neuropathology Consult):
The galeal and subgaleal soft tissues of the scalp are free of injury. There are no skull fractures, and the dura mater underlying the calvarium is intact as well. The atlanto-occipital joint is stable.

NECK:
The anterior strap muscles of the neck are homogenous and red-brown, without hemorrhage. The thyroid cartilage and hyoid bone are intact. The larynx is lined by intact white mucosa. The thyroid gland is symmetric and red-brown, without cystic or nodular change. The tip of the tongue is dessicated, but free of bite marks, hemorrhage, or other injuries. The bones of the cervical spine are intact and there is no evidence of soft tissue hemorrhage when layer-wise anterior and posterior dissections are extended to the spinal column.

BODY CAVITIES:
The ribs, sternum, and vertebral bodies are visibly and palpably intact. A 50 cc serous effusion is present in the left hemithorax, and a 400 cc serous effusion is present in the right hemithorax. The pericardial sac contains 20 cc of clear fluid. There is no excess fluid in the peritoneal cavity. The organs occupy their usual anatomic positions.

RESPIRATORY SYSTEM:
The right and left lungs weigh 690 and 560-grams, respectively. A few filmy adhesions extend from the visceral to the parietal surfaces of the right upper lung lobe. The external surfaces are deep red-purple. The pulmonary parenchyma is diffusely congested and edematous. There is a small amount of white froth in the distal trachea and bronchi. No other significant abnormality is noted.

CARDIOVASCULAR SYSTEM (See Cardiovascular Pathology Consult):
The aorta gives rise to three intact and patent arch vessels. No significant lesion is present in the thoracic or abdominal segments of the aorta. The renal and mesenteric vessels are unremarkable.

LIVER & BILIARY SYSTEM:
The 1570-gram liver has an intact, smooth capsule with prominent lobular patterning. The parenchyma is uniform tan-brown. No mass lesions or other abnormalities are seen. The gallbladder contains slightly less than 10 cc of green-black bile; there are no stones. The mucosal surface is green and velvety. The extrahepatic biliary tree is patent.

SPLEEN:
The 170-gram spleen has an intact, red-purple capsule. Several adhesions extend from the splenic surface to adjacent organs and to the abdominal wall. The parenchyma is uniformly deep purple with distinct Malpighian corpuscles. There is no evidence of a focal lesion.

ACLU Detainee DeathII ARMY MEDCOM 635

PANCREAS:
The pancreas is firm and yellow-tan, with the usual lobular architecture. No mass lesions or other abnormalities are seen.

ADRENALS:
The right and left adrenal glands are symmetric, with bright yellow cortices and grey medullae. No masses or areas of hemorrhage are identified.

GENITOURINARY SYSTEM:
The right and left kidneys weigh 170 and 180-grams, respectively. The external surfaces of the kidneys are finely granular. There is a faint wedge-shaped infarct in the superior pole of the left kidney. The cut surfaces, apart from the infarcted tissue, are red-tan and congested, with slight thinning of the cortices and sharp corticomedullary junctions. The pelves are unremarkable and the ureters are normal in course and caliber. White bladder mucosa overlies an intact bladder wall. The bladder is empty, having been drained by the urinary catheter. The prostate gland is enlarged with yellow-tan parenchyma and palpable poorly defined nodules. The seminal vesicles are unremarkable. The testes are free of mass lesions, contusions, or other abnormalities.

GASTROINTESTINAL TRACT:
The esophagus is intact and lined by smooth, grey-white mucosa. The stomach contains approximately 70-milliliters of partially digested food. The gastric wall is intact. The duodenum, loops of small bowel, and colon are unremarkable. The appendix is present.

MUSCULOSKELETAL AND INTEGUMENTARY SYSTEM
Muscle development is normal. No bone or joint abnormalities are noted. All areas of hyperpigmentation are examined by limited dissection; in no instance is there evidence of soft tissue hemorrhage. There is no evidence of injury to the back, wrists or the backs of the legs.

MICROSCOPIC EXAMINATION

Selected portions of organs are retained in formalin, with preparation of histologic slides as appropriate.

ADDITIONAL PROCEDURES/REMARKS

- Documentary photographs are taken by the OAFME staff photographers.
- Specimens submitted for toxicology and DNA analysis: vitreous, blood, gastric contents, bile, urine, brain, lung, liver, kidney, spleen, adipose, and psoas muscle.
- Full body radiographs are obtained and reflect injuries described above.
- Selected portions of organs are retained in formalin and histologic sections prepared as appropriate.
- The dissected organs are forwarded with the body.
- Personal effects are released to the appropriate mortuary operations representatives.

ACLU Detainee DeathII ARMY MEDCOM 636

SUBSPECIALTY CONSULTATION: NEUROPATHOLOGY

(b)(6) **Neuropathology, reviewed in conference 3/3/2006**

Brain, postmortem examination: Acute infarction of the right cerebral hemisphere in territory of the right middle cerebral artery. Subfalcine and transtentorial herniation. Thrombus, organizing, right middle cerebral artery. Atherosclerotic and arteriolosclerotic vascular disease.

A 1426-gram formalin-fixed brain was received. The falx cerebri is unremarkable. The remainder of the dura is not available for examination. The leptomeninges are thin and translucent, with congested meningeal vessels; minimal fresh subarachnoid hemorrhage is noted at the right inferior temporal gyrus. Contusion is not identified. There is diffuse softening of the right cerebral hemisphere. The cerebral gyral pattern is normal, but there is diffuse flattening. The cranial nerves are unremarkable. The circle of Willis shows a normal pattern. The cerebral blood vessels are removed. No aneurysms are seen. There is thrombosis of the right middle cerebral artery starting near the origin and extending to the second major bifurcation. Both posterior cerebral arteries have focal atherosclerotic plaques. There is right-to-left subfalcine herniation. There is right uncal (transtentorial) herniation with necrosis; the left uncus is notched with no softening. No tonsillar (transforaminal) herniation is seen. The brainstem and cerebellum have diffuse moderate swelling. Coronal sections of cerebrum show diffuse enlargement and softening of the right cerebral hemisphere (frontal, parietal, and temporal lobes), involving cortex, white matter, basal ganglia and thalamus. The cortico-medullary junction is preserved. A focal white matter hemorrhage is noted, right frontal lobe. Some focal hemorrhages involve the deep cortex and superficial white matter of the right occipital lobe. The left cerebral hemisphere is compressed. Right-to-left subfalcine and transtentorial herniation is confirmed. The third ventricle and right lateral ventricle are collapsed and displaced; the left lateral ventricle is displaced. The midbrain is compressed and contains multiple hemorrhages; the cerebral aqueduct is slit-like. The substantia nigra and locus caeruleus are well pigmented. A small linear hemorrhage is noted in the right rostral pons. The cerebellum, medulla oblongata, and fourth ventricle are unremarkable. The thoracolumbar spinal cord is not available for examination. A CD showing gross features of the brain is enclosed.

Summary of sections: 1. Left superior/middle frontal gyrus. 2. Left inferior parietal lobule. 3. Left superior/middle temporal gyrus. 4. Bilateral cingulate gyri (left inked black). 5. Left hippocampus. 6. Left caudate/putamen. 7. Left putamen/pallidum. 8. Bilateral thalamus/hypothalamus at mammillary bodies (left inked black). 9. Midbrain (left inked black). 10. Pons (left inked black). 11. Medulla (left inked black). 12. Left cerebellum/dentate nucleus. 13. Medullary-cervical junction (left inked black). 14. Right hippocampus. 15. Right medial occipital lobe. 16. Right frontal lobe white matter. 17. Right dorsal parietal lobe. 18. Right middle cerebral artery. 19. Bilateral posterior cerebral arteries (left inked black). All sections were processed in paraffin; slides were stained with H & E. This material was reviewed in conference by staff of the Department of Neuropathology and Ophthalmic Pathology.

Microscopic sections show extensive infarction of cerebral cortex, white matter, basal ganglia and thalamus within right middle cerebral artery territory, with acute neuronal injury, scattered macrophages, patchy neutrophils, coagulation necrosis, and vacuolation of neuropil/white matter. No significant subarachnoid hemorrhage is identified. No ventricular hemorrhage is seen. Scattered small intraparenchymal perivascular hemorrhages are present. The histologic appearance is consistent with infarct that has been approximately one week or less in duration. The right middle cerebral artery contains organizing thrombus with fibrin deposition and adherence to vessel wall. Cerebral vessels show atherosclerosis and arteriolosclerosis. Parenchymal hemorrhages are noted in midbrain and rostral pons.

(b)(6)

ACLU Detainee DeathII ARMY MEDCOM 637

SUBSPECIALTY CONSULTATION: CARDIOVASCULAR PATHOLOGY

FINAL DIAGNOSIS

DIAGNOSIS: (b)(6) **Heart, post mortem examination: Cardiomegaly**

History: Male detainee (date of birth unknown) admitted to 344th Field Hospital 12/31/05 with signs and symptoms of stroke; subject die(b)(06.

Heart: 400 grams, predicted normal 310 grams for 138 pound male; normal epicardial fat; closed foramen ovale; left ventricular cavity diameter 30 mm, left ventricular free wall thickness 13 mm, ventricular septum thickness 15 mm, right ventricle thickness 4 mm without gross scars or abnormal fat infiltrates; mildly thickened and redundant tricuspid valve, other valves grossly unremarkable; endocardium grossly unremarkable; no gross myocardial fibrosis or necrosis; histologic sections show focal microscopic subepicardial scarring; there are no inflammatory cell infiltrates, myocyte necrosis, or cardiomyopathic changes.
Coronary arteries: Normal ostia, right dominance; focally mild coronary atherosclerosis
Left anterior descending artery: 30% luminal narrowing by pathologic intimal thickening
Right coronary artery: 30% luminal narrowing by pathologic intimal thickening

Comment: There is focal microscopic subepicardial scarring, the significance of which is unknown.

Thank you for sending this case for our review. Case seen in conference.

(b)(6)

Staff pathologist

Blocks made: 7
Slides made: 7 H&E, 6 Movat

ACLU Detainee DeathII ARMY MEDCOM 638

OPINION

This detainee died of cerebral vascular disease, specifically, of thrombotic occlusion of the right middle cerebral artery and ischemic changes of the central nervous system structures it supplies. Cardiomegaly and nephrosclerotic changes support the interpretation that the decedent had hypertensive disease of long standing.

Despite extensive and detailed examination, there is no evidence of trauma or injury. The identification of lidocaine and a benzodiazepine in the urine are consistent with the detainees status as a hospitalized patient with cardiac instability and possibly seizures.

The manner of death is natural.

(b)(6)

(b)(6) Medical Examiner

(b)(6)

(b)(6) Medical Examiner

ACLU Detainee DeathII ARMY MEDCOM 639

CERTIFICATE OF DEATH *(OVERSEAS)*
Acte de décès (D'Outre-Mer)

NAME OF DECEASED *(Last, First, Middle)* Nom du décédé (Nom et prénoms)	GRADE Grade	BRANCH OF SERVICE Arme	SOCIAL SECURITY NUMBER Numéro de l'Assurance Social
BTB Ghadban, Talib, E		Not applicable - oth	(b)(6)
ORGANIZATION Organisation	NATION *(e.g. United States)* Pays: Iraq	DATE OF BIRTH Date de naissance	SEX Sexe: [X] MALE [ ] FEMALE

RACE Race		MARITAL STATUS État Civil			RELIGION Culte		
	CAUCASOID Caucasique		SINGLE Célibataire		DIVORCED Divorcé		PROTESTANT Protestant
	NEGROID Negriode		MARRIED Marié		SEPARATED Séparé		CATHOLIC Catholique
X	OTHER (Specify) Autre (Spécifier)		WIDOWED Veuf				JEWISH Juif
						X	OTHER (Specify) Autre (Spécifier)

NAME OF NEXT OF KIN Nom du plus proche parent	RELATIONSHIP TO DECEASED Parenté du décédé avec le sus
STREET ADDRESS Domicilié à (Rue)	CITY OR TOWN OR STATE *(Include ZIP Code* Ville (Code postal compris)

MEDICAL STATEMENT Déclaration médicale

CAUSE OF DEATH (Enter only one cause per line) Cause du décès (N'indiquer qu'une cause par ligne)		INTERVAL BETWEEN ONSET AND DEATH Intervalle entre l'attaque et le décès
DISEASE OR CONDITON DIRECTLY LEADING TO DEATH[1] Maladie ou condition directement responsable de la mort.[1]	Pending	
ANTECEDENT CAUSES Symptômes précurseurs de la mort. — MORBID CONDITION, IF ANY, LEADING TO PRIMARY CAUSE Condition morbide, s'il y a lieu, menant à la cause primaire		
ANTECEDENT CAUSES Symptômes précurseurs de la mort. — UNDERLYING CAUSE, IF ANY, GIVING RISE TO PRIMARY CAUSE Condition morbide, s'il y a lieu, menant à la cause primaire		
OTHER SIGNIFICANT CONDITIONS[2] Autres conditions significatives[2]		

MODE OF DEATH Condition de décès	AUTOPSY PERFORMED Autopsie effectuée [X] YES Oui [ ] NO Non	CIRCUMSTANCES SURROUNDING DEATH DUE TO EXTERNAL CAUSES Circonstances de la mort suscitées par des causes extérieures
NATURAL Mort naturelle	MAJOR FINDINGS OF AUTOPSY Conclusions principales de l'autopsie	Mode of Death : Pending
ACCIDENT Mort accidentelle		
SUICIDE Suicide	NAME OF PATHOLOGIST Nom du pathologiste: (b)(6)	
HOMICIDE Homicide	(b)(6) — DATE Date: 15 January 2006	AVIATION ACCIDENT Accident à Avion [ ] YES Oui [X] NO Non

DATE OF DEATH *(day, month, year)* Date de décès (le jour, le mois, l'année)	PLACE OF DEATH Lieu de décès
(b)(6) 2006	

I HAVE VIEWED THE REMAINS OF THE DECEASED AND DEATH OCCURRED AT THE TIME INDICATED AND FROM THE CAUSES AS STATED ABOVE.
J'ai examiné les restes mortels du dé funtet je conclus que le décès est survenu à l'heure indiquée et à, la suite des causes énumérées ci-dessus.

NAME OF MEDICAL OFFICER Nom du médicin militaire ou du médicin sanitaire	TITLE OR DEGREE Titre ou diplômé
(b)(6)	Medical Examiner
GRADE Grade: (b)(6)	INSTALLATION OR ADDRESS Installation ou adresse: Dover AFB, Dover DE
DATE Date: 18 JAN 06	(b)(6)

[1] State disease, injury or complication which caused death.
[2] State conditions contributing to the death, but not related t
[1] Préciser la nature de la maladie, de la blessure ou de la c
[2] Préciser la condition qui a contribué à la mort, mais n'ayant ... provoqué la mort.

DD FORM 1 APR 77 2064 REPLACES DA FORM 3565, 1 JAN 72 AND DA FORM 3565-R(PAS), 26 SEP 75, WHICH ARE OBSOLETE.

ARMED FORCES INSTITUTE OF PATHOLOGY
Office of the Armed Forces Medical Examiner
1413 Research Blvd., Bldg. 102
Rockville, MD 20850
301-319-0000

FINAL AUTOPSY EXAMINATION REPORT

Name: BTB Mohamed, Hamed Ali
ISN: (b)(6)
Date of Birth: (b)(6) 1952
Date of Death: (b)(6) 2006
Date of Autopsy: 15 FEB 2006 @ 1000
Date of Report: 29 JUN 2006

Autopsy No.: (b)(6)
AFIP No.: (b)(6)
Rank: Iraqi Civilian Detainee
Place of Death: Iraq
Place of Autopsy: Port Mortuary, Dover AFB, Dover, DE

Circumstances of Death: Reportedly, this Iraqi civilian detainee was assaulted by fellow detainees.

Authorization for Autopsy: Office of the Armed Forces Medical Examiner, IAW 10 USC 1471

Identification: Presumptive identification is established by accompanying identification tag and documentation. Fingerprints and DNA are taken to compare to exemplars when available.

CAUSE OF DEATH: **MULTIPLE BLUNT FORCE INJURIES**

MANNER OF DEATH: **HOMICIDE**

ACLU Detainee DeathII ARMY MEDCOM 641

FINAL AUTOPSY DIAGNOSES:

I. Multiple Blunt Force Injuries

A. Head and neck
1. Two abrasions of the forehead, 1 ¼ x 1-inch and ½ x ½-inch and located 1 ½-inches below the top of the head and ¼ left of the anterior midline to ½-inch right of the anterior midline of the head in the anatomic position; with associated subgaleal hemorrhage and multiple linear fractures of the right side of the frontal and right parietal bones
2. Contusion of the right orbit, 3 x 1 ½-inches
3. Subconjunctival hemorrhage
4. Discontinuous abrasion of the right cheek and nose, 1 x ½-inch and located 6-inches below the top of the head and 1-inch right of the anterior midline of the head in the anatomic position
5. Rectangular, patterned contusion of the right cheek, 3 x 2-inches located 6 ½-inches below the top of the head and 2 ¾-inches right of the anterior midline of the head in the anatomic position, with associated contusion of the buccal mucosa and fracture of the right zygoma
6. Discontinuous, irregular abrasion of the posterior scalp, 3 ¾ x 2-inches, located 2-inches below the top of the head and on the posterior midline of the head in the anatomic position
7. Two contusions of the anterior neck, ¼ x ¼-inch (located 10 ¾-inches below the top of the head and ½-inch left of the anterior midline of the neck in the anatomic position) and 1 x ½-inch (located 11 ½-inches below the top of the head and on the anterior midline of the neck in the anatomic position) and associated hemorrhage of the inferior aspect of the left sternohyoid muscle and hemorrhage of the right submandibular soft tissue
8. Acute subdural hemorrhage, left temporal region
9. Diffuse subarachnoid hemorrhage
10. Multiple contusions of the brain: right orbito-frontal region, left inferior temporal region, bilateral occipital lobes, bilateral cerebellar hemispheres

B. Torso
1. Irregular, outline patterned abrasion of the right chest, 4 x 3-inches, located 13 ¾-inches below the top of the head and 1 ¾-inches right of the anterior midline of the torso in the anatomic position, with an associated rectangular pattern 3 x 2-inch contusion 13 ¾-inches below the top of the head and 5 ½-inches right of the anterior midline of the head in the anatomic position
2. Abrasion of the upper left chest, 1 x ¼-inches, located 16 ½-inches below the top of the head and 1 ¾-inches left of the anterior midline of the torso in the anatomic position

ACLU Detainee DeathII ARMY MEDCOM 642

3. Irregular outline patterned abrasion of the lower left chest, 4 x 1 ¼-inches, located 19 ½-inches below the top of the head and 7-inches left of the anterior midline of the torso in the anatomic position
4. Linear abrasion of the lower left back, 4 ¾ x 1/8-inch, located 22 ½-inches below the top of the head and 6 ¾-inches left of the posterior midline of the torso in the anatomic position, with associated underlying soft tissue hemorrhage
5. Multiple left rib fractures: 2nd through 4th anterior, 2nd through 9th lateral and 2nd posterior left ribs with associated left hemothorax (400-milliliters of liquid blood)
6. Fracture of the body of the sternum
7. Hemorrhage of the soft tissues surrounding the second thoracic vertebra, bilaterally
8. Capsular hematoma of the inferior right lobe of the liver
9. Hemorrhage of the left peri-renal soft tissues

C. Extremities
1. Abrasion of the anterior right forearm, ¾ x ½-inch, located 7-inches below the elbow and ½-inch lateral to the anterior midline of the right upper extremity in the anatomic position, with an associated 2 x 1-inch ecchymosis
2. Contusion of the posterior right forearm, 1 x ¼-inch, located 5-inches below the elbow and 1 ¾-inches medial to the posterior midline of the right upper extremity in the anatomic position with associated soft tissue hemorrhage
3. Contusion of the dorsum of the left hand, 1 ¼ x ¾-inch, located 12 ¼-inches below the elbow and 1 ¼-inches lateral to the posterior midline of the left upper extremity in the anatomic position
4. Abrasion of the anterior right thigh, 1 x 1/8-inch, located 28 ¾-inches above the heel and 1-inch lateral to the anterior midline of the right lower extremity, with an associated 2 ½ x 2 ½-inch ecchymosis
5. Contusion of the medial right knee, ½ x ½-inch, located 17 ¾-inches above the heel and 4-inches medial to the anterior midline of the right lower extremity, with associated soft tissue edema
6. Cluster of abrasions of the proximal anterior right leg, ranging in size from 1/16-inch to ¼-inch and covering an area ½ x ¼-inch, located 14 ½-inches above the heel and on the anterior midline of the right lower extremity
7. Contusion of the medial right leg, 1 x ½-inch, located 13 ¾-inches above the heel and 3 ¾-inches medial to the anterior midline of the right lower extremity
8. Contusion of the right popliteal fossa, 7 ¼ x 4 ¼-inches, located 14 ¼-inches above the heel and 1-inch medial to the posterior midline of the right lower extremity with associated soft tissue hemorrhage into the posterior thigh
9. Faint contusion of the left knee, 1 x 1-inch, located 17 ½-inches above the heel and 3-inches medial to the anterior midline of the left lower extremity

ACLU Detainee DeathII ARMY MEDCOM 643

10. Square 2 x 2 patterned contusion of the left popliteal fossa, 4 ¼ x 4-inches, located 15 ¾-inches above the heel and on the posterior midline of the left lower extremity
11. Fractures of the medial condyle of the right humerus and olecranon process of the right ulna with associated soft tissue edema and ecchymoses of the right elbow (4 x 2 ½-inches) and right antecubital fossa (3 ¾ x 3 ½-inches)
12. Fracture of the olecranon process of the left ulna with associated soft tissue edema and 4 ¾ x 4-inch ecchymosis of the left antecubital fossa

II. Natural Disease

A. Mild to moderate anthracosis
D. Severe two-vessel coronary atherosclerosis
   1. The proximal left anterior coronary artery has 90% luminal narrowing
   2. The proximal right coronary artery has 75% luminal narrowing
B. Moderate atherosclerosis of the abdominal aorta
C. Mild hepatic steatosis
D. Bilateral nephrosclerosis (gross)
E. Cyst of the left kidney

III. Evidence of Medical Intervention

A. Endotracheal tube
B. Cardiac monitor leads: both shoulders, left lateral torso, abdomen, and both thighs
C. Urinary bladder catheter
D. Triple lumen catheter, right groin
E. Splints with elastic wraps, both upper extremities
F. Double lumen catheter, right hand

IV. Minimal decomposition

V. Toxicology

A. The blood is tested for carboxyhemoglobin and none is found
B. The blood is tested for cyanide and none is found
C. The blood and vitreous fluid are tested for ethanol and none is found
D. The blood is screened for medications and drugs of abuse and Atropine is detected but is not quantitated in the blood

EXTERNAL EXAMINATION

The body is that of a well-developed, well-nourished appearing 68-inch, 146-pound male whose appearance is consistent with the reported age of 53 years. Lividity is posterior and fixed. Rigor is equal in all extremities, and the temperature is that of the refrigeration unit.

ACLU Detainee DeathII ARMY MEDCOM 644

The scalp is covered with short gray hair in a male pattern baldness distribution. The irides are blue, the pupils are round and equal in diameter and the corneas are cloudy. There is subconjunctival hemorrhage present at the right lateral canthus. The external auditory canals are clear. The ears are unremarkable. The nares are patent and the lips are atraumatic. The nose and maxillae are palpably stable. The teeth appear natural and in fair condition, with remote loss of the left upper central incisor.

The neck is straight, and the trachea is midline and mobile. The chest is asymmetric. The abdomen is flat. The genitalia are those of a normal adult male. The testes are descended and free of masses. Pubic hair is present in a normal distribution. The buttocks and anus are unremarkable.

The upper and lower extremities are symmetric and without clubbing or edema.

CLOTHING AND PERSONAL EFFECTS

The following clothing items and personal effects are present on the body at the time of autopsy:

- Blue hospital gown

MEDICAL INTERVENTION

- Endotracheal tube
- Cardiac monitor leads: both shoulders, left lateral torso, abdomen, and both thighs
- Urinary bladder catheter
- Triple lumen catheter, right groin
- Splints with elastic wraps, both upper extremities
- Double lumen catheter, right hand

RADIOGRAPHS

A complete set of postmortem radiographs is obtained and demonstrates the following:

- Fracture of the right zygomatic process
- Fractures of the right side of the frontal bone and the right parietal bone
- Multiple left rib fractures
- Fractures of the olecranon process of the right ulna and the medial condyle of the right humerus
- Fracture of the olecranon process of the left ulna

EVIDENCE OF INJURY

The ordering of the following injuries is for descriptive purposes only, and is not intended to imply order of infliction or relative severity.

ACLU Detainee DeathII ARMY MEDCOM 645

I. Blunt Force Injuries

A. Head and Neck

There are two abrasions of the right forehead which measure 1 ¼ x 1-inch and ½ x ½-inch and are located 1 ½-inches below the top of the head and ¼-inch left to ½-inch right of the anterior midline of the head in the anatomic position. Underlying these abrasions is galeal and subgaleal hemorrhage and multiple linear fractures of the right side of the frontal and right parietal bones. There are multiple contusions of the brain that are located in the right orbito-frontal region, the left inferior temporal region, both occipital lobes and both cerebellar hemispheres. There is a small (less than 5-milliliters) subdural hematoma overlying the left temporal lobe, and a diffuse subarachnoid hematoma that is distributed over the superior cerebral hemispheres bilaterally.

There is a 3 x 2-inch rectangular, patterned contusion of the right cheek, located 6 ½-inches below the top of the head and 2 ¾-inches right of the anterior midline of the head in the anatomic position, with associated contusion of the buccal mucosa and fracture of the right zygomatic process. There is a 1 x ½-inch discontinuous abrasion of the right cheek and nose, located 6-inches below the top of the head and 1-inch right of the posterior midline of the head in the anatomic position. There is a 3 x 1 ½-inch right periorbital contusion with an associated subconjunctival hemorrhage at the right lateral canthus. There is a discontinuous, 3 ¾ x 2-inch irregular abrasion of the posterior scalp, located 2-inches below the top of the head and on the posterior midline of the head in the anatomic position.

There are two contusions of the anterior neck which measure 1 x ½-inch (located 11 ½-inches below the top of the head and on the anterior midline of the neck in the anatomic position) and ¼ x ¼-inch (located 10 ¾-inches below the top of the head and ½-inch left of the anterior midline of the neck in the anatomic position). Associated with these contusions are hemorrhage of the inferior aspect of the left sternohyoid muscle and hemorrhage of the right submandibular soft tissue

B. Torso

There is a faint, 1 x ¼-inch abrasion on the left chest, located 16 ½-inches below the top of the head and 1 ¾-inches left of the anterior midline. On the lower left chest, located 19 ½-inches below the top of the head and 7-inches left of the anterior midline, is a 4 x 1 ¼-inch irregular outline patterned abrasion. There is a 4 x 3-inch irregular outline patterned abrasion on the right chest located 13 ¾-inches below the top of the head and 1 ¾-inches right of the anterior midline, with an associated rectangular pattern 3 x 2-inch contusion located 13 ¾-inches below the top of the head and 5 ½-inches right of the anterior midline of the torso in the anatomic position. On the left back, located 22 ½-inches below the top of the head and 6 ¾-inches left of the

ACLU Detainee DeathII ARMY MEDCOM 646

posterior midline, is a 4 ¾ x 1/8-inch linear abrasion with underlying subcutaneous hemorrhage.

The left chest is externally markedly deformed with multiple underlying rib fractures; the 2nd through 4th anterior left ribs (cannot exclude medical intervention), the 2nd through 9th lateral left ribs and the 2nd posterior left rib are fractured with associated left hemothorax (400-milliters of liquid blood). The body of the sternum is fractured (cannot exclude medical intervention). There is a small capsular hematoma of the inferior right lobe of the liver, and there is a small left peri-renal soft tissue hemorrhage. There is focal soft tissue hemorrhage of the back at the level of the 2nd thoracic vertebra.

C. Extremities

1. Right Upper Extremity
   There are fractures of the medial condyle of the right humerus and the olecranon of the right ulna with associated soft tissue edema and a 4 x 2 ½-inch ecchymosis. There is also a 3 ¾ x 3 ½-inch ecchymosis in the right antecubital fossa, located 12 ¾-inches below the top of the shoulder and on the anterior midline of the right upper extremity.

   On the anterior right forearm, located 7-inches below the elbow and ½-inch lateral to the anterior midline of the forearm is a ¾ x ½-inch abrasion and associated 2 x1-inch ecchymosis. There is a 1 x ¼-inch contusion on the posterior right forearm, located 5-inches below the elbow and 1 ¾-inches medial to the posterior midline of the right forearm and associated soft tissue hemorrhage.

2. Left Upper Extremity
   There is a fracture of the proximal left ulna (olecranon) with associated soft tissue edema. There is also a 4 ¾ x 4-inch ecchymosis in the left antecubital fossa, located 12 ¼-inches below the top of the shoulder and on the anterior midline of the left upper extremity.

   There is a 1 ¼ x ¾-inch contusion on the dorsum of the left hand, located 12 ¼-inches below the elbow and 1 ¼-inch lateral to the posterior midline of the left upper extremity.

3. Right Lower Extremity
   There is a 1 x 1/8-inch abrasion on the anterior right thigh, located 28 ¾-inches above the heel and 1-inch lateral to the anterior midline of the right lower extremity; there is also a 2 ½ x 2 ½-inch ecchymosis associated with this abrasion. On the medial surface of the right knee, there is a ½ x ½-inch contusion located 17 ¾-inches above the heel and 4-inches medial to the anterior midline of the right lower extremity.

ACLU Detainee DeathII ARMY MEDCOM 647

On the proximal anterior right leg, there is a cluster of abrasions which range in size from 1/16 to ¼-inch covering an area of ½ x ¼-inch, located 14 ½-inches above the heel and on the anterior midline of the right lower extremity. On the medial right leg, there is a 1 x ½-inch contusion located 13 ¾-inches above the heel and 3 ¾-inches medial to the anterior midline of the right lower extremity.

In the right popliteal fossa, there is a 7 ¼ x 4 ¼-inch contusion located 14 ¼-inches above the heel and 1-inch medial to the posterior midline of the right lower extremity.

4. Left Lower Extremity
There is a 1 x 1-inch faint contusion with a faint pattern on the medial left knee, located 17 ½-inches above the heel and 3-inches medial to the anterior midline of the left lower extremity.

In the left popliteal fossa, there is a 4 ¼ x 4-inch contusion with a square 2 x 2 pattern located 15 ¾-inches above the heel and on the posterior midline of the left lower extremity.

INTERNAL EXAMINATION

HEAD:
Injuries to the head are described above (see "Evidence of Injury, I.A." above). The brain weighs 1,340-grams and is submitted for Neuropathology consultation. See the attached Neuropathology consult addendum for complete details.

NECK:
Layer-wise dissection reveals that the anterior strap muscles of the neck are homogenous and red-brown; there is hemorrhage at the base of the left sternohyoid muscle. The thyroid cartilage and hyoid bone are intact. The larynx is lined by intact white mucosa. The thyroid gland is symmetric and red-brown, without cystic or nodular change. The tongue is free of bite marks, hemorrhage, or other injuries.

Incision and dissection of the posterior neck demonstrates no deep paracervical muscular injury and no cervical spine fractures.

BODY CAVITIES:
The vertebral bodies are visibly and palpably intact. Injuries and changes involving the ribs, sternum and left pleural cavity are described above (see "Evidence Injury, I.B."). There is no excess fluid is in the right pleural, pericardial, or peritoneal cavities. The organs occupy their usual anatomic positions.

RESPIRATORY SYSTEM:
The right and left lungs weigh 590 and 610-grams, respectively. The external surfaces are smooth and deep red-purple. The pulmonary parenchyma is diffusely congested and

ACLU Detainee DeathII ARMY MEDCOM 648

edematous with anthracotic pigment. No mass lesions or areas of consolidation are present.

CARDIOVASCULAR SYSTEM:
The 430-gram heart is submitted for Cardiovascular Pathology consultation. See the attached Cardiovascular Pathology consult addendum for complete details.

LIVER & BILIARY SYSTEM:
The 1,170-gram liver has an intact, smooth capsule and a sharp anterior border. The parenchyma is yellow-tan to brown and congested, with the usual lobular architecture. Injury to the liver is described above (see "Evidence of Injury, I.B."). The gallbladder contains a minute amount of green-black bile and no stones. The mucosal surface is green and velvety. The extrahepatic biliary tree is patent.

LYMPHORETICULAR SYSTEM:
The 170-gram spleen has a smooth, intact, red-purple capsule. The parenchyma is maroon and congested, with distinct Malpighian corpuscles. The regional lymph nodes appear normal in size; the carinal lymph nodes contain anthracotic pigment.

PANCREAS:
The pancreas is firm and yellow-tan, with the usual lobular architecture. No mass lesions or other abnormalities are seen.

ADRENALS:
The right and left adrenal glands are symmetric, with bright yellow cortices and grey medullae. No masses or areas of hemorrhage are identified.

GENITOURINARY SYSTEM:
The right and left kidneys weigh 120 and 110-grams, respectively. Injuries to the kidneys are described above (see "Evidence of Injury, I.B"). The external surfaces are intact and granular, with a fluid-filled cyst at the left upper pole. The cut surfaces are red-tan and congested, with uniformly thick cortices and sharp cortico-medullary junctions. The pelves are unremarkable and the ureters are normal in course and caliber. Pink-grey bladder mucosa overlies an intact bladder wall. The bladder contains no urine. The prostate gland is normal in size, with lobular, yellow-tan parenchyma. The seminal vesicles are unremarkable. The testes are free of mass lesions, contusions, or other abnormalities.

GASTROINTESTINAL TRACT:
The esophagus is intact and lined by smooth, grey-white mucosa. The stomach contains approximately 50-milliliters of brown fluid. The gastric wall is intact. The duodenum, loops of small bowel and colon are unremarkable. The appendix is present.

MUSCULOSKELETAL SYSTEM:
No non-traumatic abnormalities of the muscles, bones or joints are noted.

ACLU Detainee DeathII ARMY MEDCOM 649

MICROSCOPIC EXAMINATION

Selected portions of organs are retained in formalin.

BRAIN:

See the attached Neuropathology consult addendum for complete details.

HEART:

See the attached Cardiovascular Pathology consult addendum for complete details.

ADDITIONAL PROCEDURES

- Documentary photographs are taken by AFMES photographers
- Specimens retained for toxicological testing and/or DNA identification are: vitreous, blood, spleen, liver, lung, kidney, bile, gastric contents, adipose tissue and psoas muscle
- The body is sutured closed without embalming and the dissected organs are forwarded with body
- There are no personal effects

ACLU Detainee DeathII ARMY MEDCOM 650

OPINION

This 53-year-old Iraqi civilian detainee (b)(6) died as a result of multiple blunt force injuries he received in unclear circumstances. Severe injuries to the head, torso and extremities were present in locations which are unlikely to have been self-inflicted or in an accidental manner. Both elbow joints were fractured in an unusual manner (olecrenon fractures) that suggests deliberate assault by another person or persons. Contusion and soft tissue hemorrhage of the right forearm suggests that the deceased was bound around the time the injuries were inflicted; at least 20 separate and distinct blunt force injuries are observed. Toxicological testing was negative for ethanol, carboxyhemoglobin, cyanide and drugs of abuse. Atropine (a medication used in resuscitation procedures) was detected but not quantitated in the blood. The manner of death is homicide.

(b)(6)

(b)(6) **Medical Examiner**

(b)(6)

(b)(6) **Medical Examiner**

ACLU Detainee DeathII ARMY MEDCOM 651

ADDENDUM 1: NEUROPATHOLOGY CONSULTATION REPORT
(PAGE 1 OF 2)

This material was reviewed in conference on 1 Jun 06.

Brain, autopsy: Multifocal traumatic injuries: 1.Hemorrhagic contusions, acute, right orbito-frontal region, left inferior temporal gyrus, bilateral occipital lobes, and bilateral cerebellar hemispheres.
2. Subarachnoid hemorrhage, acute, diffuse.
3. Subdural hematoma, acute, left temporal region.
4. Arteriolosclerosis, mild.
5. Hypoxic/ischemic changes.

We examined the approximately 1350-gram formalin-fixed brain submitted in reference to this case.

Slightly adherent subdural hemorrhage is noted in the area of the left temporal lobe. Subarachnoid hemorrhage is present over the convexities of the cerebral hemispheres. Diffuse, mild gyral flattening and sulcal narrowing is noted over both cerebral hemispheres; otherwise, the gyral pattern is normal. The cranial nerves are unremarkable. The circle of Willis was dissected from the base of the brain and found to have a normal adult configuration without aneurysms, significant atherosclerosis, or sites of occlusion. Cortical contusions are identified as follows: a 1.5 x 0.8 cm lesion involving the right anterior gyrus rectus and olfactory sulcus with focal extension into the medial, inferior frontal pole; a 0.8 x 0.8 cm contusion on the right orbital surface; a 1.5 x 1 cm lesion on the inferior-lateral surface of the left inferior temporal gyrus; a 6 x 4 cm left occipital lobe lesion, which extends into the occipital pole; multifocal contusions on the right occipital pole, ranging in size from 0.4 cm to 2.0 cm; a 3 x 2 cm left cerebellar lesion; and a 4 x 2 cm right cerebellar contusion. There is no evidence of tonsillar, uncal, or subfalcine herniation. The brainstem is unremarkable.

ACLU Detainee DeathII ARMY MEDCOM 652

ADDENDUM 1: NEUROPATHOLOGY CONSULTATION REPORT (PAGE 2 OF 2)

Serial coronal sections of the cerebrum confirm the presence of the previously described contusions; otherwise, the cortical ribbon is of normal thickness, well demarcated from subjacent white matter. A focal area of dusk discoloration is identified in the medial left occipital lobe cerebral cortex. Myelination is normal. The ventricular system is normal shape and size. The basal ganglia, hippocampi, thalami, and hypothalamus are unremarkable. Serial sectioning of the cerebellum reveals diffuse dusky discoloration of the folia and confirms the presence of the previously described contusions. The substantia nigra and locus ceruleus are normally pigmented for age. The aqueduct is slit-like. The spinal cord is not submitted, but the uppermost cervical cord and cervicomedullary junction are unremarkable.

Summary of microscopic sections: 1. Right gyrus rectus contusion. 2. Right orbital-frontal contusion. 3. Right superior frontal gyrus subarachnoid hemorrhage. 4. Left superior parietal subarachnoid hemorrhage. 5. Left inferior temporal gyrus contusion. 6. Left occipital lobe contusion. 7. Right occipital lobe contusion. 8. Left medial occipital lobe. 9. Left caudate/putamen. 10. Left putamen/globus pallidus. 11. Thalamus. 12. Left corpus callosum and periventricular area. 13. Left hippocampus. 14. Midbrain. 15. Pons. 16. Cerebellum. 17. Right cerebellar contusion. 18. Left cerebellar contusion. 19. Medulla. 20. Cervicomedullary junction. 21. Dura.

The tissue was processed in paraffin; a section prepared from each paraffin block was stained with H&E.

Microscopic sections from the left dura demonstrate intact red cells on the subdural surface, consistent with an acute subdural hemorrhage. Sections from the right superior frontal gyrus, left superior parietal lobe, mamillary body, left inferior temporal lobe, cerebellum, and brainstem show intact red cells without an associated inflammatory reaction within the leptomeninges, corresponding to acute subarachnoid hemorrhage.

Sections from the right orbital-frontal region, left temporal lobe, and bilateral occipital lobes demonstrate acute hemorrhage and vacuolation within the cerebral cortex, consistent with acute cortical contusions and associated edema. Scattered hypereosinophilic neurons are noted, which are indicative of acute hypoxic/ischemic neuronal injury. Rare Hirano bodies and granulovacuolar degeneration are identified in the left hippocampus, consistent with non-specific neurodegenerative changes. Arteriolosclerosis with associated scattered perivascular hemosiderin- laden macrophages is also noted.

Sections from both cerebellar hemispheres show acute hemorrhage and focal collections of neutrophils within the folia, consistent with acute contusions. Hypereosinophilic Purkinje cells are identified corresponding to hypoxic/ischemic changes.

(b)(6)

ACLU Detainee DeathII ARMY MEDCOM 653

ADDENDUM 2: CARDIOVASCULAR PATHOLOGY CONSULTATION REPORT (PAGE 1 OF 1)

FINAL DIAGNOSIS

DIAGNOSIS: (b)(6) **Heart, post mortem examination: Severe coronary atherosclerosis, two vessel disease, 90% luminal narrowing of proximal left anterior descending artery with healed plaque rupture and 75% narrowing of proximal right coronary artery**

History: Iraqi male detainee, date of birth unknown; sternal and rib fractures, rule out myocardial contusions

Heart: 425 grams; normal epicardial fat with no contusions seen on the external surface of the heart; closed foramen ovale; normal cardiac chamber dimensions: left ventricular cavity diameter 30 mm, left ventricular free wall thickness 14 mm, ventricular septum thickness 14 mm, right ventricle thickness 4 mm, without gross scars or abnormal fat infiltrates; valves and endocardium grossly unremarkable; no gross myocardial necrosis or fibrosis; histologic sections show mild left ventricular myocyte hypertrophy with focal interstitial and replacement fibrosis, focal myofiber disarray and rare basophilic degeneration of myocytes

Coronary arteries: Normal ostia; right dominance; focally severe coronary atherosclerosis

Left anterior descending artery (LAD): 90% narrowing of proximal LAD by fibrocalcific plaque with healed plaque rupture

Right coronary artery (RCA): 75% narrowing of proximal RCA by fibroatheromatous plaque

(b)(6)

Staff pathologist

Blocks made: 7 (5 heart, 2 coronary arteries)
Slides made: 9 (7 H&E, 2 Movat)

ACLU Detainee DeathII ARMY MEDCOM 654

CERTIFICATE OF DEATH *(OVERSEAS)*
Acte de décès (D'Outre-Mer)

NAME OF DECEASED (Last, First, Middle) Nom du décédé (Nom et prénoms)	GRADE Grade	BRANCH OF SERVICE Arme	SOCIAL SECURITY NUMBER Numéro de l'Assurance Social
BTB Mohamed, Hamed Ali,		Civilian	(b)(6)
ORGANIZATION Organisation	**NATION** (e.g. United States) Pays	**DATE OF BIRTH** Date de naissance	**SEX** Sexe
	Iraq	(b)(6) 1952	[X] MALE [ ] FEMALE

RACE Race		MARITAL STATUS État Civil		RELIGION Culte	
[X]	CAUCASOID Caucasique	[ ]	SINGLE Célibataire	[ ]	PROTESTANT Protestant
[ ]	NEGROID Negroide	[ ]	MARRIED Marié	[ ]	CATHOLIC Catholique
[ ]	OTHER (Specify) Autre (Spécifier)	[ ]	WIDOWED Veuf	[ ]	JEWISH Juif
		[ ]	DIVORCED Divorcé	[X]	OTHER (Specify) Autre (Spécifier)
		[ ]	SEPARATED Séparé		

NAME OF NEXT OF KIN Nom du plus proche parent	RELATIONSHIP TO DECEASED Parenté du décédé avec le sus
STREET ADDRESS Domicile & (Rue)	CITY OR TOWN OR STATE (Include ZIP Code Ville (Code postal compris)

MEDICAL STATEMENT Déclaration médicale

CAUSE OF DEATH (Enter only one cause per line) Cause du décès (N'indiquer qu'une cause par ligne)			INTERVAL BETWEEN ONSET AND DEATH Intervalle entre l'attaque et le décès
DISEASE OR CONDITION DIRECTLY LEADING TO DEATH [1] Maladie ou condition directement responsable de la mort.		Pending	
ANTECEDENT CAUSES Symptômes précurseurs de la mort	MORBID CONDITION, IF ANY, LEADING TO PRIMARY CAUSE Condition morbide, s'il y a lieu, menant à la cause primaire		
	UNDERLYING CAUSE, IF ANY, GIVING RISE TO PRIMARY CAUSE Condition morbide, s'il y a lieu, menant à la cause primaire		
OTHER SIGNIFICANT CONDITIONS [2] Autres conditions significatives [2]			

MODE OF DEATH Condition de décès	AUTOPSY PERFORMED Autopsie effectuée	CIRCUMSTANCES SURROUNDING DEATH DUE TO EXTERNAL CAUSES Circonstances de la mort suscitées par des causes extérieures
[ ] NATURAL Mort naturelle	[X] YES Oui [ ] NO Non	Mode of Death : Pending
[ ] ACCIDENT Mort accidentelle	MAJOR FINDINGS OF AUTOPSY Conclusions principales de l'autopsie	
[ ] SUICIDE Suicide	NAME OF PATHOLOGIST Nom du pathologiste (b)(6)	
[ ] HOMICIDE Homicide	(b)(6) DATE Date 15 February 2006	AVIATION ACCIDENT Accident à Avion [ ] YES Oui [X] NO Non

DATE OF DEATH (day, month, year) Date de décès (le jour, le mois, l'année) (b)(6) 2006 PLACE OF DEATH Lieu de décès

I HAVE VIEWED THE REMAINS OF THE DECEASED AND DEATH OCCURRED AT THE TIME INDICATED AND FROM THE CAUSES AS STATED ABOVE.
J'ai examiné les restes mortels du dé funt/e je conclus que le décès est survenu à l'heure indiquée et à, la suite des causes énumérées ci-dessus.

NAME OF MEDICAL OFFICER Nom du médecin militaire ou du médecin sanitaire	TITLE OR DEGREE Titre ou diplôme
(b)(6)	Medical Examiner
GRADE Grade (b)(6)	**INSTALLATION OR ADDRESS** Installation ou adresse Dover AFB, Dover DE
DATE Date 03 MAY 06	(b)(6)

[1] State disease, injury or complication which caused death
[2] State conditions contributing to the death, but not related
[1] Préciser la nature de la maladie, de la blessure ou de la complication qui a contribué à la mort mais non la maladie qui a causé la mort, telle qu'un arrêt du coeur, etc
[2] Préciser la condition qui a contribué à la mort, mais n'ayant aucun rapport avec la maladie ou à la condition qui a provoqué la mort.

DD FORM 1 APR 77 2064 REPLACES DA FORM 3565, 1 JAN 72 AND DA FORM 3565-R(PAS), 26 SEP 75, WHICH ARE OBSOLETE.

ARMED FORCES INSTITUTE OF PATHOLOGY
Office of the Armed Forces Medical Examiner
1413 Research Blvd., Bldg. 102
Rockville, MD 20850
301-319-0000

AUTOPSY REPORT

Name: RAZZAK, Abdul
ISN: (b)(6)
Date of Birth: not known
Date of Death: (b)(6) 2007
Place of Death: Naval Hospital Guantanamo Bay, Cuba
Place of Autopsy: Naval Hospital Guantanamo Bay, Cuba

Autopsy No.: (b)(6)
AFIP No.: (b)(6)
Rank: Civilian

Date and time of Autopsy: 30 DEC 2007 12:00 AM
Date of Report: 20 FEB 2008

Circumstances of Death: This detainee succumbed to multi-system organ failure complicating metastatic colon cancer despite appropriate adjuvant therapy

Authorization for Autopsy: Office of the Armed Forces Medical Examiner, IAW 10 USC 1471

Identification: presumptive identity is established by continuous maintenance in custody from time of apprehension

CAUSE OF DEATH: MULTISYSTEM ORGAN FAILURE DUE TO CARCINOMATOSIS

MANNER OF DEATH: NATURAL

EXTERNAL EXAMINATION

The body is that of a normally developed, cachectic appearing male, 65 inches long, weighing an estimated 110 pounds, and older in appearance than the recorded age of 60 years. Lividity is posterior. Rigor is resolving. The body is cool to touch.

Gray-black hair up to 1/2 inch in length covers the scalp in the usual male pattern of distribution. The sclerae are icteric; the irides are brown; and the pupils are round, 0.3 cm and equal in diameter. The external auditory canals are clear; the ears are unremarkable. The nares are patent and the lips are atraumatic. The nose and maxillae are palpably stable. A gray-black moustache and full beard are present. The teeth are worn, and a prosthodontic appliance is appropriately positioned where teeth are missing.

The neck is straight, and the trachea is midline and mobile. The chest is symmetric. The abdomen is scaphoid. An obliquely oriented 1-1/2 inch scar is noted on the surface of the right lower abdominal quadrant. Additionally, grouped petechiae are present over the right lower quadrant. Grouped petechiae are also present over the back and are aggregated into three large groups ranging from 2 x 1 inch up to 14 x 5 inches. Within the groups, petechiae vary in configuration from individual punctate lesions to coalescent foci. The genitalia are those of a normal adult circumcised male. The testes are descended and free of masses. Pubic hair is present in the usual male distribution. The buttocks and anus are unremarkable.

The upper and lower extremities are symmetric. Petechiae are present in the left antecubital fossa. There are no palpable cords in the popliteal fossae. There is mild edema of the hands and feet.

CLOTHING AND PERSONAL EFFECTS

The following clothing items and personal effects are present on the body at the time of autopsy:

- white robe

MEDICAL INTERVENTION

Sites of EKG lead placement shaved
EKG leads appropriately deployed over the precordium
Intravenous access site, dorsal right hand
Presumptive venipuncture site right antecubital fossa (taped 2 x 2 inch gauze sponge, right antecubital fossa
Hospital identification band on left wrist
Hospital identification band on right ankle
Medical chart entries documenting inpatient and outpatient care, including chemotherapy
For pain and nausea control agents identified, see "Toxicology"

ACLU Detainee DeathII ARMY MEDCOM 657

RADIOGRAPHS

A complete set of postmortem radiographs is obtained. The results are consistent with the findings described herein.

INTERNAL EXAMINATION

HEAD:
The galeal and subgaleal soft tissues of the scalp are free of injury. The calvarium is intact, as is the dura mater beneath it. The cerebral blood vessels are unremarkable. Clear cerebrospinal fluid surrounds the 1324 gm brain, which has unremarkable gyri and sulci. Coronal sections demonstrate sharp demarcation between white and grey matter, without hemorrhage or contusive injury. The ventricles are of normal size. The basal ganglia, brainstem, cerebellum, and arterial systems are free of injury or other abnormalities. There are no skull fractures. The atlanto-occipital joint is stable.

NECK:
On layer-wise dissection of the anterior and posterior neck, there is no hemorrhage or other evidence of trauma. The anterior strap muscles of the neck are homogenous and red-brown. The thyroid cartilage and hyoid are intact. The larynx is lined by intact white mucosa. The thyroid is symmetric and red-brown, without cystic or nodular change. The tongue is free of bite marks, hemorrhage, or other injuries.

BODY CAVITIES:
The ribs, sternum, and vertebral bodies are visibly and palpably intact. There are 40 cc of straw-colored fluid in the right pleural space and 60 cc in the left. In excess of 600 cc of fluid is found in the peritoneal cavity. There is no excess fluid is in the pericardial sac. The organs occupy their usual anatomic positions.

RESPIRATORY SYSTEM:
Dense adhesions envelop the lungs and tether them to the parietal pleural surfaces. The underlying lung surfaces are heavily anthracotic. The lungs are markedly edematous with deep purple congested cut surfaces: the right lung weighs 1145 gm, and the left lung weighs 782 gm. Nodular densities described as being seen in clinical (pre-mortem) imaging studies are not evident grossly.

CARDIOVASCULAR SYSTEM:
The 270 gm heart is contained in an intact pericardial sac. The epicardial surface is smooth, with minimal fat investment. The coronary arteries are present in a normal distribution, with a right-dominant pattern. Cross section of the vessels shows negligible focal atheromatous narrowing. The myocardial cut surface is uniformly dark brown. The valve leaflets are thin and mobile. The walls of the left and right ventricles are 1.0 and 0.3 cm thick, respectively. The endocardium is smooth and glistening. The aorta gives rise to three intact and patent arch vessels. The renal and mesenteric vessels are unremarkable.

ACLU Detainee DeathII ARMY MEDCOM 658

LIVER & BILIARY SYSTEM:
The 3400 gm liver is markedly distorted by multiple gray tan nodular masses, ranging from less than 1/16 inch up to 7 inches in maximal dimension. The residual hepatic parenchyma is focally compressed and stained yellow. The gallbladder contains a 50 cc of viscous green-black bile. There are no stones. The mucosal surface is green and velvety. The extrahepatic biliary tree is patent.

SPLEEN:
The 108 gm spleen has a thickened fibrous capsule, with focal gray tan discoloration of the usual red-purple capsule. The parenchyma is maroon and congested, with distinct Malpighian corpuscles.

PANCREAS:
The pancreas is firm and yellow, with prominent lobulation.. No mass lesions or other abnormalities are seen.

ADRENALS:
The right and left adrenal glands are symmetric, with bright yellow cortices and grey medullae. No masses or areas of hemorrhage are identified.

GENITOURINARY SYSTEM:
The right and left kidneys weigh 120 and 130 gm, respectively. The external surfaces are intact and smooth except for a 0.4 cm cortical cyst of the right kidney, with red-tan cut surfaces, uniformly thick cortices and sharp corticomedullary junctions. The pelves are unremarkable and the ureters are normal in course and caliber. White bladder mucosa overlies an intact bladder wall. The urinary bladder contains less than 200 cc of clear amber urine. The prostate is normal in size, with lobular, yellow-tan parenchyma. The seminal vesicles are unremarkable. The testes are free of mass lesions, contusions, or other abnormalities.

GASTROINTESTINAL TRACT:
The esophagus is intact and lined by smooth, grey-white mucosa. The stomach contains in excess of 100 cc of partially digested food. The gastric wall is intact. The duodenum and loops of small bowel are unremarkable. On section of the recto-sigmoid colon, a 2.9 cm tumor mass is identified on the mucosal surface and grossly appears to extend into the surrounding pericolic tissue, and includes a firm 1.4 cm nodular structure grossly consistent with a lymph node. The remaining colon is unremarkable. The appendix appears to have been partially amputated in the remote past.

MUSCULOSKELETAL SYSTEM:
Muscle development is normal. No bone or joint abnormalities are noted.

ACLU Detainee DeathII ARMY MEDCOM 659

MICROSCOPIC EXAMINATION

Central Nervous System (slides 5 & 6):

No significant histopathologic alteration

Liver (slide 1):

Metastatic adenocarcinoma, moderate-to-poorly differentiated

Hematopoietic- Lymphoid incl. Spleen (slides 2 & 3):

1. **Regional lymph node positive for Metastatic adenocarcinoma, moderate-to-poorly differentiated**
2. **Spleen: no significant histopathologic alteration**

Gastro-Intestinal (slides 2 & 8):

1. **Recto-sigmoid colon (site of primary tumor): moderate-to-poorly differentiated adenocarcinoma, with extension into pericolic adipose tissue**
2. **Gastro-intestinal tissue remote from primary tumor:**
   a. **No significant histopathologic alteration**
   b. **Diffuse autolytic change**

Heart (slide 4):

No significant histopathologic alteration

Lung (slide 3):

No significant histopathologic alteration

Genito-urinary (7):

No significant histopathologic alteration

Endocrine (slide 7):

No significant histopathologic alteration

ADDITIONAL PROCEDURES

1. Documentary photographs are taken by OAFME staff photographers.
2. Specimens retained for toxicologic testing and/or DNA identification are: vitreous fluid, blood, bile, gastric contents, urine, brain, lung, liver, kidney, spleen, skeletal muscle and adipose tissue.
4. The dissected organs are forwarded with body.
5. Personal effects are released to the appropriate mortuary operations representatives.

ACLU Detainee DeathII ARMY MEDCOM 660

AUTOPSY DIAGNOSES

I. Evidence of Multi-system Organ Failure

A. Hepatic failure
   1. Scleral icterus
   2. Features of bleeding diathesis
   3. Ascites

B. Cardiac failure
   1. Edema of hands and feet
   2. Bilateral pulmonary effusions

II. Primary Colo-rectal Tumor

A. Tumor: 2.9 cm in maximal dimension
B. Tumor extends through mucosa into pericolic fat
C. Evidence of regional lymph node involvement
D. Stage IV: T4, N1, M1 (AJCC 6th edition)

III. Metastatic Tumor Spread

A. Multiple liver nodules identified at postmortem examination
B. Clinical (radiographic) evidence of metastatic tumor nodules in the lungs

IV. Pre-existing medical Conditions

Multiple dense pleural adhesions, bilateral

V. Evidence of Medical Intervention

A. Sites of EKG lead placement shaved
B. EKG leads appropriately deployed over the precordium
C. Appropriate EKG lead placement
D. Intravenous access site, dorsal right hand
E. Presumptive venipuncture site right antecubital fossa
F. Hospital identification band on left wrist
G. Hospital identification band on right ankle
H. Medical chart entries documenting inpatient and outpatient care, including chemotherapy

VI. Identifying Features

A. Well healed surgical scar, right lower abdominal quadrant
B. Dental bridge replaces teeth 7 - 10

ACLU Detainee DeathII ARMY MEDCOM 661

VII. Toxicology

A. Blood and vitreous are negative for ethanol

B. Urine was screened for acetaminophen, amphetamine, antidepressants, antihistamines, barbiturates, benzodiazepines, cannabinoids, chloroquine, cocaine, dextromethorphan, lidocaine, narcotic analgesics, opiates, phencyclidine, phenothiazines, salicylates, sympathomimetic amines and verapamil by gas chromatography, color test or immunoassay. The following drugs were detected

1. acetaminophen was detected in the urine by immunoassay and confirmed by color test. No acetaminophen was detected in the blood at a limit of quantitation of 5 mg/L using immunoassay.
2. oxycodone was detected in the urine by immunoassay and confirmed by gas chromatography/mass spectrometry. The blood contained 0.10 mg/L of oxycodone as quantitated by gas chromatography/mass spectrometry
3. oxymorphone was detected in the urine by immunoassay and confirmed by gas chromatography/mass spectrometry. No oxymorphone was detected in the blood at t limit of quantitation of 0.05 mg/L using gas chromatography/mass spectrometry
4. morphine was detected in the urine by immunoassay and confirmed by gas chromatography/mass spectrometry. The blood contained 0.36 mg/L of morphine as quantitated by gas chromatography/mass spectrometry
5. promethazine was detected in the urine by gas chromatography and confirmed by gas chromatography/mass spectrometry. The blood contained 0.25 mg/L of promethazine as quantitated by gas chromatography/mass spectrometry

VII Post-mortem Changes

No significant postmortem change is noted; mild postmortem changes consist of early corneal clouding , resolving rigor and posterior fixed lividity.

ACLU Detainee DeathII ARMY MEDCOM 662

OPINION

(b)(6) succumbed to multisystem organ failure due to disseminated carcinomatosis. His liver was almost twice the mass expected for a man his size, and consisted predominantly of metastatic tumor nodules. Correspondingly, features of liver failure were prominent at autopsy and consisted of jaundice, ascites and features of a bleeding diathesis. Smaller tumor deposits identified on clinical roentgenograms were not detected at the postmortem exam. His last round of chemotherapy was on the 13th of December. While it is difficult to assess the toxic potential of the decedent's chemotherapy regimen, it is very clear, both from the extensive tumor burden and from the critical organ systems affected, that the overwhelmingly preponderant causal factor in this man's death was carcinoma. The levels of analgesic and antiemetic agents identified on toxicologic analysis of blood and urine indicate that all reasonable efforts were made to control pain and nausea. The cause of death is multisystem organ failure due to carcinomatosis. The manner of death is natural.

(b)(6)

(b)(6) Medical Examiner (b)(6)

ACLU Detainee DeathII ARMY MEDCOM 663

CERTIFICATE OF DEATH *(OVERSEAS)*
Acte de décès (D'Outre-Mer)

NAME OF DECEASED *(Last, First, Middle)* Nom du décédé (Nom et prénoms)	GRADE Grade	BRANCH OF SERVICE Arme	SOCIAL SECURITY NUMBER Numéro de l'Assurance Social
Razzak, Abdul,		Civilian	(b)(6)
ORGANIZATION Organisation	**NATION** *(e.g. United States)* Pays: Iraq	**DATE OF BIRTH** Date de naissance	**SEX** Sexe: [X] MALE [ ] FEMALE

RACE Race		MARITAL STATUS État Civil			RELIGION Culte		
X	CAUCASOID Caucasique		SINGLE Célibataire		DIVORCED Divorcé		PROTESTANT Protestant		OTHER (Specify) Autre (Spécifier)
	NEGROID Negroide		MARRIED Marié		SEPARATED Séparé		CATHOLIC Catholique	X	
	OTHER (Specify) Autre (Spécifier)		WIDOWED Veuf				JEWISH Juif		

NAME OF NEXT OF KIN Nom du plus proche parent	RELATIONSHIP TO DECEASED Parenté du décédé avec le sus
STREET ADDRESS Domicilé à (Rue)	CITY OR TOWN OR STATE *(Include ZIP Code)* Ville (Code postal compris)

MEDICAL STATEMENT Déclaration médicale

	CAUSE OF DEATH (Enter only one cause per line) Cause du décès (N'indiquer qu'une cause par ligne)	INTERVAL BETWEEN ONSET AND DEATH Intervalle entre l'attaque et le décès
DISEASE OR CONDITON DIRECTLY LEADING TO DEATH [1] Maladie ou condition directement responsable de la mort. [1]	Multisystem organ failure due to carcinomatosis	Months
ANTECEDENT CAUSES Symptômes précurseurs de la mort. MORBID CONDITION, IF ANY, LEADING TO PRIMARY CAUSE Condition morbide, s'il y a lieu, menant à la cause primaire		
UNDERLYING CAUSE, IF ANY, GIVING RISE TO PRIMARY CAUSE Condition morbide, s'il y a lieu, menant à la cause primaire		
OTHER SIGNIFICANT CONDITIONS [2] Autres conditions significatives [2]		

MODE OF DEATH Condition de décès		AUTOPSY PERFORMED Autopsie effectuée [X] YES Oui [ ] NO Non	CIRCUMSTANCES SURROUNDING DEATH DUE TO EXTERNAL CAUSES Circonstances de la mort suscitées par des causes extérieures
X	NATURAL Mort naturelle	MAJOR FINDINGS OF AUTOPSY Conclusions principales de l'autopsie	
	ACCIDENT Mort accidentelle		
	SUICIDE Suicide	NAME OF PATHOLOGIST Nom du pathologiste (b)(6)	
	HOMICIDE Homicide	SIGNATURE (b)(6) DATE Date 30 December 2007	AVIATION ACCIDENT Accident à Avion [ ] YES Oui [X] NO Non

DATE OF DEATH *(day, month, year)* Date de décès (le jour, le mois, l'année)	PLACE OF DEATH Lieu de décès
(b)(6) 2007	Guantanamo Bay Cuba

I HAVE VIEWED THE REMAINS OF THE DECEASED AND DEATH OCCURRED AT THE TIME INDICATED AND FROM THE CAUSES AS STATED ABOVE
J'ai examiné les restes mortels du dé funtet je conclus que le décès est survenu à l'heure indiquée et à, la suite des causes énumérées ci-dessus.

NAME OF MEDICAL OFFICER Nom du médicin militaire ou du médicin sanitaire	TITLE OR DEGREE Titre ou diplômé
(b)(6)	Medical Examiner
GRADE Grade (b)(6)	**INSTALLATION OR ADDRESS** Installation ou adresse Dover AFB, Dover DE
DATE Date 5/7/2008	**SIGNATURE** (b)(6)

[1] State disease, injury or complication which caused death, but not mode of
[2] State conditions contributing to the death, but not related to the disease or condition causing death.
[1] Préciser la nature de la maladie, de la blessure ou de la complication qui a contribué à la mort, mais non la manière de mourir, telle qu'un arrêt du coeur, etc
[2] Préciser la condition qui a contribué à la mort, mais n'ayant aucun rapport avec la maladie ou à la condition qui a provoqué la mort.

DD FORM 1 APR 77 2064 REPLACES DA FORM 3565, 1 JAN 72 AND DA FORM 3565-R(PAS), 26 SEP 76, WHICH ARE OBSOLETE.

MEDCOM 0664

(REMOVE, REVERSE AND RE-INSERT CARBONS BEFORE COMPLETING THIS SIDE)

DISPOSITON OF REMAINS

NAME OF MORTICIAN PREPARING REMAINS	GRADE	LICENSE NUMBER AND STATE	OTHER

INSTALLATION OR ADDRESS (b)(6)	DATE	SIGNATURE

NAME OF CEMETERY OR CREMATORY	LOCATION OF CEMETERY OR CREMATORY

TYPE OF DISPOSTION	DATE OF DISPOSTION

REGISTRATION OF VITAL STATISTICS

REGISTRY *(Town and Country)*	DATE REGISTERED	FILE NUMBER	
		STATE	OTHER

NAME OF FUNERAL DIRECTOR	ADDRESS

SIGNATURE OF AUTHORIZED INDIVIDUAL

DD FORM 2064, APR 1977 (BACK) *USAPA V1.00*

ACLU Detainee DeathII ARMY MEDCOM 665

ARMED FORCES INSTITUTE OF PATHOLOGY
Office of the Armed Forces Medical Examiner
1413 Research Blvd., Bldg. 102
Rockville, MD 20850
301-319-0000

AUTOPSY EXAMINATION REPORT

Name: Al Alwani, Thair Hamid Khalaf Hassan
CCN: (b)(6)
Date of Birth (b)(6) 1979
Date of Death: (b)(6) 2007
Date/Time of Autopsy: 28 DEC 2007 1030 to 1400

Autopsy No.: (b)(6)
AFIP No.: (b)(6)
Rank: Civilian detainee
Place of Death: Iraq
Place of Autopsy: Port Mortuary, Dover AFB, Dover, DE

Date of Report: 23 JAN 2008

Circumstances of Death: This 28-year-old civilian detainee was reportedly killed by small arms fire while being transported in a mine resistant ambush protected vehicle. During this transport, the civilian detainee reportedly grabbed an M4 rifle and fired one round below the groin area of a Marine. The Marine was not struck yet, retrieved his 9 mm pistol and shot the civilian detainee. At the time of his death, the civilian detainee was reportedly flex cuffed in the front and blindfolded.

Authorization for Autopsy: Armed Forces Medical Examiner, per 10 U.S. Code 1471

Identification: Presumptive identification is established by the examination of accompanying paper work.

CAUSE OF DEATH: Multiple gunshot wounds

MANNER OF DEATH: Homicide

ACLU Detainee DeathII ARMY MEDCOM 666

EXTERNAL EXAMINATION

The body is that of a well-developed, well-nourished male. The body weighs 167 pounds, is 67 ½ inches in length and appears compatible with the reported age of 28 years. The body is cold. Rigor is passing in all extremities. Lividity is present and fixed on the posterior surface of the body, except in areas exposed to pressure. Injuries of the head are described below. The head is normocephalic, and the scalp hair is black. Facial hair consists of a mustache and beard. The irides are brown. The corneae are cloudy. The conjunctivae are pale. The sclerae are white. The external auditory canals, external nares and oral cavity are free of foreign material and abnormal secretions. The nasal skeleton and maxilla are palpably intact. The lips are without evident injury. The teeth are natural and in good condition. Examination of the neck reveals no evidence of injury. A 1/2 x 1/4 inch scar is on the right cheek. Injuries of the torso are described below. No evidence of injury of the ribs or the sternum is evident externally. The abdomen is flat. Healed surgical scars are not identified. The external genitalia are those of a normal adult circumcised male. The anus is unremarkable. The extremities show healed scar on both knees (right 1/2 inch and left 1 inch). The fingernails are intact. No tattoos are identified. Brown paper bags are secured over both hands with rubber bands.

CLOTHING AND PERSONAL EFFECTS

The clothing and personal effects are photographically documented. [1]

WORN:

- Red and white headscarf (lying on the back of the head)
- Olive colored jacket (cut)
- Long green shirt that extends to the legs (cut)
- Black shirt (cut)
- White t-shirt (cut)
- Black t-shirt (cut)
- White tank top (cut)
- White boxers (cut)
- Gray pants (cut)
- Black socks
- Brown sandal (right foot)

ACCOMPANYING:

- White flex cuffs
- Brown sandal

[1] There are multiple defects identified on the headscarf, shirts and coat. Bullet wipe is seen associated with some of the defects on the headscarf. No definitive soot deposition or unburned gunpowder is seen.

ACLU Detainee DeathII ARMY MEDCOM 667

MEDICAL INTERVENTION

- None

RADIOGRAPHS

A complete set of postmortem radiographs is obtained. Injuries seen radiographically are incorporated into the Evidence of Injury section below.

EVIDENCE OF INJURY

The ordering of the following injuries is for descriptive purposes only, and is not intended to imply order of infliction or relative severity. All wound pathways are given relative to standard anatomic position.

PERFORATING GUNSHOT WOUND OF THE HEAD:

Entrance:

On the right side of the head, posterior to the right ear, is a 1/4 inch circular entrance gunshot wound. The edges of the wound contain multiple fine lacerations. There is an eccentric marginal abrasion that measures up to 1/8 inch on the anterior border at the two to four o'clock position. There is also a 1/2 inch poorly formed and faint abrasion extending from the two to four o'clock position of the anterior border. The wound is located 3-1/2 inches below the top of the head and 3-3/4 inches to the right of the posterior midline. No soot or gunpowder stippling is identified on the surrounding skin. (A section of this wound is submitted for histologic examination. Please see the Microscopic Examination section below.)

Injured:

The right temporoparietal scalp, right temporoparietal bones (1/2 inch defect with inward beveling), right occipital lobe of the cerebrum, cerebellum, occipital bone (1 x 1/2 inch defect with outward beveling), and occipital scalp on the left side of the head are injured.

Exit:

On the left side of the head, posterior to the left ear, is a 1/2 x 1/4 inch lacerated exit gunshot wound located 5 inches below the top of the head and 2 inches to the left of the posterior midline.

Recovered:

Two copper colored metal jacket fragments are recovered from the head scarf. One copper colored metal fragment and one gray colored metal fragment is recovered from the inner table of the left side of the occipital bone. One copper and gray colored metal fragment is recovered from the right temporal scalp.

ACLU Detainee DeathII ARMY MEDCOM 668

Trajectory:

The bullet trajectory is right to left, slightly front to back and slightly downward.

Associated Injuries:

Associated is diffuse subarachnoid hemorrhage, subgaleal hemorrhage of the right and left side of the scalp, and linear fractures of the occipital, right temporal and right parietal bones.

PERFORATING GUNSHOT WOUND OF THE TORSO (RIGHT):

Entrance:

On the right side of the chest is a 1/4 inch circular entrance gunshot wound with a concentric 1/8 inch marginal abrasion. The wound margin appears dark and dried, and there is a slight red-purple discoloration of the skin immediately surrounding the wound. No definitive soot or gunpowder stippling is identified on the skin surrounding the wound. The wound is located 13-3/4 inches below the top of the head and 1/2 inch to the right of the anterior midline. (A section of the wound is submitted for histological examination. Please see the Microscopic Examination section below.)

Injured:

The skin, subcutaneous tissues, right second intercostal muscles, middle lobe of the right lung (1/4 inch lacerated wound), hilum of the right lung, lower lobe of the right lung (1 inch lacerated wound), posterior aspect of the ninth right rib, and skin of the right side of the back are injured.

Exit:

On the right side of the back (superior) is a 1/2 x 1/4 inch lacerated exit wound that has an eccentric marginal abrasion that measures up to 3/8 inch on the medial/inferior border in the four to ten o'clock position. The wound is located 17-1/2 inches below the top of the head and 2-3/4 inches to the right of the posterior midline.

Recovered:

No evidence is recovered at autopsy.

Trajectory:

The trajectory of the bullet is front to back and downward with slight left to right deviation.

Associated Injuries:

Associated with this wound is a right hemothorax (1250 ml).

ACLU Detainee DeathII ARMY MEDCOM 669

PERFORATING GUNSHOT WOUND OF THE TORSO (LEFT):

Entrance:

On the left side of the chest is an oval 1/4 x 1/8 inch entrance gunshot wound with an eccentric marginal abrasion that measures up to 3/8 inch on the lateral border in the twelve to four o'clock position. The wound is located 14-1/2 inches below the top of the head and 1-1/2 inches to the left on the anterior midline. There is no soot or gunpowder stippling identified on the surrounding skin. (A section of the wound is submitted for histological examination. Please see the Microscopic Examination section below.)

Injured:

The skin, subcutaneous tissues, second left intercostal muscles, pericardium, heart (right ventricle - 1/2 inch lacerated wound, interventricular septum, tricuspid valve, and right atrium - 1/2 inch lacerated wound), right hemidiaphragm (1/2 inch lacerated wound), liver (5 inch pulpified wound of the anterior right lobe and 2 inch pulpified wound of the posterior right lobe), right hemidiaphragm (1/2 inch lacerated wound), ninth right intercostal muscle and skin of the right side of the back are injured.

Exit:

On the right side of the back (inferior) is a 1/4 inch exit wound with irregular margins and an eccentric marginal abrasion that measures 1/8 inch on the lateral/superior border (nine to six o'clock position), and 1/4 inch on the medial/inferior border (six to nine o'clock position). The wound is located 19-3/4 inches below the top of the head and 5-3/4 inches to the right of the posterior midline.

Recovered:

No evidence is recovered.

Trajectory:

The trajectory of the bullet is left to right, front to back and downwards.

Associated Injuries:

There is a hemopericardium (30 ml), a right hemothorax (1250 ml), and a hemoperitoneum (300 ml).

ACLU Detainee DeathII ARMY MEDCOM 670

HEALED SUPERFICIAL PENETRATING BLAST FRAGMENTATION INJURY OF THE HEAD.

Entrance:

On the right cheek is a 1/2 x 1/4 inch well healed scar located 7 inches below the top of the head and 4-1/2 inches to the right of the anterior midline.

Injured:

The skin, subcutaneous tissues and muscle of the right side of the face are injured.

Recovered:

One irregular gray-metal fragment is recovered from a fibrous capsule adjacent to the right zygoma.

Trajectory:

The trajectory of the metal fragment is most likely right to left, back to front and upward.

Associated Injuries:

Associated with this wound is fibrosis and scarring seen on the right side of the face.

OTHER INJURIES:

There is a 1/2 x 1/4 inch abraded contusion on the right side of the forehead above the medial aspect of the right eyebrow. On the second finger of the left hand is a 1/4 inch linear abrasion.

INTERNAL EXAMINATION

BODY CAVITIES:

The body is opened by the usual thoraco-abdominal incision and the chest plate is removed. The sternum and vertebral bodies are visibly and palpably intact. The right posterior ninth rib is fractured. No adhesions are present in any of the body cavities. One thousand two hundred and fifty milliliters of blood is identified in the right pleural cavity, 30 ml of blood is identified in the pericardium, and 300 ml of blood is identified in the peritoneum. All body organs are present in normal anatomical position. The subcutaneous fat layer of the abdominal wall is 1/2 inch thick.

ACLU Detainee DeathII ARMY MEDCOM 671

HEAD AND CENTRAL NERVOUS SYSTEM:

Please see Evidence of Injury. Injuries of the scalp, skull and brain are described above. The scalp is reflected. The calvarium of the skull is removed. There is no epidural or subdural hemorrhage present. Where uninjured, the leptomeninges are thin and delicate. Blood tinged cerebrospinal fluid surrounds the injured brain which weighs 1270 grams. Where uninjured, the gyri and sulci are unremarkable. Coronal sections through the cerebral hemispheres reveal no non-traumatic lesions. Transverse sections through the brain stem are unremarkable. The atlanto-occipital joint is stable. The spinal cord is unremarkable.

NECK:

The anterior strap muscles of the neck are homogenous and red-brown, without hemorrhage by layer-wise dissection. The thyroid cartilage and hyoid bone are intact. The larynx is lined by intact white mucosa. The tongue is free of bite marks, hemorrhage, or other injuries. Incision and dissection of the posterior neck demonstrates no deep paracervical muscular injury and no cervical spine fractures.

CARDIOVASCULAR SYSTEM:

See Evidence of Injury. The injured heart weighs 310 grams. Where uninjured, the epicardial surface is smooth, and there is minimal fat investment. The coronary arteries are present in a normal distribution, with a right-dominant pattern. Cross sections of the vessels show wide patency. Where uninjured, the myocardium is homogenous, red-brown, and firm, and the valve leaflets are thin and mobile. The walls of the left ventricle, interventricular septum, and right ventricle are 1.0, 1.1, and 0.3-cm thick, respectively. Where uninjured, the endocardium is smooth and glistening. The aorta gives rise to three intact and patent arch vessels. The renal and mesenteric vessels are unremarkable.

RESPIRATORY SYSTEM:

Please see Evidence of Injury. The upper airway is clear of debris and foreign material; the mucosal surfaces are smooth, yellow-tan and unremarkable. The pleural surfaces are smooth, glistening and unremarkable bilaterally. Where uninjured, the pulmonary parenchyma is diffusely congested and edematous, exuding slight to moderate amounts of blood and frothy fluid; no focal non-traumatic lesions are noted. The pulmonary arteries are normally developed, patent and without thrombus or embolus. The injured right lung weighs 300 grams. The left lung weighs 290 grams.

ACLU Detainee DeathII ARMY MEDCOM 672

HEPATOBILIARY SYSTEM:

Please see Evidence of Injury. The 1480 gram liver has a smooth capsule covering dark red-brown, moderately congested parenchyma with no focal non traumatic lesions noted. The gallbladder contains 10 ml of green-brown, mucoid bile; the mucosa is velvety and unremarkable. The extrahepatic biliary tree is patent, without evidence of calculi.

GASTROINTESTINAL SYSTEM:

The esophagus is lined by gray-white, smooth mucosa. The gastric mucosa is arranged in the usual rugal folds and the lumen contains 20 ml of partially digested food. The small and large bowels are unremarkable. The pancreas has a normal pink-tan lobulated appearance and the ducts are clear. The appendix is present.

GENITOURINARY SYSTEM:

The right kidney weighs 90 grams; the left 90 grams. The renal capsules are smooth and thin, semi-transparent and strip with ease from the underlying smooth, red-brown cortical surface. The cortex is sharply delineated from the medullary pyramids, which are red-purple to tan and unremarkable. The calyces, pelves and ureters are unremarkable. White bladder mucosa overlies an intact bladder wall. The bladder contains approximately 50 ml of clear yellow urine. The testes, prostate gland and seminal vesicles are without note.

LYMPHORETICULAR SYSTEM:

The 170 gram spleen has a smooth, intact capsule covering red-purple, moderately firm parenchyma; the lymphoid follicles are unremarkable. Lymph nodes in the hilar, periaortic and iliac regions are not enlarged.

ENDOCRINE SYSTEM:

The pituitary gland is examined in situ and is unremarkable. The thyroid gland is symmetric and red-brown, without cystic or nodular change. The right and left adrenal glands are symmetric, with bright yellow cortices and red-brown medullae. No masses or areas of hemorrhage are identified.

MUSCULOSKELETAL SYSTEM:

No non-traumatic abnormalities of muscle or bone are identified.

ACLU Detainee DeathII ARMY MEDCOM 673

RECOVERED EVIDENCE:

- Left hand swab in swab box
- Right hand swab in swab box
- Brown paper bag, rubber band and fingernail clippings from left hand
- Brown paper bag, rubber band and fingernail clippings from right had
- Major case fingerprints
- One white cotton tank top
- One black t-shirt
- One white t-shirt
- Black long sleeved sweatshirt
- Tan striped calf-length blood soaked t-shirt
- Black/brown reversible corduroy jacket
- Brown leather sandals
- One gray pair of pants
- One pair of white boxer shorts
- One pair of black socks
- Metal bullet fragments from head (see Evidence of Injury section above)
- Metal bullet fragments from red/white scarf (see Evidence of Injury section above)
- Metal bullet fragments from right jaw (see Evidence of Injury section above)
- White cut flexi-cuff
- Red and white patterned scarf

ADDITIONAL PROCEDURES

1. Documentary photographs are taken by (b)(6) OAFME staff photographer.
2. Personal effects and evidence are released to Special Agent (b)(6) NCIS - HQ - Washington DC.
3. Specimens retained for toxicology testing are: brain, heart, lung, liver, spleen, kidney, skeletal muscle, adipose tissue, blood, vitreous fluid, bile, urine and gastric contents.
4. The dissected organs are forwarded with body.
5. Special Agent (b)(6) attended the autopsy in its entirety.
6. (b)(6) OAFME staff autopsy assistant, assisted with the autopsy.

MICROSCOPIC EXAMINATION

- Entrance gunshot wound (head) No definitive soot deposition is seen
- Entrance gunshot wound (right chest) No definitive soot deposition is seen
- Entrance gunshot wound (left chest) No definitive soot deposition is seen

ACLU Detainee DeathII ARMY MEDCOM 674

FINAL AUTOPSY DIAGNOSES:

I. Perforating gunshot wound of the head
- **A. Entrance: On the right side of the head, posterior to the right ear, is a 1/4 inch circular entrance gunshot wound; there is an eccentric marginal abrasion; there is a poorly formed faint abrasion extending from the two to four o'clock position; no soot or gunpowder stippling is identified**
- **B. Injured: The scalp, right temporal/parietal bone, cerebrum, cerebellum, occipital bone and occipital scalp**
- **C. Exit: On the left side of the head, posterior to the left ear, is a 1/2 x 1/4 inch lacerated exit gunshot wound**
- **D. Recovered: Two copper colored metal jacket fragments from the head scarf; one copper colored metal fragment and one gray colored metal fragment from the inner table of the left side of the occipital bone and one copper and one gray colored metal fragment from the right temporal scalp**
- **E. Trajectory: Right to left, slightly front to back and slightly downward**
- **F. Associated injuries: Diffuse subarachnoid hemorrhage, subgaleal hemorrhage, and linear fractures of the occipital right temporal and right parietal bones**

II. Perforating gunshot wound of the torso (right)
- **A. Entrance: On the right side of the chest is a 1/4 inch circular entrance gunshot wound with a concentric 1/8 inch marginal abrasion; no definitive soot or gunpowder stippling is identified on the surrounding skin**
- **B. Injured: The skin, subcutaneous tissue, right second intercostal muscles, right lung, posterior aspect of the ninth right rib and skin of the right side of the back**
- **C. Exit: On the right side of the back (superior) is a 1/2 x 1/4 inch lacerated exit wound**
- **D. Recovered: Nothing**
- **E. Trajectory: The trajectory of the bullet is front to back and downward with slight left to right deviation**
- **F. Associated injuries: Associated with this wound is a right hemothorax (1250 ml)**

III. Perforating gunshot wound of the torso (left)
- **A. Entrance: On the left side of the chest is an oval 1/4 x 1/8 inch entrance gunshot wound with an eccentric marginal abrasion; there is no soot or gunpowder stippling identified on the surrounding skin**
- **B. Injured: The skin, subcutaneous tissue, second left intercostal muscles, pericardium, heart, right hemidiaphragm, liver, ninth right intercostal muscles and skin of the right side of the back**
- **C. Exit: On the right side of the back (inferior) is a 1/4 inch exit wound with lacerated margins**
- **D. Recovered: Nothing**
- **E. Trajectory: Left to right, front to back and downward**
- **F. Associated injuries: There is a hemopericardium (30 ml), a right hemothorax (1250 ml) and a hemoperitoneum (300 ml)**

IV. Healed superficial penetrating blast fragment injury of the head
- **A. Entrance: On the right cheek is 1/2 x 1/4 inch scar**
- **B. Injured: Skin, subcutaneous tissue and muscle**

ACLU Detainee DeathII ARMY MEDCOM 675

C. **Recovered: One irregular gray metal fragment is recovered from a fibrous capsule adjacent to the right zygoma**
D. **Trajectory: Most likely right to left, back to front, and upward**
E. **Associated injuries: Fibrosis and scarring of the right side of the face**

V. **Other injuries:**
A. **Abraded contusion of the right side of the forehead**
B. **Linear abrasion of the second finger of the left hand**

VI. **Natural Disease: None identified within the limits of the examination**
VII. **Medical Therapy: None**
VIII. **Postmortem Changes: As described above**
IX. **Identifying Marks: As described above**
X. **Toxicology (AFIP):**
A. **VOLATILES: No ethanol is detected in the blood and vitreous fluid**
B. **DRUGS: No screened drugs of abuse or medications are detected in the urine**
C. **CARBON MONOXIDE: The carboxyhemoglobin saturation in the blood is less than 1%**
D. **CYANIDE: No cyanide is detected in the blood**

OPINION

This 28-year-old civilian detainee (b)(6) died of multiple gunshot wounds. The detainee suffered a perforating gunshot wound of the head. The entrance was on the right side of the head posterior to the right ear, and there was no evidence of close range discharge of a firearm surrounding the wound. The scalp, skull and brain were injured. The exit wound was located on the left side of the head posterior to the left ear. Multiple bullet fragments were recovered from a headscarf which was situated behind the deceased head, the scalp, and the inner table of the occipital bone. The trajectory of this bullet was right to left, slightly front to back and slightly downward. Associated injuries included bleeding into the subarachnoid space of the brain, subgaleal hemorrhage, and fractures of the occipital, right temporal, and right parietal bones. A second gunshot wound was to the right side of the chest. The entrance was located on the right side of the chest and there was no evidence of close range discharge from a firearm on the skin surrounding the wound. The skin, subcutaneous tissues, right second intercostal muscles, right lung, the posterior aspect of the ninth right rib, and the skin of the right side of the back are injured. An exit was located on the right side of the back (superior). No evidence was recovered in association with this wound. The trajectory of the bullet was front to back and downward with slight left to right deviation. Associated with this wound was a right hemothorax. There was also a perforating gunshot wound of the left side of the chest. The entrance was located on the left side of the chest and there was no evidence of close range discharge of a firearm surrounding the wound. The skin, subcutaneous tissues, second left intercostal muscles, pericardium, heart, right hemidiaphragm, liver, and skin of the right side of the back were injured. There was an exit wound on the right side of the back. No evidence was recovered in association with this wound. The trajectory of the bullet was left to right and front to back and downward. Associated with this wound were a hemopericardium, a right hemothorax, and a hemoperitoneum. An additional injury discovered at autopsy was a healed superficial penetrating blast fragmentation injury of the head. The entrance was evidenced by a scar on the right cheek. The blast fragment injured the skin, subcutaneous tissues and muscle of the right side of the face. One irregular gray metal fragment

ACLU Detainee DeathII ARMY MEDCOM 676

was recovered from a fibrous capsule adjacent to the right zygoma. The trajectory of the metal fragment was most likely right to left, back to front and upward. Injuries associated with this wound were fibrosis and scarring which was seen on the right side of the face. Additional minor injuries discovered at autopsy were an abraded contusion on the right side of the forehead and a linear abrasion on the second finger of the left hand. The toxicology screen is negative for cyanide, volatiles and screened medications and drugs of abuse. The carxyhemoglobin saturation in the blood was not elevated. The manner of death is homicide.

(b)(6)

(b)(6) MEDICAL EXAMINER

ACLU Detainee DeathII ARMY MEDCOM 677

CERTIFICATE OF DEATH (OVERSEAS)
Acte de décès (D'Outre-Mer)

NAME OF DECEASED (Last, First, Middle) Nom du décédé (Nom et prénoms)	GRADE Grade	BRANCH OF SERVICE Arme	SOCIAL SECURITY NUMBER Numéro de l'Assurance Social
AL Alwani, Thair Hamid, Khalaf Hassan		Civilian	(b)(6)
ORGANIZATION Organization	NATION (e.g. United States) Pays	DATE OF BIRTH Date de naissance	SEX Sexe [X] MALE [ ] FEMALE

RACE Race		MARITAL STATUS Etat Civil			RELIGION Culte		
X	CAUCASOID Caucasique		SINGLE Célibataire		DIVORCED Divorcé		PROTESTANT Protestant
	NEGROID Negroïde		MARRIED Marié		SEPARATED Séparé		CATHOLIC Catholique
	OTHER (Specify) Autre (Spécifier)		WIDOWED Veuf				JEWISH Juif
						X	OTHER (Specify) Autre (Spécifier)

NAME OF NEXT OF KIN Nom du plus proche parent	RELATIONSHIP TO DECEASED Parenté du décédé avec le sus
STREET ADDRESS Domicile à (Rue)	CITY OR TOWN OR STATE (Include ZIP code) Ville (Code postal compris)

MEDICAL STATEMENT Déclaration médicale

CAUSE OF DEATH (Enter only one cause per line) Cause du décès (N'indiquer qu'une cause par ligne)		INTERVAL BETWEEN ONSET AND DEATH Intervalle entre l'attaque et le décès
DISEASE OR CONDITON DIRECTLY LEADING TO DEATH[1] Maladie ou condition directement responsable de la mort	Multiple gunshot wounds	
ANTECEDENT CAUSES Symptômes précurseurs de la mort — MORBID CONDITION, IF ANY, LEADING TO PRIMARY CAUSE Condition morbide, s'il y a lieu, menant à la cause primaire		
ANTECEDENT CAUSES Symptômes précurseurs de la mort — UNDERLYING CAUSE, IF ANY, GIVING RISE TO PRIMARY CAUSE Condition morbide, s'il y a lieu, menant à la cause primaire		
OTHER SIGNIFICANT CONDITIONS[2] Autres conditions significatives[2]		

MODE OF DEATH Condition de décès	AUTOPSY PERFORMED Autopsie effectuée [X] YES Oui [ ] NO Non	CIRCUMSTANCES SURROUNDING DEATH DUE TO EXTERNAL CAUSES Circonstances de la mort suscitées par des causes extérieures
NATURAL Mort naturelle	MAJOR FINDINGS OF AUTOPSY Conclusions principales de l'autopsie	
ACCIDENT Mort accidentelle		
SUICIDE Suicide	NAME OF DATOR DEBIT Nom du pourvoyeur (b)(6)	
X HOMICIDE Homicide	(b)(6)	DATE Date 28 December 2007 — AVIATION ACCIDENT Accident à Avion [ ] YES Oui [X] NO Non

DATE OF DEATH (day, month, year) Date de décès (Jour, le mois, l'année)	PLACE OF DEATH Lieu de décès
(b)(6) 2007	Iraq

I HAVE VIEWED THE REMAINS OF THE DECEASED AND DEATH OCCURRED AT THE TIME INDICATED AND FROM THE CAUSES AS STATED ABOVE.
J'ai examiné les restes mortels du dé furent je remplis que le décès est survenu à l'heure indiquée et à la suite des causes énumérées ci-dessus.

NAME OF MEDICAL OFFICER Nom du médecin militaire ou du médecin auxiliaire	TITLE OR DIVISION Titre ou diplôme
(b)(6)	Medical Examiner
GRADE Grade (b)(6)	INSTALLATION OR ADDRESS Installation ou adresse Dover AFB, Dover DE (b)(6)
DATE Date 12/28/2007	

[1] [illegible]
[2] [illegible]
[3] [illegible]
[4] [illegible]

DD FORM 1 APR 77 2064 REPLACES DA FORM 3505, 1 JAN 72 AND DA FORM 3505-R(PAS), 28 SEP 76, WHICH ARE OBSOLETE.

(REMOVE, REVERSE AND RE-INSERT CARBONS BEFORE COMPLETING THIS SIDE)

DISPOSITON OF REMAINS

NAME OF MORTICIAN PREPARING REMAINS	GRADE	LICENSE NUMBER AND STATE	OTHER

INSTALLATION OR ADDRESS	DATE	SIGNATURE
(b)(6)		

NAME OF CEMETERY OR CREMATORY	LOCATION OF CEMETERY OR CREMATORY

TYPE OF DISPOSITION	DATE OF DISPOSITION

REGISTRATION OF VITAL STATISTICS

REGISTRY (Town and Country)	DATE REGISTERED	FILE NUMBER	
		STATE	OTHER

NAME OF FUNERAL DIRECTOR	ADDRESS

SIGNATURE OF AUTHORIZED INDIVIDUAL

DD FORM 2064, APR 1977 (BACK) ***USAPA V1.00***

ACLU Detainee DeathII ARMY MEDCOM 679

ARMED FORCES INSTITUTE OF PATHOLOGY
Office of the Armed Forces Medical Examiner
1413 Research Blvd., Bldg. 102
Rockville, MD 20850
301-319-0000

AUTOPSY EXAMINATION REPORT

Name: DHAHI, Al Amiri Hassan Husayn
ISN: (b)(6)
Date of Birth: Unknown
Date of Death: (b)(6) 2007
Date/Time of Autopsy: 28 DEC 2007 @0900 hrs
Date of Report: 11 MAR 2008

Autopsy No.: (b)(6)
AFIP No.: (b)(6)
Rank: Civilian/Detainee
Place of Death: Iraq
Place of Autopsy: Port Mortuary *Dover* AFB, DE

Circumstances of Death: This Operation Iraqi Freedom detainee, as reported, was vomiting blood and was transported to the surgical operating room for an emergency laparotomy. During the procedure, the decedent had uncontrollable gastric bleeding near the gastro-esophageal junction. The patient died, despite all attempts to control his acute blood loss.

Authorization for Autopsy: Armed Forces Medical Examiner, per U.S. Code 10, Section 1471

Identification: Presumptive identification per CID investigation.

CAUSE OF DEATH: **HEMORRHAGE DUE TO PEPTIC ULCER DISEASE**

MANNER OF DEATH: **NATURAL**

ACLU Detainee DeathII ARMY MEDCOM 680

EXTERNAL EXAMINATION

The body is that of a well-developed, well-nourished male. The body weighs 144 pounds and is 67 ½ inches in length. The body is cold. Rigor is present to an equal degree in all extremities. Lividity is present and fixed on the posterior surface of the body, except in areas exposed to pressure.

The head is normocephalic, and the scalp hair is black. Facial hair consists of mustache and extends into a full black/gray beard. The irides are hazel. The corneae are cloudy. The conjunctivae and sclerae are unremarkable. The external auditory canals and oral cavity are free of foreign material and abnormal secretions. The naris has dried blood present. The nasal skeleton and maxilla are palpably intact. The lips are without evident injury. The teeth are natural and in good condition. Examination of the neck reveals no evidence of injury.

The chest is unremarkable. No evidence of injury of the ribs or the sternum is evident externally. The abdomen is flat. The external genitalia are those of a normal adult circumcised male. The anus is unremarkable.

The fingernails are intact. There are two well healed scars on the dorsal surface of the right foot measuring up to 1 inch in maximum dimension. There is one well healed scar on the dorsal surface of the left foot measuring up to 1 inch in maximum dimension. There are no tattoos noted on the body. There is a skin tag measuring ¼ inch in maximum dimension on the left back. The majority of the posterior torso has multiple vitiligo patches.

CLOTHING AND PERSONAL EFFECTS

None identified.

MEDICAL INTERVENTION

A six inch vertical, surgical staple line is above the umbilicus. There is a puncture mark on the left antecubital fossa.

RADIOGRAPHS

A complete set of postmortem radiographs is obtained and demonstrates only a surgical staple line from T-11 to L3.

EVIDENCE OF INJURY

None identified.

ACLU Detainee DeathII ARMY MEDCOM 681

INTERNAL EXAMINATION

BODY CAVITIES:

The ribs, sternum, and vertebral bodies are visibly and palpably intact. The peritoneal has 200 milliliters of bloody fluid. All body organs are present in normal anatomical position. The subcutaneous fat layer of the abdominal wall is ¾ inch thick.

HEAD AND NECK:

The galeal and subgaleal soft tissues of the scalp are free of injury. There are no skull fractures. The dura mater and falx cerebri are intact. There is no epidural or subdural hemorrhage present. The leptomeninges are thin and delicate. The cerebral hemispheres are symmetrical. The structures at the base of the brain, including cranial nerves and blood vessels are intact.

The brain weighs 1270 grams, which has unremarkable gyri and sulci. Coronal sections through the cerebral hemispheres reveal no lesions. Transverse sections through the brain stem and cerebellum are unremarkable. The atlanto-occipital joint is stable.

The anterior strap muscles of the neck are homogenous and red-brown, without hemorrhage by layer-wise dissection. The thyroid cartilage and hyoid bone are intact. The larynx is lined by intact tan mucosa. The tongue is free of bite marks, hemorrhage, or other injuries.

CARDIOVASCULAR SYSTEM:

The heart weighs 320 grams and surrounded by an intact pericardial sac. The epicardial surface is smooth, with minimal fat investment. The coronary arteries are present in a normal distribution, with a right-dominant pattern. Cross sections of the vessels show no significant atherosclerotic luminal stenosis present. The myocardium is homogenous, red-brown, and firm. The valve leaflets are thin and mobile. The walls of the left ventricle, interventricular septum, and right ventricle are 1.4, 1.4, and 0.3 centimeters thick, respectively. The endocardium is smooth and glistening.

The aorta gives rise to three intact and patent arch vessels. The renal and mesenteric vessels are unremarkable.

RESPIRATORY SYSTEM:

The upper airway is clear of debris and foreign material: the mucosal surfaces are smooth, yellow-tan and unremarkable. The right pleural surface has adhesions; but the left pleural surface has a smooth, glistening and unremarkable appearance. The pulmonary parenchyma is unremarkable, it exudes a slight amount of blood and frothy fluid; no focal lesions are noted.

The pulmonary arteries are normally developed, patent and without thrombus or embolus. The right lung weighs 360 grams; the left 330 grams.

ACLU Detainee DeathII ARMY MEDCOM 682

HEPATOBILIARY SYSTEM:

The liver weighs 1050 grams has an intact smooth capsule covering moderately congested tan-brown parenchyma with no focal lesions noted.

The gallbladder contains 1 milliliter of green-brown, mucoid bile; the mucosa is velvety and unremarkable. The extrahepatic biliary tree is patent, without evidence of calculi.

GASTROINTESTINAL SYSTEM:

The esophagus is lined by gray-white, smooth mucosa. The gastric mucosa is arranged in the usual rugal folds and shows a 7 x 5 centimeter defect near the greater curvature. Located 1 centimeter from the gastric-esophageal junction are two gastric ulcers measuring 0.7 and 1.0 centimeters in maximum dimension. Both ulcers are surrounded by a 5.5 x 5 centimeter area of mucosal erythema. A black surgical suture is located between these two lesions.

The small and large bowels contain bloody semi-liquid and fecal matter, respectively. The pancreas is slightly decomposed with a tan lobulated appearance and the ducts are clear. The appendix is present.

GENITOURINARY SYSTEM:

The right kidney weighs 90 grams; the left kidney weighs 110 grams. The renal capsules are smooth and thin, semi-transparent and strip with ease from the underlying smooth, red-brown cortical surface. The cortices are sharply delineated from the medullary pyramids, which are red-purple to tan and unremarkable. The calyces, pelves and ureters are unremarkable.

Tan bladder mucosa overlies an intact bladder wall. The bladder contains no urine. The testes, prostate gland and seminal vesicles are unremarkable.

LYMPHORETICULAR SYSTEM:

The spleen weighs 870 grams has a smooth, intact capsule covering red-purple, moderately firm parenchyma; the lymphoid follicles are unremarkable.

Lymph nodes in the hilar, periaortic and iliac regions are not enlarged.

ENDOCRINE SYSTEM:

The pituitary gland is left *in situ* and is unremarkable. The thyroid gland is symmetric and red-brown, without cystic or nodular change. The right and left adrenal glands are symmetric, with bright yellow cortices and red-brown medullae. No masses or areas of hemorrhage are identified.

ACLU Detainee DeathII ARMY MEDCOM 683

MUSCULOSKELETAL SYSTEM:

No non-traumatic abnormalities of muscle or bone are identified.

MICROSCOPIC EXAMINATION

Selected portions of organs are retained in formalin, with preparation of histology slides of the spleen pending.

ADDITIONAL PROCEDURES

1. Documentary photographs are taken by OAFME.
2. Personal effects are released to the appropriate mortuary operations representatives.
3. Specimens retained for toxicology testing and/or DNA identification are: vitreous fluid, blood, bile, spleen, liver, lung, kidney, brain, myocardium, adipose tissue and skeletal muscle.
4. The dissected organs are forwarded with body.

ACLU Detainee DeathII ARMY MEDCOM 684

FINAL AUTOPSY DIAGNOSES

I. **Gastric Ulcers, Multiple, Near the Gastro-Esophageal Junction**

II. **Natural diseases or pre-existing conditions:**
A. Vitiligo of the posterior torso
B. Splenomegaly, 870 grams

III. **Evidence of Medical/Surgical Therapy:**
A. A 7 x 5 centimeter defect near the greater curvature of the stomach
B. Black suture present near the site of gastric bleeding
C. A vertical surgical staple line above the umbilicus
D. Puncture mark on the left antecubital fossa

IV. **Post-Mortem Changes:** Described above

V. **Identifying Body Marks:** None identified

VI. **Toxicology (AFIP)**
A. VOLATILES: No ethanol detected in the blood and vitreous fluid
B. DRUGS: Midazolam was detected in the blood
C. CYANIDE: There was no cyanide detected in the blood

ACLU Detainee DeathII ARMY MEDCOM 685

OPINION

The cause of death for this detainee (b)(6) is due to acute blood loss from two bleeding gastric ulcers. The 7 x 5 centimeter defect near the greater curvature of the stomach was produced by the surgeon to find the site of bleeding during the emergency laparotomy. The toxicology screen was positive for midazolam, an intravenous general anesthetic used on surgery patients. The puncture mark on the left antecubital fossa was the likely site of administration for this anesthetic during the decedent's emergency operation. Vitiligo is a benign condition that results in depigmentation of the skin. The manner of death is natural.

Histology slides of the spleen are pending. If there is significant information identified from these slides an addendum report will be generated.

(b)(6)

(b)(6) Medical Examiner

(b)(6)

(b)(6) Medical Examiner

ACLU Detainee DeathII ARMY MEDCOM 686

CERTIFICATE OF DEATH *(OVERSEAS)*
Acte de décès (D'Outre-Mer)

NAME OF DECEASED (Last, First, Middle) Nom du décédé (Nom et prénoms)	GRADE Grade	BRANCH OF SERVICE Arme	SOCIAL SECURITY NUMBER Numéro de l'Assurance Social
BTB Dhahi, Al Amiri, Hassan Husayn		Civilian	(b)(6)

ORGANIZATION Organisation	NATION (e.g. United States) Pays	DATE OF BIRTH Date de naissance	SEX Sexe
			[X] MALE [ ] FEMALE

RACE Race		MARITAL STATUS État Civil			RELIGION Culte		
[X]	CAUCASOID Caucasique	[ ]	SINGLE Célibataire	[ ] DIVORCED Divorcé	[ ] PROTESTANT Protestant	[X]	OTHER (Specify) Autre (Spécifier)
[ ]	NEGROID Negroide	[ ]	MARRIED Marié	[ ] SEPARATED Séparé	[ ] CATHOLIC Catholique		
[ ]	OTHER (Specify) Autre (Spécifier)	[ ]	WIDOWED Veuf		[ ] JEWISH Juif		

NAME OF NEXT OF KIN Nom du plus proche parent	RELATIONSHIP TO DECEASED Parenté du décédé avec le sus
STREET ADDRESS Domicile à (Rue)	CITY OR TOWN OR STATE (Include ZIP Code) Ville (Code postal compris)

MEDICAL STATEMENT Déclaration médicale

	CAUSE OF DEATH (Enter only one cause per line) Cause du décès (N'indiquer qu'une cause par ligne)	INTERVAL BETWEEN ONSET AND DEATH Intervalle entre l'attaque et le décès
DISEASE OR CONDITON DIRECTLY LEADING TO DEATH [1] Maladie ou condition directement responsable de la mort	Hemorrhage due to peptic ulcer disease	
ANTECEDENT CAUSES Symptômes précurseurs de la mort — MORBID CONDITION, IF ANY, LEADING TO PRIMARY CAUSE Condition morbide, s'il y a lieu, menant à la cause primaire		
ANTECEDENT CAUSES Symptômes précurseurs de la mort — UNDERLYING CAUSE, IF ANY, GIVING RISE TO PRIMARY CAUSE Condition morbide, s'il y a lieu, menant à la cause primaire		
OTHER SIGNIFICANT CONDITIONS [2] Autres conditions significatives [2]		

MODE OF DEATH Condition de décès	AUTOPSY PERFORMED Autopsie effectuée [X] YES Oui [ ] NO Non	CIRCUMSTANCES SURROUNDING DEATH DUE TO EXTERNAL CAUSES Circonstances de la mort ausctées par des causes extérieures
[X] NATURAL Mort naturelle	MAJOR FINDINGS OF AUTOPSY Conclusions principales de l'autopsie	
[ ] ACCIDENT Mort accidentelle		
[ ] SUICIDE Suicide	NAME OF PATHOLOGIST Nom du pathologiste (b)(6)	
[ ] HOMICIDE Homicide	(b)(6) DATE Date 28 December 2007	AVIATION ACCIDENT Accident d'Avion [ ] YES Oui [X] NO Non

DATE OF DEATH (day, month, year) Date du décès (le jour, le mois, l'année)	PLACE OF DEATH Lieu du décès
(b)(6) 2007	Iraq

I HAVE VIEWED THE REMAINS OF THE DECEASED AND DEATH OCCURRED AT THE TIME INDICATED AND FROM THE CAUSES AS STATED ABOVE.
J'ai examiné les restes mortels du dé funtat je conclus que le décès est survenu à l'heure indiquée et à, la suite des causes énumérées ci-dessus

NAME OF MEDICAL OFFICER Nom du médecin militaire ou du médecin sanitaire	TITLE OR DEGREE Titre ou diplômé
(b)(6)	Medical Examiner

GRADE Grade	INSTALLATION OR ADDRESS Installation ou adresse
(b)(6)	Dover AFB, Dover DE
DATE Date 3/13/2008	SIGNATURE (b)(6)

[1] State disease, injury or complication which caused death, but not mode of dying such as heart failure, etc.
[2] State conditions contributing to the death, but not related to the disease or condition causing death.
[1] Préciser la nature de la maladie, de la blessure ou de la complication qui a contribué à la mort, mais non la manière de mourir, telle qu'un arrêt du coeur, etc
[2] Préciser la condition qui a contribué à la mort, mais n'ayant aucun rapport avec la maladie ou à la condition qui a provoqué la mort

DD FORM 1 APR 77 2064 REPLACES DA FORM 3868, 1 JAN 72 AND DA FORM 3868-R(PAS), 28 SEP 75, WHICH ARE OBSOLETE.

MEDCOM 0687

ACLU Detainee DeathII ARMY MEDCOM 687

(REMOVE, REVERSE AND RE-INSERT CARBONS BEFORE COMPLETING THIS SIDE)

DISPOSITON OF REMAINS

NAME OF MORTICIAN PREPARING REMAINS	GRADE	LICENSE NUMBER AND STATE	OTHER
INSTALLATION OR ADDRESS (b)(6)	DATE	SIGNATURE	
NAME OF CEMETERY OR CREMATORY	LOCATION OF CEMETERY OR CREMATORY		
TYPE OF DISPOSITION	DATE OF DISPOSITION		

REGISTRATION OF VITAL STATISTICS

REGISTRY *(Town and Country)*	DATE REGISTERED	FILE NUMBER	
		STATE	OTHER
NAME OF FUNERAL DIRECTOR	ADDRESS		
SIGNATURE OF AUTHORIZED INDIVIDUAL			

DD FORM 2064, APR 1977 (BACK) ***USAPA V1.00***

ACLU Detainee DeathII ARMY MEDCOM 688

ARMED FORCES INSTITUTE OF PATHOLOGY
Office of the Armed Forces Medical Examiner
1413 Research Blvd., Bldg. 102
Rockville, MD 20850
301-319-0000

AUTOPSY EXAMINATION REPORT

Name: (BTB) MOSHIN. Ra'ad Sa'ad
ISN/TMEP (b)(6)
Date of Birth: (b)(6) JAN 1987
Date of Death: (b)(6) 2007

Autopsy No.: (b)(6)
AFIP No. (b)(6)
Rank: Civilian Detainee
Place of Death: Baghdad, Iraq

Date/Time of Autopsy: 20 DEC 2007 @ 0930
Place of Autopsy: Port Mortuary, Dover AFB, DE

Date of Report: 01 JUL 2008

Circumstances of Death: This Civilian Detainee was admitted to the 31st CSH intensive care unit at Camp Cropper, Baghdad, Iraq on 12 DEC 2007 due to complications of end stage liver disease of an unknown etiology. He first came to the attention of the medical staff at Camp Cropper in October 2007 with complaints of nausea and fatigue, and was diagnosed with viral syndrome. His past medical history was significant only for a dermatitis for which he used topical medications and occasional oral prednisone. He developed progressive weight loss and jaundice with rising bilirubin, liver enzymes and ammonia levels in November 2007. He denied exposure to chemicals, medications, alcohol or herbal preparations. Viral markers for hepatitis A, B, C and HIV were negative. His condition progressively deteriorated to multi-organ system failure and he expired on (b)(6) 2007.

Authorization for Autopsy: Armed Forces Medical Examiner, per U.S. Code 10, Section 1471

Identification: Presumptive identification is made based upon identification bracelets on the body. Positive identification the ISN is confirmed by the comparison of an antemortem DNA reference and a postmortem DNA sample. Fingerprints are taken for comparison to an exemplar if one becomes available.

CAUSE OF DEATH: **LIVER FAILURE DUE TO CRYPTOGENIC HEPATITIS**

MANNER OF DEATH: **NATURAL**

ACLU Detainee DeathII ARMY MEDCOM 689

EXTERNAL EXAMINATION

The body is that of a well-developed, well-nourished Caucasoid male received unclad and wrapped in two sheets. The body weighs 183-pounds, is 66-inches in length and appears older than the reported age of 20-years. The body is cold. Rigor is passing to an equal degree in all extremities. Lividity is present and fixed on the posterior surface of the body, except in areas exposed to pressure. The body is jaundiced and anasarcic, with 4+ pitting edema over the entire torso and all extremities. The skin appears pale and dry with flaking, most notably on the scalp. Large bullae are present on the skin, mostly on the dependent portions of the body. Some skin slippage is present.

The head is normocephalic, and the scalp hair is sparse, short and brown. Facial hair consists of a sparse beard and moustache. The irides are brown, the corneae are cloudy, and the conjunctivae are edematous and otherwise unremarkable. The sclerae are icteric. The external auditory canals, external nares and oral cavity are free of foreign material and abnormal secretions. The earlobes are not pierced. The nasal skeleton and maxilla are palpably intact. The lips are without evident injury. The teeth are natural and in good condition. Examination of the neck reveals no evidence of injury.

The chest is unremarkable. No evidence of injury of the ribs or the sternum is evident externally. The abdomen is markedly protuberant with striae and an obvious fluid wave. The external genitalia are those of a normal adult circumcised male. The anus is without note. There is a partial thickness decubitis ulcer in the natal cleft on the left buttock that measures ½ x 3/8-inch. Healed surgical scars are not noted on the torso.

The extremities show the presence of a few healed scars on the shin and a few bruises, but no evidence of fractures, lacerations or deformities. The fingernails are trimmed and intact. A tattoo is noted (b)(6) An irregular scar is noted on the medial left ankle region that measures 1 ½ x ½-inch. There are numerous pustules associated with hair follicles on the extremities in various stages of healing.

CLOTHING AND PERSONAL EFFECTS

No clothing or personal effects are received with the body.

MEDICAL INTERVENTION

- Intravenous line inserted in the right subclavian region
- Urinary bladder catheter
- Nasogastric tube inserted into the left naris, properly located
- Medical dressing on decubitis ulcer, left buttock

ACLU Detainee DeathII ARMY MEDCOM 690

RADIOGRAPHS

A complete set of postmortem radiographs and CT images are obtained and demonstrates the following:

- Medical therapy
- Bilateral pleural effusions
- No old or recent fractures of the skull, axial skeleton or extremities
- No metallic foreign bodies

EVIDENCE OF INJURY

There is no evidence of old or recent injury.

INTERNAL EXAMINATION

BODY CAVITIES:
The body is opened by the usual thoraco-abdominal incision and the chest plate is removed. The ribs, sternum, and vertebral bodies are visibly and palpably intact. No adhesions are present in any of the body cavities. Both pleural cavities contain 300-milliliters of serosanguinous fluid. The pericardial sac contains 80-milliliters of serosanguinous fluid, and the abdominal cavity contains 3,400-milliliters of yellow serous fluid. All body organs are present in normal anatomical position.

The subcutaneous fat layer of the abdominal wall is 1-inch thick at the umbilicus.

HEAD AND CENTRAL NERVOUS SYSTEM:
The scalp is reflected. The galeal and subgaleal soft tissues of the scalp are free of injury. There are no skull fractures. The calvarium of the skull is removed. The dura mater and falx cerebri are intact. There is no epidural or subdural hemorrhage present. The leptomeninges are thin and delicate. The cerebral hemispheres are symmetrical. The structures at the base of the brain, including cranial nerves and blood vessels are intact.

Clear cerebrospinal fluid surrounds the 1,590-gram brain, which has unremarkable gyri and sulci. Coronal sections through the cerebral hemispheres reveal no lesions. Transverse sections through the brain stem and cerebellum are unremarkable. The atlanto-occipital joint is stable.

NECK:
The anterior strap muscles of the neck are homogenous and red-brown, without hemorrhage by layer-wise dissection. The thyroid cartilage is soft and the hyoid bone is intact and unfused. The larynx is lined by intact white mucosa. The tongue is free of bite marks, hemorrhage, or other injuries.

CARDIOVASCULAR SYSTEM:
The 330-gram heart is contained in an intact pericardial sac. The epicardial surface is smooth, with minimal fat investment. The coronary arteries are present in a normal distribution, with a right-

ACLU Detainee DeathII ARMY MEDCOM 691

dominant pattern. Cross sections of the vessels show no luminal narrowing and are widely patent.

The myocardium is homogenous, red-brown, and firm. The valve leaflets are thin and mobile. The walls of the left ventricle, inter-ventricular septum, and right ventricle are 1.0, 0.3 and 1.0-centimeters thick, respectively. The endocardium is smooth and glistening.

The aorta gives rise to three intact and patent arch vessels; mild atherosclerosis (fatty streaks) is noted. The renal and mesenteric vessels are unremarkable.

RESPIRATORY SYSTEM:
The upper airway is clear of debris and foreign material: the mucosal surfaces are smooth, yellow-tan and unremarkable. The parietal pleural surfaces are smooth, glistening and unremarkable bilaterally.

The pulmonary parenchyma is diffusely congested and edematous, exuding moderate to large amounts of blood and frothy fluid; no focal lesions are noted. The visceral pleural surfaces are smooth, glistening and unremarkable bilaterally.

The pulmonary arteries are normally developed, patent and without thrombus or embolus. The right lung weighs 800-grams; the left 790-grams.

HEPATOBILIARY SYSTEM:
The 2,340-gram liver has an intact smooth capsule covering very soft, yellow to tan parenchyma with no focal lesions noted. The expected liver weight for body weight is 2,315-grams.

The gallbladder contains 20-milliliters of green-brown, mucoid bile; the mucosa is velvety and unremarkable. The extrahepatic biliary tree is patent, without evidence of calculi.

GASTROINTESTINAL SYSTEM:
The esophagus is lined by gray-white, smooth mucosa; no varices are noted. The gastric mucosa is arranged in the usual rugal folds and the lumen contains 60-milliliters of tan, semi-solid material.

The small and large bowels are unremarkable. The pancreas is soft and autolyzed and the ducts are clear. The appendix is present.

GENITOURINARY SYSTEM:
The right kidney weighs 120-grams; the left 110-grams. The renal capsules are smooth and thin, semi-transparent and strip with ease from the underlying smooth, dusky red-brown cortical surface.

The cortex is sharply delineated from the medullary pyramids, which are red-purple to tan and unremarkable. The calyces, pelves and ureters are unremarkable.

White bladder mucosa with focal hemorrhage overlies an intact bladder wall. The bladder contains approximately 10-milliliters of cloudy yellow urine. The testes, prostate gland and seminal vesicles are without note.

ACLU Detainee DeathII ARMY MEDCOM 692

LYMPHORETICULAR SYSTEM:
The 210-gram spleen has a smooth, intact capsule covering red-purple, moderately firm congested parenchyma; the lymphoid follicles are unremarkable.

Lymph nodes in the hilar, periaortic and iliac regions are not enlarged.

ENDOCRINE SYSTEM:
The pituitary gland is left *in situ* and is grossly unremarkable. The thyroid gland is symmetric and red-brown, without cystic or nodular change. The right and left adrenal glands are slightly autolyzed and symmetric, with bright yellow cortices and red-brown medullae. No masses or areas of hemorrhage are identified.

MUSCULOSKELETAL SYSTEM:
No non-traumatic abnormalities of muscle or bone are identified. Skin incisions with undermining subcutaneous dissection in areas of ecchymosis are negative for traumatic injury.

SLIDE KEY AND MICROSCOPIC EXAMINATION

Selected portions of organs are retained in formalin, with preparation of histology slides.

1. Lung :} {Vascular congestion and desquamation of pnuemocytes into the alveolar
2. Lung :} {spaces. There is no evidence of acute infection.
3. Kidney: Autolysis.
4. Kidney: Autolysis.
5. Spleen: Congestion, otherwise unremarkable.
6. Liver: Severe macrosteatohepatitis, bridging fibrosis, bile stasis and biliary hyperplasia, with remarkably little inflammation.
7. Pancreas: Autolysis.
8. Heart (Left Ventricle): No pathologic diagnosis.
9. Heart: (Septum and Right Ventricle): No pathologic diagnosis.
10. Adrenal Glands: Autolysis.
11. Brain (Hippocampus): Hypoxic changes of the neurons in the CA-1 region.
12. Brain (Cerebellum): No pathologic diagnosis.
13. Brain (Pons): Hypoxic changes of the neurons in the periaqueductal gray matter.
14. Spinal Cord: No pathologic diagnosis.
15. Lymph Node: No pathologic diagnosis.
16. Thyroid Glands: No pathologic diagnosis.

ADDITIONAL PROCEDURES

1. Documentary photographs are taken by AFMES staff photographer.
2. Personal effects are released to the appropriate mortuary operations representatives.
3. Specimens retained for toxicology testing and/or DNA identification are: vitreous fluid, blood, urine, bile, gastric contents, spleen, liver, lung, kidney, brain, myocardium, adipose tissue and skeletal muscle.
4. The dissected organs are forwarded with body.

ACLU Detainee DeathII ARMY MEDCOM 693

5. Histological sections of the liver are submitted to the Department of Hepatic Pathology, AFIP for expert consultation. The results are described above (see "Slide Key and Microscopic Examination" (6. Liver).
6. Body fluids and tissue is submitted to the Department of Environmental and Infectious Disease Sciences, AFIP for heavy metal analysis. The results are described below (see "Toxicology").

FINAL AUTOPSY DIAGNOSES

I. Natural Disease
- A. Anasarca
- B. Pulmonary edema and congestion, bilateral
- C. Pleural effusions, bilateral
- D. Pericardial effusion
- E. Ascites
- F. Hepatomegaly and severe macrosteatohepatitis with bridging fibrosis, bile stasis and biliary hyperplasia
- G. Decubitis ulcer, left buttock
- H. Icterus and jaundice

II. There is no evidence of physical abuse.

III. Evidence of Medical Therapy
- A. Intravenous line inserted in the right subclavian region
- B. Urinary bladder catheter
- C. Nasogastric tube inserted into the left naris

IV. Post-Mortem Changes
- A. Rigor is absent and equal in all extremities
- B. Lividity is posterior and fixed except in areas exposed to pressure
- C. The body temperature is cold to touch
- D. Skin slippage

V. Identifying Body Marks
- A. Tattoo (b)(6)
- B. Scar on the medial left ankle region

VI. Toxicology
- A. The blood is tested for carbon monoxide and the carboxyhemoglobin saturation is less than 1%.
- B. The blood is tested for cyanide and none is detected.
- C. The blood and vitreous fluid are tested for volatile compounds including ethanol and none are found.
- D. The urine is screened for medications and drugs of abuse and the following medications are found:
  1. Lidocaine (an anti-arrhythmic medication) is present in the urine but not quantitated.

ACLU Detainee DeathII ARMY MEDCOM 694

2. Morphine (a narcotic analgesic medication) is present in the urine and is quantitated in the blood at a level of 0.57 milligrams per liter.
3. Promethazine (an anti-emetic medication) is present in the urine and is quantitated in the blood at a level of 0.16 milligrams per liter.

E. The liver, kidney, urine, blood and bile are tested for heavy metals including aluminum (Al), antimony (Sb), arsenic (As), cadmium (Cd), chromium (Cr), cobalt (Co), copper (Cu), lead (Pb), manganese (Mn), mercury (Hg), molybdenum (Mo), nickel (Ni), thallium (Tl), tin (Sn), titanium (Ti), uranium (U), vanadium (V), tungsten (W) and zinc (Zn) and the following are detected:
1. The liver and kidney did not contain elevated levels of any tested metals.
2. The blood contained elevated levels of cadmium (Cd), manganese (Mn) and tungsten (W). See the attached toxicology report for details.

OPINION

This 20-year-old male civilian detainee, (believed to be) (b)(6) died of liver failure. The liver failure progressed to multi-organ system failure over a period of approximately 2 months. The cause of the liver failure is unknown; viral markers were negative (by review of the medical records) and by history the deceased denied chemical or drug exposure. Routine toxicological testing for ethanol and screened drugs of abuse was negative. Carbon monoxide and cyanide were not detected in the blood. The medications morphine and promethazine were present in the blood at therapeutic levels, consistent with hospitalization. Extended toxicological testing for heavy metal exposure was inconclusive. Although elevated levels of cadmium (Cd), manganese (Mn) and tungsten (W) were present in the blood, they were not present in the liver and kidney tissues tested and likely represent post-mortem re-distribution or artifact. The microscopic appearance of the liver tissue is a general pattern and an etiology of the liver failure cannot be determined with certainty. Based on the current investigation, laboratory studies and autopsy findings, the manner of death is best classified as natural.

(b)(6)

(b)(6) Medical Examiner

ACLU Detainee DeathII ARMY MEDCOM 695

CERTIFICATE OF DEATH *(OVERSEAS)*
Acte de décès (D'Outre-Mer)

NAME OF DECEASED *(Last, First, Middle)* Nom du décédé (Nom et prénoms)	GRADE Grade	BRANCH OF SERVICE Arme	SOCIAL SECURITY NUMBER Numéro de l'Assurance Sociale
BTB Mosin, Raad, Saad		Civilian	(b)(6)
ORGANIZATION Organisation	**NATION** *(e.g. United States)* Pays: Iraq	**DATE OF BIRTH** Date de naissance	**SEX** Sexe: [X] MALE [ ] FEMALE

RACE Race		MARITAL STATUS État Civil			RELIGION Culte		
[X]	CAUCASOID Caucasique	[ ]	SINGLE Célibataire	[ ] DIVORCED Divorcé	[ ]	PROTESTANT Protestant	[ ] OTHER (Specify) Autre (Spécifier)
[ ]	NEGROID Negroïde	[ ]	MARRIED Marié	[ ] SEPARATED Séparé	[ ]	CATHOLIC Catholique	[X]
[ ]	OTHER (Specify) Autre (Spécifier)	[ ]	WIDOWED Veuf		[ ]	JEWISH Juif	

NAME OF NEXT OF KIN Nom du plus proche parent	RELATIONSHIP TO DECEASED Parenté du décédé avec le sus
STREET ADDRESS Domicilié à (Rue)	CITY OR TOWN OR STATE *(Include ZIP Code)* Ville (Code postal compris)

MEDICAL STATEMENT Déclaration médicale

CAUSE OF DEATH (Enter only one cause per line) Cause du décès (N'indiquez qu'une cause par ligne)			INTERVAL BETWEEN ONSET AND DEATH Intervalle entre l'attaque et le décès
DISEASE OR CONDITION DIRECTLY LEADING TO DEATH [1] Maladie ou condition directement responsable de la mort		Pending	
ANTECEDENT CAUSES Symptômes précurseurs de la mort	MORBID CONDITION, IF ANY, LEADING TO PRIMARY CAUSE Condition morbide, s'il y a lieu, menant à la cause primaire		
	UNDERLYING CAUSE, IF ANY, GIVING RISE TO PRIMARY CAUSE Condition morbide, s'il y a lieu, menant à la cause primaire		
OTHER SIGNIFICANT CONDITIONS [2] Autres conditions significatives [2]			

MODE OF DEATH Condition de décès	AUTOPSY PERFORMED Autopsie effectuée [X] YES Oui [ ] NO Non	CIRCUMSTANCES SURROUNDING DEATH DUE TO EXTERNAL CAUSES Circonstances de la mort suscitées par des causes extérieures
[X] NATURAL Mort naturelle	MAJOR FINDINGS OF AUTOPSY Conclusions principales de l'autopsie	
[ ] ACCIDENT Mort accidentelle		
[ ] SUICIDE Suicide	NAME OF PATHOLOGIST Nom du pathologiste (b)(6)	
[ ] HOMICIDE Homicide	SIGNATURE (b)(6) DATE Date 20 December 2007	AVIATION ACCIDENT Accident d'Avion [ ] YES Oui [X] NO Non

DATE OF DEATH (day, month, year) Date de décès (jour, le mois, l'année)	PLACE OF DEATH Lieu de décès
(b)(6) 2007 (b)(6)	Camp Bucca Iraq

I HAVE VIEWED THE REMAINS OF THE DECEASED AND DEATH OCCURRED AT THE TIME INDICATED AND FROM THE CAUSES AS STATED ABOVE.
J'ai examiné les restes mortels du dé funtet je conclus que le décès est survenu à l'heure indiquée et à la suite des causes énumérées ci-dessus.

NAME OF MEDICAL OFFICER Nom du médicin militaire ou du médicin sanitaire	TITLE OR DEGREE Titre ou diplômé
(b)(6)	Medical Examiner

GRADE Grade	INSTALLATION OR ADDRESS Installation ou adresse
(b)(6)	Dover AFB, Dover DE
DATE Date 12/20/2007	SIGNATURE (b)(6)

[1] State disease, injury or complication which caused death, but not
[2] State conditions contributing to the death, but not related to the d
[1] Préciser la nature de la maladie, de la blessure ou de la complication qui a provoqué la mort, sans non la manière du moins, telle qu'un arrêt du cœur, etc
[2] Préciser la condition qui a contribué à la mort, mais n'ayant aucun rapport avec la maladie ou à la condition qui a provoqué la mort

DD FORM 1 APR 77 2064 REPLACES DA FORM 3565, 1 JAN 72 AND DA FORM 3565-R(PAS), 29 SEP 75, WHICH ARE OBSOLETE.

ARMED FORCES INSTITUTE OF PATHOLOGY
Office of the Armed Forces Medical Examiner
1413 Research Blvd., Bldg. 102
Rockville, MD 20850
301-319-0000

AUTOPSY EXAMINATION REPORT

Name: Khazi, Hamid Muhsin
ID#: (b)(6)
Date of Birth: Unknown
Date of Death: (b)(6) 2007
Date/Time of Autopsy: 12 DEC 2007@0900
Date of Report: 07 JAN 2008

Autopsy No.: (b)(6)
AFIP No.: (b)(6)
Rank: Detainee
Place of Death: Iraq
Place of Autopsy: Port Mortuary
Dover AFB, Dover, DE

Circumstances of Death: This detainee was reportedly mortally wounded by small arms fire after attacking a United States Army Soldier with a wooden board and attempting to grab the soldier's pistol.

Authorization for Autopsy: Armed Forces Medical Examiner, per 10 U.S. Code 1471

Identification: Presumptive identification is established by examining accompanying paper work.

CAUSE OF DEATH: Multiple gunshot wounds

MANNER OF DEATH: Homicide

ACLU Detainee DeathII ARMY MEDCOM 697

EXTERNAL EXAMINATION

The body is that of a well-developed, well-nourished male. The body weighs 201 pounds, is 70 inches in length and appears to be 30 to 40 years of age. The body is cold. Rigor is present to an equal degree in all extremities. Lividity is present and fixed on the posterior surface of the body, except in areas exposed to pressure. The head is normocephalic, and the scalp hair is black and short. Facial hair consists of a black mustache. The irides are brown. The corneae are cloudy. The conjunctivae are pale. The sclerae are white. The external auditory canals, external nares and oral cavity are free of foreign material and abnormal secretions. The nasal skeleton and maxilla are palpably intact. The lips are without evident injury. The teeth are natural and in good condition. Examination of the neck reveals no evidence of injury. Injuries of the torso are described below. No evidence of injury of the ribs or the sternum is evident externally. The external genitalia are those of a circumcised adult male. Gauze encircles the tip of the penis and there is a 3/4 inch sutured wound of the dorsal surface of the shaft of the penis adjacent to the glans. The posterior torso and anus are without note. Injuries of the extremities are described below. Encircling the right wrist is a hospital ID band inscribed with (b)(6) A gauze bandage encircles the proximal right thigh. Underlying this gauze is a 2-3/4 x 1-1/2 inch healing and debrided wound of the posterior right thigh and a 1-1/2 inch sutured healing wound of the proximal medial right thigh.[1] Scars are noted on the posterior left arm (4 inches), right buttock (3/4 inch), right knee (1-1/2 inches and 1/4 inch), posterior left thigh (1 inch), and right popliteal fossa (1 inch). The fingernails are intact.

CLOTHING AND PERSONAL EFFECTS

Worn:

- Tan socks
- Blue running suit with gray stripes
- Yellow boxers
- White tank top t-shirt

(There are multiple defects noted on the clothing. Many of these defects correspond to injuries that are described below. No soot or gunpowder was identified upon unaided visual examination of the clothing.)

MEDICAL INTERVENTION

- EKG lead on the anterior torso
- Gauze bandages (penis and right thigh)

[1] Medical records indicate that the deceased was being treated for a gunshot wound of the right thigh and penis.

ACLU Detainee DeathII ARMY MEDCOM 698

RADIOGRAPHS

A complete set of postmortem radiographs is obtained. Injuries seen on radiographs are incorporated into the evidence of injury section.

EVIDENCE OF INJURY

The ordering of the following injuries is for descriptive purposes only, and is not intended to imply order of infliction or relative severity. All wound pathways are given relative to standard anatomic position.

GUNSHOT WOUND OF THE RIGHT SIDE OF THE CHEST:

Entrance: On the right side of the chest is a 1/4 inch circular entrance gunshot wound with a 1/8 inch concentric marginal abrasion. The wound is located 21-1/2 inches below the top of the head and 5 inches to the right of the anterior midline. No soot or gunpowder stippling is identified on the surrounding skin.

Injured: The skin, subcutaneous tissue, muscles of the right side of the chest, muscles of the ninth anterior intercostal space, right hemidiaphragm (1 inch defect), right lobe of the liver (2-1/2 x 2-1/4 inch defect), right kidney (1 inch defect through the hilum), renal artery (transected), renal vein (transected), muscle and skin are injured.

Exit: On the right side of the back is a 1/2 x 1/4 inch lacerated exit wound. The wound is located 23-1/2 inches below the top of the head and 1/2 inch to the right of the posterior midline.

Recovered: Nothing is recovered.

Trajectory: The bullet trajectory is front to back, right to left and downwards.

Associated Injuries: There is 350 ml of blood identified in the peritoneal space.

GUNSHOT WOUND OF THE LEFT SIDE OF THE CHEST (SUPERIOR):

Entrance: On the left side of the chest (below the left nipple) is a 1/4 inch circular entrance wound with a 1/8 inch concentric marginal abrasion. The wound is located 19-1/2 inches below the top of the head and 5-3/4 inches to the left of the anterior midline. No soot or gunpowder stippling is identified on the surrounding skin.

Injured: The skin, subcutaneous tissue, lateral aspect of the left fifth rib, upper lobe of the left lung (1/2 inch defect), posterior ninth intercostal muscles, muscles of the back and skin are injured.

ACLU Detainee DeathII ARMY MEDCOM 699

Exit: The projectile exits the center of the upper back through a 1/2 x 1/4 inch exit wound that has an eccentric marginal abrasion measuring up to 1/2 inch on the twelve to six o'clock border. The wound is located 16 inches below the top of the head and 1-1/4 inches to the left of the posterior midline.

Recovered: Seven copper and gray colored bullet fragments are recovered from the surface of the body and clothing.

Trajectory: The bullet trajectory is front to back, left to right and upward.

Associated Injuries: There is 1200 ml of blood identified in the left chest cavity.

GUNSHOT WOUND TO THE LEFT SIDE OF THE CHEST (MEDIAL):

Entrance: On the medial left side of the chest is a 1/4 inch circular gunshot wound with a 1/16 inch concentric marginal abrasion. The wound is located 23-1/2 inches below the top of the head and 2-1/2 inches to the left of the anterior midline. No soot or gunpowder stippling is identified on the surrounding skin.

Injured: The skin, subcutaneous tissue, muscles of the left side of the chest, peritoneum, left lobe of the liver (2 x 1 inch defect), muscles of the back and skin are injured.

Exit: There is a 1/4 x 1/8 inch partial exit wound on the right side of the back with an eccentric 3/4 inch marginal abrasion on the twelve to three o'clock border. The wound is located 19-1/2 inches below the top of the head and 4-3/4 inches to the right of the posterior midline.

Recovered: One intact copper colored jacketed projectile (with a base that measures 9 mm in greatest dimension) is recovered from the musculature of the right side of the back adjacent to the exit wound.

Trajectory: The bullet trajectory is front to back, left to right and upward.

Associated Injuries: There is 350 ml of blood identified in the peritoneal cavity.

GUNSHOT WOUND OF THE LEFT SIDE OF THE CHEST (LATERAL):

Entrance: On the lateral aspect of the left side of the chest is a 1/4 inch circular entrance gunshot wound with an eccentric marginal abrasion measuring up to 1/8 inch on the six to nine o'clock border. The wound is located 24-1/4 inches below the top of the head and 4-1/2 inches to the left of the anterior midline. No soot or gunpowder stippling is identified on the surrounding skin.

Injured: The skin, subcutaneous tissue, muscles of the left side of the chest, anterior aspect of the left ninth rib, peritoneum, left hemidiaphragm (1 inch defect), stomach (2 inch and 1-

ACLU Detainee DeathII ARMY MEDCOM 700

3/4 inch defects), upper pole of the left kidney (3/4 inch defect), tenth intercostal muscles, muscles of the back and skin are injured.

Exit: On the center of the upper back is a 3/4 x 1/2 inch exit wound with an eccentric marginal abrasion that measures up to 1/8 inch on the nine to six o'clock border. The exit wound is located 18-1/4 inches below the top of the head and is on the posterior midline.

Recovered: One deformed copper colored jacketed bullet is recovered from the muscles of the right side of the upper back adjacent to the right scapula (the deformed base measures 10 mm in greatest dimension)

Trajectory: The trajectory of the bullet is left to right, front to back, and upward.

Associated Injuries: Three hundred and fifty milliliters of blood is identified in the peritoneal cavity.

PERFORATING GUNSHOT WOUND OF THE LEFT FOREARM (PROXIMAL):

Entrance: On the proximal left forearm is a 1/4 inch circular entrance gunshot wound with a 1/16 inch concentric marginal abrasion. The wound is located 4 inches below the elbow and 1-1/2 inches to the right of the anterior midline of the forearm in the anatomic position. No soot or gunpowder stippling is identified on the surrounding skin.

Injured: The skin, subcutaneous tissue, muscle and skin are injured.

Exit: On the proximal left forearm is a 1/4 x 1/4 inch lacerated exit wound located 4 inches below the elbow and 1/4 inches to the left of the anterior midline of the forearm in the anatomic position.

Recovered: Nothing is recovered.

Trajectory: The bullet trajectory is right to left, slightly back to front with no significant up-down deviation.

Associated Injuries: There is bleeding along the wound tract.

PERFORATING GUNSHOT WOUND OF THE LEFT FOREARM (DISTAL):

Entrance: On the left forearm is a 1/4 inch circular entrance gunshot wound with a concentric 1/16 inch marginal abrasion. The wound is located 7-1/2 inches below the elbow and 2 inches to the right of the anterior midline of the forearm in the anatomic position. No soot or gunpowder stippling is identified on the surrounding skin.

Injured: The skin, subcutaneous tissue, muscle, and skin are injured.

ACLU Detainee DeathII ARMY MEDCOM 701

Exit: On the left forearm is a 1/4 x 1/4 inch lacerated exit wound located 7-1/2 inches below the elbow and in the anterior midline of the forearm in the anatomic position.

Recovered: Nothing is recovered.

Trajectory: The trajectory of the bullet is right to left, slightly back to front with no significant up-down deviation.

Associated Injuries: Associated with this wound is bleeding along the wound tract.

OTHER INJURIES:

By medical report there is a perforating gunshot wound of the right thigh. This injury is in the process of healing and has been treated medically (please see the External Examination section above). The skin, subcutaneous tissues and muscle are injured. The trajectory is indeterminate.

By medical report there is a gunshot wound of the penis. The injury is in the process of healing and has been medically treated (please see the External Examination section above). The skin and subcutaneous tissues are injured. The trajectory is indeterminate.

INTERNAL EXAMINATION

BODY CAVITIES:

The body is opened by the usual thoraco-abdominal incision and the chest plate is removed. The sternum, and vertebral bodies are visibly and palpably intact. No adhesions in any of the body cavities. Blood is identified in the right chest cavity (150 ml), left chest cavity (1200 ml), and peritoneum (350 ml). All body organs are present in normal anatomical position. The subcutaneous fat layer of the abdominal wall is 3/4 inches thick.

HEAD AND CENTRAL NERVOUS SYSTEM:

The scalp is reflected. The galeal and subgaleal soft tissues of the scalp are free of injury. There are no skull fractures. The calvarium of the skull is removed. The dura mater and falx cerebri are intact. There is no epidural or subdural hemorrhage present. The leptomeninges are thin and delicate. The cerebral hemispheres are symmetrical. The structures at the base of the brain, including cranial nerves and blood vessels are intact. Clear cerebrospinal fluid surrounds the 1530 gram brain, which has unremarkable gyri and sulci. Coronal sections through the cerebral hemispheres reveal no lesions. Transverse sections through the brain stem and cerebellum are unremarkable. The atlanto-occipital joint is stable. The spinal cord is unremarkable.

NECK:

The anterior strap muscles of the neck are homogenous and red-brown, without hemorrhage by layer-wise dissection. The thyroid cartilage and hyoid bone are intact. The larynx is lined by intact white mucosa. The tongue is free of bite marks, hemorrhage, or other injuries. Incision and

ACLU Detainee DeathII ARMY MEDCOM 702

dissection of the posterior neck demonstrates no deep paracervical muscular injury and no cervical spine fractures.

CARDIOVASCULAR SYSTEM:

The 430 gram heart is contained in an intact pericardial sac. The epicardial surface is smooth, with minimal fat investment. The coronary arteries are present in a normal distribution, with a left-dominant pattern. Cross sections of the vessels show wide patency. The myocardium is homogenous, red-brown, and firm. The valve leaflets are thin and mobile. The walls of the left ventricle, interventricular septum, and right ventricle are 1.2, 1.2, and 0.3-cm thick, respectively. The endocardium is smooth and glistening. The aorta gives rise to three intact and patent arch vessels. The renal and mesenteric vessels are unremarkable.

RESPIRATORY SYSTEM:

Please see Evidence of Injury. The upper airway is clear of debris and foreign material; the mucosal surfaces are smooth, yellow-tan and unremarkable. The pleural surfaces are smooth, glistening and unremarkable bilaterally. The pulmonary parenchyma is diffusely congested and edematous, exuding slight to moderate amounts of blood and frothy fluid; no focal non-traumatic lesions are noted. The pulmonary arteries are normally developed, patent and without thrombus or embolus. The right lung weighs 720 grams; the left 380 grams.

HEPATOBILIARY SYSTEM:

Please see Evidence of Injury. The 1950 gram liver, where uninjured, has a smooth capsule covering dark red-brown, moderately congested tan-brown parenchyma with no focal non-traumatic lesions noted. The gallbladder contains 5 ml of green-brown, mucoid bile; the mucosa is velvety and unremarkable. The extrahepatic biliary tree is patent, without evidence of calculi.

GASTROINTESTINAL SYSTEM:

Please see Evidence of Injury. The esophagus is lined by gray-white, smooth mucosa. The gastric mucosa is arranged in the usual rugal folds and the lumen contains scant mucoid brown fluid. The small and large bowels are unremarkable. The pancreas has a normal pink-tan lobulated appearance and the ducts are clear. The appendix is present.

GENITOURINARY SYSTEM:

Please see Evidence of Injury. The injured right kidney weighs 150 grams; the injured left kidney weighs 150 grams. The renal capsules are smooth and thin, semi-transparent and strip with ease from the underlying smooth, red-brown cortical surface. The cortex is sharply delineated from the medullary pyramids, which are red-purple to tan and unremarkable. The calyces, pelves and ureters are unremarkable. White bladder mucosa overlies an intact bladder wall. The bladder contains approximately 50 ml of clear yellow urine. The testes, prostate gland and seminal vesicles are without note.

ACLU Detainee DeathII ARMY MEDCOM 703

LYMPHORETICULAR SYSTEM:

The 120 gram spleen has a smooth, intact capsule covering red-purple, moderately firm parenchyma; the lymphoid follicles are unremarkable. Lymph nodes in the hilar, periaortic and iliac regions are not enlarged.

ENDOCRINE SYSTEM:

The pituitary gland is examined in situ and is unremarkable. The thyroid gland is symmetric and red-brown, without cystic or nodular change. The right and left adrenal glands are symmetric, with bright yellow cortices and red-brown medullae. No masses or areas of hemorrhage are identified.

MUSCULOSKELETAL SYSTEM:

No non-traumatic abnormalities of muscle or bone are identified.

ADDITIONAL PROCEDURES

1. Documentary photographs are taken by (b)(6) OAFME staff photographer.
2. Personal effects are released to the appropriate mortuary operations representatives.
3. Specimens retained for toxicology testing and/or DNA identification are: blood, vitreous fluid, bile, urine, gastric contents, brain, heart, lung, liver, spleen, kidney, brain, skeletal muscle and adipose tissue.
4. The dissected organs are forwarded with body.
5. The recovered evidence is turned released to Special Agent (b)(6) CID.

MICROSCOPIC EXAMINATION

Selected portions of organs are retained in formalin, without preparation of histology slides.

ACLU Detainee DeathII ARMY MEDCOM 704

FINAL AUTOPSY DIAGNOSES:

I Gunshot wound of the right side of the chest

A Entrance: On the right side of the chest is a 1/4 inch circular entrance gunshot wound with a 1/8 inch concentric marginal abrasion; located 21-1/2 inches below the top of the head and 5 inches to the right of the anterior midline; no soot or gunpowder stippling is identified on the surrounding skin.

B Injured: The skin, subcutaneous tissue, muscles of the right side of the chest, muscles of the ninth anterior intercostal space, right hemidiaphragm (1 inch defect), right lobe of the liver (2-1/2 x 2-1/4 inch lacerated wound), right kidney (1 inch defect through the hilum), renal artery (transected), renal vein (transected), muscle and skin are injured

C Exit: On the right side of the back is a 1/2 x 1/4 inch lacerated exit wound; the wound is located 23-1/2 inches below the top of the head and 1/2 inch to the right of the posterior midline

D Recovered: Nothing recovered at autopsy

E Trajectory: Front to back, right to left and downward

F Associated Injuries: Hemoperitoneum (350 ml)

II Gunshot wound of the left side of the chest (superior):

A Entrance: On the left side of the chest (below the left nipple) is a 1/4 inch circular entrance wound with a 1/8 inch concentric marginal abrasion; located 19-1/2 inches below the top of the head and 5-3/4 inches to the left of the anterior midline; no soot or gunpowder stippling is identified on the surrounding skin

B Injured: The skin, subcutaneous tissue, lateral aspect of the left fifth rib, upper lobe of the left lung (1/2 inch defect), posterior ninth intercostal muscles, muscles of the back and skin are injured

C Exit: The projectile exits the center of the upper back through a 1/2 x 1/4 inch exit wound that has an eccentric marginal abrasion which measures up to 1/2 inch on the twelve to six o'clock border; the wound is located 16 inches below the top of the head and 1-1/4 inches to the left of the posterior midline

D Recovered: Seven copper and gray colored bullet fragments are recovered from the surface of the body and clothing

E Trajectory: Front to back, left to right and upward

F Associated Injuries: Left hemothorax (1200 ml)

III Gunshot wound of the left side of the chest (medial):

A Entrance: On the medial left side of the chest is a 1/4 inch circular gunshot wound with a 1/16 inch concentric marginal abrasion; located 23-1/2 inches below the top of the head and 2-1/2 inches to the left of the anterior midline; no soot or gunpowder stippling is identified on the surrounding skin

B Injured: The skin, subcutaneous tissue, muscle of the left side of the chest, peritoneum, left lobe of the liver (2 x 1 inch defect), muscles of the back and skin are injured

C Exit: There is a 1/4 x 1/8 inch partial exit wound on the right side of the back with an eccentric 3/4 inch marginal abrasion on the twelve to three o'clock border; located 19-1/2 inches below the top of the head and 4-3/4 inches to the right of the posterior midline

ACLU Detainee DeathII ARMY MEDCOM 705

D Recovered: One intact copper colored jacketed projectile (with a base that measures 9 mm in greatest dimension) is recovered from the musculature of the right side of the back adjacent to the exit wound
E Trajectory: Front to back, left to right and upward.
F Associated Injuries: Hemoperitoneum (350 ml)

IV Gunshot wound of the left side of the chest (lateral):
A Entrance: On the lateral aspect of the left side of the chest is a 1/4 inch circular entrance gunshot wound with an eccentric marginal abrasion measuring up to 1/8 inch on the six to nine o'clock border; located 24-1/4 inches below the top of the head and 4-1/2 inches to the left of the anterior midline; no soot or gunpowder stippling is identified on the surrounding skin
B Injured: The skin, subcutaneous tissue, muscles of the left side of the chest, anterior aspect of the left ninth rib, peritoneum, left hemidiaphragm (1 inch defect), stomach (2 inch and 1-3/4 inch defects), upper pole of the left kidney (3/4 inch defect), tenth intercostal muscles, muscles of the back and skin are injured.
C Exit: On the center of the upper back is a 3/4 x 1/2 inch exit wound with an eccentric marginal abrasion that measures up to 1/8 inch on the nine to six o'clock border; located 18-1/4 inches below the top of the head and is on the posterior midline
D Recovered: One deformed copper colored jacketed bullet is recovered from the muscles of the right side of the upper back adjacent to the right scapula
E Trajectory: Left to right, front to back, and upward.
F Associated Injuries: Three hundred and fifty milliliters of blood is identified in the peritoneal cavity

V Perforating gunshot wound of the left forearm (proximal):
A Entrance: On the proximal left forearm is a 1/4 inch circular entrance wound with a 1/16 inch concentric marginal abrasion; located 4 inches below the elbow and 1-1/2 inches to the right of the anterior midline of the forearm in the anatomic position; no soot or gunpowder stippling is identified
B Injured: The skin, subcutaneous tissue, muscle and skin are injured
C Exit: On the proximal left forearm is a 1/4 x 1/4 inch lacerated exit wound; located four inches below the elbow and 1/4 inch to the left of the anterior midline of the forearm in the anatomic position
D Recovered: Nothing recovered
E Trajectory: Right to left, slightly back to front with no significant up-down deviation
F Associated Injury: Bleeding along the wound tract

VI Perforating gunshot wound of the left forearm (distal):
A Entrance: On the left forearm is a 1/4 inch circular entrance gunshot wound with a 1/16 inch marginal abrasion; located 7-1/2 inches below the elbow and 2 inches to the right anterior midline of the forearm in the anatomic position; no soot or gunpowder stippling identified
B Injured: The skin, subcutaneous tissue, muscle and skin are injured
C Exit: On the left forearm is a 1/4 x 1/4 inch lacerated exit wound; located 7-1/2 inches below the elbow and in the anterior midline of the forearm in the anatomic position

ACLU Detainee DeathII ARMY MEDCOM 706

D Recovered: Nothing recovered
E Trajectory: Right to left and slightly back to front with no significant up-down deviation
F Associated Injuries: Bleeding along the wound tract

VII Other Injuries: Healing and medically treated gunshot wounds of the penis and right thigh

VIII Natural Disease: No significant natural disease is identified within the limits of the examination

IX Medical Therapy and Remote Injuries: As described above

X Postmortem Changes: As described above

XI Identifying Marks: As described above

XII Toxicology (AFIP):
A VOLATILES: No ethanol is detected in the blood and vitreous fluid
B DRUGS: Ketamine (an anesthetic) and ephedrine (a sympathomimetic amine commonly used to treat hypotention associated with regional anesthesia) are detected in the urine
C CARBON MONOXIDE: The carboxyhemoglobin level in the blood is 1%
D CYANIDE: No cyanide is detected in the blood

ACLU Detainee DeathII ARMY MEDCOM 707

OPINION

This 30 to 40-year-old male (b)(6) died of multiple gunshot wounds. There were four gunshot wounds of the torso and two gunshot wounds of the left forearm. No evidence of close range discharge of a firearm was identified on the clothing or skin surrounding any of the entrance wounds. It is my opinion that three of the four exit wounds on the back of the torso appear to be shored. The recovered evidence was turned over to Special (b)(6) CID. The toxicology screen is positive for ketamine and ephedrine. Ketamine and ephedrine are commonly used medications and their detection is unrelated to the cause and manner of death. The manner of death is homicide.

(b)(6)

(b)(6) MEDICAL EXAMINER

ACLU Detainee DeathII ARMY MEDCOM 708

CERTIFICATE OF DEATH (OVERSEAS)

Acte de décès (D'Outre-Mer)

NAME OF DECEASED (Last, First, Middle) Nom du décédé (Nom et prénoms)	GRADE Grade	BRANCH OF SERVICE Arme	SOCIAL SECURITY NUMBER
BTB Khazi, Hamid, Muhsin		Civilian	(b)(6)
ORGANIZATION Organisation	NATION (e.g. United States) Pays: Iraq	DATE OF BIRTH Date de naissance	SEX Sexe: [X] MALE [ ] FEMALE

RACE		MARITAL STATUS			RELIGION		
[X]	CAUCASOID Caucasien	[ ]	SINGLE Célibataire	[ ] DIVORCED Divorcé	[ ]	PROTESTANT Protestant	[ ] OTHER (Specify) Autre (Spécifier)
[ ]	NEGROID Nègroïde	[ ]	MARRIED Marié	[ ] SEPARATED Séparé	[ ]	CATHOLIC Catholique	[X]
[ ]	OTHER (Specify) Autre (Spécifier)	[ ]	WIDOWED Veuf		[ ]	JEWISH Juif	

NAME OF NEXT OF KIN Nom du plus proche parent:

RELATIONSHIP TO DECEASED Parenté du décédé avec le vue:

STREET ADDRESS Domicile à (Rue):

CITY OR TOWN OR STATE (Include ZIP Code) Ville (Code postal compris):

MEDICAL STATEMENT Déclaration médicale

	CAUSE OF DEATH (Enter only one cause per line) Cause du décès (N'indiquer qu'une cause par ligne)	INTERVAL BETWEEN ONSET AND DEATH Intervalle entre l'début et le décès
DISEASE OR CONDITION DIRECTLY LEADING TO DEATH Maladie ou condition entraînant directement la mort	Multiple gunshot wounds	Seconds to Minutes
ANTECEDENT CAUSES Symptômes précurseurs de la mort. MORBID CONDITION, IF ANY, LEADING TO PRIMARY CAUSE Condition morbide, s'il y a lieu, menant à la cause primaire		
ANTECEDENT CAUSES Symptômes précurseurs de la mort. UNDERLYING CAUSE, IF ANY, GIVING RISE TO PRIMARY CAUSE Condition morbide, s'il y a lieu, menant à la cause primaire		
OTHER SIGNIFICANT CONDITIONS Autres conditions significatives		

MODE OF DEATH Condition du décès

- [ ] NATURAL Mort naturelle
- [ ] ACCIDENT Mort accidentelle
- [ ] SUICIDE Suicide
- [X] HOMICIDE Homicide

AUTOPSY PERFORMED Autopsie effectuée: [X] YES Oui [ ] NO Non

MAJOR FINDINGS OF AUTOPSY Constatations principales de l'autopsie:

NAME OF PATHOLOGIST Nom du pathologiste: (b)(6)

DATE Date: 12 December 2007

CIRCUMSTANCES SURROUNDING DEATH DUE TO EXTERNAL CAUSES Circonstances de la mort ascribées par des causes extérieures:

AVIATION ACCIDENT Accident d'Avion: [ ] YES Oui [X] NO Non

DATE OF DEATH (Day, month, year) Date de décès (Jour, le mois, l'année): (b)(6) 2007

PLACE OF DEATH Lieu de décès: Iraq

I HAVE VIEWED THE REMAINS OF THE DECEASED AND DEATH OCCURRED AT THE TIME INDICATED AND FROM THE CAUSES AS STATED ABOVE.
J'ai examiné les restes mortels du défunt et je conclus que le décès est survenu à l'heure indiquée et à, la suite des causes énumérées ci-dessus.

NAME OF MEDICAL OFFICER: (b)(6) TITLE OF OFFICER Titre du officier: Medical Examiner

(b)(6)

INSTALLATION OR ADDRESS: Dover AFB, Dover DE

DATE Date: 12/13/2007

SIGN: (b)(6)

1 State disease, injury or complication which caused death, but not mode or agency through which it occurred, such as heart failure, etc.
2 Enter conditions contributing to the death, but not related to the disease or condition causing death.
1 Indiquer la maladie, la blessure ou la complication qui a provoqué la mort, mais non le mode ou l'agent par lequel elle est survenue, tels que l'arrêt du cœur, etc.
2 Indiquer les conditions qui ont contribué à la mort, mais non reliées à la maladie ou à l'état morbide provoquant la mort.

DD FORM 1 JAN 77 2064 REPLACES DA FORM 3066, 1 JAN 72 AND DA FORM 3065-R(AR), 30 SEP 75, WHICH ARE OBSOLETE.

(REMOVE, REVERSE AND RE-INSERT CARBONS BEFORE COMPLETING THIS SIDE)

DISPOSITION OF REMAINS

NAME OF MORTICIAN PREPARING REMAINS	GRADE	LICENSE NUMBER AND STATE	OTHER

INSTALLATION OR ADDRESS	DATE	SIGNATURE
(b)(6)		

NAME OF CEMETERY OR CREMATORY	LOCATION OF CEMETERY OR CREMATORY

TYPE OF DISPOSITION	DATE OF DISPOSITION

REGISTRATION OF VITAL STATISTICS

REGISTRY (Town and County)	DATE REGISTERED	FILE NUMBER	
		STATE	OTHER

NAME OF FUNERAL DIRECTOR	ADDRESS

SIGNATURE OF AUTHORIZED INDIVIDUAL

DD FORM 2064, APR 1977 (BACK) USAPA V1.00

ACLU Detainee DeathII ARMY MEDCOM 710

ARMED FORCES INSTITUTE OF PATHOLOGY
Office of the Armed Forces Medical Examiner
1413 Research Blvd., Bldg. 102
Rockville, MD 20850
301-319-0000

AUTOPSY EXAMINATION REPORT

Name: DIAB, Yahiyr Diasti
SSAN: (b)(6)
Date of Birth: Estimate 1950s
Date of Death: (b)(6) 2007
Place of Death: 31st Combat Support Hospital, Camp Cropper, Iraq

Autopsy No.: (b)(6)
AFIP No. (b)(6)
Rank: Detainee

Date and Time of Autopsy: 07 DEC 2007, 1100
Place of Autopsy: Port Mortuary, Dover AFB, DE

Date of Report: 03 MAR 2008

Circumstances of Death: This estimated 50-year-old male, Iraqi detainee was pronounced dead at the intensive care unit of the 31st Combat Support Hospital (CSH) at Camp Cropper, Iraq on (b)(6) 2007. The decedent was admitted to the 31st CSH on 25 November 2007 with complains of vomiting blood and passing tarry stool for approximately three days. He was transferred to the 332 Expeditionary Medical Group in Balad for management of his condition. While at Balad, he had an upper endoscopy procedure with the finding of esophageal varices and underwent banding of the lesion. He was transferred back to the 31st CSH at Camp Cropper on 27 November 2007 for continuing inpatient hospitalization. He was pronounced dead with severe variceal bleeding, liver failure, and severe sepsis.

Authorization for Autopsy: Armed Forces Medical Examiner, IAW 10 USC 1471

Identification: Presumptive identification by incarceration serial number

CAUSE OF DEATH: Gastrointestinal hemorrhage

MANNER OF DEATH: Natural

ACLU Detainee DeathII ARMY MEDCOM 711

On 07 December 2007 at 1100, a complete postmortem examination is performed on the body of (b)(6) who was presumptively identified by his incarceration serial number in theater.

EXTERNAL EXAMINATION

The body is received nude with evidence of medical intervention as noted below. The body is that of a well-developed, well-nourished, adult male and cold from refrigeration. He is 69 inches long, weighs 272 pounds, and appears consistent with an estimated age of 50-years. Rigor mortis is dissipated. Postmortem lividity is fixed on the posterior surface of the body with moderate suffusion of the head and neck.

The head is covered with short black and gray hair in a normal distribution. The irides are brown, corneas are clear, and the sclerae are lightly yellow. The pupils are round and equal in diameter. No contact lenses are present and no conjunctival petechiae are seen. The nose is unremarkable. No foreign material is present in the nostrils or the oral cavity. The lips and frenula are atraumatic. Natural teeth are present with signs of tooth decay and gum disease. The external auditory canals are free of blood. The ears are unremarkable and not pierced. The face has a full beard and mustache.

The neck has no masses or deformities. The chest is symmetric with no increase in the anteroposterior diameter. The abdomen is not distended. The external genitalia are those of a circumcised adult male. The testes are descended and free of masses. There is moderate edema of the penis and scrotum. Pubic hair is present in a normal distribution. The back and buttocks are unremarkable.

The upper and lower extremities are symmetric with evidence of pedal edema. The following scars are present on the legs:

- A ¾ x ⅛-inch scar of the posterior aspect of the left thigh
- A ¾ x ⅛-inch scar of the anterior aspect of the right leg
- A 1 ¼ x ½-inch scar of the anterior aspect of the left leg

CLOTHING AND PERSONAL EFFECT

None

MEDICAL INTERVENTION

- Puncture wounds (x2) covered with gauze, taped in place over the left subclavian area
- Intravenous catheter and arterial catheter inserted and covered with gauze, taped in place over the right femoral area
- Intravenous catheter inserted and covered with gauze, taped in place over the dorsum of the left hand
- Patches of shaved body hair of the right and left chest surfaces
- Puncture with hematoma of the distal right arm

ACLU Detainee DeathII ARMY MEDCOM 712

POSTMORTEM ARTIFACTS
None

RADIOGRAPHS
A complete set of total body postmortem radiographs is obtained and shows no evidence of fractures or foreign materials.

EVIDENCE OF INJURY
There is no evidence of blunt or sharp force injuries.

INTERNAL EXAMINATION

BODY CAVITIES:
The body is opened with a standard Y-shaped incision. The abdominal panniculus is 4-cm thick at the umbilicus. The muscles of the chest and abdominal walls are normal. The rib cage, sternum, and clavicles are intact. The mediastinum is unremarkable. The visceral and parietal pleural surfaces are smooth and glistening; however, there are pleural adhesions of the lateral wall and apex of the right lung, and posterior wall of the left lung. There is approximately 100 ml of clear straw-colored fluid in the pericardial sac. The right and left pleural cavities contain 300 ml and 150 ml of clear straw-colored fluid, respectively. The peritoneal cavity has 150 ml of clear straw-colored fluid. The organs occupy their usual anatomic positions within the pleural and peritoneal cavities. There is no evidence of pericarditis or peritonitis. The omentum and retroperitoneum are unremarkable.

NECK:
The larynx and trachea are in the midline. There is no hemorrhage in the skin, fat or sternocleidomastoid muscles of the anterior neck. The strap muscles and large vessels have no abnormalities. The thyroid cartilage and hyoid bone are intact. The larynx has smooth pink-tan mucosa without focal lesions. No foreign material is present. The tongue is free of bite marks, hemorrhage, or other injuries. The soft tissues of the neck are free of hemorrhage. No fractures or dislocations of the cervical vertebrae are detected.

CARDIOVASCULAR SYSTEM:
The 480 gm heart is contained in an intact pericardial sac. The epicardial surface is smooth, with minimal fat investment. There are no epicardial petechiae. The coronary arteries are present in a normal distribution with a right dominant pattern and are unremarkable on multiple cross sections of the vessels. The myocardium is homogenous, dark red-brown, and soft with no gross myocardial fibrosis noted. No defects in the atrial or ventricular septa are present. The valve leaflets are thin and mobile. The circumferences of the cardiac valves are within normal limit for age and heart size. The left ventricle measures 1.8 cm, right ventricle 0.5 cm, and interventricular septum 1.8 cm in thickness. The endocardium is smooth and glistening.

ACLU Detainee DeathII ARMY MEDCOM 713

The aorta gives rise to three intact and patent arch vessels. There are atheromatous plaques of the intima of the abdominal aorta. No evidence of aneurysm, coarctation, dissection, or laceration of the aorta is noted. The renal and mesenteric vessels are unremarkable.

RESPIRATORY SYSTEM:
The right and left lungs weigh 1090 and 970 gm, respectively. The trachea is complete, without malformation, from the larynx to the carina. There is no aspirated gastric material or aspirated blood in the trachea. The pleural surfaces are smooth and glistening. The lungs and hilar nodes are moderately anthracotic and there is no gross emphysematous change. On cut section, there is no aspirated blood apparent in alveoli. The pulmonary parenchyma is diffusely edematous. No mass lesions or areas of consolidation are present. There is no pulmonary contusion. Pulmonary thromboemboli are not present.

HEPATOBILIARY SYSTEM:
The 1030 gm liver has a lumpy capsule with a 3-cm scar-like structure of the anterior-superior-lateral aspect of the right lobe. The parenchyma is yellow-tan and has a lobular architecture. No mass lesions or other abnormalities are seen. The gallbladder is present and contains approximately 10 ml of black bile sludge. There is no stone in the gallbladder. The mucosal surface is green and velvety. The extrahepatic biliary tree is patent.

HEMOLYMPHATIC SYSTEM:
The 750 gm intact spleen has a reddish thickened capsule. The parenchyma is deep red, with indistinct Malpighian corpuscles. Autolysis is not significant.

Lymph nodes are not prominent in the cervical region, thoracic or peritoneal cavities.

UROGENITAL SYSTEM:
The right and left kidneys weigh 140 and 290 gm, respectively. The renal capsules strip with ease from the underlying smooth cortical surfaces. The cut surfaces are red-tan, with uniformly thick cortices and sharp corticomedullary junctions. The pelves are unremarkable and the ureters are normal in course and caliber. There are no stones or tumors in the kidneys, pelves, ureters, or bladder. The bladder wall is intact and covered with white mucosa, except for a focal area of hemorrhage of the posterior wall. The bladder contains approximately 15 ml of pinkish-colored urine. The prostate is normal in size, with lobular, yellow-tan parenchyma. The seminal vesicles are unremarkable. The testes are free of mass lesions, contusions, or other abnormalities.

GASTROINTESTINAL TRACT:
The esophagus is intact and lined by smooth, grey-white mucosa. There is evidence of banding of the distal esophageal mucosa at the region of the gastroesophageal junction. The stomach contains approximately 500 ml of blood and blood clots. The gastric wall is intact. The small and large intestines are intact and full of liquid blood. The appendix is present. There is blood oozing at the anus.

ACLU Detainee DeathII ARMY MEDCOM 714

On further examination after formalin fixation of the proximal stomach and distal esophagus, there is an ovoid 2 x 0.5-cm erosion-like, vertically oriented, lesion of the distal esophageal mucosa. The lower edge of this lesion is encroaching on the gastroesophageal junction. Approximately 0.5 cm distal from the lower edge of this lesion is a 1.5 x 0.7-cm erosion of the gastroesophageal junction mucosa within which a 0.5-cm elastic banded stump is present.

ENDOCRINE SYSTEM:
The thyroid gland is normal in size and symmetric with dark red-brown parenchyma. No masses are present.

The right and left adrenal glands are symmetric, with bright yellow cortices and grey medullae. No masses or areas of hemorrhage are identified. Autolysis is not significant.

PANCREAS:
The pancreas is firm and yellow-tan, with the usual lobular architecture. No mass lesions or other abnormalities are seen. Autolysis is not significant.

MUSCULOSKELETAL SYSTEM:
The vertebral column and pelvis are visibly and palpably intact. The musculature is normally developed and of the usual color and consistency. The back and posterior aspect of the lower extremities are incised with two continuous incisions from the shoulder to the ankles and shows no evidence of injuries.

HEAD AND CENTRAL NERVOUS SYSTEM:
The cranial cavity is opened with a coronal incision of the scalp and removal of the calvarium. The galeal and subgaleal soft tissues of the scalp are free of injury. The calvarium is intact, as is the dura mater beneath it. There is no evidence of epidural, subdural, or subarachnoid hemorrhage. The brain weighs 1480 gm. The leptomeninges are transparent and strip with ease. The gyral pattern and sulci are unremarkable. The major vessels at the base of the brain have the usual anatomic distribution and no significant atherosclerosis is found. The cranial nerves are symmetrical and intact. No evidence of herniation is present. Coronal sections through the cerebral hemispheres reveal no lesions. The ventricles are of normal size and contain clear cerebrospinal fluid. Transverse sections through the brain stem and cerebellum are unremarkable. There are no skull fractures. The atlanto-occipital joint is stable. The spinal cord is not examined in its entirety.

OTHER PROCEDURES

1. Photographic evidence is obtained by OAFME photographers.
2. Specimens for toxicology: blood, bile, vitreous, urine, liver tissue, kidney tissue, lung tissue, spleen tissue, brain tissue, heart tissue, and adipose tissue.
3. Specimen collected for DNA analysis: psoas muscle.
4. Representative tissue samples are retained in formalin, with preparation of histologic slides.
5. Dissected organs are forwarded with the body.

ACLU Detainee DeathII ARMY MEDCOM 715

MICROSCOPIC EXAMINATION

Lungs (slide 1 -5): diffuse pulmonary edema with emphysematous change and no evidence of increase inflammatory cells infiltrate. There are scattered foci of microscopic calcification within the parenchyma and diffuse anthracotic deposition.

Kidneys (slide 8): tubular autolysis with scattered glomerulosclerosis. A focal fibrosis is seen in the medulla.

Spleen (slide 9 – 11): congestion with increase fibrosis of the red pulp areas. White pulp is present with unremarkable periarteriolar lymphatic sheath.

Esophageal defect (slide 12 – 14): denuded squamous epithelium with coagulative necrotic changes and early replacement fibrosis. There are numerous dilated vascular spaces in the submucosal tissue with some of them containing early organizing thrombi. There is no evidence of acute rupture of the blood vessels in this area.

Consultation

Liver: Hepatoportal sclerosis

The liver is extremely autolyzed. Changes are best appreciated on the Masson stains.

There is considerable parenchymal atrophy, causing the vascular structures (portal tracts and central veins) to be close together and wrinkling of the Glisson's capsule in section 7. There is no cirrhosis, but there is a great deal of portal fibrosis with portal-portal bridging. Hepatic artery branches are present in the portal tracts, but many small portal tracts have only small portal vein branches or lack portal veins entirely. Several large portal areas have veins that are markedly thickened by intimal proliferation, presumably secondary to the patient's portal hypertension. A few outflow veins are also thickened. The features are those of the uncommon disorder known variably as "hepatoportal sclerosis", "idiopathic portal hypertension", or "noncirrhotic portal fibrosis". The cause and pathogenesis are uncertain, but patients with this disease can develop severe portal hypertension in the absence of cirrhosis. See attached pictures.


Atrophic Liver


Wrinkled Capsule


Small Portal Vein Branch


Missing Portal Veins

ACLU Detainee DeathII ARMY MEDCOM 716



Thickened Large Portal Vein - Arrows show original vein wall.



Recanalized Large Portal Vein



Portal & Bridging Fibrosis

References:

1. Aikat BK, et al: The pathology of noncirrhotic portal fibrosis. Human Pathol1979; 10:405-418
2. Okuda K, et al: Liver pathology of idiopathic portal hypertension. Comparison with non-cirrhotic portal fibrosis of India. Liver 1982; 2:176-192.
3. Bioulac-Sage P, et al: Hepatoportal sclerosis. Sem Liver Dis 1995; 15:329-339.
4. Nakanuma Y, et al: Pathology and pathogenesis of idiopathic portal hypertension with an emphasis on the liver. Pathol Res Pract 2001; 197:65-76.
5. Fiel MI, et al: Liver failure and need for transplantation in patients with advanced hepatoportal sclerosis. Am J Surg Pathol 2007; 31:607-614.

//SIGNED//
(b)(6)

Armed Forces Institute of Pathology

ACLU Detainee DeathII ARMY MEDCOM 717

FINAL AUTOPSY DIAGNOSES:

I. Gastrointestinal hemorrhage
- A. Hepatoportal sclerosis
- B. Status post banding for esophageal varices
- C. Approximately 500 ml of blood and blood clot collected in the stomach
- D. Intestinal lumen is filled with blood with discharge of blood via the anus

II. Other natural disease diagnoses
- A. Concentric left ventricular hypertrophy
- B. Microscopic finding of diffuse enlarged portal fibrosis of the liver
- C. Splenomegaly (750 gm)
- D. Asymmetrical kidneys (right – 140 gm, left -290 gm)
- E. Pericardial, pleural, and peritoneal effusions
- F. Pedal and scrotal edema

III. Medical therapy
- A. Intravenous catheter inserted and covered with gauze of the left subclavian area
- B. Arterial catheter and intravenous catheter inserted and covered with gauze of the right femoral area
- C. Intravenous catheter inserted and covered with gauze of the left hand
- D. Puncture wound with hematoma of the right arm

IV. Identifying marks
- A. Scar of the posterior aspect of the right thigh
- B. Scars of the anterior aspects of both legs

V. Toxicology results
- A. No ethanol detected in the blood and vitreous fluid
- B. Drug screen
  - a. Lidocaine detected in the urine
  - b. Morphine detected in the urine. The blood contained 0.11 mg/L
  - c. Acetaminophen detected in the urine. The blood contained 5 mg/L
  - d. Midazolam detected in the urine. The blood contained 0.34 mg/L
  - e. 1-Hydorxymidazolam detected in the urine. The blood contained 0.025 mg/L

ACLU Detainee DeathII ARMY MEDCOM 718

OPINION

This estimated 50-year-old male died as a result of acute upper gastrointestinal hemorrhage from esophageal variceal bleeding.

The banding of the esophageal varices was in place. The lesion of the distal esophagus was consistent with that of a healing erosion above the banded esophageal varice. Although we did not find the source of the bleeding, re-bleeding is a known complication with high mortality of the esophageal varices. Esophageal varices develop in 90% of cirrhotic patients and are most often associated with alcoholic cirrhosis. Worldwide, hepatic schistosomiasis is the second most common cause of variceal bleeding. The decedent's liver showed characteristic of an uncommon disorder known as hepatoportal sclerosis as indicated from the AFIP consultation. As such, patients with this disorder were known to develop severe portal hypertension, and ultimately gastroesophageal varices.

The postmortem toxicology analysis showed the present of lidocaine, morphine, acetaminophen, midazolam, and 1-hydroxymidazolam (a byproduct of midazolam) consistent with medical therapeutic modalities.

We had requested the complete medical record for the time of his hospitalization from 25 November 2007 to the time of his death on (b)(6) 2007; however, received only the documentation for the admission, brief surgical note of the esophageal banding, and the brief note of death notification. The progress notes for his hospitalization were absent for our review. Therefore, we are certifying the cause and manner of death based on the available medical record, autopsy, and toxicology findings. If there is additional material becomes available, we will review the case and issue our finding if warranted.

The manner of death is natural.

(b)(6)

(b)(6) Medical Examiner

(b)(6)

(b)(6) Medical Examiner

ACLU Detainee DeathII ARMY MEDCOM 719

1

CERTIFICATE OF DEATH (OVERSEAS)
Acte de décès (D'Outre-Mer)

NAME OF DECEASED (Last, First, Middle) / Nom du décédé (Nom et prénoms)	GRADE / Grade	BRANCH OF SERVICE / Arme	SOCIAL SECURITY NUMBER / Numéro de sécurité sociale
BTB Diab, Yahiyr, Diasti		Civilian	(b)(6)
ORGANIZATION / Organisation	NATION (e.g. United States) / Pays	DATE OF BIRTH / Date de naissance	SEX / Sexe: [X] MALE [ ] FEMALE

RACE / Race		MARITAL STATUS / État civil				RELIGION / Culte			
X	CAUCASOID / Caucasique		SINGLE / Célibataire		DIVORCED / Divorcé		PROTESTANT / Protestant		OTHER (Specify) / Autre (Spécifier)
	NEGROID / Négroïde		MARRIED / Marié		SEPARATED / Séparé		CATHOLIC / Catholique	X	
	OTHER (Specify) / Autre (Spécifier)		WIDOWED / Veuf				JEWISH / Juif		

NAME OF NEXT OF KIN / Nom du plus proche parent	RELATIONSHIP TO DECEASED / Parenté du décédé avec le sus
STREET ADDRESS / Domicile à (Rue)	CITY OR TOWN OR STATE (include ZIP Code) / Ville (Code postal complet)

MEDICAL STATEMENT / Déclaration médicale

CAUSE OF DEATH (Enter only one cause per line) / Cause du décès (N'indiquer qu'une cause par ligne)		INTERVAL BETWEEN ONSET AND DEATH / Intervalle entre l'attaque et le décès
DISEASE OR CONDITON DIRECTLY LEADING TO DEATH[1] / Maladie ou condition directement responsable de la mort[1]	Gastrointestinal hemorrhage	
ANTECEDENT CAUSES / Symptômes précurseurs de la mort — MORBID CONDITION, IF ANY, LEADING TO PRIMARY CAUSE / Condition morbide, s'il y a lieu, menant à la cause primaire		
ANTECEDENT CAUSES / Symptômes précurseurs de la mort — UNDERLYING CAUSE, IF ANY, GIVING RISE TO PRIMARY CAUSE / Condition morbide, s'il y a lieu, menant à la cause primaire		
OTHER SIGNIFICANT CONDITIONS[2] / Autres conditions significatives[2]		

MODE OF DEATH / Condition du décès	AUTOPSY PERFORMED / Autopsie effectuée	CIRCUMSTANCES SURROUNDING DEATH DUE TO EXTERNAL CAUSES / Circonstances de la mort suscitées par des causes extérieures
X NATURAL / Mort naturelle	[X] YES / Oui [ ] NO / Non	
ACCIDENT / Mort accidentelle	MAJOR FINDINGS OF AUTOPSY / Conclusions principales de l'autopsie	
SUICIDE / Suicide	NAME OF PATHOLOGIST / Nom du pathologiste: (b)(6)	
HOMICIDE / Homicide	(b)(6) — DATE / Date: 7 December 2007	AVIATION ACCIDENT / Accident à l'avion: [ ] YES / Oui [X] NO / Non

DATE OF DEATH (Day, month, year) / Jour, le mois, l'année	PLACE OF DEATH / Lieu de décès
(b)(6) 2007 (b)(6) (b)(6)	Camp Cropper Iran

I HAVE VIEWED THE REMAINS OF THE DECEASED AND DEATH OCCURRED AT THE TIME INDICATED AND FROM THE CAUSES AS STATED ABOVE.
J'ai examiné les restes mortels du dé [illegible] le conseil que le décès est survenu à l'heure indiquée et à la suite des causes énumérées ci-dessus.

(b)(6)	SIGNED / Time du diplôme: Medical Examiner
GRADE / Grade: MAJ	INSTALLATION OR ADDRESS / Installation ou adresse: Dover AFB, Dover DE
DATE / Date: 12/7/2007	(b)(6)

1 State disease, injury or [illegible]
2 State conditions contributing to the death, but not related to the [illegible]
3 Number in section on [illegible]

DD FORM 1 APR 77 2064 REPLACES DA FORM 3668, 1 JAN 72 AND DA FORM 3668 (PAS), 30 SEP 75, WHICH ARE OBSOLETE.

MEDCOM 0720

(REMOVE, REVERSE AND RE-INSERT CARBONS BEFORE COMPLETING THIS SIDE)

DISPOSITON OF REMAINS

NAME OF MORTICIAN PREPARING REMAINS	GRADE	LICENSE NUMBER AND STATE	OTHER

INSTALLATION OR ADDRESS	DATE	SIGNATURE
(b)(6)		

NAME OF CEMETERY OR CREMATORY	LOCATION OF CEMETERY OR CREMATORY

TYPE OF DISPOSTION	DATE OF DISPOSTION

REGISTRATION OF VITAL STATISTICS

REGISTRY *(Town and County)*	DATE REGISTERED	FILE NUMBER	
		STATE	OTHER

NAME OF FUNERAL DIRECTOR	ADDRESS

SIGNATURE OF AUTHORIZED INDIVIDUAL

DD FORM 2064, APR 1977 (BACK) *USAPA V1.00*

ARMED FORCES INSTITUTE OF PATHOLOGY
Office of the Armed Forces Medical Examiner
1413 Research Blvd., Bldg. 102
Rockville, MD 20850
1-301-319-0000

AUTOPSY EXAMINATION REPORT

Name: BTB Ahmad, Marwan Taha
ISN: (b)(6)
Date of Birth: (b)(6) 1960, as reported
Date of Death: (b)(6) 2007
Date/Time of Autopsy: 28 NOV 2007/1220
Date of Report: 23 JAN 2008

Autopsy No.: (b)(6)
AFIP No.: (b)(6)
Rank: Detainee
Place of Death: Camp Cropper, Iraq
Place of Autopsy: Port Mortuary
Dover AFB, Dover, DE

Circumstances of Death: This approximately 40-50 year old adult detainee, believed to be (BTB) (b)(6) at Camp Cropper in Iraq was noticed to be missing from a mandatory muster. Upon investigation (b)(6) was found without signs of life. Attempts at resuscitation were unsuccessful. Circumstances surrounding the incident are currently under investigation.

Authorization for Autopsy: Armed Forces Medical Examiner, per 10 U.S. Code 1471

Identification: Presumptive identification by accompanying reports, identification tags and documentation. A postmortem dental examination, postmortem fingerprint examination, and a postmortem DNA sample are taken for profile purposes should exemplars become available for positive identification.

CAUSE OF DEATH: Multiple blunt force injuries

MANNER OF DEATH: Homicide

ACLU Detainee DeathII ARMY MEDCOM 722

EXTERNAL EXAMINATION

Injuries will be described in detail in a separate section, and will only be briefly alluded to in the remainder of the report, for purposes of orientation and completeness. The body is that of a well-developed, well-nourished appearing, adult male, whose appearance is consistent with the reported approximate age of 40 to 50-years. The body is received clad in a white tank top style undershirt pulled above the nipples, a yellow button down long sleeved shirt, and a single white sock with an alligator logo on the right foot. The hands are covered with paper bags secured at the wrists. The remains are 72-inches in length, and weigh 204-pounds. Lividity is present and fixed on the posterior surface of the body except in areas exposed to pressure. Marbling is present on the anterior shoulders and upper arms. Rigor is present to an equal degree in all extremities. The temperature of the body is that of the refrigeration unit.

The head is normocephalic, and the scalp is covered with straight black hair with scattered strands of grey, in a male pattern baldness distribution. Facial hair consists of grey-black stubble. The irides are brown. The corneae are hazy. The conjunctivae are congested. The pupils are round and equal in diameter. The sclerae are white and without petechial hemorrhage. The external auditory canals, external nares, and oral cavity are free of foreign material and abnormal secretions. The ears are unremarkable. The nares are patent and the lips are atraumatic. The maxillae are palpably intact. The teeth appear natural and in poor condition. The neck is straight, and the trachea is midline and mobile.

The chest is symmetric. The abdomen is mildly protuberant. The genitalia are those of a normal adult circumcised male. The testes are descended and free of masses. Pubic hair is present in a normal male distribution. The buttocks and anus are unremarkable.

The upper and lower extremities are symmetric and without clubbing or edema. The fingernails are intact, trimmed, and the nailbeds cyanotic.

Identifying marks include a fine 2-inch linear scar on the dorsum of the left hand.

CLOTHING AND PERSONAL EFFECTS

The following clothing items and personal effects are present on the body at the time of autopsy:

- White tank top style undershirt
- Yellow button down long sleeved shirt
- Single white sock with an alligator logo on the right foot

MEDICAL INTERVENTION

Medical intervention consists of a nasal trumpet in the right naris.

ACLU Detainee DeathII ARMY MEDCOM 723

RADIOGRAPHS

A complete set of postmortem radiographs is obtained and demonstrates the following:

- Fractures of the nasal bones
- Multiple rib fractures
- Fracture of the sternum

EVIDENCE OF INJURY

The ordering of the following injuries is for descriptive purposes only, and is not intended to imply order of infliction or relative severity.

There is a ¼ x ¼-inch superficial abrasion of the glabella. A 1-inch subgaleal hemorrhage is identified on the right frontal scalp without underlying skull fracture. Fractures of the nasal bones are palpable. Layerwise dissection of the structures of the anterior neck indicate hemorrhage into the superficial anterior strap muscles (left greater than right) with an intact hyoid bone and intact thyroid cartilage. Incision and dissection of the posterior neck demonstrates no deep paracervical muscular injury and no cervical spine fractures.

There are multiple cutaneous injuries of the torso. There is a faint 1-inch contusion on the anterior right shoulder. Below the right nipple is a horizontally oriented 5 x 2 ½-inch contusion. On the mid-upper chest, extending over the left upper chest is a 6 x 4-inch contusion with a ½ x ¼-inch abrasion at the inferior medial margin. There are multiple contusions on the lower right chest, 1 to 2-inches in greatest dimensions. On the right inferior lateral chest wall is a 6 ½ x 1 ½-inch contusion. On the upper abdomen above the umbilicus is a 5 ½ x 7 ½-inch obliquely oriented (along the 4 to 10 o'clock axis) contusion with a 7 x ¼-inch linear area of sparing along the long axis of the contusion. There is a 7 x 3-inch cluster of contusions on the inferior left lateral chest wall, measuring up to ½-inches in greatest dimensions. Contused abrasions are noted above the right and left iliac crests measuring 4 x 2-inches and 3 x 1-inch, respectively. On the right lower back is a 7 x 2 ½-inch cluster of fine vertically oriented parallel abrasions. Similarly on the left lower back is a 13 x 2 ½-inch cluster of fine vertically oriented parallel abrasions. There are bilateral hemorthoraces (right – 200-milliliters, left – 100-milliliters). Non-quantifiable hemorrhage is noted on the intact anterior pericardial sac. There is a 100-milliliter retroperitoneal hemorrhage. There are multiple rib fractures (right anterior #2-7, left lateral #4-6, left anterior #1-3 and #5). There is a displaced fracture of the sternum located at the 2nd intercostal space. A 2 x 1 ½ x ½-inch laceration of the inferior left lobe of the liver is noted adjacent to an intact gallbladder. Focal hemorrhage is noted on the cortical surface of the right kidney and the mesentery of the small bowel. Layerwise dissection of the back demonstrates focal subcutaneous hemorrhage underlying the injuries described above.

Layerwise dissection of the extremities and buttocks demonstrates no evidence of musculoskeletal injuries.

ACLU Detainee DeathII ARMY MEDCOM 724

INTERNAL EXAMINATION

BODY CAVITIES:
(See above "Evidence of Injury")
The body is opened by the usual thoraco-abdominal incision and the chest plate is removed. The vertebral bodies are visibly and palpably intact. No adhesions are present in the pleural, pericardial, or peritoneal cavities. No abnormal collection of fluid is noted within the pericardial sac. All body organs are present in their normal anatomic positions. There is no internal evidence of penetrating injury to the thoraco-abdominal region.

The subcutaneous fat layer of the abdominal wall is 1 1/2-inches thick.

HEAD AND CENTRAL NERVOUS SYSTEM:
(See above "Evidence of Injury")
The scalp is reflected. There are no skull fractures. The calvarium is intact, as is the dura mater beneath it. There are no epidural or subdural hemorrhages present. The leptomeninges are thin and delicate. Clear cerebrospinal fluid surrounds the 1500-gram brain. The cerebral hemispheres are symmetrical with unremarkable gyri and sulci. The structures at the base of the brain, including cranial nerves and blood vessels, are intact and unremarkable.

Coronal sections demonstrate sharp demarcation between white and grey matter, without hemorrhage or contusive injury. The ventricles are of normal size. The basal ganglia, brainstem, cerebellum, and arterial systems are free of injury or other abnormalities. The atlanto-occipital joint is stable.

NECK:
(See above "Evidence of Injury")
The anterior strap muscles of the neck are homogenous and red-brown with the previously described superficial hemorrhages. The thyroid cartilage and hyoid bone are intact. The larynx is lined by intact white mucosa. The tongue is free of bite marks, hemorrhage, or other injuries.

RESPIRATORY SYSTEM:
The upper airway is clear of debris and foreign material; the mucosal surfaces are smooth, yellow-tan and unremarkable. The pleural surfaces are smooth, glistening and unremarkable bilaterally. The pulmonary parenchyma is salmon pink, diffusely congested and edematous, exuding slight to moderate amounts of blood and frothy fluid. No mass lesions or areas of consolidation are present. The right and left lungs weigh 400 and 390-grams, respectively.

ACLU Detainee DeathII ARMY MEDCOM 725

CARDIOVASCULAR SYSTEM:
(See above "Evidence of Injury")
The pericardial surfaces are smooth, glistening and unremarkable. The 420-gram heart is contained in an intact pericardial sac free of significant fluid or adhesions. The epicardial surface is smooth, with minimal fat investment. The coronary arteries arise normally, follow the usual distribution in a right dominant pattern, are widely patent, and without evidence of thrombosis. Atherosclerotic luminal narrowing of less then 20% involves the left main, left anterior descending, and right coronary arteries. The myocardium is homogenous, red-brown, firm and unremarkable; the atrial and ventricular septae are intact. The walls of the left ventricle, right ventricle, and interventricular septum are 1.5, 0.4, and 1.5-centimeters thick, respectively. The valve leaflets are thin and mobile. The aorta and its major branches arise normally, follow the usual course and have mild focal atherosclerotic streaking. The venae cavae and its major tributaries return to the heart in the usual distribution and are free of thrombi. The renal and mesenteric vessels are unremarkable.

HEPATOBILIARY SYSTEM:
(See above "Evidence of Injury")
The hepatic capsule, where uninjured, is smooth and glistening, covering dark red-brown, moderately congested parenchyma. No mass lesions or other non-traumatic abnormalities are noted. The gallbladder contains 10-milliliters of green-brown mucoid bile; the mucosa is velvety and unremarkable. The extrahepatic biliary tree is patent and without evidence of calculi. The liver weighs 1850-grams.

GASTROINTESTINAL TRACT:
(See above "Evidence of Injury")
The esophagus is intact and lined by smooth, grey-white mucosa. The gastric wall is intact and the lumen of the stomach is empty. The gastric mucosa is arranged in the usual rugal folds. The duodenum, loops of small bowel and colon are unremarkable. The appendix is present.

GENITOURINARY SYSTEM:
(See above "Evidence of Injury")
The right and left kidneys weigh 140 and 80-grams, respectively. The renal capsules are smooth and thin, semi-transparent and strip with ease from the underlying smooth, red-brown cortical surface. The cut surfaces are red-tan and congested, with uniformly thick cortices and sharp corticomedullary junctions. The pelves and calyces are unremarkable. The ureters are normal in course and caliber. White bladder mucosa overlies an intact bladder wall. The bladder contains approximately 30-milliliters of clear yellow urine. The prostate is normal in size, with lobular, yellow-tan parenchyma. The seminal vesicles are unremarkable. The testes are free of mass lesions, contusions, or other abnormalities.

ACLU Detainee DeathII ARMY MEDCOM 726

LYMPHORETICULAR SYSTEM:
The 160-gram spleen has a smooth, intact capsule covering maroon, moderately firm parenchyma; the lymphoid follicles are unremarkable. Lymph nodes in the hilar, periaortic, and iliac regions are not enlarged.

ENDOCRINE SYSTEM:
The pituitary gland is unremarkable. The thyroid is symmetric and red-brown, without cystic or nodular change. The pancreas is firm and yellow-tan, with the usual lobular architecture. No mass lesions or other abnormalities are noted. The right and left adrenal glands are symmetric, with bright yellow cortices and grey medullae. No masses or areas of hemorrhage are identified.

MUSCULOSKELETAL SYSTEM:
Muscle development appears normal. No non-traumatic bone or joint abnormalities are noted.

ADDITIONAL PROCEDURES

1. Documentary photographs are taken by OAFME staff photographers.
2. Specimens retained for toxicology testing and/or DNA identification are: Blood, vitreous fluid, urine, bile, heart, spleen, liver, lung, kidney, brain, adipose tissue, and skeletal muscle
3. Full body radiographs are obtained and demonstrate the above findings.
4. Selected portions of organs are retained in formalin.
5. The dissected organs are forwarded with the body.
6. Personal effects are released to the mortuary affairs representatives.

MICROSCOPIC EXAMINATION

Selected portions of organs are retained in formalin, without preparation of histologic slides.

ACLU Detainee DeathII ARMY MEDCOM 727

FINAL AUTOPSY DIAGNOSES:

I. Multiple blunt force injuries
   A. Blunt force injuries of the head and neck
      1. Superficial abrasion of the face
      2. Subgaleal hemorrhage of the right frontal scalp
      3. Fractures of the nasal bones
      4. No evidence of neck injury or fractures of the calvarium
   B. Blunt force injuries of the torso
      1. Multiple patterned contusions and abrasions of the torso
      2. Multiple fractures of the ribs and sternum with associated hemorrhage into the anterior mediastinum
      3. Bilateral hemothoraces (right – 200-milliliters, left – 100-milliliters)
      4. Retroperitoneal hemorrhage (100-milliliters)
      5. Laceration of the liver
      6. Focal hemorrhage of the right kidney and mesentery of the small bowel

II. Natural disease diagnoses
   A. Atherosclerotic narrowing of the coronary arteries (left main, left anterior descending, and right) of less then 20%
   B. Focal atherosclerotic streaking of the aorta

III. Medical intervention consists of a nasal trumpet in the right naris

IV. Post-mortem changes
   A. Lividity is fixed on the posterior surface of the body except in areas exposed to pressure
   B. Marbling of the skin is present on the right anterior shoulder
   C. Rigor is present to an equal degree in all extremities

V. Toxicology results
   A. Volatiles: The blood and vitreous fluid were examined for the presence of ethanol at a cutoff of 20 mg/dl. No ethanol was detected.
   B. Drugs: The urine was screened for amphetamine, antidepressants, antihistamines, barbiturates, benzodiazepines, cannabinoids, chloroquine, cocaine, dextromethorphan, lidocaine, narcotic analgesics, opiates, phencyclidine, phenothiazines, sympathomimetic amines and verapamil by gas chromatography, color test or immunoassay: none detected.
   C. Carbon Monoxide: The carboxyhemoglobin saturation in the blood was less than 1% as determined by spectrophotometry with a limit of quantitation of 1%. Carboxyhemoglobin saturations of 0-3% are expected for non-smokers and 3-10% for smokers. Saturations above 10% are considered elevated and are confirmed by gas chromatography.
   D. Cyanide: No cyanide was detected in the blood. The limit of quantitation for cyanide is 0.25 mg/L. Normal blood cyanide concentrations are less than 0.15mg/L. Lethal concentrations of cyanide are greater than 3 mg/L.

ACLU Detainee DeathII ARMY MEDCOM 728

OPINION

This 40-50 year old civilian detainee at Camp Cropper Iraq, BTB (b)(6) died as the result of multiple blunt force injuries. Autopsy examination revealed blunt force injuries, predominately of the torso, resulting in a flail chest, liver laceration, and injury to the attachments of the small bowel.

Postmortem analysis of the body fluids was negative for the presence of ethanol, screened medications and screened drugs of abuse. There was no evidence of significant natural disease processes that would have contributed to the cause or manner of death noted at the time of autopsy.

The manner of death is homicide.

(b)(6)

(b)(6) Medical Examiner

ACLU Detainee DeathII ARMY MEDCOM 729

CERTIFICATE OF DEATH (OVERSEAS)
Acte de décès (D'Outre-Mer)

NAME OF DECEASED (Last, First, Middle) Nom du décédé (Nom et prénoms)	GRADE Grade	BRANCH OF SERVICE Arme	SOCIAL SECURITY NUMBER Numéro de l'Assurance Social
BTB Ahmad, Merwan, Taha		Civilian	(b)(6)
ORGANIZATION Organisation	NATION (e.g. United States) Pays	DATE OF BIRTH Date de naissance	SEX Sexe ☐ MALE ☐ FEMALE

RACE Race		MARITAL STATUS État Civil		RELIGION Culte	
X CAUCASOID Caucasique		SINGLE Célibataire	DIVORCED Divorcé	PROTESTANT Protestant	OTHER (Specify) Autre (Spécifier)
NEGROID Négroïde		MARRIED Marié	SEPARATED Séparé	CATHOLIC Catholique	X
OTHER (Specify) Autre (Spécifier)		WIDOWED Veuf		JEWISH Juif	

NAME OF NEXT OF KIN Nom du plus proche parent	RELATIONSHIP TO DECEASED Parenté du décédé avec le lieu
STREET ADDRESS Domicile à (lieu)	CITY OR TOWN OR STATE (include ZIP Code) Ville (Code postal compris)

MEDICAL STATEMENT Déclaration médicale

CAUSE OF DEATH (Enter only one cause per line) Cause du décès (N'indiquer qu'une cause par ligne)		INTERVAL BETWEEN ONSET AND DEATH Intervalle entre l'attaque et le décès
DISEASE OR CONDITON DIRECTLY LEADING TO DEATH[1] Maladie ou condition directement responsable de la mort[1]	Multiple blunt force injuries	Minutes
ANTECEDENT CAUSES Symptômes précurseurs de la mort — MORBID CONDITION, IF ANY, LEADING TO PRIMARY CAUSE Condition morbide, s'il y a lieu, menant à la cause primaire		
ANTECEDENT CAUSES Symptômes précurseurs de la mort — UNDERLYING CAUSE, IF ANY, GIVING RISE TO PRIMARY CAUSE Condition morbide, s'il y a lieu, menant à la cause primaire		
OTHER SIGNIFICANT CONDITIONS[2] Autres conditions significatives[2]		

MODE OF DEATH Condition de décès	AUTOPSY PERFORMED Autopsie effectuée ☒ YES Oui ☐ NO Non	CIRCUMSTANCES SURROUNDING DEATH DUE TO EXTERNAL CAUSES Circonstances de la mort dissociées par des causes extérieures
☐ NATURAL Mort naturelle	MAJOR FINDINGS OF AUTOPSY Conclusions principales de l'autopsie	
☐ ACCIDENT Mort accidentelle		
☐ SUICIDE Suicide	NAME OF PATHOLOGIST Nom du pathologiste (b)(6)	
X HOMICIDE Homicide	(b)(6) DATE Date 28 November 2007	AVIATION ACCIDENT Accident à Avion ☐ YES Oui ☒ NO Non

DATE OF DEATH (day, month, year) Date de décès (Jour, le mois, l'année)	PLACE OF DEATH Lieu de décès
(b)(6) r 2007 (b)((b)(6)	Camp Remembrance Iraq

I HAVE VIEWED THE REMAINS OF THE DECEASED AND DEATH OCCURRED AT THE TIME INDICATED AND FROM THE CAUSES AS STATED ABOVE.
J'ai examiné les restes mortels du dé funtel je constate que le décès est survenu à l'heure indiquée et à la suite des causes énumérées ci-dessus.

NAME OF MEDICAL OFFICER Nom du médecin militaire ou du médecin sanitaire	TITLE OR GRADE Titre ou diplôme
(b)(6)	Medical Examiner
GRADE Grade (b)(6)	INSTALLATION OR ADDRESS Installation ou adresse Dover AFB, Dover DE
DATE Date 11/28/2007	(b)(6)

1 State disease, injury or complication which caused death
2 State conditions contributing to the death, but not related
3 Indicate in words the manner in which the injury occurred, such as in a mortar or a fall
4 Indicate in words the manner in which the injury occurred, such as in a mortar or a fall

DD FORM 1 APR 77 2064 REPLACES DA FORM 3355, 1 JAN 72 AND DA FORM 3355-R(PAS), 26 SEP 72, WHICH ARE OBSOLETE.

(REMOVE, REVERSE AND RE-INSERT CARBONS BEFORE COMPLETING THIS SIDE)

DISPOSITON OF REMAINS

NAME OF MORTICIAN PREPARING REMAINS	GRADE	LICENSE NUMBER AND STATE	OTHER
INSTALLATION OR ADDRESS (b)(6)	DATE	SIGNATURE	
NAME OF CEMETERY OR CREMATORY	LOCATION OF CEMETERY OR CREMATORY		
TYPE OF DISPOSITION	DATE OF DISPOSITION		

REGISTRATION OF VITAL STATISTICS

REGISTRY (Town and County)	DATE REGISTERED	FILE NUMBER	
		STATE	OTHER
NAME OF FUNERAL DIRECTOR	ADDRESS		
SIGNATURE OF AUTHORIZED INDIVIDUAL			

DD FORM 2064, APR 1977 (BACK) *USAPA V1.00*

ACLU Detainee DeathII ARMY MEDCOM 731

ARMED FORCES INSTITUTE OF PATHOLOGY
Office of the Armed Forces Medical Examiner
1413 Research Blvd., Bldg. 102
Rockville, MD 20850
301-319-0000

AUTOPSY EXAMINATION REPORT

Name: Khalaf Al Fahadawi, Layith Husayn
ISN: (b)(6)
Date of Birth: (b)(6) 1980
Date of Death (b)(6) 2007
Date/Time of Autopsy: 17 NOV 2007 @ 1100
Date of Report: 29 NOV 2007

Autopsy No.: (b)(6)
AFIP No.: (b)(6)
Rank: Detainee
Place of Death: Iraq
Place of Autopsy: Port Mortuary, Dover Air Force Base, Dover, DE

Circumstances of Death: Initial reports state that this detainee (b)(6) (b)(6) was brought by fellow detainees to security forces with faint signs of life.

Authorization for Autopsy: Armed Forces Medical Examiner, per 10 U.S. Code 1471

Identification: Accompanying documentation establishes presumptive identification.

CAUSE OF DEATH: **Asphyxia by Smothering**

MANNER OF DEATH: **Homicide**

ACLU Detainee DeathII ARMY MEDCOM 732

EXTERNAL EXAMINATION

The body is that of a well-developed, well-nourished Caucasoid male. The body weighs 144 pounds and measures 67-1/2 inches in length. Lividity is fixed on the posterior surfaces of the body. Rigor is passing. The body temperature is cold to touch. Decomposition changes consist of mild skin slippage on the chest, back, right foot, and left ankle.

Injuries of the head are described below. The scalp is covered with straight brown hair of medium length in a normal distribution. The irides are brown, the corneae are hazy, the conjunctivae are pale, and the sclerae are white. The external auditory canals are clear of debris. The ears are unremarkable. The nares are clear of debris. The nose and maxillae are palpably stable. The teeth are natural and in good condition. The neck is straight, and the trachea is midline and mobile.

Injuries of the torso are described below. The chest is symmetric. The abdomen is flat. The genitalia are those of a normal adult circumcised male. The testes are descended. Pubic hair is present in a normal distribution. The back is symmetric. The anus is unremarkable.

Injuries of the extremities are described below. The upper and lower extremities are symmetric. The fingernails are intact and clipped for evidence. Identifying marks are not present.

CLOTHING AND PERSONAL EFFECTS

No clothing items or personal effects are present on the body at the time of autopsy.

MEDICAL INTERVENTION

Medical intervention present on the body at the time of autopsy includes:

- Defibrillator pads on the right chest and left flank
- Cardiac monitor leads on the anterior torso
- Triple lumen catheter, left subclavian region
- Oral endotracheal intubation
- Intravascular catheter, left ante-cubital fossa

RADIOGRAPHS

A complete set of postmortem radiographs is obtained and demonstrates the following:

- No bony fractures
- No metallic foreign bodies

ACLU Detainee DeathII ARMY MEDCOM 733

EVIDENCE OF INJURY

The ordering of the following injuries is for descriptive purposes only, and is not intended to imply order of infliction or relative severity. All wound pathways are given relative to standard anatomic position.

I. Evidence of asphyxia by smothering

On the right corner of the upper lip is a 1/2" x 1/8" abrasion. A 1" x 1/9" abrasion is on the left corner of the upper lip. Along the lower lip is a 1" x 1/8" abrasion.

II. Blunt force injuries

A. Head and neck

A 1/8" abrasion is on the left side of the forehead and a 1/4" x 1/8" abrasion on the front of the neck.

B. Torso

A 5" x 3-1/4" contusion is on the upper left chest, 11" below the top of the head. A 1/2" x 1/8" abrasion is on the right groin. A 12" x 2" contusion is on the upper back 9" to 11" below the top of the head. A cluster of abrasions, 1/16" to 1-1/4" in greatest dimension, covers an area of 2-1/2" x 2" on the upper central back. A 10-1/2" x 4-1/2" contusion is on the right side of the back, 11" to 22" below the top of the head. On the left side of the back is an 8" x 6" contusion 15" to 20" below the top of the head. A 10" x 5" contusion is on the left buttock, 27-1/2" to 35-1/2" below the top of the head. Incisions into the contusions reveal hemorrhage confined to the underlying subcutaneous tissues; there is no skeletal muscle necrosis.

C. Extremities

A 9" x 5" contusion is on the posterior right arm, 6-1/2" to 13-1/2" below the top of the shoulder. A cluster of contusions, 1/4" to 2-1/2" in greatest dimension, covers an area of 5" x 2-1/2" on the posterior left arm, 6" to 11" below the top of the shoulder. A 1/2" x 1/4" abrasion is on the posterior left wrist and a 1/2" abrasion is on the dorsum of the left hand. A 1/4" contusion (hematoma) is on the palm of the left hand and a 1/2" contusion (hematoma) is on the palmar aspect of the left index finger. A cluster of abrasions, 1/8" to 1/2" in greatest dimension, covers an area of 2" x 1" on the anterior right thigh. Encircling the right thigh and extending up the right buttock is a 22" x 17" contusion, 21" to 37" above the bottom of the heel. A Cluster of abrasions, 1/16" to 1/8" in greatest dimension, covers an area of 1" x 1/4" on the anterior thigh. A 1" x 1/2" abrasion is on the right knee. A cluster of contusions, 1/2" to 8" in greatest dimension, covers an area of 9" x 5" on the anterior right leg, 4-1/2" to 14-1/2" above the bottom of the heel. Two abrasions, 1/2" and 1" in greatest dimension, is on the anterior right leg. A circumferential contusion, 21-1/2" x 11", is on the left thigh, 10" to 29" above the bottom of the heel. A cluster of contusions, 2" to 5-1/2" in greatest dimension, covers an area of 10" x 3" on the anterior left leg, 5" to 14-1/2" above the bottom of the heel. A cluster of abrasions, 1/8" to 1-1/4" in greatest dimension, covers an area of 1-1/2" x 1-1/4" on the anterior left leg. Incisions into the contusions reveal hemorrhage confined to the underlying subcutaneous tissues; there is no skeletal muscle necrosis.

ACLU Detainee DeathII ARMY MEDCOM 734

INTERNAL EXAMINATION

HEAD AND CENTRAL NERVOUS SYSTEM:
The galeal and subgaleal soft tissues of the scalp are free of injury. There are no skull fractures. The dura mater is intact with no evidence of hemorrhage. The leptomeninges are thin and delicate. Clear cerebrospinal fluid surrounds the 1340 gm brain, which has unremarkable gyri and sulci. The cerebral hemispheres are symmetrical and the structures at the base of the brain, including the cranial nerves and blood vessels are intact. Coronal sections demonstrate sharp demarcation between white and gray matter, without hemorrhage or contusive injury. The ventricles are not enlarged. The basal ganglia, brainstem, and cerebellum are free of injury or other abnormalities. The atlanto-occipital joint is stable. The spinal cord is unremarkable.

NECK:
Layer-wise dissection of the neck reveals that the anterior strap muscles are homogenous and red-brown, without hemorrhage. The thyroid cartilage and hyoid are intact. The larynx is lined by intact white mucosa. The thyroid gland is symmetric and red-brown, without cystic or nodular change. The parathyroid glands are not identified. The major vessels of the neck are intact. The tongue is free of bite marks, hemorrhage, or other injuries.

Incision and dissection of the posterior neck demonstrates no deep paracervical muscular injury and no cervical spine fractures.

BODY CAVITIES:
The ribs, sternum, and vertebral bodies are visibly and palpably intact. No excess fluid is in the pleural, pericardial, or peritoneal cavities. The organs occupy their usual anatomic positions.

MUSCULOSKELETAL:

(See Evidence of Injury)

No non-traumatic abnormalities of the muscles or bones of the appendicular and axial skeletons are identified.

RESPIRATORY SYSTEM:
The airways are clear of debris and foreign material and the mucosal surfaces are smooth, yellow-tan, and unremarkable. The right and left lungs weigh 500 and 420 gm, respectively. The external surfaces are smooth and deep red-purple. The pulmonary parenchyma is diffusely congested and edematous. No mass lesions or areas of consolidation are present. The pulmonary arteries are normally developed and patent. The diaphragm is intact.

ACLU Detainee DeathII ARMY MEDCOM 735

CARDIOVASCULAR SYSTEM:
The 360 gm heart is contained in an intact pericardial sac. The epicardial surface is smooth, with minimal fat investment. The coronary arteries are unremarkable in distribution, with a right-dominant pattern. Cross sections of the vessels show no luminal narrowing. The myocardium is homogenous, red-brown, and firm. The valve leaflets are thin and mobile. The walls of the left ventricle, interventricular septum, and right ventricle are 1.4, 1.5. and 0.4-cm thick, respectively. The endocardium is smooth and glistening. The aorta gives rise to three intact and patent arch vessels. The renal, mesenteric, and iliac vessels as well as the venae cavae are unremarkable.

HEPATOBILIARY SYSTEM:
The 1150 gm liver has an intact, smooth capsule and a sharp anterior border. The parenchyma is tan-brown and congested, with unremarkable lobular architecture. No mass lesions or other non-traumatic abnormalities are seen. The gallbladder contains a minute amount of green-black bile and no stones. The mucosal surface is green and velvety.

LYMPHORETICULAR SYSTEM:
The 210 gm spleen has a smooth, intact, red-purple capsule. The parenchyma is maroon and congested, with distinct Malpighian corpuscles. Lymph nodes in the hilar, periaortic, and iliac regions are unremarkable. Residual thymus is present in the anterior mediastinum.

ENDOCRINE SYSTEM:
The pituitary gland is unremarkable. The thyroid gland has been described (see NECK, above). The right and left adrenal glands are symmetric, with bright yellow cortices and red-brown medullae. No masses or areas of hemorrhage are identified.

GENITOURINARY SYSTEM:
The right and left kidneys weigh 90 and 100 gm, respectively. The external surfaces are intact and smooth. The cut surfaces are red-tan and congested, with uniformly thick cortices and sharp corticomedullary junctions. The pelves and ureters are unremarkable. White bladder mucosa overlies an intact bladder wall. The bladder is empty. The prostate has lobular, yellow-tan parenchyma and is not enlarged. The seminal vesicles are unremarkable. The testes are free of mass lesions, contusions, or other abnormalities.

GASTROINTESTINAL TRACT:
The esophagus is intact and lined by smooth, gray-white mucosa. The stomach contains approximately 150 ml of mixed solids and fluids. The gastric wall is intact. The duodenum, distal loops of intestine, and colon are unremarkable. The pancreas is firm and yellow-tan, with lobular architecture. No mass lesions or other abnormalities are seen. The appendix is present.

ACLU Detainee DeathII ARMY MEDCOM 736

ADDITIONAL PROCEDURES

1. Documentary photographs are taken by OAFME staff.
2. Personal effects are released to the appropriate mortuary operations representatives.
3. Specimens retained for toxicology testing and/or DNA identification are blood, vitreous fluid, bile, gastric contents, brain, adipose tissue, lung, heart muscle, spleen, kidney, liver, and psoas muscle.
4. The dissected organs are forwarded with body.
5. Trace evidence and/or foreign material are collected and retained by Army Criminal Investigation Division Special Agent (b)(6)

MICROSCOPIC EXAMINATION

Selected portions of organs are retained in formalin.

Kidney: Mild autolysis and generally intact tubules with unremarkable glomeruli, interstitial, and vasculature

ACLU Detainee DeathII ARMY MEDCOM 737

FINAL AUTOPSY DIAGNOSES:

I. Evidence of asphyxia by smothering
- Multiple (3) abrasions of the lips

II. Blunt force injuries
- A. Head and neck
  - 1. Abrasion, left forehead
  - 2. Abrasions, neck
- B. Torso
  - 1. Contusion, upper left chest
  - 2. Abrasion, right groin
  - 3. Multiple (3) contusions, back
  - 4. Cluster of abrasions, back
  - 5. Contusion, left buttock
- C. Extremities
  - 1. Right upper extremity
    - Contusion, posterior arm
  - 2. Left upper extremity
    - a. Cluster of contusions, posterior arm
    - b. Abrasion, posterior wrist
    - c. Abrasion, dorum of the hand
    - d. Contusion (hematoma), palm
    - e. Contusion, (hematoma), index finger
  - 3. Right lower extremity
    - a. Cluster of abrasions, anterior thigh
    - b. Circumferential contusion, thigh and buttock
    - c. Cluster of abrasions, anterior thigh
    - d. Abrasion, knee
    - e. Cluster of contusions, anterior leg
    - f. Multiple (2) abrasions, anterior leg
  - 4. Left lower extremity
    - a. Circumferential contusion, thigh
    - b. Cluster of contusions, anterior leg
    - c. Cluster of abrasions, anterior leg

III. Natural disease and pre-existing conditions: none identified within the limitations of the examination

IV. Medical intervention
- A. Defibrillator pads on the right chest and left flank
- B. Cardiac monitor leads on the anterior torso
- C. Triple lumen catheter, left subclavian region
- D. Oral endotracheal intubation
- E. Intravascular catheter, left ante-cubital fossa

ACLU Detainee DeathII ARMY MEDCOM 738

V. Post-mortem changes
   A. Mild decomposition
   B. Passing rigor
   C. Fixed posterior livor

VI. Identifying marks: none

VII. Toxicology results
   A. Volatiles (blood and vitreous fluid): no ethanol detected
   B. Screened drugs of abuse and medications (blood):
      1. Positive atropine
      2. No other screened drugs of abuse or medications detected
   C. Carbon monoxide (blood): less than 1%
   D. Cyanide (blood): none detected

ACLU Detainee DeathII ARMY MEDCOM 739

OPINION

This detainee (b)(6) died of asphyxia from smothering. Abrasions around the mouth suggest forceful covering of the airways to prevent adequate respirations. He did sustain multiple blunt force injuries, however, these were not severe enough to cause death. Toxicology tests for ethanol and screened drugs of abuse were negative. The manner of death is homicide.

(b)(6)

(b)(6) Medical Examiner

ACLU Detainee DeathII ARMY MEDCOM 740

CERTIFICATE OF DEATH *(OVERSEAS)*
Acte dé décès (D'Outre-Mer)

NAME OF DECEASED (Last, First, Middle) Nom du décédé (Nom et prénoms)	GRADE Grade	BRANCH OF SERVICE Arme	SOCIAL SECURITY NUMBER Numéro de l'Assurance Social
BTB Khalaf Al Fahadawi, Layith Husayne,		Civilian	(b)(6)

ORGANIZATION Organisation	NATION (e.g. United States) Pays	DATE OF BIRTH Date de naissance	SEX Sexe
Detainee	Iraq	(b)(6) 1980	[X] MALE [ ] FEMALE

RACE Race		MARITAL STATUS État Civil			RELIGION Culte		
[X]	CAUCASOID Caucasique		SINGLE Célibataire		DIVORCED Divorcé		PROTESTANT Protestant
	NEGROID Negriode		MARRIED Marié		SEPARATED Séparé		CATHOLIC Catholique
	OTHER (Specify) Autre (Spécifier)		WIDOWED Veuf				JEWISH Juif

	OTHER (Specify) Autre (Spécifier)
[X]	

NAME OF NEXT OF KIN Nom du plus proche parent	RELATIONSHIP TO DECEASED Parenté du décéde avec le sus
STREET ADDRESS Domicilé à (Rue)	CITY OR TOWN OR STATE (Include ZIP Code) Ville (Code postal compris)

MEDICAL STATEMENT Déclaration médicale

CAUSE OF DEATH (Enter only one cause per line) Cause du décès (N'indiquer qu'une cause par ligne)		INTERVAL BETWEEN ONSET AND DEATH Intervalle entre l'attaque et le décés
DISEASE OR CONDITON DIRECTLY LEADING TO DEATH [1] Malade ou condition directement responsable de la mort [1]	Asphyxia by smothering	
ANTECEDENT CAUSES Symptômes précurseurs de la mort. MORBID CONDITION, IF ANY, LEADING TO PRIMARY CAUSE Condition morbide, s'il y a lieu, menant à la cause primaire		
UNDERLYING CAUSE, IF ANY, GIVING RISE TO PRIMARY CAUSE Condition morbide, s'il y a lieu, menant à la cause primaire		
OTHER SIGNIFICANT CONDITIONS [2] Autres conditions significatives [2]		

MODE OF DEATH Condition de décés	AUTOPSY PERFORMED Autopsie effectuée [X] YES Oui [ ] NO Non	CIRCUMSTANCES SURROUNDING DEATH DUE TO EXTERNAL CAUSES Circonstances de la mort suscitées par des causes extérieures
[ ] NATURAL Mort naturelle	MAJOR FINDINGS OF AUTOPSY Conclusions principales de l'autopsie	
[ ] ACCIDENT Mort accidentelle		
[ ] SUICIDE Suicide	NAME OF PATHOLOGIST Nom du pathologiste (b)(6)	
[X] HOMICIDE Homicide	SIGNATURE (b)(6) DATE Date 17 November 2007	AVIATION ACCIDENT Accident à Avion [ ] YES Oui [X] NO Non

DATE OF DEATH (day, month, year) Date de décés (le jour, le mois, l'année)	PLACE OF DEATH Lieu de décés
(b)(6) 2007 (b)(6)	31st Combat Support Hospital Iraq

I HAVE VIEWED THE REMAINS OF THE DECEASED AND DEATH OCCURRED AT THE TIME INDICATED AND FROM THE CAUSES AS STATED ABOVE
J'ai examiné les restes mortels du dé funtet je conclus que le décés est survenu à l'heure indiquée et à, la suite des causes énumérées ci-dessus.

NAME OF MEDICAL OFFICER Nom du médicin militaire ou du médicin sanitaire	TITLE OR DEGREE Titre ou diplômé
(b)(6)	Medical Examiner

GRADE Grade	INSTALLATION OR ADDRESS Installation ou adresse
(b)(6)	Dover AFB, Dover DE
DATE Date 11/29/2007	SIGNATURE (b)(6)

[1] State disease, injury or complication which caused death, but not mode of dying such as hea
[2] State conditions contributing to the death, but not related to the disease or condition causing
[1] Préciser la nature de la maladie, de la blessure ou de la complication qui a contribué à la mort, mais non la manière de mourir, telle qu 'un arrêt du coeur, etc
[2] Préciser la condition qui a contribué à la mort, mais n'ayant aucun rapport avec la maladie ou à la condition qui a provoqué la mort.

DD FORM 1 APR 77 2064 REPLACES DA FORM 3565, 1 JAN 72 AND DA FORM 3565-R(PAS), 26 SEP 75, WHICH ARE OBSOLETE.

MEDCOM 0741

(REMOVE, REVERSE AND RE-INSERT CARBONS BEFORE COMPLETING THIS SIDE)

DISPOSITON OF REMAINS

NAME OF MORTICIAN PREPARING REMAINS	GRADE	LICENSE NUMBER AND STATE	OTHER

INSTALLATION OR ADDRESS	DATE	SIGNATURE
(b)(6)		

NAME OF CEMETERY OR CREMATORY	LOCATION OF CEMETERY OR CREMATORY

TYPE OF DISPOSTION	DATE OF DISPOSTION

REGISTRATION OF VITAL STATISTICS

REGISTRY *(Town and Country)*	DATE REGISTERED	FILE NUMBER	
		STATE	OTHER

NAME OF FUNERAL DIRECTOR	ADDRESS

SIGNATURE OF AUTHORIZED INDIVIDUAL

DD FORM 2064, APR 1977 (BACK) *USAPA V1.00*

ACLU Detainee DeathII ARMY MEDCOM 742

ARMED FORCES INSTITUTE OF PATHOLOGY
Office of the Armed Forces Medical Examiner
1413 Research Blvd., Bldg. 102
Rockville, MD 20850
301-319-0000

AUTOPSY EXAMINATION REPORT

Name: Habib Al-Sarray, Salim Abo Alla
(b)(6)
Date of Birth: (b)(6) 1968
Date of Death (b)(6) 2007
Date/Time of Autopsy: 14 NOV 2007 @ 1230 hrs
Place of Autopsy: Port Mortuary, Dover AFB, Dover, DE
Date of Report: 12 February 2008

Autopsy No. (b)(6)
AFIP No.: (b)(6)
Rank: Civilian/Detainee
Place of Death: Iraq

Circumstances of Death: This 38-year-old Operation Iraqi Freedom detainee, as reported, complained of malaise and was found to have a low blood pressure and high heart rate. He was transported to the ICU where he went into shock and was treated with life saving measures which were unsuccessful. He was pronounced dead on (b)(6) 2007.

Authorization for Autopsy: Armed Forces Medical Examiner, per U.S. Code 10, Section 1471

Identification: Presumptive identification per CID investigation.

CAUSE OF DEATH: **ATHEROSCLEROTIC CARDIOVASCULAR DISEASE**

MANNER OF DEATH: **NATURAL**

ACLU Detainee DeathII ARMY MEDCOM 743

EXTERNAL EXAMINATION

The body is that of a well-developed, well-nourished male. The body weighs 246 pounds, is 70 inches in length and appears compatible with the reported age of 38 years. The body is cold. Rigor is present to an equal degree in all extremities. Lividity is present and fixed on the posterior surface of the body, except in areas exposed to pressure.

The head is normocephalic, and the scalp hair is black and gray. A well healed scar is on the lateral surface of the right forehead. The Facial hair consists of a black beard. The irides are brown. The corneae are cloudy. The vessels of the right conjunctiva and sclera are engorged, but the left is unremarkable. The external auditory canals, external nares and oral cavity are free of foreign material and abnormal secretions. The nasal skeleton and maxilla are palpably intact. The teeth are natural and in good condition. The upper and lower frenuluae are unremarkable. Examination of the neck reveals no evidence of injury.

The abdomen is protuberant. The external genitalia are those of a normal adult circumcised male. There is a 4 inch well healed scar on the left lower abdominal quadrant. On the lateral surface of the right buttock are four superficial circular healed ulcers measuring up to ¾ inches in maximum dimension. There is a ½ x ¼ x 1/8 inch anal skin tag on the twelve o'clock surface of the anus.

The extremities show no evidence of fractures, lacerations or deformities. The fingernails are intact. There are (b)(6) tattoos (b)(6)

CLOTHING AND PERSONAL EFFECTS

None identified.

MEDICAL INTERVENTION

- Endo-tracheal tube present in the mouth, resulting in a left upper lip contused laceration (measuring ½ x ¼ inches) and a contusion of the left inner lower lip (measuring 2 x 0.5 centimeters)
- Left subclavian IV-line
- Left and right antecubital fossa IV-lines with surrounding contusions measuring up to 3 inches in maximum dimension.
- Foley catheter
- Dorsal surface IV-line on the left hand with surrounding contusion measuring up to 2 inches in maximum dimension.
- There is a linear array of the minute puncture marks, about 25, located on the right upper chest below the right clavicle measuring 4 x 1 inches in area.
- Cardio-Pulmonary Resuscitation (CPR) related injuries:
  - Right anterior 2nd-5th
  - Left anterior 3rd-6th
  - There is a 5 x 5 inch contusion on the sternal surface of the chest.

ACLU Detainee DeathII ARMY MEDCOM 744

RADIOGRAPHS

A complete set of postmortem radiographs is obtained and demonstrates the following changes listed below.

EVIDENCE OF INJURY

The ordering of the following injuries is for descriptive purposes only, and is not intended to imply order of infliction or relative severity. All wound pathways are given relative to standard anatomic position.

There is a 1 x 1 inch contusion near the right elbow.

There is a dry, bloodless anal laceration measuring ¼ x ¼ of an inch at the six o'clock position located ¼ of an inch from the anal verge.

There is an area of soft tissue hemorrhage measuring 3.5 centimeters in maximum dimension located along the dorsal surface of the right wrist.

INTERNAL EXAMINATION

BODY CAVITIES:

There is 50 milliliters of serosanguineous fluid in the pericardial sac. All body organs are present in normal anatomical position. There are two subcutaneous lipomas near the umbilicus and at the upper (midline region) abdominal quadrant measuring 5 x 5 x 2 centimeters and 7 x 4 x 3 centimeters, respectively.

Remote rib fractures are identified along the right lateral (1st -4th and 6th) right posterior (4th and 6th) ribs. Remote rib fractures are identified along the left lateral (3rd, 4th, and 9th) ribs.

The subcutaneous fat layer of the abdominal wall is 2 ½ inches thick.

HEAD AND NECK:

The galena and subarea soft tissues of the scalp are free of injury. There are no skull fractures. The dura mater and falx cerebri are intact. There is no epidural or subdural hemorrhage present. The leptomeninges are thin and delicate. The cerebral hemispheres are symmetrical. The structures at the base of the brain, including cranial nerves and blood vessels are intact.

The brain weighs 1350 grams and has unremarkable gyri and sulci. Coronal sections through the cerebral hemispheres reveal no lesions. Transverse sections through the brain stem and cerebellum are unremarkable. The atlanto-occipital joint is stable.

ACLU Detainee DeathII ARMY MEDCOM 745

The anterior strap muscles of the neck are homogenous and red-brown, without hemorrhage by layer-wise dissection. The thyroid cartilage and hyoid bone are intact. The larynx is lined by intact tan mucosa. The tongue is free of bite marks, hemorrhage, or other injuries. Incision and dissection of the posterior neck demonstrates no deep paracervical muscular injury and no cervical spine fractures.

CARDIOVASCULAR SYSTEM:

The heart weighs 460 grams and is contained in an intact pericardial sac. The epicardial surface is smooth, with minimal fat investment.

The coronary arteries are present in a normal distribution, with a left-dominant pattern. Cross sections of the heart show the right coronary artery with severe, greater than 75% luminal stenosis measuring 5 centimeters from the right coronary artery orifice; the diagonal branch of the left coronary artery with severe, greater than 75% luminal stenosis near the bifurcation with the left coronary artery; and left main/anterior descending artery with moderate, greater than 50% luminal stenosis measuring 4 centimeters from the opening of the left coronary artery. The myocardium is homogenous, red-brown, and firm. The valve leaflets are thin and mobile. The walls of the left ventricle, interventricular septum, and right ventricle are 1.5, 1.7, and 0.3 centimeter thick, respectively. The endocardium is smooth and glistening.

The aorta gives rise to three intact and patent arch vessels. The renal and mesenteric vessels are unremarkable.

RESPIRATORY SYSTEM:

The upper airway is clear of debris and foreign material: the mucosal surfaces are smooth, yellow-tan and unremarkable. The pleural surfaces are smooth, glistening and unremarkable bilaterally.

The pulmonary parenchyma is diffusely congested and edematous, exuding large amounts of blood and frothy fluid; no focal lesions are noted.

The pulmonary arteries are normally developed, patent and without thrombus or embolus. The right lung weighs 1080 grams; the left 1030 grams.

HEPATOBILIARY SYSTEM:

The 2700 gram liver has an intact smooth capsule covering a yellow and fatty parenchyma with no focal lesions noted.

The gallbladder contains 10 milliliters of green-brown, mucoid bile; the mucosa is velvety and unremarkable. The extrahepatic biliary tree is patent, without evidence of calculi.

ACLU Detainee DeathII ARMY MEDCOM 746

GASTROINTESTINAL SYSTEM:

The esophagus is lined by gray-white, smooth mucosa. The gastric mucosa is arranged in the usual rugal folds and the lumen contains 350 milliliters of serosanguineous fluid.

The small and large bowels are unremarkable. The pancreas has a normal pink-tan lobulated appearance and the ducts are clear. The appendix is absent.

GENITOURINARY SYSTEM:

The right kidney weighs 180 grams; the left 200 grams. The renal capsules are smooth and thin, semi-transparent and strip with ease from the underlying smooth, red-brown cortical surface.

The cortices are sharply delineated from the medullary pyramids, which are red-purple to tan and unremarkable. The calyces, pelves and ureters are unremarkable.

Tan bladder mucosa overlies an intact bladder wall. The bladder contains approximately 15 milliliters of yellow urine. The testes, prostate gland and seminal vesicles are unremarkable. A 0.3 x 0.3 x 0.3 centimeter yellow calcified nodule is present in the urethra of the prostate gland.

LYMPHORETICULAR SYSTEM:

The 210 gram spleen has a smooth, intact capsule covering red-purple, moderately firm parenchyma; the lymphoid follicles are unremarkable.

There is an enlarged lymph node of the neck (cervical) measuring 1.4 centimeters in maximum dimension. Lymph nodes in the hilar, periaortic and iliac regions are not enlarged.

ENDOCRINE SYSTEM:

The pituitary gland is left *in situ* and is unremarkable. The thyroid gland is symmetric and red-brown, without cystic or nodular change. The right and left adrenal glands are symmetric, with bright yellow cortices and red-brown medullae. No masses or areas of hemorrhage are identified.

MUSCULOSKELETAL SYSTEM:

A healed 4th metatarsal fracture of the right foot is identified radiologically. No non-traumatic abnormalities of muscle or bone are identified.

ACLU Detainee DeathII ARMY MEDCOM 747

MICROSCOPIC EXAMINATION

Selected portions of organs are retained in formalin with preparation of histology slides listed below.

Sections of the right coronary artery (slide 1) display severe stenosis due to atherosclerotic plaque composed of fibrin, cholesterol clefts, calcification, and a mixed inflammatory cell infiltrate.

Sections of the diagonal branch of the left coronary artery (slide 2) display only an edge of the vessel attached with fibro-adipose tissue. No pathological diagnosis identified.

Sections of the left anterior descending coronary artery (slide 3) display a tangential cross section of stenosis due to atherosclerotic plaque composed of fibrin, cholesterol clefts, calcification, and a mixed inflammatory cell infiltrate

Sections of the umbilical and abdominal masses (slides 4 and 5, respectively) display unremarkable adipocytes surrounded by congested blood vessels and a benign fibrous capsule.

Section of the bisected cervical lymph node (slide 6) displays unremarkable tissue.

Sections of the left and right lungs (slides 7 and 8, respectively) display congested blood vessels with benign alveolar and hemosiderin-laden (heart failure cells) macrophages. No frank acute or chronic inflammation, necrosis, granulomas, viral cytopathic effect, emboli, or malignancy identified.

Sections of the liver (slide 9) display severe mixed macrosteatosis and microsteatosis with chronic inflammatory cells and bile duct proliferation at the portal traids. There is no evidence of regenerated nodules, discrete masses, granulomas, cytopathic effect, or frank inflammation identified.

ADDITIONAL PROCEDURES

1. Documentary photographs are taken by OAFME.
2. Personal effects are released to the appropriate mortuary operations representatives.
3. Specimens retained for toxicology testing and/or DNA identification are: vitreous fluid, blood, urine, bile, gastric contents, spleen, liver, lung, kidney, brain, myocardium, adipose tissue and skeletal muscle.
4. The dissected organs are forwarded with body.

ACLU Detainee DeathII ARMY MEDCOM 748

FINAL AUTOPSY DIAGNOSES

I. **Atherosclerotic cardiovascular disease:**
- A. Right coronary artery, severe, greater than 75% luminal stenosis
- B. Diagonal branch of the left coronary artery, severe, greater than 75% luminal stenosis near the bifurcation with the left coronary artery
- C. Left anterior descending coronary artery, moderate, greater than 50% luminal stenosis
- D. Pericardial effusion, 50 milliliters of serosangious fluid
- E. Pulmonary congestion, right lung 1080 grams, left lung 1030 grams

II. **Additional findings/preexisting injuries:**
- A. Contusion of the right elbow
- B. Postmortem laceration of the anus
- C. Soft tissue hemorrhage of the right wrist.
- D. Subcutaneous lipomas of the umbilicus and at the midline of the upper abdominal quadrant
- E. Multiple superficial circular healed ulcers of the lateral surface of the right buttock
- F. Remote/healed rib fractures, bilateral
- G. A healed 4th metatarsal fracture of the right foot
- H. Fatty liver change, severe
- I. Calcified nodule in prostate
- J. Benign cervical lymphadenopathy
- K. Status/post appendectomy

III. **Evidence of Medical Therapy:** Described above

IV. **Identifying Body Marks**
- A. Multiple tattoos (b)(6)
- B. Well healed scar of the left lower abdominal quadrant and right forehead

V. **Toxicology (AFIP)**
- A. VOLATILES: No ethanol detected in the blood and vitreous fluid
- B. DRUGS: No screened drugs of abuse/medications detected in the urine

ACLU Detainee DeathII ARMY MEDCOM 749

OPINION

This 38-year-old Operation Iraqi Freedom detainee died from atherosclerotic cardiovascular disease with moderate to severe narrowing (luminal stenosis of the left anterior descending, diagonal branch of the left coronary artery, and right coronary artery) of the coronary vessels and resulting in the back up of blood in the pulmonary vessels (pulmonary congestion). Additional findings at autopsy include abdominal lipomas, fatty liver change and superficial ulcers of the right buttock. The cut (laceration) and bruise (contusion) of the lips are likely due to intubation. Bruises of the chest and anterior ribs fractures were likely produced by CPR-related chest compressions. Bruises of the upper extremities are likely due to IV-line insertions to help treat the decedent's cardio-pulmonary collapse. The minute puncture marks located on the right upper chest were likely produced by multiple syringe injections of cardiac medication(s) during his emergency medical intervention. There were several healed rib fracture identified on both sides of the rib cage and right foot, the significance of these remote injuries is uncertain. Soft tissue hemorrhage to the right wrist may be due to the vigorous intervention by the emergency response team to acutely treat the detainee while he was hand cuffed. The manner of death is natural.

(b)(6)

(b)(6) Medical Examiner

(b)(6)

(b)(6) Medical Examiner

ACLU Detainee DeathII ARMY MEDCOM 750

CERTIFICATE OF DEATH (OVERSEAS)
Acte de décès (D'Outre-Mer)

NAME OF DECEASED (Last, First, Middle) Nom du décédé (Nom et prénoms)	GRADE Grade	BRANCH OF SERVICE Arme	SOCIAL SECURITY NUMBER Numéro de l'Assurance Sociale
BTB Habib Al-Sarray, Salim Abo, Alla		Civilian	(b)(6)
ORGANIZATION Organisation: CID 789236746H9B	NATION (e.g. United States) Pays: Iraq	DATE OF BIRTH Date de naissance: (b)(6) 1968	SEX Sexe: [X] MALE [ ] FEMALE

RACE Race		MARITAL STATUS État civil				RELIGION Culte			
X	CAUCASOID Caucasique		SINGLE Célibataire		DIVORCED Divorcé		PROTESTANT Protestant		OTHER (Specify) Autre (Spécifier)
	NEGROID Negroïde		MARRIED Marié		SEPARATED Séparé		CATHOLIC Catholique	X	
	OTHER (Specify) Autre (Spécifier)		WIDOWED Veuf				JEWISH Juif		

NAME OF NEXT OF KIN Nom du plus proche parent	RELATIONSHIP TO DECEASED Parenté du décédé avec le sus
STREET ADDRESS Domicile à (Rue)	CITY OR TOWN OR STATE (Include ZIP Code) Ville (Code postal compris)

MEDICAL STATEMENT Déclaration médicale

CAUSE OF DEATH (Enter only one cause per line) Cause du décès (N'indiquer qu'une cause par ligne)		INTERVAL BETWEEN ONSET AND DEATH Intervalle entre l'attaque et le décès
DISEASE OR CONDITON DIRECTLY LEADING TO DEATH[1] Maladie ou condition directement responsable de la mort.	Pending	
ANTECEDENT CAUSES Symptômes présumables de la mort. — MORBID CONDITION, IF ANY, LEADING TO PRIMARY CAUSE Condition morbide, s'il y a lieu, menant à la cause primaire		
ANTECEDENT CAUSES Symptômes présumables de la mort. — UNDERLYING CAUSE, IF ANY, GIVING RISE TO PRIMARY CAUSE Condition morbide, s'il y a lieu, menant à la cause primaire		
OTHER SIGNIFICANT CONDITIONS[2] Autres conditions significatives[2]		

MODE OF DEATH Condition de décès	AUTOPSY PERFORMED Autopsie effectuée [X] YES Oui [ ] NO Non	CIRCUMSTANCES SURROUNDING DEATH DUE TO EXTERNAL CAUSES Circonstances de la mort suscitées par des causes extérieures
NATURAL Mort naturelle	MAJOR FINDINGS OF AUTOPSY Conclusions principales de l'autopsie	Mode of Death: Pending
ACCIDENT Mort accidentelle		
SUICIDE Suicide	NAME OF PATHOLOGIST Nom du pathologiste: (b)(6)	
HOMICIDE Homicide	SIGNATURE: (b)(6) — DATE Date: 14 November 2007	AVIATION ACCIDENT Accident à Avion [ ] YES Oui [X] NO Non

DATE OF DEATH (Mon, month, year) Date de décès (Jour, le mois, l'année)	PLACE OF DEATH Lieu de décès
(b)(6) 2007	Camp Cropper Iraq

I HAVE VIEWED THE REMAINS OF THE DECEASED AND DEATH OCCURRED AT THE TIME INDICATED AND FROM THE CAUSES AS STATED ABOVE.
J'ai examiné les restes mortels du gé fumé je conclus que le décès est survenu à l'heure indiquée et à la suite des causes énumérées ci-dessus.

NAME OF MEDICAL OFFICER Nom du médecin officiel ou du médecin spécialiste	TITLE OR USURES Titre ou spécialité
(b)(6)	Medical Examiner
GRADE Grade: (b)(6)	INSTALLATION OR ADDRESS Installation ou adresse: Dover AFB, Dover DE
DATE Date: 11/14/2007	SIGNATURE: (b)(6)

1 State disease, injury or complication which caused death, but not the mode of dying.
2 State conditions contributing to the cause, but not related to the disease or condition causing death.
3 Provisions in accord with the instructions on the reverse of the form, and in addition to the instructions on the reverse of the form.
4 Provisions in accordance with the instructions on the reverse of the form.

DD FORM 1 APR 77 2064 REPLACES DA FORM 2064, 1 JAN 72 AND DA FORM 2064-R(PAS), 25 SEP 72, WHICH ARE OBSOLETE.

ARMED FORCES INSTITUTE OF PATHOLOGY
Office of the Armed Forces Medical Examiner
1413 Research Blvd., Bldg. 102
Rockville, MD 20850
301-319-0000

AUTOPSY EXAMINATION REPORT

Name: BTB Hasan, Al Jabbar N
ISN: (b)(6)
Date of Birth: BTB (b)(6) 1957 (49 years)
Date of Death: (b)(6) 2007
Date/Time of Autopsy: 14 NOV 2007@1300
Date of Report: 14 DEC 2007

Autopsy No. (b)(6)
AFIP No.: (b)(6)
Rank: Civilian/Detainee
Place of Death: Iraq
Place of Autopsy: Port Mortuary
Dover AFB, Dover, DE

Circumstances of Death: This 49-year-old Iraqi male detainee reportedly died in a medical treatment facility (31st CSH). At the time of his death, he was being treated for end-stage heart failure.

Authorization for Autopsy: Armed Forces Medical Examiner, per 10 U.S. Code 1471

Identification: Presumptive identification is established by the examination of the accompanying paper work and identification bracelet. Fingerprints, postmortem dental charting, and a specimen suitable for DNA are obtained.

CAUSE OF DEATH: Acute myocardial infraction complicated by left ventricular mural thrombus

MANNER OF DEATH: Natural

EXTERNAL EXAMINATION

The body is that of an unclad edematous male. The body weighs 214 pounds, is 63 inches in length and appears compatible with the reported age of 49 years. The body is cold. Rigor has passed. Lividity is present and fixed on the posterior surface of the body, except in areas exposed to pressure. The congested head is normocephalic, and the scalp hair is gray and black. Facial hair consists of a gray and black mustache and beard. The irides are brown. The corneae are cloudy. The conjunctivae are congested. The sclerae are white. The external auditory canals are free of foreign material and abnormal secretions. Purged fluid is identified in the mouth and nose. The nasal skeleton and maxilla are palpably intact. The lips are without evident injury. The teeth are natural. Examination of the neck reveals no evidence of injury. The chest is unremarkable. No evidence of injury of the ribs or the sternum is evident externally. The abdomen is slightly protuberant. The external genitalia are those of a normal adult circumcised male. The scrotum is edematous. The posterior torso and anus are without note. The extremities exhibit peripheral edema. The fingernails are intact. Ecchymoses are identified on the left arm and forearm, and abdomen. A 1/2 inch scar is identified on both knees. A 1 x 1 inch scar is seen on the left forearm. Skin slippage is seen on the left upper extremity. A 1/4 inch flesh colored papule is identified on the right shoulder.

CLOTHING AND PERSONAL EFFECTS

- Green hospital shirt
- A blue chuck is present in the body transverse bag

MEDICAL INTERVENTION

- The hair on the chest is shaved
- Needle puncture marks are identified on both antecubital fossa and the left forearm
- Black ink (most likely identifying peripheral pulses) is on the left ankle and right foot
- Three EKG lead impression marks are on the anterior torso

RADIOGRAPHS

A complete set of postmortem radiographs is obtained. No blunt force or penetrating injuries are identified. No radio-opaque foreign bodies are seen.

EVIDENCE OF INJURY

There is no significant physical injury identified at autopsy.

ACLU Detainee DeathII ARMY MEDCOM 753

INTERNAL EXAMINATION

BODY CAVITIES:

The body is opened by the usual thoraco-abdominal incision and the chest plate is removed. The ribs, sternum, and vertebral bodies are visibly and palpably intact. No adhesions are present in any of the body cavities. Serous fluid is identified in the left chest cavity (250 ml), right chest cavity (250 ml), and the abdomen (500 ml). All body organs are present in normal anatomical position. The subcutaneous fat layer of the abdominal wall is 1 inch thick.

HEAD AND CENTRAL NERVOUS SYSTEM:

The scalp is reflected. The galeal and subgaleal soft tissues of the scalp are free of injury. There are no skull fractures. The calvarium of the skull is removed. The dura mater and falx cerebri are intact. There is no epidural or subdural hemorrhage present. The leptomeninges are thin and delicate. The cerebral hemispheres are symmetrical. The structures at the base of the brain, including cranial nerves and blood vessels are intact. Clear cerebrospinal fluid surrounds the 1440 gram brain, which has unremarkable gyri and sulci. Coronal sections through the cerebral hemispheres reveal no lesions. Transverse sections through the brain stem and cerebellum are unremarkable. The atlanto-occipital joint is stable. The spinal cord is unremarkable.

NECK:

The anterior strap muscles of the neck are homogenous and red-brown, without hemorrhage by layer-wise dissection. The thyroid cartilage and hyoid bone are intact. The larynx is lined by intact white mucosa. The tongue is free of bite marks, hemorrhage, or other injuries. Incision and dissection of the posterior neck demonstrates no deep paracervical muscular injury and no cervical spine fractures.

ACLU Detainee DeathII ARMY MEDCOM 754

CARDIOVASCULAR SYSTEM:

The 550 gram heart is contained in an intact pericardial sac. The epicardial surface is smooth, with minimal fat investment. The coronary arteries are present in a normal distribution, with a right-dominant pattern. Cross sections of the vessels show 80% stenosis of the left anterior descending coronary artery by calcified atherosclerotic plaque with an adherent fresh occlusive thrombus, 75% stenosis of the right coronary artery by calcified atherosclerotic plaque, and 50% stenosis of the left circumflex coronary artery by calcified atherosclerotic plaque. Cross sections through the heart reveal a fibrous scar extending from the anterior wall of the left ventricle and the inter-ventricular septum that is 3-1/2 inches in greatest dimension. The left ventricular free wall and inter-ventricular septum are thinned. There is a 1/2 x 1/2 x 1/4 inch hyperemic area of myocardium with a central area of yellow-tan necrosis in the posterior aspect of the intraventricular septum. A mural thrombus is identified in the apex of the chamber of the left ventricle. The valve leaflets are thin and mobile. The walls of the left ventricle, interventricular septum, and right ventricle are 0.9, 0.5, and 0.3-cm thick, respectively. The left ventricle and right ventricle are dilated. The aorta gives rise to three intact and patent arch vessels. Calcifications are seen at the aortic bifurcation. The renal and mesenteric vessels are unremarkable.

RESPIRATORY SYSTEM:

The upper airway is clear of debris and foreign material; the mucosal surfaces are smooth, yellow-tan and unremarkable. The pleural surfaces are smooth, glistening and unremarkable bilaterally. The pulmonary parenchyma is diffusely congested and edematous, exuding slight to moderate amounts of blood and frothy fluid; no focal lesions are noted. The pulmonary arteries are normally developed, patent and without thrombus or embolus. The right lung weighs 650 grams; the left 550 grams.

HEPATOBILIARY SYSTEM:

The 1720 gram liver has an intact smooth capsule covering congested parenchyma. No non-traumatic focal lesions are noted. The cut surface has a nutmeg appearance. The gallbladder contains 5 ml of green-brown, mucoid bile; the mucosa is velvety and unremarkable. The extrahepatic biliary tree is patent, without evidence of calculi.

GASTROINTESTINAL SYSTEM:

The esophagus is lined by gray-white, smooth mucosa. The gastric mucosa is arranged in the usual rugal folds and the lumen contains 10 ml of brown fluid. The small and large bowels are unremarkable. The pancreas has a normal pink-tan lobulated appearance and the ducts are clear. The appendix is present.

ACLU Detainee DeathII ARMY MEDCOM 755

GENITOURINARY SYSTEM:

The right kidney weighs 180 grams; the left 180 grams. The renal capsules are smooth and thin, semi-transparent and strip with ease from the underlying granular, red-brown cortical surface. The cortex is sharply delineated from the medullary pyramids, which are red-purple to tan and unremarkable. The calyces, pelves and ureters are unremarkable. White bladder mucosa overlies an intact bladder wall. The bladder is empty. Punctate hemorrhages are seen on the bladder mucosa. The testes, prostate gland and seminal vesicles are without note.

LYMPHORETICULAR SYSTEM:

The 200 gram spleen has a smooth, intact capsule covering red-purple, moderately firm parenchyma; the lymphoid follicles are unremarkable. Lymph nodes in the hilar, periaortic and iliac regions are not enlarged.

ENDOCRINE SYSTEM:

The thyroid gland is symmetric and red-brown, without cystic or nodular change. The right and left adrenal glands are symmetric, with bright yellow cortices and red-brown medullae. No masses or areas of hemorrhage are identified.

MUSCULOSKELETAL SYSTEM:

No non-traumatic abnormalities of muscle or bone are identified.

ADDITIONAL PROCEDURES

1. Documentary photographs are taken by OAFME staff photographers.
2. Personal effects are released to the appropriate mortuary operations representatives.
3. Specimens retained for toxicology testing and/or DNA identification are: vitreous fluid, blood, spleen, liver, lung, kidney, brain, myocardium, bile, gastric contents, adipose tissue and psoas muscle.
4. The dissected organs are forwarded with body.
5. Posterior cut-downs are performed. No traumatic injuries are seen.

MICROSCOPIC EXAMINATION

Left Ventricle (Slide - 3) and Inter-Ventricular Septum (Slide - 4) - Areas show coagulation necrosis with loss of myocyte nuclei and striations with an acute inflammatory infiltrate. Other areas show disintegration of myocytes with phagocytosis and a chronic inflammatory infiltrate. Prominent granulation tissue is present. There are also areas that show early scar formation and replacement by collagen.

ACLU Detainee DeathII ARMY MEDCOM 756

Left Anterior Descending Coronary Artery (Slide - 2) - There is 80% stenosis of the lumen by calcified atherosclerotic plaque with evidence of plaque rupture and overlying adherent thrombus.
Right Coronary Artery (Slide - 1) – There is a calcified atherosclerotic plaque.

FINAL AUTOPSY DIAGNOSES:

I. Cardiovascular System:
- **A. Acute myocardial infarction with mural thrombus at the left ventricle**
- **B. Fibrous scar of the left anterior wall of the left ventricle and the inter-ventricular septum that is 3-1/2 inches in greatest dimension**
- **C. Significant Coronary Artery Atherosclerosis:**
  1. **80% stenosis of the left anterior descending coronary artery with a calcified atherosclerotic plaque and an occlusive thrombus**
  2. **75% stenosis of the right coronary artery by calcified atherosclerotic plaque**
  3. **50% stenosis of the left circumflex coronary artery by calcified atherosclerotic plaque**
- **D. Cardiomegaly (heart weight 550 grams)**
- **E. Dilated left and right ventricles**
- **F. Mild atherosclerosis of the aorta**

II. Anasarca

III. Respiratory System: Pulmonary congestion and edema; lung weight: (right lung 650 grams, left lung 550 grams)

IV. Hepatobiliary System: Severe congestion (liver weight 1720 grams) and gross appearance consistent with centrolobular necrosis

V. Genitourinary System:
- **A. Gross appearance consistent with arteriolosclerosis**
- **B. Punctate hemorrhages of the bladder mucosa**

VI. Toxicology (AFIP):
- **A. VOLATILES: No ethanol is detected in the blood and vitreous fluid; acetone is detected in the blood (10 mg/dl) and vitreous fluid (12 mg/dl)**
- **B. DRUGS: No screened drugs of abuse or medications are detected in the blood**
- **C. CARBON MONOXIDE: The carboxyhemoglobin saturation in the blood is less than 1%**
- **D. CYANIDE: No cyanide is detected in the blood**

ACLU Detainee DeathII ARMY MEDCOM 757

OPINION

This 49-year-old Iraqi male detainee (b)(6) died of an acute myocardial infarction complicated by a mural thrombus of the left ventricle. The toxicology is positive for acetone in the blood and vitreous fluid. This finding can be explained by the deceased's clinical course prior to death. There was no evidence of physical injury discovered at autopsy. Based upon the information available to me at the time of this report, the manner of death is natural.

(b)(6)

(b)(6) MEDICAL EXAMINER

ACLU Detainee DeathII ARMY MEDCOM 758

CERTIFICATE OF DEATH (OVERSEAS)
Acte de décès . (D'Outre-Mer)

NAME OF DECEASED (Last, First, Middle) Nom du défunt (nom et prénoms)	GRADE Grade	BRANCH OF SERVICE Arme	SOCIAL SECURITY NUMBER Numéro de l'Assurance Sociale
STB Hasan, Al Jabbar, N		Civilian	(b)(6)
ORGANIZATION Organisation	NATION (If U.S. citizen, State) Pays	DATE OF BIRTH Date de naissance	SEX Sexe
	Iraq		[X] MALE [ ] FEMALE

RACE Race	MARITAL STATUS État Civil	RELIGION Culte
[X] CAUCASOID Caucasique	[ ] SINGLE Célibataire	[ ] DIVORCED Divorcé
[ ] NEGROID Negroïde	[ ] MARRIED Marié	[ ] SEPARATED Séparé
[ ] OTHER (Specify) Autre (Spécifier)	[ ] WIDOWED Veuf	[ ] PROTESTANT Protestant
		[ ] CATHOLIC Catholique
		[ ] JEWISH Juif
		[X] OTHER (Specify) Autre (Spécifier)

NAME OF NEXT OF KIN Nom du plus proche parent	RELATIONSHIP TO DECEASED Parenté du décédé avec le sus
STREET ADDRESS Domicile à (Rue)	CITY OR TOWN OR STATE (Include ZIP Code) Ville (Code postal compris)

MEDICAL STATEMENT Déclaration médicale

	CAUSE OF DEATH (Enter only one cause per line) Cause du décès (N'indiquer qu'une cause par ligne)	INTERVAL BETWEEN ONSET AND DEATH Intervalle entre l'attaque et le décès
DISEASE OR CONDITION DIRECTLY LEADING TO DEATH Maladie ou condition directement responsable de la mort	Acute Myocardial Infarction Complicated by Mural Thrombus	Days
ANTECEDENT CAUSES Symptômes antérieurs de la mort — MORBID CONDITION, IF ANY, LEADING TO PRIMARY CAUSE Condition morbide, s'il y a lieu, menant à la cause primaire		
ANTECEDENT CAUSES Symptômes antérieurs de la mort — UNDERLYING CAUSE, IF ANY, GIVING RISE TO PRIMARY CAUSE Condition morbide, s'il y a lieu, menant à la cause primaire		
OTHER SIGNIFICANT CONDITIONS Autres conditions significatives		

MODE OF DEATH Condition de décès	AUTOPSY PERFORMED Autopsie effectuée	CIRCUMSTANCES SURROUNDING DEATH DUE TO EXTERNAL CAUSES Circonstances de la mort survenue par des causes extérieures
[X] NATURAL Mort naturelle	[X] YES Oui [ ] NO Non	
[ ] ACCIDENT Mort accidentelle	MAJOR FINDINGS OF AUTOPSY Conclusions principales de l'autopsie	
[ ] SUICIDE Suicide	(b)(6)	
[ ] HOMICIDE Homicide	SIGNATURE (b)(6)	DATE Date 14 November 2007
		AVIATION ACCIDENT Accident d'Avion [ ] YES Oui [X] NO Non

DATE OF DEATH (Day, month, year) Date du décès (Jour, le mois, l'année)	PLACE OF DEATH Lieu du décès
(b)(6) 2007	Iraq

I HAVE VIEWED THE REMAINS OF THE DECEASED AND DEATH OCCURRED AT THE TIME INDICATED AND FROM THE CAUSES AS STATED ABOVE.
J'ai examiné les restes mortels du de cujus je constate que le décès est survenu à l'heure indiquée et à la suite des causes énumérées ci-dessus.

NAME OF MEDICAL OFFICER Nom du médecin traitant ou du médecin examinateur	TITLE OR DEGREE Titre ou diplôme
(b)(6)	Medical Examiner
GRADE Grade (b)(6)	INSTALLATION OR ADDRESS Installation ou adresse Dover AFB, Dover DE
DATE Date 11/14/2007	SIGNATURE (b)(6)

* State conditions, injury or complication which caused illness, if any.
* Autres conditions contributives de la mort, mais non reliées à la maladie ou l'état pathologique ayant causé la mort.
* Indiquer la nature de la blessure, de la complication qui a entraîné la mort, sinon dire la maladie ou l'état pathologique ayant causé la mort.

DD FORM APR 77 2064 REPLACES DA FORM 3402, 1 JAN 72 AND DA FORM 3402-R(AF), 30 SEP 72, WHICH ARE OBSOLETE.

ARMED FORCES INSTITUTE OF PATHOLOGY
Office of the Armed Forces Medical Examiner
1413 Research Blvd., Bldg. 102
Rockville, MD 20850
1-301-319-0000
(FAX 1-301-319-0635)

FINAL AUTOPSY REPORT

Name: MUSTAF, Hussayn Abid
ISN (b)(6)
Date of Birth: (b)(6) 1940 (66 years)
Date of Death (b)(6) 2007
Date of Autopsy: 07 OCT 2007, 1330 hours
Date of Report: 15 OCT 2007

Autopsy No.: (b)(6)
AFIP No.: (b)(6)
Rank: Iraqi Detainee
Place of Death: Balad, Iraq
Place of Autopsy: Dover Port Mortuary
Dover AFB, Dover, DE

Circumstances of Death:
CID investigation revealed that on (b)(6) 2007, (b)(6) had lost his balance while reaching for a water bottle on a ledge over the entrance of the latrine, falling backward and striking his head on the cement floor. (b)(6) then requested medical attention. Several detainees witnessed the fall. No detainees were in the direct vicinity of the (b)(6) when he fell. (b)(6) was conscious and walking on his own when he went to the hospital.

Authorization for Autopsy: Office of the Armed Forces Medical Examiner, IAW 10 USC 1471

Identification:
Detainee (b)(6) is identified by transportation documents and the accompanied CID Investigation Report. Fingerprints, dental radiographs and a sample for DNA identification are obtained on 07 Oct 2007.

CAUSE OF DEATH:
Closed Head Trauma

MANNER OF DEATH:
Accident

ACLU Detainee DeathII ARMY MEDCOM 760

EXTERNAL EXAMINATION

The unclad body is that of a well-developed, well-nourished Caucasian male with no external evidence of trauma. The body weighs 164 pounds and is approximately 69" in length. The external appearance is consistent with the reported age of 66 years.

The head is normocephalic with no gross evidence of trauma. The scalp hair is gray, with prominent male baldness. A grey mustache and stubble beard are also noted. The eyelids are unremarkable with no apparent trauma. The eyes are unremarkable. The irides are pale and grayish. The corneae are whitish and cloudy. The sclerae are white with no apparent hemorrhage or petechiae. The external auditory canals, external nares and oral cavity are free of foreign material or apparent trauma. The nasal skeleton is palpably intact. The tongue is unremarkable with no significant trauma or evidence of sharp force injuries. The lips are unremarkable with no apparent injury. The teeth are natural, in poor condition and many are remotely missing. The neck is unremarkable with no evidence of trauma or abnormality.

The chest is unremarkable. No injury of the ribs or sternum is evident externally. The abdomen is unremarkable with no evidence of trauma or major surgical scars. The back is unremarkable with no evidence of trauma or gross abnormality. The external genitalia are those of an adult circumcised male with unremarkable descended testes.

The extremities are unremarkable with no evidence of trauma or gross abnormality. A slightly deformed left external ear and a deep scar of the left side of the face are noted, consistent with a history of remote firearm injury. The scar extends from the cheek bone to the external auditory canal. No tattoos, major surgical or characteristic scars or other identifying marks are noted.

EVIDENCE OF INJURY

No evidence of injury is noted on external examination except a small area of possible superficial contusion on the right side of the face which is of questionable clinical significance. Careful dissection of the extremities and the back reveal no evidence of recent or remote trauma or skeletal fractures. Examination of the neck with layer-by-layer dissection of the strap muscles reveals no evidence of trauma.

A. Injuries of the Head:

Examination of the head reveals no external evidence of trauma. A small contusion of the left forehead is noted. No other contusions, abrasions or gross evidence of trauma is noted. Reflection of the scalp reveals significant left parietal subgaleal and temporalis muscle hemorrhage. Reflection of the left temporalis muscle reveals linear fracture of the parietal bone extending anteriorly and downward into the left anterior cranial fossa and posteriorly to the left side of the occipital bone. Removal of the skull cap reveals left epidural hemorrhage of an estimated 10-15 cc of blood. Bilateral subdural hemorrhage is noted, more prominent on the left side. Removal of the brain reveals marked bilateral hemorrhage under the frontal lobes, more prominent on the left side and marked necrosis of the left frontal lobe. Diffuse bilateral subarachnoid hemorrhage is noted as well as around the cerebellum.

ACLU Detainee DeathII ARMY MEDCOM 761

B. Remote Firearm Injury to the Face:

Examination of the left face reveals a prominent depressed scar of the cheek, extending from the cheek bone to the left external auditory canal, measuring 2 ½ x ¼", and is associated with deformity of the left external ear. Reflection of the face reveals presence of marked scarring of the underlying tissue and muscle. Two round metal fragments (? pellets) are recovered, photographed, submitted as evidence and retained by OAFME. Multiple similar metallic fragments are noted on radiographs but their recovery would have lead to mutilation of the face and were not recovered.

INTERNAL EXAMINATION

BODY CAVITIES:

The body is opened by the usual thoraco-abdominal incision and the chest plate is removed. No adhesions or abnormal collections of fluid are present in any of the body cavities. All body organs are present in the normal anatomical position. There is no internal evidence of blunt force or penetrating injury to the thoraco-abdominal region. No abnormal collection of blood or fluid is noted in the body cavities.

HEAD: (CENTRAL NERVOUS SYSTEM)

The scalp is reflected. Closed head traumatic injuries are noted above. No non-traumatic abnormality is noted. The brain weighs 1310 grams.

NECK:

Examination and dissection of the soft tissues of the neck, layer-by-layer, reveals no abnormal mobility or evidence of trauma. The thyroid cartilage and hyoid bone are intact.

CARDIOVASCULAR SYSTEM:

The pericardium is intact. The pericardial sac is free of fluid and adhesions. The coronary arteries arise normally, follow the usual distribution and are patent, without evidence of excessive atherosclerosis. The left main coronary artery reveals 15% atherosclerotic narrowing. The chambers and valves exhibit the usual size-position relationship and are unremarkable. The myocardium is pale brown and reveals marked postmortem changes. The atrial and ventricular septae are intact. The aorta and its major branches arise normally, follow the usual course and are unremarkable without significant atherosclerosis and other abnormality. The venae cavae and their major tributaries return to the heart in the usual distribution and are free of thrombi. The heart weighs 340 grams.

RESPIRATORY SYSTEM:

The upper airway is clear of debris and foreign material; the mucosal surfaces are unremarkable. The pleural surfaces are unremarkable bilaterally. The pulmonary parenchyma is congested and edematous red-grey and reveals no focal lesions. The

ACLU Detainee DeathII ARMY MEDCOM 762

pulmonary arteries are normally developed, patent and without thrombus or embolus. The right and left lung weigh 810 grams and 800 grams, respectively.

LIVER & BILIARY SYSTEM:
The hepatic capsule is smooth and intact, covering dark brown parenchyma with no apparent focal lesions. The gallbladder is intact and contains green bile and no stones. The extrahepatic biliary tree is without evidence of calculi. The liver weighs 1280 grams.

ALIMENTARY TRACT:
The tongue exhibits no evidence of injury. The esophagus is lined by gray-white mucosa. The gastric mucosa is unremarkable with unremarkable rugal folds. The lumen contains 20 ml of brownish fluid, submitted for toxicology. The small and large bowel is unremarkable. The pancreas is autolysed. The appendix is present and unremarkable.

GENITOURINARY SYSTEM:
The renal capsules are smooth and thin and strip with ease from the underlying renal smooth brown cortical surfaces. The cortices are delineated from the medullary pyramids, and unremarkable. The calyces, pelves and ureters are unremarkable. The urinary bladder mucosa is unremarkable and contains no urine. The right and left kidneys weigh 130 and 120 grams, respectively. The external genitalia are those of an adult circumcised male with unremarkable testes.

RETICULOENDOTHELIAL SYSTEM:
The spleen has a smooth, intact capsule covering pasty purple parenchyma; and grossly unremarkable. No enlarged lymph nodes are seen. The spleen weighs 180 grams.

ENDOCRINE SYSTEM:
The pituitary, thyroid and adrenal glands are grossly unremarkable.

MUSCULOSKELETAL SYSTEM:
Muscle development is normal. No non-traumatic bone or joint abnormalities are noted. See "Evidence of Injury".

EVIDENCE COLLECTION

Two gray metallic spheres, pellets are recovered from the left facial subcutaneous tissue, photographed for documentation, submitted as evidence and retained by OAFME.

IDENTIFYING MARKS

A deep left facial scar consistent with a remote firearm injury is noted. No tattoos, major surgical scars or other identifying marks are noted.

ACLU Detainee DeathII ARMY MEDCOM 763

NATURAL DISEASES

Mild coronary atherosclerosis is noted. No evidence of other natural diseases is identified during the autopsy examination.

MEDICAL INTERVENTION

Multiple intravenous access lines are noted in the left antecubital fossa, right wrist and left inguinal area, and a urinary catheter are noted.

POSTMORTEM CHANGES

Rigor is equal in all extremities. Livor is consistent with supine position. Body temperature is cold due to refrigeration.

TOXICOLOGY

A. Volatiles (Blood and Vitreous fluid):
   - No ethanol was detected.

D. Screened drugs of abuse and medications:
   - Lidocaine: detected and confirmed.
   - Benzodiazepine (Midazolam): 0.14 mg/L
   - Benzodiazepine (1-Hydroxymidazolam): 0.057 mg/L

ADDITIONAL PROCEDURES

- Documentary photographs are taken by an OAFME photographer.
- Full body radiographs and computerized body scans are obtained.
- Specimens retained for toxicological and/or DNA identification are: Blood, vitreous fluid, bile, urine, gastric contents, and tissue samples from liver, lung, kidney, spleen, brain, psoas and heart muscles, and adipose tissue.
- Representative sections of organs are retained in formalin for microscopic examination if needed in the future.
- Evidence recovered is retained by OAFME.
- Review of the available medical records.

FINAL AUTOPSY DIAGNOSIS

I. Closed Head Trauma:
   - Left parietal skull fracture.
   - Left epidural hemorrhage.
   - Bilateral subdural hemorrhage, left > right.
   - Diffuse bilateral subarachnoid hemorrhage, left > right.
   - Marked necrosis of the left frontal lobe.

ACLU Detainee DeathII ARMY MEDCOM 764

II. Remote Facial Trauma:
- Well-healed firearm injury of the left face.

III. Toxicology: Lidocaine and Benzodiazepine were detected and confirmed. "See toxicology results above). Negative for ethanol and drugs of abuse.

IV. Evidence: Two metallic spheres pellets are recovered and retained by OAFME.

OPINION

The remains of believed to be (BTB) (b)(6) an Iraqi detainee, reveal injuries consistent with a reported and witnessed fall. The closed head trauma caused skull fractures, extensive intracranial hemorrhages and necrosis of the left frontal lobe. No evidence of other acute trauma is present. A remote (old) well healed scar of a firearm injury is noted. Toxicological studies reveal the presence of Lidocaine and Benzodiazepines which may be related to medical treatment, and is non-contributory to his death. No ethanol or drugs of abuse are detected. Manner of death is "Accident".

(b)(6)

(b)(6) **Medical Examiner** (b)(6)

ACLU Detainee DeathII ARMY MEDCOM 765

CERTIFICATE OF DEATH *(OVERSEAS)*
Acte de décès (D'Outre-Mer)

NAME OF DECEASED (Last, First, Middle) Nom du décédé (Nom et prénoms)	GRADE Grade	BRANCH OF SERVICE Arme	SOCIAL SECURITY NUMBER Numéro de l'Assurance Social
Mustaf, Hussayn, (b)(6)		Civilian	(b)(6)
ORGANIZATION Organisation	**NATION** (e.g. United States) Pays	**DATE OF BIRTH** Date de naissance	**SEX** Sexe
	Iraq	(b)(6) 1940	[X] MALE [ ] FEMALE

RACE Race		MARITAL STATUS État Civil			RELIGION Culte		
[X]	CAUCASOID Caucasique	[ ]	SINGLE Célibataire	[ ] DIVORCED Divorcé	[ ] PROTESTANT Protestant	[X]	OTHER (Specify) Autre (Spécifier)
[ ]	NEGROID Negroide	[ ]	MARRIED Marié	[ ] SEPARATED Séparé	[ ] CATHOLIC Catholique		
[ ]	OTHER (Specify) Autre (Spécifier)	[ ]	WIDOWED Veuf		[ ] JEWISH Juif		

NAME OF NEXT OF KIN Nom du plus proche parent	RELATIONSHIP TO DECEASED Parenté du décédé avec le sus
STREET ADDRESS Domicile à (Rue)	CITY OR TOWN OR STATE (Include ZIP Code) Ville (Code postal compris)

MEDICAL STATEMENT Déclaration médicale

CAUSE OF DEATH (Enter only one cause per line) Cause du décès (N'indiquer qu'une cause par ligne)		INTERVAL BETWEEN ONSET AND DEATH Intervalle entre l'attaque et le décès
DISEASE OR CONDITON DIRECTLY LEADING TO DEATH [1] Maladie ou condition directement responsable de la mort [1]	Closed head trauma	Hours
ANTECEDENT CAUSES Symptômes précurseurs de la mort. MORBID CONDITION, IF ANY, LEADING TO PRIMARY CAUSE Condition morbide, s'il y a lieu, menant à la cause primaire		
UNDERLYING CAUSE, IF ANY, GIVING RISE TO PRIMARY CAUSE Condition morbide, s'il y a lieu, menant à la cause primaire		
OTHER SIGNIFICANT CONDITIONS [2] Autres conditions significatives [2]		

MODE OF DEATH Condition de décès	AUTOPSY PERFORMED Autopsie effectuée [X] YES Oui [ ] NO Non	CIRCUMSTANCES SURROUNDING DEATH DUE TO EXTERNAL CAUSES Circonstances de la mort suscitées par des causes extérieures
[ ] NATURAL Mort naturelle	MAJOR FINDINGS OF AUTOPSY Conclusions principales de l'autopsie	
[X] ACCIDENT Mort accidentelle		
[ ] SUICIDE Suicide	NAME OF PATHOLOGIST Nom du pathologiste (b)(6)	
[ ] HOMICIDE Homicide	SIGNATURE (b)(6)	DATE Date 7 October 2007
		AVIATION ACCIDENT Accident à Avion [ ] YES Oui [X] NO Non

DATE OF DEATH (day, month, year) Date de décès (le jour, le mois, l'année)	PLACE OF DEATH Lieu de décès
(b)(6) 2007 (b)(6)	Iraq

I HAVE VIEWED THE REMAINS OF THE DECEASED AND DEATH OCCURRED AT THE TIME INDICATED AND FROM THE CAUSES AS STATED ABOVE.
J'ai examiné les restes mortels du dé funtet je conclus que le décès est survenu à l'heure indiquée et à, la suite des causes énumérées ci-dessus.

NAME OF MEDICAL OFFICER Nom du médicin militaire ou du médicin sanitaire	TITLE OR DEGREE Titre ou diplômé
(b)(6)	Medical Examiner

GRADE Grade	INSTALLATION OR ADDRESS Installation ou adresse
(b)(6)	Dover AFB, Dover DE
DATE Date 10/24/2007	SIGNATURE (b)(6)

[1] State disease, injury or complication which caused death, but not mode of dying such as heart failure, ect.
[2] State conditions contributing to the death, but not related to the disease or condition causing death.
[1] Préciser la nature de la maladie, de la blessure ou de la complication qui a contribué à la mort, mais non la manière de mourir, telle qu 'un arrêt du coeur, etc
[2] Préciser la condition qui a contribué à la mort, mais n'ayant aucun rapport avec la maladie ou à la condition qui a provoqué la mort.

DD FORM 1 APR 77 2064 REPLACES DA FORM 3565, 1 JAN 72 AND DA FORM 3565-R(PAS), 26 SEP 76, WHICH ARE OBSOLETE.

MEDCOM 0766

ACLU Detainee DeathII ARMY MEDCOM 766

(REMOVE, REVERSE AND RE-INSERT CARBONS BEFORE COMPLETING THIS SIDE)

DISPOSITON OF REMAINS

NAME OF MORTICIAN PREPARING REMAINS	GRADE	LICENSE NUMBER AND STATE	OTHER

INSTALLATION OR ADDRESS	DATE	SIGNATURE
(b)(6)		

NAME OF CEMETERY OR CREMATORY	LOCATION OF CEMETERY OR CREMATORY

TYPE OF DISPOSTION	DATE OF DISPOSTION

REGISTRATION OF VITAL STATISTICS

REGISTRY *(Town and Country)*	DATE REGISTERED	FILE NUMBER	
		STATE	OTHER

NAME OF FUNERAL DIRECTOR	ADDRESS

SIGNATURE OF AUTHORIZED INDIVIDUAL

DD FORM 2064, APR 1977 (BACK) *USAPA V1.00*

ACLU Detainee DeathII ARMY MEDCOM 767

ARMED FORCES INSTITUTE OF PATHOLOGY
Office of the Armed Forces Medical Examiner
1413 Research Blvd., Bldg. 102
Rockville, MD 20850
301-319-0000

AUTOPSY EXAMINATION REPORT

Name: ABULLA. Mohammad Khudayer
ISN: (b)(6)
Date of Birth: (b)(6) 1980
Date of Death (b)(6) 2007

Autopsy No.: (b)(6)
AFIP No.: (b)(6)
Rank: Civilian Detainee
Place of Death: Camp Bucca, Iraq

Date/Time of Autopsy: 26 SEP 2007 @ 1200
Place of Autopsy: Port Mortuary, Dover AFB, DE

Date of Report: 29 NOV 2007

Circumstances of Death: This 27-year-old civilian detainee was brought to a guard shack at Camp Bucca without a pulse and not breathing.

Authorization for Autopsy: Armed Forces Medical Examiner, per U.S. Code 10, Section 1471

Identification: Positive identification is established by comparison of postmortem DNA sample and antemortem DNA records. Fingerprints were taken and a postmortem dental examination was performed if exemplars become available.

CAUSE OF DEATH: **LIGATURE STRANGULATION**

MANNER OF DEATH: **HOMICIDE**

EXTERNAL EXAMINATION

The body is that of a well-developed, well-nourished male received unclad. The body weighs 136-pounds, is 66-inches in length and appears compatible with the reported age of 27-years. The body is cold. Rigor is absent. Lividity is present and fixed on the posterior surface of the body, except in areas exposed to pressure. There is green discoloration of the abdomen and marbling of the skin is present.

The head is normocephalic, and the scalp hair is dark and medium length. Facial hair consists of beard stubble. The irides are brown, the corneae are cloudy, the sclerae are white, and the conjunctivae are congested with scattered rare petechiae. The external auditory canals, external nares and oral cavity are free of foreign material and abnormal secretions. The nasal skeleton and maxilla are palpably intact. The lips are without evident injury. The teeth are natural and in good condition. Injuries of the neck are described below (see "Evidence of Injury").

The chest is unremarkable. No evidence of injury of the ribs or the sternum is evident externally. The abdomen is flat. The external genitalia are those of a normal adult circumcised male. The anus is without note. Healed surgical scars or tattoos are not noted on the torso (b)(6) is written in black marker pen on the abdomen. A 1/8-inch diameter pigmented macule is noted at the sternal notch. There are three round to ovoid scars on the upper back that range in size from 1/8-inch in diameter to ¼ x 1/8-inch.

The extremities show no evidence of fractures, lacerations or deformities. The fingernails are intact and trimmed. Tattoos are noted (b)(6)
(b)(6) Scars are noted on the anterior right arm (5/8 x ½-inch) and in the right popliteal fossa (5/8-inch diameter).

CLOTHING AND PERSONAL EFFECTS

No clothing or personal effects are received with the body.

MEDICAL INTERVENTION

- Therapeutic needle stick-marks on the upper right and left chest
- Therapeutic needle stick-marks in both antecubital fossae with associated hemorrhage into the adjacent subcutaneous tissue
- Therapeutic needle stick-mark in the right groin

RADIOGRAPHS

A complete set of postmortem radiographs and CT images are obtained and demonstrates the following:

- Metallic foreign bodies in the upper left back, the left buttock, the left forearm, the left hand, and the right leg
- Changes of decomposition

ACLU Detainee DeathII ARMY MEDCOM 769

EVIDENCE OF INJURY

The ordering of the following injuries is for descriptive purposes only, and is not intended to imply order of infliction or relative severity. All wound pathways are given relative to standard anatomic position.

I. Ligature Strangulation

At least three 1/8-inch in width, circumferential, continuous ligature furrows are present on the skin of the neck and are directed horizontally. The ligature furrows cross the lower half of the thyroid cartilage, between 9 ½-inches to 10 ½-inches below the top of the head, between 2 5/8-inches and 3 ¼-inches below the tragus of the right ear and 3-inches and 3 ¾-inches below the tragus of the left ear. On the back of the neck, the ligature furrows cross the posterior midline 9-inches below the top of the head. The ligature is not available for examination.

On the right side of the neck, there is a 1 x ¾-inch abrasion that is not associated with a ligature furrow, and on the left side of the neck, there is a 1 ½ x 3/8-inch abrasion that is not associated with a ligature furrow. Layer-wise, anterior neck dissection demonstrates focal hemorrhage of the superior right sternocleidomastoid muscle, a fracture of the right superior horn of the thyroid cartilage, and an intact hyoid bone.

II. Evidence of Old Fragmentation Injuries

During radiographic studies, metallic foreign bodies are identified and located in the upper left back posterior to the left scapula, the left buttock, the left forearm, the left hand, and in the right leg between the tibia and fibula. The fragments located in the upper left back and the left buttock are recovered and retained as evidence by the OAFME. The other fragments identified are not recovered. Both of the recovered fragments were encased by fibrous tissue; wound tracts and entrance wounds are not identified.

III. Other Injuries

There is a 1/8 x 1/8-inch abrasion on the 4th digit of the right hand (ring finger) and a 1 x 3/8-inch abrasion on the left knee.

INTERNAL EXAMINATION

BODY CAVITIES:

The body is opened by the usual thoraco-abdominal incision and the chest plate is removed. The ribs, sternum, and vertebral bodies are visibly and palpably intact. No adhesions are present in any of the body cavities. Decomposition fluid is present in both pleural cavities (right, 300-milliliters; left 200-milliliters). All body organs are present in normal anatomical position, and demonstrate early changes of decomposition.

The subcutaneous fat layer of the abdominal wall is ¾-inch thick.

Posterior incisions of the torso and both upper and lower extremities, fail to demonstrate any subcutaneous ecchymoses other than that caused by the therapeutic procedures that have been

ACLU Detainee DeathII ARMY MEDCOM 770

described above (see "Medical Intervention").

HEAD AND CENTRAL NERVOUS SYSTEM:

The scalp is reflected. The galeal and subgaleal soft tissues of the scalp are free of injury. There are no skull fractures. The calvarium of the skull is removed. The dura mater and falx cerebri are intact. There is no epidural or subdural hemorrhage present. The leptomeninges are thin and delicate. The cerebral hemispheres are symmetrical. The structures at the base of the brain, including cranial nerves and blood vessels are intact.

Clear cerebrospinal fluid surrounds the 1,600-gram brain, which has unremarkable gyri and sulci. Coronal sections through the cerebral hemispheres reveal no lesions. Transverse sections through the brain stem and cerebellum are unremarkable. The atlanto-occipital joint is stable.

NECK:

Injuries of the neck are described above (see "Evidence of Injury"). The hyoid bone is intact. The larynx is lined by intact white mucosa. The tongue is free of bite marks, hemorrhage, or other injuries. Incision and dissection of the posterior neck demonstrates no deep paracervical muscular injury and no cervical spine fractures.

CARDIOVASCULAR SYSTEM:

The 290-gram heart is contained in an intact pericardial sac. The epicardial surface is smooth, with minimal fat investment. The coronary arteries are present in a normal distribution, with a right-dominant pattern. Cross sections of the vessels show no luminal narrowing.

The myocardium is homogenous, red-brown, and firm. The valve leaflets are thin and mobile. The walls of the left ventricle, interventricular septum, and right ventricle are 1.0, 1.0, and 0.3-centimeters thick, respectively. The endocardium is smooth and glistening.

The aorta gives rise to three intact and patent arch vessels. The renal and mesenteric vessels are unremarkable.

RESPIRATORY SYSTEM:

The upper airway is clear of debris and foreign material: the mucosal surfaces are smooth, yellow-tan and unremarkable. The pleural surfaces are smooth, glistening and unremarkable bilaterally.

The pulmonary parenchyma is diffusely congested and edematous, exuding slight to moderate amounts of blood and frothy fluid; no focal lesions are noted.

The pulmonary arteries are normally developed, patent and without thrombus or embolus. The right lung weighs 710-grams; the left 600-grams.

ACLU Detainee DeathII ARMY MEDCOM 771

HEPATOBILIARY SYSTEM:

The 1,180-gram liver has an intact smooth capsule covering moderately congested tan-brown parenchyma with no focal lesions noted.

The gallbladder contains 10-milliliters of green-brown, mucoid bile; the mucosa is velvety and unremarkable. The extrahepatic biliary tree is patent, without evidence of calculi.

GASTROINTESTINAL SYSTEM:

The esophagus is lined by gray-white, smooth mucosa. The gastric mucosa is arranged in the usual rugal folds and the lumen contains 150-milliiters of red-black fluid.

The small and large bowels are unremarkable. The pancreas is autolyzed, but appears normal. The appendix is present.

GENITOURINARY SYSTEM:

The right kidney weighs 110-grams; the left 90-grams. The renal capsules are smooth and thin, semi-transparent and strip with ease from the underlying smooth, red-brown cortical surface.

The cortex is sharply delineated from the medullary pyramids, which are red-purple to tan and unremarkable. The calyces, pelves and ureters are unremarkable.

White bladder mucosa overlies an intact bladder wall. The bladder contains approximately 155-milliliters of cloudy urine. The testes, prostate gland and seminal vesicles are without note.

LYMPHORETICULAR SYSTEM:

The 190-gram spleen has a smooth, intact capsule covering red-purple, moderately firm parenchyma; the lymphoid follicles are unremarkable.

Lymph nodes in the hilar, periaortic and iliac regions are not enlarged.

ENDOCRINE SYSTEM:

The pituitary gland is left *in situ* and is grossly unremarkable. The thyroid gland is symmetric and red-brown, without cystic or nodular change. The right and left adrenal glands are symmetric, and are autolyzed. No masses or areas of hemorrhage are identified.

MUSCULOSKELETAL SYSTEM:

No non-traumatic abnormalities of muscle or bone are identified.

ACLU Detainee DeathII ARMY MEDCOM 772

MICROSCOPIC EXAMINATION

Selected portions of organs are retained in formalin, without preparation of histology slides.

ADDITIONAL PROCEDURES

1. Documentary photographs are taken by AFMES staff photographers.
2. Personal effects are released to the appropriate mortuary operations representatives.
3. Specimens retained for toxicology testing and/or DNA identification are: vitreous fluid, blood, decomposition fluid, urine, bile, gastric contents, spleen, liver, lung, kidney, brain, myocardium, adipose tissue and skeletal muscle.
4. The dissected organs are forwarded with body.
5. Metallic foreign bodies are collected from the upper left back and left buttock and are retained by the OAFME as evidence.

FINAL AUTOPSY DIAGNOSES

IV. Ligature Strangulation

A. The ligature is not available for examination
B. At least three circumferential, continuous ligature furrows are directed horizontally
C. The ligature furrows cross the lower half of the thyroid cartilage
D. On both sides of the neck, there are abrasions that are not associated with a ligature furrow
E. Anterior neck dissection demonstrates focal hemorrhage of the superior right sternocleidomastoid muscle, a fracture of the right superior horn of the thyroid cartilage, and an intact hyoid bone

V. Evidence of Old Fragmentation Injuries

A. Metallic foreign bodies identified by radiography, located in the upper left back and in the left buttock are recovered and retained as evidence
B. Metallic foreign bodies identified by radiography, located in the left hand, in the left forearm, and in the right leg between the tibia and fibula are not recovered

VI. Other Injuries

A. Abrasion on the 4th digit of the right hand (ring finger)
B. Abrasion on the left knee

IV. No significant natural diseases or pre-existing conditions are identified, within the limitations of this examination.

V. There is no evidence of additional physical abuse

VI. Evidence of Medical Therapy

A. Needle stick-marks in the upper right and left chest
B. Needle stick-marks in both antecubital fossae with associated hemorrhage into the adjacent subcutaneous tissue

ACLU Detainee DeathII ARMY MEDCOM 773

C. Needle stick-mark in the right groin

VII. Post-Mortem Changes

A. Rigor is absent
B. Lividity is posterior and fixed except in areas exposed to pressure
C. The body temperature is cold to touch
D. There is green discoloration of the abdomen
E. Marbling is present

VIII. Identifying Body Marks

A. Tattoo (b)(6)
B. Tattoo
C. Multiple scars on the back, ranging from 1/8-inch diameter to ¼ x 1/8-inch
D. Scar on the anterior right arm, 5/8 x ½-inch
E. Scar on the right popliteal fossa, 5/8-inch diameter
F. Pigmented macule at the sternal notch

IX. Toxicology

A. The blood and urine are tested for volatile compounds including ethanol and none are found.
B. The urine is screened for medications and drugs of abuse and none are found.

OPINION

This 27-year-old male (b)(6) died of ligature strangulation. There were multiple, circumferential and continuous horizontally-oriented ligature furrows present on his neck. Abrasions noted on both sides of the neck that were not associated with a ligature furrow may represent defensive-type injuries. There was also evidence of old fragmentation injuries noted at autopsy; five metallic foreign bodies were identified radiographically and two fragments were recovered and retained as evidence. The scars noted on the body may represent the locations of entrance wounds that are associated with the fragmentation injuries. Toxicological testing for ethanol and screened drugs of abuse was negative. The manner of death is homicide.

(b)(6)

(b)(6) Medical Examiner

ACLU Detainee DeathII ARMY MEDCOM 774

CERTIFICATE OF DEATH (OVERSEAS)
Acte de décès. (D'Outre-Mer)

NAME OF DECEASED (Last, First, Middle) Nom du décédé (Nom et prénoms)	GRADE Grade	BRANCH OF SERVICE Arme	SOCIAL SECURITY NUMBER Numéro de l'Assurance Sociale
Abulia, Mohammed,		Civilian	(b)(6)
ORGANIZATION Organisation	NATION (e.g. United States) Pays: Iraq	DATE OF BIRTH Date de naissance: (b)(6) 1981	SEX Sexe: [X] MALE [ ] FEMALE

RACE Race		MARITAL STATUS État civil			RELIGION Culte		
X	CAUCASOID Caucasique	SINGLE Célibataire		DIVORCED Divorcé		PROTESTANT Protestant	OTHER (Specify) Autre (Spécifier)
	NEGROID Negroïde	MARRIED Marié		SEPARATED Séparé		CATHOLIC Catholique	X
	OTHER (Specify) Autre (Spécifier)	WIDOWED Veuf				JEWISH Juif	

NAME OF NEXT OF KIN Nom du plus proche parent	RELATIONSHIP TO DECEASED Parents du décédé avec le cas
STREET ADDRESS Domicile à (Rue)	CITY OR TOWN OR STATE (include Zip Code) Ville (Code postal compris)

MEDICAL STATEMENT Déclaration médicale

CAUSE OF DEATH (Enter only one cause per line) Cause du décès (N'indiquer qu'une cause par ligne)		INTERVAL BETWEEN ONSET AND DEATH Intervalle entre l'attaque et le décès
DISEASE OR CONDITON DIRECTLY LEADING TO DEATH[1] Maladie ou condition directement responsable de la mort[1]	Ligature strangulation	Minutes
ANTECEDENT CAUSES Symptômes précurseurs de la mort — MORBID CONDITION, IF ANY, LEADING TO PRIMARY CAUSE Condition morbide, s'il y a lieu, menant à la cause primaire		
ANTECEDENT CAUSES Symptômes précurseurs de la mort — UNDERLYING CAUSE, IF ANY, GIVING RISE TO PRIMARY CAUSE Condition morbide, s'il y a lieu, menant à la cause primaire		
OTHER SIGNIFICANT CONDITIONS[2] Autres conditions significatives[2]		

MODE OF DEATH Condition de décès	AUTOPSY PERFORMED Autopsie effectuée [X] YES Oui [ ] NO Non	CIRCUMSTANCES SURROUNDING DEATH DUE TO EXTERNAL CAUSES Circonstances de la mort causées par des causes extérieures
NATURAL Mort naturelle	MAJOR FINDINGS OF AUTOPSY Conclusions principales de l'autopsie	
ACCIDENT Mort accidentelle		
SUICIDE Suicide	NAME OF PATHOLOGIST Nom du pathologiste: (b)(6)	
X HOMICIDE Homicide	SIGNATURE (b)(6) — DATE Date: 26 September 2007	AVIATION ACCIDENT Accident à Avion [ ] YES Oui [X] NO Non

DATE OF DEATH (day, month, year) Date de décès (Jour, le mois, l'année)	PLACE OF DEATH Lieu de décès
(b)(6) 2007	Iraq

I HAVE VIEWED THE REMAINS OF THE DECEASED AND DEATH OCCURRED AT THE TIME INDICATED AND FROM THE CAUSES AS STATED ABOVE.
J'ai examiné les restes mortels du dé furent le conclus que le décès est survenu à l'heure indiquée et à la suite des causes énumérées ci-dessus.

NAME OF MEDICAL OFFICER Nom du médecin officier ou du médecin de la Marine	TITLE OF OFFICER Titre du médecin
(b)(6)	Medical Examiner
GRADE Grade: (b)(6)	INSTALLATION OR ADDRESS Installation ou adresse: Dover AFB, Dover DE
DATE Date: 9/26/2007	SIGNATURE (b)(6)

[1] Mode de décès, notre le diagnostique [illegible]
[2] Autres conditions contributives à la mort, [illegible]
[3] [illegible]
[4] [illegible]

DD FORM 1 APR 77 2064 REPLACES DA FORM 2069, 1 JAN 73 AND DA FORM 2069-R(PAS), 28 SEP 75, WHICH ARE OBSOLETE.

(REMOVE, REVERSE AND RE-INSERT CARBONS BEFORE COMPLETING THIS SIDE)

DISPOSITION OF REMAINS

NAME OF MORTICIAN PREPARING REMAINS	GRADE	LICENSE NUMBER AND STATE	OTHER

INSTALLATION OR ADDRESS	DATE	SIGNATURE
(b)(6)		

NAME OF CEMETERY OR CREMATORY	LOCATION OF CEMETERY OR CREMATORY

TYPE OF DISPOSITION	DATE OF DISPOSITION

REGISTRATION OF VITAL STATISTICS

REGISTRY (Town and County)	DATE REGISTERED	FILE NUMBER	
		STATE	OTHER

NAME OF FUNERAL DIRECTOR	ADDRESS

SIGNATURE OF AUTHORIZED INDIVIDUAL

DD FORM 2064, APR 1977 (BACK) USAPA V1.00

ACLU Detainee DeathII ARMY MEDCOM 776

ARMED FORCES INSTITUTE OF PATHOLOGY
Office of the Armed Forces Medical Examiner
1413 Research Blvd., Bldg. 102
Rockville, MD 20850
301-319-0000

AUTOPSY EXAMINATION REPORT

Name: Lateef, Hatem K (b)(6)
ISN: (b)(6)
Date of Birth: (b)(6) 1985
Date of Death: (b)(6) 2007
Date/Time of Autopsy: 27 AUG 2007 @1100 hrs
Date of Report: 20 NOV 2007

Autopsy No.: (b)(6)
AFIP No.: (b)(6)
Rank: Detainee
Place of Death: Iraq
Place of Autopsy: Port Mortuary, Dover AFB, Dover, Delaware

Circumstances of Death: It is reported that this detainee was admitted to the 31st Combat Surgical Hospital on 4 JUL 2007 after receiving numerous battlefield injuries including shrapnel injuries, lacerations of the liver, kidney damage, and brain injury. He clinically suffered multiple complications including hemothorax, pneumothorax, bowel perforation, diabetic ketoacidosis, cardiac arrest (two times), congestive heart failure, anoxic brain injury, and peritonitis. Despite treatment, this detainee died on (b)(6) 2007.

Authorization for Autopsy: Armed Forces Medical Examiner, per 10 U.S. Code 1471

Identification: Presumptive identification is established by review of accompanying paperwork. Post-mortem dental charting, fingerprints and a specimen suitable for DNA comparison are obtained.

CAUSE OF DEATH: **Complications of blast and blast fragmentation injuries.**

MANNER OF DEATH: **Homicide.**

ACLU Detainee DeathII ARMY MEDCOM 777

EXTERNAL EXAMINATION

The body is that of a well-developed, well-nourished male clad in a hospital gown. The body exhibits generalized edema, weighs 156 pounds, is 69 inches in length, and appears compatible with the reported age of 21 years. The body is cold. Rigor has passed. Lividity is present and fixed on the posterior surface of the body, except in areas exposed to pressure. Skin slippage is identified on the extremities and face.

The head is normocephalic, and the scalp hair is short and black. The irides are brown. The corneae are cloudy. The conjunctivae are congested. The sclerae are white. The external auditory canals, external nares and oral cavity are free of foreign material and abnormal secretions. The nasal skeleton and maxilla are palpably intact. The lips are without evident injury. The teeth are natural. Examination of the neck reveals no evidence of injury.

Injuries of the torso and extremities are described below. No evidence of injury of the ribs or the sternum is evident externally. The abdomen is protuberant. Healed surgical scars are noted on the abdomen. The external genitalia are those of an adult male. The anus is without note. The scrotum is swollen.

The fingernails are intact. Decubitus ulcers are identified on the lower back overlying the sacrum (6 x 2 inches), the buttock (1/4 inch), the back of the head (1 inch), the medial surface of the right thigh (4 x 4 inches), and the lateral surfaces of both heels (right - 2 x 1 inch, left - 1 1/2 x 3/4 inches).

CLOTHING AND PERSONAL EFFECTS

- None

MEDICAL INTERVENTION

- Nasogastric tube
- IV access (left subclavian; left groin)
- Laparotomy scar (10 inch vertical with a 1 inch area of granulation tissue on the superior, and a 1 1/2 inch area of granulation tissue on the inferior aspects)
- Foley catheter and attached urine bag
- EKG leads on the torso
- Multiple gauze dressings
- Sutures located in multiple loops of small and large bowel
- Tracheostomy
- A plastic bag is affixed to the left lower quadrant of the abdomen overlying a 1 inch stapled incision

ACLU Detainee DeathII ARMY MEDCOM 778

RADIOGRAPHS

A complete set of postmortem radiographs is obtained.

EVIDENCE OF INJURY

The ordering of the following injuries is for descriptive purposes only, and is not intended to imply order of infliction or relative severity. All wound pathways are given relative to standard anatomic position.

HEAD/NECK:

On the left side of the face, lateral to the left eye, is a 1/4 inch scar. Radiographically there is a minute fragment of radiopaque foreign material (not recovered).

TORSO:

There is a 1 x 1 inch healing laceration on the right side of the chest, a 1/4 x 1/4 inch healing laceration of the center of the chest just left of the midline, and two healing lacerations of the left side of the chest lateral to the left nipple (1/2 x 1/2 inch and 1 1 /2 x 1 inch). Within the superior aspect of the above described laparotomy scar is a 1/4 x 1/4 inch healing laceration. On the right side of the abdomen are two 1/8 inch healing lacerations. On the left side of the abdomen are two healing lacerations that measure 1/2 and 1 1/2 inches in greatest dimension. On the right lower back is a 1/4 x 1/4 inch healing laceration. Multiple radiopaque foreign bodies are detected in the torso radiographically. However, due to their small size and limited evidentiary value these foreign bodies are not recovered. One thousand two hundred and fifty milliliters of serosanguineous fluid is identified in the right chest cavity, and 350 mL of serosanguineous fluid is identified in the left chest cavity. One liter of serosanguineous fluid is identified in the abdomen with mucous and frank pus present. There is a 250 mL of clotted blood identified in the left lower quadrant of the abdomen. Within the area of the clotted blood, there is a small amount of green stool. There is a 1 inch superficial laceration of the left lobe of the liver and a 1/2 inch superficial laceration of the spleen. Both of these wounds appear to be healing and are associated with old hemorrhage into the surrounding tissues. There are multiple defects of the small and large bowel that are sutured. The left scapula is fractured. Posterior cutdowns revealed hemorrhage into the soft tissues of the right buttock.

ACLU Detainee DeathII ARMY MEDCOM 779

EXTREMITIES:

Right upper extremity - There is a 1 inch healing laceration of the posterior right arm. A cutdown of the forearm reveals hemorrhage into the anterior muscle group of the forearms.

Left upper extremity - There is a 1/2 inch healing laceration of the anterior forearm, and two 1/8 inch healing lacerations of the posterior forearm.

Right lower extremity - There is a 1/4 inch abrasion of the distal anterior thigh, and 3/4 x 1/4 inch healing laceration of the proximal right shin. There is a 1/4 inch healing laceration of the posterior right thigh, and four (4) 1/4 inch healing lacerations of the lateral right ankle.[1]

INTERNAL EXAMINATION

BODY CAVITIES:

The body is opened by the usual thoraco-abdominal incision and the chest plate is removed. The ribs, sternum, and vertebral bodies are visibly and palpably intact. Multiple adhesions are identified in both chest cavities and in the abdomen. All body organs are present in normal anatomical position. The subcutaneous fat layer of the abdominal wall is 1/8 inch thick.

HEAD AND CENTRAL NERVOUS SYSTEM

The scalp is reflected. The galeal and subgaleal soft tissues of the scalp are free of injury. There are no skull fractures. The calvarium of the skull is removed. The dura mater and falx cerebri are intact. There is no epidural or subdural hemorrhage present. The leptomeninges are thin and delicate. The cerebral hemispheres are symmetrical. The structures at the base of the brain, including cranial nerves and blood vessels are intact. Clear cerebrospinal fluid surrounds the 1260-gram brain, which has unremarkable gyri and sulci. Coronal sections through the cerebral hemispheres reveal no lesions. Transverse sections through the brain stem and cerebellum are unremarkable. The atlanto-occipital joint is stable. The spinal cord is unremarkable. The entire brain is soft, however, this finding is most prominent in the brainstem.

NECK:

The anterior strap muscles of the neck are homogenous and red-brown, without hemorrhage. The thyroid cartilage and hyoid bone are intact. The larynx is lined by intact white mucosa. The tongue is free of bite marks, hemorrhage, or other injuries. Incision and dissection of the posterior neck demonstrates no deep paracervical muscular injury and no cervical spine fractures.

[1] The healing lacerations that are described most likely represent superficial and deep penetrating blast fragmentation injuries.

ACLU Detainee DeathII ARMY MEDCOM 780

CARDIOVASCULAR SYSTEM:

The 310-gram heart is contained in an intact pericardial sac. The epicardial surface is smooth, with minimal fat investment. The coronary arteries are present in a normal distribution, with a right-dominant pattern. Cross sections of the vessels show wide patency. The myocardium is homogenous, red-brown, and firm. The valve leaflets are thin and mobile. The walls of the left ventricle, interventricular septum, and right ventricle are 1.2, 1.2, and 0.3 cm thick, respectively. The endocardium is smooth and glistening. The aorta gives rise to three intact and patent arch vessels. The renal and mesenteric vessels are unremarkable.

RESPIRATORY SYSTEM:

The upper airway is clear of debris and foreign material: the mucosal surfaces are smooth, yellow-tan and unremarkable. The pleural surfaces are smooth, glistening and unremarkable bilaterally. The pulmonary parenchyma is diffusely congested and edematous, exuding slight to moderate amounts of blood and frothy fluid; no focal lesions are noted. The cut surfaces are firm and red. The pulmonary arteries are normally developed, patent and without thrombus or embolus. The right lung weighs 880 grams; the left 690 grams.

HEPATOBILIARY SYSTEM:

See Evidence of Injury. The 1230-gram liver has a smooth capsule. The cut surface of the liver has a nutmeg appearance. No focal nontraumatic lesions are identified. The gallbladder contains 10 ml of green-brown, mucoid bile; the mucosa is velvety and unremarkable. The extrahepatic biliary tree is patent, without evidence of calculi.

GASTROINTESTINAL SYSTEM:

See Evidence of Injury. The esophagus is lined by gray-white, smooth mucosa. The gastric mucosa is arranged in the usual rugal folds and the lumen contains 10 ml of brown fluid. The small and large bowels are described above. The pancreas has a normal pink-tan lobulated appearance and the ducts are clear.

GENITOURINARY SYSTEM:

The right kidney weighs 110 grams; the left 200 grams. The renal capsules are smooth and thin, semi-transparent and strip with ease from the underlying smooth, red-brown cortical surface. The cortex is dotted with numerous (less than 0.1 cm) abscesses. The calyces, pelves and ureters are unremarkable. White bladder mucosa overlies an intact bladder wall. The bladder is empty. The prostate gland and seminal vesicles are without note.

ACLU Detainee DeathII ARMY MEDCOM 781

LYMPHORETICULAR SYSTEM:

See Evidence of Injury. The 320-gram spleen has a smooth, capsule covering red-purple, moderately firm parenchyma; the lymphoid follicles are unremarkable. Lymph nodes in the hilar, periaortic, and iliac regions are not enlarged.

ENDOCRINE SYSTEM:

The thyroid gland is symmetric and red-brown, without cystic or nodular change. The right and left adrenal glands are symmetric, with bright yellow cortices and red-brown medullae. No masses or areas of hemorrhage are identified.

MUSCULOSKELETAL SYSTEM:

No non-traumatic abnormalities of muscle or bone are identified.

ADDITIONAL PROCEDURES

1. Documentary photographs are taken by OAFME staff photographers.
2. Personal effects are released to the appropriate mortuary operations representatives.
3. Specimens retained for toxicology testing and/or DNA identification are: brain, heart, lung, kidney, liver, spleen, skeletal muscle, adipose tissue, blood, vitreous fluid, gastric contents, bile, and urine (from urine bag).
4. The dissected organs are forwarded with body.

MICROSCOPIC EXAMINATION

Lung (Slide 1) – There is extensive autolysis, congestion and edema. Intra-alveolar neutrophils are seen, consistent with an acute bronchopneumonia.

Spleen (Slide 1) – No significant pathological changes.

Kidney (Slide 2) – Numerous cortical abcesses are identified

Liver (Slide 3) – Necrosis is identified and confined to the peri-central hepatocytes. There is relative sparing of the peri-portal hepatocytes. These changes are consistent with centrolobular necrosis.

Brain (Slide 4) – There are changes consistent with anoxic brain injury and ischemia.

Heart (Slides 5, 6, 7) – Focal areas of granulomatous inflammation with calcifications are seen. There is focal sub-endocardial myocytolysis and necrosis. Special stains (periodic acid-Schiff, Gomori methenamine silver and Ziehl-Neelsen) are negative.

ACLU Detainee DeathII ARMY MEDCOM 782

FINAL AUTOPSY DIAGNOSES:

I. Blast and blast fragmentation injuries
   - A. Multiple superficial and deep penetrating blast fragmentation injuries
   - B. Multiple lacerations of the small and large bowel
   - C. Clotted blood and stool is identified in the left lower quadrant of the abdomen
   - D. Lacerations of the spleen
   - E. Lacerations of the liver

II. Other findings:
   - A. Anoxic brain injury
   - B. Acute bronchopneumonia
   - C. Acute pyelonephritis with abcess formation
   - D. Changes consistent with peritonitis
   - E. Centrolobular necrosis of the liver
   - F. Granulomatous myocarditis
   - G. Serosanguineous fluid is identified in both chest cavities and the abdomen
   - H. Multiple adhesions are identified in both chest cavities and the abdomen

III. Medical therapy: As described above

IV. Postmortem changes: As described above

V. Identifying marks: None

VI. Toxicology (AFIP):
   - A. VOLATILES: No ethanol is detected in the blood and vitreous fluid. Acetone is detected in the blood (11 mg/dL) and vitreous fluid (14 mg/dL). Trace amounts of 2-Propanol are detected in the blood and vitreous fluid.
   - B. DRUGS: No screened drugs of abuse or medications are detected in the blood.
   - C. CARBON MONOXIDE: The carboxyhemoglobin saturation in the blood was less than 1%.
   - D. CYANIDE: No cyanide is detected in the blood.

ACLU Detainee DeathII ARMY MEDCOM 783

(REMOVE, REVERSE AND RE-INSERT CARBONS BEFORE COMPLETING THIS SIDE)

DISPOSITION OF REMAINS

NAME OF MORTICIAN PREPARING REMAINS	GRADE	LICENSE NUMBER AND STATE	OTHER

INSTALLATION OR ADDRESS	DATE	SIGNATURE
(b)(6)		

NAME OF CEMETERY OR CREMATORY	LOCATION OF CEMETERY OR CREMATORY

TYPE OF DISPOSITION	DATE OF DISPOSITION

REGISTRATION OF VITAL STATISTICS

REGISTRY (Town and Country)	DATE REGISTERED	FILE NUMBER	
		STATE	OTHER

NAME OF FUNERAL DIRECTOR	ADDRESS

SIGNATURE OF AUTHORIZED INDIVIDUAL

DD FORM 2064, APR 1977 (BACK) *USAPA V1.00*

ACLU Detainee DeathII ARMY MEDCOM 784

ARMED FORCES INSTITUTE OF PATHOLOGY
Office of the Armed Forces Medical Examiner
1413 Research Blvd., Bldg. 102
Rockville, MD 20850
1-301-319-0000
(FAX 1-301-319-0635)

FINAL AUTOPSY REPORT

Name: AL-ISAWI, Mohammed Ajimi
ISN: (b)(6)
Date of Birth: (b)(6) 1976 (31 years)
Date of Death (b)(6) 2007
Date of Autopsy: 26 AUG 2007, 0900 hours
Date of Report: 04 SEP 2007

Autopsy No.: (b)(6)
AFIP No.: (b)(6)
Rank: Iraqi Detainee
Place of Death: Camp Bucca, Iraq
Place of Autopsy: Dover Port Mortuary
Dover AFB, Dover, DE

Circumstances of Death:
Preliminary investigation revealed that a detainee was murdered by other detainees, members of the (b)(6) and buried in a grave inside the detention facility compound. A subsequent search revealed the human remains suspected to be that of (b)(6) He was allegedly sentenced to death by the (b)(6) for speaking against the compound leadership (detainees' leadership).

Authorization for Autopsy: Office of the Armed Forces Medical Examiner, IAW 10 USC 1471

Identification:
Detainee (b)(6) is identified by transportation documents and the accompanied CID Investigation Report. Fingerprints, dental radiographs and a sample for DNA identification are obtained on 26 Aug 2007.

CAUSE OF DEATH:
Multiple Injuries

MANNER OF DEATH:
Homicide

ACLU Detainee DeathII ARMY MEDCOM 785

EXTERNAL EXAMINATION

The body is that of a well-developed, well-nourished Caucasian male, clad in a yellow shirt, yellow pants and yellow shorts. Postmortem adipocere changes are noted. A towel is tied around the neck. The legs are loosely tied by a black thin rope. The hands are loosely entangled/tied with a yellow draw string made from the same material as the clothing. The body weighs 79 pounds and is approximately 71" in height. The age of the decedent can not be definitely determined but appears to be of a middle aged man.

The scalp hair is black. The scalp hair is focally disappeared and small scattered patches of hair are noted, due to postmortem changes. Patches of a mustache hair and a beard are noted. The eyelids are unremarkable with no apparent trauma. The eye globes are protruding and collapsed, with no apparent trauma. The irides are pale and grayish. The corneae are whitish and cloudy. The sclerae are white with no apparent hemorrhage or petechiae. The external auditory canals, external nares and oral cavity are free of foreign material or apparent trauma. The nasal skeleton is palpably intact. The tongue is unremarkable with no significant trauma or evidence of sharp force injuries. The lips are unremarkable with no apparent injury. The teeth are natural and are unremarkable.

The neck is surrounded by a towel with a knot on the left side. Focal area of skin discoloration (possible contusion) is noted on the left.

The chest is unremarkable. No injury of the ribs or sternum is evident externally. The abdomen is unremarkable with no evidence of major surgical scars or sharp force trauma. The posterior torso reveals contusions on the back of the chest and upper abdomen. The external genitalia are deformed and reveal extensive postmortem adipocere precluding proper examination. The torso reveals no evidence of sharp force injuries.

The extremities reveal presence of contusions and deformities of the upper extremities at the wrist joints, and fracture of both legs. The left leg is separated/amputated from the proximal leg. The right leg is partially amputated; the distal leg is attached to the proximal leg by thin stripes of skin and subcutaneous tissue. No evidence of sharp force trauma is identified.

No tattoos, major surgical or characteristic scars or other identifying marks are noted.

ACLU Detainee DeathII ARMY MEDCOM 786

EVIDENCE OF INJURY

Multiple injuries are noted of the neck, torso and extremities and are described below. No evidence of trauma to the eyes or the tongue and no evidence of sharp force injuries are noted.

A. Injuries of the Head:
No evidence of blunt or sharp force trauma to the head. No Subgaleal hemorrhage is seen. No skull fractures or evidence of intracranial injury or hemorrhage.

B. Injuries of the Neck:

1. Ligature Strangulation:
A wide ligature furrow is noted around the neck with a knot impression on the left side of the neck. Examination of the subcutaneous tissue and the muscles of the neck reveal no hemorrhage under the ligature furrow, except focally on the left side. No thyroid cartilage or hyoid bone fractures are noted. An area of localized hemorrhage is noted on the back of the neck, left of the posterior midline (left of the spinal processes of the cervical vertebrae C4-C7). (See below)

2. Neck Trauma:
External examination of the neck reveals abnormal hypermobility. Further dissection of the neck reveals focal areas of hemorrhage in the muscles of the neck, mainly on the left side, anteriorly and posteriorly. Removal of the neck organs reveals underlying hemorrhage of the cervical vertebrae C4-C7, under the anterior ligament, left of the midline. The anterior part of the lower cervical vertebrae is removed to document the presence of hemorrhage. The vertebral segment is photographed for documentation, stored in formalin, and retained by OAFME. No gross evidence of fracture is noted. The hemorrhage is consistent with abnormal neck manipulation by hyperflexion or hyperextension.

C. Blunt Force Trauma to the Torso:
External examination of the torso reveals suspected contusions on the left shoulder, upper left chest and the back, more prominent on the left side of the posterior midline. Reflection of the skin and subcutaneous tissue reveals no evidence of trauma to the left shoulder or chest. Examination of the back reveals areas of intramuscular hemorrhages on both sides of the thoracic spine, more prominent on the left side. Amount of hemorrhage is considerable though it can not be definitely determined due to post mortem changes. The hemorrhage is also noted in the intercostal spaces of the chest cavity. No evidence of lung injury, rib fractures or compromise of the parietal pleura and chest cavity.

D. Blunt Force Trauma to the Extremities:
Examination of the upper extremities reveals deformity of both wrists without fractures. No hemorrhage is noted of the wrist joints. Examination of the subcutaneous tissue and

ACLU Detainee DeathII ARMY MEDCOM 787

muscles reveals an area of hemorrhage on the posterior left arm. No associated fracture is noted.
Examination of the lower extremities reveals areas of contusions on the anterior proximal thighs. No femoral fractures are noted. Examination of the legs reveals bilateral comminuted fractures of the tibia and fibula on both sides. The fractures reveal no surrounding hemorrhage, suggestive of being the result of postmortem trauma. The left leg is completely amputated from the proximal leg. The right leg is essentially amputated, and is only attached to its proximal part by a stripe of skin and subcutaneous soft tissue.

INTERNAL EXAMINATION

BODY CAVITIES:

The body is opened by the usual thoraco-abdominal incision and the chest plate is removed. No adhesions or abnormal collections of fluid are present in any of the body cavities. All body organs are present in the normal anatomical position. The lungs and heart are collapsed. There is no internal evidence of blunt force or penetrating injury to the thoraco-abdominal region. No abnormal collection of blood or fluid is noted in the body cavities.

HEAD: (CENTRAL NERVOUS SYSTEM)

The scalp is reflected. No evidence of trauma is noted. The calvarium of the skull is removed. The dura mater and falx cerebri are intact. There is no epidural or subdural hemorrhage present. The leptomeninges are thin and delicate. The cerebral parenchyma reveals extensive postmortem decomposition precluding proper examination of the intracranial contents. No trauma or hemorrhage is noted. The brain weighs 880 grams.

NECK:

Examination and dissection of the soft tissues of the neck, layer-by-layer, reveal abnormal mobility and focal neck trauma. The thyroid cartilage and hyoid bone are intact. See "Evidence of Injury" above".

CARDIOVASCULAR SYSTEM:

The pericardium is intact. The pericardial sac is free of fluid and adhesions. The coronary arteries arise normally, follow the usual distribution and are patent, without evidence of atherosclerosis or thrombosis. The chambers and valves exhibit the usual size-position relationship and are unremarkable. The myocardium is pale brown and reveal marked postmortem changes. The atrial and ventricular septa are intact. The aorta and its major branches arise normally, follow the usual course and are unremarkable without significant atherosclerosis and other abnormality. The venae cavae and their major tributaries return to the heart in the usual distribution and are free of thrombi. The heart weighs 80 grams.

ACLU Detainee DeathII ARMY MEDCOM 788

RESPIRATORY SYSTEM:
The upper airway is clear of debris and foreign material; the mucosal surfaces are unremarkable except for postmortem changes. The pleural surfaces are unremarkable bilaterally. The pulmonary parenchyma is grey and reveals no focal lesions. The pulmonary arteries are normally developed, patent and without thrombus or embolus. The right and left lung weigh 70 grams and 60 grams, respectively.

LIVER & BILIARY SYSTEM:
The hepatic capsule is smooth and intact, covering dark brown parenchyma with no apparent focal lesions. The gallbladder is intact and contains no bile; the mucosa is unremarkable. The extrahepatic biliary tree is without evidence of calculi. The liver weighs 390 grams.

ALIMENTARY TRACT:
The tongue exhibits no evidence of injury, except a small contusion on the right side. No evidence of significant injury or sharp force trauma. The esophagus is lined by gray-white mucosa. The gastric mucosa is autolysed with thin wall and no rugal folds. The lumen contains a black pasty material submitted for toxicology. The small and large bowel is unremarkable. The pancreas is autolysed. The appendix is present and unremarkable.

GENITOURINARY SYSTEM:
The renal capsules are smooth and thin and strip with ease from the underlying renal smooth brown cortical surfaces. The cortices are delineated from the medullary pyramids, and unremarkable. The calyces, pelves and ureters are unremarkable. The urinary bladder mucosa is unremarkable and contains no urine. The right and left kidneys weigh 20 and 30 grams, respectively. The external genitalia are those of an adult male, but could not be properly examined secondary to the marked postmortem changes. The testes are grossly unremarkable.

RETICULOENDOTHELIAL SYSTEM:
The spleen has a smooth, intact capsule covering pasty purple parenchyma; and grossly unremarkable. No enlarged lymph nodes are seen. The spleen weighs 20 grams.

ENDOCRINE SYSTEM:
The pituitary, thyroid and adrenal glands are grossly unremarkable except for the prominent postmortem changes.

MUSCULOSKELETAL SYSTEM:
Muscle development is normal. No non-traumatic bone or joint abnormalities are noted. See "Evidence of Injury".

ACLU Detainee DeathII ARMY MEDCOM 789

EVIDENCE COLLECTION

The deceased clothing, rope and a sample of muscle tissue are collected during autopsy and submitted as evidence to Special Agent (b)(6) CID, who attended the autopsy.

IDENTIFYING MARKS

No tattoos, major surgical scars or other identifying marks are noted.

NATURAL DISEASES

No evidence of natural diseases identified during the autopsy examination.

MEDICAL INTERVENTION

None.

POSTMORTEM CHANGES

Adipocere formation is noted of the skin and partially in the internal organs. Atelectasis, shrinkage and postmortem changes are noted of the internal organs.

TOXICOLOGY

A. Carbon Monoxide: Analysis not performed. No specimen was suitable for testing.
B. Cyanide: Analysis not performed. No specimen was suitable for testing.
C. Volatiles:
   - Liver: Acetaldehyde, trace; ethanol, 32 mg/dL, acetone, none found; 2-propanol, 9 mg/dL; 1-propanol, 5 mg/dL
   - Muscle: Acetaldehyde, none found; ethanol, 26 mg/dL, acetone, trace; 2-propanol, 11 mg/dL; 1-propanol, 5 mg/dL
D. Screened drugs of abuse and medications:

ADDITIONAL PROCEDURES

- Documentary photographs are taken by an OAFME photographer.
- Full body radiographs and computerized body scans are obtained.
- Specimens retained for toxicological and/or DNA identification are: Gastric contents, and tissue samples from liver, lung, kidney, spleen, brain, psoas and heart muscles, and adipose tissue.
- Representative sections of organs are retained in formalin for microscopic examination if needed in the future.
- Clothing and evidence are released to SA (b)(6) CID.

ACLU Detainee DeathII ARMY MEDCOM 790

FINAL AUTOPSY DIAGNOSIS

I. Multiple Injuries:

a. Injuries of the Head:
- None. No evidence of blunt or sharp force trauma to the head.

b. Injuries of the Neck:

1. Ligature Strangulation:
- A wide ligature furrow around the neck with a knot impression on the left side of the neck.
- Hemorrhage under the ligature furrow, focally on the left side.
- No thyroid cartilage or hyoid bone fractures are noted.
- Localized hemorrhage, back of the neck, left side.

2. Neck Trauma:
- Abnormal hypermobility.
- Focal areas of hemorrhage in the muscles of the neck, left side, anteriorly and posteriorly.
- Hemorrhage around cervical vertebrae C4-C7, under the anterior ligament, left of the midline, consistent with abnormal neck manipulation by hyperflexion or hyperextension.

c. Blunt Force Trauma to the Torso:
- Contusions on the posterior torso, more prominent on the left side
- Hemorrhage of intercostal spaces of the chest cavity, more left.

d. Blunt Force Trauma to the Extremities:
- Deformity of both wrists without fractures. No hemorrhage is noted.
- Contusion posterior left arm, with no associated fractures.
- Contusions on the anterior proximal thighs. No femoral fractures are noted.
- Bilateral comminuted fractures of the tibia and fibula on both sides, postmortem.
- Amputation of the left leg and partial amputation of the right leg (postmortem).

II. Toxicology: Detected ethanol and its metabolites is consistent with postmortem changes. Negative for screened medications and drugs of abuse.

III. Evidence: The deceased clothing, rope and a sample of muscle tissue are collected during autopsy and submitted as evidence to Special Agent (b)(6) CID.

ACLU Detainee DeathII ARMY MEDCOM 791

OPINION

The remains of believed to be (BTB) (b)(6) an Iraqi detainee reveal injuries consistent with strangulations, abnormal neck manipulations (Hyperextension / hyperflextion), and blunt force trauma to the back. There is no evidence of sharp force trauma, or trauma to the eyes and tongue. Toxicological studies for ethanol are consistent with postmortem changes/artifacts. No screened medications and drugs of abuse are detected. The feet were tied with rope and he was buried between two tents in the detention facility compound. Manner of death is "Homicide".

(b)(6)

(b)(6) **Medical Examiner**

ACLU Detainee DeathII ARMY MEDCOM 792

CERTIFICATE OF DEATH *(OVERSEAS)*
Acte dé décès (D'Outre-Mer)

NAME OF DECEASED *(Last, First, Middle)* Nom du décédé (Nom et prénoms)	GRADE Grade	BRANCH OF SERVICE Arme	SOCIAL SECURITY NUMBER Numéro de l'Assurance Social
BTB Al-Isawi, Mohammad, Ajimi		Civilian	(b)(6)

ORGANIZATION Organisation	NATION *(e.g. United States)* Pays	DATE OF BIRTH Date de naissance	SEX Sexe
(b)(6)	Iraq		[X] MALE [ ] FEMALE

RACE Race		MARITAL STATUS État Civil			RELIGION Culte		
[X]	CAUCASOID Caucasique	[ ]	SINGLE Célibataire	[ ] DIVORCED Divorcé	[ ]	PROTESTANT Protestant	[X] OTHER (Specify) Autre (Spécifier)
[ ]	NEGROID Negroide	[ ]	MARRIED Marié	[ ] SEPARATED Séparé	[ ]	CATHOLIC Catholique	
[ ]	OTHER (Specify) Autre (Spécifier)	[ ]	WIDOWED Veuf		[ ]	JEWISH Juif	

NAME OF NEXT OF KIN Nom du plus proche parent	RELATIONSHIP TO DECEASED Parenté du décédé avec le sus
STREET ADDRESS Domicilé à (Rue)	CITY OR TOWN OR STATE *(Include ZIP Code)* Ville (Code postal compris)

MEDICAL STATEMENT Déclaration médicale

	CAUSE OF DEATH (Enter only one cause per line) Cause du décès (N'indiquer qu'une cause par ligne)	INTERVAL BETWEEN ONSET AND DEATH Intervalle entre l'attaque et le décès
DISEASE OR CONDITON DIRECTLY LEADING TO DEATH [1] Maladie ou condition directement responsable de la mort.	Multiple injuries	
ANTECEDENT CAUSES Symptômes précurseurs de la mort. MORBID CONDITION, IF ANY, LEADING TO PRIMARY CAUSE Condition morbide, s'il y a lieu, menant à la cause primaire		
UNDERLYING CAUSE, IF ANY, GIVING RISE TO PRIMARY CAUSE Condition morbide, s'il y a lieu, menant à la cause primaire		
OTHER SIGNIFICANT CONDITIONS [2] Autres conditions significatives [2]		

MODE OF DEATH Condition de décès	AUTOPSY PERFORMED Autopsie effectuée [X] YES Oui [ ] NO Non	CIRCUMSTANCES SURROUNDING DEATH DUE TO EXTERNAL CAUSES Circonstances de la mort suscitées par des causes extérieures
[ ] NATURAL Mort naturelle	MAJOR FINDINGS OF AUTOPSY Conclusions principales de l'autopsie	
[ ] ACCIDENT Mort accidentelle		
[ ] SUICIDE Suicide	NAME OF PATHOLOGIST Nom du pathologiste (b)(6)	
[X] HOMICIDE Homicide	SIGNATURE Sig (b)(6) DATE Date 26 August 2007	AVIATION ACCIDENT Accident à Avion [ ] YES Oui [X] NO Non

DATE OF DEATH *(day, month, year)* Date de décès (le jour, le mois, l'année)	PLACE OF DEATH Iraq
(b)(6) 2007	

I HAVE VIEWED THE REMAINS OF THE DECEASED AND DEATH OCCURRED AT THE TIME INDICATED AND FROM THE CAUSES AS STATED ABOVE
J'ai examiné les restes mortels du dé funtet je conclus que le décès est survenu à l'heure indiquée et à. la suite des causes énumérées ci-dessus.

NAME OF MEDICAL OFFICER Nom du médicin militaire ou du médicin sanitaire	TITLE OR DEGREE Titre ou diplômé
(b)(6)	Medical Examiner

GRADE Grade	INSTALLATION OR ADDRESS Installation ou adresse
(b)(6)	Dover AFB, Dover DE
DATE Date 9/13/2007	SIGNATURE Signature (b)(6)

[1] State disease, injury or complication which caused death, but not mode of dying such as heart failure,
[2] State conditions contributing to the death, but not related to the disease or condition causing death
[1] Préciser la nature de la maladie, de la blessure ou de la complication qui a contribué à la mort, mais non la manière de mourir, telle qu 'un arrêt du coeur, etc
[2] Préciser la condition qui a contribué à la mort, mais n'ayant aucun rapport avec la maladie ou à la condition qui a provoqué la mort

DD FORM 1 APR 77 **2064** REPLACES DA FORM 3565, 1 JAN 72 AND DA FORM 3565-R(PAS), 26 SEP 75, WHICH ARE OBSOLETE.

ACLU Detainee DeathII ARMY MEDCOM 793

(REMOVE, REVERSE AND RE-INSERT CARBONS BEFORE COMPLETING THIS SIDE)

DISPOSITON OF REMAINS

NAME OF MORTICIAN PREPARING REMAINS	GRADE	LICENSE NUMBER AND STATE	OTHER

INSTALLATION OR ADDRESS	DATE	SIGNATURE
(b)(6)		

NAME OF CEMETERY OR CREMATORY	LOCATION OF CEMETERY OR CREMATORY

TYPE OF DISPOSTION	DATE OF DISPOSTION

REGISTRATION OF VITAL STATISTICS

REGISTRY *(Town and Country)*	DATE REGISTERED	FILE NUMBER	
		STATE	OTHER

NAME OF FUNERAL DIRECTOR	ADDRESS

SIGNATURE OF AUTHORIZED INDIVIDUAL

DD FORM 2064, APR 1977 (BACK) *USAPA V1.00*

ACLU Detainee DeathII ARMY MEDCOM 794

ARMED FORCES INSTITUTE OF PATHOLOGY
Office of the Armed Forces Medical Examiner
1413 Research Blvd., Bldg. 102
Rockville, MD 20850
301-319-0000

FINAL AUTOPSY REPORT

Name: **BTB** Ahmed, Emad Wasmee
ISN: (b)(6)
Date of Birth (b)(6) 1989 (estimated)
Date of Death (b)(6) 2007
Date/Time of Autopsy: 12 AUG 2007 @ 0900
Date of Report: 27 SEP 2007

Autopsy No.: (b)(6)
AFIP No.: (b)(6)
Grade: Civilian (Detainee)
Place of Death: Iraq
Place of Autopsy: Port Mortuary, Dover AFB, Dover, DE

Circumstances of Death: This 17 year-old civilian was being detained at the Theater Internment Facility at Camp Cropper, Iraq when, as reported, compound guards observed two unknown detainees carrying the body of the deceased in a blanket, placing him on the ground, and then running from sight.

Authorization for Autopsy: Office of the Armed Forces Medical Examiner, IAW 10 USC 1471.

Identification: Presumptive identification based on review of all papers in case file. Post-mortem fingerprint and dental examinations conducted. A suitable specimen for DNA analysis is obtained.

CAUSE OF DEATH: **Multiple blunt force injuries**

MANNER OF DEATH: **Homicide**

ACLU Detainee DeathII ARMY MEDCOM 795

EXTERNAL EXAMINATION

The body is that of a well-developed, well-nourished male. The body weighs 120 pounds, is 65 inches in length and appears compatible with the reported age of 17 years. The body is cold. Rigor is resolved in all extremities. Lividity is obscured by diffuse contusions of the back (see "Evidence of Injury"). There is green discoloration of the skin of the abdomen.

Injuries of the head, torso and extremities are described in "Evidence of Injury". The head is normocephalic, and the scalp hair is black. Facial hair consists of black mustache and beard. The eyes are sunken. The irides are brown. The corneae are cloudy. The conjunctivae are pale. The sclerae are white. The external auditory canals, external nares and oral cavity are free of foreign material and abnormal secretions. The earlobes are not pierced. The nasal skeleton and maxilla are palpably intact. The teeth are natural and in fair condition with both deciduous and permanent teeth.

The external genitalia are those of an adult circumcised male. The anus is unremarkable.

The extremities are symmetric. The fingernails are intact. There is a 1/2-inch scar on the left knee. There is a 1/2-inch healing abrasion on the right medial ankle. The soles of the feet are callous.

CLOTHING AND PERSONAL EFFECTS

The body is clad in a white t-shirt, orange trousers (with defect in the crotch and defect of the left buttocks), white boxers and a green personal effects bag around the right wrist. There are various letters, numbers, and symbols written on the right pant leg of the orange trousers. Within the personal effects bag are three pieces of paper.

MEDICAL INTERVENTION

None.

RADIOGRAPHS

A complete set of postmortem radiographs is obtained and demonstrates no skeletal fractures.

EVIDENCE OF INJURY

I. Blunt force injuries:

A. Head and neck:

On the left side of the forehead is a 1-1/2 x 1-1/2-inch contusion. On the right side of the face lateral to the right eyebrow is a 1/2 x 1/2-inch contusion. There are two, 1/2 x 1/2-inch abrasions on the bridge of the nose. On the tip of the nose is a 1/4-inch abrasion. A 1/2 x 1/2-inch contusion is on the left cheek. On the mucosal surface of the left lower lip is a 1/2 x 1/2-inch abrasion. The helix of the left ear has a 1/4 x 1/4-inch contusion.

ACLU Detainee DeathII ARMY MEDCOM 796

Internal examination reveals a 3 x 2-inch contusion of the left temporalis muscle. There is a 3 x 3-inch hematoma of the right lateral strap muscles. There is superficial hemorrhage of the posterior strap muscles of the neck. There is a bilateral, parasagittal subdural hemorrhage (approximately 10 ml). On the left temporal lobe of the brain is a focal 2 x 1-inch subarachnoid hemorrhage.

B. TORSO:

On the skin over the right clavicle is a 1-1/2 x 1-1/2-inch contusion. On the right chest medial to the right nipple is a 1 x 1-inch contusion. On the lateral right torso, inferior to the right nipple, is a confluent 6 x 5-inch contusion that extends to the anterior midline. On the left side of the anterior torso, inferior to the left nipple, is a 2 x 1-inch contusion. On the right lower quadrant of the abdomen is a 3 x 2-inch contusion with a centrally located 1/2 x 1/2-inch abrasion. On the skin over the right anterior iliac crest is a 2 x 1-inch contusion. A 1 x1-inch contusion is on the skin over the left anterior iliac crest. There are diffuse contusions over the entire back (17 x 15 inches). There is a 1/4 x 1/4-inch abrasion of the right upper back. On the skin over the left scapula is a 1/4 x 1/4-inch abrasion. There are two 1 x 1-inch abrasions of the lower right back. There is a 4 x 1-inch abrasion of the middle of the lower back.

Internal examination reveals a 2 x 2-inch contusion of the posterior left eighth intercostal muscles. Superficial skin incisions of the back reveal a superficial hematoma that involves the entire back (approximately 300 milliliters of blood).

C. EXTREMITIES:

There is a 2 x 1-inch contusion of the anterior right arm. There is an 8 x 4-inch contusion of the posterior right arm. There are three abrasions of the right elbow ranging in size from 1/4-inch to 3/4-inch, in maximum dimension. On the posterior right forearm are two contusions that are 2 x 1-inch and 3 x 2 inches, respectively. There is a 3 x 1-inch contusion of the anterior right forearm. On the palm of the right hand, over the thenar eminence, is a 2 x 1-inch contusion. There are two 1 x 1-inch contusions of the back of the right hand. There is a 1/2 x 1/2-inch contusion of the right index finger and right middle finger.

On the posterior left arm, extending to the medial left forearm, is a near circumferential contusion that is 11 x 11 inches. There is a 1 x 1/2-inch abrasion of the left elbow. On the posterior left forearm are a 2 x 2-inch contusion and a 1/2 x 1/2-inch contusion. There is a 2 x 1-inch contusion of the palmar surface of the left hand. A 2 x 1/2-inch contusion is on the posterior aspect of the left middle finger. A 2 x 1/2-inch contusion is on the posterior aspect of the left small finger.

There are diffuse contusions of the posterior right thigh and buttocks (15 x 10 inches) extending to the anterior lateral aspect of the right thigh. There are two 1/2-inch circular contusions of the anterior right thigh with areas of

ACLU Detainee DeathII ARMY MEDCOM 797

central pallor (3/8-inch in diameter). On the anterior-medial right thigh are two 1/2 x 1/2-inch contusions. There is a 1 x 1-inch contusion of the right knee. On the posterior right leg is a 5 x 4-inch contusion.

On the left buttock is a 7 x 6-inch contusion. On the posterior left thigh are diffuse contusions (9 x 8 inches). On the anterior left thigh are multiple (4) contusions ranging in size from 1 x 1-inch to 7 x 3 inches. On the anterior left leg is a 1/4 x 1/4-inch contusion. On the posterior left leg is a 5 x 3-inch contusion.

Superficial skin incisions of the posterior aspect of the extremities reveal a hematoma of the posterior right arm (approximately 50 milliliters), hematoma of the posterior right thigh (approximately 50 milliliters), and a hematoma of the posterior left thigh (approximately 50 milliliters).

INTERNAL EXAMINATION

BODY CAVITIES:

The body is opened by the usual thoraco-abdominal incision and the chest plate is removed. The ribs, sternum, and vertebral bodies are visibly and palpably intact. No adhesions or abnormal collections of fluid are present in any of the body cavities. All body organs are present in normal anatomical position.

HEAD AND CENTRAL NERVOUS SYSTEM

See "Evidence of Injury". The brain weighs 1300 grams. The leptomeninges are thin and delicate. The cerebral hemispheres are symmetrical. The structures at the base of the brain, including cranial nerves and blood vessels are intact. Coronal and transverse sections through the cerebral hemispheres and brain stem and cerebellum reveal no non-traumatic lesions. The atlanto-occipital joint is stable.

NECK:

See "Evidence of Injury". The thyroid cartilage and hyoid bone are intact. The larynx is lined by intact white mucosa. The tongue is free of bite marks, hemorrhage, or other injuries. Incision and dissection of the posterior neck demonstrates injuries described above.

CARDIOVASCULAR SYSTEM:

The 230 gram heart is contained in an intact pericardial sac. The epicardial surface is smooth, with minimal fat investment. The coronary arteries are present in a normal distribution and are widely patent. The myocardium is homogenous, red-brown, and firm. The valve leaflets are thin and mobile. The walls of the left ventricle, interventricular septum, and right ventricle are 0.8, 0.9, and 0.3-cm thick, respectively. The right ventricle is dilated. The endocardium is smooth and glistening. The aorta gives rise to three intact and patent arch vessels. The renal and mesenteric vessels are unremarkable.

RESPIRATORY SYSTEM:

The upper airway is clear of debris and foreign material: the mucosal surfaces are smooth, yellow-tan and unremarkable. The pleural surfaces are smooth, glistening and

ACLU Detainee DeathII ARMY MEDCOM 798

unremarkable bilaterally. The pulmonary parenchyma is congested, exuding slight to moderate amounts of blood and frothy fluid; no focal lesions are noted. The pulmonary arteries are normally developed, patent and without thrombus or embolus. The right lung weighs 380 grams; the left 350 grams.

HEPATOBILIARY SYSTEM:
The 180 gram liver has an intact smooth capsule covering dark red-brown, moderately congested tan-brown parenchyma with no focal lesions noted. The gallbladder contains less than 5 milliliters of green-brown, mucoid bile; the mucosa is velvety and unremarkable. The extrahepatic biliary tree is patent, without evidence of calculi.

GASTROINTESTINAL SYSTEM:
The esophagus is lined by gray-white, smooth mucosa. The gastric mucosa is arranged in the usual rugal folds and the lumen contains 350 milliliters of brown fluid and rice particles. The small and large bowels are unremarkable. The pancreas has a normal pink-tan lobulated appearance and the ducts are clear. The appendix is present.

GENITOURINARY SYSTEM:
The right kidney weighs 70 grams; the left kidney weighs 50 grams. The renal capsules are smooth and thin, semi-transparent and stripped with ease from the underlying smooth, red-brown cortical surface. The cortex is sharply delineated from the medullary pyramids, which are red-purple to tan and unremarkable. The calyces, pelves and ureters are unremarkable. White bladder mucosa overlies an intact bladder wall. The bladder contains approximately 10 milliliters of blood-tinged urine. The testes, prostate gland and seminal vesicles are without note.

LYMPHORETICULAR SYSTEM:
The 50 gram spleen has a smooth, intact capsule covering red-purple, moderately firm parenchyma; the lymphoid follicles are unremarkable. Lymph nodes in the hilar, periaortic and iliac regions are not enlarged.

ENDOCRINE SYSTEM:
The thyroid gland is symmetric and red-brown, without cystic or nodular change. The right and left adrenal glands are symmetric, with bright yellow cortices and red-brown medullae. No masses or areas of hemorrhage are identified.

MUSCULOSKELETAL SYSTEM:
Muscle development is normal. No bone or joint abnormalities are identified.

ADDITIONAL PROCEDURES

1. Specimens retained for toxicology testing and/or DNA identification are: Blood, bile, urine, liver, lung, kidney, spleen, brain, psoas muscle, myocardium, adipose tissue and gastric contents.
2. The dissected organs are forwarded with the body.
3. Selected portions of organs are retained in formalin.
4. Personal effects are released to the appropriate mortuary operations representatives.
5. Recovered evidence: Nails, retained by OAFME.

ACLU Detainee DeathII ARMY MEDCOM 799

FINAL AUTOPSY DIAGNOSES

I. **Multiple blunt force injuries:**
   A. Head and neck:
      1. Parasagittal subdural hemorrhage
      2. Focal subarachnoid hemorrhage
      3. Hemorrhage of the left temporalis muscle
      4. Hemorrhage of the right lateral and posterior strap muscles
      5. Multiple contusions and abrasion
   B. Torso:
      1. Multiple diffuse contusions and abrasions
      2. Soft tissue hematoma of the back
   C. Extremities:
      1. Multiple diffuse contusions and abrasions
      2. Soft tissue hematomas of the posterior right arm, posterior right thigh, and posterior left thigh

II. **Evidence of medical intervention:** None

III. **Identifying marks:** None

IV. **Post-mortem changes:**
   A. Rigor has resolved in the upper and lower extremities
   B. Green discoloration of the abdomen
   C. Cloudy cornea

V. **Natural disease:** None identified within the limits of the examination

VI. **Toxicology (AFIP):**
   A. VOLATILES: No ethanol detected in the blood and vitreous fluid
   B. DRUGS: No screened drugs of abuse/medications detected in the urine
   C. CARBON MONOXIDE: The carboxyhemoglobin saturation in the blood was less than 1%[1]
   D. CYANIDE: There was no cyanide detected in the blood

[1] Carboxyhemoglobin saturations of 0-3% are expected for non-smokers and 3-10% for smokers.

ACLU Detainee DeathII ARMY MEDCOM 800

OPINION

This 17 year-old male, **BTB** (b)(6) died of multiple blunt force injuries sustained while being detained at the Theater Internment Facility at Camp Cropper, Iraq. He had multiple confluent contusions of the head, torso, and extremities with associated soft tissue hematomas. In addition, he had focal subarachnoid and subdural hemorrhage of the brain. A possible contributory component of asphyxia cannot be excluded. The toxicology screen was negative. The manner of death is homicide.

(b)(6)

(b)(6) Medical Examiner

ACLU Detainee DeathII ARMY MEDCOM 801

CERTIFICATE OF DEATH *(OVERSEAS)*
Acte de décès (D'Outre-Mer)

NAME OF DECEASED *(Last, First, Middle)* Nom du décédé (Nom et prénoms)	GRADE Grade	BRANCH OF SERVICE Arme	SOCIAL SECURITY NUMBER Numéro de l'Assurance Social
BTB Ahmed, Emad, Wasmee		Civilian	(b)(6)

ORGANIZATION Organisation	NATION *(e.g. United States)* Pays	DATE OF BIRTH Date de naissance	SEX Sexe
	Iraq	(b)(6) 1989	[X] MALE [ ] FEMALE

RACE Race		MARITAL STATUS État Civil			RELIGION Culte		
[X]	CAUCASOID Caucasique	[ ]	SINGLE Célibataire	[ ] DIVORCED Divorcé	[ ]	PROTESTANT Protestant	[X] OTHER (Specify) Autre (Spécifier)
[ ]	NEGROID Negroïde	[ ]	MARRIED Marié	[ ] SEPARATED Séparé	[ ]	CATHOLIC Catholique	
[ ]	OTHER (Specify) Autre (Spécifier)	[ ]	WIDOWED Veuf		[ ]	JEWISH Juif	

NAME OF NEXT OF KIN Nom du plus proche parent	RELATIONSHIP TO DECEASED Parenté du décédé avec le sus
STREET ADDRESS Domicilié à (Rue)	CITY OR TOWN OR STATE *(Include ZIP Code)* Ville (Code postal compris)

MEDICAL STATEMENT Déclaration médicale

CAUSE OF DEATH (Enter only one cause per line) Cause du décès (N'indiquer qu'une cause par ligne)		INTERVAL BETWEEN ONSET AND DEATH Intervalle entre l'attaque et le décès
DISEASE OR CONDITON DIRECTLY LEADING TO DEATH [1] Maladie ou condition directement responsable de la mort.	Multiple blunt force injuries	
ANTECEDENT CAUSES Symptômes précurseurs de la mort. — MORBID CONDITION, IF ANY, LEADING TO PRIMARY CAUSE Condition morbide, s'il y a lieu, menant à la cause primaire		
ANTECEDENT CAUSES Symptômes précurseurs de la mort. — UNDERLYING CAUSE, IF ANY, GIVING RISE TO PRIMARY CAUSE Condition morbide, s'il y a lieu, menant à la cause primaire		
OTHER SIGNIFICANT CONDITIONS [2] Autres conditions significatives [2]		

MODE OF DEATH Condition de décès	AUTOPSY PERFORMED Autopsie effectuée [X] YES Oui [ ] NO Non	CIRCUMSTANCES SURROUNDING DEATH DUE TO EXTERNAL CAUSES Circonstances de la mort suscitées par des causes extérieures
[ ] NATURAL Mort naturelle	MAJOR FINDINGS OF AUTOPSY Conclusions principales de l'autopsie	
[ ] ACCIDENT Mort accidentelle		
[ ] SUICIDE Suicide	NAME OF PATHOLOGIST Nom du pathologiste (b)(6)	
[X] HOMICIDE Homicide	SIGNATURE Signature (b)(6) — DATE Date 12 August 2007	AVIATION ACCIDENT Accident à Avion [ ] YES Oui [X] NO Non

DATE OF DEATH *(day, month, year)* Date de décès (le jour, le mois, l'année)	PLACE OF DEATH Lieu de décès
(b)(6) 2007	Unknown Location Iraq

I HAVE VIEWED THE REMAINS OF THE DECEASED AND DEATH OCCURRED AT THE TIME INDICATED AND FROM THE CAUSES AS STATED ABOVE.
J'ai examiné les restes mortels du dé funt et je conclus que le décès est survenu à l'heure indiquée et à la suite des causes énumérées ci-dessus.

NAME OF MEDICAL OFFICER Nom du médecin militaire ou du médecin sanitaire	TITLE OR DEGREE Titre ou diplôme
(b)(6)	Medical Examiner

GRADE Grade	INSTALLATION OR ADDRESS Installation ou adresse
(b)(6)	Dover AFB, Dover DE
DATE Date 8/12/2007	SIGNATURE Signature (b)(6)

[1] State disease, injury or complication which caused death, but not mode or dying such as heart failure, etc.
[2] State conditions contributing to the death, but not related to the disease or condition causing death.
[1] Préciser la nature de la maladie, de la blessure ou de la complication qui a contribué à la mort, mais non la manière de mourir, tels qu'un arrêt du coeur, etc.
[2] Préciser la condition qui a contribué à la mort, mais n'ayant aucun rapport avec la maladie ou à la condition qui a provoqué la mort.

DD FORM 1 APR 77 2064 REPLACES DA FORM 3565, 1 JAN 72 AND DA FORM 3565-R(PAS), 26 SEP 75, WHICH ARE OBSOLETE.

(b)(6)

(b)(6)

ACLU Detainee DeathII ARMY MEDCOM 803

(REMOVE, REVERSE AND RE-INSERT CARBONS BEFORE COMPLETING THIS SIDE)

DISPOSITON OF REMAINS

NAME OF MORTICIAN PREPARING REMAINS	GRADE	LICENSE NUMBER AND STATE	OTHER

INSTALLATION OR ADDRESS	DATE	SIGNATURE
(b)(6)		

NAME OF CEMETERY OR CREMATORY	LOCATION OF CEMETERY OR CREMATORY

TYPE OF DISPOSTION	DATE OF DISPOSTION

REGISTRATION OF VITAL STATISTICS

REGISTRY *(Town and County)*	DATE REGISTERED	FILE NUMBER	
		STATE	OTHER

NAME OF FUNERAL DIRECTOR	ADDRESS

SIGNATURE OF AUTHORIZED INDIVIDUAL

DD FORM 2064, APR 1977 (BACK) *USAPA V1.00*

ACLU Detainee DeathII ARMY MEDCOM 804

ARMED FORCES INSTITUTE OF PATHOLOGY
Office of the Armed Forces Medical Examiner
1413 Research Blvd., Bldg. 102
Rockville, MD 20850
301-319-0000

AUTOPSY EXAMINATION REPORT

Name: BTB Kazim, Fayis Halim
SSAN: (b)(6)
Date of Birth (b)(6) 1965
Date of Deat (b)(6) 2007
Date and time of Autopsy: 06 AUG 2007 9:00 AM

Autopsy No.: (b)(6)
AFIP No.: (b)(6)
Rank: Detainee
Place of Death: Iraq
Place of Autopsy: Port Mortuary
Dover AFB, Dover DE

Date of Initial Report: 09 AUG 2007
Date of Final Report: 05 DEC 2007

Circumstances of Death: (b)(6) was being detained pending interrogation when he was reportedly found in his cell unresponsive. He had previously complained of dyspepsia and ranitidine had been prescribed for him.

Authorization for Autopsy: Office of the Armed Forces Medical Examiner, IAW 10 USC 1471

Identification: by means of capture tag and continuous chain of custody

CAUSE OF DEATH: Coronary Thrombosis

MANNER OF DEATH: Natural

ACLU Detainee DeathII ARMY MEDCOM 805

EXTERNAL EXAMINATION

The body is that of a well-developed, well-nourished appearing male, 63-1/4 inches tall, weighing 139 pounds, whose appearance is consistent with the reported age of 42 years. Lividity is posterior. Rigor is resolving. The body is cool to touch.

Black hair is distributed in the usual male pattern. The irides are brown, with a prominent arcus senilis. The pupils are round, 0.3 cm and equal in diameter. The external auditory canals are clear; (b)(6) the ears are otherwise unremarkable. The nares are patent and the lips are atraumatic. The nose and maxillae are palpably stable. A moustache and closely trimmed beard are distributed in the usual pattern. The teeth are natural with evidence of mild to moderate neglect.

The neck is straight, and the trachea is midline and mobile. The chest is symmetric. The abdomen is slightly protuberant. The genitalia are those of a normal adult circumcised male. The testes are descended and free of masses. Pubic hair is present in the usual male distribution. The buttocks and anus are unremarkable.

The upper and lower extremities are symmetric and without clubbing, cyanosis or edema.

CLOTHING AND PERSONAL EFFECTS

The remains are clad in a white gown

EVIDENCE OF INJURY

An old, healing 1 x 1/2 inch abrasion is present on the central forehead. An old, healing 2 x 1/2 inch abrasion is present on the upper back, slightly to the right of the midline. Extremity injuries include a group of old-healing abrasions and contusions clustered over the posterior right elbow, ranging from 1/2 inch up to 3/4 x 1/2 inch. A healing 1/2 inch abrasion is present just above the left elbow. A group of punctate defects surrounded by a 1/2 inch green-blue contusion is present just above and lateral to the right knee.

INTERNAL EXAMINATION

HEAD:
The galeal and subgaleal soft tissues of the scalp are free of injury. The calvarium is intact, as is the dura mater beneath it. The cerebral blood vessels are engorged with blood, but are otherwise unremarkable. Clear cerebrospinal fluid surrounds the 1100 gm brain, which has unremarkable gyri and sulci. Coronal sections demonstrate sharp demarcation between white and grey matter, without hemorrhage or contusive injury. The ventricles are of normal size. The basal ganglia, brainstem, cerebellum, and arterial systems are free of injury or other abnormalities. There are no skull fractures. The atlanto-occipital joint is stable. A posterior neck dissection confirms that the abrasion identified over the posterior back is superficial and remote chronologically.

ACLU Detainee DeathII ARMY MEDCOM 806

NECK:
The anterior strap muscles of the neck are homogenous and red-brown, without hemorrhage. The thyroid cartilage and hyoid are intact. The larynx is lined by intact white mucosa. The thyroid is symmetric and red-brown, without cystic or nodular change. The tongue is free of bite marks, hemorrhage, or other injuries.

BODY CAVITIES:
The ribs, sternum, and vertebral bodies are visibly and palpably intact. There is a small pleural effusion bilaterally (radiographic finding). Multiple adhesions extend from the right lung to the parietal pleural surface. Otherwise, there is no excess fluid is in the pleural, pericardial, or peritoneal cavities. The organs occupy their usual anatomic positions.

RESPIRATORY SYSTEM:
The congested right and left lungs weigh 630 and 490 gm, respectively. The right pleural adhesions have been noted. Intraparenchymal calcifications are identified radiographically, but are not identified on direct inspection. The pulmonary parenchyma is diffusely congested and edematous. No mass lesions or areas of consolidation are grossly evident.

CARDIOVASCULAR SYSTEM:
The 330 gm heart is contained in an intact pericardial sac. The epicardial surface is smooth, with moderate fat investment. Mottling with focal pale color change is present. The coronary arteries are present in a normal distribution, with a right-dominant pattern. On cross sections of the vessels a hemorrhagic occlusive plaque is present in the left anterior descending coronary artery. Calcifications are also evident radiographically in the circumflex and left anterior descending coronary arteries. A tan cut surface with irregular mottling is noted on sections through the myocardium. The valve leaflets are thin and mobile. The walls of the left ventricle, interventricular septum and right ventricles are 0.9, 1.0 and 0.4 cm thick, respectively. The aorta displays atheromatous plaque deposition, with prominent calcified lesions at the level of the iliac bifurcation. There is no evidence of congenital or infectious lesion. The renal and mesenteric vessels are unremarkable.

LIVER & BILIARY SYSTEM:
The 1330 gm liver has an intact, smooth capsule and a sharp anterior border. The parenchyma is tan-brown and congested, with the usual lobular architecture. No mass lesions or other abnormalities are seen. The gallbladder contains approximately 10 cc of green-black bile. There are no stones. The mucosal surface is green and velvety. The extrahepatic biliary tree is patent.

SPLEEN:
The 170 gm spleen has a smooth, intact, red-purple capsule. The parenchyma is maroon and congested, with distinct Malpighian corpuscles.

ACLU Detainee DeathII ARMY MEDCOM 807

PANCREAS:
The pancreas is congested, with the usual lobulated architecture on cut surface. No mass lesions or other abnormalities are seen.

ADRENALS:
The right and left adrenal glands are symmetric, with bright yellow cortices and grey medullae. No masses or areas of hemorrhage are identified.

GENITOURINARY SYSTEM:
The right and left kidneys weigh 90 and 80 gm, respectively. The cut surfaces are red-tan and congested, with uniformly thick cortices and sharp corticomedullary junctions. The pelves are unremarkable and the ureters are normal in course and caliber. White bladder mucosa overlies an intact bladder wall. The urinary bladder contains approximately 80cc of clear amber urine. The prostate is normal in size, with lobular, yellow-tan parenchyma. Brown material is expressed from the ducts; the seminal vesicles are otherwise unremarkable. The testes are free of mass lesions, contusions, or other abnormalities.

GASTROINTESTINAL TRACT:
The esophagus is intact and lined by smooth, grey-white mucosa. The stomach contains approximately 200 cc of partially digested food. The gastric wall is intact. The duodenum, loops of small bowel and colon are unremarkable. The appendix is present.

MUSCULOSKELETAL SYSTEM:
Muscle development is normal. Degenerative changes of the thoracic and lumbar spine are identified radiographically. Otherwise, there are no bone or joint abnormalities noted.

MICROSCOPIC EXAMINATION

Selected portions of organs are retained in formalin, without preparation of histologic slides.

ADDITIONAL PROCEDURES

1. Documentary photographs are taken by OAFME staff photographers.
2. Specimens retained for toxicologic testing and/or DNA identification are: vitreous fluid, blood, bile, gastric contents, urine, brain, myocardium, lung, kidney, spleen, skeletal muscle and adipose tissue.
4. The dissected organs are forwarded with body.
5. Personal effects are released to the appropriate mortuary operations representatives.

ACLU Detainee DeathII ARMY MEDCOM 808

AUTOPSY DIAGNOSES

I. Evidence of Disease
- A. Arcus senilis
- B. Engorgement of the cerebral cortical vessels
- C. Calcification of the left anterior descending coronary artery (radiographic finding and direct examination)
- D. Calcification of the circumflex coronary artery (radiographic finding and direct examination)
- E. Occlusive thrombus superimposed on an atheromatous plaque, left anterior descending coronary artery
- F. Mottling of the myocardium
- G. Calcification of the aortic root (radiographic finding)
- H. Aortic intimal erosion
- I. Calcification of the abdominal aorta at the iliac bifurcation (radiographic finding and direct examination)
- J. Bilateral pulmonary congestion (radiographic finding and direct examination)
- K. Right sided pleural adhesions
- L. No radiographically identifiable trauma
- M. No radiographically identifiable foreign body
- N. No significant extremity injury identified
- O. Scattered small abrasions and contusions
  1. forehead (1), of chronologically remote origin
  2. upper back (1), without significant underlying trauma
  3. posterior right elbow (3)
  4. left elbow (1)
  5. right knee (1)

II. Evidence of Medical Intervention: none noted

III. Natural Disease
- A. Degenerative changes of the thoracic spine (radiographic finding)
- B. Degenerative change of the lumbar spine (radiographic finding)

IV. Identifying Marks:
(b)(6)

V. Toxicology: negative

VI. Post-mortem Changes: no significant change noted

ACLU Detainee DeathII ARMY MEDCOM 809

OPINION

(b)(6) a 42 year-old detainee, died when his left anterior descending coronary artery became occluded by superimposition of a thrombus on a pre-existing atheromatous lesion. The cause of death is therefore coronary thrombosis. The manner of death is natural.

(b)(6)

(b)(6) **Medical Examiner** (b)(6)

ACLU Detainee DeathII ARMY MEDCOM 810

CERTIFICATE OF DEATH *(OVERSEAS)*

Acte dé décès (D'Outre-Mer)

NAME OF DECEASED *(Last, First, Middle)* Nom du décédé (Nom et prénoms)	GRADE Grade	BRANCH OF SERVICE Arme	SOCIAL SECURITY NUMBER Numéro de l'Assurance Social
BTB Kazim, Fayis, Halim		Civilian	(b)(6)
ORGANIZATION Organisation	**NATION** *(e.g. United States)* Pays	**DATE OF BIRTH** Date de naissance	**SEX** Sexe
	Iraq	(b)(6) 1965	[X] MALE [ ] FEMALE

RACE Race		MARITAL STATUS État Civil			RELIGION Culte		
[X]	CAUCASOID Caucasique		SINGLE Célibataire		DIVORCED Divorcé		PROTESTANT Protestant
	NEGROID Negroide		MARRIED Marié		SEPARATED Séparé		CATHOLIC Catholique
	OTHER (Specify) Autre (Spécifier)		WIDOWED Veuf			[X]	JEWISH Juif

OTHER (Specify) Autre (Spécifier)

NAME OF NEXT OF KIN Nom du plus proche parent	RELATIONSHIP TO DECEASED Parenté du décède avec le sus
STREET ADDRESS Domicilé à (Rue)	CITY OR TOWN OR STATE *(Include ZIP Code)* Ville (Code postal compris)

MEDICAL STATEMENT Déclaration médicale

	CAUSE OF DEATH (Enter only one cause per line) Cause du décès (N'indiquer qu'une cause par ligne)	INTERVAL BETWEEN ONSET AND DEATH Intervalle entre l'attaque et le décès
DISEASE OR CONDITON DIRECTLY LEADING TO DEATH [1] Maladie ou condition directement responsable de la mort.	Coronary Thrombosis	
ANTECEDENT CAUSES — MORBID CONDITION, IF ANY, LEADING TO PRIMARY CAUSE Condition morbide, s'il y a lieu, menant à la cause primaire		
Symptômes précurseurs de la mort — UNDERLYING CAUSE, IF ANY, GIVING RISE TO PRIMARY CAUSE Condition morbide, s'il y a lieu, menant à la cause primaire		
OTHER SIGNIFICANT CONDITIONS [2] Autres conditions significatives [2]		

MODE OF DEATH Condition de décès	AUTOPSY PERFORMED Autopsie effectuée [X] YES Oui [ ] NO Non	CIRCUMSTANCES SURROUNDING DEATH DUE TO EXTERNAL CAUSES Circonstances de la mort suscitées par des causes extérieures
[X] NATURAL Mort naturelle	MAJOR FINDINGS OF AUTOPSY Conclusions principales de l'autopsie	
[ ] ACCIDENT Mort accidentelle		
[ ] SUICIDE Suicide	NAME OF PATHOLOGIST Nom du pathologiste (b)(6)	
[ ] HOMICIDE Homicide	SIGNATURE (b)(6) DATE Date 6 August 2007	AVIATION ACCIDENT Accident à Avion [ ] YES Oui [X] NO Non

DATE OF DEATH *(day, month, year)* Date du décès (le jour, le mois, l'année)	PLACE OF DEATH Lieu de décès
(b)(6) 2007	Iraq

I HAVE VIEWED THE REMAINS OF THE DECEASED AND DEATH OCCURRED AT THE TIME INDICATED AND FROM THE CAUSES AS STATED ABOVE.
J'ai examiné les restes mortels du dé funtet je conclus que le décès est survenu à l'heure indiquée et à, la suite des causes énumérées ci-dessus.

NAME OF MEDICAL OFFICER Nom du médicin militaire ou du médicin sanitaire	TITLE OR DEGREE Titre ou diplôme
(b)(6)	Medical Examiner

GRADE Grade	INSTALLATION OR ADDRESS Installation ou adresse
(b)(6)	Dover AFB, Dover DE
DATE Date 8/6/2007	SIGNATURE (b)(6)

[1] State disease, injury or complication which caused death, but not mod
[2] State conditions contributing to the death, but not related to the disease or condition causing death.
[1] Préciser la nature de la maladie, de la blessure ou de la complication qui a contribué à la mort, mais non la manière de mourir, telle qu'un arrêt du coeur, etc
[2] Préciser la condition qui a contribué à la mort, mais n'ayant aucun rapport avec la maladie ou à la condition qui a provoqué la mort

DD FORM 1 APR 77 **2064** REPLACES DA FORM 3565, 1 JAN 72 AND DA FORM 3565-R(PAS), 26 SEP 75, WHICH ARE OBSOLETE.

MEDCOM 0811

ACLU Detainee DeathII ARMY MEDCOM 811

(REMOVE, REVERSE AND RE-INSERT CARBONS BEFORE COMPLETING THIS SIDE)

DISPOSITON OF REMAINS

NAME OF MORTICIAN PREPARING REMAINS	GRADE	LICENSE NUMBER AND STATE	OTHER

INSTALLATION OR ADDRESS	DATE	SIGNATURE

NAME OF CEMETERY OR CREMATORY	LOCATION OF CEMETERY OR CREMATORY

TYPE OF DISPOSTION	DATE OF DISPOSTION

REGISTRATION OF VITAL STATISTICS

REGISTRY *(Town and Country)*	DATE REGISTERED	FILE NUMBER	
		STATE	OTHER

NAME OF FUNERAL DIRECTOR	ADDRESS

SIGNATURE OF AUTHORIZED INDIVIDUAL

DD FORM 2064, APR 1977 (BACK) *USAPA V1.00*

ACLU Detainee DeathII ARMY MEDCOM 812

ARMED FORCES INSTITUTE OF PATHOLOGY
Office of the Armed Forces Medical Examiner
1413 Research Blvd., Bldg. 102
Rockville, MD 20850
301-319-0000

FINAL AUTOPSY REPORT
****AMENDED****

Name: **BTB** Khalid, Muhammad Qusay
ISN (b)(6)
Date of Birth: (b)(6) 1976 (estimated)
Date of Death (b)(6) 2007
Date/Time of Autopsy: 30 JUL 2007 @ 0900 hrs
Date of Report: 30 OCT 2007
Date of Amended Report: 31 MAR 2008

Autopsy No.: (b)(6)
AFIP No. (b)(6)
Grade: Civilian (Detainee)
Place of Death: Iraq
Place of Autopsy: Port Mortuary, Dover AFB, Dover, DE

Circumstances of Death: This 31 year-old civilian was being detained at the Theater Internment Facility (TIF) at Camp Bucca, Iraq when, as reported, he was assaulted by unknown detainee(s) on 24 JUL 2007. He was transported to the TIF hospital for treatment and transferred to the 28th Combat Support Hospital for further treatment. On (b)(6) 2007 he began to exhibit signs and symptoms of a stroke and was intubated. Resuscitative efforts were unsuccessful and he was pronounced dead at 0247 hrs (b)(6) (b)(6) 2007.

Authorization for Autopsy: Office of the Armed Forces Medical Examiner, IAW 10 USC 1471.

Identification: Presumptive identification based on review of all papers in case file. Post-mortem fingerprint and dental examinations conducted. A suitable specimen for DNA analysis is obtained.

CAUSE OF DEATH: **Complications of sharp and blunt force injuries of the head**

MANNER OF DEATH: **Homicide**

31 MAR 2008
The first page of this report is amended to correct a typographic error in the AFIP number.

(b)(6)

(b)(6) Medical Examiner

ACLU Detainee DeathII ARMY MEDCOM 813

EXTERNAL EXAMINATION

The body is that of a well-developed, well-nourished male. The body is 70 inches in length, weighs 211 pounds, and appears compatible with the stated age of 31 years old. The body is cold. Lividity is fixed on the posterior surface of the body except in the areas exposed to pressure. Rigor is resolving and equal in the upper and lower extremities.

Injuries are described in "Evidence of Injury". The scalp hair is black and short. The facial hair consists of a black beard. A plastic cap covers the left eye and injury of the left eye precludes assessment. The right iris is indistinct. The right cornea is cloudy. The right conjunctiva is congested and the right sclera is hemorrhagic. The teeth are natural. On the anterior scalp is a 2-inch linear scar. A ½ x ½-inch nevus is on the bridge of the nose.

The chest is symmetric. The hair of the upper left side of the chest is shaved. A 4-inch linear scar is on the right lower quadrant of the abdomen. The genitalia are those of an adult circumcised male. The anus is unremarkable.

The upper and lower extremities are symmetric. The fingernails are intact. The soles of the feet are callous. On the left upper extremity are multiple scars in various stages of healing ranging in size from 4 x ¼-inch to 2 x 1-inch. On the lateral right hip are six, 1/8-inch in maximum dimension, skin defects. There are multiple healed scars on both knees that are ¼-inch in maximum dimension. A scar is on the anterior left foot that is ¾-inch in maximum dimension.

CLOTHING AND PERSONAL EFFECTS

The body is unclad and no personal effects are present with the body.

MEDICAL INTERVENTION

On the right side of the scalp is a 1/8-inch defect that is secured by two metal staples. This defect correlates with a 3 millimeter defect in the calvarium and a 3 millimeter defect in the dura mater (consistent with trephine). There is gauze over the left eye. Both upper eyelids and the right lower eyelid have sutures (see "Evidence of Injury".) On the upper left side of the chest is a puncture mark. A 5-1/2-inch incision closed with staples is on the posterior right forearm. On the left groin are two, 1/8-inch incisions (consistent with vascular access cut downs).

RADIOGRAPHS

A complete set of post-mortem radiographs is obtained and demonstrate fractures of both medial walls of the orbits, staples in the scalp, and fracture of the ulna with associated plate and screw fixation and overlying skin staples.

EVIDENCE OF INJURY

I. **Head and neck:**

On the upper and lower right eyelids are obliquely oriented, 1-inch in length penetrating sharp force wounds (sutured). The underlying medial extra-ocular muscles of the eye have been incised and there are fractures of the medial wall of the right orbit (radiographic). On the upper left eyelid are two obliquely oriented penetrating sharp force wounds (sutured) that are ½-inch and 1-inch in length. The underlying eyeball is ruptured and the extra-ocular muscles are incised.

ACLU Detainee DeathII ARMY MEDCOM 814

There are fractures of the medial wall of the left orbit extending into the sphenoid sinus (radiographic) with associated hemorrhage of the sphenoid sinus. The left optic nerve is transected. There is ecchymosis of the upper and lower left eyelids. On the right cheek is a ¼ x ¼-inch abrasion.

On the left side of the neck, inferior to the left ear, is a 1 x ½-inch contusion. There is a ½ x ½-inch contusion of the left earlobe. Internal examination reveals a 2 x 1-inch contusion of the left temporalis muscle. There is diffuse subarachnoid hemorrhage and contusions of the left frontal and parietal lobes of the brain. There is hemorrhage of the anterior midbrain and left caudate nucleus and thalamus.

II. Torso:

On the upper right side of the chest is a 3 x 2-inch contusion. There is a 1 x 1-inch contusion and a ½ x ½-inch abrasion on the left side of the chest.

III. Extremities:

On the anterior right arm are two, horizontally oriented contusions that are both 2 x ½-inch with an area of central pallor that is ½ x ¼-inch. There is a 4 x 2-inch contusion of the medial right elbow. There are two, ½-inch abrasions and a ¼-inch in maximum dimension laceration of the right elbow. A 1 x 1-inch abrasion and a ½ x ½-inch abrasion are on the posterior right forearm. On the medial left arm are multiple, ¼ x ¼-inch contusions. A 6 x 3-inch contusion is on the lateral left elbow. A 2 x 1-inch contusion is on the back of the left hand and a ½ x ¼-inch contusion is on the base of the left thumb. There is a 1 x 1-inch abrasion on the back of the left hand.

A 3 x 2-inch contusion is on the anterior right thigh. On the right knee are a 3 x 2-inch contusion and a ¼ x ¼-inch abrasion. There are two lacerations of the anterior right leg that are ½-inch and ¾-inch, respectively and are separated by ¼-inch. Inferior to these lacerations is a ¼ x ¼-inch abrasion. A ¼ x ¼-inch contusion is on the anterior right thigh and a 1 x 1-inch contusion is on the right knee.

Superficial skin incisions of the posterior aspect of the extremities reveal a hematoma of the right forearm (6 x 2 x ½-inch), left forearm (8 x 2 x ½-inch), right thigh and leg (10 x 4 x ½-inch).

INTERNAL EXAMINATION

BODY CAVITIES:
The ribs, sternum, and vertebral bodies are visibly and palpably intact. There are adhesions of the abdomen. The organs occupy their usual anatomic positions.

HEAD, NECK, and CENTRAL NERVOUS SYSTEM:
See "Evidence of Injury" and "Medical Intervention". The brain weighs 1420 grams.

The anterior strap muscles of the neck are homogenous and red-brown, without hemorrhage by layer-wise dissection. The thyroid cartilage and hyoid bone are intact.

ACLU Detainee DeathII ARMY MEDCOM 815

The thyroid gland is symmetric and red-brown, without cystic or nodular change. The larynx is lined by intact white mucosa. The tongue is unremarkable.

RESPIRATORY SYSTEM:
The upper airway is clear of debris and foreign material. The mucosal surfaces are smooth, yellow-tan and unremarkable. The right and left lungs weigh 1050 and 810 grams, respectively. The pulmonary parenchyma is diffusely congested and edematous, exuding moderate amounts of blood and frothy fluid. No mass lesions or areas of consolidation are present. The pulmonary arteries are normally developed and patent without thrombus or embolus.

CARDIOVASCULAR SYSTEM:
The heart weighs 380 grams and is contained in an intact pericardial sac. The coronary arteries are widely patent. The atrial and ventricular septum are intact. The cardiac valves are unremarkable. The left interventricular septum measures 1.5 centimeters and the left ventricular free wall measures 1.4 centimeters. The right ventricular free wall is 0.3 centimeters thick. The right ventricle is dilated. The aorta and its major branches arise normally and follow the usual course and are unremarkable. The vena cava and its major tributaries return to the heart in the usual distribution and are free of thrombi.

LIVER & BILIARY SYSTEM:
The 1630 gram liver has an intact, smooth capsule and a sharp anterior border. The parenchyma is pale with the usual lobular architecture. No mass lesions or other abnormalities are seen. The gallbladder contains 15 milliliters of green bile. The extrahepatic biliary tree is patent.

SPLEEN:
The 200 gram spleen has a smooth, intact, red-purple capsule. The parenchyma is maroon with unremarkable lymphoid follicles.

PANCREAS:
The pancreas is red-tan. No mass lesions or other abnormalities are seen.

ADRENALS:
The right and left adrenal glands are symmetric, with bright yellow cortices and red-brown medullae. No masses or areas of hemorrhage are identified.

GENITOURINARY SYSTEM:
The right and left kidneys weigh 150 and 170 grams, respectively. The external surfaces are intact and smooth. The cortex is sharply delineated from the medullary pyramids. The pelves are unremarkable and the ureters are normal in course and caliber. The bladder contains 150 milliliters of yellow urine. The prostate and testes are unremarkable.

ACLU Detainee DeathII ARMY MEDCOM 816

GASTROINTESTINAL TRACT:
The esophagus is intact and lined by smooth, grey-white mucosa. The stomach, small bowel, and colon are unremarkable. The stomach contains 60 milliliters of brown fluid. The appendix is absent.

MUSCULOSKELETAL:
See "Evidence of Injury". Muscle development is normal. No non-traumatic bone or joint abnormalities are identified.

ADDITIONAL PROCEDURES

1. Specimens retained for toxicology testing and/or DNA identification are: Blood, vitreous fluid, bile, urine, liver, lung, kidney, spleen, brain, psoas muscle, myocardium, adipose tissue and gastric contents.
2. The dissected organs are forwarded with the body.
3. Selected portions of organs are retained in formalin.
4. Personal effects are released to the appropriate mortuary operations representatives.
5. Recovered evidence: None.

MICROSCOPIC EXAMINATION

Brain, left parietal cortex (Slide 1): Hemorrhage of the cortical surface extending into the underlying white matter

Optic nerve, left (Slide 1): Diffuse hemorrhage of the optic nerve sheath with acute inflammatory response; ischemic changes of a portion of the neurons

Midbrain (Slide 2): Scattered hemorrhage of the anterior parenchyma

ACLU Detainee DeathII ARMY MEDCOM 817

FINAL AUTOPSY DIAGNOSES

I. Sharp and blunt force injuries:

A. Two penetrating sharp force wounds of the upper left eyelid with associated rupture of the left eyeball, transected optic nerve, disruption of the extra-ocular muscles, and fractures of the orbital wall and sphenoid sinus
B. Penetrating sharp force wounds of the upper and lower right eyelids with associated disruption of the extra-ocular muscles and fractures of the orbital wall
C. Subarachnoid hemorrhage and contusions of the left parietal and frontal lobes of the brain
D. Hemorrhage of the left temporalis muscle
E. Abrasion of the right cheek
F. Contusions of the left ear and left neck
G. Contusions of both sides of the chest
H. Fracture of the right ulna
I. Soft tissue hematoma of the right forearm, left forearm, and right lower extremity
J. Multiple contusions, abrasions, and lacerations of the extremities

II. Identifying marks:

A. Appendectomy scar
B. Multiple scars of the left upper extremity and both lower extremities

III. Evidence of medical intervention: As described above

IV. Post-mortem changes:

A. Lividity is fixed on the posterior surface of the body except in areas exposed to pressure
B. Rigor is resolved in the upper and lower extremities
C. Cloudy right cornea

V. Natural disease: None identified within the limits of the examination

VI. Toxicology (AFIP):

A. VOLATILES: No ethanol detected in the blood and vitreous fluid
B. CARBON MONOXIDE: The carboxyhemoglobin saturation in the blood was less than 1%
C. CYANIDE: No cyanide detected in the blood
D. DRUGS:
    1. Morphine was detected in the urine. The blood contained 0.50 mg/L of morphine.
    2. Lorazepam was detected in the urine. The blood contained 0.05 mg/L of lorazepam.
    3. Ephedrine was detected in the urine. The blood contained 0.06 mg/L of ephedrine.

ACLU Detainee DeathII ARMY MEDCOM 818

4. Fentanyl was detected in the urine. The blood contained 0.07 mg/L of fentanyl.
5. Acetaminophen was detected in the urine. The blood contained 6.3 mg/L of acetaminophen.
6. Lidocaine was detected in the urine.

OPINION

This 31 year-old male (b)(6) died of complications of sharp and blunt force injuries of the head. He had penetrating sharp force injuries of both eyes. The left optic nerve was transected and there were fractures of the orbital walls that extended into the sphenoid sinus. In addition, he had subarachnoid hemorrhage and contusions of the left side of the brain. Gross examination and microscopic sections of the brainstem revealed hemorrhages of the midline that are consistent with herniation. The results of the toxicology screen are consistent with resuscitative efforts. The manner of death is homicide.

(b)(6)

(b)(6) Medical Examiner (b)(6)

ACLU Detainee DeathII ARMY MEDCOM 819

CERTIFICATE OF DEATH *(OVERSEAS)*

Acte de décès (D'Outre-Mer)

NAME OF DECEASED *(Last, First, Middle)* Nom du décédé (Nom et prénoms)	GRADE Grade	BRANCH OF SERVICE Arme	SOCIAL SECURITY NUMBER Numéro de l'Assurance Social
BTB Khalid, Muhammed, Qusay		Civilian	(b)(6)

ORGANIZATION Organisation	NATION *(e.g. United States)* Pays	DATE OF BIRTH Date de naissance	SEX Sexe
	Iraq	(b)(6) 1976	[X] MALE [ ] FEMALE

RACE Race		MARITAL STATUS État Civil			RELIGION Culte		
[X]	CAUCASOID Caucasique	[ ]	SINGLE Célibataire	[ ]	DIVORCED Divorcé	[ ] PROTESTANT Protestant	[ ] OTHER (Specify) Autre (Spécifier)
[ ]	NEGROID Negroide	[ ]	MARRIED Marié	[ ]	SEPARATED Séparé	[ ] CATHOLIC Catholique	[X] Sunni-Islam
[ ]	OTHER (Specify) Autre (Spécifier)	[ ]	WIDOWED Veuf			[ ] JEWISH Juif	

NAME OF NEXT OF KIN Nom du plus proche parent	RELATIONSHIP TO DECEASED Parenté du décédé avec le sus
STREET ADDRESS Domicile à (Rue)	CITY OR TOWN OR STATE *(Include ZIP Code)* Ville (Code postal compris)

MEDICAL STATEMENT Déclaration médicale

	CAUSE OF DEATH (Enter only one cause per line) Cause du décès (N'indiquer qu'une cause par ligne)	INTERVAL BETWEEN ONSET AND DEATH Intervalle entre l'attaque et le décès
DISEASE OR CONDITION DIRECTLY LEADING TO DEATH [1] Maladie ou condition directement responsable de la mort [1]	Complications of sharp force and blunt force injuries of the head	
ANTECEDENT CAUSES Symptômes précurseurs de la mort. MORBID CONDITION, IF ANY, LEADING TO PRIMARY CAUSE Condition morbide, s'il y a lieu, menant à la cause primaire		
ANTECEDENT CAUSES Symptômes précurseurs de la mort. UNDERLYING CAUSE, IF ANY, GIVING RISE TO PRIMARY CAUSE Condition morbide, s'il y a lieu, menant à la cause primaire		
OTHER SIGNIFICANT CONDITIONS [2] Autres conditions significatives [2]		

MODE OF DEATH Condition de décès	AUTOPSY PERFORMED Autopsie effectuée [X] YES Oui [ ] NO Non	CIRCUMSTANCES SURROUNDING DEATH DUE TO EXTERNAL CAUSES Circonstances de la mort suscitées par des causes extérieures
[ ] NATURAL Mort naturelle	MAJOR FINDINGS OF AUTOPSY Conclusions principales de l'autopsie	
[ ] ACCIDENT Mort accidentelle		
[ ] SUICIDE Suicide	NAME OF PATHOLOGIST Nom du pathologiste (b)(6)	
[X] HOMICIDE Homicide	SIGNATURE Signature (b)(6) DATE Date 30 July 2007	AVIATION ACCIDENT Accident à Avion [ ] YES Oui [X] NO Non

DATE OF DEATH *(day, month, year)* Date de décès (le jour, le mois, l'année)	PLACE OF DEATH Lieu de décès
(b)(6) 2007	Iraq

I HAVE VIEWED THE REMAINS OF THE DECEASED AND DEATH OCCURRED AT THE TIME INDICATED AND FROM THE CAUSES AS STATED ABOVE.
J'ai examiné les restes mortels du dé funt je conclus que le décès est survenu à l'heure indiquée et à, la suite des causes énumérées ci-dessus.

NAME OF MEDICAL OFFICER Nom du médecin militaire ou du médecin certifiant	TITLE OR DEGREE Titre ou diplôme
(b)(6)	

GRADE Grade	INSTALLATION OR ADDRESS Installation ou adresse
(b)(6)	Dover AFB, Dover DE

DATE Date	SIGNATURE Signature
7/30/2007	(b)(6)

[1] State disease, injury or complication which caused death, and the mode of injury, such as fracture, burn, etc.
[2] State conditions contributing to the death, but not related to the disease or condition causing death.
[1] Préciser la nature de la maladie, de la blessure ou de la complication qui a constitué à la mort, mais non la manière de mourir, telle qu'un arrêt du coeur, etc
[2] Préciser la condition qui a contribué à la mort, mais n'ayant aucun rapport avec la maladie ou à la condition qui a provoqué la mort

DD FORM 1 APR 77 2064 REPLACES DA FORM 3565, 1 JAN 72 AND DA FORM 3565-R(PAS), 26 SEP 75, WHICH ARE OBSOLETE.

ACLU Detainee DeathII ARMY MEDCOM 820

(REMOVE, REVERSE AND RE-INSERT CARBONS BEFORE COMPLETING THIS SIDE)

DISPOSITON OF REMAINS			
NAME OF MORTICIAN PREPARING REMAINS	GRADE	LICENSE NUMBER AND STATE	OTHER
INSTALLATION OR ADDRESS	DATE	SIGNATURE	
NAME OF CEMETERY OR CREMATORY	LOCATION OF CEMETERY OR CREMATORY		
TYPE OF DISPOSTION	DATE OF DISPOSTION		

REGISTRATION OF VITAL STATISTICS			
REGISTRY *(Town and Country)*	DATE REGISTERED	FILE NUMBER	
		STATE	OTHER
NAME OF FUNERAL DIRECTOR	ADDRESS		
SIGNATURE OF AUTHORIZED INDIVIDUAL			

DD FORM 2064, APR 1977 (BACK) ***USAPA V1.00***

ACLU Detainee DeathII ARMY MEDCOM 821

ARMED FORCES INSTITUTE OF PATHOLOGY
Office of the Armed Forces Medical Examiner
1413 Research Blvd., Bldg. 102
Rockville, MD 20850
301-319-0000

AUTOPSY EXAMINATION REPORT

Name: Hussein, Hader Ali
ISN: (b)(6)
Date of Birth: (b)(6) 1981
Date of Death (b)(6) 2007
Date/Time of Autopsy (b)(6) 2007 (b)(6)
Place of Death: Theater Interment Facility (TIF) Hospital, Camp Bucca, Iraq
Date of Report: 04 SEP 2007

Autopsy No.: (b)(6)
AFIP No.: (b)(6)
Status: Detainee
Place of Autopsy: Port Mortuary, Dover AFB, Dover, Delaware

Circumstances of Death:
On 04 JUL 2007, this 26-year-old Iraqi male was being detained at the TIF (Camp Bucca, Iraq) when, as reported, he was physically assaulted by other detainees. He was transferred to the TIF hospital for treatment. Approximately 1 1/2 hours later, he suffered a massive myocardial infarction. Despite medical treatment provided by the TIF hospital medical personnel, (b)(6) died on (b)(6) 2007.

Authorization for Autopsy:
Armed Forces Medical Examiner, per 10 U.S. Code 1471

Identification:
Presumptive identification is provided by accompanying paperwork.

CAUSE OF DEATH:
Myocardial infarction complicated by blunt force injuries.

MANNER OF DEATH:
Homicide.

ACLU Detainee DeathII ARMY MEDCOM 822

EXTERNAL EXAMINATION

The body is that of a nude, well-developed, well-nourished male. The body weighs 190 pounds, is 67 inches long and appears compatible with the reported age of 26 years. The body is cold. Rigor has passed. Lividity is present and fixed on the posterior surface of the body, except in areas exposed to pressure. There is marbling of the skin of the upper extremities. The hands and feet are macerated with skin slippage identified on the hands. There is bullae formation on both lower extremities, and these bullae are associated with skin slippage. The head is normocephalic, and the scalp hair is short, black, and exhibits male pattern balding. Facial hair consists of a moustache and goatee. The irides are brown. The corneae are cloudy. The conjunctivae are pale. The sclerae are tan. The external auditory canals, external nares and oral cavity are free of foreign material and abnormal secretions. The nasal skeleton and maxillae are palpably intact. The lips are without evident injury. The teeth are natural and the left upper central incisor is missing. Examination of the neck reveals no evidence of injury. Injuries to the chest are described below. No evidence of injury of the ribs or the sternum is evident externally. The abdomen is slightly protuberant. The external genitalia are those of a normal adult circumcised male. A 2 inch superficial decubitus ulcer is identified on the skin overlying the sacrum. A 5 inch thin curvilinear scar is located on the skin of the right upper quadrant of the abdomen, and a 5 inch curvilinear scar is located on the skin overlying the right lower back. The fingernails are intact. No tattoos are identified.

CLOTHING AND PERSONAL EFFECTS

- Accompanying the deceased are white and green hospital sheets, and a white hospital blanket.

MEDICAL INTERVENTION

- None is present on the body at the time of autopsy.
- Evidence of previous medical intervention includes a 1/2 inch superficial mucosal ulceration of the proximal esophagus and a 1/4 inch superficial mucosal ulceration of the pharynx just distal to the vocal fold.

RADIOGRAPHS

A complete set of postmortem radiographs is obtained and demonstrates the following:

- Calcification of the midline falx cerebri.
- Consolidation of both lungs.
- Fluid filled trachea and bronchial trees.
- No fractures are identified.
- No foreign bodies are identified.

ACLU Detainee DeathII ARMY MEDCOM 823

EVIDENCE OF INJURY

The ordering of the following injuries is for descriptive purposes only, and is not intended to imply order of infliction or relative severity. All wound pathways are given relative to standard anatomic position.

BLUNT FORCE INJURIES:

HEAD/NECK:
There is a 1 1/2 x 1/8 inch healing linear abrasion on the right side of the face. Above the left eyebrow is a 1 x 1 inch purple contusion, and on the center of the forehead is a 1 x 1/2 inch purple contusion. Associated with these two contusions is a 4 inch frontal subgaleal hemorrhage that extends to the bilateral parietal scalp. Over the occipital protuberance is a 3/4 x 3/4 inch healing laceration that has central granulation tissue. On the back of the head, just to the left of the midline, is a 3/4 x 1/4 inch V-shaped healing laceration with central granulation tissue present. On the right side of the back of the head is a 1 x 1/4 inch healing laceration with central granulation tissue.

TORSO:
There is a 1 inch purple contusion of the right lower quadrant of the abdomen and two purple contusions, 1/2 inch and 1 inch respectively, of the central aspect of the lower abdomen. On the right buttock is a 2 inch purple contusion. Upon reflection of the skin of the right side of the chest, an area of contusion, 1 1/2 inches, is identified within the musculature overlying the anterior aspects of right ribs 6-8. The anterior aspect of the sixth right rib is fractured. Further, an area of contusion, 3 x 2 inches, is identified in the musculature overlying the anterior aspect of right ribs 9 and 10. The underlying ribs are not fractured. (The injuries of the chest may be due to medical intervention.)

EXTREMITIES:
Overlying the anterior aspect of the right leg is a 1 inch healing scabbed abrasion which is located within the center of a 3 inch purple contusion.

ACLU Detainee DeathII ARMY MEDCOM 824

INTERNAL EXAMINATION

BODY CAVITIES:

The body is opened by the usual thoraco-abdominal incision and the chest plate is removed. The sternum and vertebral bodies are visibly and palpably intact. Bilateral pleural and pericardial adhesions are seen in both chest cavities and within the pericardial sac. Both chest cavities contain 200 ml of serosanguineous fluid. The pericardial sac contains 10 ml of serosanguineous fluid. The peritoneal cavity contains 100 ml of serosanguineous fluid. All body organs are present in normal anatomical position.

The subcutaneous fat layer of the abdominal wall is 1 1/2 inches thick.

Posterior cutdowns are performed revealing evidence of injury consistent with those described above.

HEAD AND CENTRAL NERVOUS SYSTEM

The scalp is free of nontraumatic lesions. There are no skull fractures. The calvarium of the skull is removed. The dura mater and falx cerebri are intact and calcifications are identified within the falx cerebri, and the midline dura. There is no epidural or subdural hemorrhage present. The leptomeninges are thin and delicate. The cerebral hemispheres are symmetrical. The structures at the base of the brain, including cranial nerves and blood vessels are intact.

Clear cerebrospinal fluid surrounds the 1480-gram brain, which has unremarkable gyri and sulci. Coronal sections through the cerebral hemispheres reveal no lesions. Transverse sections through the brain stem and cerebellum are unremarkable. The atlanto-occipital joint is stable. The spinal cord is unremarkable.

NECK:

The anterior strap muscles of the neck are homogenous and red-brown, without hemorrhage by layer-wise dissection. The thyroid cartilage and hyoid bone are intact. The larynx is lined by pink-white mucosa and a 1/4 inch area of ulceration is identified just distal to the vocal fold on the left side. The tongue is free of bite marks, hemorrhage, or other injuries. Incision and dissection of the posterior neck demonstrates no deep paracervical muscular injury and no cervical spine fractures.

ACLU Detainee DeathII ARMY MEDCOM 825

CARDIOVASCULAR SYSTEM:

The 450-gram heart is contained in an intact pericardial sac. 10 ml of serosanguineous fluid is identified in the pericardial sac. There are fibrinous adhesions between the pericardium and the heart. The epicardial surface is granular and rough, with minimal fat investment.

The coronary arteries are present in a normal distribution, with a right-dominant pattern. Cross sections of the vessels show occlusion of the proximal portion of the left anterior descending coronary artery by atherosclerotic plaque and adherent organized thrombus.

There is a 4 x 3 inch area of soft yellow-brown discoloration of the myocardium extending from the apex along the anterior wall of the left ventricle and extending just into the intraventricular septum and to the lateral wall of the left ventricle (within the perfusion zone of the left anterior descending coronary artery). This area of myocardial necrosis extends through the full thickness of the left ventricular wall (transmural). A mural thrombus is identified within the left ventricular chamber. The valve leaflets are thin and mobile. The walls of the left ventricle, interventricular septum, and right ventricle are 1.0, 1.1, and 0.3-cm thick, respectively. The endocardium is smooth and glistening.

The aorta gives rise to three intact and patent arch vessels. The renal and mesenteric vessels are unremarkable.

RESPIRATORY SYSTEM:

The upper airway is clear of debris and foreign material: the mucosal surfaces are smooth, yellow-tan and unremarkable. The pleural surfaces are smooth, glistening and unremarkable bilaterally.

The pulmonary parenchyma is diffusely congested and edematous, exuding slight to moderate amounts of blood and frothy fluid; the cut surfaces of both lungs exhibits patches of gray, purulent consolidation most prominent in the perihilar regions.

The pulmonary arteries are normally developed, patent and without thrombus or embolus. The right lung weighs 1530 grams; the left 1450 grams.

HEPATOBILIARY SYSTEM:

The 1810-gram liver has an intact smooth capsule covering a moderately congested tan-brown parenchyma with no focal lesions noted (the cut surface has a nutmeg appearance).

The gallbladder contains 5 ml of green-brown, mucoid bile; the mucosa is velvety and unremarkable. The extrahepatic biliary tree is patent, without evidence of calculi.

ACLU Detainee DeathII ARMY MEDCOM 826

GASTROINTESTINAL SYSTEM:

The esophagus is lined by gray-white, smooth mucosa. The gastric mucosa is arranged in the usual rugal folds and the lumen contains 50 ml of brown-tan fluid. A ½-inch mucosal ulceration is identified in the proximal esophagus.

The small and large bowels are unremarkable. The pancreas has a normal pink-tan lobulated appearance and the ducts are clear. The appendix is present.

GENITOURINARY SYSTEM:

The right kidney weighs 180 grams; the left 200 grams. The renal capsules are smooth and thin, semi-transparent and stripped with ease from the underlying smooth, red-brown cortical surface.

The cortex is sharply delineated from the medullary pyramids, which are red-purple to tan and unremarkable. The calyces, pelves and ureters are unremarkable.

White bladder mucosa overlies an intact bladder wall. The bladder is empty. The testes, prostate gland and seminal vesicles are without note.

LYMPHORETICULAR SYSTEM:

The 280-gram spleen has a smooth, intact capsule covering red-purple, moderately firm parenchyma; the lymphoid follicles are unremarkable.

Lymph nodes in the hilar, periaortic, and iliac regions are not enlarged.

ENDOCRINE SYSTEM:

The pituitary gland is unremarkable. The thyroid gland is symmetric and red-brown, without cystic or nodular change. The right and left adrenal glands are symmetric, with bright yellow cortices and red-brown medullae. No masses or areas of hemorrhage are identified.

MUSCULOSKELETAL SYSTEM:

No non-traumatic abnormalities of muscle or bone are identified.

ACLU Detainee DeathII ARMY MEDCOM 827

ADDITIONAL PROCEDURES

1. Documentary photographs are taken by OAFME staff photographers.
2. Personal effects are released to the appropriate mortuary operations representatives.
3. Specimens retained for toxicology testing and/or DNA identification are: brain, lung, heart, liver, kidney, spleen, adipose tissue, skeletal muscle, vitreous fluid, blood, bile, and gastric contents.
4. The dissected organs are forwarded with body.

MICROSCOPIC EXAMINATION

- Left Anterior Descending Coronary Artery (Slide 1) – An atherosclerotic plaque with hemorrhage and necrosis is seen. There is an occlusive organizing and adherent thrombus within the residual lumen.
- Heart – Left Ventricle at Apex (Slide 2) – There is an adherent mural thrombus identified within the left ventricle. Within the myocardium there are areas of complete myocyte replacement by granulation tissue with loose collagen and abundant capillaries. There is a predominant chronic inflammatory response identified.
- Heart – Left Ventricle (Slide 3) - Within the myocardium there are areas of complete myocyte replacement by granulation tissue with loose collagen and abundant capillaries. There is a predominant chronic inflammatory response identified.
- Lung (Slide 4) – A neutrophil rich exudate fills the bronchioles and adjacent alveolar spaces.
- Liver (Slide 5) – There is necrosis of the peri-central hepotocytes with relative sparring of hepatocytes in the peri-portal areas.

ACLU Detainee DeathII ARMY MEDCOM 828

FINAL AUTOPSY DIAGNOSES:

I. CARDIOVASCULAR SYSTEM:
- **A. Myocardial infarction - in the distribution of the left anterior descending coronary artery.**
- **B. Atherosclerotic cardiovascular disease - occlusion of the proximal left anterior**
- **C. descending coronary artery by atherosclerotic plaque with adherent organizing thrombus.**
- **D. Mural thrombus - left ventricular chamber.**

II. PULMONARY SYSTEM:
- **A. Bilateral bronchopneumonia.**
- **B. Pulmonary congestion and edema.**

III. HEPATOBILIARY SYSTEM: Centrolobular Necrosis

IV. CENTRAL NERVOUS SYSTEM: Calcifications of the falx cerebri and midline dura.

V. SKIN: Superficial decubitus ulcer overlying the sacrum.

VI. LARYNX: Superficial ulceration.

VII. ESOPHAGUS: Superficial ulceration.

VIII. INJURIES: Multiple contusions and healing lacerations.

IX. EVIDENCE OF MEDICAL THERAPY: As described above.

X. POSTMORTEM CHANGES: As described above.

XI. IDENTIFYING MARKS: As described above.

XII. TOXICOLOGY (AFIP):
- **A. VOLATILES: No ethanol is detected in the blood and bile**
- **B. DRUGS: Acetaminophen in the blood (19 mg/L); Atropine in the blood; Diazepam in the blood (0.13 mg/L; Nordiazepam in the blood (0.12 mg/L)**
- **C. CYANIDE: No cyanide is detected in the blood**
- **D. CARBON MONOXIDE: The carboxyhemoglobin saturation in the blood was less than 1%**

ACLU Detainee DeathII ARMY MEDCOM 829

OPINION

This 26-year-old Iraqi male died of a myocardial infarction complicated by blunt force injuries. It is reported that he suffered a myocardial infarction a short time after being assaulted by other detainees in a detention facility. It is my opinion based on the information available to me that there is a causal relation between the assault and the myocardial infarction. The manner of death is homicide.

(b)(6)

(b)(6) MEDICAL EXAMINER

ACLU Detainee DeathII ARMY MEDCOM 830

CERTIFICATE OF DEATH *(OVERSEAS)*
Acte de décès (D'Outre-Mer)

NAME OF DECEASED *(Last, First, Middle)* Nom du décédé (Nom et prénoms)	GRADE Grade	BRANCH OF SERVICE Arme	SOCIAL SECURITY NUMBER Numéro de l'Assurance Social
BTB Hussein, Haider, Al		Civilian	(b)(6)
ORGANIZATION Organization	**NATION** *(e.g. United States)* Pays	**DATE OF BIRTH** Date de naissance	**SEX** Sexe
	Iraq	(b)(6) 1981	[X] MALE [ ] FEMALE

RACE Race		MARITAL STATUS État Civil			RELIGION Culte		
[X]	CAUCASOID Caucasique	[ ]	SINGLE Célibataire	[ ] DIVORCED Divorcé	[ ] PROTESTANT Protestant	[X]	OTHER (Specify) Autre (Spécifier)
[ ]	NEGROID Negricole	[ ]	MARRIED Marié	[ ] SEPARATED Séparé	[ ] CATHOLIC Catholique		
[ ]	OTHER (Specify) Autre (Spécifier)	[ ]	WIDOWED Veuf		[ ] JEWISH Juif		

NAME OF NEXT OF KIN Nom du plus proche parent	RELATIONSHIP TO DECEASED Parenté du décédé avec le sus
STREET ADDRESS Domicile à (Rue)	CITY OR TOWN OR STATE *(Include ZIP Code)* Ville (Code postal compris)

MEDICAL STATEMENT Déclaration médicale

	CAUSE OF DEATH (Enter only one cause per line) Cause du décès (N'indiquer qu'une cause par ligne)	INTERVAL BETWEEN ONSET AND DEATH Intervalle entre l'attaque et le décès
DISEASE OR CONDITON DIRECTLY LEADING TO DEATH [1] Maladie ou condition directement responsable de la mort.	Myocardial Infarction complicating blunt force injuries	
ANTECEDENT CAUSES Symptômes précurseurs de la mort. MORBID CONDITION, IF ANY, LEADING TO PRIMARY CAUSE Condition morbide, s'il y a lieu, menant à la cause primaire		
UNDERLYING CAUSE, IF ANY, GIVING RISE TO PRIMARY CAUSE Condition morbide, s'il y a lieu, menant à la cause primaire		
OTHER SIGNIFICANT CONDITIONS [2] Autres conditions significatives [2]		

MODE OF DEATH Condition de décès	AUTOPSY PERFORMED Autopsie effectuée [X] YES Oui [ ] NO Non	CIRCUMSTANCES SURROUNDING DEATH DUE TO EXTERNAL CAUSES Circonstances de la mort suscitées par des causes extérieures
[ ] NATURAL Mort naturelle	MAJOR FINDINGS OF AUTOPSY Conclusions principales de l'autopsie	
[ ] ACCIDENT Mort accidentelle		
[ ] SUICIDE Suicide	NAME OF PATHOLOGIST Nom du pathologiste (b)(6) (b)(6)	
[X] HOMICIDE Homicide	DATE Date 30 July 2007	AVIATION ACCIDENT Accident à Avion [ ] YES Oui [X] NO Non

DATE OF DEATH *(day, mo* Date de décès *(le jour, le* (b)(6) 2007 — Iraq

I HAVE VIEWED THE REMAINS OF THE DECEASED AND DEATH OCCURRED AT THE TIME INDICATED AND FROM THE CAUSES AS STATED ABOVE.
J'ai examiné les restes mortels du dé funtet je conclus que le décès est survenu à l'heure indiquée et à, la suite des causes énumérées ci-dessus.

NAME OF MEDICAL OFFICER Nom du médicin militaire ou du médicin sanitaire	TITLE OR DEGREE Titre ou diplômé
(b)(6)	Medical Examiner
GRADE Grade (b)(6)	INSTALLATION OR ADDRESS Installation ou adresse Dover AFB, Dover DE
DATE Date 7/30/2007	SIG (b)(6)

[1] State disease, injury or complication which caused death, but
[2] State conditions contributing to the death, but not related to the disease or complication causing death.
[1] Préciser la nature de la maladie, de la blessure ou de la complication qui a contribué à la mort, mais non la manière de mourir, telle qu'un arrêt du cœur, etc.
[2] Préciser la condition qui a contribué à la mort, mais n'ayant aucun rapport avec la maladie ou à la condition qui a provoqué la mort.

DD FORM 1 APR 77 2064 REPLACES DA FORM 3565, 1 JAN 72 AND DA FORM 3565-R(PAS), 26 SEP 75, WHICH ARE OBSOLETE.

(REMOVE, REVERSE AND RE-INSERT CARBONS BEFORE COMPLETING THIS SIDE)

DISPOSITON OF REMAINS			
NAME OF MORTICIAN PREPARING REMAINS	GRADE	LICENSE NUMBER AND STATE	OTHER
INSTALLATION OR ADDRESS	DATE	SIGNATURE	
NAME OF CEMETERY OR CREMATORY	LOCATION OF CEMETERY OR CREMATORY		
TYPE OF DISPOSTION	DATE OF DISPOSTION		

REGISTRATION OF VITAL STATISTICS			
REGISTRY *(Town and Country)*	DATE REGISTERED	FILE NUMBER	
		STATE	OTHER
NAME OF FUNERAL DIRECTOR	ADDRESS		
SIGNATURE OF AUTHORIZED INDIVIDUAL			

DD FORM 2064, APR 1977 (BACK) *USAPA V1.00*

ACLU Detainee DeathII ARMY MEDCOM 832

ARMED FORCES INSTITUTE OF PATHOLOGY
Office of the Armed Forces Medical Examiner
1413 Research Blvd., Bldg. 102
Rockville, MD 20850
301-319-0000

AUTOPSY EXAMINATION REPORT

Name: Abdul Rahim, Mohammed Hashim
ISN: (b)(6)
Date of Birth: (b)(6) 1976
Date of Death: (b)(6) 2007
Date of Autopsy: 17 JUL 2007 at 0900

Autopsy No.: (b)(6)
AFIP No.: (b)(6)
Rank: NA
Place of Death: Camp Bucca, Iraq
Place of Autopsy: Port Mortuary
Dover AFB, DE

Date of Report: 30 JUL 2007

Circumstances of Death: According to initial investigative reports, (b)(6) (b)(6) was brought to the guard shack, at Theater International Facility, Camp Bucca, Iraq, by other detainees who found him unconscious and bleeding. Despite institution of resuscitative efforts, he was without signs of life when evaluated at the camp hospital.

Authorization for Autopsy: Office of the Armed Forces Medical Examiner, IAW 10 USC 1471

Identification: Detainee serial number

CAUSE OF DEATH: MULTIPLE BLUNT AND SHARP FORCE INJURIES

MANNER OF DEATH: HOMICIDE

ACLU Detainee DeathII ARMY MEDCOM 833

AUTOPSY DIAGNOSES:

I. Injuries

A. Head and Neck

1. Midline, vertex of the scalp, laceration, 1-1/2 inches, with adjacent 1-1/4 x 1/2 inch abrasion and evidence of underlying subgaleal hemorrhage; no underlying skull fracture identified
2. Occipital scalp on the left side, abrasion, 1/2 x 1/2 inches, with evidence of underlying subgaleal hemorrhage; no underlying skull fracture identified
3. Left fronto-temporal scalp, abrasion, 1 x 1/2 inches
4. Right eyebrow, lateral aspect, contusion, 3/4 x 1/4 inch
5. Right zygomatic area, contusion, 3/4 x 1/2 inch
6. Extensive injuries to the right and left eyes are present
   a. right eye injuries include:
      i. upper eyelid, medial, deep penetrating wound, 3/4 inch
      ii. upper eyelid, lateral, penetrating wound, 1/8 inch
      iii. lower eyelid, lateral, penetrating wound, 1/8 inch
   b. left eye injuries include:
      i. upper eyelid, lateral, ragged penetrating wounds, 1-1/4 inches and 3/4 x 1/2 inch respectively
      ii. lower lid, medial, penetrating wound, 3/4 x 1/4 inch
      iii. enucleation of the left globe with tearing of the extra-ocular muscles and transection of the optic nerve
7. Lower lip, mucosal surface, abrasion, 1 inch
8. Absence/avulsion of the anterior 1/3 of the tongue
9. Chin, through-and-through laceration, 1/2 inch defect through the skin surface, communicates with a 3/4 inch defect of the mucosal surface of the lower lip
10. Maxillary injuries include
    a. fracture of the left side anteriorly
    b.av ulsion of teeth 9 and 11, with associated lacerations of the sockets
    c. partial avulsion of tooth 8 with associated laceration of the socket
11. Fracture of the nasal bone (radiographically)
12. Fracture of the bones of right ethmoid sinus (radiographically)

B. Torso

1. Posteriorly, complex patterned contusion on the upper back on the left side, extending over a 5 x 4 inch area with evidence of hemorrhage into the subjacent soft tissue
2. Posteriorly, linear contusion, extending from the middle of the lower back to the right posterior axillary fold, 8 x 1 inches
3. Posteriorly, contusion-abrasion, middle of the back on the left, 1 inch in maximal dimension
4. Evidence of hemorrhage into the cervical paraspinous soft tissues posteriorly
5. Evidence of hemorrhage into the soft tissues overlying the right and left scapulae and associated fractures of the right and left scapulae

ACLU Detainee DeathII ARMY MEDCOM 834

6. Anteriorly, discontinuous linear patterned contusion, extending from the right shoulder and upper chest, across the middle of the upper chest and onto the left upper chest and shoulder, 22 inches in length, with width varying from 1-1/4 inches up to 2-1/2 inches associated with
   a. factures of the sternum and right ribs 2 – 4 at the costo-sternal junction
   b.as sociated evidence; of hemorrhage into the adjacent soft tissues of the anterior chest wall
   c. evidence of adventitial and peri-adventitial hemorrhage adjacent to the left anterior descending coronary artery
   d.m inute (up to 0.2 cm) lacerations of the posterior aorta
   e. evidence of hemorrhage into the adjacent paraspinous soft tissues
   f. left hemothorax (50 cc)

C. Extremities
1. Left upper extremity
   a. faint contusion, posterior elbow, 4 x 3 inches
   b.f racture dislocation of the left elbow
2. Left lower extremity
   a. linear superficial abrasion, proximal thigh, antero-medially, 2-1/2 x 1/2 inches
   b. superficial abrasions surrounding the knee, 1 inch and 2 inches respectively
   c. complex, discontinuous contusion, anterior surface of the distal thigh and knee, 7 x 5 inches
   d. linear contusion proximal thigh posteriorly, 2 x 1-1/2 inches
   e. diffuse erythema (contusion) over the popliteal fossa, 8x 5 inches
   f. evidence of hemorrhage into the soft tissue of the popliteal fossa
   k. multiple penetrating wounds, extending over the anterior surface of the leg, from the proximal leg to the distal leg, ranging from 1/2 inch up to 1 inch in maximal dimension
   l. superficial penetrating wound, dorsal surface of the foot, 3/4 inch
   m. fracture of the proximal tibia
   n. fracture of the distal tibia and fibula
   o. fracture of the distal fibula at the lateral malleolus
   p. multiple fractures of the bones of the left foot including: the cuneiforms and the 1st and 3rd metatarsals
3. Right upper extremity
   a. incised wound through the skin of the antecubital fossa, 2-1/2 x 3/4 inches and evidence of injury to the subjacent neurovascular structures including the brachial artery and antecubital vein
   b. fracture dislocation of the elbow
4. Right lower extremity
   a. evidence of hemorrhage into the soft tissue of the right buttock
   b. linear contusion, proximal thigh, postero-medially, 7 x 1-1/2 inches in maximal dimensions

ACLU Detainee DeathII ARMY MEDCOM 835

4. Right lower extremity injuries (cont.)
   c. linear contusion, postero-lateral proximal thigh extending into the popliteal fossa, 8 x 1 inches
   d. evidence of hemorrhage into the soft tissue of the popliteal fossa
   e. discontinuous contusion, antero-lateral surface of the proximal thigh, extending over a 6 x 5 inch area
   f. diffuse erythema (contusion) surrounding the knee, extends over a 6-1/2 x 5-1/2 inch area
   g. superficial abrasions, right knee, 1/2 x 1/4 inch and 1 x 3/4 inch, respectively
   h. discontinuous contusions, anterior surface of the leg, extend over an area 10 x 4 inches
   i. superficial incised wounds, anterior surface of the leg, range up to 1/2 x 1/2 inch in maximal dimensions
   j. fracture of the distal femur
   k. comminuted fractures of the proximal tibia and fibula
   l. fractures of the distal tibia and fibula
   m. multiple fractures of the bones of the leg including proximal and distal tibia and fibula
   n. fracture of the lateral malleolus of the right ankle
   o. multiple fractures of the bones of the right foot including: the navicular, cuboid, 3rd and 4th metatarsals and the proximal phalanx of the great toe

II. Evidence of Medical Intervention
Unequivocal evidence of medical intervention is not identified

III. Evidence of Pre-existing Disease
A. Well healed, variably pigmented scar extends obliquely over the surface of the right lower abdominal quadrant (consistent with an appendectomy scar)
B. Dense pulmonary adhesions extending from the all visceral pleural surfaces to the adjacent parietal pleural surfaces
C. Dense fibrous adhesions fuse adjacent loops of small and large bowel together
D. Mild to moderate atheromatous narrowing of the left anterior descending coronary artery is noted within 1 cm of its origin
E. Evidence of historically remote, healed fracture of the right humerus (radiographically)
F. Evidence of bilateral spondylolysis at L5, (radiographically)or descending coronary artery is noted within 1 cm of its origin

IV. Identifying Marks
A. Healed surgical scar, right lower abdomen
B. (Radiographic) healed right humeral fracture

V. Toxicology
Negative

ACLU Detainee DeathII ARMY MEDCOM 836

VI. Post-mortem Changes
A. Resolving rigor mortis
B. Mild lividity evident posteriorly

EXTERNAL EXAMINATION

Injuries will be described in detail in a separate section, and will only be briefly alluded to in the remainder of the report, for purposes of orientation and completeness. The body, unclothed, is that of a well-developed, 67 inch tall, 162 pounds male whose appearance is consistent with the reported age of 30 years. Lividity is posterior and fixed, rigor is resolving, and the body is cooled to refrigeration temperature.

The scalp is covered with closely trimmed black, hair in the normal male distribution and a full, black moustache and closely trimmed full, black beard are present. The corneas are mildly opacified, the underlying irides are brown. The sclerae are clear. The ears are unremarkable. The nares are patent. The injuries to the mouth have been noted.

The neck is straight, and the trachea is midline and mobile. The chest is symmetric. The abdomen is flat. The genitalia are those of a normal circumcised adult male. The testes are descended and free of masses. Pubic hair is present in the usual male distribution. The injury to the right buttock has been noted. The anus is without evidence of trauma or other lesion. Apart from the injuries noted, the upper and lower extremities are symmetric and without clubbing or edema.

CLOTHING AND PERSONAL EFFECTS

There are no items of clothing accompanying the remains. There are no personal effects accompanying the remains.

RADIOGRAPHS

A complete set of postmortem radiographs is obtained and demonstrates the following:

- Fracture of the bones of the ethmoid sinus, nasal bones and maxilla
- Fractures of the sternum and costo-sternal fractures, right ribs 2 - 4
- Fracture dislocation of the left elbow complex
- Fracture dislocation of the right elbow complex
- Fracture, remote-healed, of the right humerus
- Fracture of the distal right femur
- Multiple fractures of the right leg, including the proximal and distal tibia and fibula, and the lateral malleolus of the ankle
- Multiple fractures of the bones of the right foot including: the navicular, cuboid, 3rd and 4th metatarsals and the proximal phalanx of the great toe
- Fractures of the left leg include the proximal tibia, the distal tibia and fibula, and the lateral malleolus of the ankle
- Multiple fractures of the bones of the left foot including: the cuneiforms and the 1st and 3rd metatarsals
- Absence of radio-opaque foreign material

ACLU Detainee DeathII ARMY MEDCOM 837

EVIDENCE OF INJURY

Scalp injuries include a 1-1/2 cm laceration of the vertex of the scalp associated with underlying , an adjacent 1-1/4 inch superficial abrasion and a 1/2 inch superficial abrasion of the occipital scalp. Facial injuries include a 3/4 inch contusion lateral to the right eyebrow, a 3/4 inch contusion over the right cheek and a through-and through laceration of the chin. Injuries to the right eye include two penetrating wounds of the upper eyelid (1/8 up to 3/4 inch), and a penetrating wound of the lower eyelid (1/8 inch). The left eye has been enucleated from the socket and the optic nerve severed. The extra-ocular muscles of the eye have been lacerated, as have the upper eyelid (two penetrating wounds, 1-1/4 and 3/4 inches in maximal dimensions respectively) the lower eyelid (a 3/4 inch penetrating wound). A 1 inch abrasion is present on the mucosal surface of the lower lip, and inferior to this, a 3/4 inch laceration is continuous with the laceration to the chin. Teeth 9 and 10 are avulsed from their sockets in the maxilla, and tooth 8 is partially avulsed. There is evidence of abundant hemorrhage into and around the associated sockets. The anterior one-third of the tongue is absent. Radiographically identified injuries include fractures of the nasal bones, the bones of the right ethmoid sinus and the maxillary bone.

Torso injuries include: a complex 5 x 4 inch patterned contusion of the upper back on the left side; a linear 8 x 1 inch contusion, extending from the middle of the lower back to the right posterior axillary fold and a 1 inch contused abrasion in the middle of the back on the left side. Anteriorly, a ribbon-like, discontinuous linear patterned contusion, 22 inches long, extends from the shoulders onto the chest. Direct examination of the subjacent tissues discloses underlying injuries including: hemorrhage into the soft tissues of the anterior chest wall (associated with fractures listed below); evidence of adventitial and peri-adventitial hemorrhage adjacent to the left anterior descending coronary artery; minute (0.2 cm maximum) lacerations of the posterior aorta; evidence of hemorrhage into the adjacent paraspinous soft tissues, and a left hemothorax (50 cc). Additionally, there is evidence of hemorrhage into the cervical paraspinous soft tissues and into the soft tissues overlying the right and left scapulae. Radiographically defined torso injuries include fractures of the right and left scapulae, and fractures of the sternum and the right second through fourth ribs on the right, at the costo-sternal junction.

Left extremity injuries include: a contusion around the elbow, 4 x 3 inches; a fracture dislocation of the left elbow; complex, a linear superficial abrasion of the proximal thigh (2-1/2 x 1/2 inches); superficial abrasions surrounding the knee (up to 2 inches in maximal dimension); a discontinuous contusion, anterior surface of the distal thigh and knee, 7 x 5 inches; a linear contusion posterior thigh (2 x 1-1/2 inches); a contusion of the popliteal fossa; evidence of hemorrhage into the soft tissue of the popliteal fossa, and multiple incised wounds of the leg anteriorly (ranging up to 1 inch in maximal dimension), as well as a superficial, 3/4 inch incised wound of dorsum of the foot. Radiographically defined lesions of the left lower extremity include fractures of: the proximal tibia; the distal tibia and fibula; the lateral malleolus; the cuneiform bones of the midfoot and the first and third metatarsals of the forefoot.

ACLU Detainee DeathII ARMY MEDCOM 838

EVIDENCE OF INJURY
(cont.)

Right extremity injuries include: an incised wound of the antecubital fossa (2-1/2 inches in maximal dimension) associated with injuries to the underlying brachial artery and antecubital vein; a fracture dislocation of the elbow; evidence of hemorrhage into the buttock; a linear contusion of the postero-medial surface of the proximal thigh (7 inches in maximal dimension); a linear contusion of the postero-lateral surface of the proximal thigh, which extends into the popliteal fossa (8 inches in maximal dimension); linear contusion posterior thigh (2 x 1-1/2 inches); superficial abrasions over the anterior surface of the right knee, 1/2 x 1/4 inch and 1 x 3/4 inch, respectively; a contusion of the popliteal fossa; evidence of hemorrhage into the soft tissue of the popliteal fossa; a discontinuous contusion of the antero-lateral surface of the proximal thigh which extends over a 6 x 5 inch area; diffuse erythema surrounding the knee which extends over a 6-1/2 x 5-1/2 inch area; discontinuous contusions over the anterior surface of the leg, extending over a 10 x 4 inch area; and superficial incised wounds of the anterior surface of the leg (up to 1/2 inch in maximal dimension). Radiographically defined lesions of the left lower extremity include fractures of: the distal femur; the proximal tibia and fibula; the distal tibia and fibula; the lateral malleolus, and multiple bones of the foot including the navicular, the cuboid, the 3rd and 4th metatarsals and the proximal phalanx of the great toe

INTERNAL EXAMINATION

HEAD:
Injuries to the scalp and face have been described. The blood vessels overlying the 1570 gram brain are engorged. The sulci and gyri are unremarkable, and on coronal sections, the demarcation between white and gray matter is distinct. There is no evidence of hemorrhage or contusive injury. The ventricles are of normal size. The basal ganglia, brainstem, cerebellum, and arterial systems are free of injury or other abnormalities. There are no skull fractures.

NECK:
The anterior strap muscles of the neck are homogenous and red-brown, without hemorrhage. The thyroid cartilage and hyoid bone are intact. The larynx is lined by intact white mucosa. The thyroid gland is symmetric and red-brown, without cystic or nodular change. Posteriorly, there is evidence of hemorrhage into the soft tissue surrounding the cervical spine. The anterior third of the tongue is absent

BODY CAVITIES:
Hemorrhage surrounds the fractured sternum and fractures of the costo-sternal joints of the 2nd through 4th ribs on the right. Dense fibrous adhesions extend between the lung surfaces and the parietal pleural surfaces. Bilateral pneumothoraces are present (radiographically). Approximately 50 cc of blood is present in the left hemithorax. There is no excess fluid in the right pleural space. No excess blood or fluid is present either in the pericardial sac, or in the peritoneal cavity. The organs of the thorax, abdomen and pelvis occupy their usual anatomic positions.

ACLU Detainee DeathII ARMY MEDCOM 839

INTERNAL EXAMINATION
(cont.)

RESPIRATORY SYSTEM:
The right and left lungs weigh 580 and 460 gm, respectively. The dense fibrous adhesions over the plural surfaces have been noted. The pleural surfaces are otherwise unremarkable, and on section, the pulmonary parenchyma is uniformly deep purple, without evidence of mass lesion or areas of consolidation. The proximal airway is unremarkable.

CARDIOVASCULAR SYSTEM:
The 280 gm heart is contained in an intact pericardial sac. Adjacent to the pulmonary artery, along the posterior surface of the base of the heart, is a 0.6 cm contusion. The epicardial surface is otherwise smooth, with scant fat investment. The coronary arteries are present in a normal distribution. Petechial hemorrhage permeates the epicardial fat surrounding the proximal segment of the left anterior descending coronary artery. There is no evidence of an atheromatous lesion or thrombus. The remaining coronary arterial vessels are unremarkable. The myocardium is homogenous, red-brown, and firm without evidence of focal lesion or injury. The valve leaflets are thin and mobile. The walls of the left and right ventricular free walls are 1.0 and 0.2 cm thick, respectively; the interventricular septum is 0.9 cm thick. The endocardium is red-brown and without evidence of focal lesion or injury. The aorta arises and is distributed in the usual pattern. Hemorrhage into the soft tissue adjacent to the thoracic vertebral column emanates from several minute (less than 0.1 cm) lacerations in the posterior aortic wall. The renal and mesenteric vessels are unremarkable.

LIVER & BILIARY SYSTEM:
The 1400 gm liver has an intact, smooth capsule and a sharp anterior border. The parenchyma is tan-brown and congested, with the usual lobular architecture. No mass lesions or other abnormalities are seen. The gallbladder contains 8 cc of green-black bile. There are no stones. The mucosal surface is green and velvety. The extrahepatic biliary tree is patent.

SPLEEN:
The 180 gm spleen has a smooth, intact, red-purple capsule. The parenchyma is maroon and congested, with distinct Malpighian corpuscles.

PANCREAS:
The pancreas is firm and yellow-tan, with the usual lobular architecture. There is no focal lesion or evidence of injury.

ADRENALS:
The right and left adrenal glands are symmetric, with bright yellow cortices and grey medullae. No masses or areas of hemorrhage are identified

ACLU Detainee DeathII ARMY MEDCOM 840

INTERNAL EXAMINATION
(cont.)

GENITOURINARY SYSTEM:
The right and left kidneys weigh 100 and 120 gm, respectively. The external surfaces are intact and smooth. The cut surfaces are red-tan and congested, with uniformly thick cortices and sharp corticomedullary junctions. The pelves are unremarkable and the ureters are normal in course and caliber. White bladder mucosa overlies an intact bladder wall. The bladder contains approximately 30 cc of clear yellow urine. The prostate is normal in size, with lobular, yellow-tan parenchyma. The seminal vesicles are unremarkable. The testes are free of mass lesions, contusions, or other abnormalities.

GASTROINTESTINAL TRACT:
The esophagus is intact and lined by smooth, grey-white mucosa. The stomach contains approximately 40 cc of partially digested food. There are no pill fragments identified. The gastric wall is intact. The colonic segments and loops of small bowel are fused together by focally dense fibrous adhesions. Otherwise, the segments of the gastro-intestinal tract are intact and unremarkable. The appendix is absent.

MUSCULOSKELETAL SYSTEM:
Muscle development is normal. Apart from the recent and remote (healed) injuries noted, no bone or joint abnormalities are noted.

MICROSCOPIC EXAMINATION

Small sections of formalin fixed tissue are retained for microscopy as necessary.

ADDITIONAL PROCEDURES/REMARKS

- Documentary photographs are taken by the OAFME staff photographers.
- Specimens retained for toxicologic testing and/or DNA identification are: blood, vitreous fluid, bile, urine, gastric contents, brain, myocardium, lung, liver, spleen, kidney, adipose tissue and skeletal muscle.
- Full body radiographs are obtained and reflect injuries described above.
- Selected portions of organs are retained in formalin, without preparation of histologic slides.
- Fingernail parings are obtained from both hands, sealed in marked evidence envelopes, and custody maintained by Army CID.
- The dissected organs are forwarded with the body.
- Personal effects are released to the appropriate mortuary operations representatives.

ACLU Detainee DeathII ARMY MEDCOM 841

OPINION

According to initial investigative reports (b)(6) was brought to the camp guard shack by other detainees who found him unconscious and bleeding. On transport to the facility hospital, it is reported that he was pulseless, without blood pressure and that his pupils were fixed and dilated.

At post-mortem exam, it is found that the decedent sustained multiple blunt and sharp force injuries. Individually, these injuries are sub-lethal; in aggregate however, the injuries caused loss of blood sufficient to result in death. Additionally, the intensity of the pain associated with the combined injuries would generate immense sympathetic nervous system stimulation such that a possible contributory cardiac dysrrhythmia cannot be excluded.

Finally, multiple dense pulmonary adhesions as well as bowel adhesions (indicative of prior infectious diseases) suggest that the decedent may have had a diminished reserve capacity to withstand injury and the pain induced when the injuries were inflicted.

The manner of death is homicide.

(b)(6)

(b)(6) Medical Examiner

ACLU Detainee DeathII ARMY MEDCOM 842

CERTIFICATE OF DEATH (OVERSEAS)
Acte de décès (D'Outre-Mer)

NAME OF DECEASED (Last, First, Middle) Nom du décédé (Nom et prénoms)	GRADE Grade	BRANCH OF SERVICE Arme	SOCIAL SECURITY NUMBER Numéro de l'Assurance Sociale
BTB Abdul Rahim, Mohammed, Hashim		Civilian	(b)(6)
ORGANIZATION Organisation	NATION (e.g. United States) Pays: Iraq	DATE OF BIRTH Date de naissance: (b)(6) 1978	SEX Sexe: [X] MALE [ ] FEMALE

RACE Race		MARITAL STATUS État Civil				RELIGION Culte			
X	CAUCASOID Caucasique		SINGLE Célibataire		DIVORCED Divorcé		PROTESTANT Protestant		OTHER (Specify) Autre (Spécifier)
	NEGROID Négroïde		MARRIED Marié		SEPARATED Séparé		CATHOLIC Catholique	X	
	OTHER (Specify) Autre (Spécifier)		WIDOWED Veuf				JEWISH Juif		

NAME OF NEXT OF KIN Nom du plus proche parent	RELATIONSHIP TO DECEASED Parents du décédé avec le sud
STREET ADDRESS Domicile à (Rue)	CITY OR TOWN OR STATE (Include ZIP Code) Ville (Code postal compris)

MEDICAL STATEMENT Déclaration médicale

CAUSE OF DEATH (Enter only one cause per line) Cause du décès (N'indiquer qu'une cause par ligne)		INTERVAL BETWEEN ONSET AND DEATH Intervalle entre l'attaque et le décès
DISEASE OR CONDITON DIRECTLY LEADING TO DEATH[1] Maladie ou condition directement responsable de la mort.	Multiple blunt and sharp force injuries	
ANTECEDENT CAUSES Symptômes précurseurs de la mort. — MORBID CONDITION, IF ANY, LEADING TO PRIMARY CAUSE Condition morbide, s'il y a lieu, menant à la cause primaire		
ANTECEDENT CAUSES Symptômes précurseurs de la mort. — UNDERLYING CAUSE, IF ANY, GIVING RISE TO PRIMARY CAUSE Condition morbide, s'il y a lieu, menant à la cause primaire		
OTHER SIGNIFICANT CONDITIONS[2] Autres conditions significatives[2]		

MODE OF DEATH Condition de décès		AUTOPSY PERFORMED Autopsie effectuée [X] YES Oui [ ] NO Non	CIRCUMSTANCES SURROUNDING DEATH DUE TO EXTERNAL CAUSES Circonstances de la mort résultées par des causes extérieures
	NATURAL Mort naturelle	MEDICAL FINDINGS OF AUTOPSY Constatations principales de l'autopsie	
	ACCIDENT Mort accidentelle		
	SUICIDE Suicide	NAME OF PATHOLOGIST Nom du pathologiste: (b)(6)	
X	HOMICIDE Homicide	(b)(6) DATE Date: 17 July 2007	AVIATION ACCIDENT Accident à l'avion [ ] YES Oui [X] NO Non

DATE OF DEATH (day, month, year) Date de la mort (le jour, le mois, l'année)	PLACE OF DEATH Lieu de décès
(b)(6) 2007 (b)(6)	Iraq

I HAVE VIEWED THE REMAINS OF THE DECEASED AND DEATH OCCURRED AT THE TIME INDICATED AND FROM THE CAUSES AS STATED ABOVE.
J'ai examiné les restes mortels du dé funtel le cadeau que le décès est survenu à l'heure indiquée et à la suite des causes énumérées ci-dessus.

NAME OF MEDICAL OFFICER Nom du médecin officiel ou du médecin certifié	TITLE OR DEGREE Titre ou diplôme
(b)(6)	Medical Examiner

GRADE Grade	INSTALLATION OR ADDRESS Installation ou adresse
(b)(6)	(b)(6)
DATE Date: 7/17/2007	

1 Mode d'accès, rapid or disappointed within certain cases, but not cause of injury cause or even injury, etc.
2 Such conditions contributing to the death, but not related to the disease or condition causing death.
3 Préciser le nature de la maladie, de la blessure ou de la complication qui a contribué à la mort, mais non la maladie de mort, telle que les soins du cœur, etc.
4 Préciser la condition qui a contribué à la mort, mais [illegible]

DD FORM 1 APR 77 2064 REPLACES DA FORM 3565, 1 JAN 72 AND DA FORM 3565-R(PAS), 26 SEP 75, WHICH ARE OBSOLETE.

(REMOVE, REVERSE AND RE-INSERT CARBONS BEFORE COMPLETING THIS SIDE)

DISPOSITON OF REMAINS			
NAME OF MORTICIAN PREPARING REMAINS	GRADE	LICENSE NUMBER AND STATE	OTHER
INSTALLATION OR ADDRESS	DATE	SIGNATURE	
NAME OF CEMETERY OR CREMATORY	LOCATION OF CEMETERY OR CREMATORY		
TYPE OF DISPOSITION	DATE OF DISPOSITION		

REGISTRATION OF VITAL STATISTICS			
REGISTRY (Town and County)	DATE REGISTERED	FILE NUMBER	
		STATE	OTHER
NAME OF FUNERAL DIRECTOR	ADDRESS		
SIGNATURE OF AUTHORIZED INDIVIDUAL			

DD FORM 2064, APR 1977 (BACK) USAPA V1.00

ACLU Detainee Death II ARMY MEDCOM 844

ARMED FORCES INSTITUTE OF PATHOLOGY
Office of the Armed Forces Medical Examiner
1413 Research Blvd., Bldg. 102
Rockville, MD 20850
1-301-319-0000

AUTOPSY EXAMINATION REPORT

Name: Mustafi. Muhavman Jalal
ISN: (b)(6)
Date of Birth: (b)(6) 1990
Date of Death (b)(6) 2007
Date/Time of Autopsy: 16 JUL 2007/0930
Date of Report: 13 AUG 2007

Autopsy No.: (b)(6)
AFIP No.: (b)(6)
Rank: Detainee
Place of Death: Iraq
Place of Autopsy: Port Mortuary
Dover AFB, Dover, DE

Circumstances of Death: This 16-year-old male detainee was interned at Camp Cropper Iraq. Initial investigative reports indicate that the unresponsive body of (b)(6) was dragged to the compound gate by three unknown males who fled the scene. Despite emergency medical intervention (b)(6) succumbed to his injuries.

Authorization for Autopsy: Armed Forces Medical Examiner, per 10 U.S. Code 1471

Identification: Presumptive identification by accompanying reports, identification tags and documentation. A postmortem dental examination, postmortem fingerprint examination, and a postmortem DNA sample are taken for profile purposes should exemplars becomes available for positive identification.

CAUSE OF DEATH: Multiple blunt force injuries

MANNER OF DEATH: Homicide

ACLU Detainee DeathII ARMY MEDCOM 845

EXTERNAL EXAMINATION

Injuries will be described in detail in "Evidence of Injury", and will only be briefly alluded to in the remainder of the report, for purposes of orientation and completeness. The body is that of a well-developed, well-nourished appearing, adult male, whose appearance is consistent with the reported age of 16-years. The body is received wrapped in a green zippered nylon bag and clad in a pair of body fluid stained white boxer shorts. The remains are 68 ½-inches in length, and weigh 154-pounds. Lividity is present and fixed on the posterior surface of the body except in areas exposed to pressure. Rigor is present to an equal degree in all extremities. There is greenish discoloration of the skin of the abdomen. Maceration and skin slippage is noted on the upper extremities. The temperature of the body is that of the refrigeration unit.

The head is normocephalic, and the scalp is covered with straight black hair measuring up to 1 ½-inches, in a normal distribution. Facial hair consists of a trim black beard and moustache. The irides are dark. The corneae are hazy. The conjunctivae are unremarkable. The pupils are round and equal in diameter. The sclerae are white and without petechial hemorrhage. The external auditory canals, external nares, and oral cavity are free of foreign material and abnormal secretions. The ears and lips demonstrate no non-traumatic abonormalities. The nares are patent. The nasal skeleton and maxillae are palpably intact. The uninjured teeth appear natural and in good condition. The neck is straight, and the trachea is midline and mobile.

The chest is symmetric. The abdomen is flat. The genitalia are those of a normal adult circumcised male. The testes are descended and free of masses. Pubic hair is present in a normal male distribution. The buttocks and anus are unremarkable.

The upper and lower extremities are symmetric and without clubbing or edema. The fingernails are intact and the nailbeds cyanotic.

CLOTHING AND PERSONAL EFFECTS

The following clothing items and personal effects are received with or are on the body at the time of autopsy:

- A blood and body fluid stained short sleeve undershirt cut from the front collar to the hem
- A pair of body fluid stained white boxer shorts
- A green cloth bag containing personal effects is affixed to the right wrist, contents of which have been photographed and inventoried on form DD 1076.

MEDICAL INTERVENTION

No evidence of medical intervention is in place at the time of autopsy.

ACLU Detainee DeathII ARMY MEDCOM 846

RADIOGRAPHS

A complete set of postmortem radiographs is obtained and demonstrates the following:

- Fracture of the left maxillary sinus
- Fracture of the 3rd metacarpal of the left hand
- Fracture of the distal right fibula
- Fracture of the posterior spinous process o the 2nd thoracic vertebra
- No internal metal identified
- No pneumothorax identified

EVIDENCE OF INJURY

The ordering of the following injuries is for descriptive purposes only, and is not intended to imply order of infliction or relative severity.

I. Multiple blunt force injuries
   A. Blunt force injuries of the head and neck
      1. Obliquely oriented (along the 4 to 10 o'clock axis) laceration above the right eyebrow, 2 x 1/16-inches to periosteum (3/8-inches)
      2. Vertically oriented curvilinear contused laceration of the nasal bridge, 1 1/8 x 1/16, 3/8-inches deep
      3. Obliquely oriented (along the 5 to 11 o'clock axis) laceration on the right occipital scalp to subcutaneous tissues
      4. Obliquely oriented (along the 1 to 7 o'clock axis) laceration on the left occipito-parietal scalp, 2 ¾ x 1/16-inches to periosteum (3/8-inches)
      5. Horizontally oriented laceration on the left parietal scalp, posterior to the left ear, 1 1/16 x 1/16-inches, 3/8-inches deep with undermining of the superior aspect of the wound
      6. Superficial abrasion on the posterior pinna of the left ear, 3/8 x 1/8-inches
      7. Intersecting lacerations of the posterior left parietal scalp measuring 2 3/4 x 1/16-inches (along the 5 to 11 o'clock axis) and 1 3/8 x 1/16-inches (along the 7 to 1 o'clock axis), both 3/8-inches in depth
      8. Obliquely oriented (along thel 1 to 7 o'clock axis) superficial laceration on the left temporal scalp to subcutaneous tissue, 5/8 x 1/16-inches
      9. Obliquely oriented (along the 5 to 11 o'clock axis) laceration on the mid-sagittal frontal scalp, 2 ¾ x 1/16-inches to periosteum (3/8-inches)
      10. Obliquely oriented (along the 7 to 1 o'clock axis) laceration of the left frontal scalp at the hairline, 1 ½ x 1 1/16-inches to a depth of 1/8-inches
      11. Obliquely oriented (along the 7 to 1 o'clock axis) laceration of the left temporal scalp extending onto the forehead and contusion of the skin of the inferior margin of the wound, 2 ½ x 1/16-inches to a depth of 3/8-inches
      12. Left periorbital contusion with associated superficial lacerations of the lateral left eyebrow (3) measuring up to 7/8-inches in greatest dimensions and a horizontally oriented laceration of the lateral left eyelid, 1 ½ x 1/16-inches

ACLU Detainee DeathII ARMY MEDCOM 847

13. Obliquely oriented (along the 2 to 8 o'clock axis) contused laceration of the left cheek measuring 1 1/6 x 1/16-inches with a depth of ¼-inches and associated fracture of the left maxillary sinus
14. Contused laceration of the left upper lip (5/8 x 1/8-inches) extending into the oral cavity with associated fracture of tooth #10
15. Subgaleal hemorrhage associated with the above scalp lacerations
16. No gross or radiographic evidence of fractures of the calvarium
17. Diffuse subarachnoid hemorrhage involving the convexities of both occipital lobes, brainstem, and both cerebellar hemispheres
18. Diffuse hemorrhage of the right sternocleidomastoid muscle and focal hemorrhage of the right sternohyoid muscle
19. Intact hyoid bone, thyroid cartilage, and tracheal cartilage
20. Cortical contusions of the inferior aspect of the left frontal and right occipital poles of the brain, each measuring less than 1/8-inches in greatest dimensions
21. Laceration of the right lateral aspect of the tongue, ¼ x 1/8-inches

B. Blunt force injuries of the torso

1. Superficial abrasion of the medial right clavicle, 1 ¾ x 3/16-inches
2. Cluster (1 ½ x ½-inches) of superficial abrasions overlying the right acromioclavicular joint, 3/8 to ½-inches in greatest dimensions
3. Curvilinear contused abrasion overlying the middle third of the right clavicle, 4 x ¾-inches
4. Contusion of the right lateral chest wall (8 x 6 ½-inches) with a centrally oriented triangular shaped patterned abrasion, 1 ¼ x 1 1/8-inches
5. Multiple (2) circular superficial abrasions above the right inguinal ligament measuring ½-inches, each
6. Contusions on the lateral right hip, 1 ½ x 5/8-inches
7. Superficial abrasion on the anterior right hip, ½ x 3/8-inches
8. Obliquely oriented (along the 10 to 4 o'clock axis) patterned contusion on the upper back to the left of the 6th and 7th cervical vertebrae, 5 ¼ x 1-inches
9. Obliquely oriented (along the 10 to 4 o'clock axis) patterned contusion above the superior border of the left scapula, 6 x 1 ½-inches
10. Contusion (2 ¾ x 1 ¼-inches) on the posterior left shoulder with superficial marginal abrasion at the superior margin of the wound measuring 3 x 1/16-inches
11. Contusion in the posterior left axillary fold, 2 x 1-inches
12. Trapezoidal shaped patterned abrasion (2 ½ x ¾-inches) above the posterior left iliac crest with a centrally placed ½-inch circular area of sparing
13. Obliquely oriented (along the 1 to 7 o'clock axis) linear contusion of the upper back at the level of the 4th thoracic vertebrae, 5 ¼ x ¾-inches
14. Circular 1-inch contusion on the upper medial border of the right scapula
15. Rectangular contusion on the posterior right shoulder, 2 x 1-inches
16. Horizontally oriented abrasion on the right posterior axillary line at the level of the 8th thoracic vertebrae, 1 ½ x1/8-inches
17. Parallel (1-inch separation) superficial linear abrasions (2) below the tip of the right scapula, 2 x 1/16-inches, each

ACLU Detainee DeathII ARMY MEDCOM 848

18. Obliquely oriented (along the 2 to 8 o'clock axis) rectangular contusion on the right lower back, 7 x 1-inches
19. Fracture of the spinous process of the 2nd thoracic vertebrae with hemorrhage into the surrounding paraspinal muscles
20. Multiple rib fractures (lateral right - 8-9, posterior right – 9-10) with associated soft tissue hemorrhage, 6 x 5-inches
21. Evidence of hemorrhage into the soft tissues overlying the right scapula
22. Evidence of hemorrhage into the soft tissues associated with the contusions and abrasions of the torso, as described above

C. Blunt force injuries of the extremities
1. Right upper extremity
   a. Horizontally oriented superficial laceration of the distal posterior right arm, ½ x 1/8-inches
   b. Obliquely oriented (along the 5 to 11 o'clock axis) superficial laceration of the right elbow, 1 x ½-inches
   c. Cluster (2 x ½-inches) of superficial lacerations and abrasions on the proximal ulnar aspect of the right forearm measuring up to 2-inches in greatest dimensions
   d. Confluent contusion of the lateral right arm, dorsal right forearm, and dorsum of the right hand
   e. Contusions of the palmar surface of the right hand over the heads of the 4th-5th metacarpals (1 ¾ x 1-inches) and head of the 2nd metacarpal (1 x ¾-inches)
2. Left upper extremity
   a. Confluent contusion of the distal lateral left arm, dorsal left forearm, and dorsum of the left hand
   b. Contusions of the palmar aspects of the 4th and 5th digits of the left hand
   c. Confluent contusion of the left palm, 3 ¼ x 3-inches
   d. Fracture of the 3rd metacarpal of the left hand
3. Right lower extremity
   a. Horizontally oriented contusion on the anterior right thigh, 2 x ¾-inches
   b. Contusion above the lateral right patella, 1 ¼ x 1-inches
   c. Circular contusion of the medical right knee, 1-inch
   d. Contusion below the lateral right patella, 1 ½ x 1-inches
   e. Lacerations (2) on the proximal and middle anterior right leg, 3/16-inches each
   f. Confluent contusion on the dorsum of the right foot and lateral/anterior right leg (12 x 3 ½-inches)
   g. Contusion at the lateral right gluteal crease, 1 ½ x ¾-inches
   h. Multiple obliquely oriented (along the 1 to 8 o'clock axis) superficial linear contused abrasions on the posterior right thigh measuring up to 3 inches in greatest dimensions
   i. Contusion over the head of the right fibula, 1 ½ x ¾-inches
   j. Multiple (3) lacerations on the right lateral malleolus, 7/16 to 1-inch in greatest dimensions
   k. Fracture of the distal right fibula

ACLU Detainee DeathII ARMY MEDCOM 849

4. Left lower extremity
   a. Superficial abrasion (1 x ½-inches) with surrounding contusion (2 ½ x 1 ¾-inches) on the anterior left thigh
   b. Superficial laceration on the superior lateral left knee, ¾ x 1/16-inches
   c. Obliquely oriented (along the 4 to 10 o'clock axis) contused abrasion below the left knee, 4 ¼ x ¾-inches
   d. Superficial laceration on the proximal anterior left leg, 1 x ¾-inches
   e. Contusions (2) of the middle and distal anterior left leg, 2 ½ to 4-inches in greatest dimensions
   f. Multiple contusions and abrasions of the posterior left thigh and lateral left gluteal crease, 3/16 to 3-inches in greatest dimensions
   g. Multiple superficial contusions, abrasions, and lacerations of the left calf and lateral malleolus, ¼ to 1 ¾-inches in greatest dimensions
5. No evidence of ligature restraint is demonstrated

INTERNAL EXAMINATION

BODY CAVITIES:
The body is opened by the usual thoraco-abdominal incision and the chest plate is removed. The ribs, sternum, and vertebral bodies are visibly and palpably intact. No adhesions or abnormal collections of fluid are present in the pleural, pericardial, or peritoneal cavities. All body organs are present in their normal anatomic positions. There is no internal evidence of penetrating injury to the thoraco-abdominal region.

The subcutaneous fat layer of the abdominal wall is 3/4-inches thick.

HEAD AND CENTRAL NERVOUS SYSTEM:
Injuries to the scalp and face have been described. The scalp is reflected. The calvarium is intact, as is the dura mater beneath it. There are no epidural or subdural hemorrhages present. The leptomeninges are thin and delicate. Subarachnoid hemorrhage and injury to the frontal and occipital lobes have been described. The brain weighs 1430-grams. The cerebral hemispheres are symmetrical with unremarkable gyri and sulci. The structures at the base of the brain, including cranial nerves and blood vessels, are intact and unremarkable.

Coronal sections demonstrate sharp demarcation between white and grey matter. The ventricles are of normal size. The basal ganglia, brainstem, cerebellum, and arterial systems are free of non-traumatic abnormalities. The atlanto-occipital joint is stable.

NECK:
A layerwise dissection of the neck demonstrates the injuries described above. The thyroid cartilage and hyoid bone are intact. The larynx is lined by intact white mucosa.

Incision and dissection of the posterior neck demonstrates the injuries as described. There is no evidence of cervical spine fractures.

ACLU Detainee DeathII ARMY MEDCOM 850

Incision and dissection of the posterior neck demonstrates the injuries as described. There is no evidence of cervical spine fractures.

RESPIRATORY SYSTEM:
The upper airway is clear of debris and foreign material; the mucosal surfaces are smooth, yellow-tan and unremarkable. The pleural surfaces are smooth, glistening and unremarkable bilaterally. The pulmonary parenchyma is salmon pink, diffusely congested and edematous, exuding slight to moderate amounts of blood and frothy fluid. No mass lesions or areas of consolidation are present. The right and left lungs weigh 410 and 370-grams, respectively.

CARDIOVASCULAR SYSTEM:
The pericardial surfaces are smooth, glistening and unremarkable. The 310-gram heart is contained in an intact pericardial sac free of significant fluid or adhesions. The epicardial surface is smooth, with minimal fat investment. The coronary arteries arise normally, follow the usual distribution in a right dominant pattern, are widely patent, and without evidence of thrombosis or significant atherosclerosis. The myocardium is homogenous, red-brown, firm and unremarkable; the atrial and ventricular septae are intact. The walls of the left and right ventricles are 0.8 and 0.2-centimeters thick, respectively. The valve leaflets are thin and mobile. The aorta and its major branches arise normally, follow the usual course and are free of significant atherosclerosis or other abnormalities. The venae cavae and its major tributaries return to the heart in the usual distribution and are free of thrombi. The renal and mesenteric vessels are unremarkable.

HEPATOBILIARY SYSTEM:
The hepatic capsule is smooth, glistening and intact, covering dark red-brown, moderately congested parenchyma. No mass lesions or other abnormalities are noted. The gallbladder contains 4.0-milliliters of green-brown mucoid bile; the mucosa is velvety and unremarkable. The extrahepatic biliary tree is patent and without evidence of calculi. The liver weighs 1370-grams.

GASTROINTESTINAL TRACT:
The esophagus is intact and lined by smooth, grey-white mucosa. The gastric wall is intact and the stomach contains approximately 75-milliliters of thick dark brown fluid with partially digested rice. The gastric mucosa is arranged in the usual rugal folds. The duodenum, loops of small bowel and colon are unremarkable. The appendix is present.

GENITOURINARY SYSTEM:
The right and left kidneys weigh 130 and 110-grams, respectively. The renal capsules are smooth and thin, semi-transparent and strip with ease from the underlying smooth, red-brown cortical surface. The cut surfaces are red-tan and congested, with uniformly thick cortices and sharp corticomedullary junctions. The pelves and calyces are unremarkable. The ureters are normal in course and caliber. White bladder mucosa overlies an intact bladder wall. The bladder contains approximately 25-milliliters of clear yellow urine. The prostate is normal in size, with lobular, yellow-tan parenchyma. The seminal

ACLU Detainee DeathII ARMY MEDCOM 851

vesicles are unremarkable. The testes are free of mass lesions, contusions, or other abnormalities.

LYMPHORETICULAR SYSTEM:
The 160-gram spleen has a smooth, intact capsule covering maroon, moderately firm parenchyma; the lymphoid follicles are unremarkable. Lymph nodes in the hilar, periaortic, and iliac regions are not enlarged.

ENDOCRINE SYSTEM:
The pituitary gland is unremarkable. The thyroid is symmetric and red-brown, without cystic or nodular change. The pancreas is firm and yellow-tan, with the usual lobular architecture. No mass lesions or other abnormalities are noted. The right and left adrenal glands are symmetric, with bright yellow cortices and grey medullae. No masses or areas of hemorrhage are identified.

MUSCULOSKELETAL SYSTEM:
Muscle development appears normal. No non-traumatic bone or joint abnormalities are noted.

ADDITIONAL PROCEDURES

1. Documentary photographs are taken by OAFME staff photographers.
2. Specimens retained for toxicology testing and/or DNA identification are: Blood, vitreous fluid, urine, gastric contents, bile, heart, spleen, liver, lung, kidney, brain, adipose tissue, and skeletal muscle
3. Full body radiographs are obtained and demonstrate the above findings.
4. Selected portions of organs are retained in formalin.
5. The dissected organs are forwarded with the body.
6. Personal effects are released to the mortuary affairs representatives.

MICROSCOPIC EXAMINATION

Selected portions of organs are retained in formalin, without preparation of histologic slides.

ACLU Detainee DeathII ARMY MEDCOM 852

FINAL AUTOPSY DIAGNOSES:

I. Multiple blunt force injuries
   A. Blunt force injuries of the head and neck
      1. Cortical contusions of the left frontal and right occipital lobes of the brain
      2. Diffuse subarachnoid hemorrhage involving the convexities of the occipital lobes, both cerebellar hemispheres and the brainstem
      3. Superficial hemorrhage into the strap muscles of the anterior neck
      4. Multiple scalp and facial contusions, abrasions, and lacerations
   B. Blunt force injuries of the torso
      1. Multiple superficial lacerations, abrasions and contusions of the chest, back, and pelvis
      2. Multiple rib fractures
      3. Fracture of the spinous process of the 2nd thoracic vertebra with associated hemorrhage into the paraspinal muscles
      4. Near confluent hemorrhage into the superficial muscles of the back
   C. Blunt force injuries of the extremities
      1. Confluent contusions of the posterior arms, dorsal forearms, and anterior legs
      2. Multiple contusions, abrasions, and lacerations of all extremities.
      3. Contusions of the palms of both hands
      4. Fractures of the 3rd metacarpal of the left hand and the distal right fibula
      5. No evidence of restraint identified

II. No natural disease processes identified within the limitations of the examination.

III. No evidence of medical therapy is in place at the time of autopsy.

IV. Post-mortem changes
   A. Lividity is fixed on the posterior surface of the body except in areas exposed to pressure
   B. Rigor is present to an equal degree in all extremities
   C. Green discoloration of the skin of the abdomen is present
   D. Maceration and skin slippage of the extremities

V. Toxicology results: negative

ACLU Detainee DeathII ARMY MEDCOM 853

OPINION

This 16-year-old male detainee (b)(6) was interned at Camp Cropper Iraq. Initial investigative reports indicate that the unresponsive body (b)(6) was dragged to the compound gate by three unknown male detainees who fled the scene. Despite emergency medical intervention at the scene (b)(6) succumbed to his injuries.

Autopsy examination revealed that the decedent sustained multiple blunt force injuries. The most severe injuries were to the head and neck resulting in contusions and hemorrhage of the brain. The remaining injuries, although individually sub-lethal in nature and not injuring vital structures, in aggregate would have caused significant loss of blood.

Postmortem analysis of the body fluids was negative for the presence of ethanol, screened medications and screened drugs of abuse. There was no evidence of significant natural disease processes noted at the time of autopsy.

The manner of death is homicide.

(b)(6)

(b)(6) Medical Examiner

(b)(6)

(b)(6) Medical Examiner

ACLU Detainee DeathII ARMY MEDCOM 854

CERTIFICATE OF DEATH *(OVERSEAS)*
Acte de décès (D'Outre-Mer)

NAME OF DECEASED *(Last, First, Middle)* Nom du décédé (Nom et prénoms)	GRADE Grade	BRANCH OF SERVICE Arme	SOCIAL SECURITY NUMBER Numéro de l'Assurance Social
BTB Mustafi, Muhayman, Jalal		Civilian	(b)(6)

ORGANIZATION Organisation	NATION *(e.g. United States)* Pays	DATE OF BIRTH Date de naissance	SEX Sexe
	Iraq	(b)(6) 1990	[X] MALE [ ] FEMALE

RACE Race		MARITAL STATUS État Civil				RELIGION Culte			
[X]	CAUCASOID Caucasique	[ ]	SINGLE Célibataire	[ ]	DIVORCED Divorcé	[ ]	PROTESTANT Protestant	[X]	OTHER (Specify) Autre (Spécifier)
[ ]	NEGROID Negroide	[ ]	MARRIED Marié	[ ]	SEPARATED Séparé	[ ]	CATHOLIC Catholique		
[ ]	OTHER (Specify) Autre (Spécifier)	[ ]	WIDOWED Veuf			[ ]	JEWISH Juif		

NAME OF NEXT OF KIN Nom du plus proche parent	RELATIONSHIP TO DECEASED Parenté du décédé avec le sus
STREET ADDRESS Domicilé à (Rue)	CITY OR TOWN OR STATE *(Include ZIP Code)* Ville (Code postal compris)

MEDICAL STATEMENT Déclaration médicale

	CAUSE OF DEATH (Enter only one cause per line) Cause du décés (N'indiquer qu'une cause par ligne)	INTERVAL BETWEEN ONSET AND DEATH Intervalle entre l'attaque et le décés
DISEASE OR CONDITON DIRECTLY LEADING TO DEATH [1] Maladie ou condition directement responsable de la mort	Multiple blunt force injuries	Undetermined
ANTECEDENT CAUSES Symptômes précurseurs de la mort — MORBID CONDITION, IF ANY, LEADING TO PRIMARY CAUSE Condition morbide, s'il y a lieu, menant à la cause primaire		
ANTECEDENT CAUSES Symptômes précurseurs de la mort — UNDERLYING CAUSE, IF ANY, GIVING RISE TO PRIMARY CAUSE Condition morbide, s'il y a lieu, menant à la cause primaire		
OTHER SIGNIFICANT CONDITIONS [2] Autres conditions significatives		

MODE OF DEATH Condition de décés		AUTOPSY PERFORMED Autopsie effectuée [X] YES Oui [ ] NO Non	CIRCUMSTANCES SURROUNDING DEATH DUE TO EXTERNAL CAUSES Circonstances de la mort suscitées par des causes extérieures
[ ]	NATURAL Mort naturelle	MAJOR FINDINGS OF AUTOPSY Conclusions principales de l'autopsie	
[ ]	ACCIDENT Mort accidentelle		
[ ]	SUICIDE Suicide	NAME OF PATHOLOGIST Nom du pathologiste (b)(6)	
[X]	HOMICIDE Homicide	SIGNATURE (b)(6) — DATE Date 16 July 2007	AVIATION ACCIDENT Accident à Avion [ ] YES Oui [X] NO Non

DATE OF DEATH *(day, month, year)* Date de décés (le jour, le mois, l'année)	PLACE OF DEATH Lieu de décés
(b)(6) 2007 (b)(6)	Iraq

I HAVE VIEWED THE REMAINS OF THE DECEASED AND DEATH OCCURRED AT THE TIME INDICATED AND FROM THE CAUSES AS STATED ABOVE.
J'ai examiné les restes mortels du dé funtet je condus que le décés est survenu à l'heure indiquée et à, la suite des causes énumérées ci-dessus.

NAME OF MEDICAL OFFICER Nom du médicin militaire ou du médicin sanitaire	TITLE OR DEGREE Titre ou diplômé
(b)(6)	Medical Examiner

GRADE Grade	INSTALLATION OR ADDRESS Installation ou adresse
(b)(6)	Dover AFB, Dover DE
DATE Date 7/16/2007	SIGNATURE (b)(6)

[1] State disease, injury or complication which caused death, but not mode of dying such as heart failure, ect.
[2] State conditions contributing to the death, but not related to the disease or condition causing death.
[1] Préciser la nature de la maladie, de la blessure ou de la complication qui a contribué à la mort, mais non la manière de mourir, telle qu 'un arrêt du coeur, etc
[2] Préciser la condition qui a contribué à la mort, mais n'ayant aucun rapport avec la maladie ou à la condition qui a provoqué la mort.

DD FORM 1 APR 77 2064 REPLACES DA FORM 3565, 1 JAN 72 AND DA FORM 3565-R(PAS), 26 SEP 76, WHICH ARE OBSOLETE.

MEDCOM 0855

ACLU Detainee DeathII ARMY MEDCOM 855

(REMOVE, REVERSE AND RE-INSERT CARBONS BEFORE COMPLETING THIS SIDE)

DISPOSITON OF REMAINS

NAME OF MORTICIAN PREPARING REMAINS	GRADE	LICENSE NUMBER AND STATE	OTHER

INSTALLATION OR ADDRESS	DATE	SIGNATURE

NAME OF CEMETERY OR CREMATORY	LOCATION OF CEMETERY OR CREMATORY

TYPE OF DISPOSTION	DATE OF DISPOSTION

REGISTRATION OF VITAL STATISTICS

REGISTRY *(Town and Country)*	DATE REGISTERED	FILE NUMBER	
		STATE	OTHER

NAME OF FUNERAL DIRECTOR	ADDRESS

SIGNATURE OF AUTHORIZED INDIVIDUAL

DD FORM 2064, APR 1977 (BACK) *USAPA V1.00*

ARMED FORCES INSTITUTE OF PATHOLOGY
Office of the Armed Forces Medical Examiner
1413 Research Blvd., Bldg. 102
Rockville, MD 20850
301-319-0000

FINAL AUTOPSY REPORT

Name: Amhed. Rafah Abdul Al Kader
ISN (b)(6)
Date of Birt (b)(6) 1938
Date of Death (b)(6) 2007
Date/Time of Autopsy: 09 July 2007@1000
Date of Report: 23 Aug 2007

Autopsy No.: (b)(6)
AFIP No. (b)(6)
Rank: Detainee
Place of Death: Iraq
Place of Autopsy: Port Mortuary, Dover DE

Circumstances of Death: This 69 year old Iraqi detainee was admitted to the Theater Internment Hospital, Camp Bucca, on 07 June 2007 and was being treated for a reported tuberculosis infection. His condition deteriorated and he was transferred to the intensive care unit. He was pronounced dead o (b)(6) 2007.

Authorization for Autopsy: Armed Forces Medical Examiner, per 10 U.S. Code 1471

Identification: Presumptive identification is established by review of all paperwork in the case file. Postmortem fingerprints and a specimen suitable for DNA analysis are obtained.

CAUSE OF DEATH: **Metastatic Mucinous Adenocarcinoma**

MANNER OF DEATH: **Natural**

ACLU Detainee DeathII ARMY MEDCOM 857

EXTERNAL EXAMINATION

The body is that of a well-developed, well-nourished male. The body weighs 194 pounds, is 66 inches in length and appears compatible with the reported age of 69 years. The body is cold. Rigor is present to an equal degree in all extremities. Lividity is present and fixed on the posterior surface of the body, except in areas exposed to pressure.

The head is normocephalic, and the scalp hair is gray and one inch in length. Facial hair consists of moustache and beard. The irides are brown. The corneae are cloudy. The conjunctivae are unremarkable. The sclerae are white/yellow. The external auditory canals, external nares and oral cavity are free of foreign material and abnormal secretions. The ear lobes are not pierced. The nasal skeleton and maxilla are palpably intact. The lips are without evident injury. The teeth are natural and in fair condition. Examination of the neck reveals no evidence of injury. There is a 1 inch tan papule on the left cheek.

The chest is unremarkable. No evidence of injury of the ribs or the sternum is evident externally. The abdomen is soft and slightly protuberant. Healed surgical scars are not noted. The external genitalia are those of a normal adult male. There is a superficial decubitus ulcer on the mid-lower back, 2 ½ x 2 inches. The anus is without note.

The extremities show the presence of a few healed scars on the shin and a few contusions, but no evidence of fractures, lacerations or deformities. There is pitting edema of both legs and feet. The fingernails are intact. Tattoos are not noted.

CLOTHING AND PERSONAL EFFECTS

- No clothing or personal effects accompany the body.

MEDICAL INTERVENTION

- Triple lumen intravenous catheter on the right side of the neck
- Foley catheter with collection bag with brown urine in the bag
- EKG lead on the right side of the back
- Clear dressing on the mid-lower back
- Contusions on the abdomen and upper extremities associated with needle puncture sites

RADIOGRAPHS

A complete set of postmortem radiographs is obtained and demonstrates no fractures.

EVIDENCE OF INJURY

There is no evidence of recent significant injury.

ACLU Detainee DeathII ARMY MEDCOM 858

INTERNAL EXAMINATION

BODY CAVITIES:

The ribs, sternum, and vertebral bodies are visibly and palpably intact. No adhesions are present in any of the body cavities. There is approximately 250 ml of serosanguinous fluid in each of the pleural cavities. All body organs are present in normal anatomical position. The subcutaneous fat layer of the abdominal wall is 1 inch thick.

HEAD AND CENTRAL NERVOUS SYSTEM:

The galeal and subgaleal soft tissues of the scalp are free of injury. There are no skull fractures. The dura mater and falx cerebri are intact. There is no epidural or subdural hemorrhage present. The leptomeninges are thin, delicate and slightly opaque. The cerebral hemispheres are symmetrical. The structures at the base of the brain, including cranial nerves and blood vessels are intact. Clear cerebrospinal fluid surrounds the 1420-gram brain, which has unremarkable gyri and sulci. Coronal sections through the cerebral hemispheres reveal no lesions. Transverse sections through the brain stem and cerebellum are unremarkable. The atlanto-occipital joint is stable.

NECK:

The anterior strap muscles of the neck are homogenous and red-brown, without hemorrhage. The thyroid cartilage and hyoid bone are intact. The larynx is lined by intact white mucosa. The tongue is free of bite marks, hemorrhage, or other injuries.

CARDIOVASCULAR SYSTEM:

The 400-gram heart is contained in an intact pericardial sac. The epicardial surface is smooth, with minimal fat investment. The coronary arteries are present in a normal distribution, with a right-dominant pattern. Cross sections of the vessels show no significant atherosclerosis. The myocardium is homogenous, red-brown, and firm. The valve leaflets are thin and mobile. The endocardium is smooth and glistening. The aorta gives rise to three intact and patent arch vessels. The renal and mesenteric vessels are unremarkable.

RESPIRATORY SYSTEM:

The upper airway is clear of debris and foreign material. The mucosal surfaces are smooth, yellow-tan and unremarkable. The pleural surfaces are covered with purulent exudate bilaterally. There are multiple mass lesions palpable in all lobes of the lung. The pulmonary parenchyma is markedly congested and edematous, exuding moderate to large amounts of blood and frothy fluid. Sectioning reveals multiple non-caseating, tan-yellow mass lesions ranging in size from 0.6 cm to 5 x 3.75 cm. The pulmonary arteries are normally developed, patent and without thrombus or embolus. The right lung weighs 1040 grams; the left 790 grams.

ACLU Detainee DeathII ARMY MEDCOM 859

HEPATOBILIARY SYSTEM:

The 1450-gram liver has an intact smooth capsule covering tan-yellow, moderately congested parenchyma. There are numerous tan-yellow sub-capsular and deep mass lesions noted in the liver, ranging in size from 1.3 cm to 7.6 x 5 cm. The gallbladder contains 5 ml of green-brown, mucoid bile; the mucosa is velvety and unremarkable. The extrahepatic biliary tree is patent, without evidence of calculi.

GASTROINTESTINAL SYSTEM:

The esophagus is lined by gray-white, smooth mucosa. The gastric mucosa is arranged in the usual rugal folds and the lumen contains 300 ml of tan fluid. The lesser and greater curvatures of the distal stomach, the proximal duodenum, and the pancreas are firm and fibrotic, and are grossly involved by a tan-yellow mass lesion measuring 13 x 10 cm. The remainder of the small and large bowel is unremarkable. The appendix is present.

GENITOURINARY SYSTEM:

The right kidney weighs 120 grams; the left 120 grams. The renal capsules are smooth and thin, semi-transparent and stripped with ease from the underlying smooth, red-brown cortical surface. The cortex is sharply delineated from the medullary pyramids, which are red-purple to tan and unremarkable. The calyces, pelves and ureters are unremarkable. The bladder contains a Foley catheter and there is approximately 50 ml of brown urine in the collection bag. The testes, prostate gland and seminal vesicles are without note.

LYMPHORETICULAR SYSTEM:

The 70-gram spleen has a smooth, intact capsule covering red-purple, moderately firm parenchyma; the lymphoid follicles are unremarkable. There are numerous enlarged, tan-yellow lymph nodes in the hilar, periaortic, iliac, and retroperitoneal regions, ranging in size from 5 x 2.5 cm to 15 x 8 cm.

ENDOCRINE SYSTEM:

The thyroid gland is enlarged and red-brown, with diffuse cystic change. There are no distinct mass lesions identified. The right and left adrenal glands are symmetric, with bright yellow cortices and red-brown medullae. No areas of hemorrhage are identified.

MUSCULOSKELETAL SYSTEM:

No significant abnormalities of muscle or bone are identified.

ACLU Detainee DeathII ARMY MEDCOM 860

ADDITIONAL PROCEDURES

1. Documentary photographs are taken by OAFME staff photographers.
2. Specimens retained for toxicology testing and/or DNA identification are: blood, urine, kidney, spleen, liver, brain, bile, gastric contents, adipose tissue, heart, lung, and psoas muscle.
3. The dissected organs are forwarded with body.
4. Incisions of the posterior torso and posterior upper and lower extremities demonstrate no evidence of injury.

MICROSCOPIC EXAMINATION

Selected portions of organs are retained in formalin, with preparation of (7) histology slides.

Slide Key:

1-2. Retroperitoneal lymph nodes
3-5. Pancreas, stomach, small bowel
6. Liver
7. Lung

Lung, liver, stomach, pancreas, small bowel, and retroperitoneal lymph nodes: Metastatic mucinous adenocarcinoma

ACLU Detainee DeathII ARMY MEDCOM 861

FINAL AUTOPSY DIAGNOSES:

I. **Metastatic mucinous adenocarcinoma of the lungs, liver, stomach, pancreas, small bowel and numerous lymph nodes**

II. **Evidence of medical intervention: As listed above**

III. **Postmortem changes:**
- A. **Rigor mortis is present to an equal degree in all extremities**
- B. **Lividity is present and fixed on the posterior surface of the body, except in areas exposed to pressure**

IV. **No identifying marks or tattoos are identified**

V. **Toxicology (AFIP):**
- A. **Volatiles: No ethanol is detected in the blood and urine**
- B. **Drugs: Morphine, metoprolol, metoclopramide, and promethazine are detected in the urine but not in the blood**

OPINION

This 69 year old male, (b)(6) died of metastatic mucinous adenocarcinoma. There were mass lesions identified in the lungs, liver, pancreas, stomach, and proximal small bowel, in addition to numerous enlarged lymph nodes. There was no evidence of tuberculosis. There was no evidence of recent significant trauma. Toxicological studies were positive for medications consistent with hospitalization. The manner of death is natural.

(b)(6)

(b)(6) MEDICAL EXAMINER

(b)(6)

(b)(6) MEDICAL EXAMINER

ACLU Detainee DeathII ARMY MEDCOM 862

CERTIFICATE OF DEATH *(OVERSEAS)*
Acte de décès (D'Outre-Mer)

NAME OF DECEASED *(Last, First, Middle)* Nom du décédé (Nom et prénoms)	GRADE Grade	BRANCH OF SERVICE Arme	SOCIAL SECURITY NUMBER Numéro de l'Assurance Social
Amhed, Rafah, Abdul Al Kader		Civilian	(b)(6)

ORGANIZATION Organisation	NATION *(e.g. United States)* Pays	DATE OF BIRTH Date de naissance	SEX Sexe
Iraqi Detainee	Iraq		[X] MALE [ ] FEMALE

RACE Race		MARITAL STATUS État Civil			RELIGION Culte		
[X]	CAUCASOID Caucasique	[ ]	SINGLE Célibataire	[ ] DIVORCED Divorcé	[ ] PROTESTANT Protestant	[X]	OTHER (Specify) Autre (Spécifier)
[ ]	NEGROID Negroide	[ ]	MARRIED Marié	[ ] SEPARATED Séparé	[ ] CATHOLIC Catholique		
[ ]	OTHER (Specify) Autre (Spécifier)	[ ]	WIDOWED Veuf		[ ] JEWISH Juif		

NAME OF NEXT OF KIN Nom du plus proche parent	RELATIONSHIP TO DECEASED Parenté du décédé avec le sus
STREET ADDRESS Domicilié à (Rue)	CITY OR TOWN OR STATE *(Include ZIP Code)* Ville (Code postal compris)

MEDICAL STATEMENT Déclaration médicale

	CAUSE OF DEATH (Enter only one cause per line) Cause du décès (N'indiquer qu'une cause par ligne)	INTERVAL BETWEEN ONSET AND DEATH Intervalle entre l'attaque et le décès
DISEASE OR CONDITON DIRECTLY LEADING TO DEATH [1] Maladie ou condition directement responsable de la mort.	Metastatic Mucinous Adenocarcinoma	Weeks
ANTECEDENT CAUSES Symptômes précurseurs de la mort. MORBID CONDITION, IF ANY, LEADING TO PRIMARY CAUSE Condition morbide, s'il y a lieu, menant à la cause primaire		
UNDERLYING CAUSE, IF ANY, GIVING RISE TO PRIMARY CAUSE Condition morbide, s'il y a lieu, menant à la cause primaire		
OTHER SIGNIFICANT CONDITIONS [2] Autres conditions significatives [2]		

MODE OF DEATH Condition de décès	AUTOPSY PERFORMED Autopsie effectuée [X] YES Oui [ ] NO Non	CIRCUMSTANCES SURROUNDING DEATH DUE TO EXTERNAL CAUSES Circonstances de la mort suscitées par des causes extérieures
[X] NATURAL Mort naturelle	MAJOR FINDINGS OF AUTOPSY Conclusions principales de l'autopsie	
[ ] ACCIDENT Mort accidentelle		
[ ] SUICIDE Suicide	NAME OF PATHOLOGIST Nom du pathologiste (b)(6)	
[ ] HOMICIDE Homicide	SIGNATURE (b)(6) DATE Date 9 July 2007	AVIATION ACCIDENT Accident d Avion [ ] YES Oui [X] NO Non

DATE OF DEATH *(day, month, year)* Date de décès (le jour, le mois, l'année)	PLACE OF DEATH Lieu de décès
(b)(6) 2007 (b)(6)	Camp Bucca Iraq

I HAVE VIEWED THE REMAINS OF THE DECEASED AND DEATH OCCURRED AT THE TIME INDICATED AND FROM THE CAUSES AS STATED ABOVE.
J'ai examiné les restes mortels du dé funtet je conclus que le décès est survenu à l'heure indiquée et à, la suite des causes énumérées ci-dessus.

NAME OF MEDICAL OFFICER Nom du médicin militaire ou du médicin sanitaire	TITLE OR DEGREE Titre ou diplôme
(b)(6)	Medical Examiner
GRADE Grade (b)(6)	INSTALLATION OR ADDRESS Installation ou adresse Dover AFB, Dover DE
DATE Date 8/23/2007	SIGNATURE (b)(6)

[1] State disease, injury or complication which caused death, but not mod
[2] State conditions contributing to the death, but not related to the disease or condition causing death.
[1] Préciser la nature de la maladie, de la blessure ou de la complication qui a contribué à la mort, mais non la manière de mourir, telle qu 'un arrêt du coeur, etc
[2] Préciser la condition qui a contribué à la mort, mais n'ayant aucun rapport avec la maladie ou à la condition qui a provoqué la mort

DD FORM 1 APR 77 2064 REPLACES DA FORM 3565, 1 JAN 72 AND DA FORM 3565-R(PAS), 26 SEP 75, WHICH ARE OBSOLETE.

MEDCOM 0863

ACLU Detainee DeathII ARMY MEDCOM 863

(REMOVE, REVERSE AND RE-INSERT CARBONS BEFORE COMPLETING THIS SIDE)

DISPOSITON OF REMAINS

NAME OF MORTICIAN PREPARING REMAINS	GRADE	LICENSE NUMBER AND STATE	OTHER

INSTALLATION OR ADDRESS	DATE	SIGNATURE
(b)(6)		

NAME OF CEMETERY OR CREMATORY	LOCATION OF CEMETERY OR CREMATORY

TYPE OF DISPOSTION	DATE OF DISPOSTION

REGISTRATION OF VITAL STATISTICS

REGISTRY *(Town and Country)*	DATE REGISTERED	FILE NUMBER	
		STATE	OTHER

NAME OF FUNERAL DIRECTOR	ADDRESS

SIGNATURE OF AUTHORIZED INDIVIDUAL

DD FORM 2064, APR 1977 (BACK) *USAPA V1.00*

ACLU Detainee DeathII ARMY MEDCOM 864

ARMED FORCES INSTITUTE OF PATHOLOGY
Office of the Armed Forces Medical Examiner
1413 Research Blvd., Bldg. 102
Rockville, MD 20850
301-319-0000

FINAL AUTOPSY REPORT

Name: BTB Salih, Khatab Aswad
Detainee Number: (b)(6)
Date of Birth: Unknown
Date of Death (b)(6) 2007
Date/Time of Autopsy (b)(6) 2007 (b)(6)
Date of Report: 31 July 2007

Autopsy No.: (b)(6)
AFIP No.: (b)(6)
Rank: Civilian
Place of Death: Iraq
Place of Autopsy: Port Mortuary, Dover AFB, Dover, DE

Circumstances of Death: This Iraqi civilian was reportedly shot multiple times by US Army soldiers on 23 June 2007. He was transported to the 506th Expeditionary Medical Squadron where he underwent surgery for gunshot wounds. He was transferred to the 399th Combat Support Hospital for further treatment, where he died on (b)(6) 2007.

Authorization for Autopsy: Armed Forces Medical Examiner, per 10 U.S. Code 1471

Identification: Presumptive identification is established by examination of paperwork in the case file. Post-mortem fingerprints and a specimen suitable for DNA analysis are obtained.

CAUSE OF DEATH: **Multiple Gunshot Wounds**

MANNER OF DEATH: **Homicide**

ACLU Detainee DeathII ARMY MEDCOM 865

EXTERNAL EXAMINATION

The body is that of a well-developed, well-nourished unclad male. The body weighs 213 pounds and is 70 inches in length. The body is cold. Rigor is absent. Lividity is present and fixed on the anterior and posterior surface of the body, except in areas exposed to pressure.

The head is normocephalic, and the scalp hair is 1 inch in length, straight and black. Facial hair consists of moustache and beard. The irides are brown. The corneae are cloudy. The conjunctivae are congested. The sclerae are suffused. The external auditory canals, external nares and oral cavity are free of foreign material and abnormal secretions. The nasal skeleton and maxilla are palpably intact. The lips are without evident injury. The teeth are natural and in good condition. Examination of the neck reveals no evidence of injury.

The chest is unremarkable. No evidence of injury of the ribs or the sternum is evident externally. The abdomen is soft and slightly protuberant. Healed surgical scars are not noted. The external genitalia are those of a normal adult circumcised male. The anus is without note.

The distal phalanx of the left 3rd digit is absent. The fingernails are intact. There is edema of the upper extremities. There is skin slippage of the upper and lower extremities. There are multiple bullae on the lower extremities, ranging in size from ½-inch to 1 ½-inches. There are a few healed scars on the shins. Tattoos are not noted.

CLOTHING AND PERSONAL EFFECTS

- No clothing or personal effects are received with the body

MEDICAL INTERVENTION

- Triple lumen intravenous catheter with overlying dressing, left subclavian region
- Intraosseous catheter puncture site, sternum
- Chest tube (left sixth intercostal space), with a 2-inch sutured incision
- Vertical incision, 12 1/2 x 1 ½-inches, extending from the midchest to the mid-abdomen
- Wrapping, gauze, and armboard, right arm and forearm
- Wrapping and gauze, left arm and forearm
- Gauze dressing on the left side of the abdomen
- Intravenous catheter in the right femoral region
- Foley catheter with attached collection bag
- Multiple surgical clips noted in the head, torso, and extremities
- Debrided wound on the right shoulder, 2 1/2 x 2-inches
- Surgical absence of the left kidney and re-anastomosis of the descending colon

ACLU Detainee DeathII ARMY MEDCOM 866

RADIOGRAPHS

A complete set of post-mortem radiographs is obtained and demonstrates the medical intervention as described above. Please see "Evidence of Injury" for further radiologic findings.

EVIDENCE OF INJURY

The ordering of the following injuries is for descriptive purposes only, and is not intended to imply order of infliction or relative severity. All wound pathways are given relative to standard anatomic position.

I. Multiple (5) Gunshot Wounds:

A. Superficial perforating gunshot wound of the head:
On the right cheek is a 3/4 x 5/16-inch gunshot entrance wound with a 1/16-1/8-inch inferior-medial marginal abrasion. The center of the wound is located 5 ½-inches below the top of the head and 2 ½-inches right of the anterior midline. There is no gunpowder stippling or soot deposition on the surrounding skin. The bullet injures skin and subcutaneous tissue. There is a 1 1/4 x ¼-inch gunshot exit wound on the right side of the face, the center of which is located 4 ½-inches below the top of the head and 4 ½-inches right of the anterior midline. No bullet or bullet fragments are recovered. The direction of the wound path is front to back, left to right, and upwards. Associated injuries include a 3/4 x 1/16-inch graze gunshot wound on the helix of the right ear with a 3/16-inch marginal abrasion, located 4-inches below the top of the head and 6 ¾-inches right of the anterior midline, and hemorrhage along the wound path.

B. Gunshot wound of the face:
On the left cheek is a 1/8-inch in diameter circular gunshot entrance wound with a 1/8-inch circumferential marginal abrasion, located 5-inches below the top of the head and 2 ¾-inches left of the anterior midline. There is no gunpowder stippling or soot deposition on the surrounding skin. The bullet injures skin, subcutaneous tissue, left zygoma and left maxilla, soft tissues of the face, sphenoid bone, and the mastoid process of the right temporal bone (fractured). There is a 3/4 x ¼-inch irregular gunshot exit wound posterior to the right ear with an associated 1 1/2 x ¼-inch superior abrasion, centered 5 ½-inches below the top of the head, and 4-inches right of the posterior midline. No bullet or bullet fragments are recovered. The direction of the wound path is front to back, left to right, and downward. Associated injuries include right parietal subdural hemorrhage (approximately 2 ml), contusion of the right parietal/temporal lobe, subarachnoid hemorrhage of both parietal lobes, the right temporal lobe, and right cerebellum, fracture of the right temporal bone of the calvarium, fractures of the right middle and posterior cranial fossae, and hemorrhage of the right temporalis muscle.

ACLU Detainee DeathII ARMY MEDCOM 867

C. Gunshot wound of the back:
On the lower left back is a 3/16-inch circular gunshot entrance wound with a 1/16-inch circumferential marginal abrasion, located 30 ½-inches below the top of the head and 2 ½- inches left of the posterior midline. There is no gunpowder stippling or soot deposition on the surrounding skin. The bullet injures skin, subcutaneous tissue, left psoas muscle, descending colon (surgically re-anastomosed), small bowel (re-anastomosed on 23 June 2007 per operative note), and abdominal wall. The left kidney and left adrenal gland are surgically absent and cannot be evaluated for injury. There are three gunshot exit wounds on the upper left side of the abdomen. The superior wound is ¼-inch in diameter, and is located 23 ¾-inches below the top of the head and 2 ¼-inches left of the anterior midline. The middle wound is 7/16-inch in diameter, and is located 25 ¼-inches below the top of the head and 2 ½-inches left of the anterior midline. The inferior wound is 3/16-inch in diameter, and is located 25 ¾-inches below the top of the head and 2 ½-inches left of the anterior midline. A metal fragment is recovered from the subcutaneous tissue underneath the middle exit wound. The direction of the wound path is back to front and upward, with no significant left/right deviation. Associated injury includes hemorrhage along the wound path.

D. Gunshot wound of the right arm:
On the anterior right arm is a 1/2 x ¼-inch oval gunshot entrance wound with a 1 x ¼-inch superior and lateral marginal abrasion, centered 8-inches below the top of the shoulder and ½-inch left of the anterior midline of the arm. There is no soot deposition or gunpowder stippling on the surrounding skin. The bullet injures skin, soft tissue, and the right humerus (fractured). There is a 3 ¼ x 1 ¾-inch gunshot exit wound on the posterior right arm, centered 6 ½-inches below the top of the shoulder and 3-inches right of the posterior midline of the arm. No bullet or bullet fragments are recovered. The direction of the wound path is front to back, left to right, and upward (with the upper extremity in anatomic position). Associated injury includes hemorrhage along the wound path.

E. Gunshot wound of the left arm:
On the posterior left arm is a 3/16-inch in diameter gunshot entrance wound located 10 ½-inches below the top of the shoulder and 2 ½-inches left of the posterior midline of the arm. There is no soot deposition or gunpowder stippling on the surrounding skin. The bullet injures skin and soft tissue. There is a 2 ¾ x 1 ¼-inch gunshot exit wound on the medial aspect of the left elbow, centered 14-inches below the top of the shoulder and 2 ½-inches right of the posterior midline of the arm. No bullet or bullet fragments are recovered. The direction of the wound path is back to front, left to right, and downward (with the upper extremity in anatomic position). Associated injury includes hemorrhage along the wound path.

II. Additional Injuries: There is a 2 ½ x 2-inch debrided wound on the right shoulder. There is a ¾ x ½-inch abrasion on the right knee. There is a ½-inch abrasion on the anterior right leg.

ACLU Detainee DeathII ARMY MEDCOM 868

INTERNAL EXAMINATION

BODY CAVITIES:

The body is opened by the usual thoraco-abdominal incision and the chest plate is removed. The ribs, sternum, and vertebral bodies are visibly and palpably intact. There is 50 ml of serosanguinous fluid in the right pleural cavity. There is 50 ml of serosanguinous fluid in the peritoneal cavity. There are bilateral posterior pleural adhesions. All body organs are present in normal anatomical position. The subcutaneous fat layer of the abdominal wall is 1 inch thick.

HEAD AND CENTRAL NERVOUS SYSTEM:

See "Evidence of Injury". The scalp is reflected. The calvarium of the skull is removed. The dura mater and falx cerebri are intact. There is no epidural hemorrhage present. The leptomeninges are thin and delicate. The cerebral hemispheres are symmetrical. The structures at the base of the brain, including cranial nerves and blood vessels are intact. The brain weighs 1480 grams. Coronal sections through the cerebral hemispheres reveal no non-traumatic lesions. Transverse sections through the brain stem and cerebellum are unremarkable. The atlanto-occipital joint is stable.

NECK:

The anterior strap muscles of the neck are homogenous and red-brown, without hemorrhage. The thyroid cartilage and hyoid bone are intact. The larynx is lined by intact white mucosa. The tongue is free of bite marks, hemorrhage, or other injuries. Incision and dissection of the posterior neck demonstrates no deep paracervical muscular injury and no cervical spine fractures.

CARDIOVASCULAR SYSTEM:

The 390 gram heart is contained in an intact pericardial sac. The epicardial surface is smooth, with minimal fat investment. The coronary arteries are present in a normal distribution, with a right-dominant pattern. Cross sections of the vessels show no significant atherosclerosis. The myocardium is homogenous, red-brown, and firm. The endocardium is smooth and glistening. The aorta gives rise to three intact and patent arch vessels. The renal and mesenteric vessels are unremarkable.

RESPIRATORY SYSTEM:

The upper airway is clear of debris and foreign material: the mucosal surfaces are smooth, yellow-tan and unremarkable. The pulmonary parenchyma is diffusely congested and edematous, exuding moderate to large amounts of blood and frothy fluid; no focal lesions are noted. The pulmonary arteries are normally developed, patent and without thrombus or embolus. The right lung weighs 980 grams; the left 850 grams.

ACLU Detainee DeathII ARMY MEDCOM 869

HEPATOBILIARY SYSTEM:

The 1670 gram liver has an intact smooth capsule covering dark red-brown, moderately congested parenchyma with no focal lesions noted. The gallbladder contains 10 ml of green-brown, mucoid bile; the mucosa is velvety and unremarkable. The extrahepatic biliary tree is patent, without evidence of calculi.

GASTROINTESTINAL SYSTEM:

See "Evidence of Injury". The esophagus is lined by gray-white, smooth mucosa. The gastric mucosa is arranged in the usual rugal folds and the lumen contains 30 ml of tan fluid.
No non-traumatic lesions of the small bowel and colon are identified. The pancreas has a normal pink-tan lobulated appearance and the ducts are clear. The appendix is present.

GENITOURINARY SYSTEM:

See "Evidence of Injury". The right kidney weighs 180 grams; the left kidney is absent. The renal capsule is smooth and thin, semi-transparent and stripped with ease from the underlying smooth, red-brown cortical surface. The cortex is sharply delineated from the medullary pyramids, which are red-purple to tan and unremarkable. The calyx, pelvis and ureter are unremarkable. White bladder mucosa overlies an intact bladder wall. The bladder contains approximately 20 ml of clear, yellow/dark urine. The testes, prostate gland and seminal vesicles are without note.

LYMPHORETICULAR SYSTEM:

The 210 gram spleen has a smooth, intact capsule covering red-purple, moderately firm parenchyma; and the lymphoid follicles are unremarkable. Lymph nodes in the hilar, periaortic and iliac regions are not enlarged.

ENDOCRINE SYSTEM:

See "Evidence of Injury". The thyroid gland is symmetric and red-brown, without cystic or nodular change. The right adrenal gland is symmetric, with bright yellow cortices and red-brown medullae. The left adrenal gland is absent. No masses or areas of hemorrhage are identified.

MUSCULOSKELETAL SYSTEM:

See "Evidence of Injury". No non-traumatic abnormalities of muscle or bone are identified.

ACLU Detainee DeathII ARMY MEDCOM 870

ADDITIONAL PROCEDURES

1. Documentary photographs are taken by OAFME staff photographers.
2. Specimens retained for toxicology testing and/or DNA identification are: vitreous fluid, blood, urine, spleen, brain, bile, gastric contents, psoas muscle, heart, lung, liver, kidney, and adipose tissue.
3. The dissected organs are forwarded with the body.
4. Trace evidence is collected and retained by Special Agent (b)(6) US Army CID.
5. Incisions of the posterior torso and posterior upper and lower extremities demonstrate no evidence of injury.

MICROSCOPIC EXAMINATION

Selected portions of organs are retained in formalin, without preparation of histology slides.

ACLU Detainee DeathII ARMY MEDCOM 871

FINAL AUTOPSY DIAGNOSES:

I. **Multiple (5) gunshot wounds:**
   - A. **Superficial perforating gunshot wound of the head:**
     1. **Entrance: Right cheek; no soot or gunpowder stippling on the skin**
     2. **Injury: Skin and subcutaneous tissue**
     3. **Exit: Right side of the face**
     4. **Recovered: No bullet or bullet fragments**
     5. **Wound path: Front to back, left to right, and upward**
     6. **Associated injuries: Graze gunshot wound of the right ear and hemorrhage along the wound path**

   - B. **Gunshot wound of the head:**
     1. **Entrance: Left cheek; no soot or gunpowder stippling on the skin**
     2. **Injury: Skin, soft tissue, left zygoma and maxilla, sphenoid bone, and right mastoid process**
     3. **Exit: Posterior to the right ear**
     4. **Recovered: No bullet or bullet fragments**
     5. **Wound path: Front to back, left to right, and downward**
     6. **Associated injuries: Subdural and subarachnoid hemorrhage, skull fractures, and contusions of the brain**

   - C. **Gunshot wound of the back:**
     1. **Entrance: Lower left back; no soot or gunpowder stippling on the skin**
     2. **Injury: Skin, subcutaneous tissue, left psoas muscle, descending colon, small bowel, and abdominal wall (The left kidney and adrenal gland are surgically absent and cannot be evaluated for injury)**
     3. **Exit wounds (3): Upper left side of the abdomen**
     4. **Recovered: Metal fragment from the subcutaneous tissue of the left side of the abdomen**
     5. **Wound path: Back to front and upward, without significant left/right deviation**
     6. **Associated injury: Hemorrhage along the wound path**

   - D. **Gunshot wound of the right arm:**
     1. **Entrance: Anterior right arm; no soot or gunpowder stippling on the skin**
     2. **Injury: Skin, soft tissue, and right humerus**
     3. **Exit: Posterior right arm**
     4. **Recovered: No bullet or bullet fragments**
     5. **Wound path: Front to back, left to right, and upwards**
     6. **Associated injury: Hemorrhage along the wound path**

   - E. **Gunshot wound of the left arm:**
     1. **Entrance: Posterior left arm; no soot or gunpowder stippling on the skin**
     2. **Injury: Skin and soft tissue**
     3. **Exit: Medial left elbow**
     4. **Recovered: No bullet or bullet fragments**
     5. **Wound path: Back to front, left to right, and downward**
     6. **Associated injury: Hemorrhage along the wound path**

ACLU Detainee DeathII ARMY MEDCOM 872

II. Additional Injuries:
- **A. Debrided wound of the right shoulder, 2 ½ x 2-inches**
- **B. Abrasions of the right lower extremity, ranging in size from 1/2 to 3/4 x ½ inch**

III. No significant natural disease is identified within the limitations of this autopsy

IV. Evidence of Medical Intervention: Present as described above

V. Post-mortem changes: Skin slippage of the upper and lower extremities and multiple bullae of the lower extremities

VI. Identifying marks and tattoos: None identified

VII. Toxicology (AFIP):
- **A. Volatiles: No ethanol is detected in the blood and vitreous fluid**
- **B. Drugs: Midazolam is detected in the urine and quantitated in the blood at a concentration of 0.027 mg/L. 1-Hydroxymidazolam is detected in the urine but not the blood. Morphine is detected in the urine and quantitated in the blood at a concentration of 0.49 mg/L.**
- **C. Carbon Monoxide: The carboxyhemoglobin saturation in the blood is less than 1%**
- **D. Cyanide: No cyanide is detected in the blood**

OPINION

This Iraqi detainee, BTB (b)(6) died of multiple (5) gunshot wounds of the head (2), torso (1), right upper extremity (1), and left upper extremity (1). Gunshot wound (A) of the head was a superficial perforating wound and injured skin and subcutaneous tissue only. Gunshot wound (B) of the head injured the soft tissues of the face and was associated with skull fractures and injury to the brain. Gunshot wound (C) of the back injured soft tissue, small bowel, and the descending colon. The left kidney and adrenal gland were surgically absent and could not be evaluated for injury. The three exit wounds associated with gunshot wound (C) are consistent with bullet fragmentation. Gunshot wound (D) of the right arm injured soft tissue and the right humerus. Gunshot wound (E) of the left arm injured soft tissue. There was no evidence of close range discharge of a firearm on the skin surrounding any of the gunshot entrance wounds. A metal fragment was recovered associated with gunshot wound (C), placed into a labeled evidence container, and retained by Special Agent (b)(6) US Army CID. Toxicological findings did not contribute to the cause and manner of death. The manner of death is homicide.

(b)(6)

(b)(6) MEDICAL EXAMINER

(b)(6)

(b)(6) MEDICAL EXAMINER (b)(6)

ACLU Detainee DeathII ARMY MEDCOM 873

CERTIFICATE OF DEATH *(OVERSEAS)*
Acte dé décès (D'Outre-Mer)

NAME OF DECEASED (Last, First, Middle) Nom du décédé (Nom et prénoms)	GRADE Grade	BRANCH OF SERVICE Arme	SOCIAL SECURITY NUMBER Numéro de l'Assurance Social
BTB Salih, Khatab, Aswad		Civilian	(b)(6)
ORGANIZATION Organisation	**NATION** (e.g. United States) Pays: Iraq	**DATE OF BIRTH** Date de naissance	**SEX** Sexe: [X] MALE [ ] FEMALE

RACE Race		MARITAL STATUS État Civil				RELIGION Culte			
[X]	CAUCASOID Caucasique	[ ]	SINGLE Célibataire	[ ]	DIVORCED Divorcé	[ ]	PROTESTANT Protestant	[X]	OTHER (Specify) Autre (Spécifier)
[ ]	NEGROID Negroide	[ ]	MARRIED Marié	[ ]	SEPARATED Séparé	[ ]	CATHOLIC Catholique		
[ ]	OTHER (Specify) Autre (Spécifier)	[ ]	WIDOWED Veuf			[ ]	JEWISH Juif		

NAME OF NEXT OF KIN Nom du plus proche parent	RELATIONSHIP TO DECEASED Parenté du décéde avec le sus
STREET ADDRESS Domicilié à (Rue)	CITY OR TOWN OR STATE (Include ZIP Code) Ville (Code postal compris)

MEDICAL STATEMENT Déclaration médicale

	CAUSE OF DEATH (Enter only one cause per line) Cause du décés (N'indiquer qu'une cause par ligne)	INTERVAL BETWEEN ONSET AND DEATH Intervalle entre l'attaque et le décés
DISEASE OR CONDITON DIRECTLY LEADING TO DEATH [1] Maladie ou condition directement responsable de la mort [1]	Multiple gunshot wounds	Days
ANTECEDENT CAUSES — MORBID CONDITION, IF ANY, LEADING TO PRIMARY CAUSE Condition morbide, s'il y a lieu, menant à la cause primaire		
Symptômes précurseurs de la mort — UNDERLYING CAUSE, IF ANY, GIVING RISE TO PRIMARY CAUSE Condition morbide, s'il y a lieu, menant à la cause primaire		
OTHER SIGNIFICANT CONDITIONS [2] Autres conditions significatives [2]		

MODE OF DEATH Condition de décés	AUTOPSY PERFORMED Autopsie effectuée [X] YES Oui [ ] NO Non	CIRCUMSTANCES SURROUNDING DEATH DUE TO EXTERNAL CAUSES Circonstances de la mort suscitées par des causes extérieures
[ ] NATURAL Mort naturelle	MAJOR FINDINGS OF AUTOPSY Conclusions principales de l'autopsie	
[ ] ACCIDENT Mort accidentalle		
[ ] SUICIDE Suicide	NAME OF PATHOLOGIST Nom du pathologiste: (b)(6)	
[X] HOMICIDE Homicide	SIGNATI (b)(6) — DATE Date: 1 July 2007	AVIATION ACCIDENT Accident à Avion: [ ] YES Oui [X] NO Non

DATE OF DEATH (day, month, year) Date de décés (le jour, le mois, l'année)	PLACE OF DEATH Lieu de décés
(b)(6) 2007 (b)(6)	Iraq

I HAVE VIEWED THE REMAINS OF THE DECEASED AND DEATH OCCURRED AT THE TIME INDICATED AND FROM THE CAUSES AS STATED ABOVE.
J'ai examiné les restes mortels du dé funtet je conclus que le décés est survenu à l'heure indiquée et à, la suite des causes énumérées ci-dessus.

NAME OF MEDICAL OFFICER Nom du médicin militaire ou du médicin sanitaire	TITLE OR DEGREE Titre ou diplôme
(b)(6)	Medical Examiner
GRADE Grade: (b)(6)	INSTALLATION OR ADDRESS Installation ou adresse: Dover AFB, Dover DE
DATE Date: 7/1/2007	SIGNATUR (b)(6)

[1] State disease, injury or complication which caused death, but not mode of dying such as heart failure, ect.
[2] State conditions contributing to the death, but not related to the disease or condition causing death.
[1] Préciser la nature de la maladie, de la blessure ou de la complication qui a contribué à la mort, mais non la manière de mourir, telle qu 'un arrêt du coeur, etc
[2] Préciser la condition qui a contribué à la mort, mais n'ayant aucun rapport avec la maladie ou à la condition qui a provoqué la mort.

DD FORM 1 APR 77 **2064** REPLACES DA FORM 3565, 1 JAN 72 AND DA FORM 3565-R(PAS), 26 SEP 75, WHICH ARE OBSOLETE.

MEDCOM 0874

ACLU Detainee DeathII ARMY MEDCOM 874

(REMOVE, REVERSE AND RE-INSERT CARBONS BEFORE COMPLETING THIS SIDE)

DISPOSITON OF REMAINS

NAME OF MORTICIAN PREPARING REMAINS	GRADE	LICENSE NUMBER AND STATE	OTHER

INSTALLATION OR ADDRESS	DATE	SIGNATURE

NAME OF CEMETERY OR CREMATORY	LOCATION OF CEMETERY OR CREMATORY

TYPE OF DISPOSTION	DATE OF DISPOSTION

REGISTRATION OF VITAL STATISTICS

REGISTRY *(Town and Country)*	DATE REGISTERED	FILE NUMBER	
		STATE	OTHER

NAME OF FUNERAL DIRECTOR	ADDRESS

SIGNATURE OF AUTHORIZED INDIVIDUAL

DD FORM 2064, APR 1977 (BACK) *USAPA V1.00*

ACLU Detainee DeathII ARMY MEDCOM 875

ARMED FORCES INSTITUTE OF PATHOLOGY
Office of the Armed Forces Medical Examiner
1413 Research Blvd., Bldg. 102
Rockville, MD 20850
1-301-319-0000

FINAL AUTOPSY EXAMINATION REPORT

Name: (BTB) AL-UMARI, Abd Al-Rahman M.
ISN: (b)(6)
Date of Birth: (BTB) (b)(6) 1972
Date of Death: (b)(6) 2007

Autopsy No.: (b)(6)
AFIP No.: (b)(6)
Rank: Civilian Detainee
Place of Death: Camp V, Guantanamo Bay, Cuba

Date/Time of Autopsy: 01 JUN 2007 @ 1230
Date of Report: 20 JUN 2007

Place of Autopsy: Guantanamo Bay, Cuba

Circumstances of Death: This 35-year-old male civilian detainee at Guantanamo Bay, Cuba was found hanging by his neck in his cell with a ligature made of braided strips of bed sheet. By report, similar fabric bound his hands loosely behind him. Although ACLS protocols were followed, he could not be resuscitated.

Authorization for Autopsy: Office of the Armed Forces Medical Examiner, IAW 10 USC 1471.

Identification: Positive identification of the ISN number is established by comparison of a postmortem DNA sample and antemortem DNA records.

CAUSE OF DEATH: **HANGING**

MANNER OF DEATH: **SUICIDE**

ACLU Detainee DeathII ARMY MEDCOM 876

FINAL AUTOPSY DIAGNOSES

I. Evidence of Hanging

A. The suspected ligature had been removed from the body prior to examination. It is available for inspection and consists of a 22-1/2-inch, three-strand braided ligature composed of white cotton material. The ligature measures on average, ¾-inch wide and ½-inch thick. At one end of the ligature is a loop formed by tying the ligature to itself. Eight inches from the loop end is a 4-inch area of soiling with attached dark hairs.

B. A brown to gray – tan, 9 1/8-inch discontinuous ligature furrow is on the skin of the neck and is directed obliquely upward at approximately 45-degrees on both sides of the neck

C. The ligature furrow crosses the superior third of the thyroid cartilage, 9 3/8-inches below the top of the head and then extends superiorly on both sides of the neck, ending 1-inch below the lobe of the right ear and passing 2-inches below the lobe of the left ear.

D. The highest point of the furrow is located on the back of the neck, 6 ½-inches below the top of the head and on the posterior midline

E. The width of the ligature furrow ranges from ¾-inch to 3/8-inch.

F. The depth of the furrow ranges from less than 1/16-inch (posterior) to 1/8-inch (left)

G. There is a 1 ¼ x 5/8-inch abrasion on the right side of the neck

H. A layer-wise anterior neck dissection shows no injury to the underlying soft tissues or hemorrhage into the strap muscles. The hyoid bone and thyroid cartilage are intact

I. Associated injuries:
   1. The face is suffused with scattered petechiae on the skin
   2. Petechiae on the bulbar and palpebral conjunctivae, bilateral

II. Other Injuries

A. Superficial, incised wound on the right second (fore) finger, 1/8-inch

B. Superficial, incised wound on the left second (fore) finger, ¼-inch

C. Abrasion on the right thumb, 1/8 x 1/16-inch

D. Cluster of abrasions on the posterior right forearm, ranging in size from punctate to ¼ x 1/16-inch

III. There is no evidence of physical abuse

A. A complete skeletal survey is negative for fractures by radiology

B. Radiographs of the cervical spine are negative for fractures or dislocations

C. Posterior neck dissection is negative for soft tissue or bony

D. Posterior incisions of the torso and extremities are negative for soft tissue injury

E. There is no soft tissue evidence of recent binding around the wrists.

ACLU Detainee DeathII ARMY MEDCOM 877

IV. No significant natural diseases or pre-existing conditions are identified within the limitations of this examination

V. Evidence of Medical Therapy
- A. Endotracheal tube (properly placed)
- B. Cardiac pacing pads on the anterior and left chest
- C. Multiple electrocardiogram electrodes on the anterior torso and both arms
- D. Needle stick-marks in both antecubital fossae and on the dorsal surfaces of the left hand and right foot

VI. Post-Mortem Changes
- A. Rigor is passing and equal in all extremities
- B. Lividity is posterior and fixed except in areas exposed to pressure
- C. The body temperature is cold to touch, status post refrigeration

VII. Identifying Body Marks
- A. Puckered, circular scar on the medial right wrist, 1-inch diameter
- B. Puckered scar on the medial left wrist, 1 ½ x 1 ¼-inch
- C. Pigmented papule on the right back, 1/8-inch diameter
- D. Pigmented papule on the right buttock, 1/16-inch diameter
- E. Linear pigmentation on the left buttock, ½ x 1/16-inch

VIII. Toxicology
- A. The blood and vitreous fluid are tested for ethanol and none is found.
- B. The urine is negative for screened medications (including Mefloquine) and drugs of abuse and none are found.
- C. The blood is tested for carbon monoxide and cyanide and none is found.

EXTERNAL EXAMINATION

The body is that of a well-developed, well-nourished appearing, thin, 66-inch, 140-pounds (estimated) male whose appearance is younger than the reported age of 35-years. Lividity is posterior and violaceous except in areas exposed to pressure. Rigor is full and equal in all extremities. The temperature of the body is that of the refrigeration unit.

The head is normocephalic altered and the scalp is covered with dark hair in a normal distribution. The skin of the face is congested and suffused with scattered petechiae. Facial hair consists of a full beard and moustache. The irides are brown, the corneae are hazy and the pupils are round and equal in diameter. The conjunctivae have petechiae scattered on both the bulbar and palpebral surfaces, bilaterally. The external auditory canals are patent and free of foreign material. The ears are unremarkable. The nares are patent and the lips are atraumatic. The nose and maxillae are palpably stable. The teeth appear natural and in good condition.

Injuries to the neck are described below (see "Evidence of Injury"). The neck is straight, and the trachea is midline and mobile. The chest is symmetric and the abdomen is flat.

ACLU Detainee DeathII ARMY MEDCOM 878

The posterior torso is unremarkable. The genitalia are those of a normal adult male. The penis appears to have been circumcised and the testes are descended and free of masses. Pubic hair is shaved, but present in a normal distribution. The buttocks and anus are unremarkable. There are pigmented papules on the right back (1/8-inch diameter) and on the right buttock (1/16-inch diameter). There is an area of linear pigmentation on the left buttock that measures ½ x 1/16-inch.

The upper and lower extremities are symmetric and without clubbing or edema. The fingernails and toenails are trimmed and intact and are otherwise unremarkable. The following minor injuries are noted on the extremities: There is a superficial, incised wound on the right second (fore) finger that measures 1/8-inch and a superficial, incised wound on the left second (fore) finger that measures ¼-inch. There is an abrasion on the right thumb (1/8 x 1/16-inch) and a cluster of abrasions on the posterior right forearm, ranging in size from punctate to ¼ x 1/16-inch. A puckered, circular scar on the medial right wrist (1-inch diameter) and a puckered scar on the medial left wrist (1 ½ x 1 ¼-inch) are noted.

CLOTHING AND PERSONAL EFFECTS

The following clothing items and personal effects are present on the body at the time of autopsy:

- Brown shorts
- An identification bracelet accompanies the remains, but is not attached to an extremity

MEDICAL INTERVENTION

- Endotracheal tube (properly located in the trachea, above the carina)
- Cardiac pacing pads are located on the anterior right chest and the left lateral chest
- Electrocardiogram electrodes are on the anterior torso and the extremities
- Needle stick-marks are located in both antecubital spaces, the dorsum of the left hand, and the dorsal right foot

RADIOGRAPHS

A complete set of postmortem radiographs is obtained and demonstrates the following:

- No fractures of the skull, axial skeleton or long bones
- No metallic foreign bodies
- Medical therapy (endotracheal tube)

ACLU Detainee DeathII ARMY MEDCOM 879

EVIDENCE OF INJURY

Evidence of Hanging
The suspected ligature had been removed from the body prior to examination. It is available for inspection and consists of a 22 ½-inch, three-strand braided ligature composed of white cotton material. The ligature measures, on average, ¾-inch wide and ½-inch thick. At one end of the ligature is a loop formed by tying the ligature to itself. Eight inches from the loop end is a 4-inch area of soiling with embedded dark hairs.

A brown to gray-tan, 9 1/8-inch discontinuous ligature furrow is on the skin of the neck and is directed obliquely upward at approximately 45-degrees on both sides of the neck. The ligature furrow crosses the superior third of the thyroid cartilage 9 3/8-inches below the top of the head, and extends superiorly on both sides of the neck, ending 1-inch below the lobe of the right ear and passing 2-inches below the lobe of the left ear. The highest point of the furrow is located on the back of the neck, 6 ½-inches below the top of the head and on the posterior midline. The width of the ligature furrow ranges from ¾-inch to 3/8-inch, and the depth of the furrow ranges from less than 1/16-inch (posterior) to 1/8-inch (left). There is some noticeable periodicity in the furrow, which corresponds with the suspected ligature. There is a 1 ¼ x 5/8-inch abrasion on the right side of the neck that is associated with the ligature furrow. There are no scratches or contusions on the neck.

There is no injury to the underlying soft tissues or hemorrhage into the strap muscles by layer-wise anterior neck dissection. The hyoid bone and thyroid cartilage are intact

Other injuries associated with the hanging include: The face is suffused with scattered petechiae on the skin and there are petechiae on the bulbar and palpebral conjunctivae, bilaterally.

INTERNAL EXAMINATION

BODY CAVITIES:
The ribs, sternum, and vertebral bodies are visibly and palpably intact. No excess fluid is in the pleural, pericardial, or peritoneal cavities. The organs occupy their usual anatomic positions. The abdominal fat layer is 5/8-inch thick at the umbilicus.

HEAD AND CENTRAL NERVOUS SYSTEM:
The galeal and subgaleal soft tissues of the scalp are free of injury. The calvarium is intact, as is the dura mater beneath it. Clear cerebrospinal fluid surrounds the 1,475-gram brain, which has unremarkable gyri and sulci. Coronal sections demonstrate sharp demarcation between white and gray matter, without hemorrhage or contusive injury. The ventricles are of normal size. The basal ganglia, brainstem, cerebellum, and arterial systems are free of injury or other abnormalities. The pituitary gland is normal appearing. There are no skull fractures. The atlanto-occipital joint is stable. The spinal cord is unremarkable.

ACLU Detainee DeathII ARMY MEDCOM 880

NECK:
Injuries to the neck are described above (see "Evidence of Injury"). The anterior strap muscles of the neck are homogenous and red-brown and without hemorrhage by layer-wise dissection. The thyroid cartilage and hyoid bone are intact. The larynx is lined by intact white mucosa. The tongue is free of bite marks, hemorrhage, or other injuries.

Incision and dissection of the posterior neck demonstrates no deep paracervical muscular injury and no cervical spine fractures.

RESPIRATORY SYSTEM:
The right and left lungs weigh 425 and 300-grams, respectively. The external surfaces are smooth and pink to red-purple. The pulmonary parenchyma is diffusely congested and edematous. No mass lesions or areas of consolidation are present.

CARDIOVASCULAR SYSTEM:
The 250-gram heart is contained in an intact pericardial sac. The epicardial surface is smooth, with minimal fat investment. The coronary arteries are present in a normal distribution, with a right-dominant pattern. Cross sections of the vessels show widely patent lumens. The myocardium is homogenous, red-brown, and firm. The valve leaflets are thin and mobile. The foramen ovale is closed. The walls of the left and right ventricles are 1.0 and 0.3-centimeters thick, respectively. The endocardium is smooth and glistening. The aorta gives rise to three intact and patent arch vessels. The renal and mesenteric vessels are unremarkable.

HEPATOBILIARY SYSTEM:
The 1,400-gram liver has an intact, smooth capsule and a sharp anterior border. The parenchyma is tan-brown and congested, with the usual lobular architecture. No mass lesions or other abnormalities are seen. The gallbladder contains 15-milliliters of green-brown bile and no stones. The mucosal surface is green and velvety. The extrahepatic biliary tree is patent.

LYMPHORETICULAR SYSTEM:
The 125-gram spleen has a smooth, intact, red-purple capsule. The parenchyma is maroon and congested, with distinct lymphoid follicles. Lymph nodes in the hilar, periaortic and iliac regions are not enlarged.

ENDOCRINE SYSTEM:
The thyroid gland is symmetric and red-brown, without cystic or nodular change. The pancreas is slightly autolytic and ranges in appearance from hemorrhagic to yellow-tan, with the usual lobular architecture. No mass lesions or other abnormalities are seen. The right and left adrenal glands are symmetric, with bright yellow cortices and gray medullae. No masses or areas of hemorrhage are identified.

ACLU Detainee DeathII ARMY MEDCOM 881

GENITOURINARY SYSTEM:
The right and left kidneys both weigh100-grams each. The external surfaces are intact and smooth. The cut surfaces are red-tan and congested, with uniformly thick cortices and sharp cortico-medullary junctions. The pelves are unremarkable and the ureters are normal in course and caliber. Gray-pink bladder mucosa overlies an intact bladder wall. The bladder contains approximately 50-milliliters of yellow urine. The prostate gland is normal in size, with lobular, yellow-tan parenchyma. The seminal vesicles are unremarkable. The testes are free of mass lesions, contusions, or other abnormalities.

GASTROINTESTINAL SYSTEM:
The esophagus is intact and lined by smooth, gray-white mucosa. The stomach contains approximately 35-milliliters of pink-brown fluid. The gastric wall is intact. The duodenum, loops of small bowel and colon are unremarkable. The appendix is present.

MUSCULOSKELETAL SYSTEM:
There is no non-traumatic bone or joint abnormalities. Skeletal muscle development is normal. Superficial incisions along the posterior midlines of all four extremities and the back are made and the skin reflected to the anterior midlines to expose the underlying subcutaneous tissue and muscle. Areas of hemorrhage associated with resuscitation efforts are noted.

MICROSCOPIC EXAMINATION

Selected portions of organs are retained in formalin, without preparation of histological slides.

ADDITIONAL PROCEDURES/REMARKS

- Documentary photographs are taken by AFMES staff photographer (b)(6) (b)(6)
- Observed by (b)(6) Medical Examiner (b)(6)
- Specimens retained for toxicologic testing and/or DNA identification are: heart blood, vitreous fluid, gastric contents, urine, bile, spleen, liver, lung, kidney, brain, myocardium, and skeletal muscle
- The dissected organs are forwarded with the body and the body is sutured closed without embalming
- Personal effects are released to the mortuary affairs representatives

ACLU Detainee DeathII ARMY MEDCOM 882

OPINION

This (BTB) 35-year-old civilian detainee, (BTB) (b)(6) died of hanging. Investigation reveals that a razor blade from a razor was used to cut strips from one or more bed sheets and a ligature was fashioned by braiding these strips together. A sliding noose was formed by tying a loop in one end of the ligature and bringing the opposite end through the loop. The free end of the ligature was secured to a ventilation opening, and (b)(6) likely stood on his bedroll to place the noose over his head. It is not known if he was fully or partially suspended when found. The subject's face was congested with petechiae; it is likely that he was partially suspended (DiMaio and DiMaio, *Forensic Pathology, 2nd Ed.*, CRC Press, 2001, pp. 252-253). Some periodicity was noted in the ligature furrow at autopsy which corresponded with the suspected ligature. There was also an abrasion on the right side of the neck which corresponded with the loop at the end of the ligature. It was reported that the hands were bound loosely behind the body when found and no evidence of constrictive binding of the wrists was present at autopsy. Complete body radiographs and multiple skin incisions of the posterior back and extremities failed to reveal any evidence of physical abuse. Toxicological testing for ethanol, carbon monoxide, cyanide, medications and screened drugs of abuse was negative. The manner of death is suicide.

(b)(6)

(b)(6) Medical Examiner

ACLU Detainee DeathII ARMY MEDCOM 883

OPINION

This (BTB) 35-year-old civilian detainee, (BTB) (b)(6) died of hanging. Investigation reveals that a razor blade from a razor was used to cut strips from one or more bed sheets and a ligature was fashioned by braiding these strips together. A sliding noose was formed by tying a loop in one end of the ligature and bringing the opposite end through the loop. The free end of the ligature was secured to a ventilation opening, and (b)(6) likely stood on his bedroll to place the noose over his head. It is not known if he was fully or partially suspended when found. The subject's face was congested with petechiae; it is likely that he was partially suspended (DiMaio and DiMaio, *Forensic Pathology, 2nd Ed.*, CRC Press, 2001, pp. 252-253). Some periodicity was noted in the ligature furrow at autopsy which corresponded with the suspected ligature. There was also an abrasion on the right side of the neck which corresponded with the loop at the end of the ligature. It was reported that the hands were bound loosely behind the body when found and no evidence of constrictive binding of the wrists was present at autopsy. Complete body radiographs and multiple skin incisions of the posterior back and extremities failed to reveal any evidence of physical abuse. Toxicological testing for ethanol, carbon monoxide, cyanide, medications and screened drugs of abuse was negative. The manner of death is suicide.

(b)(6)

(b)(6) **Medical Examiner**

(b)(6)

ACLU Detainee DeathII ARMY MEDCOM 884

CERTIFICATE OF DEATH *(OVERSEAS)*

Acte de décès (D'Outre-Mer)

NAME OF DECEASED (Last, First, Middle) Nom du décédé (Nom et prénoms)	GRADE Grade	BRANCH OF SERVICE Arme	SOCIAL SECURITY NUMBER
BTB Al-Umari, ABD Al-Rahman, M		Civilian	(b)(6)

ORGANIZATION Organisation	NATION (e.g. United States) Pays	DATE OF BIRTH	SEX Sexe
	Saudi Arabia	(b)(6) 1972	[X] MALE [ ] FEMALE

RACE Race		MARITAL STATUS État Civil			RELIGION Culte		
[X]	CAUCASOID Caucasique	[ ]	SINGLE Célibataire	[ ] DIVORCED Divorcé	[ ]	PROTESTANT Protestant	[ ] OTHER (Specify) Autre (Spécifier)
[ ]	NEGROID Negroide	[ ]	MARRIED Marié	[ ] SEPARATED Séparé	[ ]	CATHOLIC Catholique	[X]
[ ]	OTHER (Specify) Autre (Spécifier)	[ ]	WIDOWED Veuf		[ ]	JEWISH Juif	

NAME OF NEXT OF KIN Nom du plus proche parent	RELATIONSHIP TO DECEASED Parenté du décédé avec le sus
STREET ADDRESS Domicile à (Rue)	CITY OR TOWN OR STATE (Include ZIP Code) Ville (Code postal compris)

MEDICAL STATEMENT Déclaration médicale

	CAUSE OF DEATH (Enter only one cause per line) Cause du décès (N'indiquer qu'une cause par ligne)	INTERVAL BETWEEN ONSET AND DEATH Intervalle entre l'attaque et le décès
DISEASE OR CONDITON DIRECTLY LEADING TO DEATH [1] Maladie ou condition directement responsable de la mort	Hanging	Seconds to Minutes
ANTECEDENT CAUSES Symptômes précurseurs de la mort — MORBID CONDITION, IF ANY, LEADING TO PRIMARY CAUSE Condition morbide, s'il y a lieu, menant à la cause primaire		
ANTECEDENT CAUSES Symptômes précurseurs de la mort — UNDERLYING CAUSE, IF ANY, GIVING RISE TO PRIMARY CAUSE Condition morbide, s'il y a lieu, menant à la cause primaire		
OTHER SIGNIFICANT CONDITIONS [2] Autres conditions significatives [2]		

MODE OF DEATH Condition de décès	AUTOPSY PERFORMED Autopsie effectuée [X] YES Oui [ ] NO Non	CIRCUMSTANCES SURROUNDING DEATH DUE TO EXTERNAL CAUSES Circonstances de la mort susciées par des causes extérieures
[ ] NATURAL Mort naturelle	MAJOR FINDINGS OF AUTOPSY Conclusions principales de l'autopsie	
[ ] ACCIDENT Mort accidentelle		
[X] SUICIDE Suicide	NAME OF PATHOLOGIST Nom du pathologiste (b)(6)	
[ ] HOMICIDE Homicide	(b)(6) DATE Date 1 June 2007	AVIATION ACCIDENT Accident d'Avion [ ] YES Oui [X] NO Non

DATE OF DEATH (day, month, year) Date du décès (le jour, le mois, l'année)

I HAVE VIEWED THE REMAINS OF THE DECEASED AND DEATH OCCURRED AT THE TIME INDICATED AND FROM THE CAUSES AS STATED ABOVE.
J'ai examiné les restes mortels du dé funt et je conclus que le décès est survenu à l'heure indiquée et à, la suite des causes énumérées ci-dessus.

NAME OF MEDICAL OFFICER Nom du médecin militaire ou du médecin sanitaire	TITLE OR DEGREE Titre ou diplôme
(b)(6)	Medical Examiner

GRADE Grade	INSTALLATION OR ADDRESS Installation ou adresse
(b)(6)	Guantanamo Bay Naval Base, Cuba

DATE Date	
6/4/2007	(b)(6)

[1] State disease, injury or complication which caused death.
[2] State conditions contributing to the death, but not relating
[1] Préciser la nature de la maladie, de la blessure ou de la complication qui a entraîné la mort, mais sans la manière de mourir, telle qu'un arrêt du cœur, etc
[2] Préciser la condition qui a contribué à la mort, mais n'ayant aucun rapport avec la maladie ou à la condition qui a provoqué la mort

DD FORM 1 APR 77 2064 REPLACES DA FORM 3566, 1 JAN 72 AND DA FORM 3566-R(PAS), 28 SEP 76, WHICH ARE OBSOLETE.

ACLU Detainee DeathII ARMY MEDCOM 885

ARMED FORCES INSTITUTE OF PATHOLOGY
Office of the Armed Forces Medical Examiner
1413 Research Blvd., Bldg. 102
Rockville, MD 20850
1-301-319-0000

FINAL AUTOPSY REPORT

Name: Mahmoud, Naffa Ibrahim
ISN: (b)(6)
Date of Birth: (b)(6) 1954
Date of Death (b)(6) 2007
Date/Time of Autopsy: 2 June 2007 @0730
Date of Report: 28 June 2007

Autopsy No.: (b)(6)
AFIP No.: (b)(6)
Rank: Iraqi detainee
Place of Death: Iraq
Place of Autopsy: Port Mortuary, Dover AFB, DE

Circumstances of Death: This 53 year-old Iraqi detainee reportedly collapsed while speaking with his son, who is also a detainee, at Compound 2B, Camp Remembrance II, Theatre Internment Facility, Camp Cropper, Bagdad, Iraq.

Authorization for Autopsy: Office of the Armed Forces Medical Examiner, IAW 10 USC 1471

Identification: Accompanying documentation establishes presumptive identification

CAUSE OF DEATH: Hypertensive atherosclerotic cardiovascular disease

MANNER OF DEATH: Natural

ACLU Detainee DeathII ARMY MEDCOM 886

FINAL AUTOPSY DIAGNOSES

I. Hypertensive atherosclerotic cardiovascular disease:
- A. Coronary artery calcifying atherosclerosis
  1. Left coronary artery with 95% stenosis (gross observation)
  2. Left anterior descending artery with 99% stenosis (gross observation)
  3. Left circumflex artery with 75% stenosis (gross observation)
  4. Right coronary artery with 95% stenosis (gross observation)
- B. Transmural cardiac myocyte replacement fibrosis, anterior wall of the left ventricle, 1.5 x 1.0 x 0.5 centimeters
- C. Cardiomegaly (580 grams) with cardiac myocyte hypertrophy,
- D. Hypertensive changes of the kidneys

II. Evidence of medical therapy:
- A. Endotracheal tube appropriately positioned and secured with tape
- B. Five electrocardiogram pick ups on the anterior torso
- C. Two defibrillator pads appropriately positioned on the anterior torso
- D. Intravenous catheter in the right antecubital fossa secured with purple tape
- E. Puncture mark to the left antecubital fossa
- F. Bilateral anterior rib fractures

III. Post-mortem changes:
- A. Lividity fixed on the posterior surface of the body except where exposed to pressure
- B. Rigor passing to an equal degree in all extremities
- C. Body cold

IV. Identifying marks:
- A. Brown papule on the right upper cheek, 1/8-inch
- B. Well healed scar to the lateral and upper surface of the right thigh
- C. Well healed scar above the right knee, 1-1/2 x 1-inches
- D. Firm, raised subdermal nodule to the anterior surface of the right foot, ½-inch
- E. Missing right 5th toe

V. Toxicology:
- A. Volatiles (blood and vitreous fluid): No ethanol detected
- B. Screened medications and screened drugs of abuse (blood): None detected
- C. Carbon monoxide (blood): carboxyhemoglobin saturation less than 1%
- D. Cyanide (blood): None detected

ACLU Detainee DeathII ARMY MEDCOM 887

VI. Microscopy:

A. Heart: extensive transmural myocyte replacement fibrosis; mild myocyte hypertrophy
B. Coronary vessels: calcifying atheromas, with one section demonstrating 90 % stenosis
C. Kidney: obsolescent glomeruli; arteriosclerosis; arteriolosclerosis; interstitial fibrosis
D. Lung: vascular congestion, otherwise unremarkable
E. Liver: vascular congestion, otherwise unremarkable

ACLU Detainee DeathII ARMY MEDCOM 888

EXTERNAL EXAMINATION

The body is that of a well-developed, well-nourished appearing Male whose appearance is consistent with the reported age of 53 years. The body is 68 inches in length and weighs 178 pounds. Lividity is fixed on the posterior aspect of the body except where exposed to pressure. Rigor is equal in all extremiteis. The body temperature is cold.

The head and the face are atraumatic. There is a 1/8-inch brown papule on the left cheek. The scalp is covered with closely shaved brown and grey hair with male patterned baldness. The irides are brown, the corneae are clear, the conjunctivae are unremarkable, and the sclerae are white. The external auditory canals are unremarkable. The ears are unremarkable. The nares and the lips are unremarkable. The nose and maxillae are palpably intact. The teeth are natural with multiple remotely absent. The neck is straight, and the trachea is midline and mobile.

The chest is unremarkable. The abdomen is soft with no palpable masses. The genitalia are those of a normal adult circumcised male. The testes are present and free of masses. Pubic hair is present in a normal distribution. The back is unremarkalbe. The buttocks and anus are unremarkable.

The upper and lower extremities are symmetric and without clubbing or edema. There is a 1-1/2 x 1-1/4-inche well healed scar on the upper lateral surface of the right thigh. A 1-1/2-inch x 1-inch well healed scar on the right knee. A ½-inch firm flesh colored nodule is on the dorsum of the foot. The right 5th toe is absent.

There is a personal effects bag secured to the left wrist. A paper identification tag is secured to the right wrist. The left wrist has an orange band with the words "Insulin Dependent Diabetic." A Dover Port Mortuary identification tag is secured to the left ankle.

CLOTHING AND PERSONAL EFFECTS

The following clothing items and personal effects accompany the body at the time of autopsy:

- White shirt, previously cut and partially wrapped around the right arm
- Yellow trousers
- White boxer shorts
- Three passports
- Four picture identifications
- Five miscellaneous papers
- Watch inscribed (b)(6)
- Compact disc with pictured cover
- Various medications in plastic bags with dosing instructions, to include:
    - Paxil 20 milligrams
    - Lisinopril 10 milligrams
    - Glyburide 5 milligrams

ACLU Detainee DeathII ARMY MEDCOM 889

- Tamsulosin 0.4 milligrams
- Multivitamins
- Lasix 20 milligrams
- Metformin 500 milligrams
- Aspirin 81 milligrams

MEDICAL INTERVENTION

- Endotracheal tube appropriately positioned and secured with white tape
- Vascular catheter in the right antecubital fossa secured with purple tape and connected to IV tubing
- Puncture site in the left antecubital fossa
- Two defibrillator pad on the anterior torso
- Five electrocardiogram pick-ups on both shoulders and the left upper thigh
- Bilateral anterior rib fractures
  - Right anterior 3rd through 5th
  - Left anterior 3rd through 5th

RADIOGRAPHS

A complete set of postmortem radiographs is obtained and demonstrates no traumatic injuries.

EVIDENCE OF INJURY

There is no evidence of recent injury. A complete dissection of the back, buttocks and posterior extremities reveals no intramuscular hemorrhage.

INTERNAL EXAMINATION

HEAD:
The galeal and subgaleal soft tissues of the scalp are free of injury. The calvarium is intact, as is the dura mater beneath it. Clear cerebrospinal fluid surrounds the 1520 gram brain, which has unremarkable gyri and sulci. Coronal sections demonstrate sharp demarcation between white and gray matter, without hemorrhage or contusive injury. The ventricles are of normal size. The basal ganglia, brainstem, and cerebellum are free of injury or other abnormalities. The arterial system is anatomically normal and there is mild atherosclerosis of the internal carotid arteries. There are no skull fractures. The atlanto-occipital joint is stable.

NECK:
Layer by layer dissection of the anterior neck is performed. The anterior strap muscles of the neck are homogenous and red-brown, without hemorrhage. The thyroid cartilage and hyoid are intact. The larynx is lined by intact white mucosa. The thyroid is symmetric and red-brown, without cystic or nodular change. The tongue is free of bite marks, hemorrhage, or other injuries.

ACLU Detainee DeathII ARMY MEDCOM 890

BODY CAVITIES:
The ribs, sternum, and vertebral bodies are visibly and palpably intact. No excess fluid is in the pleural, pericardial, or peritoneal cavities. The organs occupy their usual anatomic positions.

RESPIRATORY SYSTEM:
The right and left lungs weigh 890 and 700 grams, respectively. The external surfaces are smooth and deep red-purple. The pulmonary parenchyma is diffusely congested and edematous. No mass lesions or areas of consolidation are present.

CARDIOVASCULAR SYSTEM:
The 580 gram heart is contained in an intact pericardial sac. The epicardial surface is smooth, with moderate fat investment. The coronary arteries are present in a normal distribution. Cross sections of the vessels show 95 % calcifying atherosclerotic stenosis of the left coronary artery, 99% calcifying atherosclerotic stenosis of the entire left anterior descending artery, 75% calcifying atherosclerotic stenosis of the proximal left circumflex artery and 95% calcifying atherosclerotic stenosis of the right coronary artery. The myocardium of the anterior wall of the left ventricle is replaced by transmural fibrosis, 1.5 x 1.0 x 0.5-centimeters. The valve leaflets are thin and mobile. The anterior, lateral, posterior and interventricular walls of the left ventricle are 0.8-centimeter, 1.2-centimeters, 1.4-centimeters and 1.3-centimeters respectfully. The right ventricular wall is 0.2-centimeters. The endocardium is smooth and glistening. The aorta gives rise to three intact and patent arch vessels and has diffuse calcifying atheromas. The renal and mesenteric vessels are unremarkable.

LIVER & BILIARY SYSTEM:
The 1640 gram liver has an intact, smooth capsule and a sharp anterior border. The parenchyma is tan-brown and congested, with the usual lobular architecture. No mass lesions or other abnormalities are seen. The gallbladder contains 5-milliliters of green-black bile and no stones. The mucosal surface is green and velvety. The extrahepatic biliary tree is patent.

SPLEEN:
The 300 gram spleen has a smooth, intact, red-purple capsule. The parenchyma is maroon and congested, with distinct lymphoid follicles.

PANCREAS:
The pancreas is firm and yellow-tan, with the usual lobular architecture. No mass lesions or other abnormalities are seen.

ADRENALS:
The right and left adrenal glands are symmetric, with bright yellow cortices and red-brown medullae. No masses or areas of hemorrhage are identified.

ACLU Detainee DeathII ARMY MEDCOM 891

GENITOURINARY SYSTEM:
The right and left kidneys weigh 140 and 180 grams, respectively. The external surfaces are intact and diffusely granular. The cut surfaces are red-tan and congested, with uniformly thick cortices and sharp corticomedullary junctions. The pelves are unremarkable and the ureters are normal in course and caliber. White bladder mucosa overlies an intact bladder wall. The bladder contains approximately 30 milliliters of clear yellow urine. The prostate is normal in size, with lobular, yellow-tan parenchyma. The seminal vesicles are unremarkable. The testes are free of mass lesions, contusions, or other abnormalities.

GASTROINTESTINAL TRACT:
The esophagus is intact and lined by smooth, grey-white mucosa. The stomach contains approximately 300 milliliter of tan viscous fluid with whole black beans. The gastric wall is intact. The duodenum, loops of small bowel, and colon are unremarkable. The appendix is present.

MUSCULOSKELETAL:
No non-traumatic abnormalities of muscle or bone are identified.

MICROSCOPIC EXAMINATION

- Heart: extensive transmural myocyte replacement fibrosis; mild myocyte hypertrophy
- Coronary vessels: calcifying atheromas, with one section demonstrating 90 % stenosis
- Kidney: obsolescent glomeruli; arterosclerosis; arteriolosclerosis; interstitial fibrosis
- Lung: vascular congestion, otherwise unremarkable
- Liver: vascular congestion, otherwise unremarkable

TOXICOLOGY

- Volatiles (blood and vitreous fluid): No ethanol detected
- Screened medications and screened drugs of abuse (blood): None detected
- Carbon monoxide (blood): carboxyhemoglobin saturation less than 1%
- Cyanide (blood): None detected

ADDITIONAL PROCEDURES

1. Documentary photographs are taken by OAFME staff photographers.
2. Full body radiographs and computed tomography are obtained.
3. Specimens retained for toxicology testing and/or DNA identification are: Blood, vitreous fluid, bile, urine, gastric contents, brain, heart, lung, liver, spleen, kidney, adipose tissue and psoas muscle.
4. The dissected organs are forwarded with the body.
5. Selected portions of organs are retained in formalin.
6. Personal effects are released to the appropriate mortuary operations representatives.

ACLU Detainee DeathII ARMY MEDCOM 892

OPINION

This 53-year-old Male Iraqi detainee (b)(6) died from hypertensive atherosclerotic cardiovascular disease. The decedent had documented insulin dependent diabetes mellitus and essential hypertension. The decedent had significant narrowing of the coronary arteries, a prior healed myocardial infarction, a large heart and changes to the heart and kidneys consistent with hypertension. Toxicology analyses are negative for ethanol, screened drugs of abuse, screened medication and cyanide. Toxicology analysis for carbon monoxide is less than 1%. The manner of death is natural.

(b)(6)

(b)(6) Medical Examiner

(b)(6)

(b)(6) Medical Examiner

ACLU Detainee DeathII ARMY MEDCOM 893

CERTIFICATE OF DEATH (OVERSEAS)
Acte de décès (D'Outre-Mer)

NAME OF DECEASED (Last, First, Middle) / Nom du décédé (Nom et prénoms)	GRADE / Grade	BRANCH OF SERVICE / Arme	SOCIAL SECURITY NUMBER / Numéro de l'Assurance Sociale
BTB Mahmoud, Naffa, Ibrahim		Civilian	(b)(6)

ORGANIZATION / Organisation	NATION (e.g. United States) / Pays	DATE OF BIRTH / Date de naissance	SEX / Sexe
	Iraq	(b)(6) 1954	[X] MALE [ ] FEMALE

RACE / Race		MARITAL STATUS / État Civil				RELIGION / Culte			
X	CAUCASOID / Caucasique		SINGLE / Célibataire		DIVORCED / Divorcé		PROTESTANT / Protestant		OTHER (Specify) / Autre (Spécifier)
	NEGROID / Négrices		MARRIED / Marié		SEPARATED / Séparé		CATHOLIC / Catholique	X	
	OTHER (Specify) / Autre (Spécifier)		WIDOWED / Veuf				JEWISH / Juif		

NAME OF NEXT OF KIN / Nom du plus proche parent	RELATIONSHIP TO DECEASED / Parenté du décédé avec le sus

STREET ADDRESS / Domicile à (Rue)	CITY OR TOWN OR STATE (Include ZIP Code) / Ville (Code postal compris)

MEDICAL STATEMENT / Déclaration médicale

CAUSE OF DEATH (Enter only one cause per line) / Cause du décès (N'indiquer qu'une cause par ligne)		INTERVAL BETWEEN ONSET AND DEATH / Intervalle entre l'attaque et le décès
DISEASE OR CONDITON DIRECTLY LEADING TO DEATH[1] / Maladie ou condition directement responsable de la mort[1]	Hypertensive atherosclerotic cardiovascular disease	
ANTECEDENT CAUSES / Symptômes précurseurs de la mort — MORBID CONDITION, IF ANY, LEADING TO PRIMARY CAUSE / Condition morbide, s'il y a lieu, menant à la cause primaire		
ANTECEDENT CAUSES / Symptômes précurseurs de la mort — UNDERLYING CAUSE, IF ANY, GIVING RISE TO PRIMARY CAUSE / Condition morbide, s'il y a lieu, menant à la cause primaire		
OTHER SIGNIFICANT CONDITIONS[2] / Autres conditions significatives[2]		

MODE OF DEATH / Condition du décès	AUTOPSY PERFORMED / Autopsie effectuée	CIRCUMSTANCES SURROUNDING DEATH DUE TO EXTERNAL CAUSES / Circonstances de la mort suscitées par des causes extérieures
X NATURAL / Mort naturelle	[X] YES Oui [ ] NO Non	
ACCIDENT / Mort accidentelle	MAJOR FINDINGS OF AUTOPSY / Conclusions principales de l'autopsie	
SUICIDE / Suicide	NAME OF PATHOLOGIST / Nom du pathologiste (b)(6)	
HOMICIDE / Homicide	(b)(6)	AVIATION ACCIDENT / Accident à Avion [ ] YES Oui [X] NO Non

DATE OF DEATH (day, month, year) / Date de décès (Jour, mois, année)		DATE / Date
(b)(6) 2007	✓	2 June 2007

	Baghdad Iraq

I HAVE VIEWED THE REMAINS OF THE DECEASED AND DEATH OCCURRED AT THE TIME INDICATED AND FROM THE CAUSES AS STATED ABOVE.
J'ai examiné les restes mortels du dé suivant le conclus que le décès est survenu à l'heure indiquée et à la suite des causes énumérées ci-dessus.

NAME OF MEDICAL OFFICER / Nom du médecin militaire ou du médecin spécialiste	TITLE OR DEGREE / Titre ou diplôme
(b)(6)	Medical Examiner

GRADE / Grade	INSTALLATION OR ADDRESS / Installation ou adresse
(b)(6)	Bayes AFB, DSTB DE (b)(6)

DATE / Date
6/2/2007

[1] State disease, injury or complication which caused de...
[2] State conditions contributing to the death, but not relat...
[3] Describe la nature de la maladie, de la blessure ou de...
[4] Enter the condition and a mechanical, a...

REPLACES DA FORM 5003, 1 JAN 72 AND DA FORM 5003-1 ... OBSOLETE.

DD FORM 1 APR 77 2064

MEDCOM 0894

ARMED FORCES INSTITUTE OF PATHOLOGY
Office of the Armed Forces Medical Examiner
1413 Research Blvd., Bldg. 102
Rockville, MD 20850
1-301-319-0000

FINAL AUTOPSY REPORT

Name: Abdulkarim, Mohammed Anwar
ISN: (b)(6)
Date of Birth: (b)(6) 1976
Date of Death: (b)(6) 2007
Date of Autopsy: 3 May 2007 @ 1200
Date of Report: 23 May 2007

Autopsy No.: (b)(6)
AFIP No. (b)(6)
Rank: Detainee
Place of Death: Iraq
Place of Autopsy: Port Mortuary
Dover AFB, DE

Circumstances of Death: This 30 year-old Iraqi detainee was reportedly discovered by other detainees unresponsive and suffering from multiple sharp and blunt force injuries

Authorization for Autopsy: Office of the Armed Forces Medical Examiner, IAW 10 USC 1471

Identification: Presumptive identification is established by internment serial number. Post-mortem fingerprints and a specimen suitable for DNA analysis are obtained.

CAUSE OF DEATH: **Sharp and Blunt Force Injuries**

MANNER OF DEATH: **Homicide**

ACLU Detainee DeathII ARMY MEDCOM 895

FINAL AUTOPSY DIAGNOSES:

I. Sharp and Blunt Force Injuries:

A. Incised wound of the left chest

1. **Wound characteristics: ¾ x 1/8-inch length, one sharp and one blunt edge, with an approximate depth of penetration of ½-inch**
2. **Injury to: Skin and subcutaneous tissue**
3. **Direction: Front to back, without significant left/right or up/down deviation**
4. **Associated injuries: Hemorrhage along the wound path**

B. Stab wound of the left chest:

1. **Wound characteristics: 2 1/8 x 1/8-inch length, one sharp and one blunt edge, with an approximate depth of penetration of 5 ½-inches**
2. **Injury to: Skin, subcutaneous tissue, left anterior 3rd intercostal space, pericardium, left ventricle (3-inch defect), pericardium, left lower lobe of the lung (two defects, each 1 ¼-inch), left posterior 7th intercostal space**
3. **Direction: Front to back and downward, without significant right/left deviation**
4. **Associated injuries: Left hemothorax (500 ml), laceration of the distal left anterior descending coronary artery**

C. Stab wound of the left chest:

1. **Wound characteristics: 2 ¼ x 1/8-inch length, one sharp and one blunt edge, with an approximate depth of penetration of 6-inches**
2. **Injury to: Skin, subcutaneous tissue, left anterior 3rd intercostal space, pericardium, left ventricle (1 1/4-inch defect), pericardium, left hemidiaphragm (2-inch defect), left lobe of the liver (2 ¾-inch defect), stomach (1/2-inch defect), left posterior 8th intercostal space**
3. **Direction: Front to back and downward, without significant right/left deviation**
4. **Associated injuries: Left hemothorax (500 ml), laceration of the distal left anterior descending coronary artery**

D. Stab wound of the right upper quadrant of the abdomen:

1. **Wound characteristics: 1 ¼ x 1/8-inch length, one sharp and one blunt edge, with an approximate depth of penetration of 1 1/2-inches**
2. **Injury to: Skin and subcutaneous tissue**
3. **Direction: Front to back, without significant left/right or up/down deviation**
4. **Associated injuries: Hemorrhage along the wound path**

ACLU Detainee DeathII ARMY MEDCOM 896

E. Stab wound of the left upper quadrant of the abdomen:
1. **Wound characteristics: 1 ¾ x 1/8-inch length, one sharp and one blunt edge, with an approximate depth of penetration of 4-inches**
2. **Injury to: Skin, subcutaneous tissue, omentum, pancreas (1 ½-inch defect), mesentery, descending colon**
3. **Direction: Front to back, without significant left/right or up/down deviation**
4. **Associated injuries: Hemorrhage along the wound path**

F. Blunt force injuries of the head:
1. **Laceration right forehead, 1 ¼ x ¼-inch, with surrounding abrasion, 1 ½ x ½-inch, and contusion, 2 x 1 ½-inches**
2. **Laceration right upper eyelid, 1 x 1/8-inch**
3. **Petechial hemorrhage, right eye**
4. **Contusion right preauricular area, 1 ½ x 1-inch, with underlying 2 x 1 ¼-inch defect of the temporal skull with fracture of the right temporal bone**
5. **Stellate laceration left parietal/temporal scalp, 4 x up to 3-inches, with underlying 3 x 2-inch defect of the temporal skull with multiple fractures of the left temporal bone**
6. **Contusion left temporal scalp, 3 x 2-inches**
7. **Abrasion left ear, 1 x ¾-inch**
8. **Hinge fractures (2) of the anterior and middle cranial fossae**
9. **Multiple fractures of the sphenoid bone**
10. **Fracture of the right zygoma, right orbit, and right nasal bone**
11. **Fracture of the left zygoma and left maxillary sinus**
12. **Diffuse subarachnoid hemorrhage**

II. Additional Injuries
- **A. Contusion, left upper extremity, 6 x 4-inches**
- **B. Abrasion and contusions, left lower extremity, ranging from 1 x ½-inch to 4 x 2 ½-inches**

III. No significant natural disease identified within the limitations of this autopsy

IV. No evidence of medical intervention

V. Identifying marks or tattoos:
- **A. Scars on the right side and midline of the abdomen, right leg, and left parietal scalp**
- **B. Tattoo** (b)(6)

ACLU Detainee DeathII ARMY MEDCOM 897

VI. Toxicology (AFIP):

- **A. Volatiles: No ethanol is detected in the blood and vitreous fluid**
- **B. Drugs: No screened drugs of abuse or medications are found in the urine**
- **C. Carbon Monoxide: The carboxyhemoglobin saturation in the blood is 1%**
- **D. Cyanide: No cyanide is detected in the blood**

EXTERNAL EXAMINATION

The body is that of a well-developed, well-nourished appearing, 67-inch tall, 195-pound Middle Eastern male whose appearance is consistent with the reported age of 30 years. Lividity is on the posterior torso and fixed. Rigor is passing, and the temperature is that of the refrigeration unit.

The scalp is covered with 2-inch long straight brown hair in a normal distribution. There is a 1-inch scar on the left parietal scalp. Facial hair consists of a moustache and beard. The irides are brown, the corneae are cloudy, the right conjunctiva has petechial hemorrhage, the left conjunctiva is pale, the sclerae are white and the pupils are round and equal in diameter. There is blood in the left external auditory canal. The right external auditory canal is clear. The ears are not pierced. The nares are patent. The nose and maxillae are palpably stable. The teeth appear natural and in fair condition, with some molars missing.

The neck is straight, and the trachea is midline and mobile. The chest is symmetric. The abdomen is soft and slightly protuberant. There are two ½-inch scars on the right side of the abdomen and a 9 ½-inch scar on the midline of the abdomen. The genitalia are those of a normal adult male. Pubic hair is present in a normal distribution. The buttocks and anus are unremarkable.

The upper and lower extremities are symmetric and without clubbing or edema. There is a tattoo (b)(6) Please refer to the evidence of injury section for injury to the head and torso.

CLOTHING AND PERSONAL EFFECTS

The following clothing items and personal effects are present on the body at the time of autopsy:

- None

MEDICAL INTERVENTION

- None

RADIOGRAPHS

A complete set of postmortem radiographs is obtained and demonstrates the following:

- Skeletal trauma as described below

ACLU Detainee DeathII ARMY MEDCOM 898

EVIDENCE OF INJURY

I. Sharp and Blunt Force Injuries:

A. Incised Wound of the Left Chest:

On the left chest, located 15-inches below the top of the head and centered 2-inches left of the anterior midline, is an incised wound which measures ¾ x 1/8-inch after re-approximation. This wound is horizontally oriented. The medial end is blunt and the lateral end is sharp. The incised wound penetrates skin and subcutaneous tissue. The wound path is directed front to back, without significant left/right or up/down deviation, with an approximate depth of penetration of ½-inch. Associated with the incised wound is hemorrhage along the wound path.

B. Stab Wound of the Left Chest:

On the left chest, located 16 ½-inches below the top of the head and centered 3-inches left of the anterior midline, is a stab wound which measures 2 1/8 x 1/8-inch after re-approximation. This wound is obliquely oriented along the 2 to 8 o'clock axis. The 8 o'clock end is blunt and the 2 o'clock end is sharp. The stab wound penetrates skin, subcutaneous tissue, the anterior left 3rd intercostal space, pericardium, left ventricle of the heart (3-inch defect), pericardium, lower lobe of the left lung (two defects, each 1 ¼-inch), and the posterior left 7th intercostal space. The wound path is directed front to back and downward, without significant left/right deviation, with an approximate depth of penetration of 5 ½-inches. Associated with the stab wound is left hemothorax (500 ml), transection of the distal left anterior descending coronary artery, and hemorrhage along the wound path.

C. Stab Wound of the Left Chest:

On the left chest, located 17-inches below the top of the head and centered 3 ½-inches left of the anterior midline, is a stab wound which measures 2 ¼ x 1/8-inch after re-approximation. This wound is horizontally oriented. The medial end is blunt and the lateral end is sharp. The stab wound penetrates skin, subcutaneous tissue, the anterior left 3rd intercostal space, pericardium, left ventricle of the heart (1 1/4-inch defect), pericardium, left hemidiaphragm, left lobe of the liver (2 ¾-inch defect), stomach (1/2-defect), and the posterior left 8th intercostal space. The wound path is directed front to back and downward, without significant left/right deviation, with an approximate depth of penetration of 6-inches. Associated with the stab wound is left hemothorax (500 ml), transection of the distal left anterior descending coronary artery, and hemorrhage along the wound path.

D. Stab Wound of the Abdomen:

On the right upper quadrant of the abdomen, located 24-inches below the top of the head and centered 2-inches right of the anterior midline, is a stab wound which measures 1 ¼ x 1/8-inch after re-approximation. This wound is obliquely oriented along the 2 to 8 o'clock axis. The 8 o' clock end is blunt and the 2 o' clock end is sharp. The stab wound penetrates skin and subcutaneous tissue. The wound path is directed front to back without significant up/down or left/right

ACLU Detainee DeathII ARMY MEDCOM 899

deviation, with an approximate depth of penetration of 1 ½-inches. Associated with the stab wound is hemorrhage along the wound path.

E. Stab Wound of the Abdomen:
On the left upper quadrant of the abdomen, located 24-inches below the top of the head and centered 2-inches left of the anterior midline, is a stab wound which measures 1 ¾ x 1/8-inch after re-approximation. This wound is obliquely oriented along the 2 to 8 o'clock axis. The 8 o' clock end is blunt and the 2 o' clock end is sharp. The stab wound penetrates skin, subcutaneous tissue omentum, pancreas (1 ½-inch defect), mesentery and descending colon. The wound path is directed front to back without significant up/down or left/right deviation, with an approximate depth of penetration of 4-inches. Associated with the stab wound is hemorrhage along the wound path.

F. Blunt Force Injuries of the Head and Extremities:
There is a laceration of the right side of the forehead, 1 ¼ x ¼-inch, with a surrounding contusion, 2 x 1 ½-inches, and abrasion, 1 ½ x ½-inch. There is a laceration of the upper right eyelid, 1 x 1/8-inch. There is a contusion of the right preauricular area, 1 ½ x 1-inch, with an underlying 2 x 1 ¼-inch defect of the temporal bone with fracture of the temporal bone. There is a stellate laceration of the left parietal/temporal scalp, 4 x up to 3-inches, with an underlying 3 x 2-inches defect of the temporal bone with multiple fractures of the temporal bone. There is a contusion of the left temporal scalp, 3 x 2-inches. There is an abrasion of the left ear, 1 x ¾-inch. There are hinge fractures of the anterior and middle cranial fossae. There are multiple fractures of the sphenoid bone. There are multiple bilateral facial fractures. There is diffuse subarachnoid hemorrhage. There is a contusion of the left arm, 6 x 4-inches. There is an abrasion, 3 x 1-inch, and contusions, ranging from 1 x ½-inch to 4 x 2 ½-inches, of the left leg.

INTERNAL EXAMINATION

HEAD:
See "Evidence of Injury". The 1330 gm brain has unremarkable gyri and sulci. Coronal sections demonstrate sharp demarcation between white and grey matter. The ventricles are of normal size. The basal ganglia, brainstem, cerebellum, and arterial systems are free of injury or other non-traumatic abnormalities.

NECK:
The thyroid cartilage and hyoid bone are intact. The larynx is lined by intact white mucosa. The thyroid gland is symmetric and red-brown, without cystic or nodular change. The tongue is free of bite marks, hemorrhage, or other injuries.

BODY CAVITIES:
See "Evidence of Injury". The ribs, sternum, and vertebral bodies are visibly and palpably intact. No excess fluid is in the pericardial or peritoneal cavities. The organs occupy their usual anatomic positions.

ACLU Detainee DeathII ARMY MEDCOM 900

RESPIRATORY SYSTEM:
See "Evidence of Injury". The right and left lungs weigh 410 and 240 gm, respectively. The uninjured external surfaces are smooth and deep red-purple. The uninjured pulmonary parenchyma is moderately congested and edematous. No areas of consolidation are present.

CARDIOVASCULAR SYSTEM:
See "Evidence of Injury". The heart weighs 320 gm. The uninjured epicardial surface is smooth, with minimal fat investment. The uninjured coronary arteries are present in a normal distribution, with a right-dominant pattern. Cross sections of the vessels show no atherosclerosis. The uninjured myocardium is homogenous, red-brown, and firm. The valve leaflets are thin and mobile. The uninjured endocardium is smooth and glistening. The aorta gives rise to three intact and patent arch vessels. The renal and mesenteric vessels are unremarkable.

LIVER & BILIARY SYSTEM:
See "Evidence of Injury". The 1900 gm liver has a smooth capsule and a sharp anterior border. The parenchyma is tan-brown and congested, with the usual lobular architecture. No mass lesions or other non-traumatic abnormalities are seen. The gallbladder contains 5 ml of green-black bile and no stones. The mucosal surface is green and velvety. The extrahepatic biliary tree is patent.

SPLEEN:
The 190 gm spleen has a smooth, intact, red-purple capsule. The parenchyma is maroon and congested, with distinct Malpighian corpuscles.

PANCREAS:
See "Evidence of Injury". The uninjured pancreas is firm and yellow-tan, with the usual lobular architecture. No mass lesions or other non-traumatic abnormalities are seen.

ADRENALS:
The right and left adrenal glands are symmetric, with bright yellow cortices and grey medullae. No masses or areas of hemorrhage are identified.

GENITOURINARY SYSTEM:
The right and left kidneys weigh 110 and 120 gm, respectively. The external surfaces of the kidneys are intact and smooth. The cut surfaces are red-tan and congested, with uniformly thick cortices and sharp corticomedullary junctions. The pelves are unremarkable and the ureters are normal in course and caliber. Grey-pink bladder mucosa overlies an intact bladder wall. The bladder contains 100 ml of clear yellow urine. The prostate is normal in size, with lobular, yellow-tan parenchyma. The seminal vesicles are unremarkable. The testes are free of mass lesions, contusions, or other abnormalities

GASTROINTESTINAL TRACT:
See "Evidence of Injury". The esophagus is intact and lined by smooth, grey-white mucosa. The stomach contains approximately 100 ml of dark green material. The

ACLU Detainee DeathII ARMY MEDCOM 901

duodenum, loops of small bowel and uninjured colon are unremarkable. The appendix is present.

MUSCULOSKELETAL SYSTEM:
See "Evidence of Injury". There are no non-traumatic bone or joint abnormalities. Skeletal muscle development is normal.

ADDITIONAL PROCEDURES

- Documentary photographs are taken by OAFME staff photographers
- Full body radiographs are obtained
- Specimens retained for toxicological testing and/or DNA identification are: spleen, liver, blood, brain, bile, urine, gastric contents, vitreous, psoas muscle, adipose tissue, lung and kidney
- The dissected organs are forwarded with body.
- Selected portions of organs are retained in formalin, without preparation of histological slides
- Personal effects are released to the appropriate mortuary operations representatives

OPINION

This 30 year-old mal(b)(6) died of sharp and blunt force injuries. Stab wounds of the left chest (B) and (C) injured the heart and left lung, resulting in massive bleeding into the left chest cavity, and also injured the liver and stomach. Stab wound (E) of the left upper quadrant of the abdomen injured the omentum, mesentery, pancreas and large bowel. An incised wound (A) of the left chest and stab wound (D) of the right upper quadrant of the abdomen did not injure vital structures but contributed to overall blood loss. Blunt force injuries of the head resulted in diffuse bleeding on the surface of the brain and multiple skull and facial fractures, including two hinge fractures. Toxicological testing for ethanol, drugs and cyanide was negative. The carboxyhemoglobin saturation was 1%. The manner of death is homicide.

(b)(6)
(b)(6) Medical Examiner

(b)(6)
(b)(6) Medical Examiner

ACLU Detainee DeathII ARMY MEDCOM 902

CERTIFICATE OF DEATH (OVERSEAS)
Acte de décès (D'Outre-Mer)

NAME OF DECEASED (Last, First, Middle) / Nom du décédé (Nom et prénoms)	GRADE / Grade	BRANCH OF SERVICE / Arme	SOCIAL SECURITY NUMBER / Numéro de l'Assurance Social
BTB Abdulkarim, Mohammed, Anwar		Civilian	(b)(6)
ORGANIZATION / Organisation	NATION (e.g. United States) / Pays: Iraq	DATE OF BIRTH / Date de naissance: (b)(6) 1976	SEX / Sexe: [X] MALE [ ] FEMALE

RACE / Race		MARITAL STATUS / État Civil		RELIGION / Culte	
X CAUCASOID / Caucasique		SINGLE / Célibataire	DIVORCED / Divorcé	PROTESTANT / Protestant	OTHER (Specify) / Autre (Spécifier)
NEGROID / Negroïde		MARRIED / Marié	SEPARATED / Séparé	CATHOLIC / Catholique	X
OTHER (Specify) / Autre (Spécifier)		WIDOWED / Veuf		JEWISH / Juif	

NAME OF NEXT OF KIN / Nom du plus proche parent	RELATIONSHIP TO DECEASED / Parenté du décédé avec le sujet
STREET ADDRESS / Domicile à (Rue)	CITY OR TOWN OR STATE (include ZIP Code) / Ville (Code postal compris)

MEDICAL STATEMENT / Déclaration médicale

CAUSE OF DEATH (Enter only one cause per line) / Cause du décès (Indiquer qu'une cause par ligne)		INTERVAL BETWEEN ONSET AND DEATH / Intervalle entre l'attaque et le décès
DISEASE OR CONDITION DIRECTLY LEADING TO DEATH[1] / Maladie ou condition directement responsable de la mort[1]	Blunt and sharp force injuries	Minutes
ANTECEDENT CAUSES / Symptômes précurseurs de la mort — MORBID CONDITION, IF ANY, LEADING TO PRIMARY CAUSE / Condition morbide, s'il y a lieu, menant à la cause primaire		
ANTECEDENT CAUSES / Symptômes précurseurs de la mort — UNDERLYING CAUSE, IF ANY, GIVING RISE TO PRIMARY CAUSE / Condition morbide, s'il y a lieu, menant à la cause primaire		
OTHER SIGNIFICANT CONDITIONS[2] / Autres conditions significatives[2]		

MODE OF DEATH / Condition de décès	AUTOPSY PERFORMED / Autopsie effectuée	CIRCUMSTANCES SURROUNDING DEATH DUE TO EXTERNAL CAUSES / Circonstances de la mort suscitées par des causes extérieures
NATURAL / Mort naturelle	[X] YES / Oui [ ] NO / Non	
ACCIDENT / Mort accidentelle	Minute Indicates of Autopsy / Conclusions principales de l'autopsie	
SUICIDE / Suicide	NAME OF PATHOLOGIST / Nom du pathologiste: (b)(6)	
X HOMICIDE / Homicide	(b)(6)	DATE / Date: 3 May 2007 — AVIATION ACCIDENT / Accident à l'avion: [ ] YES / Oui [X] NO / Non

DATE OF DEATH (day, month, year) / Date de décès (le jour, le mois): (b)(6) 2007

I HAVE VIEWED THE REMAINS OF THE DECEASED AND DEATH OCCURRED AT THE TIME INDICATED AND FROM THE CAUSES AS STATED ABOVE.
J'ai examiné les restes mortels du dé tunlet je conclus que le décès est survenu à l'heure indiquée et à la suite des causes énumérées ci-dessus.

NAME OF MEDICAL OFFICER / Nom du médecin officiel ou du médecin spécialiste	TITLE OR DEGREE / Titre ou diplôme
(b)(6)	Medical Examiner
GRADE / Grade: (b)(6)	INSTALLATION OR ADDRESS / Paraisse ou adresse: Dover AFB, Dover DE
DATE / Date: 5/3/2007	(b)(6)

1 Enter amount, if any or complaints where applicable
2 Enter significant information in the space, but not related
3 Indicate in nature of the remains, as in bloody or as in
4 Indicate in addition not a partial or a full, state other

DD FORM 1 APR 77 2064 REPLACES DA FORM 2064, 1 JAN 72 AND DA FORM 2064-R(PAS), 22 SEP 72, WHICH ARE OBSOLETE.

ARMED FORCES INSTITUTE OF PATHOLOGY
Office of the Armed Forces Medical Examiner
1413 Research Blvd., Bldg. 102
Rockville, MD 20850
1-301-319-0000

FINAL AUTOPSY REPORT

Name: BTB Mahmud, Karwan Muhammad Ali
ISN: (b)(6)
Date of Birth (b)(6) 1980
Date of Death (b)(6) 2007
Date of Autopsy: 13 Apr 2007 @ 1200
Date of Report: 19 June 2007

Autopsy No.: (b)(6)
AFIP No.: (b)(6)
Rank: Detainee
Place of Death: Iraq
Place of Autopsy: Port Mortuary
Dover AFB, DE

Circumstances of Death: This 26 year-old Iraqi detainee was found unresponsive by other detainees and subsequently removed from life-support 4 days later after medical intervention.

Authorization for Autopsy: Office of the Armed Forces Medical Examiner, IAW 10 USC 1471

Identification: Presumptive identification is established by a wrist identification band. Post-mortem fingerprints, dental examination, and a specimen suitable for DNA analysis are obtained.

CAUSE OF DEATH: **Left Ventricular Hypertrophy with Focal Subendocardial Interstitial and Replacement Fibrosis**

MANNER OF DEATH: **Natural**

ACLU Detainee DeathII ARMY MEDCOM 904

FINAL AUTOPSY DIAGNOSES:

I. **No evidence of significant recent injury**

II. **Evidence of natural disease:**
- A. **Diffuse neuronal hypoxic/ischemic changes in the cerebrum and cerebellum**
- B. **Cardiomegaly, 440 grams**
- C. **Subendocardial coagulative necrosis and multifocal single cell contraction band necrosis, left ventricle**
- D. **Left ventricular hypertrophy with focal subendocardial interstitial and replacement fibrosis**
- E. **Bronchopneumonia with bilateral pulmonary congestion (1010 grams right, 830 grams left)**
- F. **Bilateral pleural effusion (100 ml right, 50 ml left)**
- G. **Pericardial effusion (50 ml)**
- H. **Peritoneal effusion (50 ml)**

III. **Evidence of medical intervention:**
- A. **Nasogastric tube, orogastric tube, endotracheal tube, large-bore intravenous catheter left neck, Foley catheter, multiple needle puncture sites upper and lower extremities with associated contusions, EKG leads (3) on torso, defibrillator pad outlines (2) on chest, and two separate bags of intravenous fluids (one of normal saline and one containing morphine sulfate)**

IV. **Identifying marks or tattoos: Scars of the right hand, right forearm, and right foot**

V. **Toxicology (AFIP):**
- A. **Volatiles: No ethanol is detected in the blood and vitreous fluid**
- B. **Drugs: Lorazepam and 1-Hydroxymidazolam are detected in the urine but not in the blood. Morphine is detected in the urine and quantitated in the liver at 0.43 mg/kg**
- C. **Carbon Monoxide: The carboxyhemoglobin saturation in the blood is 1%**[1]
- D. **Cyanide: No cyanide is detected in the blood**

[1] Carboxyhemoglobin saturations of 0-3% are expected for non-smokers.

ACLU Detainee DeathII ARMY MEDCOM 905

EXTERNAL EXAMINATION

The body is that of a well-developed, well-nourished appearing, 66 inch tall, 140 pound Middle Eastern male whose appearance is consistent with the reported age of 26 years. Lividity is on the posterior ears and neck, posterior torso and posterior lower extremities and fixed. Rigor is passing, and the temperature is that of the refrigeration unit.

The scalp is covered with 2-inch long straight black hair in a normal distribution. Facial hair consists of a goatee and moustache. The irides are brown, the corneae are cloudy, the conjunctivae are pale, the sclerae are white and the pupils are round and equal in diameter. The external auditory canals are clear. The ears are not pierced. The nares are patent. The nose and maxillae are palpably stable. The teeth appear natural and in good condition. There is a 0.5 cm abrasion on the lower gingival.

The neck is straight, and the trachea is midline and mobile. The chest is symmetric. The abdomen is soft and flat. The genitalia are those of a normal adult male. Pubic hair is present in a normal distribution. The buttocks and anus are unremarkable.

The upper extremities are diffusely edematous. The fingernails are intact. The lower extremities are symmetric and without clubbing or edema.

CLOTHING AND PERSONAL EFFECTS

The following clothing items and personal effects accompany the body at the time of autopsy:

- Blue long-sleeve T-shirt
- White T-shirt
- Black sweatpants
- Green scrub pants
- White socks (2)
- Green towel

MEDICAL INTERVENTION

- Nasogastric tube
- Orogastric tube
- Endotracheal tube
- Large-bore intravenous catheter left neck with associated underlying soft tissue hemorrhage
- Foley catheter
- Multiple needle puncture sites upper and lower extremities with associated contusions
- EKG leads (3) on torso
- Defibrillator pad outlines (2) on chest
- One bag of intravenous normal saline
- One bag of intravenous fluid with morphine sulfate

ACLU Detainee DeathII ARMY MEDCOM 906

RADIOGRAPHS

A complete set of postmortem radiographs is obtained and demonstrates no fractures and no internal metal fragments

INTERNAL EXAMINATION

HEAD:
The calvarium is intact, as is the dura mater beneath it. Clear cerebrospinal fluid surrounds the 1350 gm brain (fresh weight). Please see Neuropathology Addendum. There are no skull fractures.

NECK:
Layer-wise dissection of the anterior and posterior neck structures reveals no injury. The thyroid cartilage and hyoid bone are intact. The larynx is lined by intact white mucosa. The thyroid gland is symmetric and red-brown, without cystic or nodular change. The tongue is free of bite marks, hemorrhage, or other injuries.

BODY CAVITIES:
The ribs, sternum, and vertebral bodies are visibly and palpably intact. There are bilateral pleural effusions (100 ml right, 50 ml left). There is a pericardial effusion (50 ml). There is a peritoneal effusion (50 ml). The organs occupy their usual anatomic positions.

RESPIRATORY SYSTEM:
The right and left lungs weigh 1010 and 830 gm, respectively. The external surfaces are smooth and deep red-purple. The pulmonary parenchyma is severely congested and edematous. Focal areas of consolidation are present.

CARDIOVASCULAR SYSTEM:
The 440 gm heart is contained in an intact pericardial sac. Please see Cardiovascular Pathology Addendum. The aorta gives rise to three intact and patent arch vessels. The renal and mesenteric vessels are unremarkable.

LIVER & BILIARY SYSTEM:
The 1800 gm liver has an intact, smooth capsule and a sharp anterior border. The parenchyma is tan-brown and congested, with the usual lobular architecture. No mass lesions or other abnormalities are seen. The gallbladder contains 20 ml of green-black bile and no stones. The mucosal surface is green and velvety. The extrahepatic biliary tree is patent.

SPLEEN:
The 360 gm spleen has a smooth, intact, red-purple capsule. The parenchyma is maroon and congested, with distinct Malpighian corpuscles.

PANCREAS:
The pancreas is firm and yellow-tan, with the usual lobular architecture. No mass lesions or other abnormalities are seen.

ACLU Detainee DeathII ARMY MEDCOM 907

ADRENALS:
The right and left adrenal glands are symmetric, with bright yellow cortices and gray medullae. No masses or areas of hemorrhage are identified.

GENITOURINARY SYSTEM:
The right and left kidneys weigh 140 and 170 gm, respectively. The external surfaces of the kidneys are intact and smooth. The cut surfaces are red-tan and congested, with uniformly thick cortices and sharp corticomedullary junctions. The pelves are unremarkable and the ureters are normal in course and caliber. Gray-pink bladder mucosa overlies an intact bladder wall. The bladder contains 100 ml of yellow urine. The prostate is normal in size, with lobular, yellow-tan parenchyma. The seminal vesicles are unremarkable. The testes are free of mass lesions, contusions, or other abnormalities

GASTROINTESTINAL TRACT:
The esophagus is intact and lined by smooth, gray-white mucosa. The stomach contains approximately 5 ml of brown liquid. The gastric wall is intact. The duodenum, loops of small bowel and colon are unremarkable. The appendix is present.

MUSCULOSKELETAL SYSTEM:
There are no bone or joint abnormalities. Skeletal muscle development is normal. Cut downs of the upper and lower extremities and back are unremarkable.

MICROSCOPIC EXAMINATION

- Lung: One section of lung demonstrates bronchopneumonia; another section of lung demonstrates pulmonary edema
- Liver: No significant microscopic abnormalities
- Kidney: No significant microscopic abnormalities

ADDITIONAL PROCEDURES

- Documentary photographs are taken by OAFME staff photographers
- Full body radiographs are obtained
- Specimens retained for toxicological testing and/or DNA identification are: spleen, liver, blood, bile, urine, gastric contents, vitreous fluid, psoas muscle, adipose tissue, lung and kidney
- The dissected organs are forwarded with body.
- Selected portions of organs are retained in formalin, with preparation of histological slides of the lungs, liver and kidney
- Personal effects are released to the appropriate mortuary operations representatives
- The heart and brain are submitted for further examination by cardiovascular pathology and neuropathology, respectively
- Re-association of the heart (Dover # 9450) and the brain (Dover # 9451)

ACLU Detainee DeathII ARMY MEDCOM 908

OPINION

This 26 year-old Iraqi detainee died of left ventricular hypertrophy with focal subendocardial interstitial and replacement fibrosis. There was no evidence of recent significant injury or bruising on the head. Per investigative reports, there were conflicting reports of possible head trauma when the deceased was examined at two different medical treatment facilities in Iraq. A head CT scan at one facility reportedly demonstrated "severe anoxic brain injury with herniation, cephalohematoma in scalp right occipital and left parietal". Hypoxic changes in the brain can result in herniation, however there was no evidence of blunt force trauma or herniation at the time of autopsy. The heart demonstrated enlargement of the left ventricle, which has been associated with fatal arrhythmias. The brain demonstrated changes consistent with a decrease in blood flow, which could occur as a result of a cardiac arrhythmia. Microscopic sections of one of the lungs demonstrated focal bronchopneumonia, which most likely developed while the deceased was hospitalized for 4 days. Sections of the liver and kidney were unremarkable. Toxicological testing was negative for ethanol and cyanide. The carboxyhemoglobin saturation in the blood was 1%. Two drugs associated with resuscitation, lorazepam and 1-Hydroxymidazolam, were detected in the urine. A third drug associated with resuscitation, morphine, was detected in the urine and quantitated in the liver at a concentration consistent with therapeutic dosing. The manner of death is natural.

(b)(6)

(b)(6) **Medical Examiner**

(b)(6)

(b)(6) **Medical Examiner** (b)(6)

ACLU Detainee DeathII ARMY MEDCOM 909

NEUROPATHOLOGY ADDENDUM

(b)(6)

BRAIN, AUTOPSY: DIFFUSE HYPOXIC/ISCHEMIC CHANGES

We examined the approximately 1380-gram formalin-fixed brain submitted in reference to this case.

The dura is unremarkable without hemorrhages or masses. The leptomeninges are translucent without hemorrhages. The cerebral hemispheres are symmetrical. The gyral pattern is normal. The circle of Willis has a normal adult configuration without aneurysms, significant atherosclerosis, or sites of occlusion. The cranial nerves, cerebellum, and brainstem are unremarkable. The optic chiasm is gray and soft. There is no evidence of uncal, tonsillar, or subfalcine herniation. Serial coronal sections of the cerebrum show a cortical ribbon of normal thickness, well demarcated from subjacent white matter. Myelination is normal. The ventricular system is of normal size and shape. The basal ganglia, hippocampi, thalami, and hypothalamus are unremarkable. Serial sectioning of the cerebellum shows some dusky discoloration. The left cerebellar tonsil is more prominent than the right. The brainstem is unremarkable. The substantia nigra and locus ceruleus are normally pigmented for age. The aqueduct is patent. The spinal cord is not submitted, but the uppermost cervical cord and cervicomedullary junction are unremarkable.

Summary of microscopic sections: 1. left middle frontal gyrus. 2. left cingulate gyrus. 3. left superior/middle temporal gyri. 4. mamillary bodies. 5. left basal ganglia. 6. optic chiasm. 7. right thalamus. 8. left parietal lobule. 9. left hippocampus. 10. vermis. 11. right hippocampus. 12. left cerebellar dentate nucleus.13. left cerebellar tonsil.14. right cerebellar tonsil. 15. dusky right cerebellum 16. dusky left cerebellum. 17. occipital lobe. 18. substantia nigra. 19. pons. 20. medulla.

The tissue was processed in paraffin; a section prepared from each paraffin block was stained with H&E. Additional sections prepared from selected blocks were stained with GMS and PAS.

Microscopic sections demonstrate diffuse neuronal hypoxic/ischemic changes in the cerebrum and cerebellum. Purkinje cell loss is noted with developed Bergmann gliosis. Neutrophils are present in the optic chiasm. The left thalamus has focal intravascular branching structures that are PAS positive and GMS negative. This may represent fibrin. The underlying cause of the diffuse hypoxic/ischemic changes is undetermined.

(b)(6)

6/13/2007

ACLU Detainee DeathII ARMY MEDCOM 910

CARDIOVASCULAR PATHOLOGY ADDENDUM

FINAL DIAGNOSIS

DIAGNOSIS: (b)(6)

1. **Subendocardial coagulative necrosis and multifocal single cell contraction band necrosis, left ventricle**
2. **Left ventricular hypertrophy with focal subendocardial interstitial and replacement fibrosis**

History: 26 year old Iraqi detainee found unresponsive by other detainees, resuscitated and later removed from life support

Heart: 440 grams, per contributor; normal epicardial fat; probe patent foramen ovale; concentric left ventricular hypertrophy: left ventricular cavity diameter 30 mm, left ventricular free wall thickness 17 mm, ventricular septum thickness 18 mm; right ventricular dilatation: right ventricle thickness 5 mm, without gross scars or abnormal fat infiltrates; grossly unremarkable valves and endocardium; subendocardial hemorrhage, ventricular septum and posteromedial papillary muscle; histologic sections show left ventricular myocyte hypertrophy with focal subendocardial interstitial and replacement fibrosis, posterior and septal left ventricle; coagulative necrosis, posteromedial papillary muscle and posterior septum; multifocal single cell contraction band necrosis (brain death lesions)

Coronary arteries: Normal ostia, right dominance; no gross atherosclerosis

Comment: The subendocardial necrosis and multifocal single cell contraction band necrosis are secondary to anoxic brain injury and catecholamine release following a period of hypoperfusion. The cause of the initial cardiac arrest is uncertain, but may be due to arrhythmia associated with left ventricular hypertrophy and subendocardial fibrosis.

(b)(6)

Cardiovascular Pathologist

ACLU Detainee DeathII ARMY MEDCOM 911

CERTIFICATE OF DEATH *(OVERSEAS)*
Acte de décès (D'Outre-Mer)

NAME OF DECEASED (Last, First, Middle) Nom du décédé (Nom et prénoms)	GRADE Grade	BRANCH OF SERVICE Arme	SOCIAL SECURITY NUMBER Numéro de l'Assurance Social
Mahmud, BTB Karwan, Muhammad Ali		Civilian	(b)(6)

ORGANIZATION Organisation	NATION (e.g. United States) Pays	DATE OF BIRTH Date de naissance	SEX Sexe
Iraqi Detainee	Iraq	(b)(6) 1980	[X] MALE [ ] FEMALE

RACE Race		MARITAL STATUS État Civil			RELIGION Culte		
[X]	CAUCASOID Caucasique		SINGLE Célibataire		DIVORCED Divorcé		PROTESTANT Protestant		OTHER (Specify) Autre (Spécifier)
[ ]	NEGROID Negroide		MARRIED Marié		SEPARATED Séparé		CATHOLIC Catholique	[X]	
[ ]	OTHER (Specify) Autre (Spécifier)		WIDOWED Veuf				JEWISH Juif		

NAME OF NEXT OF KIN Nom du plus proche parent	RELATIONSHIP TO DECEASED Parenté du décédé avec le sus
STREET ADDRESS Domicilé à (Rue)	CITY OR TOWN OR STATE (Include ZIP Code) Ville (Code postal compris)

MEDICAL STATEMENT Déclaration médicale

	CAUSE OF DEATH (Enter only one cause per line) Cause du décès (N'indiquer qu'une cause par ligne)	INTERVAL BETWEEN ONSET AND DEATH Intervalle entre l'attaque et le décès
DISEASE OR CONDITON DIRECTLY LEADING TO DEATH [1] Maladie ou condition directement responsable de la mort. [1]	Left ventricular hypertrophy with focal subendocardial interstitial and replacement fibrosis	
ANTECEDENT CAUSES Symptômes précurseurs de la mort. — MORBID CONDITION, IF ANY, LEADING TO PRIMARY CAUSE Condition morbide, s'il y a lieu, menant à la cause primaire		
ANTECEDENT CAUSES Symptômes précurseurs de la mort. — UNDERLYING CAUSE, IF ANY, GIVING RISE TO PRIMARY CAUSE Condition morbide, s'il y a lieu, menant à la cause primaire		
OTHER SIGNIFICANT CONDITIONS [2] Autres conditions significatives [2]		

MODE OF DEATH Condition de décès	AUTOPSY PERFORMED Autopsie effectuée [X] YES Oui [ ] NO Non	CIRCUMSTANCES SURROUNDING DEATH DUE TO EXTERNAL CAUSES Circonstances de la mort suscitées par des causes extérieures
[X] NATURAL Mort naturelle	MAJOR FINDINGS OF AUTOPSY Conclusions principales de l'autopsie	
[ ] ACCIDENT Mort accidentelle		
[ ] SUICIDE Suicide	NAME OF PATHOLOGIST Nom du pathologiste (b)(6)	
[ ] HOMICIDE Homicide	SIGNATURE (b)(6) — DATE Date 13 April 2007	AVIATION ACCIDENT Accident à Avion [ ] YES Oui [X] NO Non

DATE OF DEATH (day, month, year) Date de décès (le jour, le mois, l'année)	PLACE OF DEATH Lieu de décès
(b)(6) 2007	Camp Bucca Iraq

I HAVE VIEWED THE REMAINS OF THE DECEASED AND DEATH OCCURRED AT THE TIME INDICATED AND FROM THE CAUSES AS STATED ABOVE.
J'ai examiné les restes mortels du dé funtet je conclus que le décès est survenu à l'heure indiquée et à, la suite des causes énumérées ci-dessus

NAME OF MEDICAL OFFICER Nom du médicin militaire ou du médicin sanitaire	TITLE OR DEGREE Titre ou diplômé
(b)(6)	Medical Examiner

GRADE Grade	INSTALLATION OR ADDRESS Installation ou adresse
(b)(6)	Dover AFB Dover DE
DATE Date 6/21/2007	SIGNATURE (b)(6)

[1] State disease, injury or complication which caused death, but not mode of d
[2] State conditions contributing to the death, but not related to the disease or condition causing death
[1] Préciser la nature de la maladie, de la blessure ou de la complication qui a contribué à la mort, mais non la manière de mourir, telle qu'un arrêt du coeur, etc
[2] Préciser la condition qui a contribué à la mort, mais n'ayant aucun rapport avec la maladie ou à la condition qui a provoqué la mort

DD FORM 1 APR 77 2064 REPLACES DA FORM 3565, 1 JAN 72 AND DA FORM 3565-R(PAS), 26 SEP 75, WHICH ARE OBSOLETE.

ACLU Detainee DeathII ARMY MEDCOM 912

(REMOVE, REVERSE AND RE-INSERT CARBONS BEFORE COMPLETING THIS SIDE)

DISPOSITON OF REMAINS

NAME OF MORTICIAN PREPARING REMAINS	GRADE	LICENSE NUMBER AND STATE	OTHER

INSTALLATION OR ADDRESS	DATE	SIGNATURE

NAME OF CEMETERY OR CREMATORY	LOCATION OF CEMETERY OR CREMATORY

TYPE OF DISPOSTION	DATE OF DISPOSTION

REGISTRATION OF VITAL STATISTICS

REGISTRY *(Town and Country)*	DATE REGISTERED	FILE NUMBER	
		STATE	OTHER

NAME OF FUNERAL DIRECTOR	ADDRESS

SIGNATURE OF AUTHORIZED INDIVIDUAL

DD FORM 2064, APR 1977 (BACK) *USAPA V1.00*

ACLU Detainee DeathII ARMY MEDCOM 913

ARMED FORCES INSTITUTE OF PATHOLOGY
Office of the Armed Forces Medical Examiner
1413 Research Blvd., Bldg. 102
Rockville, MD 20850
1-301-319-0000

FINAL AUTOPSY REPORT

Name: Nassir Jabrin, Umar Sa'ad
ISN: (b)(6)
Date of Birth: (BTB (b)(6) 1985
Date of Death (b)(6) 2007
Date of Autopsy: 9 Apr 2007 @ 1300
Date of Report: 11 May 2007

Autopsy No. (b)(6)
AFIP No.: (b)(6)
Rank: Detainee
Place of Death: Iraq
Place of Autopsy: Port Mortuary
Dover AFB, DE

Circumstances of Death: This 22 year-old Saudi detainee was found deceased in a garbage dumpster.

Authorization for Autopsy: Office of the Armed Forces Medical Examiner, IAW 10 USC 1471

Identification: Presumptive identification is established by a wrist identification band. Post-mortem fingerprints, dental examination, and a specimen suitable for DNA analysis are obtained.

CAUSE OF DEATH: **Multiple Blunt Force Injuries Complicated by Manual Strangulation and Chest Compression**

MANNER OF DEATH: **Homicide**

ACLU Detainee DeathII ARMY MEDCOM 914

FINAL AUTOPSY DIAGNOSES:

I. **Multiple Blunt Force Injuries:**

A. **Head and Neck:**

1. Diffuse bilateral scleral hemorrhage
2. Abrasion of the forehead, ¾ x ½-inch
3. Bilateral periorbital contusions
4. Contusions of the upper and lower lips and oral mucosa
5. Abrasion of the left side of the nose, ¼-inch
6. Abrasions of the right side of the face, 1-inch, and right side of the neck, 2-inches
7. Contusion of the right side of the neck, 1 x ½-inch
8. Abrasion of the left side of the neck, 3/8-inch
9. Contusion of the posterior neck, 2 x 1-inch
10. Diffuse subgaleal hemorrhage
11. Hemorrhage in both temporalis muscles

B. **Torso:**

1. Contusion of the left side of the chest and abdomen, 9 x 1-inch
2. Abrasion of the left side of the chest, 1-inch
3. Patterned contusion of the left lower quadrant of the abdomen and left hip, 3 x 3-inches
4. Patterned abrasion of the right lower quadrant of the abdomen, 2 ½ x 1-inch
5. Contusion of the upper right back, 1 ¼ x ¾-inch
6. Patterned contusion of the upper right back, 3 x 2-inches
7. Contusion of the lower mid back, ¾ x ½-inch
8. Right hemothorax, 200 ml
9. Fractures of the anterior left ribs, 2nd-9th
10. Fractures of the left pubis and ischium
11. Fracture of the right ischium
12. Fractures of the left transverse processes of the 2nd-4th lumbar vertebral bodies
13. Fracture of the right sacroiliac joint
14. Rupture of the left and right hemidiaphragm with associated displacement of abdominal contents into the thorax
15. Rupture of the stomach with gastric contents in the left thorax
16. Mesenteric hemorrhage
17. Laceration of the right adrenal gland, 0.5 cm
18. Right periadrenal hemorrhage

C. **Extremities:**

1. Contusion of the right elbow, 1 x ¾-inch
2. Contusion of the left shoulder, 2 ¾ x 1 ¾-inches
3. Abrasion of the left shoulder, ¼ x 1/8-inch
4. Contusion of the left arm, 2 ½ x ½-inch
5. Abrasion of the left axilla, ¾ x 1/8-inch

ACLU Detainee DeathII ARMY MEDCOM 915

6. Contusion of the anterior right thigh, 8 x ½-inch
7. Abrasions (2) of the right leg, ¼-inch and 1/8-inch
8. Contusion of the left buttock, 2 x 1-inch
9. Contusions (2) of the anterior left thigh, 3 x 2-inches and 4 x 1 ½-inches

II. Evidence of Manual Strangulation and Chest Compression
   A. Neck:
      1. Diffuse bilateral scleral hemorrhage (see I. A. 1.)
      2. Numerous bilateral petechial hemorrhages of the upper chest
      3. Diffuse bilateral hemorrhage of the anterior and posterior neck musculature
      4. Diffuse hemorrhage of the thyroid
      5. Contusion of the right side of the neck, 1 x ½-inch (see I.A.7.)
      6. Abrasion of the left side of the neck, 3/8-inch (see I.A.8.)
      7. Contusion of the posterior neck, 2 x 1-inch (see I.A.9.)
      8. Hyoid bone and thyroid cartilage intact

III. Evidence of natural disease: See addendum for cardiovascular pathology

IV. No evidence of medical intervention

V. Identifying marks or tattoos: Vertical scar on mid chest, 8-inch

VI. Toxicology (AFIP):
   A. Volatiles: No ethanol is detected in the blood or vitreous fluid
   B. Drugs: No screened drugs of abuse or medications are detected in the blood
   C. Carbon Monoxide: The carboxyhemoglobin saturation in the blood is less than 1%[1]
   D. Cyanide: No cyanide is detected in the blood

[1] Carboxyhemoglobin saturations of 0-3% are expected for non-smokers.

ACLU Detainee DeathII ARMY MEDCOM 916

EXTERNAL EXAMINATION

The body is that of a well-developed, well-nourished appearing, 65-inch tall, 103 pound male whose appearance is consistent with the reported age of 22 years. Lividity is on the posterior torso and posterior extremities and fixed. Rigor is passing, and the temperature is cool.

The scalp is covered with 1 1/2-inch long straight brown hair in a normal distribution. Facial hair consists of a moustache and beard. The irides are brown, the corneae are cloudy, the conjunctivae are unremarkable, the sclerae are diffusely hemorrhagic bilaterally and the pupils are round and equal in diameter. The external auditory canals are clear. The ears are not pierced. The nares are patent with blood present bilaterally. The nose and maxillae are palpably stable. The teeth appear natural.

The neck is straight, and the trachea is midline and mobile. The chest is symmetric. The abdomen is soft and flat. The genitalia are those of a normal adult male. Pubic hair is present in a normal distribution. The buttocks and anus are unremarkable.

The upper and lower extremities are symmetric and without clubbing or edema. Please refer to the evidence of injury section for injury to the torso and extremities.

CLOTHING AND PERSONAL EFFECTS

The following clothing items and personal effects are present on the body at the time of autopsy:

- Yellow pants
- Three video cameras
- Four cassette tapes
- One USB cable
- Two silver cases labeled "Mobile Disk External Data Storage"
- Two unknown silver electronic accessory items

MEDICAL INTERVENTION

- No evidence of medical intervention

RADIOGRAPHS

A complete set of postmortem radiographs is obtained and demonstrates the following:

- Skeletal trauma to the torso as noted below

ACLU Detainee DeathII ARMY MEDCOM 917

EVIDENCE OF INJURY

I. Multiple Blunt Force Injuries:

A. Head and Neck:

There is an abrasion of the forehead, ¾ x ½-inch. There are bilateral periorbital contusions. There is diffuse bilateral scleral hemorrhage. There are contusions of the upper and lower lips and oral mucosa, ¼-inch to 2 x ½-inch. There is an abrasion of the left side of the nose, ¼-inch. There is an abrasion of the right side of the face, 1-inch, and an abrasion of the right side of the neck, 2-inches. There is diffuse subgaleal hemorrhage. There is hemorrhage in both temporalis muscles.

B. Torso:

There is a contusion of the left side of the chest and abdomen, 9 x 1-inch. There is abrasion of the left side of the chest, 1-inch. There is a semi-circular patterned contusion of the left lower quadrant of the abdomen and left hip, 3 x 3-inches. There is a contusion of the right upper back, 1 ¼ x ¾-inch. There is a semi-circular patterned contusion of the right upper back, 3 x 2-inches. There is a contusion of the mid lower back, ¾ x ½-inch. There are fractures of the anterior 2nd-9th left ribs. There is a right hemothorax, 200 ml. There is rupture of the left and right hemidiaphragm with associated displacement of the abdominal contents into the thorax. There is rupture of the stomach with gastric contents in the left thorax. There is hemorrhage of the mesentery. There is a laceration of the right adrenal gland, 0.5 cm, and right periadrenal hemorrhage. There are fractures of the left pubis and ischium, right ischium, and right sacroiliac joint. There are fractures of the left transverse processes of the 2nd-4th lumbar vertebral bodies.

C. Extremities:

There is a contusion of the left shoulder, 2 ¾ x 1 ¾-inches, and an abrasion of the left shoulder, ¼ x 1/8-inch. There is a contusion of the right arm, 2 ½ x ½-inch. There is a contusion of the right elbow, 1 x ¾-inch. There is an abrasion of the left axilla, ¾ x 1/8-inch. There is a contusion of the anterior right thigh, 8 x ½-inch. There are two (2) contusions of the anterior left thigh, 3 x 2-inches and 4 x 1 ½-inches. There is a contusion of the left buttock, 2 x 1-inch. There are two (2) abrasions of the right leg, ¼-inch and 1/8-inch.

II. Evidence of Manual Strangulation and Chest Compression:

A. Head and Neck:

There is diffuse bilateral scleral hemorrhage. There is a contusion of the right side of the neck, 1 x ½-inch. There is a contusion of the left side of the neck, 3/8-inch. There is a contusion of the posterior neck, 2 x 1-inch. There is diffuse bilateral hemorrhage of the anterior and posterior neck musculature. There is diffuse bilateral hemorrhage of the thyroid. The hyoid bone and thyroid cartilage are intact.

B. Torso:

There are numerous bilateral petechial hemorrhages of the upper chest.

ACLU Detainee DeathII ARMY MEDCOM 918

INTERNAL EXAMINATION

HEAD:
See "Evidence of Injury". The calvarium is intact, as is the dura mater beneath it. Clear cerebrospinal fluid surrounds the 1550 gm brain, which has unremarkable gyri and sulci. Coronal sections demonstrate sharp demarcation between white and grey matter, without hemorrhage or contusive injury. The ventricles are of normal size. The basal ganglia, brainstem, cerebellum, and arterial systems are free of injury or other abnormalities. There are no skull fractures.

NECK:
Separate anterior and posterior neck dissections are performed. See "Evidence of Injury". The thyroid cartilage and hyoid bone are intact. The larynx is lined by intact white mucosa. The thyroid gland is symmetric and hemorrhagic, without cystic or nodular change. The tongue is free of bite marks, hemorrhage, or other injuries.

BODY CAVITIES:
See "Evidence of Injury". The sternum and vertebral bodies are visibly and palpably intact. No excess fluid is in the left pleural and peritoneal cavities. The organs occupy their usual anatomic positions.

RESPIRATORY SYSTEM:
The right and left lungs weigh 230 and 210 gm, respectively. The external surfaces are smooth and deep red-purple. The pulmonary parenchyma is moderately congested and edematous. No areas of consolidation are present.

CARDIOVASCULAR SYSTEM:
The heart weighs 390 gm and is adherent to the chest wall. The heart is sent for cardiovascular pathology evaluation (see addendum). The aorta gives rise to three intact and patent arch vessels. The renal and mesenteric vessels are unremarkable.

LIVER & BILIARY SYSTEM:
The 1050 gm liver has an intact, smooth capsule and a sharp anterior border. The parenchyma is tan-brown and congested, with the usual lobular architecture. No mass lesions or other abnormalities are seen. The gallbladder contains 10 ml of green-black bile and no stones. The mucosal surface is green and velvety. The extrahepatic biliary tree is patent.

SPLEEN:
The 70 gm spleen has a smooth, intact, red-purple capsule. The parenchyma is maroon and congested, with distinct Malpighian corpuscles.

PANCREAS:
The pancreas is firm and yellow-tan, with the usual lobular architecture. No mass lesions or other abnormalities are seen.

ACLU Detainee DeathII ARMY MEDCOM 919

ADRENALS:
See "Evidence of Injury". The right and left adrenal glands have bright yellow cortices and grey medullae. No non-traumatic lesions are seen.

GENITOURINARY SYSTEM:
The right and left kidneys weigh 120 and 100 gm, respectively. The external surfaces of the kidneys are intact and smooth. The cut surfaces are pale tan, with uniformly thick cortices and sharp corticomedullary junctions. The pelves are unremarkable and the ureters are normal in course and caliber. Grey-pink bladder mucosa overlies an intact bladder wall. The bladder contains 10 ml of clear yellow urine. The prostate is normal in size, with lobular, yellow-tan parenchyma. The seminal vesicles are unremarkable. The testes are free of mass lesions, contusions, or other abnormalities

GASTROINTESTINAL TRACT:
See "Evidence of Injury". The esophagus is intact and lined by smooth, grey-white mucosa. There are 100 ml of tan semi-solid gastric contents in the left thorax. The duodenum, loops of small bowel and colon are unremarkable. The appendix is present.

MUSCULOSKELETAL SYSTEM:
Dissection of the subcutaneous tissue of the back and both upper and lower extremities is performed. See "Evidence of Injury". There are no non-traumatic bone or joint abnormalities. Skeletal muscle development is normal.

ADDITIONAL PROCEDURES

- Documentary photographs are taken by OAFME staff photographers
- Full body radiographs are obtained
- Specimens retained for toxicological testing and/or DNA identification are: blood, spleen, liver, brain, bile, urine, gastric contents, vitreous, psoas muscle, adipose tissue, lung and kidney
- The dissected organs are forwarded with body
- The heart is retained for consultation
- Selected portions of organs are retained in formalin, without preparation of histological slides
- Personal effects are released to the appropriate mortuary operations representatives

ACLU Detainee DeathII ARMY MEDCOM 920

OPINION

This 22 year-old male (b)(6) died of multiple blunt force injuries complicated by manual strangulation and chest compression. There were blunt force injuries to the head, neck, torso, and upper and lower extremities. There were injuries to the head, neck and torso consistent with manual strangulation and chest compression. Toxicological testing for ethanol, drugs of abuse, medications, and cyanide was negative. The carboxyhemoglobin concentration was less than 1%. The manner of death is homicide.

(b)(6)

(b)(6) Medical Examiner

(b)(6)

(b)(6) Medical Examiner

(b)(6)

ACLU Detainee DeathII ARMY MEDCOM 921

ADDENDUM

DIAGNOSIS (b)(6) **Congenital heart disease:**

1. **Pulmonic stenosis with subvalvular fibrous band, status post valvuloplasty**
2. **Bicuspid aortic valve**
3. **Patch repair of atrial septal defect**

History: 22 year old Iraqi detainee found in a garbage bag at internment facility; sternotomy scar noted at autopsy

Heart: 280 grams; diffuse fibrous pericardial adhesions and 2 x 1 cm hematoma on posterior surface of left ventricle at apex; patch repair of atrial septal defect; normal left ventricular chamber dimensions: left ventricular cavity diameter 25 mm, left ventricular free wall thickness 13 mm, ventricular septum thickness 15 mm; right ventricular hypertrophy: right ventricle thickness 7 mm; endocardial thickening, right ventricle; pulmonic stenosis: endocardial fibrous band below pulmonic valve extending inferiorly from commissures of anterior and right pulmonic cusps, absent left pulmonic cusp; thickened tricuspid valve leaflets; bicuspid aortic valve: conjoined anterior leaflet with midline raphe between left and right coronary cusps; suture material and fibrosis, anterior right ventricle; histologic sections show mild subendocardial interstitial fibrosis, posterior left ventricle, otherwise unremarkable endocardium; focal bone marrow embolus, epicardial coronary artery, anterior left ventricle

Coronary arteries: Normal ostia; right dominance; no gross atherosclerosis

Comment: The primary abnormality appears to be pulmonic stenosis, possibly arising in a bicuspid pulmonic valve. However, because there has been prior valvuloplasty, the morphology of the pulmonic valve has been altered and the original pathologic condition cannot be determined with certainty. Also, the coincidence of bicuspid pulmonic and aortic valves is extremely rare.

(b)(6)
Cardiovascular Pathologist

Blocks made: 5 heart
Slides made: 5 H&E

ACLU Detainee DeathII ARMY MEDCOM 922

CERTIFICATE OF DEATH *(OVERSEAS)*

Acte dé décès (D'Outre-Mer)

NAME OF DECEASED *(Last, First, Middle)* Nom du décédé (Nom et prénoms)	GRADE Grade	BRANCH OF SERVICE Arme	SOCIAL SECURITY NUMBER Numéro de l'Assurance Social
Nassir Jabrin, Umar Sa'ad,		Civilian	(b)(6)

ORGANIZATION Organisation	NATION *(e.g. United States)* Pays	DATE OF BIRTH Date de naissance	SEX Sexe
Iraqi Detainee	Saudi Arabia	(b)(6) 1985	[X] MALE [ ] FEMALE

RACE Race		MARITAL STATUS État Civil				RELIGION Culte			
[X]	CAUCASOID Caucasique	[ ]	SINGLE Célibataire	[ ]	DIVORCED Divorcé	[ ]	PROTESTANT Protestant	[X]	OTHER (Specify) Autre (Spécifier)
[ ]	NEGROID Negroide	[ ]	MARRIED Marié	[ ]	SEPARATED Séparé	[ ]	CATHOLIC Catholique		
[ ]	OTHER (Specify) Autre (Spécifier)	[ ]	WIDOWED Veuf			[ ]	JEWISH Juif		

NAME OF NEXT OF KIN Nom du plus proche parent	RELATIONSHIP TO DECEASED Parenté du décédé avec le sus
STREET ADDRESS Domicilé à (Rue)	CITY OR TOWN OR STATE *(Include ZIP Code)* Ville (Code postal compris)

MEDICAL STATEMENT Déclaration médicale

CAUSE OF DEATH (Enter only one cause per line) Cause du décès (N'indiquer qu'une cause par ligne)		INTERVAL BETWEEN ONSET AND DEATH Intervalle entre l'attaque et le décès
DISEASE OR CONDITON DIRECTLY LEADING TO DEATH [1] Maladie ou condition directement responsable de la mort.	Multiple blunt force injuries complicated by manual strangulation and chest compression	
ANTECEDENT CAUSES Symptômes précurseurs de la mort	MORBID CONDITION, IF ANY, LEADING TO PRIMARY CAUSE Condition morbide, s'il y a lieu, menant à la cause primaire	
	UNDERLYING CAUSE, IF ANY, GIVING RISE TO PRIMARY CAUSE Condition morbide, s'il y a lieu, menant à la cause primaire	
OTHER SIGNIFICANT CONDITIONS [2] Autres conditions significatives [2]		

MODE OF DEATH Condition de décès	AUTOPSY PERFORMED Autopsie effectuée [X] YES Oui [ ] NO Non	CIRCUMSTANCES SURROUNDING DEATH DUE TO EXTERNAL CAUSES Circonstances de la mort suscitées par des causes extérieures
[ ] NATURAL Mort naturelle	MAJOR FINDINGS OF AUTOPSY Conclusions principales de l'autopsie	
[ ] ACCIDENT Mort accidentelle		
[ ] SUICIDE Suicide	NAME OF PATHOLOGIST Nom du pathologiste (b)(6)	
[X] HOMICIDE Homicide	SIGNATURE (b)(6) DATE Date 9 April 2007	AVIATION ACCIDENT Accident à Avion [ ] YES Oui [X] NO Non

DATE OF DEATH *(day, month, year)* Date de décès (le jour, le mois, l'année)	PLACE OF DEATH Lieu de décès
(b)(6) 2007 (b)(6)	Iraq

I HAVE VIEWED THE REMAINS OF THE DECEASED AND DEATH OCCURRED AT THE TIME INDICATED AND FROM THE CAUSES AS STATED ABOVE
J'ai examiné les restes mortels du dé funtet je conclus que le décès est survenu à l'heure indiquée et à, la suite des causes énumérées ci-dessus.

(b)(6)	TITLE OR DEGREE Titre ou diplôme: Medical Examiner

GRADE Grade	INSTALLATION OR ADDRESS Installation ou adresse
(b)(6)	Dover AFB, Dover DE
DATE Date 5/15/2007	SIGNATURE (b)(6)

[1] State disease, injury or complication which caused death, but not mode of d
[2] State conditions contributing to the death, but not related to the disease or condition causing death.
[1] Préciser la nature de la maladie, de la blessure ou de la complication qui a contribué à la mort, mais non la manière de mourir, telle qu'un arrêt du coeur, etc
[2] Préciser la condition qui a contribué à la mort, mais n'ayant aucun rapport avec la maladie ou à la condition qui a provoqué la mort.

DD FORM 1 APR 77 2064 REPLACES DA FORM 3565, 1 JAN 72 AND DA FORM 3565-R(PAS), 28 SEP 76, WHICH ARE OBSOLETE.

MEDCOM 0923

ACLU Detainee DeathII ARMY MEDCOM 923

ARMED FORCES INSTITUTE OF PATHOLOGY
Office of the Armed Forces Medical Examiner
1413 Research Blvd., Bldg. 102
Rockville, MD 20850
301-319-0000

FINAL AUTOPSY REPORT

Name: Muhammad, Khayri Naim
CID#: (b)(6)
Date of Birth: (b)(6) 1972
Date of Death: (b)(6) 07 (Found)
Date/Time of Autopsy: 06 MAR 2007 @ 1100
Date of Report: 06 JUL 2007

Autopsy No.: (b)(6)
AFIP No.: (b)(6)
Rank: Civilian, Detainee
Place of Death: Iraq
Place of Autopsy: Port Mortuary, Dover AFB, Dover, DE

Circumstances of Death: This 34 year-old civilian detainee was interned at Compound 3-C, Camp Remembrance II, Theater Internment Facility, Camp Cropper, Baghdad, Iraq when, as reported, he was found unresponsive in a latrine stall with a pair of yellow trousers tied around his neck.

Authorization for Autopsy: Office of the Armed Forces Medical Examiner, IAW 10 USC 1471.

Identification: Presumptive identification by examination of papers in case file. Post-mortem specimen suitable for DNA analysis is obtained.

CAUSE OF DEATH: **Asphyxia due to strangulation**

MANNER OF DEATH: **Homicide**

ACLU Detainee DeathII ARMY MEDCOM 924

FINAL AUTOPSY DIAGNOSES

I. Strangulation:
- A. A nearly contiguous ligature mark is around the neck
- B. Petechiae of conjunctivae of the right and left, upper and lower eyelids and the mucosa of the upper lip
- C. Hemorrhage of the left sterno-hyoid muscle, 1 x 1/4 inch
- D. Hemorrhage of the soft tissue surrounding the left horn of the hyoid bone, 1/4 x 1/4 inch
- E. Hemorrhage of the posterior spinous muscle beneath the ligature mark, 1/2 x 1/2 inch
- F. Additional injuries:
  1. Abrasion of the left side of the forehead, 2-1/2 x 1 inch
  2. Subgaleal hemorrhage, left parietal, 2 x 1 inch
  3. Subgaleal hemorrhage, occiput, 1/4 x 1/4 inch
  4. Hemorrhage of the left temporalis muscle, 3 x 2 inches
  5. Abrasion of the head of the left clavicle, 1/4 x 1/4 inch
  6. Abrasion of the right side of the chest, 3/4 x 1/4 inch
  7. Abrasion of the left side of the lower back, 1/4 x 1/4 inch
  8. Abrasions (3) of the left elbow, ranging from 1/2 inch to 3/4 inch in greatest dimension
  9. Contusion of the sacrum, 2 x 1 inch
  10. Contusion of the left buttock, 2 x 1 inch

II. Other findings:
- A. Edematous lungs:
  1. Right lung, 720 grams (expected 360-570 grams)
  2. Left lung, 710 grams (expected 325-480 grams)

III. Evidence of medical intervention: None

IV. Natural disease: Adhesions of the right lung

V. Post-mortem changes:
- A. Lividity is fixed on the posterior surface of the body except in the areas exposed to pressure
- B. Rigor is resolving in all four extremities
- C. Cloud corneae

VI. Recovered evidence:
- A. Hand bags
- B. Nail clippings and fingernail clipper
- C. White fibers from back of white t-shirt and red fiber from yellow shirt

VII. Toxicology (AFIP):
- A. VOLATILES: No ethanol detected in the blood and vitreous fluid

ACLU Detainee DeathII ARMY MEDCOM 925

B. DRUGS: No screened drugs of abuse/medications detected in the urine
C. CARBON MONOXIDE: The carboxyhemoglobin saturation in the blood was 4% as determined by spectrophotometry with a limit of quantitation of 1%.[1]
D. CYANIDE: None detected in the blood

VIII. Microscopic examination: Lung, right lower lobe – focal intra-alveolus edema and vascular congestion

[1] Carboxyhemoglobin saturations of 0-3% are expected for non-smokers and 3-10% for smokers.

ACLU Detainee DeathII ARMY MEDCOM 926

EXTERNAL EXAMINATION

The body is that of a well-developed, well-nourished male. The body is 68 inches in length, weighs 120 pounds, and appears compatible with the stated age of 34 years old. The body is cold. Lividity is fixed on the posterior surface of the body except in the areas exposed to pressure. Rigor is resolving in all four extremities.

Injury to the head and neck are described in "Evidence of Injury". The head is normocephalic. The scalp hair is grey-black and straight. Facial hair consists of a thin moustache and stubble. The irides are brown. The corneae are cloudy. The conjunctivae are congested with petechiae of both upper and lower eyelids. The sclerae are white. The external auditory canals contain dried blood. The oral cavity and nares are free of foreign material or abnormal secretions. The nasal skeleton is palpably intact. The oral mucosa of the upper lip has petechiae. The teeth are natural and in poor condition. There is a 1 x 1/8 inch scar on the bottom of the chin at the midline.

The chest is symmetric. The genitalia are those of an adult, circumcised male. The upper and lower extremities are symmetric and without clubbing or edema. The fingernails are intact. There is a 2 x 1/4 inch scar on the posterior right arm. There is a 1-1/2 x 1/8 inch scar on the posterior right forearm. There is a 2 x 1/8 inch scar on the posterior left wrist. There is a 1 inch area of hyperpigmented skin on the anterior left hip. There is a 1/4 inch scar on the posterior left leg.

CLOTHING AND PERSONAL EFFECTS

The body is clad a yellow shirt (with blood on the left shoulder), white t-shirt, yellow trousers, and white underwear. Brown paper evidence bags are secured over both hands. On the yellow shirt is a red fiber. On the white t-shirt (between the t-shirt and yellow shirt) is a white fiber. On the left wrist is an ID tag with the name (b)(6) (b)(6).

MEDICAL INTERVENTION

There is no evidence of medical intervention.

RADIOGRAPHS

A complete set of post-mortem radiographs is obtained.

EVIDENCE OF INJURY

I. Strangulation:

A nearly contiguous ligature mark is around the neck consisting primarily of a red abrasion. At the anterior midline, the ligature mark is 1/4 inch wide and located 10-1/2 inches below the top of the head. To the left of the anterior midline, the ligature mark is directed upward at a 10 degree angle. To the right of the anterior midline, the ligature mark is directed upward at a 10 degree angle. At the left ear, the ligature mark is 1/2 inch wide and located 9-1/2 inches below the top of the head. The ligature mark continues across the posterior neck. At the posterior midline, the ligature mark is 1 inch wide and 9-1/4 inches below the top of the head. At the right ear, the ligature mark is 1/4 inch wide and located 9-1/2 inches below the top of the head.

Petechiae are noted on the conjunctivae of the right and left, upper and lower eyelids and the mucosa of the upper lip. Separate anterior neck dissection

ACLU Detainee DeathII ARMY MEDCOM 927

shows a 1 x 1/4 inch hemorrhage of the left sterno-hyoid muscle and a 1/4 x 1/4 inch hemorrhage of the soft tissue surrounding the left horn of the hyoid bone. The hyoid bone and thyroid cartilage are intact. A separate posterior neck dissection shows a 1/2 x 1/2 inch hemorrhage of the spinous muscle beneath the ligature mark.

II. Additional injuries:

There is a 2-1/2 x 1 inch abrasion of the left side of the forehead. There is a 2 x 1 inch subgaleal hemorrhage of the left parietal and a 1/4 x 1/4 inch subgaleal hemorrhage of the occiput. There is a 3 x 2 inch hemorrhage of the left temporalis muscle.

On the head of the left clavicle is a 1/4 x 1/4 inch abrasion. There is a 3/4 x 1/4 inch abrasion of the right side of the chest. There is a 1/4 x 1/4 inch abrasion of the lower left back. On the left elbow are three (3) abrasions that range from 1/2 inch to 3/4 inch in greatest dimension. Posterior superficial incisions reveal a 2 x 1inch contusion of the sacrum and a 2 x 1inch contusion of the left buttock.

INTERNAL EXAMINATION

HEAD: (CENTRAL NERVOUS SYSTEM)
See "Evidence of Injury". The scalp is reflected. The calvarium of the skull is removed. The dura mater and falx cerebri are intact. The leptomeninges are thin and delicate. The cerebral hemispheres are symmetrical. The structures at the base of the brain are intact. Coronal sections through the cerebellum and transverse sections through the brainstem and cerebellum reveal no lesions. The brain weighs 1520 grams.

NECK:
See "Evidence of Injury". The thyroid cartilage and hyoid are intact. The thyroid is symmetric and red-brown, without cystic or nodular change. The larynx is lined by intact white mucosa.

BODY CAVITIES:
The ribs, sternum, and vertebral bodies are visibly and palpably intact. There is no excess fluid in any of the body cavities. There are multiple dense adhesions of the right lung. The organs occupy their usual anatomic positions.

RESPIRATORY SYSTEM:
The upper airway is clear of debris and foreign material; the mucosal surfaces are smooth, yellow-tan and unremarkable. There are multiple dense adhesions of the lobes of the right lung. The right and left lungs weigh 720 and 710 grams, respectively (expected, 360 – 570 gram right lung and 325 – 480 gram left lung). The pulmonary parenchyma is red-purple exuding moderate amounts of blood. No mass lesions are present. The diaphragm is intact. The pulmonary arteries are normally developed and patent without thrombus or embolus.

ACLU Detainee DeathII ARMY MEDCOM 928

CARDIOVASCULAR SYSTEM:
The heart weighs 390 grams (expected 224 – 446 grams for body length). The pericardial surfaces are smooth, glistening and unremarkable. The pericardial sac is free of significant fluid or adhesions. There is increased epicardial fat. The coronary arteries follow their usual course and are widely patent. The atrial and ventricular septum are intact. The valves are unremarkable. The left ventricular septum measures 1.3 centimeters and the left ventricular free wall measures 1.2 centimeters. The right ventricular free wall is 0.3 centimeters thick. The aorta and its major branches arise normally and follow the usual course. There is mild non-calcific atherosclerotic disease of the aorta. The vena cava and its major tributaries return to the heart in the usual distribution and are free of thrombi.

LIVER & BILIARY SYSTEM:
The 1530 gram liver has an intact, smooth capsule and a sharp anterior border. The parenchyma is moderately congested and tan-brown with the usual lobular architecture. No mass lesions or other abnormalities are seen. The gallbladder contains 8 milliliters of green bile. The extrahepatic biliary tree is patent.

SPLEEN:
The 210 gram (expected 150 - 200 grams) spleen has a smooth, intact, red-purple capsule. The parenchyma is maroon with unremarkable lymphoid follicles.

PANCREAS:
The pancreas is firm and yellow-tan, with the usual lobular architecture. No mass lesions or other abnormalities are seen.

ADRENALS:
The right and left adrenal glands are symmetric, with bright yellow cortices and red-brown medullae. No masses or areas of hemorrhage are identified.

GENITOURINARY SYSTEM:
The right and left kidneys weigh 120 and 130 gm, respectively. The external surfaces are intact and smooth. The cut surfaces are red-tan. The pelves are unremarkable and the ureters are normal in course and caliber. White bladder mucosa overlies an intact bladder wall. The bladder contains 20 milliliters of yellow urine. The prostate gland and testes are unremarkable.

GASTROINTESTINAL TRACT:
The esophagus is intact and lined by smooth, grey-white mucosa. The stomach contains 150 milliliters of partially digested food particles. The stomach, colon, and appendix are unremarkable.

MUSCULOSKELETAL:
Muscle development is normal. No bone or joint abnormalities are identified.

ACLU Detainee DeathII ARMY MEDCOM 929

MICROSCOPIC EXAMINATION

Lung, right lower lobe – focal intra-alveolus edema and vascular congestion

ADDITIONAL PROCEDURES

1. Documentary photographs are taken by OAFME staff photographers.
2. Full body radiographs are obtained and demonstrate the injuries as described.
3. Specimens retained for toxicology testing and/or DNA identification are: Blood, vitreous fluid, bile, urine, liver, lung, kidney, spleen, brain, psoas muscle, adipose tissue and gastric contents.
4. The dissected organs are forwarded with the body.
5. Selected portions of organs are retained in formalin.
6. Personal effects are released to the appropriate mortuary operations representatives.
7. Recovered evidence: As described above, released to CID.
8. Superficial incisions of the posterior surface of the body and extremities (See Evidence of Injury)

OPINON

This 34 year-old male (b)(6) died of asphyxia due to strangulation. The toxicology screen was negative. The manner of death is homicide.

(b)(6)

(b)(6) Medical Examiner

(b)(6)

(b)(6) Medical Examiner

ACLU Detainee DeathII ARMY MEDCOM 930

CERTIFICATE OF DEATH (OVERSEAS)
Acte de décès (D'Outre-Mer)

NAME OF DECEASED (Last, First, Middle) Nom du décédé (Nom et prénoms): Muhammad, Khayri, Naim	GRADE Grade	BRANCH OF SERVICE Arme: Civilian	SOCIAL SECURITY NUMBER Numéro de l'assurance Sociale: (b)(6)
ORGANIZATION Organisation	NATION (e.g. United States) Pays: Iraq	DATE OF BIRTH Date de naissance: (b)(6) 1972	SEX Sexe: [X] MALE [ ] FEMALE

RACE Race		MARITAL STATUS État Civil			RELIGION Culte		
[X]	CAUCASOID Caucasique	[ ]	SINGLE Célibataire	[ ]	DIVORCED Divorcé	[ ]	PROTESTANT Protestant
[ ]	NEGROID Negroïde	[ ]	MARRIED Marié	[ ]	SEPARATED Séparé	[ ]	CATHOLIC Catholique
[ ]	OTHER (Specify) Autre (Spécifier)	[ ]	WIDOWED Veuf			[ ]	JEWISH Juif
						[X]	OTHER (Specify) Autre (Spécifier)

NAME OF NEXT OF KIN Nom du plus proche parent:

RELATIONSHIP TO DECEASED Parenté du défunt avec le sus

STREET ADDRESS Domicile à (Rue):

CITY OR TOWN OR STATE (Include ZIP Code) Ville (Code postal compris):

MEDICAL STATEMENT Déclaration médicale

CAUSE OF DEATH (Enter only one cause per line) Cause du décès (Inscrire qu'une cause par ligne)		INTERVAL BETWEEN ONSET AND DEATH Intervalle entre l'attaque et le décès
DISEASE OR CONDITION DIRECTLY LEADING TO DEATH Maladie ou condition directement responsable de la mort	Asphyxia due to strangulation	
ANTECEDENT CAUSES — MORBID CONDITION, IF ANY, LEADING TO PRIMARY CAUSE. Condition morbide, s'il y a lieu, menant à la cause primaire		
Symptômes précurseurs de la mort. — UNDERLYING CAUSE, IF ANY, GIVING RISE TO PRIMARY CAUSE. Condition morbide, s'il y a lieu, donnant à la cause primaire		
OTHER SIGNIFICANT CONDITIONS Autres conditions significatives		

MODE OF DEATH Condition de décès	AUTOPSY PERFORMED Autopsie effectuée	CIRCUMSTANCES SURROUNDING DEATH DUE TO EXTERNAL CAUSES Circonstances de la mort survenue par des causes extérieures
[ ] NATURAL Mort naturelle	[X] YES Oui [ ] NO Non	
[ ] ACCIDENT Mort accidentelle	PHYSICAL FINDINGS OF AUTOPSY Constatations principales de l'autopsie	
[ ] SUICIDE Suicide	NAME OF PATHOLOGIST Nom du pathologiste: (b)(6)	
[X] HOMICIDE Homicide	SIGNATURE Signature: (b)(6) DATE Date: 6 March 2007	AVIATION ACCIDENT Accident d'Avion [ ] YES Oui [X] NO Non

DATE OF DEATH (day, month, year) Date du décès (le jour, le mois, l'année): (b)(6) 2007

PLACE OF DEATH Lieu de décès:

I HAVE VIEWED THE REMAINS OF THE DECEASED AND DEATH OCCURRED AT THE TIME INDICATED AND FROM THE CAUSES AS STATED ABOVE.
J'ai examiné les restes mortels du défunt je constate que le décès est survenu à l'heure indiquée et à la suite des causes énumérées ci-dessus.

NAME OF MEDICAL OFFICER Nom du médecin militaire ou du médecin assermenté: (b)(6)

TITLE OR DEGREE Titre ou diplôme:

GRADE Grade: (b)(6)

INSTALLATION OR ADDRESS Institution ou adresse: Dover AFB, Dover DE

DATE Date: 3/6/2007

(b)(6)

1 State disease, injury or complication which caused death, but not mode of dying, such as heart failure, etc.
2 State conditions contributing to the death, but not related to the disease or condition causing death.
3 Patient in active labor, dying from hemorrhage, etc. Is autopsy performed? Were findings considered in determining cause of death? State why an autopsy was or was not performed, etc.

DD FORM 2064 REPLACES DA FORM 3083, 1 JAN 72 AND DA FORM 3083-R (AE), 30 SEP 77, WHICH ARE OBSOLETE.

ACLU Detainee DeathII ARMY MEDCOM 931

(REMOVE, REVERSE AND RE-INSERT CARBONS BEFORE COMPLETING THIS SIDE)

DISPOSITION OF REMAINS			
NAME OF MORTICIAN PREPARING REMAINS	DATE	LICENSE NUMBER AND STATE	OTHER
INSTALLATION OR ADDRESS	DATE	SIGNATURE	
NAME OF CEMETERY OR CREMATORY	LOCATION OF CEMETERY OR CREMATORY		
TYPE OF DISPOSITION	DATE OF DISPOSITION		

REGISTRATION OF VITAL STATISTICS			
REGISTRY (Town and County)	DATE REGISTERED	FILE NUMBER	
		STATE	OTHER
NAME OF FUNERAL DIRECTOR	ADDRESS		
SIGNATURE OF AUTHORIZED INDIVIDUAL			

DD FORM 2064, APR 1977 (BACK) USAPA V1.00

ACLU Detainee DeathII ARMY MEDCOM 932

ARMED FORCES INSTITUTE OF PATHOLOGY
Office of the Armed Forces Medical Examiner
1413 Research Blvd., Bldg. 102
Rockville, MD 20850
301-319-0000

FINAL AUTOPSY REPORT

Name: BTB Abdal. Ahmad Khalaf
SSAN: (b)(6)
Date of Birth: BTI(b)(6) 1947
Date of Death: (b)(6) 2007
Date/Time of Autopsy: 09 JAN 2007 @ 0900
Date of Report: 06 APR 2007

Autopsy No.: (b)(6)
AFIP No.: (b)(6)
Rank: Civilian
Place of Death: Iraq
Place of Autopsy: Port Mortuary, Dover AFB, Dover, DE

Circumstances of Death: This 59 year-old civilian was detained at Camp Ripper, Al Asad, Iraq when, as reported, he died during an interrogation with a human exploitation team member. Per report, he appeared to have fainted thirty minutes into the interrogation and became unresponsive.

Authorization for Autopsy: Office of the Armed Forces Medical Examiner, IAW 10 USC 1471.

Identification: Presumptive identification by examination of papers in case file. Post-mortem fingerprints and specimen suitable for DNA analysis are obtained.

CAUSE OF DEATH: **Atherosclerotic cardiovascular disease**
Mitral valve prolapse with annular calcification

MANNER OF DEATH: **Undetermined**

ACLU Detainee DeathII ARMY MEDCOM 933

FINAL AUTOPSY DIAGNOSES

I. Pathologic diagnoses:

A. Cardiovascular system:

1. Focal healed subendocardial infarct, lateral and posterior left ventricle
2. Left ventricular hypertrophy with subendocardial and perivascular interstitial fibrosis
3. Mitral valve prolapse with annular calcification
4. Focal moderate coronary atherosclerosis
5. Cardiomegaly, 530 grams
6. Mild atherosclerotic disease of the aorta and arteries of the base of the brain

B. Respiratory system:

1. Congested lungs:
   i. Right lung, 740 grams
   ii. Left lung, 500 grams
2. No evidence of pulmonary thromboembolism

II. No evidence of significant recent injury

III. Minor injuries:

A. Abrasion of the posterior left forearm, 1/8 inch
B. Abrasion of the posterior left hand, 1/8 inch
C. Healing abrasion of the forehead, 1/8 inch

IV. Evidence of medical intervention:

A. Intravenous catheters in the right and left antecubital fossae
B. Defibrillator pad mark/abrasion, left side of the chest, 2 x ½ inch

V. Post-mortem changes:

A. Lividity is fixed on the posterior surface of the body except in areas exposed to pressure
B. Rigor is passed in all extremities
C. Cloudy corneae

VI. Toxicology (AFIP):

A. VOLATILES: No ethanol detected in the blood and vitreous fluid
B. DRUGS: No screened drugs of abuse/medications detected in the urine
C. CARBON MONOXIDE: Carboxyhemoglobin saturation in the blood was less than 1%*
D. CYANIDE: No cyanide detected in the blood

* Carboxyhemoglobin saturations of 0-3% are expected for non-smokers and 3-10% for smokers.

ACLU Detainee DeathII ARMY MEDCOM 934

EXTERNAL EXAMINATION

The body is that of a well-developed, well-nourished white male. The body is 66 inches in length, weighs 175 pounds, and appears compatible with the stated age of 59 years old. The body is cold. Lividity is fixed on the posterior surface of the body except in the areas exposed to pressure. The head and neck are suffused. Rigor has passed in both the upper and lower extremities.

The head is normocephalic. The scalp hair is grey/black with male pattern baldness. Facial hair consists of a grey moustache and beard. The irides are indistinct. The corneae are cloudy. The conjunctivae are congested. The sclerae are white. The external auditory canals, nasal cavity, and oral cavity are free of foreign material and abnormal secretions. The earlobes are not pierced. The nasal skeleton is palpably intact. The lips are without evident injury. The teeth are natural and in poor condition. The upper two incisors are absent with a denture in place. There are no petechiae of the oral mucosa. There is a 1/4 x 1/8 skin tag of the right eyelid. The neck is straight, and the trachea is midline and mobile with no evidence of injury. There are multiple skin tags of the neck ranging from 1/8 inch to 1/4 inch in greatest dimension.

The chest is symmetric. There are multiple 1/8 inch skin tags in both axillae. The abdomen is flat. The genitalia are those of a normal adult male with no evidence of injury. There are two, 1 inch, round scars on the back. (b)(6) tattoo (b)(6) There is a 2 x 1 x 1 inch skin tag of the natal fold. The anus is unremarkable.

The upper and lower extremities are symmetric and without clubbing or edema. (b)(6) tattoos (b)(6) (b)(6) tattoo (b)(6) (b)(6) tattoo (b)(6) (b)(6) tattoo (b)(6) (b)(6) tattoo (b)(6) tattoos (b)(6) (b)(6) tattoos (b)(6) (b)(6) (b)(6) tattoo (b)(6) There is a 1 inch circular scar of the anterior right thigh. There are two circular scars of the lateral right leg, 1 inch and 1/2 inch, respectively. There is a 1/4 x 1/8 inch skin tag of the posterior right leg. (b)(6) tattoo (b)(6) There are two circular scars of the lateral left leg, 3/4 inch and 1-1/2 inch, respectively. The palms of the hands and soles of the feet are callous.

CLOTHING AND PERSONAL EFFECTS

The body is in an orange shirt (cut), white t-shirt (cut), orange pants, and white boxers. Brown paper evidence bags are secured with evidence tape over both hands.

MEDICAL INTERVENTION

Intravenous catheters are in the right and left antecubital fossae. There is a 2 x 1/2 inch abrasion of the left side of the chest consistent with defibrillator pad placement.

RADIOGRAPHS

A complete set of postmortem radiographs is obtained and do not demonstrate evidence of injury.

ACLU Detainee DeathII ARMY MEDCOM 935

EVIDENCE OF INJURY

There is a 1/8 inch healing abrasion of the forehead. There is a 1/8 inch abrasion of the posterior left forearm. There is a 1/8 inch abrasion of the posterior left hand.

INTERNAL EXAMINATION

HEAD: (CENTRAL NERVOUS SYSTEM)
The scalp is reflected. The calvarium of the skull is removed. The dura mater and falx cerebri are intact. There is no epidural or subdural hemorrhage present. The leptomeninges are thin and delicate. The cerebral hemispheres are symmetrical. The structures at the base of the brain, including cranial nerves and blood vessels are intact. There is mild, non-occlusive atherosclerotic disease of the arteries. Coronal sections through the cerebral hemispheres and transverse sections through the brainstem and cerebellum are unremarkable. The brain weighs 1440 grams.

NECK:
The anterior and posterior strap muscles of the neck are homogenous and red-brown, without hemorrhage (separate anterior and posterior neck dissections). The thyroid cartilage and hyoid are intact. The larynx is lined by intact white mucosa. The thyroid is symmetric and red-brown, without cystic or nodular change.

BODY CAVITIES:
The ribs, sternum, and vertebral bodies are visibly and palpably intact. There is 20 milliliters of serosanguinous fluid in each of the thoracic cavities. No excess fluid is in the pericardial or peritoneal cavities. The organs occupy their usual anatomic positions.

RESPIRATORY SYSTEM:
The upper airway is clear of debris and foreign material; the mucosal surfaces are smooth, yellow-tan and unremarkable. The right and left lungs weigh 740 and 500 grams, respectively (expected 360-570 grams and 325-480 grams). The external surfaces are smooth, glistening and unremarkable. The pulmonary parenchyma is red-purple exuding slight to moderate amounts of blood. No mass lesions or areas of consolidation are present. The pulmonary arteries are normally developed and patent without thrombus or embolus.

CARDIOVASCULAR SYSTEM:
The 530 gram (expected 265-460 grams) heart is contained in an intact pericardial sac. The heart was retained and sent for cardiovascular pathology consultation (see addendum). The aorta has mild atherosclerotic disease.

LIVER & BILIARY SYSTEM:
The 1800 gram liver has an intact, smooth capsule and a sharp anterior border. The parenchyma is moderately congested and tan-brown with the usual lobular architecture. No mass lesions or other abnormalities are seen. The gallbladder contains 20 milliliters of green bile. The extrahepatic biliary tree is patent.

ACLU Detainee DeathII ARMY MEDCOM 936

SPLEEN:
The 250 gram spleen has a smooth, intact, red-purple capsule. The parenchyma is maroon with unremarkable lymphoid follicles.

PANCREAS:
The pancreas is firm and yellow-tan, with the usual lobular architecture, and has autolytic changes. No mass lesions or other abnormalities are seen.

ADRENALS:
The right and left adrenal glands are symmetric, with bright yellow cortices and red-brown medullae. No masses or areas of hemorrhage are identified.

GENITOURINARY SYSTEM:
The right and left kidneys weigh 210 and 220 gm, respectively. The external surfaces are intact and smooth. The cut surfaces are red-tan. The pelves are unremarkable and the ureters are normal in course and caliber. White bladder mucosa overlies an intact bladder wall. The bladder contains 120 milliliters of clear yellow urine. The prostate gland and testes are unremarkable.

GASTROINTESTINAL TRACT:
The esophagus is intact and lined by smooth, grey-white mucosa. The stomach contains less than 5 milliliters of brown mucous. The stomach, duodenum, loops of small bowel, and colon have diffuse mucosa hemorrhage/decomposition change. The appendix is unremarkable.

MUSCULOSKELETAL:
Muscle development is normal. No bone or joint abnormalities are identified.

ADDITIONAL PROCEDURES

1. Documentary photographs are taken by OAFME staff photographers.
2. Specimens retained for toxicology testing and/or DNA identification are: Blood, vitreous fluid, bile, liver, lung, kidney, spleen, brain, muscle, urine, adipose tissue and gastric contents.
3. The dissected organs are forwarded with the body. The heart is retained for consultation.
4. Selected portions of organs are retained in formalin.
5. Personal effects are released to the appropriate mortuary operations representatives.
6. Posterior incisions of the skin and subcutaneous soft tissue demonstrate no evidence of injury.

ACLU Detainee DeathII ARMY MEDCOM 937

OPINION

This 59 year-old male, **BTB** (b)(6) died of atherosclerotic cardiovascular disease and mitral valve prolapse with annular calcification. Histologic sections of the heart demonstrated a healed myocardial infarction (heart attack). There was no evidence of significant injury. The toxicology screen was negative. At the time of his death, per report, he was being interrogated by a human exploitation team member. The contribution of being interrogated as a precipitating event leading to his death is uncertain. Thus, the manner of death is undetermined.†

(b)(6)

(b)(6) Medical Examiner

(b)(6)

(b)(6) Medical Examiner

† If further information is obtained that requires changing the cause (and manner) of death, an amendment to this report will be made.

ACLU Detainee DeathII ARMY MEDCOM 938

ADDENDUM

Cardiovascular Pathology Consultation:

DIAGNOSIS: (b)(6)

1. Focal moderate coronary atherosclerosis
2. Left ventricular hypertrophy with subendocardial and perivascular interstitial fibrosis, and focal healed subendocardial infarct, lateral and posterior left ventricle
3. Mitral valve prolapse with annular calcification

Heart: 515 grams (post-fixation); normal epicardial fat, probe patent foramen ovale; left ventricular hypertrophy: left ventricular cavity diameter 30 mm, left ventricular free wall thickness 14 mm, ventricular septum thickness 16mm; right ventricle thickness 5mm; mitral valve prolapse: thickened and redundant valve leaflets with hooding and annular calcification of posterior leaflet; other valves unremarkable; mild endocardial thickening in left ventricular outflow tract; no gross myocardial fibrosis or necrosis; histologic sections show left ventricular myocyte hypertrophy and subendocardial and perivascular interstitial fibrosis, and focal subendocardial replacement fibrosis in lateral and posterior left walls (healed infarct)

Coronary arteries: Normal ostia; right dominance; focal moderate atherosclerosis: 35% luminal narrowing of proximal left anterior descending artery by pathologic intimal thickening with intimal foam cell infiltrates; 60% narrowing of proximal left circumflex artery by fibroatheromatous and fibrocalcific plaque with adventitial fibrosis and chronic inflammation; 30% narrowing of proximal right coronary artery by pathologic intimal thickening with intimal foam cell infiltrates

ACLU Detainee DeathII ARMY MEDCOM 939

CERTIFICATE OF DEATH *(OVERSEAS)*
Acte dé décès (D'Outre-Mer)

NAME OF DECEASED *(Last, First, Middle)* Nom du décédé (Nom et prénoms)	GRADE Grade	BRANCH OF SERVICE Arme	SOCIAL SECURITY NUMBER Numéro de l'Assurance Social
BTB Abdal, Ahmed, Khalaf		Civilian	(b)(6)

ORGANIZATION Organisation	NATION *(e.g. United States)* Pays	DATE OF BIRTH Date de naissance	SEX Sexe
	Iraq		[X] MALE [ ] FEMALE

RACE Race		MARITAL STATUS État Civil			RELIGION Culte		
[X]	CAUCASOID Caucasique	[ ]	SINGLE Célibataire	[ ] DIVORCED Divorcé	[ ]	PROTESTANT Protestant	[ ] OTHER (Specify) Autre (Spécifier)
[ ]	NEGROID Negroide	[ ]	MARRIED Marié	[ ] SEPARATED Séparé	[ ]	CATHOLIC Catholique	[X]
[ ]	OTHER (Specify) Autre (Spécifier)	[ ]	WIDOWED Veuf		[ ]	JEWISH Juif	

NAME OF NEXT OF KIN Nom du plus proche parent	RELATIONSHIP TO DECEASED Parenté du décédé avec le sus
STREET ADDRESS Domicilé á (Rue)	CITY OR TOWN OR STATE *(Include ZIP Code)* Ville (Code postal compris)

MEDICAL STATEMENT Déclaration médicale

CAUSE OF DEATH (Enter only one cause per line) Cause du décès (N'indiquer qu'une cause par ligne)		INTERVAL BETWEEN ONSET AND DEATH Intervalle entre l'attaque et le décès
DISEASE OR CONDITON DIRECTLY LEADING TO DEATH [1] Maladie ou condition directement responsable de la mort [1]	Atherosclerotic cardiovascular disease Mitral valve prolapse with annular calcification	
ANTECEDENT CAUSES Symptômes précurseurs de la mort. MORBID CONDITION, IF ANY, LEADING TO PRIMARY CAUSE Condition morbide, s'il y a lieu, menant à la cause primaire		
UNDERLYING CAUSE, IF ANY, GIVING RISE TO PRIMARY CAUSE Condition morbide, s'il y a lieu, menant à la cause primaire		
OTHER SIGNIFICANT CONDITIONS [2] Autres conditions significatives [2]		

MODE OF DEATH Condition de décès	AUTOPSY PERFORMED Autopsie effectuée [X] YES Oui [ ] NO Non MAJOR FINDINGS OF AUTOPSY Conclusions principales de l'autopsie	CIRCUMSTANCES SURROUNDING DEATH DUE TO EXTERNAL CAUSES Circonstances de la mort suscitées par des causes extérieures
[X] NATURAL Mort naturelle		
[ ] ACCIDENT Mort accidentelle		
[ ] SUICIDE Suicide	NAME OF PATHOLOGIST Nom du pathologiste (b)(6)	
[ ] HOMICIDE Homicide	SIGNATURE Signature (b)(6) DATE Date 9 January 2007	AVIATION ACCIDENT Accident á Avion [ ] YES Oui [X] NO Non

DATE OF DEATH *(day, month, year)* Date de décès (le jour, le mois, l'année)	PLACE OF DEATH Lieu de décès
(b)(6) 2007	Iraq

I HAVE VIEWED THE REMAINS OF THE DECEASED AND DEATH OCCURRED AT THE TIME INDICATED AND FROM THE CAUSES AS STATED ABOVE.
J'ai examiné les restes mortels du dé funtet je conclus que le décès est survenu à l'heure indiquée et à, la suite des causes énumérées ci-dessus.

NAME OF MEDICAL OFFICER Nom du médicin militaire ou du médicin assistant	TITLE OR DEGREE Titre ou diplômé
(b)(6)	Medical Examiner

GRADE Grade	INSTALLATION OR ADDRESS Installation ou adresse
(b)(6)	Dover AFB, Dover DE
DATE Date 9/5/2007	SIGNATURE Signature (b)(6)

[1] State disease, injury or complication which caused death, but not mode of dying such as heart failure, etc.
[2] State conditions contributing to the death, but not related to the disease or condition causing death.
[1] Préciser la nature de la maladie, de la blessure ou de la complication qui a contribué à la mort, mais non la manière de mourir, telle qu 'un arrêt du coeur, etc
[2] Préciser la condition qui a contribué à la mort, mais n'ayant aucun rapport avec la maladie ou à la condition qui a provoqué la mort.

DD FORM 1 APR 77 2064 REPLACES DA FORM 3565, 1 JAN 72 AND DA FORM 3565-R(PAS), 26 SEP 75, WHICH ARE OBSOLETE.

MEDCOM 0940

ACLU Detainee DeathII ARMY MEDCOM 940

(REMOVE, REVERSE AND RE-INSERT CARBONS BEFORE COMPLETING THIS SIDE)

DISPOSITON OF REMAINS

NAME OF MORTICIAN PREPARING REMAINS	GRADE	LICENSE NUMBER AND STATE	OTHER

INSTALLATION OR ADDRESS	DATE	SIGNATURE
(b)(6)		

NAME OF CEMETERY OR CREMATORY	LOCATION OF CEMETERY OR CREMATORY

TYPE OF DISPOSTION	DATE OF DISPOSTION

REGISTRATION OF VITAL STATISTICS

REGISTRY *(Town and Country)*	DATE REGISTERED	FILE NUMBER	
		STATE	OTHER

NAME OF FUNERAL DIRECTOR	ADDRESS

SIGNATURE OF AUTHORIZED INDIVIDUAL

DD FORM 2064, APR 1977 (BACK) *USAPA V1.00*

ACLU Detainee DeathII ARMY MEDCOM 941

ARMED FORCES INSTITUTE OF PATHOLOGY
Office of the Armed Forces Medical Examiner
1413 Research Blvd., Bldg. 102
Rockville, MD 20850
301-319-0000

AUTOPSY EXAMINATION REPORT

Name: Ibrahim, Sadir Ahmed
ISN: (b)(6)
Date of Birth: unknown
Date of Death: (b)(6) 2008
Date/Time of Autopsy: 20 FEB 2008 @ 0900
Date of Report: 17 MAR 2008

Autopsy No.: (b)(6)
AFIP No.: (b)(6)
Rank: Detainee
Place of Death: Iraq
Place of Autopsy: Port Mortuary, Dover Air Force Base, Dover, DE

Circumstances of Death: This Iraqi male was beaten by other Iraqi Nationals when they discovered him attempting to plant an Improvised Explosive Device (IED). American forces subsequently took custody of him and brought him for medical treatment. Initially, he was treated for ventricular fibrillation and hypothermia. Upon stabilization he had several complications including a decreased mental status (Glasgow Coma Scale 3), renal failure, generalized seizures, and anasarca. These conditions were considered irreversible and the decision was made to treat for comfort. Seven days after admission he developed arrhythmias, which progressed to asystole.

Authorization for Autopsy: Armed Forces Medical Examiner, per 10 U.S. Code 1471

Identification: Accompanying documents establish presumptive identification; samples from fingerprint, dental, and DNA examinations obtained for positive identification.

CAUSE OF DEATH: **Complications of Blunt Force Injuries**

MANNER OF DEATH: **Homicide**

ACLU Detainee DeathII ARMY MEDCOM 942

EXTERNAL EXAMINATION

The body is that of a well-developed, well-nourished Caucasoid male. The body weighs 170 pounds and measures 65 inches in length. Lividity is fixed on the posterior surfaces of the body. Rigor is passing. The body temperature is cold to touch. Decomposition changes consist of skin slippage on the lower extremities and back.

Injuries of the head are described below. The head is normocephalic. The scalp is covered with straight black hair of medium length in a normal distribution; facial hair consists of a beard and moustache. The right iris is brown, the cornea is clear, the conjunctiva is erythematous, and the sclera is yellow; the left iris is gray and scarred and the left globe is shrunken. A firm, movable nodule is palpable on the lateral aspect of the left orbit. The external auditory canals are clear. The nares contain mucus. The nose and maxillae are palpably stable. The teeth are natural and in good condition. The neck is straight, and the trachea is midline and mobile.

Injuries of the torso are described below. The chest is symmetric. The abdomen is mildly protuberant. The genitalia are those of a normal adult circumcised male. There is moderate scrotal edema. The testes are descended. Pubic hair is present in a normal distribution. The back is symmetric.

The upper and lower extremities are symmetric with mild to moderate edema of the distal portions. The fingernails are intact, except for a chip of the nail of the left ring finger. Identifying marks consist of an irregular scar (3/4" in diameter) of the dorsum of the right hand.

CLOTHING AND PERSONAL EFFECTS

No clothing items or personal effects are present on the body at the time of autopsy.

MEDICAL INTERVENTION

Medical intervention present on the body at the time of autopsy includes:

- Two fasciotomy incisions (7-3/4" and 8-3/4") on the anterior and lateral surfaces of the right leg
- Blue pad wrapped around fasciotomy incisions
- Large bore intravascular catheter, left subclavian
- Needle puncture marks, bilateral ante-cubital fossae
- Intravascular catheter, left wrist
- Three incisions (3/4" to 1" long), lateral left chest

ACLU Detainee DeathII ARMY MEDCOM 943

RADIOGRAPHS

A complete set of postmortem radiographs is obtained and demonstrates the following:

- Cone-shaped metal fragment on lateral aspect of the left orbit
- Fracture, left transverse process of the third lumbar vertebra
- Fracture, lateral aspect of the right sixth rib

EVIDENCE OF INJURY

The ordering of the following injuries is for descriptive purposes only, and is not intended to imply order of infliction or relative severity. All wound pathways are given relative to standard anatomic position.

I. Blunt force injuries

A. Head and neck

A cluster of healing abrasions, 1/8" to 1/4" in greatest dimension, covers an area of 1-1/4" x 1" on the left forehead. A 1/8" healing abrasion is on the upper lip. A 1/2" x 1/8" healing abrasion is on the left ear. A 0.5 cm contusion is on the right lateral aspect of the tongue. A 7 cm x 5 cm subgaleal hemorrhage is on the right frontal aspect of the skull. There is mild, but diffuse, subarachnoid hemorrhage.

B. Torso

Two healing contusions, 1-1/4" and 2" in greatest dimension, are on the left side of the chest. A 12" x 10" contusion extends over the left lateral torso from the lower chest to the proximal left thigh. A 2-1/2" x 2" contusion is on the right side of the back, just below the scapula. Three healing abrasions, 1/2" to 1" in greatest dimension, are on the middle of the back. A 25" x 13" contusion with hemorrhage into the underlying soft tissues involves the lower back and buttocks extending from the left scapula, around the lateral aspects of the buttocks, and down to the proximal posterior thighs. A 1/2" x 1/8" healing abrasion is on the scrotum.

The lateral aspects of right ribs five and six are fractured. The left transverse process of the third lumbar vertebra is fractured. Both testes have intraparenchymal hemorrhage.

C. Extremities

Three contusions, 1/2" to 3" in greatest dimension are on the anterior right arm. A 1/2" x 1/4" contusion is on the posterior right shoulder. A 1" x 1/4" healing abrasion is on the posterior right arm. A 1" x 1" contusion is on the posterior right forearm. A 2" x 1/8" healing contusion with focal hemorrhage into the underlying soft tissues is on the posterior right wrist.

A 1" x 1/8" healing contusion is on the anterior left shoulder. A cluster of contusions, 1/4" to 1" in greatest dimension, covers an area of 3" x 1-1/2" on the anterior left arm. A 6-1/2" x 3" contusion is on the anterior left upper extremity extending from the distal arm to the mid forearm. A 1" x 1/8" healing contusion with focal hemorrhage into the underlying soft tissues is on the posterior left wrist.

ACLU Detainee DeathII ARMY MEDCOM 944

On the antero-lateral aspect of the right thigh is an 11-1/2" x 11-1/2" contusion. A 6-1/2" x 2-1/2" healing abrasion is on the anterior right leg. Two healing abrasions, 1/4" and 1/2" in greatest dimension, are on the dorsum of the right foot. A 3" x 1" contusion with hemorrhage into the underlying soft tissues is on the right popliteal fossa. A cluster of healing abrasions and contusions with hemorrhage into the underlying soft tissues, 1/2" to 2" in greatest dimension, covers an area of 5" x 5" on the posterior right leg.

Two contusions, 2" and 3" in greatest dimension, are on the anterior left thigh. A cluster of healing abrasions, 1/8" to 3/4" in greatest dimension, covers an area of 16" x 4" on the anterior left lower extremity from the knee to the dorsum of the foot. A 4" x 2-1/2" contusion with hemorrhage into the underlying soft tissues is on the left popliteal fossa. A cluster of healing abrasions and contusions with hemorrhage into the underlying soft tissues, 1/4" to 2" in greatest dimension, covers an area of 3" x 3" on the posterior left leg. Two contusions, 1/2" and 1-1/2" in greatest dimension, are on the postero-lateral left leg.

INTERNAL EXAMINATION

HEAD AND CENTRAL NERVOUS SYSTEM:

(See Evidence of Injury)

There are no skull fractures. The dura mater is intact with no evidence of hemorrhage. The leptomeninges are thin and delicate. The brain weighs 1270 gm and has unremarkable gyri and sulci. The cerebral hemispheres are symmetrical and the structures at the base of the brain, including the cranial nerves are intact. The cerebral arteries are patent. Coronal sections demonstrate sharp demarcation between white and gray matter, without hemorrhage or contusive injury. The ventricles are not enlarged. The basal ganglia, brainstem, and cerebellum are free of injury or other abnormalities. The atlanto-occipital joint is stable. A cone-shaped metal fragment recovered from the soft tissues of the left orbit.

NECK:

(See Evidence of Injury)

Layer-by-layer dissection of the anterior strap muscles of the neck reveals homogenous and red-brown soft tissue, without hemorrhage. The thyroid cartilage and hyoid are intact. The larynx is lined by intact white mucosa. The thyroid gland is symmetric and red-brown, without cystic or nodular change. The parathyroid glands are not identified. The major vessels of the neck are intact.

ACLU Detainee DeathII ARMY MEDCOM 945

BODY CAVITIES:
Excess sero-sanguineous fluid is present within each body cavity: 350 ml in the right pleural, 50 ml in the left pleural, 10 ml in the pericardial, and 50 ml in the peritoneal cavities. The organs occupy their usual anatomic positions. The subcutaneous fat layer of the abdominal wall is 3.5 cm thick.

MUSCULOSKELETAL:

(See Evidence of Injury)

No non-traumatic abnormalities of the muscles or bones of the appendicular and axial skeletons are identified.

RESPIRATORY SYSTEM:
The airways are clear of debris and foreign material and the mucosal surfaces are smooth, yellow-tan, and unremarkable. The right and left lungs weigh 960 and 820 gm, respectively. The external surfaces are smooth and deep red-purple. The pulmonary parenchyma is diffusely congested and edematous. No mass lesions or areas of consolidation are present. The pulmonary arteries are normally developed and patent. The diaphragm is intact.

CARDIOVASCULAR SYSTEM:
The 450 gm heart is contained in an intact pericardial sac. The epicardial surface is smooth, with minimal fat investment. The coronary arteries are unremarkable in distribution, with a right-dominant pattern. Cross sections of the vessels show no luminal narrowing. The myocardium is homogenous, red-brown, and firm; the atrial and ventricular septae are intact. The valve leaflets are thin and mobile. The walls of the left ventricle, interventricular septum, and right ventricle are 1.4, 1.4, and 0.4-cm thick, respectively. The endocardium is smooth and glistening. The aorta gives rise to three intact and patent arch vessels; there are multi-focal thin yellow linear plaques (fatty streaking) of the descending aorta. The renal, mesenteric, and iliac vessels as well as the venae cavae are unremarkable.

HEPATOBILIARY SYSTEM:
The 1820 gm liver has an intact, smooth capsule and a sharp anterior border. The parenchyma is tan-brown and congested, with unremarkable lobular architecture. No mass lesions or other non-traumatic abnormalities are seen. The gallbladder contains a minute amount of green-black bile and no stones. The mucosal surface is green and velvety.

LYMPHORETICULAR SYSTEM:
The 250 gm spleen has a smooth, intact, red-purple capsule. The parenchyma is maroon and congested, with distinct Malpighian corpuscles. Lymph nodes in the hilar, periaortic, and iliac regions are unremarkable.

ACLU Detainee DeathII ARMY MEDCOM 946

ENDOCRINE SYSTEM:
The pituitary gland is unremarkable within the sella turcica. The thyroid gland has been described (see NECK, above). The right and left adrenal glands are symmetric, with bright yellow cortices and red-brown medullae. No masses or areas of hemorrhage are identified.

GENITOURINARY SYSTEM:

(See Evidence of Injury)

The right and left kidneys weigh 210 and 170 gm, respectively. The external surfaces are intact and smooth. The cut surfaces are red-tan and congested, with uniformly thick cortices and sharp corticomedullary junctions. The pelves and ureters are unremarkable. White bladder mucosa overlies an intact bladder wall. The bladder is empty. The prostate has lobular, yellow-tan parenchyma and is not enlarged. The seminal vesicles are unremarkable.

GASTROINTESTINAL TRACT:
The esophagus is intact and lined by smooth, gray-white mucosa. The stomach contains approximately 30 ml of pink viscous fluid. The gastric wall is intact. The duodenum, distal loops of intestine, and colon are unremarkable. The pancreas is firm and yellow-tan, with lobular architecture. Sectioning of the pancreas reveals diffuse, but mild parenchymal hemorrhage. The appendix is present.

ADDITIONAL PROCEDURES

1. Documentary photographs are taken by OAFME staff.
2. Personal effects are released to the appropriate mortuary operations representatives.
3. Specimens retained for toxicology testing and/or DNA identification are vitreous fluid, bile, blood, lung, liver, spleen, kidney, adipose tissue, heart muscle, brain, gastric contents, and psoas muscle.
4. The dissected organs are forwarded with body.
5. Trace evidence and/or foreign material are collected and retained by OAFME.

ACLU Detainee DeathII ARMY MEDCOM 947

MICROSCOPIC EXAMINATION

Selected portions of organs are retained in formalin for preparation of histology slides.

Slide Key: 1- lung, interventricular septum (heart), liver; 2- lung, left free wall (heart), pancreas; 3- lung, right free wall (heart), spleen; 4- lung, left kidney, adrenal gland; 5- lung, adrenal gland, skeletal muscle; 6- right kidney, thyroid gland, tongue; 7- cerebellum; 8- midbrain; 9- brainstem; 10- hippocampus; 11- cerebral cortex

Histology:

Brain: Diffuse neuronal eosinophilia and pyknosis; mild subarachnoid hemorrhage
Tongue: no significant pathologic change
Skeletal muscle: no significant pathologic change
Lungs: multi-focal hyalinized alveolar membranes; diffuse pulmonary edema and congestion with airspace hemorrhage
Heart: no significant pathologic change
Liver: mild to moderate macro- and micro-vesicular steatosis
Spleen: no significant pathologic change
Kidneys: tubular cell necrosis, tubular casts, and mononuclear cell infiltrates
Thyroid gland: no significant pathologic change
Adrenal Glands: no significant pathologic change
Pancreas: mild autolysis, but otherwise no significant pathologic change

ACLU Detainee DeathII ARMY MEDCOM 948

FINAL AUTOPSY DIAGNOSES:

I. Blunt force injuries
- A. Head and neck
  1. Cluster of healing abrasions, left forehead
  2. Healing abrasion, upper lip
  3. Healing abrasion, left ear
  4. Contusion, tongue
  5. Subgaleal hemorrhage, right frontal skull
  6. Diffuse subarachnoid hemorrhage
- B. Torso
  1. Multiple (2) contusions, left chest
  2. Contusion, left lateral torso
  3. Contusion, right back
  4. Multiple (3) healing abrasions, middle back
  5. Contusion, lower back and buttocks
  6. Healing abrasion, scrotum
  7. Multiple (2) right rib fractures
  8. Fracture, left transverse process of third lumbar vertebra
  9. Bilateral intraparenchymal hemorrhage, testes
- C. Extremities
  1. Right upper
     a. Multiple (3) contusions, anterior arm
     b. Contusion, posterior shoulder
     c. Healing abrasion, posterior arm
     d. Contusion, posterior forearm
     e. Healing contusion, posterior wrist
  2. Left upper
     a. Healing contusion, anterior shoulder
     b. Cluster of contusions, anterior arm
     c. Contusions, distal arm to mid forearm
     d. Healing contusion, posterior wrist
  3. Right lower
     a. Contusion, antero-lateral thigh
     b. Healing abrasion, anterior leg
     c. Multiple (2) healing abrasions, foot
     d. Contusion, popliteal fossa
     e. Cluster of abrasions and contusions, posterior leg
  4. Left lower
     a. Multiple (2) contusions, anterior thigh
     b. Cluster of healing abrasions, anterior knee, leg and foot
     c. Contusion, popliteal fossa
     d. Cluster of healing abrasions and contusions, posterior leg
     e. Multiple (2) contusions, postero-lateral leg

ACLU Detainee DeathII ARMY MEDCOM 949

II. Other evidence recovery
- Cone-shaped metallic fragment from left orbit

III. Natural disease and anatomic findings
- A. Cardiomegaly (heart weight 450 gm; expected weight range for a 170 pound person is 305 to 375 gm)
- B. Mild peripheral atherosclerosis
- C. Global ischemic changes of the brain
- D. Diffuse alveolar damage
- E. Mild intraparenchymal hemorrhage, pancreas
- F. Anasarca

IV. Medical intervention
- A. Two fasciotomy incisions, anterior and lateral right leg
- B. Blue pad wrapped around fasciotomy incisions
- C. Large bore intravascular catheter, left subclavian
- D. Needle puncture marks, bilateral ante-cubital fossae
- E. Intravascular catheter, left wrist
- F. Three incisions, lateral left chest

V. Post-mortem changes
- A. Mild decomposition
- B. Passing rigor
- C. Fixed posterior livor

VI. Identifying marks
- Scar, right hand

VII. Toxicology results
- A. Volatiles (blood and vitreous fluid): no ethanol detected
- B. Screened drugs of abuse and medications (blood):
  1. Positive benzodiazepine: Lorazepam detected in the blood at a concentration of 0.049 mg/L
  2. No other screened drugs of abuse or medications detected
- C. Carbon monoxide: not tested, no suitable specimen
- D. Cyanide (blood): none

ACLU Detainee DeathII ARMY MEDCOM 950

OPINION

This Iraqi male (b)(6) died of complications of blunt force injuries. After sustaining a beating resulting in injuries to the head, torso, and extremities he developed cardiac arrhythmias, respiratory failure, renal failure, and seizures. These clinical changes were likely due to the metabolic insults sustained from the beating, however an asphyxial contribution to his death cannot be excluded. Despite initial resuscitative efforts his condition progressively worsened and he died. Toxicology tests for ethanol, cyanide, and screened drugs of abuse were negative; Lorazepam detected in the blood is consistent with medical-related and comfort-related measures. The manner of death is homicide.

(b)(6)

(b)(6) Medical Examiner

ACLU Detainee DeathII ARMY MEDCOM 951

ARMED FORCES INSTITUTE OF PATHOLOGY
Office of the Armed Forces Medical Examiner
1413 Research Blvd., Bldg. 102
Rockville, MD 20850
301-319-0000

FINAL AUTOPSY EXAMINATION REPORT

Name: Jabar, Walid Tawfiq
SSAN: (b)(6)
Date of Birth: (b)(6) 1983
Date of Death (b)(6) 2008
Date and time of Autopsy: 27 FEB 2008 0900
Date of Report: 01 MAY 2008

Autopsy No.: (b)(6)
AFIP No.: (b)(6)
Rank: CIV
Place of Death: Iraq
Place of Autopsy: Port Mortuary
Dover AFB, Dover DE

Circumstances of Death: 25 year old male civilian detainee reportedly collapsed during interview

Authorization for Autopsy: Office of the Armed Forces Medical Examiner, IAW 10 USC 1471

Identification: Presumptive

CAUSE OF DEATH: Severe metabolic derangement due to acute adrenocortical insufficiency

MANNER OF DEATH: Natural

ACLU Detainee DeathII ARMY MEDCOM 952

EXTERNAL EXAMINATION

The body is that of a well-developed, well-nourished male that weighs 137 pounds, is 68 inches in length and appears compatible with the reported age of 25 years. The body is cold after refrigeration. Rigor is passing in all extremities. Lividity is present and fixed on the posterior surfaces of the body, except in areas exposed to pressure. The head is normocephalic, and the scalp hair is black. Facial hair consists of a black beard and mustache. The irides are dark. The corneae are cloudy. The conjunctivae are unremarkable with no evidence of petechial hemorrhages. The sclerae are white. The external auditory canals, external nares and oral cavity are free of foreign material and abnormal secretions. The nasal skeleton and maxilla are palpably intact. The upper and lower lips are dry and chapped. The teeth are natural and in good condition. Examination of the neck reveals no evidence of injury. The chest is unremarkable. No evidence of injury of the ribs or the sternum is evident externally. The abdomen is flat. The external genitalia are those of a normal adult male. The posterior torso and anus are without note. The extremities show no evidence of injury. The fingernails are intact.

CLOTHING AND PERSONAL EFFECTS

- Pair of black sandals, soiled
- Black long-sleeved shirt with the emblem "Down Nour", soiled.
- Tan and orange striped long-sleeved shirt
- Pair of blue sweat pants
- Pair of tan sweat pants

MEDICAL INTERVENTION

- Endotracheal tube
- Nasogastric tube
- Intravascular catheters in both antecubital fossae, the right wrist and right inguinal region
- Foley catheter with attached collection system

EVIDENCE OF INJURY

There is a ¼ inch contusion present on the right lower lip.

RADIOGRAPHS

A complete set of postmortem radiographs is obtained. There is no evidence of skeletal injury or metallic foreign material.

INTERNAL EXAMINATION

BODY CAVITIES:

The body is opened by the usual thoraco-abdominal incision and the chest plate is removed. The ribs, sternum, and vertebral bodies are visibly and palpably intact. No adhesions are present in any

ACLU Detainee DeathII ARMY MEDCOM 953

of the body cavities. Approximately 100 ml of amber fluid is present in the left thoracic cavity and 50 ml in the right thoracic cavity. All body organs are present in normal anatomical position. The subcutaneous fat layer of the abdominal wall is ⅛ inch thick.

HEAD AND CENTRAL NERVOUS SYSTEM:

The scalp is reflected. The galeal and subgaleal soft tissues of the scalp are free of injury. There are no skull fractures. The calvarium of the skull is removed. The dura mater and falx cerebri are intact. There is no epidural or subdural hemorrhage present. The leptomeninges are thin and delicate. The cerebral hemispheres are symmetrical. The structures at the base of the brain, including cranial nerves and blood vessels are intact. Clear cerebrospinal fluid surrounds the 1440 gram brain, which has unremarkable gyri and sulci. After fixation, coronal sections through the cerebral hemispheres reveal no lesions. Transverse sections through the brain stem and cerebellum are unremarkable. The atlanto-occipital joint is stable. The upper spinal cord is unremarkable.

NECK:

The anterior strap muscles of the neck are homogenous and red-brown, without hemorrhage by layer-wise dissection. The thyroid cartilage and hyoid bone are intact. The larynx is lined by intact white mucosa. The tongue is free of bite marks, hemorrhage, or other injuries.

CARDIOVASCULAR SYSTEM:

The 250 gram heart is contained in an intact pericardial sac. The epicardial surface is smooth, with minimal fat investment. The coronary arteries are present in a normal distribution, with a right-dominant pattern. Cross sections of the vessels show widely patent lumina. The myocardium is homogenous, red-brown, and firm. The valve leaflets are thin and mobile. The endocardium is smooth and glistening. The aorta gives rise to three intact and patent arch vessels. The renal and mesenteric vessels are unremarkable.

RESPIRATORY SYSTEM:

The upper airway is clear of debris and foreign material; the mucosal surfaces are smooth, yellow-tan and unremarkable. The pleural surfaces are smooth, glistening and unremarkable bilaterally. The pulmonary parenchyma is diffusely congested, exuding moderate amounts of blood and frothy fluid; no focal lesions are noted. The pulmonary arteries are normally developed, patent and without thrombus or embolus. The right lung weighs 520 grams; the left 650 grams.

HEPATOBILIARY SYSTEM:

The 1420 gram liver has an intact smooth capsule covering dark red-brown, moderately congested tan-brown parenchyma with no focal lesions noted. The gallbladder contains 8 ml of green-brown, mucoid bile; the mucosa is velvety and unremarkable. The extrahepatic biliary tree is patent, without evidence of calculi.

ACLU Detainee DeathII ARMY MEDCOM 954

GASTROINTESTINAL SYSTEM:

The esophagus is lined by gray-white, smooth mucosa. The gastric mucosa is arranged in the usual rugal folds and the lumen is empty. The small and large bowel are unremarkable. Formed stool is present in the rectal vault. The pancreas has a normal pink-tan lobulated appearance and the ducts are clear. The appendix is present.

GENITOURINARY SYSTEM:

The right and left kidneys each weigh 130 grams. The renal capsules are smooth, semi-transparent and strip with ease from the underlying smooth, red-brown cortical surface. The cortices are sharply delineated from the medullary pyramids, which are red-purple to tan and unremarkable. The calyces, pelves and ureters are unremarkable. White bladder mucosa overlies an intact bladder wall. The bladder is empty. Approximately 20 ml of urine is present in the collection bag. The testes, prostate gland and seminal vesicles are without note.

LYMPHORETICULAR SYSTEM:

The 160 gram spleen has a smooth, intact capsule covering red-purple, moderately firm parenchyma; the lymphoid follicles are unremarkable. Lymph nodes in the hilar, periaortic and iliac regions are unremarkable. Gastric (greater curvature) lymph nodes appear mildly enlarged.

ENDOCRINE SYSTEM:

The thyroid gland is symmetric and red-brown, without cystic or nodular change. The adrenal glands are poorly discernible from the adjacent adipose tissue.

MUSCULOSKELETAL SYSTEM:

No abnormalities of the muscles, bones or joints are identified. Longitudinal incisions of the posterior surfaces of the torso, upper and lower extremities show no evidence of injury.

ADDITIONAL PROCEDURES

1. Documentary photographs are taken by the OAFME photographer.
2. Personal effects are released to the appropriate mortuary operations representatives.
3. Specimens retained for toxicology testing and/or DNA identification are: vitreous fluid, blood, urine, spleen, liver, lung, kidney, bile, adipose tissue and psoas muscle.
4. The brain and heart are retained for further examination. The remaining dissected organs are forwarded with body.

MICROSCOPIC EXAMINATION

1. Heart (slides 1-4): No significant microscopic abnormality
2. Lungs (slides 5, 11-13): Acute bronchoalveolar pneumonia, right lower lobe; bilateral pulmonary alveolar congestion with patchy pulmonary edema

ACLU Detainee DeathII ARMY MEDCOM 955

3. Liver (slide 6): No significant microscopic abnormality
4. Spleen (slide 6): No significant microscopic abnormality
5. Kidneys (slide 7): Tubular autolysis
6. Lymph nodes, peri-gastric (slide 10): Follicular hyperplasia
7. Brain (slides 16,17): No significant microscopic abnormality
8. Tissue from region of adrenal glands (right slides 8,14; left slides 9,15): Scattered fragments of adrenal medullary tissue without evidence of adrenal cortical tissue (9,14,15); portions of lymph nodes and peripheral neural tissue, no adrenal tissue seen (8).

FINAL AUTOPSY DIAGNOSES

I. Adrenocortical atrophy
   A. Metabolic imbalance (per protocol)
      1. Hyponatremia, hyperkalemia, hypoglycemia and metabolic acidosis
      2. ECG finding of prolonged QT interval (per protocol)

II. Acute bronchoalveolar pneumonia (right lower lobe)
   A. Bilateral pulmonary congestion with patchy pulmonary edema
   B. Bilateral pleural effusions (right 50 ml, left 100 ml)

III. Toxicology: Acetone is present in the blood and urine; atropine is present in the urine

OPINION

According to reports, this 25 year old male civilian detainee collapsed while being interviewed. Resuscitative efforts were started at the scene and he was transported to the medical facility where he was found to be hypotensive, hypothermic and have a GCS of 3. Initial laboratory testing showed significant metabolic derangement (hyponatremia, hypokalemia, metabolic acidosis and hypoglycemia). Although the decedent was initially stabilized, his condition continued to worsen until his demise on the following day. Review of the available medical records revealed a history of a "hunger strike" for approximately 7-10 days prior to death and unspecified "kidney" problems for which the decedent was taking daily hydrocortisone.

Autopsy examination showed no evidence of trauma. Microscopic examination showed acute bronchopneumonia of the left lung and bilateral adrenal cortical atrophy. Toxicological examination showed the presence of atropine in the urine and acetone (trace) in the blood and urine.

Acute adrenocortical insufficiency may present as a "crisis" in patients with chronic adrenocortical insufficiency precipitated by any form of stress or from too rapid withdrawal of exogenous steroids in those whose adrenal glands have been suppressed by long term administration.[1] Findings include hyponatremia, hyperkalemia, hypoglycemia, metabolic acidosis and prolongation of the QT interval on EKG.[2] Untreated patients have a poor prognosis.[3]

---

[1] Cotran, R, Kumar, V.,et.al., Robbins Pathologic Basis of Disease, W.B. Saunders Co. 1994, 5th Ed., pg 1157
[2] Kirkland, L., Adrenal Crisis, Dec 18, 2007, http://www.emedicine.com/med/topic65.htm
[3] Klauer, K., Adrenal Insufficiency and Adrenal Crisis, Jan 30, 2007, http://www.emedicine.com/emerg/topic16.htm

ACLU Detainee DeathII ARMY MEDCOM 956

In the current case the etiology of the adrenal atrophy is uncertain. Contributing stressors included pneumonia and elective food deprivation. Postmortem toxicology showed the presence of the therapeutic substance atropine and trace amounts of acetone. Acetone is a by-product of fat metabolism and can be seen as a result of food deprivation.

In summary, this decedent most likely had long standing (chronic) adrenocortical insufficiency which progressed to acute insufficiency ("crisis") in the face of infectious (pneumonia) and food deprivation stressors (b)(6) succumbed to severe metabolic derangement due to acute adrenocortical insufficiency. The manner of death is natural.

This case is reviewed in consultation with the Departments of Endocrine and Renal Pathology. The latter is pending. Upon completion an addendum report will issued if contributory.

(b)(6)

(b)(6) Medical Examiner

ACLU Detainee DeathII ARMY MEDCOM 957

CERTIFICATE OF DEATH *(OVERSEAS)*
Acte dé décès (D'Outre-Mer)

NAME OF DECEASED *(Last, First, Middle)* Nom du décédé (Nom et prénoms)	GRADE Grade	BRANCH OF SERVICE Arme	SOCIAL SECURITY NUMBER Numéro de l'Assurance Social
Jabar, Walid, Tawfiq		Civilian	(b)(6)

ORGANIZATION Organisation	NATION *(e.g. United States)* Pays	DATE OF BIRTH Date de naissance	SEX Sexe
	Iraq	(b)(6) 1983	[X] MALE [ ] FEMALE

RACE Race		MARITAL STATUS État Civil			RELIGION Culte		
[X]	CAUCASOID Caucasique	[ ]	SINGLE Célibataire	[ ] DIVORCED Divorcé	[ ] PROTESTANT Protestant	[X]	OTHER (Specify) Autre (Spécifier) UNK
[ ]	NEGROID Negroide	[ ]	MARRIED Marié	[ ] SEPARATED Séparé	[ ] CATHOLIC Catholique		
[ ]	OTHER (Specify) Autre (Spécifier)	[ ]	WIDOWED Veuf		[ ] JEWISH Juif		

NAME OF NEXT OF KIN Nom du plus proche parent	RELATIONSHIP TO DECEASED Parenté du décède avec le sus
STREET ADDRESS Domicilé à (Rue)	CITY OR TOWN OR STATE (Include ZIP Code) Ville (Code postal compris)

MEDICAL STATEMENT Déclaration médicale

	CAUSE OF DEATH (Enter only one cause per line) Cause du décès (N'indiquer qu'une cause par ligne)	INTERVAL BETWEEN ONSET AND DEATH Intervalle entre l'attaque et le décès
DISEASE OR CONDITON DIRECTLY LEADING TO DEATH [1] Maladie ou condition directement responsable de la mort	Severe metabolic derangement due to acute adrenocortical insufficiency	Hours
ANTECEDENT CAUSES Symptômes précurseurs de la mort — MORBID CONDITION, IF ANY, LEADING TO PRIMARY CAUSE Condition morbide, s'il y a lieu, menant à la cause primaire		
ANTECEDENT CAUSES Symptômes précurseurs de la mort — UNDERLYING CAUSE, IF ANY, GIVING RISE TO PRIMARY CAUSE Condition morbide, s'il y a lieu, menant à la cause primaire		
OTHER SIGNIFICANT CONDITIONS [2] Autres conditions significatives [2]		

MODE OF DEATH Condition de décès	AUTOPSY PERFORMED Autopsie effectuée [X] YES Oui [ ] NO Non	CIRCUMSTANCES SURROUNDING DEATH DUE TO EXTERNAL CAUSES Circonstances de la mort suscitées par des causes extérieures
[X] NATURAL Mort naturelle	MAJOR FINDINGS OF AUTOPSY Conclusions principales de l'autopsie	
[ ] ACCIDENT Mort accidentelle		
[ ] SUICIDE Suicide	NAME OF PATHOLOGIST Nom du pathologiste (b)(6)	
[ ] HOMICIDE Homicide	SIGNATURE (b)(6) — DATE Date 27 February 2008	AVIATION ACCIDENT Accident à Avion [ ] YES Oui [X] NO Non

DATE OF DEATH *(day, month, year)* Date de décès (le jour, le mois, l'année)	PLACE OF DEATH Lieu de décès
(b)(6) 2008 1743	Iraq

I HAVE VIEWED THE REMAINS OF THE DECEASED AND DEATH OCCURRED AT THE TIME INDICATED AND FROM THE CAUSES AS STATED ABOVE
J'ai examiné les restes mortels du dé funtet je conclus que le décès est survenu à l'heure indiquée et à, la suite des causes énumérées ci-dessus.

NAME OF MEDICAL OFFICER Nom du médicin militaire ou du médicin sanitaire	TITLE OR DEGREE Titre ou diplôme
(b)(6)	Medical Examiner

GRADE Grade	INSTALLATION OR ADDRESS Installation ou adresse
(b)(6)	Dover AFB, Dover DE
DATE Date 5/7/2008	SIGNATURE (b)(6)

[1] State disease, injury or complication which caused death, but not mode of dying such as,
[2] State conditions contributing to the death, but not related to the disease or condition causing death.
[1] Préciser la nature de la maladie, de la blessure ou de la complication qui a contribué à la mort, mais non la manière de mourir, telle qu'un arrêt du coeur, etc
[2] Préciser la condition qui a contribué à la mort, mais n'ayant aucun rapport avec la maladie ou à la condition qui a provoqué la mort.

DD FORM 1 APR 77 2064 REPLACES DA FORM 3565, 1 JAN 72 AND DA FORM 3565-R(PAS), 26 SEP 75, WHICH ARE OBSOLETE.

MEDCOM 0958

ACLU Detainee DeathII ARMY MEDCOM 958

ARMED FORCES INSTITUTE OF PATHOLOGY
Office of the Armed Forces Medical Examiner
1413 Research Blvd., Bldg. 102
Rockville, MD 20850
1-301-319-0000
(FAX 1-301-319-0635)

FINAL AUTOPSY REPORT

Name: HUSSEIN, Hyder Abdul
ISN: (b)(6)
Date of Birth: Unknown
Date of Death: (b)(6) 2008
Date of Autopsy: 22 MAR 2008, 0900 hours
Date of Report: 30 APR 2008

Autopsy No. (b)(6)
AFIP No. (b)(6)
Rank: Civilian Iraqi Detainee
Place of Death: Camp Bucca, Iraq
Place of Autopsy: Dover Mortuary Facility, Dover AFB, DE

Circumstances of Death:
(b)(6) an Iraq civilian detainee of unknown age has a well documented history of and treatment for Dilated Cardiomyopathy during two prior admissions in January and February of 2008. He was admitted to the Theater Internment Facility (TIF) hospital, Camp Bucca, Iraq, on (b)(6) 2008 with a complaint of "not feeling well". Over the following four days, (b)(6) suffered cardiac arrest twice. On (b)(6) 08, he suffered a third cardiac arrest and could not be resuscitated. No additional pertinent information is available.

Authorization for Autopsy: Office of the Armed Forces Medical Examiner, IAW 10 USC 1471

Identification:
(b)(6) was identified by toe tags and his TIF number. Fingerprints, dental charting and sample for DNA identification are obtained.

CAUSE OF DEATH:
Dilated Cardiomyopathy

MANNER OF DEATH:
Natural

ACLU Detainee DeathII ARMY MEDCOM 959

EXTERNAL EXAMINATION

The body is that of a well-developed, White male 73 inches tall, 287 pounds and appears of middle age (unknown date of birth). The body build is obese with Body Mass Index of 37.9, (18.5-24.9 is normal; 25-29.9 is over weight and 30.0 and above is considered obese). Lividity is consistent with supine position, rigor is equally present in all extremities, and the body temperature is that of the refrigeration unit.

The scalp and facial hair, beard and mustache, are black. The irides are brown, and the pupils are round and equal in diameter. The corneas are dull and the sclerae are unremarkable. The external auditory canals and ears are unremarkable. The nares are patent and the lips are atraumatic. The nose and maxillae are palpably stable. The teeth appear unremarkable. The tongue reveals no evidence of trauma or bite marks.

The neck is straight, and the trachea is midline and mobile. The chest is symmetric. The abdomen is markedly protuberant. The genitalia are those of a normal adult circumcised male. The testes are descended and free of masses. Pubic hair is present in a normal distribution. The right buttock reveals decubitus ulceration right of the midline and an incised and drained abscess more laterally. The anus is unremarkable.

The upper and lower extremities are symmetric; reveal marked edema and no clubbing. No evidence of trauma is present on examination or dissection of the extremities. The chest and abdomen reveal remarkable stretch marks. A tattoo (b)(6) (b)(6) A large remote healed longitudinal surgical scar is noted on the left upper chest close to the anterior axillary line. No other identifying marks are noted.

CLOTHING AND PERSONAL EFFECTS

The body was received un-clad. A silver-colored ring is noted in the left middle finger. The ring is removed, photographed and submitted to the mortuary staff for proper disposition.

MEDICAL INTERVENTION

Evidence of medical intervention: Endotracheal tube; Naso-gatric tube; EKG pads; Multiple intravenous access lines and a urinary catheter.

RADIOGRAPHS

Full body radiographs and a CT-scan are obtained and demonstrate remote internal fixation of distal left forearm. No recent skeletal fractures are noted.

EVIDENCE OF INJURY

None recovered.

ACLU Detainee DeathII ARMY MEDCOM 960

INTERNAL EXAMINATION

HEAD:
The galeal and subgaleal soft tissues of the scalp are edematous and free of injury. The calvarium is intact, as is the dura mater beneath it. Clear cerebrospinal fluid surrounds the 1400 gm brain, which has unremarkable gyri and sulci. The surface vessels reveal marked congestion. Coronal sections demonstrate sharp demarcation between white and grey matter, without hemorrhage or contusive injury. The ventricles are of normal size. The basal ganglia, brainstem, cerebellum, and arterial systems are free of injury or other abnormalities. There are no skull fractures. The atlanto-occipital joint is stable.

NECK:
The anterior strap muscles of the neck are homogenous and red-brown, without hemorrhage. The thyroid cartilage and hyoid are intact. The larynx is lined by intact tan mucosa. The thyroid is symmetric and red-brown, without cystic or nodular change. The tongue is free of bite marks, hemorrhage, or other injuries. There is no deep paracervical muscular injury and no cervical spine fractures.

BODY CAVITIES:
The ribs, sternum, and vertebral bodies are visibly and palpably intact. The chest cavities reveal bilateral pleural effusion of clear straw-colored fluid; 300 cc in the left and 200 cc in the right. The pericardial sac contains 200 cc of clear straw-colored fluid, and the peritoneal cavity contains effusion fluid, approximately 300 cc. The heart appears grossly enlarged and the major organs occupy their usual anatomic positions. The abdominal wall adipose tissue measures 2" in thickness.

RESPIRATORY SYSTEM:
The right and left lungs are markedly heavy and weigh 1220 and 830 gm, respectively. The external surfaces are smooth and deep red-purple. The pulmonary parenchyma is diffusely congested and markedly edematous, oozing frothy fluid. Two dark red well-demarcated area are noted in the base of the lower lobe of the right lung and the apex of the lower lobe of the left lung, measuring 3 ½ x 2 ½ x 2" and 2 x 2 x1 ½" respectively. Sections through these areas reveal firm dark red parenchyma, with gross appearance of pulmonary infarction. The lungs are photographed for documentation. The pulmonary vessels are normally positioned and are grossly free of thrombo-emboli.

CARDIOVASCULAR SYSTEM:
The heart is markedly enlarged, weighs 790 grams and is contained in an intact pericardial sac. The epicardial surface is smooth, with increased fat investment. The coronary arteries are present in a normal distribution. Cross sections of the coronary vessels reveal no significant atherosclerotic changes. The myocardium is homogenous, red-brown, and soft. The cardiac chambers are dilated. The valve leaflets are thin and mobile except for a thickened and slightly shortened mitral valve. The tricuspid, pulmonary, mitral and aortic valves measure 13, 8, 11 and 7 cm, respectively. The mitral valve is retained for further examination. The walls of the left and right ventricles and

ACLU Detainee DeathII ARMY MEDCOM 961

the interventricular septum are 18. 5 and 18 mm. respectively. The endocardium is smooth and glistening. The aorta gives rise to three intact and patent arch vessels. The renal and mesenteric vessels are unremarkable.

LIVER & BILIARY SYSTEM:
The 3100 gm liver has an intact, smooth capsule and a sharp anterior border. The parenchyma reveals a nutmeg appearance consistent with congestive heart failure, with the usual lobular architecture. No mass lesions or other abnormalities are seen. The gallbladder wall is slightly thickened and contains dark green bile. A gall stone measuring 1 cm in diameter and multiple minute gall stones are noted in the lumen, photographed and retained. The extrahepatic biliary tree is grossly patent.

SPLEEN:
The 780 gm spleen is enlarged and has a smooth. intact, red-purple capsule. The parenchyma is maroon and congested, with distinct Malpighian corpuscles. The major lymph nodes encountered during examination are not enlarged and are unremarkable.

PANCREAS:
The pancreas is firm and yellow-tan, with the usual lobular architecture. No mass lesions or other abnormalities are seen.

ADRENALS:
The right and left adrenal glands are symmetric, with bright yellow cortices and grey medullae. No masses or areas of hemorrhage are identified.

GENITOURINARY SYSTEM:
The right and left kidneys weigh 270 gm and 240 grams, respectively. The external surfaces are intact, smooth with mild persistent lobulation. The cut surfaces are red-tan and congested, with uniformly thick cortices and sharp cortico-medullary junctions. The pelves are unremarkable and the ureters are normal in course and caliber. White bladder mucosa overlies an intact bladder wall. The bladder contains a small amount of clear yellow urine with a urinary catheter in place. Urine is submitted for toxicology. The prostate is normal in size, with lobular, yellow-tan parenchyma. The seminal vesicles are unremarkable. The testes are free of mass lesions. contusions, or other abnormalities. Bilateral hydroceles are noted.

GASTROINTESTINAL TRACT:
The esophagus is intact and lined by smooth, grey-white mucosa. The stomach contains a small amount of dark green fluid. The gastric wall is intact. The duodenum, loops of small and large intestines slightly edematous but otherwise are unremarkable.

MUSCLES & SKELETAL SYSTEM:
Grossly unremarkable with no significant pathological changes. No evidence of recent skeletal trauma is noted during examination or radiologically.

ACLU Detainee DeathII ARMY MEDCOM 962

TOXICOLOGY

- Carbon Monoxide: Carboxyhemoglobin saturation less than 1%.
- Volatiles (Blood and Urine): No ethanol was detected.
- Cyanide: No cyanide detected.
- Screened drugs of abuse and medications (Blood):
  - Positive Benzodiazepine (Midazolam); detected and confirmed.
  - Positive Benzodiazepine (1-Hydroxymidazolam), detected and confirmed.

ADDITIONAL PROCEDURES

1. Documentary photographs are taken by an OAFME photographer.
2. Full body radiographs and CT-scan are obtained.
3. Examination, with skin incisions, of the extremities and back to rule out trauma.
4. Specimens retained for toxicological and/or DNA identification are: blood, vitreous, bile, urine, gastric contents and tissue samples of heart, kidney, liver, lung, spleen, brain, adipose tissue, and muscle.
5. Representative sections of organs are retained in formalin for microscopic examination.
6. Personal effects, a silver-colored ring, is photographed and released to the mortuary staff for proper disposition.

MICROSCOPIC EXAMINATION

Selected portions of organs are retained in formalin. Histological slides are as follows:

1-4: Heart: Focal subendocardial scarring; Prominent perivascular fibrosis; Focal hypertrophic myocytes; Recent septal myocardial infarction with contraction bands and acute inflammatory cell infiltrate.
5: Mitral valve: thickened mitral valve with fibrosis and hyalinization.
6-9, 11: Lungs: Large areas of parenchymal infarctions; increased number intra-alveolar hemosidren and anthracotic pigment-laden macrophages; pulmonary congestion and edema. No evidence of pneumonia.
10: Kidney: Focal areas of acute tubular necrosis.
12: Adrenal glands: Unremarkable.
13: Spleen: Congestion, focal infarction.
14-16: Brain: Unremarkable.
1-16: Postmortem autolysis

ACLU Detainee DeathII ARMY MEDCOM 963

FINAL AUTOPSY DIAGNOSIS

A. Cardiovascular System:

- Cardiomegaly (Cardio Bovus). 790 grams
- Four chamber dilatation consistent with dilated cardiomyopathy.
- Congestive Heart Failure:
  - Bilateral hemothoraces, pericardial and peritoneal effusions.
  - Pulmonary edema, right 1,220 grams and left 830 grams.
  - Hepatomegaly with nutmeg appearance.
  - Bilateral pulmonary infarctions.
  - Generalized edema.
  - Bilateral hydroceles.
- Focal subendocardial and perivascular fibrosis.
- Thickened (fibrosed and hyalinized) mitral valve, unknown etiology.

B. Other Findings:

- Obesity, BMI 37.9 (normal 18.5-24.9, overweight 25.0-29.9, obese 30.0 and above)
- Pulmonary infarction.
- Acute tubular necrosis of kidney.
- Chronic cholecystitis and cholelithiasis.
- Right gluteal abscess, evidence of recent incision and drainage.
- Passive congestion of liver, spleen and kidneys.
- Early signs of developing decubitus ulceration.

C. Injuries

- No evidence of blunt force, sharp force or firearm injuries.

D. Toxicology:

- No evidence of ethanol or drugs of abuse.
- Positive for Benzodiazepine and its metabolites.

OPINION

(b)(6) a civilian Iraqi detainee of unknown age, died from cardiac disease (Dilated Cardiomyopathy, cardiomegaly and congestive heart failure). No evidence of trauma is noted during autopsy. Toxicological results are negative for ethanol and drugs of abuse and positive for Benzodiazepine and its metabolites (consistent with documented medical treatment), and is non-contributory to autopsy conclusions. Manner of death is natural.

(b)(6)

(b)(6)

(b)(6) Medical Examiner

ACLU Detainee DeathII ARMY MEDCOM 964

CERTIFICATE OF DEATH *(OVERSEAS)*
Acte de décès (D'Outre-Mer)

NAME OF DECEASED *(Last, First, Middle)* Nom du décédé (Nom et prénoms)	GRADE Grade	BRANCH OF SERVICE Arme	SOCIAL SECURITY NUMBER Numéro de l'Assurance Social
Hussein, Hyder, Abdul		Civilian	(b)(6)
ORGANIZATION Organisation	NATION *(e.g. United States)* Pays: Iraq	DATE OF BIRTH Date de naissance	SEX Sexe: [X] MALE [ ] FEMALE

RACE Race		MARITAL STATUS État Civil				RELIGION Culte			
X	CAUCASOID Caucasique		SINGLE Célibataire		DIVORCED Divorcé		PROTESTANT Protestant		OTHER (Specify) Autre (Spécifier)
	NEGROID Negroide		MARRIED Marié		SEPARATED Séparé		CATHOLIC Catholique	X	
	OTHER (Specify) Autre (Spécifier)		WIDOWED Veuf				JEWISH Juif		

NAME OF NEXT OF KIN Nom du plus proche parent	RELATIONSHIP TO DECEASED Parenté du décédé avec le sus
STREET ADDRESS Domicile à (Rue)	CITY OR TOWN OR STATE *(Include ZIP Code)* Ville (Code postal compris)

MEDICAL STATEMENT Déclaration médicale

CAUSE OF DEATH *(Enter only one cause per line)* Cause du décès (N'indiquer qu'une cause par ligne)		INTERVAL BETWEEN ONSET AND DEATH Intervalle entre l'attaque et le décès
DISEASE OR CONDITON DIRECTLY LEADING TO DEATH[1] Maladie ou condition directement responsable de la mort.[1]	Cardiomyopathy	
ANTECEDENT CAUSES Symptômes précurseurs de la mort. — MORBID CONDITION, IF ANY, LEADING TO PRIMARY CAUSE Condition morbide, s'il y a lieu, menant à la cause primaire		
ANTECEDENT CAUSES Symptômes précurseurs de la mort. — UNDERLYING CAUSE, IF ANY, GIVING RISE TO PRIMARY CAUSE Condition morbide, s'il y a lieu, menant à la cause primaire		
OTHER SIGNIFICANT CONDITIONS[2] Autres conditions significatives[2]		

MODE OF DEATH Condition de décès	AUTOPSY PERFORMED Autopsie effectuée [X] YES Oui [ ] NO Non	CIRCUMSTANCES SURROUNDING DEATH DUE TO EXTERNAL CAUSES Circonstances de la mort suscitées par des causes extérieures
X NATURAL Mort naturelle	MAJOR FINDINGS OF AUTOPSY Conclusions principales de l'autopsie	
ACCIDENT Mort accidentelle		
SUICIDE Suicide	NAME OF PATHOLOGIST Nom du pathologiste (b)(6)	
HOMICIDE Homicide	(b)(6)	DATE Date 22 March 2008 — AVIATION ACCIDENT Accident à Avion [ ] YES Oui [X] NO Non

DATE OF DEATH *(day, m...* Date de décès (le jour, le ... ès

(b)(6) 2008 1937 — Camp Bucca Iraq

I HAVE VIEWED THE REMAINS OF THE DECEASED AND DEATH OCCURRED AT THE TIME INDICATED AND FROM THE CAUSES AS STATED ABOVE.
J'ai examiné les restes mortels du dé funtet je conclus que le décès est survenu à l'heure indiquée et à, la suite des causes énumérées ci-dessus.

NAME OF MEDICAL OFFICER Nom du médecin militaire ou du médecin sanitaire	TITLE OR DEGREE Titre ou diplômé
(b)(6)	Medical Examiner
GRADE Grade: (b)(6)	INSTALLATION OR ADDRESS Installation ou adresse: Dover AFB, Dover DE
DATE Date: 3/24/2008	(b)(6)

[1] State disease, injury or complication which caused dea...
[2] State conditions contributing to the death, but not relat...
[1] Préciser la nature de la maladie, de la blessure ou de l...
[2] Préciser la condition qui a contribué à la mort, mais n'étant aucun rapport avec la maladie qui a la conduite qui a provoqué la mort.

DD FORM 1 APR 77 2064 REPLACES DA FORM 3565, 1 JAN 72 AND DA FORM 3565-R(PAS), 26 SEP 75, WHICH ARE OBSOLETE.

ARMED FORCES INSTITUTE OF PATHOLOGY
Office of the Armed Forces Medical Examiner
1413 Research Blvd., Bldg. 102
Rockville, MD 20850
301-319-0000

AUTOPSY EXAMINATION REPORT

Name: BTB Muhammed Al-Ithawi, Taha Daher
ISN: (b)(6)
Date of Birth: Unknown
Date of Death: (b)(6)
Date/Time of Autopsy: 1 Apr 2008@1130
Date of Report: 10 Apr 2008

Autopsy No.: (b)(6)
AFIP No.: (b)(6)
Rank: Iraqi Civilian
Place of Death: Iraq
Place of Autopsy: Port Mortuary
Dover AFB, Dover, DE

Circumstances of Death: Per investigation, this Iraqi male was admitted to the 31st Combat Surgical Hospital on 16 March 2008 for multiple medical problems, including acute renal failure, untreated diabetes mellitus, and an acute myocardial infarction. While in the hospital he underwent surgery for gastrointestinal bleeding, and was also treated for continued renal failure and another myocardial infarction. Despite aggressive medical intervention, he eventually succumbed to his multiple ailments.

Authorization for Autopsy: Armed Forces Medical Examiner, per 10 U.S. Code 1471

Identification: Presumptive identification is established by examination of paperwork in the case file. Post-mortem fingerprints and a specimen suitable for DNA analysis are obtained. .

CAUSE OF DEATH: **Hypertensive atherosclerotic cardiovascular disease**

MANNER OF DEATH: **Natural**

ACLU Detainee DeathII ARMY MEDCOM 966

EXTERNAL EXAMINATION

The body is that of a well-developed, well-nourished unclad male. The body weighs 273 pounds and is 73 inches in length. The body is cold. Rigor is passing. Lividity is present and fixed on the posterior surface of the body, except in areas exposed to pressure. The head is normocephalic, and the scalp hair is black and gray. Facial hair consists of a beard and mustache. The irides are brown. The corneae are cloudy. The conjunctivae are congested. The sclerae are white/red. The eyelids are edematous. The external auditory canals, external nares and oral cavity are free of foreign material and abnormal secretions. The earlobes have creases bilaterally. The nasal skeleton and maxilla are palpably intact. The lips are without evident injury. The upper teeth are absent and the lower teeth are in poor condition. Examination of the neck reveals no evidence of injury. No evidence of injury of the ribs or the sternum is evident externally. The abdomen is soft and distended. There is a 10 ½ inch vertical stapled incision on the midline of the abdomen. The external genitalia are those of an adult circumcised male, and the scrotum and penis are edematous. There are numerous pinpoint pustules on the posterior torso. The anus is unremarkable. The extremities are diffusely edematous. The fingernails are short and intact. Underneath the wrap and gauze on the left foot is a necrotic ulcer, 2 x 2 inches, and the 1st and 2nd toes on the left foot are absent. Scars and tattoos are not noted.

CLOTHING AND PERSONAL EFFECTS

No items of clothing or personal effects accompany the body.

MEDICAL INTERVENTION

- EKG leads (5) on the torso
- Stapled incision, mid abdomen
- Foley catheter
- Triple-lumen catheter, right femoral area
- Wrap and gauze on left foot, labeled with "29 Mar 08 0930"

RADIOGRAPHS

A complete set of postmortem radiographs is obtained and demonstrates the medical intervention and natural disease as noted.

EVIDENCE OF INJURY

No significant injuries are identified.

ACLU Detainee DeathII ARMY MEDCOM 967

INTERNAL EXAMINATION

BODY CAVITIES:

The body is opened by the usual thoraco-abdominal incision and the chest plate is removed. The ribs, sternum, and vertebral bodies are visibly and palpably intact. All body organs are present in normal anatomical position. There are dense left–sided pleural adhesions. There is 100 ml of serosanguinous fluid in the left pleural cavity. There is 1500 ml of serosanguinous fluid in the peritoneal cavity. The subcutaneous fat layer of the abdominal wall is 1 ½ inch thick.

HEAD AND CENTRAL NERVOUS SYSTEM:

The scalp is reflected. The galeal and subgaleal soft tissues of the scalp are free of injury. There are no skull fractures. The calvarium of the skull is removed. The dura mater and falx cerebri are intact. There is no epidural or subdural hemorrhage present. The leptomeninges are thin and delicate. The cerebral hemispheres are symmetrical. The structures at the base of the brain, including cranial nerves and blood vessels, are intact. Clear cerebrospinal fluid surrounds the 1410 gram brain, which has unremarkable gyri and sulci. Coronal sections through the cerebral hemispheres reveal no lesions. Transverse sections through the brain stem and cerebellum are unremarkable. The atlanto-occipital joint is stable.

NECK:

The anterior strap muscles of the neck are homogenous and red-brown, without hemorrhage. The thyroid cartilage and hyoid bone are intact. The larynx is lined by intact white mucosa. The tongue is free of bite marks, hemorrhage, or other injuries.

CARDIOVASCULAR SYSTEM:

The 660 gram heart is contained in an intact pericardial sac. The epicardial surface is smooth, with minimal fat investment. The coronary arteries are present in a normal distribution. They demonstrate the following amounts of atherosclerotic stenosis: approximately 95% of the proximal left anterior descending coronary artery, approximately 50% of the mid right coronary artery, and approximately 95% of the proximal and mid left circumflex coronary artery. The myocardium is homogenous, pale tan, and moderately firm. The valve leaflets are thin and mobile. The endocardium is smooth and glistening. The aorta gives rise to three intact and patent arch vessels, and demonstrates severe calcific change distally, which extends into the iliac arteries. The renal arteries demonstrate approximately 75% atherosclerotic stenosis bilaterally. The mesenteric vessels are unremarkable.

RESPIRATORY SYSTEM:

The upper airway is clear of debris and foreign material; the mucosal surfaces are smooth, yellow-tan and unremarkable. The right pleural surface is smooth and glistening; the left pleural surface is tan-white and fibrotic. The pulmonary parenchyma is diffusely congested and edematous, exuding large amounts of blood and frothy fluid; no focal lesions are noted. The pulmonary arteries are

ACLU Detainee DeathII ARMY MEDCOM 968

normally developed, patent, and without thrombus or embolus. The right lung weighs 1090 grams; the left 1070 grams.

HEPATOBILIARY SYSTEM:

The 2330 gram liver has an intact smooth capsule covering tan-red moderately congested parenchyma with no focal lesions noted. The gallbladder is markedly distended and contains 50 ml of green-brown, mucoid bile; the mucosa is velvety and unremarkable. The extrahepatic biliary tree is patent, without evidence of calculi.

GASTROINTESTINAL SYSTEM:

The esophagus is lined by gray-white, smooth mucosa. The gastric mucosa is arranged in the usual rugal folds and the lumen contains approximately 500 ml of thick, yellow material. There is a 4 inch sutured incision on the mucosal surface of the distal stomach. The small bowel is unremarkable. The serosal surface of the large bowel is diffusely dark purple-gray. The pancreas has a pale tan lobulated appearance and the ducts are clear. The appendix is present.

GENITOURINARY SYSTEM:

The right kidney weighs 200 grams; the left 200 grams. The renal capsules are smooth and thin, semi-transparent and stripped with ease from the underlying granular, red-brown cortical surfaces. The cortex is sharply delineated from the medullary pyramids, which are red-purple to tan and unremarkable. The calyces, pelves and ureters are unremarkable. White bladder mucosa overlies an intact bladder wall. The bladder contains a catheter and is empty. The testes, prostate gland and seminal vesicles are without note.

LYMPHORETICULAR SYSTEM:

The 460 gram spleen has a smooth, intact capsule covering red-pale tan, moderately firm parenchyma; the lymphoid follicles are unremarkable. Lymph nodes in the hilar, periaortic and iliac regions are not enlarged.

ENDOCRINE SYSTEM:

The thyroid gland is symmetrically enlarged and red-brown, without cystic or nodular change. The right and left adrenal glands are symmetric, with bright yellow cortices and red-brown medullae. No masses or areas of hemorrhage are identified.

MUSCULOSKELETAL SYSTEM:

There are degenerative changes of the 6th and 7th cervical, and 9th-12th thoracic vertebral bodies (seen radiologically). No abnormalities of muscle are identified.

ACLU Detainee DeathII ARMY MEDCOM 969

ADDITIONAL PROCEDURES

1. Documentary photographs are taken by an OAFME staff photographer.
2. Specimens retained for toxicology testing and/or DNA identification are: vitreous fluid, blood, spleen, liver, lung, kidney, brain, myocardium, bile, gastric contents, adipose tissue and psoas muscle.
3. The dissected organs are forwarded with body.

MICROSCOPIC EXAMINATION

Selected portions of organs are retained in formalin, without preparation of histology slides.

ACLU Detainee DeathII ARMY MEDCOM 970

FINAL AUTOPSY DIAGNOSES:

I. Hypertensive atherosclerotic cardiovascular disease:
A. Near-occlusive atherosclerotic stenosis of the left anterior descending and left circumflex coronary arteries, and approximately 50% atherosclerotic stenosis of the right coronary artery
B. Atherosclerotic stenosis of the renal arteries, approximately 75% bilaterally
C. Diffuse calcific change of the distal aorta and iliac arteries
D. Cardiomegaly, 660 grams
E. Gross hypertensive changes of the kidneys

II. Additional findings:
A. Bilateral pulmonary congestion, right 1090 grams, left 1070 grams
B. Dense left-sided pleural adhesions
C. Left pleural cavity, 100 ml serosanguinous fluid
D. Peritoneal cavity, 1500 ml serosanguinous fluid
E. History of untreated diabetes mellitus, with a necrotic ulcer and missing digits on the left foot
F. History of upper gastrointestinal bleeding, with a stapled abdominal incision and a sutured gastric incision
G. Grossly necrotic large bowel
H. Diffusely enlarged thyroid with no focal lesions identified

III. No evidence of significant injury

IV. Evidence of Medical Intervention: As noted above

V. Identifying marks and tattoos: None noted.

VI. Postmortem Changes: As noted above

VII. Toxicology (AFIP):
A. Ethanol: No ethanol is detected in the blood and vitreous fluid.
B. Drugs: No screened drugs of abuse are detected in the blood. Diltiazem is detected in the blood at a level of 0.78 mg/L. No other medications are detected in the blood.
C. Carbon Monoxide: The carboxyhemoglobin saturation in the blood is less than 1%.
D. Cyanide: No cyanide is detected in the blood.

ACLU Detainee DeathII ARMY MEDCOM 971

OPINION

This Iraqi male (b)(6) died of hypertensive atherosclerotic cardiovascular disease. There was almost complete blockage of two of the three main coronary arteries, and moderate blockage of the third. There was also atherosclerotic disease of the aorta and arteries supplying blood to the legs and kidneys. The heart and kidneys demonstrated changes consistent with hypertension (high blood pressure). The decedent also had a non-healing ulcer on his left foot, consistent with the given history of untreated diabetes. Additionally, the decedent's stay in the hospital was complicated by progressive kidney failure, a myocardial infarction (heart attack), and bleeding in the gastrointestinal tract. Toxicological testing was positive for a medication used to treat hypertension, but otherwise negative. The manner of death is natural.

(b)(6)

(b)(6) MEDICAL EXAMINER

ACLU Detainee DeathII ARMY MEDCOM 972

CERTIFICATE OF DEATH (OVERSEAS)
Acte de décès (D'Outre-Mer)

NAME OF DECEASED (Last, First, Middle) / Nom du décédé (Nom et prénoms)	GRADE / Grade	BRANCH OF SERVICE / Arme	SOCIAL SECURITY NUMBER / Numéro de l'Assurance Social
BTB Muhammed, Al-Ithawi, Taha Daher		Civilian	(b)(6)
ORGANIZATION / Organisation	NATION (e.g. United States) / Pays	DATE OF BIRTH / Date de naissance	SEX / Sexe: ☐ MALE ☐ FEMALE

RACE / Race		MARITAL STATUS / État Civil			RELIGION / Culte		
X	CAUCASOID / Caucasique		SINGLE / Célibataire		DIVORCED / Divorcé		PROTESTANT / Protestant
	NEGROID / Negroïde		MARRIED / Marié		SEPARATED / Séparé		CATHOLIC / Catholique
	OTHER (Specify) / Autre (Spécifier)		WIDOWED / Veuf				JEWISH / Juif
						X	OTHER (Specify) / Autre (Spécifier)

NAME OF NEXT OF KIN / Nom du plus proche parent	RELATIONSHIP TO DECEASED / Parenté du décédé avec le sus
STREET ADDRESS / Domicile à (Rue)	CITY OR TOWN OR STATE (Include ZIP Code) / Ville (Code postal compris)

MEDICAL STATEMENT / Déclaration médicale

CAUSE OF DEATH (Enter only one cause per line) / Cause du décès (N'indiquer qu'une cause par ligne)		INTERVAL BETWEEN ONSET AND DEATH / Intervalle entre l'attaque et le décès
DISEASE OR CONDITON DIRECTLY LEADING TO DEATH[1] / Maladie ou condition directement responsable de la mort.[1]	Hypertensive Atherosclerotic Cardiovascular Disease	
ANTECEDENT CAUSES / Symptômes précurseurs de la mort. — MORBID CONDITION, IF ANY, LEADING TO PRIMARY CAUSE / Condition morbide, s'il y a lieu, menant à la cause primaire		
ANTECEDENT CAUSES / Symptômes précurseurs de la mort. — UNDERLYING CAUSE, IF ANY, GIVING RISE TO PRIMARY CAUSE / Condition morbide, s'il y a lieu, menant à la cause primaire		
OTHER SIGNIFICANT CONDITIONS[2] / Autres conditions significatives[2]		

MODE OF DEATH / Condition de décès	AUTOPSY PERFORMED / Autopsie effectuée	CIRCUMSTANCES SURROUNDING DEATH DUE TO EXTERNAL CAUSES / Circonstances de la mort suscitées par des causes extérieures
X NATURAL / Mort naturelle	☒ YES / Oui ☐ NO / Non	
ACCIDENT / Mort accidentelle	MAJOR FINDINGS OF AUTOPSY / Conclusions principales de l'autopsie	
SUICIDE / Suicide	NAME OF PATHOLOGIST / Nom du pathologiste: (b)(6)	
HOMICIDE / Homicide	(b)(6) — DATE / Date: 1 April 2008	AVIATION ACCIDENT / Accident à Avion: ☐ YES / Oui ☒ NO / Non

DATE OF DEATH (day, month, year) / Date du décès (le jour, le mois, l'année)	PLACE OF DEATH / Lieu de décès
(b)(6) 2008	Iraq

I HAVE VIEWED THE REMAINS OF THE DECEASED AND DEATH OCCURRED AT THE TIME INDICATED AND FROM THE CAUSES AS STATED ABOVE.
J'ai examiné les restes mortels du dé funtel je conclus que le décès est survenu à l'heure indiquée et à, la suite des causes énumérées ci-dessus.

NAME OF MEDICAL OFFICER / Nom du médecin militaire ou du médecin sanitaire	TITLE OR DEGREE / Titre ou diplômé
(b)(6)	Medical Examiner

GRADE / Grade	INSTALLATION OR ADDRESS / Installation ou adresse
(b)(6)	Dover AFB, Dover DE
DATE / Date: 4/1/2008	(b)(6)

[1] State disease, injury or complication which caused death
[2] State conditions contributing to the death, but not related
[3] Préciser la cause de la maladie, de la blessure ou de la
[4] Préciser la condition qui a contribué à la mort, mais d'autres causes reçues sans la maladie ou à la condition qui a conservé la mort.

DD FORM 1 APR 77 2064 REPLACES DA FORM 5003, 1 JAN 72 AND DA FORM 3466-R(PAS), 28 SEP 75, WHICH ARE OBSOLETE.

MEDCOM 0973

ARMED FORCES INSTITUTE OF PATHOLOGY
Office of the Armed Forces Medical Examiner
1413 Research Blvd., Bldg. 102
Rockville, MD 20850
301-319-0000

FINAL AUTOPSY REPORT

Name: **BTB** Mansur, Ziyad Hamid
SSAN: (b)(6)
Date of Birth: (b)(6) 1967
Date of Death: (b)(6) 2008
Date/Time of Autopsy: 09 APR 2008 @ 1100
Date of Report: 26 AUG 2008

Autopsy No.: (b)(6)
AFIP No.: (b)(6)
Grade: Civilian, Detainee
Place of Death: Iraq
Place of Autopsy: Dover Mortuary
Dover AFB, DE

Circumstances of Death: This 41 year-old detainee was being detained in Theater Internment Facility (TIF) Camp Bucca, when as reported, he was observed by another detainee to be shaking while sleeping. A detainee attempted to wake him and he was noted to be unresponsive. He was carried to compound guards who initiated lifesaving measures. All resuscitative measures were unsuccessful.

Authorization for Autopsy: Office of the Armed Forces Medical Examiner, IAW 10 USC 1471.

Identification: Presumptive identification via review of all accompanying paperwork. Post-mortem fingerprints taken and dental exam performed. Suitable specimen for DNA analysis obtained.

CAUSE OF DEATH: Undetermined

MANNER OF DEATH: Undetermined

ACLU Detainee DeathII ARMY MEDCOM 974

EXTERNAL EXAMINATION

The body is that of a well-developed, well-nourished male. The body is approximately 62 ½ inches in length, weighs 152 pounds, and appears compatible with the stated age of 41 years old. The body is cold. Lividity (faint) is fixed on the posterior surface of the body except in the areas exposed to pressure. Rigor is resolving.

The scalp hair is brown/grey with male pattern baldness. Facial hair consists of a beard. The irides are indistinct. The corneae are cloudy. There are scattered petechiae of the upper right eyelid and lower left eyelid. The remaining conjunctivae are pale with no petechiae. The sclerae are white with drying artifact. The oral cavity, external nares, and external auditory canals are free of foreign material or abnormal secretions. The lips are dry. There are no petechiae of the oral mucosa

The chest is symmetric. The genitalia are those of a circumcised adult male. The pubic hair is shaved. The anus is atraumatic.

The upper and lower extremities are symmetric and without clubbing or edema. The fingernails are intact. On the right arm is a 1 x 1-inch scar. On the right knee is a 1 x 1-inch scar. On the left ankle at foot are multiple scars that measure up to 2 inches in maximum dimension.

CLOTHING AND PERSONAL EFFECTS

The body is clad in yellow pants, white pants, white underwear, and white t-shirt (cut). Two identification tags accompany the body.

MEDICAL INTERVENTION

No evidence of medical intervention is present on the body.

RADIOGRAPHS

A complete set of post-mortem radiographs is obtained and demonstrate a radio-opaque fragment in the right leg (metal fragment recovered from dense fibrous tissue, photographed and placed in a labeled evidence container).

EVIDENCE OF INJURY

There is no evidence of external or internal recent injury.

INTERNAL EXAMINATION

BODY CAVITIES:

The ribs, sternum, and vertebral bodies are visibly and palpably intact. No excess fluids or adhesions are present in any of the body cavities. The organs occupy their usual anatomic positions.

HEAD (CENTRAL NERVOUS SYSTEM) and NECK:

The galeal and subgaleal soft tissues of the scalp are free of injury. There are no skull fractures. The dura mater and falx cerebri are intact. The leptomeninges are thin and delicate. The unfixed brain weighs 1380 grams and is retained for Neuropathology consultation (see Neuropathology consultation).

ACLU Detainee DeathII ARMY MEDCOM 975

The anterior strap muscles of the neck are homogenous and red-brown without hemorrhage (by layer-wise dissection). The thyroid cartilage and hyoid bone are intact. The larynx is lined by intact white mucosa. The tongue is free of bite marks, hemorrhage, or other injuries. The thyroid is symmetric and red-brown, without cystic or nodular change. Incision and dissection of the posterior neck demonstrates no deep paracervical muscular injury and no cervical spinal column fractures.

RESPIRATORY SYSTEM:
The upper airway is clear of debris and foreign material. The mucosal surfaces are smooth, yellow-tan and unremarkable. The right and left lungs weigh 650 and 540 grams, respectively. The pulmonary parenchyma is red-purple exuding moderate amounts of blood. The pulmonary arteries are normally developed and patent without thrombus or embolus.

CARDIOVASCULAR SYSTEM:
The heart weighs 290 grams and is contained in an intact pericardial sac. The heart is retained for cardiovascular pathology consultation (see cardiovascular consultation). The aorta and its major branches arise normally and follow the usual course and are unremarkable. The vena cava and its major tributaries return to the heart in the usual distribution and are free of thrombi.

LIVER & BILIARY SYSTEM:
The 1780 gram liver has an intact, smooth capsule and a sharp anterior border. The parenchyma is tan-brown with the usual lobular architecture. In the right dome is a 3.0 x 3.0 centimeter red nodule. No other abnormalities are seen. The gallbladder contains less than 1 milliliter of bile. The extrahepatic biliary tree is patent.

SPLEEN:
The 250 gram spleen has a smooth, intact, red-purple capsule. The parenchyma is maroon with unremarkable lymphoid follicles.

PANCREAS:
The pancreas is red-tan with a lobulated appearance. No mass lesions or other abnormalities are seen.

ADRENALS:
The right and left adrenal glands are symmetric, with bright yellow cortices and red-brown medullae. No masses or areas of hemorrhage are identified.

GENITOURINARY SYSTEM:
The right and left kidneys weigh 140 and 140 grams, respectively. The external surfaces are intact and smooth. The cut surfaces are dark-red and the cortex is delineated from the medullary pyramids. The pelves are unremarkable and the ureters are normal in course and caliber. The bladder contains scant urine. The prostate and testes are unremarkable.

ACLU Detainee DeathII ARMY MEDCOM 976

GASTROINTESTINAL TRACT:
The esophagus is intact and lined by smooth, grey-white mucosa. The stomach, small bowel, colon, and appendix are unremarkable. The stomach contains 50 milliliters of partially digested food particles.

MUSCULOSKELETAL:
Muscle development is normal. No bone or joint abnormalities are identified.

MICROSCOPIC EXAMINATION

Lung, Left (slide 1):	Moderate congestion with scattered anthracotic pigment; no significant pathologic diagnosis
Lung, Right (slide 2):	Moderate congestion with scattered anthracotic pigment and focal edema
Kidney (slide 3):	Moderate congestion; no significant pathologic diagnosis
Spleen (slide 3):	Moderate congestion; no significant pathologic diagnosis
Liver (slide 4):	Hemangioma; moderate congestion

ADDITIONAL PROCEDURES

1. Specimens retained for toxicology testing and/or DNA identification are: Blood, vitreous fluid, liver, urine, lung, kidney, spleen, psoas muscle, adipose tissue and gastric contents.
2. The dissected organs are forwarded with the body. The brain and heart are retained for consultation.
3. Selected portions of organs are retained in formalin.
4. Personal effects are released with the body.
5. Recovered evidence: As described above, retained by OAFME.
6. Skin incisions of the posterior torso, buttocks and extremities reveal no evidence of trauma.
7. Documentary photographs are taken by (b)(6) (OAFME). Assisting with the autopsy is (b)(6) (OAFME).

CONSULTATIONS

I. Cardiovascular pathology (see CV Path consultation for complete report):
   a. Diagnosis: Moderate dysplasia of sinoatrial nodal artery and intramural coronary arteries in crest of ventricular septum
   b. Comment: The correlation between small vessel disease in the cardiac conduction system and sudden death is unclear, particularly in the absence of significant scarring in the crest of the septum. Fragmentation of the AV node (persistent fetal dispersion) has also been postulated as a potential source of re-entry tachyarrhythmia.

II. Neuropathology (see AFIP consultation for complete report):
   a. Mild brain swelling; unremarkable leptomeninges; no gross evidence of herniation or midline shift; no focal lesions identified
   b. On microscopic examination there is mild subependymal gliosis of the ventral surface of the corpus callosum. These changes are mild and non-specific. No other pathologic changes are noted.

ACLU Detainee DeathII ARMY MEDCOM 977

FINAL AUTOPSY DIAGNOSES

I. No evidence of significant recent trauma

II. Natural disease:
A. Moderate dysplasia of sinoatrial nodal artery and intramural coronary arteries in crest of ventricular septum
B. Hemangioma of the liver

III. Evidence of medical intervention: None

IV. Identifying marks: As described above

V. Post-mortem changes: As described above

VI. Toxicology (AFIP):
A. VOLATILES: No ethanol detected in the blood and vitreous fluid
B. DRUGS: No screened drugs of abuse/medications detected in the blood
C. CARBON MONOXIDE: The carboxyhemoglobin saturation in the blood was less than 1%
D. CYANIDE: No cyanide was detected in the blood

OPINION

This 41 year-old detainee, (b)(6) was, by report, observed to be shaking while sleeping. When another person attempted to wake him, he was noted to be unresponsive. At autopsy examination, there is no evidence of recent blunt force injury, sharp force injury, or gunshot wounds. The metal fragment recovered from the right leg is consistent with remote injury. The petechiae of the eyelids are non-specific; however, asphyxia cannot be completely excluded. Cardiovascular pathology consultation was significant for dysplasia of the nodal and intramural coronary arteries. However, the correlation between sudden death and this finding in the absence of significant scarring is unclear. Microscopic examination was non-contributory. Neuropathology consultation was non-contributory. The toxicology screen was negative. With no evidence of recent injury, negative toxicology, and non-contributory microscopic examination (including the heart and brain) the cause of death is undetermined. Thus the manner of death is undetermined[1].

(b)(6)

(b)(6) Medical Examiner (b)(6)

[1] If additional information becomes available that necessitates a change in the cause and manner of death, an amendment to this report will be made.

ACLU Detainee DeathII ARMY MEDCOM 978

CERTIFICATE OF DEATH *(OVERSEAS)*
Acte dé décès (D'Outre-Mer)

NAME OF DECEASED *(Last, First, Middle)* Nom du décédé (Nom et prénoms)	GRADE Grade	BRANCH OF SERVICE Arme	SOCIAL SECURITY NUMBER Numéro de l'Assurance Social
BTB Mansur, Ziyad, Hamid		Civilian	(b)(6)

ORGANIZATION Organisation	NATION *(e.g. United States)* Pays	DATE OF BIRTH Date de naissance	SEX Sexe
CID (b)(6)		(b)(6) 1967	[X] MALE [ ] FEMALE

RACE Race		MARITAL STATUS État Civil			RELIGION Culte		
[X]	CAUCASOID Caucasique	[ ]	SINGLE Célibataire	[ ] DIVORCED Divorcé	[ ] PROTESTANT Protestant	[X]	OTHER (Specify) Autre (Spécifier) Sunni-Islam
[ ]	NEGROID Negroide	[ ]	MARRIED Marié	[ ] SEPARATED Séparé	[ ] CATHOLIC Catholique		
[ ]	OTHER (Specify) Autre (Spécifier)	[ ]	WIDOWED Veuf		[ ] JEWISH Juif		

NAME OF NEXT OF KIN Nom du plus proche parent	RELATIONSHIP TO DECEASED Parenté du décédé avec le sus
STREET ADDRESS Domicilié à (Rue)	CITY OR TOWN OR STATE *(Include ZIP Code)* Ville (Code postal compris)

MEDICAL STATEMENT Déclaration médicale

CAUSE OF DEATH (Enter only one cause per line) Cause du décès (N'indiquer qu'une cause par ligne)		INTERVAL BETWEEN ONSET AND DEATH Intervalle entre l'attaque et le décès
DISEASE OR CONDITON DIRECTLY LEADING TO DEATH [1] Maladie ou condition directement responsable de la mort.	Undetermined	
ANTECEDENT CAUSES Symptômes précurseurs de la mort. MORBID CONDITION, IF ANY, LEADING TO PRIMARY CAUSE Condition morbide, s'il y a lieu, menant à la cause primaire		
UNDERLYING CAUSE, IF ANY, GIVING RISE TO PRIMARY CAUSE Condition morbide, s'il y a lieu, menant à la cause primaire		
OTHER SIGNIFICANT CONDITIONS [2] Autres conditions significatives		

MODE OF DEATH Condition de décès	AUTOPSY PERFORMED Autopsie effectuée [X] YES Oui [ ] NO Non	CIRCUMSTANCES SURROUNDING DEATH DUE TO EXTERNAL CAUSES Circonstances de la mort suscitées par des causes extérieures
[ ] NATURAL Mort naturelle	MAJOR FINDINGS OF AUTOPSY Conclusions principales de l'autopsie	Mode of Death : Undetermined
[ ] ACCIDENT Mort accidentelle		
[ ] SUICIDE Suicide	NAME OF PATHOLOGIST Nom du pathologiste (b)(6)	
[ ] HOMICIDE Homicide	(b)(6) DATE Date 9 April 2008	AVIATION ACCIDENT Accident à Avion [ ] YES Oui [X] NO Non

DATE OF DEATH *(day, month, year)* Date de décès (le jour, le mois, l'année)	PLACE OF DEATH Lieu de décès
(b)(6) 2008	Iraq

I HAVE VIEWED THE REMAINS OF THE DECEASED AND DEATH OCCURRED AT THE TIME INDICATED AND FROM THE CAUSES AS STATED ABOVE
J'ai examiné les restes mortels du dé funtet je conclus que le décès est survenu à l'heure indiquée et à, la suite des causes énumérées ci-dessus.

NAME OF MEDICAL OFFICER Nom du médicin militaire ou du médicin sanitaire	TITLE OR DEGREE Titre ou diplômé
(b)(6)	

GRADE Grade	INSTALLATION OR ADDRESS Installation ou adresse
(b)(6)	Dover AFB, Dover DE
DATE Date 9/3/2008	SIGNATURE (b)(6)

[1] State disease, injury or complication which caused death, but not mode of dying such as heart failure, ect.
[2] State conditions contributing to the death, but not related to the disease or condition causing death.
[1] Préciser la nature de la maladie, de la blessure ou de la complication qui a contribué à la mort, mais non la manière de mourir, telle qu 'un arrêt du coeur, etc
[2] Préciser la condition qui a contribué à la mort, mais n'ayant aucun rapport avec la maladie ou à la condition qui a provoqué la mort

DD FORM 1 APR 77 2064 REPLACES DA FORM 3565, 1 JAN 72 AND DA FORM 3565-R(PAS), 26 SEP 75, WHICH ARE OBSOLETE.

MEDCOM 0979

ACLU Detainee DeathII ARMY MEDCOM 979

ARMED FORCES INSTITUTE OF PATHOLOGY
Office of the Armed Forces Medical Examiner
1413 Research Blvd., Bldg. 102
Rockville, MD 20850
301-319-0000

AUTOPSY EXAMINATION REPORT

Name: BTB Kazim, Husayn Uwayyid (b)(6)
ISN: (b)(6)
Date of Birth: BTE (b)(6) 1978
Date of Death: (b)(6) 2008
Date/Time of Autopsy: 07 July 2008 @ 1330 hrs.
Date of Report: 25 August 2008

Autopsy No.: (b)(6)
AFIP No.: (b)(6)
Rank: Detainee
Place of Death: Camp Bucca, Iraq
Place of Autopsy: Port Mortuary, Dover AFB, DE

Circumstances of Death: This 39 year old detainee was reported missing following an internment serial number (ISN) headcount. A search of the compound found the decedent lying down in a tent. The decedent was removed from the tent and medical treatment started.

Authorization for Autopsy: Armed Forces Medical Examiner, per 10 U.S. Code 1471

Identification: Presumptive identification is made by internment serial number; psoas muscle is retained for DNA identification if needed for future identification.

CAUSE OF DEATH: **Strangulation complicated by multiple blunt force injuries**

MANNER OF DEATH: **Homicide**

ACLU Detainee DeathII ARMY MEDCOM 980

EXTERNAL EXAMINATION

The body is that of a well-developed, well-nourished Male clad in the items listed below. The body weighs 210 pounds, measures 71 inches in length and appears consistent with the reported age of 39 years. Lividity is fixed on the posterior surface of the body except where exposed to pressure. Decomposition changes include green discoloration and marbling of the upper and lower extremities. Rigor is equal in all extremities. The body, which has been previously frozen, is cold.

Injuries to the head are described below in "Evidence of Injury." The head is normocephalic. The scalp is covered with short dark black hair with temporal graying in a normal distribution. The irides are hazel and the corneae are clear. The external auditory canals are free of fluid. The ears are unremarkable. The nares and the lips are unremarkable. The nose and maxillae are palpably intact. The teeth are natural. The neck is straight, and the trachea is midline and mobile.

Injuries to the torso are described below in "Evidence of Injury." The abdomen is soft. The genitalia are those of a normal adult circumcised male. The testes are descended and free of masses. Pubic hair has been shaved close to the skin. The back is unremarkable. The buttocks and anus are unremarkable.

Injuries to the extremities are described below in "Evidence of Injury." The hands are not secured in paper bags. The fingernails are intact. Identification tags are affixed to each 2nd finger. There are no identifying marks to include tattoos.

CLOTHING AND PERSONAL EFFECTS

The following clothing items and personal effects are present on the body at the time of autopsy:

- Torn white briefs

MEDICAL INTERVENTION

Medical intervention present on the body at the time of autopsy includes:

- Endotracheal tube (appropriately placed)
- Electrocardiogram pickup on the left lateral torso

RADIOGRAPHS

A complete set of postmortem radiographs is obtained and demonstrates the injuries described below.

EVIDENCE OF INJURY

The ordering of the following injuries is for descriptive purposes only, and is not intended to imply order of infliction or relative severity.

INJURIES TO THE HEAD AND NECK:

There is an 8 x 5-inch confluent dark blue-purple contusion over the entire forehead and both periorbital regions. A 1 x 1-inch oval abraded contusion is located above the lateral left eye. Two oval abraded contusions are below the right eye, 1 x ½-inch and ¾ x ¾-inches respectively. A ¾ x ¾-inch oval abraded contusion is below the left eye. A 2 x 2-inch abraded contusion covers the

ACLU Detainee DeathII ARMY MEDCOM 981

chin. The conjunctivae and sclerae are diffusely hemorrhagic. There is diffuse subgaleal hemorrhage and bilateral intramuscular hemorrhage of the temporalis musculature. There is intramuscular hemorrhage of the left proximal aspect of the medial body of the sternocliedomastoid muscle (½-inch), inferior aspect of the left sternohyoid muscle (¼-inch) and proximal aspect of the right sternohyoid muscle (¼-inch). The inferior right thyroid gland has focal (1/4-inch) intraparenchymal hemorrhage. There is hemorrhage into the soft tissue surrounding the right greater horn of the thyroid cartilage.

INJURIES TO THE TORSO:
There are multiple, grouped, oval contusions on the right side of the chest ranging from ¼-inch to 1-1/2-inches in maximum dimension. Two oval contusions on the left side of the chest measure up to 1-½-inches in maximum diameter. The left lower quadrant of the abdomen has a 1 ½ x 1 ½-inch oval contusion. The entire back demonstrates multiple, grouped, oval contusions (right side greater than the left side) ranging from ¼-inch to 1-inch in greatest dimension. There is soft tissue and intramuscular hemorrhage of the central upper back and right shoulder measuring 2 x 2-½ and 3 x 1-inches respectively. There is soft tissue and intramuscular hemorrhage of the central lower aspect of the back and lateral left aspect of the lower lateral back measuring 6 x 1-½ and 5 x 2-inches respectively. There are fractures of the anterior aspects of the 5th, 6th and 7th right ribs and lateral aspect of the 9th left rib. Lumbar transverse processes are fractured on the right side of the 3rd and 4th and on the left side of the 4th vertebrae. There is diffuse hemorrhage of the posterior mediastinum and surrounding the thoracic vertebrae at the costovertebral junctions. There is a contusion to the posterior wall of the left ventricle of the heart. There is a subdural hematoma surrounding the thoracic spinal cord and intraparenchymal hemorrhage of the spinal cord at the level of the 9th thoracic vertebra. There are bilateral hemothoraces, 50 milliliters on the right and 75 milliliters on the left. There is diffuse retroperiotenial hemorrhage, approximately 200 milliliters, and hemoperitoneum of 200 milliliters.

INJURIES TO THE EXTREMITIES:
The anterior aspect of the right arm demonstrates two oval contusions, ¼-inch to 1-½-inches in maximum dimensions. The posterior aspect of the right arm has multiple oval contusions ranging from ¼-inch to ½-inch in greatest dimension. The anterior aspect of the left arm has three oval contusions ranging from ¼-inch to 1-½-inches in greatest dimension. The anterior aspect of the left forearm has an oval contusion measuring 2 x 2-inches. The posterior lateral aspect of the right thigh has multiple, grouped, oval contusions ranging from ¼-inch to ½-inch in maximum dimension. Anterior aspect of the left leg has an oval contusion measuring 2 x 2-inches. There is subcutaneous and intramuscular hemorrhage to the anterior aspect of the right arm (6 x 2-inches), to the posterior aspect of the right upper arm (5 x 2-inches), to the distal lateral aspect of the right thigh (3 x 2-inches), to the posterior lateral aspect of the right thigh (8 x 2-inches), to the posterior lateral aspect of the left thigh (3 x 1-1/2-inches) and to the proximal anterior aspect of the left leg (2 x 2-inches).

INTERNAL EXAMINATION

BODY CAVITIES:
Injuries are described in "Evidence of Injury." The organs occupy their usual anatomic positions. The subcutaneous fat layer of the abdominal wall is unremarkable.

ACLU Detainee DeathII ARMY MEDCOM 982

HEAD AND CENTRAL NERVOUS SYSTEM:
Injuries are described above in "Evidence of Injury." There are no skull fractures. The dura mater is intact with no evidence of hemorrhage. The leptomeninges are thin and delicate. Cloudy light red cerebrospinal fluid surrounds the 1530 gram brain, which is softening and friable. The gyri and sulci are unremarkable. The cerebral hemispheres are symmetrical and the structures at the base of the brain, including the cranial nerves and blood vessels are intact. Coronal sections demonstrate sharp demarcation between white and gray matter, without hemorrhage or contusive injury. The ventricles are of normal size. The basal ganglia, brainstem, and cerebellum are free of injury or other abnormalities. The atlanto-occipital joint is stable.

NECK:
Injuries are described above in "Evidence of Injury." The thyroid cartilage and hyoid bone are intact. The larynx is lined by intact white mucosa. The thyroid gland is symmetric, without cystic or nodular change. Incision and dissection of the posterior neck demonstrates no deep paracervical muscular injury and no cervical spine fractures.

RESPIRATORY SYSTEM:
The airways are clear of debris and foreign material and the mucosal surfaces are smooth, yellow-tan, and unremarkable. The right and left lungs weigh 530 and 560 grams, respectively. The external surfaces are smooth. No mass lesions or areas of consolidation are present. The pulmonary arteries are normally developed and patent. The diaphragm is intact.

CARDIOVASCULAR SYSTEM:
Injuries are described above in "Evidence of Injury." The 390 gram heart is contained in an intact pericardial sac. The epicardial surface is smooth, with minimal fat investment. The coronary arteries are present in a normal distribution, with a right-dominant pattern. Cross sections of the vessels show no stenosis. Where uninjured the myocardium is homogenous, red-brown, and firm. The valve leaflets are thin and mobile. The walls of the left ventricle, interventricular septum, and right ventricle are 1.1, 1.1, and 0.3-centimeters thick, respectively. The endocardium is smooth and glistening. The aorta gives rise to three intact and patent arch vessels. The renal, mesenteric, and iliac vessels as well as the venae cavae are unremarkable.

HEPATOBILIARY SYSTEM:
The 1530 gram liver has an intact, smooth capsule and a sharp anterior border. The parenchyma is tan-brown and congested, with the usual lobular architecture. No mass lesions or other abnormalities are seen. The gallbladder contains 10 milliliters of green-black bile and no stones. The mucosal surface is green and velvety. The extrahepatic biliary tree is patent.

LYMPHORETICULAR SYSTEM:
The 200 gram spleen has a smooth, intact, red-purple capsule. The parenchyma is friable, maroon and congested, with indistinct Malpighian corpuscles. Lymph nodes in the hilar, periaortic, and iliac regions are unremarkable.

ACLU Detainee DeathII ARMY MEDCOM 983

ENDOCRINE SYSTEM:
The pituitary gland is unremarkable. The thyroid gland has been described (see NECK, above). The right and left adrenal glands are symmetric, with bright yellow cortices and red-brown medullae. No masses or areas of hemorrhage are identified.

GENITOURINARY SYSTEM:
The right and left kidneys weigh 120 and 90 grams, respectively. The external surfaces are intact and smooth. The cut surfaces are pale tan with uniformly thick cortices and sharp corticomedullary junctions. The pelves are unremarkable and the ureters are normal in course and caliber. White bladder mucosa overlies an intact bladder wall. The bladder contains approximately 120 milliliters of clear yellow urine. The prostate is normal in size, with lobular, yellow-tan parenchyma. The seminal vesicles are unremarkable. The testes are free of mass lesions, contusions, or other abnormalities.

GASTROINTESTINAL TRACT:
The esophagus is intact and lined by smooth, gray-white mucosa. The stomach contains approximately 350 milliliters of tan-brown partially digested food particles and viscous fluid. The gastric wall is intact. The duodenum, loops of small bowel, and colon are unremarkable. The pancreas is firm and yellow-tan, with the usual lobular architecture. No mass lesions or other abnormalities are seen. The appendix is present.

MUSCULOSKELETAL:
No non-traumatic abnormalities of the muscles or bones of the appendicular and axial skeletons are identified.

ADDITIONAL PROCEDURES

1. Documentary photographs are taken by OAFME staff photographer.
2. Personal effects are released to the appropriate mortuary operations representatives.
3. Specimens retained for toxicology testing and/or DNA identification are: vitreous, blood, bile, urine, gastric contents, brain, myocardium, lung, liver, spleen, kidney, adipose tissue and psoas muscle.
4. The dissected organs are forwarded with body.

MICROSCOPIC EXAMINATION

Selected portions of organs are retained in formalin with the following tissue submitted for histological evaluation:

Slides 1, 2, and 5: Heart: Decomposition changes and possible extravascular red blood cells
Slide 3: Bladder: No significant pathologic change
Slide 4: Thyroid: Decomposition changes and possible extravascular red blood cells in the surrounding soft tissue

ACLU Detainee DeathII ARMY MEDCOM 984

FINAL AUTOPSY DIAGNOSES:

I. Blunt force injuries:
   A. Injuries to the head and neck
      1. Multiple contusions and abraded contusions of the face.
      2. Intramuscular hemorrhage of the anterior neck musculature.
      3. Soft tissue hemorrhage surrounding the right greater horn of the thyroid cartilage
      4. Hemorrhage of the right thyroid gland.
   B. Injuries to the torso:
      1. Multiple contusions to the chest and back
      2. Multifocal areas of marked intramusculature hemorrhage of the back
      3. Multiple rib fractures
      4. Posterior mediastinal hemorrhage
      5. Contusion of the heart
      6. Perithoracic vertebral hemorrhage
      7. Subdural hematoma of the thoracic spinal cord
      8. Intraparenchymal hemorrhage of the thoracic spinal cord
      9. Fractures of the lumbar transverse processes
      10. Bilateral hemothoraces
      11. Retroperintoneal hemorrhage
      12. Hemoperitoneum
   C. Injuries to the extremities:
      1. Contusions of all four extremities
      2. Marked intramusculature hemorrhage of the right upper, right lower and left lower extremities.

II. Evidence of medical therapy: As noted above

III. Post-mortem changes: As noted above

IV. Identifying marks: None identified

V. Natural disease and pre-existing conditions: None identified within the limitations of the examination

VI. Toxicology:
   A. Volatiles (Vitreous fluid): No ethanol detected
   B. Screened drugs of abuse and screened medications (Urine): None detected
   C. Carbon monoxide (Blood): Less than 1%
   D. Cyanide (Blood): None detected

ACLU Detainee DeathII ARMY MEDCOM 985

OPINION

This 39-year-old detainee (b)(6) died from strangulation complicated by multiple blunt force injuries. The decedent showed evidence of strangulation and additional blunt force injuries of the head, torso and all extremities contributing to death. Toxicology analyses are negative for ethanol, screened medications and screened drugs of abuse. The manner of death is homicide.

(b)(6)

(b)(6) Medical Examiner

(b)(6)

(b)(6) Medical Examiner

ACLU Detainee DeathII ARMY MEDCOM 986

CERTIFICATE OF DEATH *(OVERSEAS)*
Acte de décès (D'Outre-Mer)

NAME OF DECEASED *(Last, First, Middle)* Nom du décédé (Nom et prénoms)	GRADE Grade	BRANCH OF SERVICE Arme	SOCIAL SECURITY NUMBER Numéro de l'Assurance Social
BTB Kazim, Husayn Uwayyid, Husayn		Civilian	(b)(6)

ORGANIZATION Organisation	NATION *(e.g. United States)* Pays	DATE OF BIRTH Date de naissance	SEX Sexe
	Iraq		[X] MALE [ ] FEMALE

RACE Race		MARITAL STATUS État Civil			RELIGION Culte		
[X]	CAUCASOID Caucasique	[ ]	SINGLE Célibataire	[ ] DIVORCED Divorcé	[ ]	PROTESTANT Protestant	[X] OTHER (Specify) Autre (Spécifier)
[ ]	NEGROID Negroide	[ ]	MARRIED Marié	[ ] SEPARATED Séparé	[ ]	CATHOLIC Catholique	
[ ]	OTHER (Specify) Autre (Spécifier)	[ ]	WIDOWED Veuf		[ ]	JEWISH Juif	

NAME OF NEXT OF KIN Nom du plus proche parent	RELATIONSHIP TO DECEASED Parenté du décédé avec le sus
STREET ADDRESS Domicilié à (Rue)	CITY OR TOWN OR STATE *(Include ZIP Code)* Ville (Code postal compris)

MEDICAL STATEMENT Déclaration médicale

CAUSE OF DEATH (Enter only one cause per line) Cause du décès (N'indiquer qu'une cause par ligne)			INTERVAL BETWEEN ONSET AND DEATH Intervalle entre l'attaque et le décès
DISEASE OR CONDITON DIRECTLY LEADING TO DEATH [1] Maladie ou condition directement responsable de la mort		Strangulation complicated by blunt force injuries	
ANTECEDENT CAUSES Symptômes précurseurs de la mort	MORBID CONDITION, IF ANY, LEADING TO PRIMARY CAUSE Condition morbide, s'il y a lieu, menant à la cause primaire		
	UNDERLYING CAUSE, IF ANY, GIVING RISE TO PRIMARY CAUSE Condition morbide, s'il y a lieu, menant à la cause primaire		
OTHER SIGNIFICANT CONDITIONS [2] Autres conditions significatives [2]			

MODE OF DEATH Condition de décès	AUTOPSY PERFORMED Autopsie effectuée [X] YES Oui [ ] NO Non	CIRCUMSTANCES SURROUNDING DEATH DUE TO EXTERNAL CAUSES Circonstances de la mort suscitées par des causes extérieures
[ ] NATURAL Mort naturelle	MAJOR FINDINGS OF AUTOPSY Conclusions principales de l'autopsie	
[ ] ACCIDENT Mort accidentelle		
[ ] SUICIDE Suicide	NAME OF PATHOLOGIST Nom du pathologiste (b)(6)	
[X] HOMICIDE Homicide	SIGNATURE (b)(6) DATE Date 7 July 2008	AVIATION ACCIDENT Accident à Avion [ ] YES Oui [X] NO Non

DATE OF DEATH *(day, month, year)* Date de décès (le jour, le mois, l'année)	PLACE OF DEATH Lieu de décès
(b)(6) 2008	Iraq

I HAVE VIEWED THE REMAINS OF THE DECEASED AND DEATH OCCURRED AT THE TIME INDICATED AND FROM THE CAUSES AS STATED ABOVE.
J'ai examiné les restes mortels du dé funtet je conclus que le décès est survenu à l'heure indiquée et à, la suite des causes énumérées ci-dessus.

NAME OF MEDICAL OFFICER Nom du médicin militaire ou du médicin sanitaire	TITLE OR DEGREE Titre ou diplôme
(b)(6)	Medical Examiner

GRADE Grade	INSTALLATION OR ADDRESS Installation ou adresse
(b)(6)	Dover AFB, Dover DE
DATE Date 9/3/2008	SIGNATURE (b)(6)

[1] State disease, injury or complication which caused death, but not mode of dying, such as heart failure, ect.
[2] State conditions contributing to the death, but not related to the disease or condition causing death.
[1] Préciser la nature de la maladie, de la blessure ou de la complication qui a contribué à la mort, mais non la manière de mourir, telle qu 'un arrêt du coeur, etc
[2] Préciser la condition qui a contribué à la mort, mais n'ayant aucun rapport avec la maladie ou à la condition qui a provoqué la mort.

DD FORM 1 APR 77 2064 REPLACES DA FORM 3565, 1 JAN 72 AND DA FORM 3565-R(PAS), 26 SEP 78, WHICH ARE OBSOLETE.

MEDCOM 0987

ACLU Detainee DeathII ARMY MEDCOM 987

ARMED FORCES INSTITUTE OF PATHOLOGY
Office of the Armed Forces Medical Examiner
1413 Research Blvd., Bldg. 102
Rockville, MD 20850
1-301-319-0000

AUTOPSY EXAMINATION REPORT

Name: BTB Ali, Muhammad Najib Abu-Wafa
SSAN: (b)(6)
Age: Approximately 52 years old
Date of Death: (b)(6) 2008
Date/Time of Autopsy: 05 SEP 2008/0930
Date of Report: 19 NOV 2008

Autopsy No.: (b)(6)
AFIP No.: (b)(6)
Rank: Civilian Detainee
Place of Death: Iraq
Place of Autopsy: Port Mortuary
Dover AFB, Dover, DE

Circumstances of Death: This approximately 52-year-old civilian male detainee was housed at Camp Bucca, Iraq. Available investigative reports indicate that (b)(6) collapsed to the concrete floor of his tent as reported by fellow detainees. Emergency medical personnel responded and reported that (b)(6) related to them that he had fallen. Despite aggressive medical intervention (b)(6) succumbed to his injuries.

Authorization for Autopsy: Armed Forces Medical Examiner, per 10 U.S. Code 1471

Identification: Presumptive identification by accompanying reports, identification tags and documentation. A postmortem dental examination, postmortem fingerprint examination, and a postmortem DNA sample are taken for profile purposes should examplars become available for positive identification.

CAUSE OF DEATH: Blunt force trauma of the head

MANNER OF DEATH: Accident

ACLU Detainee DeathII ARMY MEDCOM 988

EXTERNAL EXAMINATION

Injuries will be described in detail in a separate section, and will only be briefly alluded to in the remainder of the report, for purposes of orientation and completeness. The body is that of a well-developed, well-nourished appearing, adult male. The body is received unclothed. The decedent is wrapped in a multiple layers of cloth sheets and absorbent pads. The remains are 69-inches in length, and weigh 151-pounds. Lividity is present and fixed on the posterior surface of the body except in areas exposed to pressure. Rigor is present to an equal degree in all extremities. The temperature of the body is that of the refrigeration unit.

The head is normocephalic. The right occipital scalp is covered with curly black and white hair, the remainder of the scalp is shaved. Facial hair consists of a gray and white beard and mustache. The irides are brown. The corneae are hazy. The pupils are round and equal in diameter. The sclerae are muddy and without petechial hemorrhage. The external auditory canals, external nares, and oral cavity are free of foreign material and abnormal secretions. The ears are on remarkable. The nares are patent and the lips are atraumatic. The upper and lower frenula in the oral cavity are intact. The nasal skeleton and maxillae are palpably intact. The teeth appear natural and in fair condition. The neck is straight, and the trachea is midline and mobile.

The chest is symmetric. The abdomen is flat. The genitalia are those of a normal adult circumcised male. The testes are descended and free of masses. Pubic hair is present in a normal male distribution. The buttocks and anus are unremarkable.

The upper and lower extremities are symmetric and without clubbing or edema. There is amputation of the distal tips of the 1st and 2nd digits of the left hand. The fingernails are intact and the nail beds are cyanotic. There is hyperkeratosis of the heels of both feet.

Identifying marks include multiple scars:

- A 2 1/2 x 1/8-inch well healed hypopigmented scar on the right lower quadrant of the abdomen
- A well healed 4 x 1 1/2-inch scar is on the left upper chest with absence of the left nipple
- A 4 x 1/2-inch vertically oriented hypopigmented scar in the midline of the lower abdomen

CLOTHING AND PERSONAL EFFECTS

No clothing items or personal effects accompany the body at the time of autopsy.

ACLU Detainee DeathII ARMY MEDCOM 989

MEDICAL INTERVENTION

- A gauze dressing, secured beneath the chin, covers the calvarium and the eyes
- On the left frontal, parietal, and temporal scalp is an 11 1/4-inch curvilinear stapled surgical incision
- A drain exiting from the left occipital scalp contains 25-milliliters of red tinged fluid
- A ventriculostomy tube exits the right parietal scalp
- Angiocatheter in the right subclavian space
- Urinary bladder catheter
- Rectal temperature probe
- Intravenous catheters in the right antecubital fossa, right volar wrist, volar left forearm, and dorsal right foot
- A clear plastic identification tag in circles the right wrist. (b)(6)
- Plastic identification tag in circles the left wrist, (b)(6) (b)(6)
- Multiple therapeutic needle puncture sites on the forehead, abdomen, left upper chest, and both ankles
- Gauze bandage on medial left ankle

RADIOGRAPHS

A complete set of postmortem radiographs is obtained and demonstrates the following:

- Medical interventions as listed above
- Healed fracture of the left ulnar styloid
- Bone flap removed from the left fronto-temporal calvarium
- Midline shift brain to the right
- Edema of the left hemisphere with effacement of the left lateral ventricle
- Dilated right lateral ventricle posteriorly, blood in poster warned
- Blood collection in both frontal lobes, anterior horns bilaterally
- Subdural hemorrhage involving the frontal lobes, right greater than left
- Linear skull fracture of the right occiput
- Bilateral pleural effusions and patchy consolidation of the lungs
- No internal metallic fragments

EVIDENCE OF INJURY

The ordering of the following injuries is for descriptive purposes only, and is not intended to imply order of infliction or relative severity.

There is an irregular linear fracture of the posterior aspect of the petrous portion of the right temporal bone extending anteriorly into the right middle cranial fossa and posteriorly into the right posterior cranial fossa and posterior right parietal bone. On the posterior right shoulder are multiple vertically oriented fine superficial linear abrasions measuring up to 2 1/2-inches length. Additional autopsy findings pertaining to the head are described in " Evidence Of Medical Intervention and/or Internal Examination-Head And Central Nervous System ".

ACLU Detainee DeathII ARMY MEDCOM 990

Evidence of Injury (Cont):
Incision and dissection of the posterior neck, subcutaneous tissues of the torso and extremities, demonstrates no deep paracervical muscular injury, no cervical spine fractures, or evidence of blunt force trauma.

INTERNAL EXAMINATION

BODY CAVITIES:
The body is opened by the usual thoraco-abdominal incision and the chest plate is removed. The ribs, sternum, and vertebral bodies are visibly and palpably intact. No adhesions are present in the pleural, pericardial, or peritoneal cavities. There are bilateral pleural effusions (right-275-milliliters, left-175-milliliters). There are 450-milliliters of straw colored fluid in the peritoneal cavity. All body organs are present in their normal anatomic positions. There is no internal evidence of blunt force or penetrating injury to the thoraco-abdominal region.

The subcutaneous fat layer of the abdominal is 3/4-inches thick.

HEAD AND CENTRAL NERVOUS SYSTEM:
(See above "Evidence of Injury")
The scalp is reflected. Subgaleal hemorrhage is associated with the underlying fractures and medical intervention. There is a non-quantifiable subdural hemorrhage in the right anterior cranial fossa. The therapeutic medical devices are documented and removed. The 1480-gram brain and dura are removed and placed in formalin for formal Neuropathology consultation.

Formal Neuropathology Consultation:

GROSS DESCRIPTION:

Brain weight: 1,401 grams

The specimen consists of the intracranial dura and brain of an adult.
A recent craniectomy has resulted in the absence of the posterior-lateral frontal, lateral parietal/superior-lateral temporal and anterior-lateral occipital portion of the left cerebral dura. The dorsal margin of the dural defect consists of a row of tapered dural tabs with attached black sutures. The right convexity dura and the falx cerebri are intact. The paramedian dural arachnoid granulations are red-black due to accumulated acute subarachnoid blood. Scattered strands of red-black, coagulated blood up to 0.3-centimeters thick and 2-centimeters in greatest diameter adhere loosely to the inner surface of the right and left paramedian dura, the left surface of the falx cerebri, or lie loosely on the arachnoid surface of each paramedian cerebral hemisphere. The venous sinuses are patent.

A moderately deep craniectomy groove indents the left cerebral surface, outlining an elevated (herniated) oval area approximately 9 (anterior-posterior) by 6 (dorsal-ventral) centimeters involving the lateral parietal, lateral anterior two-thirds occipital and

ACLU Detainee DeathII ARMY MEDCOM 991

superior temporal lobes. A ventriculostomy tube has been inserted into left dorsal mid frontal lobe approximately 3 centimeters from the medial margin.

Red-brown cortical contusions characterized by cortical hemorrhages, cortical necrosis, leptomeningeal and cortical laceration and cortical and subcortical hematomas (up to 2.5 centimeters in greatest dimension) are situated in: anterior portion of the left inferior temporal gyrus, the anterior portion of the left superior temporal gyrus, the posterior portion of left superior temporal gyrus, the left lateral parietal lobe. Clusters of similar contusions are also present over the left inferior temporal pole (4 x 3 centimeter), the left inferior frontal pole (4 x 4 centimeter), the right inferior frontal pole (3 x 3.5 centimeter) and the right inferior temporal pole (2.5 x 2 centimeters).

There is a thin red-brown subarachnoid hemorrhage over the base of the pons and the left cerebellar peduncle. A thin, horizontal rim of similar subarachnoid hemorrhage (probably gravitational) is present over the posterior margins of the right and left cerebellar hemispheres.

Except as noted, the leptomeninges are thin, delicate and transparent. The cerebral gyri are soft, white and flattened due to swelling but have an anatomically normal configuration. The perisellar, perimesencephalic and basal cisterns are completely effaced due to brain swelling. Deep tentorial grooves indent each uncus, 0.8 centimeters on the left and 0.5 centimeters on the right. The left groove is continuous with a left parahippocampal groove. The brainstem is displaced rightward with subsequent flattening of the right surface of the midbrain. The cerebellar tonsils are deformed due to pressure against the foramen magnum.

The arteries at the base of the brain follow a normal distribution and there are no aneurysmal dilatations or sites of occlusion.

Coronal sections of the cerebrum reveal the above noted abnormalities.

In addition, there is a swollen left cerebral hemisphere with a sharply demarcated zone of softness, gray-white discoloration and blurring of the grey matter/white matter margins due to ischemic necrosis in the entire distribution of the left middle cerebral artery. There is a prominent rightward shift of the cerebral hemispheres with rightward bowing of the interhemispheric fissure and subfalcine herniation of the right cingulate gyrus. The ventriculostomy tube perforates the left frontal lobe in a ventral-medial direction and perforates the midline corpus callosum where there is interventricular hemorrhage and an approximately 3 centimeter in diameter left medial thalamic hematoma.

The ventricular system is disrupted at the above noted ventriculostomy perforation in the corpus callosum. The bodies of the lateral ventricles are not enlarged. The occipital horn of the right lateral ventricle is larger than the left (2.5 centimeter in diameter vs 0.5 centimeter) reflecting some degree of proximal obstruction. The Aqueduct of Sylvius is

ACLU Detainee DeathII ARMY MEDCOM 992

Neuropathology Consultaion (Cont):
patent with a normal size and configuration. The choroid plexus is unremarkable and the ependymal surfaces are smooth and glistening.

MICROSCOPIC EXAMINATION:

Blocks of tissue for microscopic examination are removed from: (1) left lateral frontal lobe, (2) anterior corpus callosum, (3) left medial striate body, (4) left uncus, (5) left thalamus, (6) right hippocampus, (7) left occipital lobe, (8) right occipital lobe, (9) caudal midbrain, (10) medulla, (11) left cerebellum and (12) dura.
Sections from blocks 1-12 are stained with H & E. Sections 1-11 are also stained with Bielschowsky and LFB techniques and immunostained for β-APP, GFAP and β-amyloid.

COMMENT:

There is widespread grey and white matter edema and scattered acute ischemic neuronal injury (" red neurons ") in sections of the left cerebrum (blocks 1, 2, 4 & 7) consistent with acute infarction which is probably related to the left trans craniectomy herniation. The acute hemorrhage of the left striate body and the adjacent corpus callosum and pooled blood in the occipital horn of the right lateral ventricle are related to the penetration of the ventriculostomy tube. The array of cortical contusions along the margin of the craniectomy defect is due to the pressure of the brain against the bone margin resulting from the underlying brain swelling. The left uncal necrosis resulted from the left cerebral swelling -> left to right midline shift -> left cingulate gyrus herniation -> left transtentorial uncal.

The remaining lesions appear to be primarily due to trauma. Based on the described fractures, the impact occurred on the right side of the head (temporal/parietal) which would initiate lateral rotation acceleration whether due to a blow or a fall. The bilateral, paramedian subdural hematoma is consistent with this. The bilateral frontal and temporal cortical contusions and subcortical hemorrhages and the cerebral swelling are more severe on the left than the right making injury more suggestive of a fall then a blow.

It would be helpful if we could say pre-therapeutic images of this patient to more clearly separate the primary effects of the trauma from the secondary and therapeutic effects.

NECK:
The anterior strap muscles of the neck are homogeneous and red-brown, without hemorrhage. The thyroid cartilage and hyoid bone are intact. The larynx is lined by intact white mucosa. The tongue is free of bite marks, hemorrhage, or other injuries.

Incision and dissection of the posterior neck demonstrates no deep paracervical muscular injury or cervical spine fractures.

ACLU Detainee DeathII ARMY MEDCOM 993

RESPIRATORY SYSTEM:
The upper airway is clear of debris and foreign material; the mucosal surfaces are smooth, yellow-tan and unremarkable. The pleural surfaces of the right lung are smooth, glistening and unremarkable. There are scattered loose pleural adhesions surrounding the left lung. The pulmonary parenchyma is salmon pink with anthracotic changes, congested and edematous, exuding copious amounts of blood and frothy fluid. No mass lesions or areas of consolidation are present. The right and left lungs weigh 780 and 760-grams, respectively.

CARDIOVASCULAR SYSTEM:
The pericardial surfaces are smooth, glistening and unremarkable. The 320-gram heart is contained in an intact pericardial sac free of significant fluid or adhesions. The epicardial surface is smooth, with minimal fat investment. The coronary arteries arise normally, follow the usual distribution in a right dominant pattern, are widely patent, and without evidence of thrombosis or significant atherosclerosis. The myocardium is homogeneous, red-brown, firm and unremarkable; the atrial and ventricular septae are intact. The walls of the left and right ventricles are 1.0 and 0.2-centimeters thick, respectively. The valve leaflets are thin and mobile. The aorta and its major branches arise normally, follow the usual course and are free of significant abnormalities. There is mild focal atherosclerotic streaking of the abdominal aorta. The venae cavae and their major tributaries return to the heart in the usual distribution and are free of thrombi. The renal and mesenteric vessels are unremarkable.

HEPATOBILIARY SYSTEM:
The hepatic capsule is smooth, glistening and intact, covering dark red-brown, moderately congested parenchyma. No mass lesions or other abnormalities are noted. The gallbladder contains 3-milliliters of green-brown mucoid bile; the mucosa is velvety and unremarkable. The extrahepatic biliary tree is patent and without evidence of calculi. The liver weighs 1460-grams.

GASTROINTESTINAL TRACT:
The esophagus is intact and lined by smooth, gray-white mucosa. The gastric wall is intact and the stomach contains approximately 20-milliliters of thin brown-gray fluid. The gastric mucosa is arranged in the usual rugal folds. The duodenum, loops of small bowel and colon are unremarkable. The appendix is not identified. Synthetic mesh is identified in the right inguinal canal.

GENITOURINARY SYSTEM:
The right and left kidneys weigh 160 and 140-grams, respectively. The renal capsules are smooth and thin, semi-transparent and strip with ease from the underlying smooth, red-brown cortical surface. The cut surfaces are red-tan and congested, with uniformly thick cortices and sharp corticomedullary junctions. The pelves and calyces are unremarkable.

ACLU Detainee DeathII ARMY MEDCOM 994

Genitourinary System (cont):
The ureters are normal in course and caliber. White bladder mucosa overlies an intact bladder wall. The bladder contains approximately 100-milliliters of cloudy yellow urine. The prostate is normal in size, with lobular, yellow-tan parenchyma. The seminal vesicles are unremarkable. The testes are free of mass lesions, contusions, or other abnormalities.

LYMPHORETICULAR SYSTEM:
The 280-gram spleen has a smooth, intact capsule covering maroon, moderately firm parenchyma; the lymphoid follicles are unremarkable. Lymph nodes in the hilar, periaortic, and iliac regions are not enlarged.

ENDOCRINE SYSTEM:
The pituitary gland is examined in-situ and is unremarkable. The thyroid gland is symmetric and red-brown, without cystic or nodular change. The pancreas is firm and yellow-tan, with the usual lobular architecture. No mass lesions or other abnormalities are noted. The right and left adrenal glands are symmetric, with bright yellow cortices and grey medullae. No masses or areas of hemorrhage identified.

MUSCULOSKELETAL SYSTEM:
Muscle development appears normal. No non-traumatic bone or joint abnormalities are noted.

ADDITIONAL PROCEDURES

1. Documentary photographs are taken by OAFME staff photographers.
2. Specimens retained for toxicology testing and/or DNA identification are: Blood, vitreous fluid, urine, gastric contents, bile, heart, spleen, liver, lung, kidney, adipose tissue, and skeletal muscle.
3. Full body radiographs are obtained and demonstrate the above findings.
4. Selected portions of organs are retained in formalin.
5. The dissected organs are forwarded with the body.
6. Personal effects are released to the mortuary affairs representatives.
7. Identifying body marks that include multiple scars have been documented.

MICROSCOPIC EXAMINATION

The brain is removed and placed in formalin for formal Neuropathology consultation. Selected portions of organs are retained in formalin, without preparation of histologic slides by OAFME.

ACLU Detainee DeathII ARMY MEDCOM 995

FINAL AUTOPSY DIAGNOSES:

I. Evidence of trauma
   A. Linear fractures of the calvarium involving the right temporal, parietal, and occipital bones
   B. Superficial abrasions on the posterior right shoulder
   C. Subgaleal and subdural hemorrhage

II. Evidence of closed head trauma and subsequent medical intervention (per formal Neuropathology consultation)
   A. Diffuse grey and white matter edema with ischemic neuronal injury
   B. Left transcraniectomy herniation
   C. Left to right midline shift with left cingulate gyrus and the left transtentorial uncal herniations
   D. Cortical contusions of the frontal and temporal lobes, bilaterally
   E. Subarachnoid and intraventricular hemorrhage

III. Natural disease diagnoses
   A. Evidence of prior appendectomy
   B. Evidence of prior right inguinal hernia repair
   C. Mild atherosclerotic streaking of the abdominal aorta
   D. Healed fracture of the left ulnar styloid
   E. Partial amputation of the distal 1st and 2nd digits of the left hand
   F. Absence of the left nipple, traumatic, healed

IV. Postmortem changes
   A. Lividity is fixed on the posterior surface the body except in areas exposed pressure
   B. Rigor is present to an equal degree in all extremities

VI. Toxicology results
   A. Volatiles: The blood and vitreous fluid were examined for the presence of ethanol at a cutoff of 20 mg/dL. No ethanol was detected.
   B. Drugs: The urine was screened for acetaminophen, amphetamine, antidepressants, antihistamines, barbiturates, benzodiazepines, cannabinoids, chloroquine, cocaine, dextromethorphan, lidocaine, narcotic analgesics, opiates, phencyclidine, phenothiazines, salicylates, sympathomimetic amines, and verapamil by gas chromatography, color test or immunoassay. The following drugs were detected:
   1. Positive Opiate: Morphine was detected in urine by gas chromatography/mass spectrometry. The blood contained in 0.18 mg/L of morphine as quantitated by gas chromatography/mass spectrometry.
   2. Positive Lidocaine: Lidocaine was detected in urine by gas chromatography and confirmed by gas chromatography/mass spectrometry.

ACLU Detainee DeathII ARMY MEDCOM 996

VI. Toxicology results (cont):

C. Carbon Monoxide: The carboxyhemoglobin saturation in the blood was less than 1% as determined by spectrophotometry with the limit of quantitation of 1%. Carboxyhemoglobin saturations of 0-3% are expected for non-smokers. Saturations above 10% are considered elevated are confirmed by gas chromatography.

D. Cyanide: There was no cyanide detected in the blood. The limit of quantitation for cyanide is 0.25 mg/dL. Normal blood cyanide concentrations are less than 0.15 mg/L. Lethal concentrations of cyanide are greater than 3 mg/L.

OPINION

This approximately 52-year-old male detainee at Camp Bucca Iraq, BTB (b)(6) (b)(6) died as the result of blunt force trauma of the head. Autopsy findings show evidence of skull fractures and subsequent medical intervention. No gross or x-ray evidence of recent penetrating or additional significant blunt force trauma is identified. A formal Neuropathology consultation is obtained and demonstrates the findings described above. Post mortem analysis of the body fluids for ethanol, carbon monoxide, cyanide, and screened illicit drugs of abuse are negative. The presence of morphine in the blood and lidocaine in the urine are consistent with the reported history of medical intervention and do not contribute to the cause or manner of death. (b)(6) injuries are consistent with a blow to the head or a fall. The review of available investigative reports, medical records, and Neuropathology consultation taken in conjunction with the absence of defensive injuries suggests that an accidental fall is more likely the cause of (b)(6) injuries. A blow to the head cannot be ruled out as the cause of the closed head trauma. However, with reasonable medical certainty the manner of death is best classified as accident. Should additional information become available that would change the cause or manner of death, an amended report will be issued.

(b)(6)

(b)(6) Medical Examiner

ACLU Detainee DeathII ARMY MEDCOM 997

CERTIFICATE OF DEATH *(OVERSEAS)*
Acte de décès (D'Outre-Mer)

NAME OF DECEASED *(Last, First, Middle)* Nom du décédé (Nom et prénoms)	GRADE Grade	BRANCH OF SERVICE Arme	SOCIAL SECURITY NUMBER Numéro de l'Assurance Social
BTB Ali, Muhammad Najib, Abu-Wafa		Civilian	(b)(6)

ORGANIZATION Organisation	NATION *(e.g. United States)* Pays	DATE OF BIRTH Date de naissance	SEX Sexe
	Egypt		[X] MALE [ ] FEMALE

RACE Race		MARITAL STATUS État Civil			RELIGION Culte		
[X]	CAUCASOID Caucasique		SINGLE Célibataire		DIVORCED Divorcé		PROTESTANT Protestant		OTHER (Specify) Autre (Spécifier)
[ ]	NEGROID Negroide		MARRIED Marié		SEPARATED Séparé		CATHOLIC Catholique	[X]	Muslim
[ ]	OTHER (Specify) Autre (Spécifier)		WIDOWED Veuf				JEWISH Juif		

NAME OF NEXT OF KIN Nom du plus proche parent	RELATIONSHIP TO DECEASED Parenté du décédé avec le sus
STREET ADDRESS Domicilié à (Rue)	CITY OR TOWN OR STATE *(Include ZIP Code)* Ville (Code postal compris)

MEDICAL STATEMENT Déclaration médicale

	CAUSE OF DEATH (Enter only one cause per line) Cause du décès (N'indiquer qu'une cause par ligne)	INTERVAL BETWEEN ONSET AND DEATH Intervalle entre l'attaque et le décès
DISEASE OR CONDITON DIRECTLY LEADING TO DEATH [1] Maladie ou condition directement responsable de la mort [1]	Blunt force injury of the head	Hours
ANTECEDENT CAUSES Symptômes précurseurs de la mort. MORBID CONDITION, IF ANY, LEADING TO PRIMARY CAUSE Condition morbide, s'il y a lieu, menant à la cause primaire		
UNDERLYING CAUSE, IF ANY, GIVING RISE TO PRIMARY CAUSE Condition morbide, s'il y a lieu, menant à la cause primaire		
OTHER SIGNIFICANT CONDITIONS [2] Autres conditions significatives [2]		

MODE OF DEATH Condition de décès	AUTOPSY PERFORMED Autopsie effectuée [X] YES Oui [ ] NO Non	CIRCUMSTANCES SURROUNDING DEATH DUE TO EXTERNAL CAUSES Circonstances de la mort suscitées par des causes extérieures
[ ] NATURAL Mort naturelle	MAJOR FINDINGS OF AUTOPSY Conclusions principales de l'autopsie	
[X] ACCIDENT Mort accidentelle		
[ ] SUICIDE Suicide	NAME OF PATHOLOGIST Nom du pathologiste (b)(6)	
[ ] HOMICIDE Homicide	SIGNATURE (b)(6) DATE Date 5 September 2008	AVIATION ACCIDENT Accident à Avion [ ] YES Oui [X] NO Non

DATE OF DEATH *(day, month, year)* Date de décès (le jour, le mois, l'année)	PLACE OF DEATH Lieu de décès
(b)(6) 2008 1537	Balad AFB Iraq

I HAVE VIEWED THE REMAINS OF THE DECEASED AND DEATH OCCURRED AT THE TIME INDICATED AND FROM THE CAUSES AS STATED ABOVE.
J'ai examiné les restes mortels du dé funtet je conclus que le décès est survenu à l'heure indiquée et à. la suite des causes énumérées ci-dessus.

NAME OF MEDICAL OFFICER Nom du médecin militaire ou du médecin employé	TITLE OR DEGREE Titre ou diplômé
(b)(6)	Medical Examiner

GRADE Grade	INSTALLATION OR ADDRESS Installation ou adresse
(b)(6)	Dover AFB, Dover DE
DATE Date 11/25/2008	SIGNATURE (b)(6)

[1] State disease, injury or complication which caused death, but not mode of dying such as heart failure, ect.
[2] State conditions contributing to the death, but not related to the disease or condition causing death.
[1] Préciser la nature de la maladie, de la blessure ou de la complication qui a contribué à la mort, mais non la manière de mourir, telle qu 'un arrêt du coeur, etc.
[2] Préciser la condition qui a contribué à la mort, mais n'ayant aucun rapport avec la maladie ou à la condition qui a provoqué la mort.

DD FORM 1 APR 77 2064 REPLACES DA FORM 3565, 1 JAN 72 AND DA FORM 3565-R(PAS), 26 SEP 75, WHICH ARE OBSOLETE.

MEDCOM 0998

ACLU Detainee DeathII ARMY MEDCOM 998

ARMED FORCES INSTITUTE OF PATHOLOGY
Office of the Armed Forces Medical Examiner
1413 Research Blvd., Bldg. 102
Rockville, MD 20850
301-319-0000

AUTOPSY EXAMINATION REPORT

Name: (BTB) HASHIM, Lo'y Lafta
ISN: (b)(6)
Date of Birth: (BTB) (b)(6) 1983
Date of Death: (b)(6) 2008

Autopsy No.: (b)(6)
AFIP No.: (b)(6)
Rank: Civilian Detainee
Place of Death: Iraq

Date/Time of Autopsy: 22 DEC 2008 @ 0930
Place of Autopsy: Port Mortuary, Dover AFB, DE

Date of Report: 19 FEB 2008

Circumstances of Death: This (BTB) 24-year-old male Iraqi Civilian Detainee was noted by his fellow detainees to have difficulty breathing and then became unresponsive. CPR was initiated immediately, and was escalated to full ACLS protocol upon arrival to the CSH. Resuscitative efforts were to no avail.

Authorization for Autopsy: Armed Forces Medical Examiner, per U.S. Code 10, Section 1471.

Identification: Presumptive identification is established by an identification band on the left wrist. Positive identification is established by comparison of postmortem DNA examination and antemortem DNA records according to ISN.

CAUSE OF DEATH: **ATRIOVENTRICULAR NODAL ARTERY DYSPLASIA**

MANNER OF DEATH: **NATURAL**

ACLU Detainee DeathII ARMY MEDCOM 999

EXTERNAL EXAMINATION

The body is that of a well-developed, well-nourished Caucasoid male received unclad. The body weighs 184-pounds, is 69 ½-inches in length and appears compatible with the reported age of 24-years. The body is cold. Rigor is passing and present to an equal degree in all extremities. Violaceous lividity is present and fixed on the posterior surface of the body, except in areas exposed to pressure. Green discoloration of the skin of the lower right abdomen is noted. The body is unembalmed.

The head is normocephalic, and the scalp hair is dark and approximately 2-inches in length. Facial hair consists of dark beard stubble and a soul patch. The irides are brown, the pupils are round and equal in size, the corneae are cloudy, the conjunctivae are slightly injected, and the sclerae are white. The external auditory canals, external nares and oral cavity are free of foreign material and abnormal secretions. The earlobes are not pierced. The nasal skeleton and maxilla are palpably intact. The lips and oral mucous membranes are without evident injury. The teeth are natural and in good condition. Examination of the neck reveals no evidence of injury; the trachea is palpably in the midline of the neck.

The chest is symmetric with normally formed male breasts that are free of masses. No evidence of injury of the ribs or the sternum is evident externally. The abdomen is flat without recent trauma. Healed surgical scars are not noted on the torso. The external genitalia are those of a normal adult circumcised male. The posterior torso and anus are without note.

The extremities are symmetric and normally formed without evidence of significant recent trauma. The fingernails appear cyanotic and are trimmed and intact. The toenails are unremarkable. (b)(6) (b)(6) tattoos (b)(6) There is an identification bracelet around the left wrist.

CLOTHING AND PERSONAL EFFECTS

The following items accompany the body:

- White undershirt (cut)
- White underpants
- White pants
- Yellow jacket
- Yellow shorts
- White towel
- Two prayer rugs

MEDICAL INTERVENTION

- Endotracheal tube (properly located)
- Cardiac pacing pads on the anterior torso (properly located)
- Electrocardiogram electrodes on the anterior torso
- Intravenous lines inserted in both antecubital fossae

ACLU Detainee DeathII ARMY MEDCOM 1000

- Elastic medical bandages around both wrists
- Pulse-oximetry sensor on the right 2nd digit (forefinger)
- Urinary bladder catheter (properly located) with attached reservoir bag containing 50-millilters of clear yellow urine

RADIOGRAPHS

A complete set of postmortem radiographs and CT images are obtained and demonstrates the following:

- Medical therapy as described above
- No metallic foreign bodies
- No fractures are noted

EVIDENCE OF INJURY

There is no evidence of recent significant injury.

INTERNAL EXAMINATION

BODY CAVITIES:
The body is opened by the usual thoraco-abdominal incision and the chest plate is removed. The ribs, sternum, and vertebral bodies are visibly and palpably intact. No adhesions are present in any of the body cavities. All body organs are present in normal anatomical position. There is clear, straw-colored serous fluid in both pleural cavities (right, 200-milliliters; left, 300-milliliters) as well as the peritoneal cavity (200-milliliters).

The subcutaneous fat layer of the abdominal wall is 1-inch thick at the umbilicus.

HEAD AND CENTRAL NERVOUS SYSTEM:
The scalp is reflected. The galeal and subgaleal soft tissues of the scalp are free of injury. There are no skull fractures. The calvarium of the skull is removed. The dura mater and falx cerebri are intact. There is no epidural, subdural or subarachnoid hemorrhage present. The leptomeninges are thin and delicate. The cerebral hemispheres are symmetrical with an unremarkable pattern of gyri and sulci. The blood vessels at the base of the brain are intact and symmetrical without significant atherosclerosis. The cranial nerves are likewise symmetrical and intact.

The brain weighs 1,440-grams and is fixed prior to further examination and submission for expert consultation.

Coronal sections through the cerebral hemispheres reveal no focal lesions in the cortex, white matter or deep nuclear structures. There is no midline shift. The ventricles of the brain are of normal size and contain clear cerebrospinal fluid. Transverse sections through the brain stem and cerebellum are unremarkable. See Addendum A for complete details.

ACLU Detainee DeathII ARMY MEDCOM 1001

The upper spinal cord as viewed through the foramen magnum is unremarkable. The atlanto-occipital joint is stable.

NECK:
The anterior strap muscles of the neck are homogenous and red-brown, without hemorrhage by layer-wise dissection. The thyroid cartilage and hyoid bone are intact. The larynx is lined by intact pink-white mucosa. The tongue is free of bite marks, hemorrhage, or other injuries.

CARDIOVASCULAR SYSTEM:
The 440-gram heart is contained in an intact pericardial sac. The epicardial surface is smooth, with minimal fat investment. The coronary arteries arise normally and are present in a normal distribution, with a right-dominant pattern. Cross sections of the major coronary arteries demonstrate no luminal narrowing. Trabeculae are noted in the apex of the right ventricle. The heart is fixed prior to further examination and submission for expert consultation.

The foramen ovale is closed. The cardiac chamber dimensions are normal. The myocardium is homogenous and firm without focal softening, discoloration or fibrosis. The valve leaflets are thin and mobile. The walls of the left ventricle, inter-ventricular septum, and right ventricle are 1.4, 1.4, and 0.3-centimeters thick, respectively. The endocardium is smooth and glistening. See Addendum B for complete details.

The aorta has minimal atherosclerosis and gives rise to three intact and patent arch vessels. The renal and mesenteric vessels are unremarkable.

RESPIRATORY SYSTEM:
The upper airway is clear of debris and foreign material: the mucosal surfaces are smooth, pink-tan and unremarkable. The parietal pleural surfaces are smooth, glistening and unremarkable bilaterally.

The right lung weighs 860-grams; the left 720-grams. The pulmonary parenchyma is diffusely congested and edematous, exuding slight to moderate amounts of blood and frothy fluid; no focal lesions are noted. The visceral pleural surfaces are smooth, glistening and unremarkable bilaterally.

The pulmonary arteries are normally developed, patent and without thrombus or embolus.

HEPATOBILIARY SYSTEM:
The 2,220-gram liver has an intact smooth capsule covering congested tan-brown parenchyma with no focal lesions noted.

The gallbladder contains 7-milliliters of green-brown, mucoid bile; the mucosa is velvety and unremarkable. The extrahepatic biliary tree is patent, without evidence of calculi.

GASTROINTESTINAL SYSTEM:
The esophagus is lined by gray-white, smooth mucosa. The gastric mucosa is arranged in the usual rugal folds and the lumen contains 40-milliliters of brown fluid.

ACLU Detainee DeathII ARMY MEDCOM 1002

The small and large bowels are unremarkable. The pancreas has a normal pink-tan lobulated appearance. The appendix is present.

GENITOURINARY SYSTEM:
The right kidney weighs 160-grams; the left 160-grams. The renal capsules are smooth and thin, semi-transparent and strip with ease from the underlying smooth, red-brown cortical surfaces.

The cortices are sharply delineated from the medullary pyramids, which are red-purple to tan and unremarkable. The calyces, pelves and ureters are unremarkable.

White bladder mucosa overlies an intact bladder wall. The bladder is empty of urine. The testes, prostate gland and seminal vesicles are without note.

LYMPHORETICULAR SYSTEM:
The thymus is small, fatty and otherwise unremarkable. The 340-gram spleen has a smooth, intact capsule covering congested, red-purple, moderately firm parenchyma; the lymphoid follicles are unremarkable.

Lymph nodes in the hilar, periaortic and iliac regions are not enlarged. Marked anthracosis is noted in the hilar lymph nodes.

ENDOCRINE SYSTEM:
The pituitary gland is examined *in situ* and is grossly unremarkable. The thyroid gland is symmetric and red-brown, without cystic or nodular change. The parathyroid glands are not identified. The right and left adrenal glands are symmetric, with bright yellow cortices and red-brown medullae; no masses or areas of hemorrhage are identified.

MUSCULOSKELETAL SYSTEM:
Superficial posterior skin incisions are negative for traumatic injuries. No non-traumatic abnormalities of muscle or bone are identified.

MICROSCOPIC EXAMINATION AND SLIDE KEY

Selected portions of organs are retained in formalin, and selected histology slides are prepared.

1. Thyroid (X2):	No pathologic diagnosis.
2. Lymph Node (X2):	Benign calcification and anthracotic pigment.
3. Lung (X3):	Vascular congestion, focal pulmonary edema and anthracosis.
4. Lung (X2):	Vascular congestion, focal pulmonary edema and anthracosis.
5. Adrenal (X2):	Medullary autolysis, otherwise unremarkable.
6. Kidney (X2):	Autolysis of tubule cells, otherwise unremarkable.
7a. Spleen:	No pathologic diagnosis.
7b. Pancreas:	Autolysis.
8. Liver & Gall Bladder:	Vascular congestion and bile stasis of the liver. Autolysis of the gall bladder is noted.

ACLU Detainee DeathII ARMY MEDCOM 1003

TOXICOLOGY

VOLATILES: The blood and urine are examined for the presence of volatile compounds including ethanol at a cutoff of 20-milligrams per deciliter. No ethanol is detected.

DRUGS: The urine is screened for medications and drugs of abuse including acetaminophen, amphetamine, antidepressants, antihistamines, barbiturates, benzodiazepines, cannabinoids, chloroquine, cocaine, dextromethorphan, lidocaine, narcotic analgesics, opiates, phencyclidine, phenothiazines, salicylates, sympathomimetic amines and verapamil by gas chromatography, color test or immunoassay. The following drugs are detected:

Positive Lidocaine: Lidocaine was detected in the urine by gas chromatography and confirmed by gas chromatography/mass spectrometry.

Positive Antihistamine: Diphenhydramine was detected in the urine by gas chromatography and confirmed by gas chromatography/mass spectrometry. No diphenhydramine was detected in the blood at a limit of quantitation of 0.05-milligrams per liter using gas chromatography/mass spectrometry.

CARBON MONOXIDE: The carboxyhemoglobin saturation in the blood was less than 1% as determined by spectrophotometry with a limit of quantitation of 1%.

CYANIDE: There was no cyanide detected in the blood. The limit of quantitation for cyanide is 0.25-milligrams per liter.

ADDITIONAL PROCEDURES

1. Documentary photographs are taken by (b)(6)
2. Autopsy assistance is provided by (b)(6)
3. Personal effects are released to the appropriate mortuary operations representatives.
4. Specimens retained for toxicology testing and/or DNA identification are: vitreous fluid, blood, urine, bile, gastric contents, spleen, liver, lung, kidney, brain, myocardium, adipose tissue and skeletal muscle.
5. The brain and heart are fixed and retained for expert consultation (see Addendums A and B, respectively, below).
6. The dissected organs are forwarded with the unembalmed body.
7. No trace evidence and/or foreign material are collected by OAFME.

FINAL AUTOPSY DIAGNOSES

I. **Autopsy Findings**
   A. General
      1. Serous fluid in body cavities (200-milliliters right pleural, 300-milliliters left pleural, 200-milliliters peritoneal)
      2. Vascular congestion of liver, spleen and both lungs
      3. There is no evidence of physical abuse

ACLU Detainee DeathII ARMY MEDCOM 1004

B. Cardiovascular System
   1. Mild cardiomegaly (440-gram heart, 368-grams expected for body weight)
   2. No coronary arteriosclerosis noted grossly
   3. Trabeculae noted in right ventricular apex
   4. Focal dysplasia of the atrioventricular nodal artery

II. No other significant natural diseases or pre-existing conditions are identified, within the limitations of this examination.

III. Evidence of Medical Therapy
A. Endotracheal tube (properly located)
B. Cardiac pacing pads on the anterior torso (properly located)
C. Electrocardiogram electrodes on the anterior torso
D. Intravenous lines inserted in both antecubital fossae
E. Urinary bladder catheter

IV. Post-Mortem Changes
A. Rigor is passing and equal in all extremities
B. Lividity is posterior and fixed except in areas exposed to pressure
C. The body temperature is cold
D. There is green discoloration of the right lower abdomen

V. Identifying Body Marks (b)(6) **tattoos** (b)(6)

VI. There is no evidence of physical abuse.

VII. Toxicology
A. No ethanol is detected in the blood and urine.
B. No drugs of abuse are detected in the urine.
C. No cyanide is present in the blood.
D. Carboxyhemoglobin saturation in the blood is less than 1%.
E. The following medications are detected in the urine but not the blood:
   1. Lidocaine
   2. Diphenhydramine

ACLU Detainee DeathII ARMY MEDCOM 1005

OPINION

This (BTB) 24-year-old Iraqi civilian detainee (b)(6) died of a cardiac arrhythmia due to focal dysplasia of the atrioventricular nodal artery. This cardiac abnormality cannot be detected by screening tests or by physical examination, and has been implicated as the cause of sudden death. Other diagnoses considered as the cause of death are coronary vasospasm or ion channel disorder, neither of which can be proven microscopically. All other findings at autopsy were non-specific. Toxicological testing for ethanol, screened drugs of abuse, carbon monoxide and cyanide were negative. Lidocaine (a medication used in resuscitation efforts) and diphenhydramine (an over-the-counter antihistamine) were present in the urine only. The manner of death is natural.

(b)(6)

(b)(6) Medical Examiner

ACLU Detainee DeathII ARMY MEDCOM 1006

ADDENDUM A: Neuropathology Consultation Report

ARMED FORCES INSTITUTE OF PATHOLOGY
NEUROPATHOLOGY REPORT
CASE NUMBER: (b)(6)
PATIENT NAME
DATE OF EXAMINATION: 01/08/09

GROSS DESCRIPTION:

Brain weight: 1326 gm

The specimen consists of the brain of an adult.

The leptomeninges are thin, delicate and transparent. The frontal lobe poles have been removed for toxicology studies.

The brain is pale and moderately, diffusely swollen having widened gyri, compressed sulci and partially effaced perisellar, perimesencephalic and cerebellomedullary cisterns. The gyri have an otherwise anatomically normal configuration.

There is no sign of herniation or midline shift. Tentorial grooves are not visible on either uncus. The cerebellar tonsils have a slightly swollen configuration. The external aspects of the brainstem and cerebellum are not remarkable. The arteries at the base of the brain follow a normal distribution and are free of atherosclerosis. There are no aneurysmal dilatations or sites of occlusion. The identifiable cranial nerve roots are not remarkable.

Coronal sections of the cerebrum reveal no focal lesions in the cortex, white matter or deep nuclear structures. There is no midline shift. Sections of the midbrain, pons, medulla and cerebellum show no diffuse or focal abnormalities. The substantia nigra and locus coeruleus are well pigmented.

The ventricular system and aqueduct of Sylvius are patent with a normal size and configuration. The choroid plexus is unremarkable and the ependymal surfaces are smooth and glistening.

PHOTOGRAPHS: yes

MICROSCOPIC EXAMINATION:

Blocks of tissue for microscopic examination are removed from: (1) right lateral frontal lobe, (2) cingulate gyri/anterior corpus callosum, (3) mid right cingulate gyrus/corpus callosum/caudate nucleus/anterior limb of internal capsule, (4) left thalamus/subthalamic nucleus/substantia nigra/posterior limb of the internal capsule, (5) right thalamus/ red nucleus /posterior limb of the internal capsule, (6) right hippocampus, (7) right calcarine cortex/occipital horn of lateral ventricle, (8) right cerebellum, (9) midbrain, (10) pons and (11) medulla.

Sections from each block are stained with H&E, Bielschowsky and LFB techniques and immunostained for β–amyloid precursor protein (β-APP), glial fibrillary acidic protein (GFAP) and β–amyloid.

COMMENT:

The microscopic changes show mild, diffuse edema in the form of perivascular vacuolization of the neuropil and white matter which is consistent with the mild grossly described changes. There is also mild acute gliosis in the form of astrocytic swelling, especially around blood vessels. These changes are agonal and not specific.

DIAGNOSIS:
(b)(6)

NEUROPATHOLOGIST

ACLU Detainee DeathII ARMY MEDCOM 1007

ADDENDUM B: Cardiovascular Pathology Consultation Report

AFIP ACCESSION NO. SEQUENCE NO.
(b)(6)

January 21, 2009

(b)(6)
AFIP- (b)(6)
1413 Research Blvd.
Bldg. 102
Rockville, MD 20850

DIAGNOSIS: (b)(6) **autopsy:**
No definitive cardiac cause of death identified
Focal dysplasia, atrioventricular nodal artery

History: 24 year old Iraqi male; height 177 cm, weight 83 kg; civilian detainee; began having difficulty breathing and could not be resuscitated

Heart: 440 g (per contributor) (predicted normal value 324 g, upper limit 458 g for 176 cm male); closed foramen ovale; normal cardiac chamber dimensions: left ventricular cavity diameter 30 mm, left ventricular free wall thickness 14 mm, ventricular septum thickness 14 mm, right ventricular from acute angle to septum 30 mm, posterior right ventricle wall thickness 4 mm; valves grossly unremarkable; normal endocardium; no gross myocardial scarring or fibrosis; histologic sections demonstrate no inflammation, scarring, or necrosis

Conduction system: The sinoatrial node and nodal artery are unremarkable. The compact atrioventricular (AV) node and penetrating bundle demonstrate focal fragmentation without inflammation, increased fat, or proteoglycans. The proximal left bundle branch is unremarkable and the right is not seen. There are no discernible bypass tracts between the AV node and the ventricular septum. There is mild AV nodal artery dysplasia with medial and intimal thickening and focal moderate dysplasia of an AV nodal artery branch with medial thickening.

Coronary arteries: Normal ostia; right dominance; no gross atherosclerosis

Comment: Small vessel disease (AV nodal artery dysplasia) as seen in this case has been implicated in sudden death, although causality in an individual case can be difficult to ascertain. We cannot exclude coronary spasm as a cause of death, which has no histologic imprint, or an idiopathic arrhythmia related to ion channel disorder.

(b)(6)
Department of Cardiovascular Pathology

ACLU Detainee DeathII ARMY MEDCOM 1008

(b)(6)

USE INK OR BALL-POINT PEN ONLY

Office Armed Forces Med Examiner

(b)(6)

(b)(6)

12/29/2008

(b)(6)

CONSULTATIONS

THIS IS A PERMANENT PART OF THE RECORD AND IS NOT TO BE REMOVED FROM THE FOLDER

PLEASE CIRCULATE AMONG THE FOLLOWING OFFICERS --------> AND THEN RETURN TO THE REVIEWING OFFICER ----

Neuropathology

(b)(6)

MEMO FROM REVIEWING OFFICER:

24 yo male Iraqi detainee noted to be gasping for air with seizure-like activity. See PSD for complete details. Thank you.

(b)(6)

(b)(6)

29 DEC 2008
(DATE)

(REVIEWING OFFICER)

CAFHE

ARMED FORCES INSTITUTE OF PATHOLOGY
NEUROPATHOLOGY REPORT
CASE NUMBER: (b)(6)
PATIENT NAME: HASHIM, LO'YL
DATE OF EXAMINATION: 01/08/09

GROSS DESCRIPTION:

Brain weight: 1326 gm

The specimen consists of the brain of an adult.

The leptomeninges are thin, delicate and transparent. The frontal lobe poles have been removed for toxicology studies.

The brain is pale and moderately, diffusely swollen having widened gyri, compressed sulci and partially effaced perisellar, perimesencephalic and cerebellomedullary cisterns. The gyri have an otherwise anatomically normal configuration.

There is no sign of herniation or midline shift. Tentorial grooves are not visible on either uncus. The cerebellar tonsils have a slightly swollen configuration. The external aspects of the brainstem and cerebellum are not remarkable. The arteries at the base of the brain follow a normal distribution and are free of atherosclerosis. There are no aneurysmal dilatations or sites of occlusion. The identifiable cranial nerve roots are not remarkable.

Coronal sections of the cerebrum reveal no focal lesions in the cortex, white matter or deep nuclear structures. There is no midline shift. Sections of the midbrain, pons, medulla and cerebellum show no diffuse or focal abnormalities. The substantia nigra and locus coeruleus are well pigmented.

The ventricular system and aqueduct of Sylvius are patent with a normal size and configuration. The choroid plexus is unremarkable and the ependymal surfaces are smooth and glistening.

PHOTOGRAPHS: yes

MEDCOM 1009
ACLU Detainee DeathII ARMY MEDCOM 1009

MICROSCOPIC EXAMINATION:

Blocks of tissue for microscopic examination are removed from: (1) right lateral frontal lobe, (2) cingulate gyri/anterior corpus callosum, (3) mid right cingulate gyrus/corpus callosum/caudate nucleus/anterior limb of internal capsule, (4) left thalamus/subthalamic nucleus/substantia nigra/posterior limb of the internal capsule, (5) right thalamus/ red nucleus /posterior limb of the internal capsule, (6) right hippocampus, (7) right calcarine cortex/occipital horn of lateral ventricle, (8) right cerebellum, (9) midbrain, (10) pons and (11) medulla.

Sections from each block are stained with H&E, Bielschowsky and LFB techniques and immunostained for β–amyloid precursor protein (β-APP), glial fibrillary acidic protein (GFAP) and β–amyloid.

COMMENT:

The microscopic changes show mild, diffuse edema in the form of perivascular vacuolization of the neuropil and white matter which is consistent with the mild grossly described changes. There is also mild acute gliosis in the form of astrocytic swelling, especially around blood vessels. These changes are agonal and not specific.

DIAGNOSIS:

(b)(6)

NEUROPATHOLOGIST

ACLU Detainee DeathII ARMY MEDCOM 1010

DEPARTMENT OF DEFENSE
ARMED FORCES INSTITUTE OF PATHOLOGY
WASHINGTON, DC 20306-6000

13 JAN 2005

AFIP Interdepartmental Consultation Report

AFIP ACCESSION NO. SEQUENCE NO.
(b)(6)
HASHIM, LO'Y L. (b)(6)
(b)(6)

(b)(6)
AFIP (b)(6)
1413 Research Blvd.
Bldg. 102
Rockville, MD 20850

DIAGNOSIS: (b)(6) **Heart, autopsy:**
No definitive cardiac cause of death identified
Focal dysplasia, atrioventricular nodal artery

History: 24 year old Iraqi male: height 177 cm, weight 83 kg; civilian detainee; began having difficulty breathing and could not be resuscitated

Heart: 440 g (per contributor) (predicted normal value 324 g, upper limit 458 g for 176 cm male); closed foramen ovale; normal cardiac chamber dimensions: left ventricular cavity diameter 30 mm, left ventricular free wall thickness 14 mm, ventricular septum thickness 14 mm, right ventricular from acute angle to septum 30 mm, posterior right ventricle wall thickness 4 mm; valves grossly unremarkable; normal endocardium; no gross myocardial scarring or fibrosis; histologic sections demonstrate no inflammation, scarring, or necrosis

Conduction system: The sinoatrial node and nodal artery are unremarkable. The compact atrioventricular (AV) node and penetrating bundle demonstrate focal fragmentation without inflammation, increased fat, or proteoglycans. The proximal left bundle branch is unremarkable and the right is not seen. There are no discernible bypass tracts between the AV node and the ventricular septum. There is mild AV nodal artery dysplasia with medial and intimal thickening and focal moderate dysplasia of an AV nodal artery branch with medial thickening.

Coronary arteries: Normal ostia; right dominance; no gross atherosclerosis

Comment: Small vessel disease (AV nodal artery dysplasia) as seen in this case has been implicated in sudden death, although causality in an individual case can be difficult to ascertain. We cannot exclude coronary spasm as a cause of death, which has no histologic imprint, or an idiopathic arrhythmia related to ion channel disorder.

Department of Cardiovascular Pathology
6825 16th St., N.W., Bldg. 54, Room 2088, Washington, DC 20306-6000
(b)(6)

MEDCOM 1011
ACLU Detainee DeathII ARMY MEDCOM 1011

AFIP ACCESSION NO. SEQUENCE NO.
(b)(6)

HASHIM, LO'Y L (b)(6)
(b)(6)

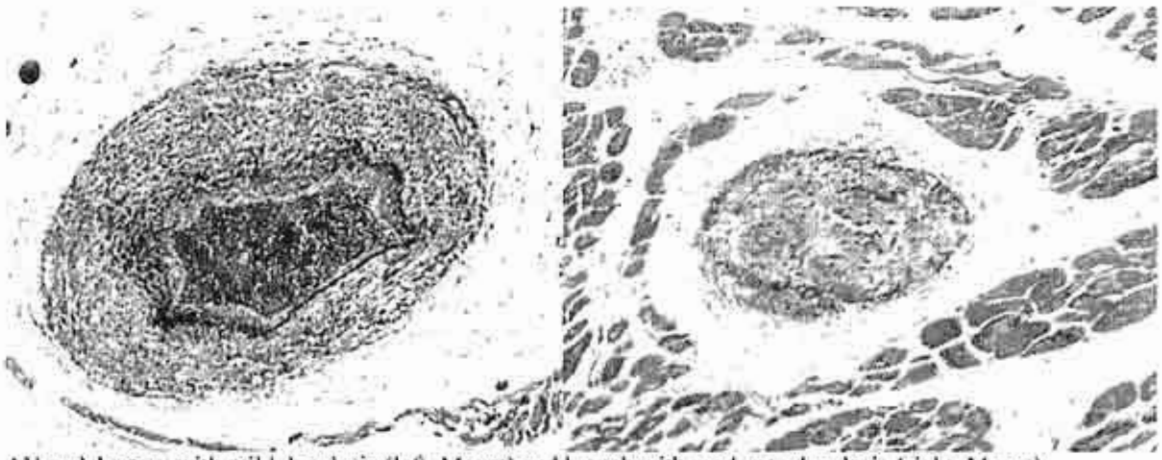

AV nodal artery with mild dysplasia (left, Movat) and branch with moderate dysplasia (right, Movat)

A copy of this report has been faxed to you at (b)(6)

Blocks made: 12 (5 myocardium, 7 conduction system)
Slides made: 12 (12 H&E, 3 Movat)

(b)(6)

Department of Cardiovascular Pathology

ACLU Detainee DeathII ARMY MEDCOM 1012

CERTIFICATE OF DEATH *(OVERSEAS)*
Acte de décès (D'Outre-Mer)

NAME OF DECEASED *(Last, First, Middle)* Nom du décédé (Nom et prénoms)	GRADE Grade	BRANCH OF SERVICE Arme	SOCIAL SECURITY NUMBER Numéro de l'Assurance Social
BTB Hashim, Lo'y, Lafta		Civilian	(b)(6)

ORGANIZATION Organisation	NATION *(e.g. United States)* Pays	DATE OF BIRTH Date de naissance	SEX Sexe
	Unknown		[X] MALE [ ] FEMALE

RACE Race		MARITAL STATUS État Civil			RELIGION Culte		
[X]	CAUCASOID Caucasique	[ ]	SINGLE Célibataire	[ ] DIVORCED Divorcé	[ ] PROTESTANT Protestant	[X]	OTHER (Specify) Autre (Spécifier) UNK
[ ]	NEGROID Negroide	[ ]	MARRIED Marié	[ ] SEPARATED Séparé	[ ] CATHOLIC Catholique		
[ ]	OTHER (Specify) Autre (Spécifier)	[ ]	WIDOWED Veuf		[ ] JEWISH Juif		

NAME OF NEXT OF KIN Nom du plus proche parent	RELATIONSHIP TO DECEASED Parenté du décédé avec le sus
STREET ADDRESS Domicilé à (Rue)	CITY OR TOWN OR STATE *(Include ZIP Code)* Ville (Code postal compris)

MEDICAL STATEMENT Déclaration médicale

	CAUSE OF DEATH (Enter only one cause per line) Cause du décès (N'indiquer qu'une cause par ligne)	INTERVAL BETWEEN ONSET AND DEATH Intervalle entre l'attaque et le décès
DISEASE OR CONDITON DIRECTLY LEADING TO DEATH [1] Maladie ou condition directement responsable de la mort	Atrioventricular Nodal Artery Dysplasia	Unknown
ANTECEDENT CAUSES Symptômes précurseurs de la mort — MORBID CONDITION, IF ANY, LEADING TO PRIMARY CAUSE Condition morbide, s'il y a lieu, menant à la cause primaire		
ANTECEDENT CAUSES Symptômes précurseurs de la mort — UNDERLYING CAUSE, IF ANY, GIVING RISE TO PRIMARY CAUSE Condition morbide, s'il y a lieu, menant à la cause primaire		
OTHER SIGNIFICANT CONDITIONS [2] Autres conditions significatives [2]		

MODE OF DEATH Condition de décès	AUTOPSY PERFORMED Autopsie effectuée [X] YES Oui [ ] NO Non	CIRCUMSTANCES SURROUNDING DEATH DUE TO EXTERNAL CAUSES Circonstances de la mort suscitées par des causes extérieures
[X] NATURAL Mort naturelle	MAJOR FINDINGS OF AUTOPSY Conclusions principales de l'autopsie	
[ ] ACCIDENT Mort accidentelle		
[ ] SUICIDE Suicide	NAME OF PATHOLOGIST Nom du pathologiste (b)(6)	
[ ] HOMICIDE Homicide	SIGN (b)(6) DATE Date 22 December 2008	AVIATION ACCIDENT Accident à Avion [ ] YES Oui [X] NO Non

DATE OF DEATH *(day, month, year)* Date du décès (le jour, le mois, l'année)	PLACE OF DEATH Lieu de décès
(b)(6) 2008 0602	Camp Cropper Iraq

I HAVE VIEWED THE REMAINS OF THE DECEASED AND DEATH OCCURRED AT THE TIME INDICATED AND FROM THE CAUSES AS STATED ABOVE
J'ai examiné les restes mortels du dé funtet je conclus que le décès est survenu à l'heure indiquée et à la suite des causes énumérées ci-dessus

NAME OF MEDICAL OFFICER Nom du médicin militaire ou du médicin sanitaire	TITLE OR DEGREE Titre ou diplômé
(b)(6)	Medical Examiner

GRADE Grade	INSTALLATION OR ADDRESS Installation ou adresse
(b)(6)	Dover AFB, Dover DE

DATE Date	SIGNATURE
3/4/2009	(b)(6)

[1] State disease, injury or complication which caused death, but not mode o
[2] State conditions contributing to the death, but not related to the disease o
[1] Préciser la nature de la maladie, de la blessure ou de la complication qui a contribué à la mort, mais non la manière de mourir, telle qu'un arrêt du coeur, etc
[2] Préciser la condition qui a contribué à la mort, mais n'ayant aucun rapport avec la maladie ou à la condition qui a provoqué la mort

DD FORM 1 APR 77 2064 REPLACES DA FORM 3565, 1 JAN 72 AND DA FORM 3566-R(PAS), 26 SEP 75, WHICH ARE OBSOLETE.

ARMED FORCES INSTITUTE OF PATHOLOGY
Office of the Armed Forces Medical Examiner
1413 Research Blvd., Bldg. 102
Rockville, MD 20850
301-319-0000

AUTOPSY EXAMINATION REPORT

Name: BTB ABD. Fu'ad Ali
ISN (b)(6)
Date of Birth (b)(6) 1955
Date of Death (b)(6) 08
Date/Time of Autopsy: 31 MAY 08 @1230 hrs
Date of Report: 27 AUG 2008

Autopsy No.: (b)(6)
AFIP No.: (b)(6)
Rank: Civilian Iraqi Detainee
Place of Death: Iraq
Place of Autopsy: Port Mortuary, Dover AFB, DE

Circumstances of Death: This 52-year-old Iraqi detainee who suffered a cerebral vascular accident one month after being diagnosed with a myocardial infarction. He was transferred to the ICU and was deemed non-operable by the neurosurgery team. He was placed on do not resuscitate (DNR) orders after an ethic committee meeting decision. He was pronounced dead shortly thereafter.

Authorization for Autopsy: Armed Forces Medical Examiner, per U.S. Code 10, Section 1471

Identification: Identified by transportation documents. Postmortem fingerprint and dental x-rays were obtained prior to the autopsy.

CAUSE OF DEATH: **SPONTANEOUS INTRACRANIAL HEMORRHAGE DUE TO ATHROSCLEROTIC CARDIOVASCULAR DISEASE**

MANNER OF DEATH: **NATURAL**

ACLU Detainee DeathII ARMY MEDCOM 1014

EXTERNAL EXAMINATION

The body is that of a well-developed nude male. The body weighs 142 pounds, is 67 inches in length and appears compatible with the reported age of 52 years. The body is cold. Rigor is present to an equal degree in all extremities. Lividity is present and fixed on the posterior surface of the body, except in areas exposed to pressure.

The head is normocephalic, and the scalp hair is black/gray. Facial hair consists of a mustache and a shaven beard. The irides are brown. The corneae are cloudy. The conjunctivae and sclerae are unremarkable. The external auditory canals, external nares and oral cavity are free of foreign material and abnormal secretions. The nasal skeleton and maxilla are palpably intact. The lips are without evident injury. The teeth are natural and in poor condition. Examination of the neck reveals no evidence of injury.

The chest is unremarkable. No evidence of injury of the ribs or the sternum is evident externally. The abdomen is unremarkable. There is a 2 ½ x 2 ¼ inch well healed surgical scar on the anterior left upper thigh. The external genitalia are those of a circumcised adult. The posterior torso and anus are unremarkable.

There is a 2 x 1 inch contusion of the dorsal surface of the right hand. There is a 1 x ½ inch contusion of the right groin. There are two contusions of the anterior left upper thigh measuring up ¼ inch in maximum dimension. There is a 2 x ¼ inch contusion with an underlying 7 x 4 centimeter area of hemorrhage. There is a 3 x ¼ inch contusion on the anterior medial right ankle.[1] The extremities show no evidence of fractures or lacerations. The fingernails are intact. Tattoos (b)(6)

CLOTHING AND PERSONAL EFFECTS

None identified.

MEDICAL INTERVENTION

- Six needle puncture marks on the right ante-cubital fossa
- Two needle puncture marks on the left ante-cubital fossa
- One needle puncture mark surrounded by a 1 x ½ inch contusion on the left femoral artery/vein region
- Two band-aids on the left palm and left anterior upper thigh

RADIOGRAPHS

A complete set of postmortem radiographs is obtained and demonstrate intra-parenchymal brain hemorrhage and multiple remote ballistic fragments in the left upper thigh which are listed under "Internal Examination."

[1] Contusions are likely a result of emergency medical intervention

ACLU Detainee DeathII ARMY MEDCOM 1015

EVIDENCE OF INJURY

None.

INTERNAL EXAMINATION

BODY CAVITIES:

The ribs, sternum, and vertebral bodies are visibly and palpably intact. No adhesions or abnormal collections of fluid are present in any of the body cavities. All body organs are present in normal anatomical position. The subcutaneous fat layer of the abdominal wall is 1 inch thick.

HEAD (CENTRAL NERVOUS SYSTEM) AND NECK:

The brain weighs 1370 grams and appears edematous. The galeal and subgaleal soft tissues of the scalp are free of injury. There are no skull fractures. The dura mater and falx cerebri are intact. There is no epidural or subdural hemorrhage present.

At the base of the anterior right temporal lobe is a 7 x 4.5 centimeter defect revealing an 8 x 5 x 3.5 centimeter intracranial clot with extension of hemorrhage into the ventricular system (right lateral ventricle, third, and fourth ventricles). Subarachnoid hemorrhage surrounds this temporal lobe defect extending to the right occipital lobe and the base of the bilateral frontal lobes and cerebellar hemispheres. The arteries of the circle of Willis are in the usual anatomic configuration and are patent. No aneursyms are identified. The cerebellum is serially sectioned along the sagittal plane, revealing an unremarkable cut surface. The brainstem is bisected sagittally to reveal duret hemorrhages. There is a 2.5 x 0.8 x. 0.4 centimeter right temporal lobe laceration along the edge of the right tentorium cerebelli. Coronal sectioning of the cerebral hemispheres reveal a separate focus of intercranial hemorrhage at the gray-white junction in the right parietal lobe measuring 1.0 x 0.8 x 0.5 centimeters. The atlanto-occipital joint is stable.

The anterior strap muscles of the neck are homogenous and red-brown, without hemorrhage by layer-wise dissection. The thyroid cartilage and hyoid bone are intact. The larynx is lined by intact white mucosa. The tongue is free of bite marks, hemorrhage, or other injuries. Incision and dissection of the posterior neck demonstrates no deep paracervical muscular injury and no cervical spine fractures.

CARDIOVASCULAR SYSTEM:

The heart weighs 380 grams and is contained in an intact pericardial sac. The epicardial surface is smooth, with minimal fat investment. The coronary arteries are present in a normal distribution, with a right-dominant pattern. Cross sections of the vessels show severe (greater than 75%) atherosclerotic luminal stenosis of the left anterior descending artery and right coronary artery measuring 5.0 and 6.0 centimeters from the left and right coronary orifice, respectively.

Much of the anterior left ventricular wall is asymmetrically thin (0.5 centimeter on average) with tan/gray discoloration compared to the posterior left ventricular wall (1.0 centimeter on average) with normal appearing homogenous, red-brown myocardial tissue. The valve leaflets are thin and mobile. The walls of the left ventricle, interventricular septum, and right ventricle are 0.5, 1.2, and 0.2 centimeters thick, respectively. The endocardial surface is dull and slightly roughened. The aorta display atherosclerotic changes and gives rise to three intact and patent arch vessels. The renal and mesenteric vessels are unremarkable.

ACLU Detainee DeathII ARMY MEDCOM 1016

RESPIRATORY SYSTEM:

The upper airway is clear of debris and foreign material: the mucosal surfaces are smooth, yellow-tan and unremarkable. The pleural surfaces are smooth, glistening and unremarkable bilaterally.

The pulmonary parenchyma is diffusely congested and edematous exudes blood and frothy fluid with no focal lesions noted. The pulmonary arteries are normally developed, patent and without thrombus or embolus. The right lung weighs 1100 grams and the left lung weighs 850 grams.

HEPATOBILIARY SYSTEM:

The liver weighs 1510 grams has an intact smooth capsule covering moderately congested tan-brown parenchyma with no focal lesions noted. The gallbladder contains 40 milliliters of green-brown, mucoid bile; the mucosa is velvety and unremarkable. The extrahepatic biliary tree is patent, without evidence of calculi.

GASTROINTESTINAL SYSTEM:

The esophagus is lined by gray-white, smooth mucosa. The gastric mucosa is arranged in the usual rugal folds and the lumen contains 350 milliliters of tan fluid. The small and large bowels are unremarkable. The pancreas has a normal pink-tan lobulated appearance and the ducts are clear. The appendix is present.

GENITOURINARY SYSTEM:

The right kidney weighs 100 grams; the left weighs 90 grams. The renal capsules are smooth and thin, semi-transparent and strip with ease from the underlying smooth, red-brown cortical surface.
The cortices are sharply delineated from the medullary pyramids, which are red-purple to tan and unremarkable. The calyces, pelves and ureters are unremarkable.

The tan bladder mucosa overlies an intact bladder wall. The bladder contains no urine. The testes, prostate gland and seminal vesicles are unremarkable.

LYMPHORETICULAR SYSTEM:

The spleen weighs 100 grams and has a smooth, intact capsule covering red-purple, moderately firm parenchyma; the lymphoid follicles are unremarkable. Lymph nodes in the hilar, periaortic and iliac regions are not enlarged.

ENDOCRINE SYSTEM:

The pituitary gland is left *in situ* and is unremarkable. The thyroid gland is symmetric and red-brown, without cystic or nodular change. The right and left adrenal glands are symmetric, with bright yellow cortices and red-brown medullae. No masses or areas of hemorrhage are identified.

MUSCULOSKELETAL SYSTEM:

No non-traumatic abnormalities of muscle or bone are identified. Multiple remote metallic fragments in the left thigh are identified.

ACLU Detainee DeathII ARMY MEDCOM 1017

MICROSCOPIC EXAMINATION

Selected portions of organs are retained in formalin with preparation of histology slides listed below:

Adrenal glands (slide 1): No pathological diagnosis

Prostate (slide 2): No pathological diagnosis

Liver, spleen, left kidney (slide 3): No pathological diagnosis

Right kidney and left lung (slide 4): No pathological diagnosis

Right lung (slide 5): Two out the three lobes of the right lung display sheets of acute inflammatory cells admixed with macrophages and red blood cells consistent with acute pneumonia.

Left anterior descending artery (slides 6) and right coronary artery (slide 7): Sections of the coronary arteries display intimal hyperplasia and atherosclerotic plaques composed of fibrin and cholesterol plaques.

Left ventricle of the heart (slide 8): Section of the heart display vast area of fibrotic stroma with congested blood vessels consistent with a remote myocardial infarction.

ADDITIONAL PROCEDURES

1. Documentary photographs are taken by OAFME.
2. Personal effects are released to the appropriate mortuary operations representatives.
3. Specimens retained for toxicology testing and/or DNA identification are: vitreous fluid, blood, bile, gastric contents, spleen, liver, lung, kidney, adipose tissue and skeletal muscle.
4. The dissected organs are forwarded with body.

ACLU Detainee DeathII ARMY MEDCOM 1018

FINAL AUTOPSY DIAGNOSIS

I. Spontaneous Intracranial Hemorrhage:
- i. 7 x 4.5 centimeter defect at the base of the anterior right temporal lobe reveals an 8 x 5 x 3.5 centimeter intracranial clot with extension of hemorrhage into the ventricular system (right lateral ventricle, third, and fourth ventricles)
- ii. Subarachnoid hemorrhage of the right temporal, right occipital, bilateral frontal lobes and both cerebellar hemispheres.
- iii. Duret hemorrhages of the brainstem
- iv. 2.5 x 0.8 x. 0.4 centimeter right temporal lobe laceration along the edge of the right tentorium cerebelli.
- v. Separated 1.0 x 0.8 x 0.5 centimeter intercranial hemorrhage at the right parietal lobe gray-white junction

II. Atherosclerotic Cardiovascular Disease
- i. Severe (greater than 75% occlusion) atherosclerotic luminal stenosis of the left anterior descending and right coronary arteries.
- ii. Extensive old myocardioal infarction, anterior wall of left ventricle.

III. Acute Pneumonia

IV. Pre-existing Condition: Remote ballistic injury to the left upper thigh

V. Evidence of Medical Therapy: As described above

VI. Post-Mortem Changes: As described above

VII. Identifying Body Marks: As described above

VIII. Toxicology (AFIP)
- i. CARBON MONOXIDE: Carboxyhemoglobin saturation in the blood
- ii. VOLATILES: No ethanol was detected in the blood and vitreous fluid
- iii. CYANIDE: No cyanide detected in the blood
- iv. SCREENED MEDICATIONS: Lidocaine was detected in the blood
- v. SCREENED DRUGS OF ABUSE: No drugs detected in the blood

ACLU Detainee DeathII ARMY MEDCOM 1019

OPINION

This 52-year-old male detainee (b)(6) died from a spontaneous intracranial hemorrhage (stroke / cerebral vascular accident) complicated by an old myocardial infarction (heart attack). Toxicology screen revealed presence of Lidocaine, a resuscitative medication. No significant sign of trauma on the body was noted at autopsy. The manner of death is natural.

(b)(6)

(b)(6) Medical Examiner

(b)(6)

(b)(6) Medical Examiner

ACLU Detainee DeathII ARMY MEDCOM 1020

CERTIFICATE OF DEATH *(OVERSEAS)*
Acte dé décès (D'Outre-Mer)

NAME OF DECEASED *(Last, First, Middle)* Nom du décédé (Nom et prénoms)	GRADE Grade	BRANCH OF SERVICE Arme	SOCIAL SECURITY NUMBER Numéro de l'Assurance Social
BTB Abd, Fu ad, Ali		Civilian	(b)(6)
ORGANIZATION Organisation	**NATION** *(e.g. United States)* Pays	**DATE OF BIRTH** Date de naissance	**SEX** Sexe
		(b)(6) 1955	[X] MALE [ ] FEMALE

RACE Race		MARITAL STATUS État Civil			RELIGION Culte		
[X]	CAUCASOID Caucasique	[ ]	SINGLE Célibataire	[ ] DIVORCED Divorcé	[ ] PROTESTANT Protestant	[X]	OTHER (Specify) Autre (Spécifier) Islam
[ ]	NEGROID Negroide	[ ]	MARRIED Marié	[ ] SEPARATED Séparé	[ ] CATHOLIC Catholique		
[ ]	OTHER (Specify) Autre (Spécifier)	[ ]	WIDOWED Veuf		[ ] JEWISH Juif		

NAME OF NEXT OF KIN Nom du plus proche parent	RELATIONSHIP TO DECEASED Parenté du décédé avec le sus
STREET ADDRESS Domicilé à (Rue)	CITY OR TOWN OR STATE *(Include ZIP Code)* Ville (Code postal compris)

MEDICAL STATEMENT Déclaration médicale

CAUSE OF DEATH (Enter only one cause per line) Cause du décès (N'indiquer qu'une cause par ligne)			INTERVAL BETWEEN ONSET AND DEATH Intervalle entre l'attaque et le décès
DISEASE OR CONDITON DIRECTLY LEADING TO DEATH [1] Maladie ou condition directement responsable de la mort. [1]		Spontaneous intracranial hemorrhage due to atherosclerotic cardiovascular disease	
ANTECEDENT CAUSES Symptômes précurseurs de la mort	MORBID CONDITION, IF ANY, LEADING TO PRIMARY CAUSE Condition morbide, s'il y a lieu, menant à la cause primaire		
	UNDERLYING CAUSE, IF ANY, GIVING RISE TO PRIMARY CAUSE Condition morbide, s'il y a lieu, menant à la cause primaire		
OTHER SIGNIFICANT CONDITIONS [2] Autres conditions significatives [2]			

MODE OF DEATH Condition de décès	AUTOPSY PERFORMED Autopsie effectuée [X] YES Oui [ ] NO Non	CIRCUMSTANCES SURROUNDING DEATH DUE TO EXTERNAL CAUSES Circonstances de la mort suscitées par des causes extérieures
[X] NATURAL Mort naturelle	MAJOR FINDINGS OF AUTOPSY Conclusions principales de l'autopsie	
[ ] ACCIDENT Mort accidentelle		
[ ] SUICIDE Suicide	NAME OF PATHOLOGIST Nom du pathologiste (b)(6)	
[ ] HOMICIDE Homicide	SIGNATURE Signature / DATE Date 31 May 2008	AVIATION ACCIDENT Accident à Avion [ ] YES Oui [X] NO Non

DATE OF DEATH *(day, month, year)* Date de décès (le jour, le mois, l'année)	PLACE OF DEATH Lieu de décès
(b)(6) 2008	Iraq

I HAVE VIEWED THE REMAINS OF THE DECEASED AND DEATH OCCURRED AT THE TIME INDICATED AND FROM THE CAUSES AS STATED ABOVE.
J'ai examiné les restes mortels du dé funtet je conclus que le décès est survenu à l'heure indiquée et à la suite des causes énumérées ci-dessus.

NAME OF MEDICAL OFFICER Nom du médicin militaire ou du médicin sanitaire	TITLE OR DEGREE Titre ou diplômé
(b)(6)	Medical Examiner

GRADE Grade	INSTALLATION OR ADDRESS installation ou adresse
(b)(6)	Dover AFB, Dover DE
DATE Date 8/27/2008	**SIGNATURE** Signature

[1] State disease, injury or complication which caused death, but not mode of dying such as heart failure, ect.
[2] State conditions contributing to the death, but not related to the disease or condition causing death
[1] Préciser la nature de la maladie, de la blessure ou de la complication qui a contribué à la mort, mais non la manière de mourir, telle qu 'un arrêt du coeur, etc
[2] Préciser la condition qui a contribué à la mort, mais n'ayant aucun rapport avec la maladie ou à la condition qui a provoqué la mort.

DD FORM 1 APR 77 **2064** REPLACES DA FORM 3565, 1 JAN 72 AND DA FORM 3565-R(PAS), 26 SEP 76, WHICH ARE OBSOLETE.

MEDCOM 1021

ACLU Detainee DeathII ARMY MEDCOM 1021

ARMED FORCES INSTITUTE OF PATHOLOGY
Office of the Armed Forces Medical Examiner
1413 Research Blvd., Bldg. 102
Rockville, MD 20850
1-301-319-0000
(FAX 1-301-319-0635)

FINAL AUTOPSY REPORT

Name: QURUNFIR Al-Araki, Husayn Kazim
ISN (b)(6)
Date of Birth: Unknown
Date of Death (b)(6) 2008
Date of Autopsy: 25 MAY 2008, 1130 hours
Date of Report: 06 JUN 2008

Autopsy No. (b)(6)
AFIP No. (b)(6)
Rank: Civilian, Iraqi Detainee
Place of Death: Camp Cropper, Iraq
Place of Autopsy: Dover Port Mortuary
Dover AFB, Dover, DE

Circumstances of Death:
Preliminary investigation revealed that (b)(6) an Iraqi detainee, was admitted to the Detainee Medical Center, Camp Remembrance II, Theater Internment Facility, Camp cropper, IZ, on (b)(6) 2008, with apparent injuries and was pronounced dead by the treating physician.

Authorization for Autopsy: Office of the Armed Forces Medical Examiner, IAW 10 USC 1471

Identification:
Detainee (b)(6) is identified by transportation documents and the accompanied CID Investigation Report. Fingerprints, dental radiographs and a sample for DNA identification are obtained on 25 MAY 2008.

CAUSE OF DEATH:
Blunt Force Injuries and Neck Compression

MANNER OF DEATH:
Homicide

ACLU Detainee DeathII ARMY MEDCOM 1022

EXTERNAL EXAMINATION

The body is that of an unclad well-developed, well-nourished Caucasian male, on a gray-black blanket in a plastic body pouch. Extensive bruising of the neck, torso and extremities are noted; see "Evidence of Injury". The body weighs 124 pounds and is approximately 63" in length. The age of the decedent can not be definitely determined but appears to be of a middle aged man.

The scalp hair is black and short. A black mustache and beard are noted. The eyelids are unremarkable with no apparent trauma. The eye globes are unremarkable with no apparent trauma. The irides are pale and grayish. The corneae are whitish and slightly cloudy. The sclerae are white with a small area of hemorrhage on the right side. The external auditory canals, external nares and oral cavity are free of foreign material. The oral cavity reveal presence of mucosal trauma on both sides: see "Evidence of Injury". The nasal skeleton is palpably intact. The tongue reveals a contusion on the left margin with no associated bite marks. The lips are unremarkable with no apparent injury. The teeth are natural and are unremarkable.

The neck reveals presence of contusions anteriorly and on both sides; see "Evidence of Injury". No ligature marks are present. .

The anterior torso reveals extensive bruising of the chest and abdomen. Contusions are dusky red, and more pronounced on the abdomen. The posterior torso also reveals contusions, more pronounced on the flanks. No penetrating wounds or sharp force injuries are noted. No contusions or trauma is noted of the suprapubic area and the external genitalia. The external genitalia are those of an adult circumcised male and are grossly unremarkable.

The upper extremities reveal contusions of the left arm and right elbow region. The lower extremities reveal presence of contusions on the upper thighs, legs and feet; see "Evidence of Injury".

No tattoos, major surgical or characteristic scars or other identifying marks are noted.

EVIDENCE OF INJURY

Multiple injuries are noted of the neck, torso and extremities and are described below. No evidence of sharp force or penetrating injuries is noted.

A. Injuries of the Head:

Examination of the head reveals no gross evidence of trauma. Examination of the oral cavity reveals bilateral mucosal contusions corresponding to the lateral teeth on both sides; see "Opinion".

ACLU Detainee DeathII ARMY MEDCOM 1023

Reflection of the scalp reveals no subgaleal hemorrhage or evidence of skull fractures. The cranial cavity is unremarkable with no evidence of trauma or intracranial hemorrhage.

B. Injuries of the Neck:
Examination of the neck reveals presence of un-patterned contusions on the anterior and lateral surfaces of the neck. Reflection of the skin reveals bilateral hemorrhages of the strap muscles, more pronounced on the left side. The hyoid is intact, but an area of hemorrhage is noted on its left side. The thyroid cartilage is intact. Localised hemorrhage is noted on the right side of the upper part of the esophagus with no evidence of laceration or perforation.

Posterior dissection of the neck reveals localized hemorrhage of the posterior right neck muscles; see "Opinion". No gross evidence of cervical spinal fractures or abnormal mobility is noted.

C. Injuries of the Torso:
External examination of the torso reveals extensive contusions on the anterior chest and abdomen, connecting the neck contusions superiorly and sparing only the supra-pubic area inferiorly. Reflection of the anterior chest and abdominal wall reveals hemorrhage of the sternum and anterior chest cage. No rib fractures are seen. Examination of the back reveals extensive subcutaneous and intramuscular hemorrhage of the back muscles, more pronounced in both flanks. No spinal fractures are noted.

Removal of the chest plate reveals hemorrhage of its posterior surface, anterior mediastinum and anterior pericardium. No gross trauma to the heart or lungs is noted. Removal of the chest organs reveals bilateral hemorrhage of the posterior-lateral inter-costal muscles, with no gross evidence of associated rib fractures.

Examination of the abdomen reveals multiple focal hemorrhagic areas of the small intestine and a single contusion of the transverse colon, midline. Hemorrhage is noted in the adipose and soft tissue surrounding the head of the pancreas with no free blood or gross pancreatic laceration. Source of hemorrhage is not identified. Bilateral severe perirenal-subcapsular hemorrhages are noted of both kidneys, more pronounced on the right side. Peri-adrenal hemorrhages are also noted, more pronounced on the right side. Severe bilateral retroperitoneal hemorrhage is noted. Hemorrhage is also noted around the prostate gland and on the anterior wall of the urinary bladder. The bladder wall is intact but empty of urine.

ACLU Detainee DeathII ARMY MEDCOM 1024

D. Injuries of the Extremities:
Examination of the upper extremities reveals marked subcutaneous and intramuscular hemorrhage of the muscles of the posterior and lateral right arm. No significant injury is noted of the right forearm or the left upper extremity.

Examination of the lower extremities reveals no significant injuries. Multiple contusions are noted on the anterior thigh and anterior-medial legs. Sections through these contusions reveal subcutaneous and intramuscular hemorrhage, though less prominent than those of the upper extremities.

Examination of both feet reveals contusions of the anterior plantar surfaces of both feet and the dorsum of both big toes. Sections through these contusions reveal subcutaneous and prominent intramuscular hemorrhages.

INTERNAL EXAMINATION

The injuries are listed above and will not be repeated.

BODY CAVITIES:

See "Evidence of Injury". The body is opened by the usual thoraco-abdominal incision and the chest plate is removed. Bilateral adhesions are noted in the chest cavitiy, more prominent on the left side. No abnormal collections of fluid are present noted. All body organs are present in their normal anatomical position.

HEAD: (CENTRAL NERVOUS SYSTEM)

The scalp is reflected. No evidence of trauma is noted. The calvarium of the skull is removed. The dura mater and falx cerebri are intact. There is no epidural or subdural hemorrhage present. The leptomeninges are thin and delicate. The cerebral parenchyma is grossly unremarkable with no significant abnormality. The brain weighs 1330 grams.

NECK:
See "Evidence of Injury"

Examination and dissection of the soft tissues of the neck, layer-by-layer, reveals no non-traumatic abnormalities. The thyroid cartilage and hyoid bone are intact.

CARDIOVASCULAR SYSTEM:
See "Evidence of Injury".

The pericardium is intact. The pericardial sac is free of fluid and adhesions. The coronary arteries arise normally, follow the usual distribution and are patent. without evidence of atherosclerosis or thrombosis. The chambers and valves exhibit the usual

ACLU Detainee DeathII ARMY MEDCOM 1025

size-position relationship and are unremarkable. The myocardium is unremarkable. The atrial and ventricular septa are intact. The aorta and its major branches arise normally, follow the usual course and are unremarkable without significant atherosclerosis and other abnormality. The venae cavae and their major tributaries return to the heart in the usual distribution and are free of thrombi. The heart weighs 300 grams.

RESPIRATORY SYSTEM:
The upper airway is clear of debris and foreign material; the mucosal surfaces are unremarkable. The pleural surfaces are unremarkable bilaterally. The pulmonary parenchyma is grey-red and are markedly congested. No consolidation or significant abnormality is grossly noted. The pulmonary arteries are normally developed, patent and without thrombus or embolus. The right and left lung weighs 610 grams and 540 grams, respectively.

LIVER & BILIARY SYSTEM:
The hepatic capsule is smooth and intact, covering dark brown parenchyma with no apparent focal lesions. The gallbladder is intact and contains dark green bile and no gall stones. The extrahepatic biliary tree is without evidence of calculi. The liver weighs 1090 grams.

ALIMENTARY TRACT:
See "Evidence of Injury".

The tongue reveals no non-traumatic abnormalities. The esophagus is lined by gray-white mucosa. The gastric mucosa reveals the normal rugal folds. The stomach is distended with undigested-partially digested food; sample is submitted for toxicology. The small and large bowel is unremarkable with no non-traumatic abnormalities. The pancreas is grossly unremarkable with no non-traumatic lesions. The appendix is present and unremarkable.

GENITOURINARY SYSTEM:
See "Evidence of Injury".

The renal capsules are smooth and thin. The cortices are delineated from the medullary pyramids, and unremarkable. The calyces, pelves and ureters are unremarkable. The urinary bladder mucosa is unremarkable and contains no urine. The right and left kidneys weigh 100 grams each. The prostate gland and testes reveal no non-traumatic abnormality.

RETICULOENDOTHELIAL SYSTEM:
The spleen has a smooth, intact capsule covering pasty purple parenchyma; and grossly unremarkable. No enlarged lymph nodes are seen. The spleen weighs 120 grams.

ACLU Detainee DeathII ARMY MEDCOM 1026

ENDOCRINE SYSTEM:
See "Evidence of Injury".

The pituitary and thyroid glands are grossly unremarkable. The adrenal glands reveal no non-traumatic abnormalities.

MUSCULOSKELETAL SYSTEM:
See "Evidence of Injury".

Muscle development is normal. No non-traumatic muscle, bone or joint abnormalities are noted.

EVIDENCE COLLECTION

None collected during autopsy.

IDENTIFYING MARKS

A dark mustache and beard are present. No tattoos, major surgical scars or other identifying marks are noted.

NATURAL DISEASES

No evidence of natural diseases is identified during the autopsy examination.

MEDICAL INTERVENTION

None noted during autopsy.

POSTMORTEM CHANGES

The body is cold due to refrigeration. Livor is consistent with supine position. Rigor is present equally in all extremities. No significant decomposition changes are noted.

TOXICOLOGY

A. Volatiles (Blood and Vitreous fluid): No ethanol was detected.
B. Screened drugs of abuse and medications (Blood): None were found.

ACLU Detainee DeathII ARMY MEDCOM 1027

ADDITIONAL PROCEDURES

- Documentary photographs are taken by an OAFME photographer.
- Full body radiographs and computerized body scans are obtained.
- Specimens retained for toxicological and/or DNA identification are: Blood, vitreous fluid, bile, Gastric contents, and tissue samples from liver, lung, kidney, spleen, brain, psoas and heart muscles, and adipose tissue.
- Representative sections of organs are retained in formalin without preparation of histological slides.

FINAL AUTOPSY DIAGNOSIS

I. Blunt Force Injuries:

a. Injuries of the Head:
- Bilateral contusions of the intra-oral mucosa.
- Scleral hemorrhage, right side.

b. Injuries of the Neck:
- Extensive contusions of the neck.
- Focal areas of hemorrhage in the muscles of the neck, bilateral and posteriorly.
- Hemorrhage on the left side of the hyoid. No fractures noted.

c. Injuries of the Torso:
- Extensive contusions on the anterior and posterior torso with subcutaneous and intramuscular hemorrhage.
- Hemorrhage of intercostal spaces of the chest cavity, bilateral.
- Retroperitoneal hemorrhage, bilateral.
- Bilateral peri-renal and peri-adrenal and peri-pancreatic hemorrhages.
- Focal hemorrhages of the esophagus, small and large intestines, urinary bladder and prostate gland.

d. Blunt Force Trauma to the Extremities:
- Extensive subcutaneous and intramuscular hemorrhage of the right arm.
- Multiple contusions with subcutaneous and intramuscular hemorrhage of the lower extremities.

II. Neck Compression:
- See Injuries of the Neck above

III. Toxicology: No ethanol, screened medications or drugs of abuse were detected.

ACLU Detainee DeathII ARMY MEDCOM 1028

OPINION

(b)(6) an Iraqi detainee, died from blunt force injuries to his torso and extremities and possible asphyxiation by neck compression and/or smothering.

(b)(6) suffered extensive subcutaneous, intramuscular and retroperitoneal hemorrhages as well as peri-renal, peri-adrenal and peri-pancreatic hemorrhages. Though there was no evidence of skeletal fractures, the extent of the noted blunt force trauma and the resulting blood loss must have resulted in a non-reversible hemorrhagic shock. Also noted is the sternal and pericardial trauma which may have effects on the heart function and myocardial conduction system that cannot be definitively determined at autopsy. The injuries appear of the same age and are consistent with acute trauma. The multiplicity of injuries and distribution, anterior and posterior torso, extremities and the plantar surfaces of both feet are consistent with torture.

The distribution of the hemorrhage of the neck muscles is consistent with manual neck compression/strangulation. The applied force was enough to cause deep hemorrhage around the esophagus, but not enough to fracture the hyoid bone. Bilateral intraoral mucosal contusions/hemorrhage is noted and is consistent with applying pressure to both cheeks forcing a contact between the teeth and the oral mucosa, consistent with smothering or forceful attempt to silence the victim. Resulting asphyxia may have caused brain damage and contributed/hastened his death.

Toxicological studies on blood and vitreous fluid are negative for ethanol, screened medications and drugs of abuse.

In summary, (b)(6) died from a combination of blunt force trauma and asphyxia by neck compression and smothering. Manner of death is "Homicide".

(b)(6)

(b)(6) Medical Examiner

ACLU Detainee DeathII ARMY MEDCOM 1029

CERTIFICATE OF DEATH *(OVERSEAS)*
Acte de décès (D'Outre-Mer)

NAME OF DECEASED *(Last, First, Middle)* Nom du décédé (Nom et prénoms)	GRADE Grade	BRANCH OF SERVICE Arme	SOCIAL SECURITY NUMBER Numéro de l'Assurance Social
BTB Qurunfir Al-Araki, Husayn Kazim,		Civilian	(b)(6)
ORGANIZATION Organisation	NATION *(e.g. United States)* Pays: Iraq	DATE OF BIRTH Date de naissance	SEX Sexe: [X] MALE [ ] FEMALE

RACE Race		MARITAL STATUS État Civil			RELIGION Culte		
[X]	CAUCASOID Caucasique	[ ]	SINGLE Célibataire	[ ] DIVORCED Divorcé	[ ]	PROTESTANT Protestant	[X] OTHER (Specify) Autre (Spécifier)
[ ]	NEGROID Negriode	[ ]	MARRIED Marié	[ ] SEPARATED Séparé	[ ]	CATHOLIC Catholique	
[ ]	OTHER (Specify) Autre (Spécifier)	[ ]	WIDOWED Veuf		[ ]	JEWISH Juif	

NAME OF NEXT OF KIN Nom du plus proche parent	RELATIONSHIP TO DECEASED Parenté du décédé avec le sus
STREET ADDRESS Domicilé à (Rue)	CITY OR TOWN OR STATE *(Include ZIP Code)* Ville (Code postal compris)

MEDICAL STATEMENT Déclaration médicale

CAUSE OF DEATH (Enter only one cause per line) Cause du décès (N'indiquer qu'une cause par ligne)			INTERVAL BETWEEN ONSET AND DEATH Intervalle entre l'attaque et le décès
DISEASE OR CONDITON DIRECTLY LEADING TO DEATH [1] Maladie ou condition directement responsable de la mort		Blut force injuries and neck compression	Unknown
ANTECEDENT CAUSES Symptômes précurseurs de la mort	MORBID CONDITION, IF ANY, LEADING TO PRIMARY CAUSE Condition morbide, s'il y a lieu, menant à la cause primaire		
	UNDERLYING CAUSE, IF ANY, GIVING RISE TO PRIMARY CAUSE Condition morbide, s'il y a lieu, menant à la cause primaire		
OTHER SIGNIFICANT CONDITIONS [2] Autres conditions significatives			

MODE OF DEATH Condition de décès	AUTOPSY PERFORMED Autopsie effectuée [X] YES Oui [ ] NO Non	CIRCUMSTANCES SURROUNDING DEATH DUE TO EXTERNAL CAUSES Circonstances de la mort suscitées par des causes extérieures
[ ] NATURAL Mort naturelle	MAJOR FINDINGS OF AUTOPSY Conclusions principales de l'autopsie	
[ ] ACCIDENT Mort accidentelle		
[ ] SUICIDE Suicide	NAME OF PATHOLOGIST Nom du pathologiste: (b)(6)	
[X] HOMICIDE Homicide	SIGNATUR (b)(6) DATE Date: 25 May 2008	AVIATION ACCIDENT Accident à Avion: [ ] YES Oui [X] NO Non

DATE OF DEATH *(day, month, year)* Date de décès (le jour, le mois, l'année)	
(b)(6) 2008 1055	Iraq

I HAVE VIEWED THE REMAINS OF THE DECEASED AND DEATH OCCURRED AT THE TIME INDICATED AND FROM THE CAUSES AS STATED ABOVE.
J'ai examiné les restes mortels du dé funt je conclus que le décès est survenu à l'heure indiquée et à, la suite des causes énumérées ci-dessus.

NAME OF MEDICAL OFFICER Nom du médicin militaire ou du médicin sanitaire	TITLE OR DEGREE Titre ou diplômé
(b)(6)	Medical Examiner
GRADE Grade: (b)(6)	INSTALLATION OR ADDRESS Installation ou adresse: Dover AFB, Dover DE
DATE Date: 6/12/2008	SIGNA (b)(6)

[1] State disease, injury or complication which caused death, but not
[2] State conditions contributing to the death, but not related to the disease or condition causing death
[1] Préciser la nature de la maladie, de la blessure ou de la complication qui a contribué à la mort, mais non la manière de mourir, telle qu 'un arrêt du coeur, etc
[2] Préciser le condition qui a contribué à la mort, mais n'ayant aucun rapport avec la maladie ou à la condition qui a provoqué la mort.

REPLACES DA FORM 3565, 1 JAN 72 AND DA FORM 3565-R(PAS), 26 SEP 75, WHICH ARE OBSOLETE.

DD FORM 1 APR 77 2064

MEDCOM 1030

ACLU Detainee DeathII ARMY MEDCOM 1030

ARMED FORCES INSTITUTE OF PATHOLOGY
Office of the Armed Forces Medical Examiner
1413 Research Blvd., Bldg. 102
Rockville, MD 20850
301-319-0000

AUTOPSY EXAMINATION REPORT

Name: BTB Mosleh, Mohammed Mazeon
ISN: (b)(6)
Date of Birth: Unknown
Date of Death (b)(6) 2008
Date/Time of Autopsy: 31 MAY 2008 @ 0930 hrs
Date of Report: 27 AUG 2008

Autopsy No.: (b)(6)
AFIP No. (b)(6)
Rank: Civilian Iraqi Detainee
Place of Death: Iraq
Place of Autopsy: Port Mortuary, Dover AFB, DE

Circumstances of Death: This detainee was found unresponsive on his sleeping mat when, as reported, his fellow detainees notified the guards and the chief of the compound. Medical personnel were sent, but they detected no signs of life. The decedent was pronounced dead shortly thereafter.

Authorization for Autopsy: Armed Forces Medical Examiner, per U.S. Code 10, Section 1471.

Identification: The deceased is identified by transportation records. Postmortem fingerprints, postmortem dental x-rays, and DNA sample are obtained.

CAUSE OF DEATH: **BIVENTRICULAR DILATION (DILATED CARDIOMYOPATHY)**

MANNER OF DEATH: **NATURAL**

ACLU Detainee DeathII ARMY MEDCOM 1031

EXTERNAL EXAMINATION

The body is that of a well-developed, well-nourished male. The body weighs 166 pounds, is 69 ½ inches in length. The body is cold. Rigor is present to an equal degree in all extremities. Lividity is present and fixed on the posterior surface of the body, except in areas exposed to pressure.

The head is normocephalic, and the scalp hair is black. Facial hair consists of a beard and mustache. The irides are hazel/green. The corneae are clear. The conjunctivae and sclerae are unremarkable. The external auditory canals are free of foreign material. The external nares contain blood. The oral cavity displays white/yellow foam. The nasal skeleton and maxilla are palpably intact. The lips are without evident injury. The teeth are natural and in good condition. Examination of the neck reveals no evidence of injury.

The torso is unremarkable. No evidence of injury of the ribs or the sternum is evident externally. The right lower quadrant of the abdomen displays an area of green discoloration.[1] No healed surgical scars are noted. The external genitalia are those of a circumcised adult. The upper back displays acne. The anus is unremarkable.

For injuries pertaining to the lower extremities, see "Evidence of Injury" below. There is a scab of the lateral left ankle measuring ¼ inch in maximum dimension. The remainder upper and lower extremities are unremarkable with no signs of intravenous puncture marks. Both feet display calluses on the dorsal and plantar surfaces. The fingernails are intact. No tattoos are noted on the body.

CLOTHING AND PERSONAL EFFECTS

Items on the body:

- White t-shirt
- White boxers

MEDICAL INTERVENTION

None

RADIOGRAPHS

A complete set of postmortem radiographs is obtained and demonstrates no skeletal abnormalities.

EVIDENCE OF INJURY

There is a 3/16 x 5/16 inch abrasion of the right cheek. There is a 1 ½ x 1 inch contusion of the right upper shin. There is a 3/16 x 1/8 inch superficial laceration on the dorsal surface of the left foot.[2]

1. Consistent with decomposition.
2. Consistent with terminal fall injuries

ACLU Detainee DeathII ARMY MEDCOM 1032

INTERNAL EXAMINATION

BODY CAVITIES:

The ribs, sternum, and vertebral bodies are visibly and palpably intact. No adhesions or abnormal collections of fluid are present in any of the body cavities. All body organs are present in normal anatomical position. The subcutaneous fat layer of the abdominal wall is 1/2inch thick.

HEAD (CENTRAL NERVOUS SYSTEM) AND NECK:

The galeal and subgaleal soft tissues of the scalp are free of injury. There are no skull fractures. The dura mater and falx cerebri are intact. There is no epidural or subdural hemorrhage present. The leptomeninges are thin and delicate. The cerebral hemispheres are symmetrical. The structures at the base of the brain, including cranial nerves and blood vessels are intact. The brain weighs 1420 grams, which has unremarkable gyri and sulci. Coronal sections through the cerebral hemispheres reveal no lesions. Transverse sections through the brain stem and cerebellum are unremarkable. The atlanto-occipital joint is stable.

The anterior strap muscles of the neck are homogenous and red-brown, without hemorrhage by layer-wise dissection. The thyroid cartilage and hyoid bone are intact. The larynx is lined by intact white mucosa. The tongue is free of bite marks, hemorrhage, or other injuries. Incision and dissection of the posterior neck demonstrates no deep paracervical muscular injury and no cervical spine fractures.

CARDIOVASCULAR SYSTEM:

"CPCR"Please see "Cardiovascular Pathology Consultation Report" below. The heart weighs 400 grams and is contained in an intact pericardial sac. The pericardial sac contains 30 milliliters of yellow fluid. The epicardial surface is smooth, with minimal fat investment. The coronary arteries are present in a normal distribution, with a right-dominant pattern. Cross sections of the vessels show no atherosclerotic luminal stenosis. The aorta gives rise to three intact and patent arch vessels. The renal and mesenteric vessels are unremarkable.

RESPIRATORY SYSTEM:

The upper airway displays white/yellow foam. The mucosal surfaces are smooth, yellow-tan and unremarkable. The pleural surfaces are smooth, glistening and unremarkable bilaterally. The pulmonary parenchyma is diffusely congested, exuding blood and frothy fluid; no focal non-traumatic lesions are noted. The pulmonary arteries are normally developed, patent and without thrombus or embolus. The right lung weighs 750 grams; the left weighs 600 grams.

ACLU Detainee DeathII ARMY MEDCOM 1033

HEPATOBILIARY SYSTEM:

The liver weighs 1530 grams and has an intact smooth capsule covering moderately congested tan-brown parenchyma with no focal lesions noted. The gallbladder contains 7 milliliters of green-brown, mucoid bile; the mucosa is velvety and unremarkable. The extrahepatic biliary tree is patent, without evidence of calculi.

GASTROINTESTINAL SYSTEM:

The esophagus is lined by gray-white, smooth mucosa. The gastric mucosa is arranged in the usual rugal folds and the lumen contains 200 of tan fluid and rice. The small and large bowels are unremarkable. The pancreas has a normal pink-tan lobulated appearance and the ducts are clear. The appendix is present.

GENITOURINARY SYSTEM:

The right and left kidneys weighs 140 grams each. The renal capsules are smooth and thin, semi-transparent and strip with ease from the underlying smooth, red-brown cortical surface. The cortices are sharply delineated from the medullary pyramids, which are red-purple to tan and unremarkable. The calyces, pelves and ureters are unremarkable.

The tan bladder mucosa overlies an intact bladder wall. The bladder contains approximately 300 milliliters of yellow urine. The testes, prostate gland and seminal vesicles are unremarkable.

LYMPHORETICULAR SYSTEM:

The 200 gram spleen has a smooth, intact capsule covering red-purple, moderately firm parenchyma; the lymphoid follicles are unremarkable. Lymph nodes in the hilar, periaortic and iliac regions are not enlarged.

ENDOCRINE SYSTEM:

The pituitary gland is left *in situ* and is unremarkable. The thyroid gland is symmetric and red-brown, without cystic or nodular change. The right and left adrenal glands are symmetric, with bright yellow cortices and red-brown medullae. The thymus weighs 20 grams and is unremarkable. No masses or areas of hemorrhage are identified.

MUSCULOSKELETAL SYSTEM:

The torso, back, anterior/posterior upper and lower extremities display no evidence of blunt force injury. No non-traumatic abnormalities of muscle or bone are identified.

ACLU Detainee DeathII ARMY MEDCOM 1034

MICROSCOPIC EXAMINATION

Selected portions of organs are retained in formalin with preparation of histology slides listed below:

Spleen, liver, adipose issue (slide 1): No pathological diagnosis

Left kidney and left lobes of the lung (slide 2): No pathological diagnosis, kidney with mild autolytic change, and lung sections display vascular congestion

Right kidney and pancreas (slide 3): No pathological diagnosis, kidney with mild autolytic change, and pancreas with diffuse autolytic change

Right lobes of the lung (slide 4): No pathological diagnosis

Adrenal glands (slide 5): No pathological diagnosis, mild autolytic change

Prostate gland (slides 6 & 7): No pathological diagnosis

Thyroid gland (slide 8): No pathological diagnosis

ADDITIONAL PROCEDURES

1. Documentary photographs are taken by OAFME.
2. Personal effects are released to the appropriate mortuary operations representatives.
3. Specimens retained for toxicology testing and/or DNA identification are: vitreous fluid, blood, urine, bile, gastric contents, spleen, liver, lung, kidney, adipose tissue and skeletal muscle.
4. The dissected organs are forwarded with body.

ACLU Detainee DeathII ARMY MEDCOM 1035

CARDIOVASCULAR PATHOLOGY CONSULTATION REPORT

FINAL DIAGNOSIS

DIAGNOSIS: (b)(6) **Biventricular dilatation (dilated cardiomyopathy)**

History: approximately 30 year old detainee found unresponsive in his cell, no evidence of foul play, toxicology negative

Heart: 420 grams; mildly increased epicardial fat; patent foramen ovale; biventricular dilatation: left ventricular cavity diameter 45 mm, left ventricular free wall thickness 12 mm, ventricular septum thickness 15 mm, right ventricle thickness 4 mm, without gross scars or abnormal fat infiltrates; mild endocardial thickening in left ventricular outflow tract; grossly unremarkable valves; no gross myocardial fibrosis or necrosis; histologic sections show mild left ventricular myocyte hypertrophy with patchy subendocardial interstitial fibrosis, otherwise unremarkable

Coronary arteries: Normal ostia; right dominance; no gross atherosclerosis

Conduction system: The sinoatrial node and sinus nodal artery are unremarkable. The compact atrioventricular (AV) node shows mild fragmentation within the central fibrous body, but is otherwise unremarkable. There is no dysplasia of the AV nodal artery. Focal adipose tissue and increased vascularity are present in the penetrating bundle, but there is no inflammation. The left proximal bundle branch is intact, and the right bundle branch is not seen in the sections. There are no discernible accessory conduction pathways between the AV node and ventricular septum.

Comment: There is biventricular dilatation, consistent with a non-ischemic cardiomyopathy. However, we cannot determine whether there is significantly increased heart weight without knowing the body weight of the deceased. A 420 gram heart would be a predicted normal weight for an adult male *weighing* approximately 255 lbs and is at the 95% upper confidence limit for someone weighing approximately 148 lbs. The etiology of dilated cardiomyopathy is unknown in up to 50% of cases.

(b)(6)

Medical Director

Blocks made: 11 (5 routine heart, 6 conduction system)
Slides made: 17 (11 H&E, 6 Movat)

ACLU Detainee DeathII ARMY MEDCOM 1036

FINAL AUTOPSY DIAGNOSES

I. **Biventricular Dilatation (Dilated Cardiomyopathy)**

II. **Evidence of Injury**
- A. Abrasion of the right cheek
- B. Contusion of the right upper shin
- C. Superficial laceration on the dorsal surface of the left foot

III. **Evidence of Medical Therapy:** None identified

IV. **Post-Mortem Changes:** As described above

V. **Identifying Body Marks:** None identified

VI. **Toxicology(AFIP)**
- A. CARBON MONOXIDE: Saturation in the blood was less than 1%
- B. CYANIDE: No cyanide detected in the blood
- C. VOLATILES: No ethanol detected in the blood and vitreous fluid
- D. DRUGS OF ABUSE: None were found in the urine

OPINION

This detainee (b)(6) died from complications of biventricular dilatation (dilated cardiomyopathy) that likely resulted in a cardiac arrhythmia (conduction abnormality).[3] Toxicology screen was negative. The manner of death is natural.

(b)(6)

(b)(6) Medical Examiner

(b)(6)

(b)(6) Medical Examiner

3. Akar, F. G. "Conduction abnormalities in nonischemic dilated cardiomyopathy: basic mechanisms and arrhythmic consequences." Trends Cardiovasc 15 (2005): 259-64.

ACLU Detainee DeathII ARMY MEDCOM 1037

CERTIFICATE OF DEATH *(OVERSEAS)*
Acte de décès (D'Outre-Mer)

NAME OF DECEASED *(Last, First, Middle)* Nom du décédé (Nom et prénoms)	GRADE Grade	BRANCH OF SERVICE Arme	SOCIAL SECURITY NUMBER Numéro de l'Assurance Social
BTB Mosleh, Mohammed, Mazeon		Civilian	(b)(6)
ORGANIZATION Organisation	NATION *(e.g. United States)* Pays	DATE OF BIRTH Date de naissance	[X] MALE [ ] FEMALE

RACE Race		MARITAL STATUS État Civil			RELIGION Culte		
[X]	CAUCASOID Caucasique	[ ]	SINGLE Célibataire	[ ] DIVORCED Divorcé	[ ]	PROTESTANT Protestant	[ ] OTHER (Specify) Autre (Spécifier)
[ ]	NEGROID Negroïde	[ ]	MARRIED Marié	[ ] SEPARATED Séparé	[ ]	CATHOLIC Catholique	[X]
[ ]	OTHER (Specify) Autre (Spécifier)	[ ]	WIDOWED Veuf		[ ]	JEWISH Juif	

NAME OF NEXT OF KIN Nom du plus proche parent	RELATIONSHIP TO DECEASED Parenté du décédé avec le sus
STREET ADDRESS Domicilé à (Rue)	CITY OR TOWN OR STATE *(Include ZIP Code)* Ville (Code postal compris)

MEDICAL STATEMENT Déclaration médicale

	CAUSE OF DEATH (Enter only one cause per line) Cause du décès (N'indiquer qu'une cause par ligne)	INTERVAL BETWEEN ONSET AND DEATH Intervalle entre l'attaque et le décès
DISEASE OR CONDITION DIRECTLY LEADING TO DEATH [1] Maladie ou condition directement responsable de la mort	Biventricular Dilation (Dilated Cardiomyopathy)	
ANTECEDENT CAUSES — MORBID CONDITION, IF ANY, LEADING TO PRIMARY CAUSE Condition morbide, s'il y a lieu, menant à la cause primaire		
Symptômes précurseurs de la mort — UNDERLYING CAUSE, IF ANY, GIVING RISE TO PRIMARY CAUSE Condition morbide, s'il y a lieu, menant à la cause primaire		
OTHER SIGNIFICANT CONDITIONS [2] Autres conditions significatives		

MODE OF DEATH Condition de décès		AUTOPSY PERFORMED Autopsie effectuée [X] YES Oui [ ] NO Non	CIRCUMSTANCES SURROUNDING DEATH DUE TO EXTERNAL CAUSES Circonstances de la mort suscitées par des causes extérieures
[X]	NATURAL Mort naturelle	MAJOR FINDINGS OF AUTOPSY Conclusions principales de l'autopsie	
[ ]	ACCIDENT Mort accidentelle		
[ ]	SUICIDE Suicide	NAME OF PATHOLOGIST Nom du pathologiste (b)(6)	
[ ]	HOMICIDE Homicide	(b)(6) DATE Date 31 May 2008	AVIATION ACCIDENT Accident à Avion [ ] YES Oui [X] NO Non

DATE OF DEATH *(day, month, year)* Date de décès (le jour, le mois, l'année)	PLACE OF DEATH Lieu de décès
(b)(6) 2008	Iraq

I HAVE VIEWED THE REMAINS OF THE DECEASED AND DEATH OCCURRED AT THE TIME INDICATED AND FROM THE CAUSES AS STATED ABOVE.
J'ai examiné les restes mortels du de funtet je conclue que le décès est survenu à l'heure indiquée et a, la suite des causes énumérées ci-dessus

NAME OF MEDICAL OFFICER Nom du médicin militaire ou du médicin sanitaire	TITLE OR DEGREE Titre ou diplôme
(b)(6)	Medical Examiner
GRADE Grade (b)(6)	INSTALLATION OR ADDRESS Installation ou adresse Dover AFB, Dover DE
DATE Date 8/22/2008	(b)(6)

[1] State disease, injury or complication which caused death
[2] State conditions contributing to the death, but not relati
[1] Préciser la nature de la maladie, de la blessure ou de la complication qui a provoqué la mort, mais non la manière de mourir, telle qu'un arrêt du cœur, etc
[2] Préciser la condition qui a contribué à la mort, mais n'ayant aucun rapport avec la maladie ou à la condition qui a provoqué la mort

DD FORM 1 APR 77 **2064** REPLACES DA FORM 3565, 1 JAN 72 AND DA FORM 3565-R(PAS), 26 SEP 75, WHICH ARE OBSOLETE.

MEDCOM 1038

ACLU Detainee DeathII ARMY MEDCOM 1038

ARMED FORCES INSTITUTE OF PATHOLOGY
Office of the Armed Forces Medical Examiner
1413 Research Blvd., Bldg. 102
Rockville, MD 20850
301-319-0000

FINAL AUTOPSY EXAMINATION REPORT

Name: BTB Marush, Muhammad Fahdil Khamat
SSAN: (b)(6)
Date of Birth (b)(6) 1968
Date of Deat (b)(6) 2008
Date and time of Autopsy: 10 DEC 2008 9:00 AM
Date of Report: 06 FEB 2009

Autopsy No. (b)(6)
AFIP No. (b)(6)
Rank: CIV
Place of Death: Balad, Iraq
Place of Autopsy: Port Mortuary
Dover AFB, Dover DE

Circumstances of Death: Iraqi detainee with history of remote penetrating head injury found unresponsive

Authorization for Autopsy: Office of the Armed Forces Medical Examiner, IAW 10 USC 1471

Identification: Positive identification by Fingerprint

CAUSE OF DEATH: Complications of penetrating head injury

MANNER OF DEATH: Undetermined

ACLU Detainee DeathII ARMY MEDCOM 1039

EXTERNAL EXAMINATION

The body is that of a well-developed, well-nourished male that weighs 139 pounds, is 69 inches in length and appears compatible with the reported age of 40 years. The body is cold after refrigeration. Rigor is present to an equal degree in all extremities. Lividity is present and fixed on the posterior surface of the body, except in areas exposed to pressure. The head shows evidence of medical therapy to be further described below. The scalp hair is black and shaved. Facial hair consists of a black mustache and beard. The irides are brown. The corneae are clear. The conjunctivae are unremarkable. The sclerae are white. The external auditory canals, external nares and oral cavity are free of foreign material and abnormal secretions. The nasal skeleton and maxilla are palpably intact. The lips are without evident injury. There are multiple remotely missing maxillary and mandibular teeth. The remaining teeth are natural and in fair condition. Examination of the neck reveals no evidence of injury. The chest is unremarkable. No evidence of injury of the ribs or the sternum is evident externally. The abdomen is flat. A healed 7 inch scar is present on the medial surface of the left upper arm and 2 ¼ inch scar is present on the lateral surface. The external genitalia are those of a normal adult circumcised male. The posterior torso and anus are without note. The extremities show evidence of injury to be further described below. The fingernails are intact. (b)(6) tattoo (b)(6)
(b)(6) tattoo (b)(6)
(b)(6)

CLOTHING AND PERSONAL EFFECTS

- The body is received nude for examination.

MEDICAL INTERVENTION

- A gauze bandage is present over the head
- An 11 ½ inch stapled incision extends across the biparietal and frontal regions of the scalp
- A 2 ½ inch stapled incision extends posteriorly from the biparietal incision to the right parietal region
- A 2 inch stapled incision extends posteriorly from the biparietal incision to the left parietal region
- Three drains exit the scalp in the occipital vertex region
- Internal examination shows a bilateral craniectomy with removal of the majority of the biparietal regions of the calvarium
- Sutured therapeutic needle puncture sites are present in the right subclavian region and the right inguinal region

RADIOGRAPHS

A complete set of postmortem radiographs is obtained and, in addition to the above demonstrates multiple metallic fragments in the left frontal region. These are not recovered.

ACLU Detainee DeathII ARMY MEDCOM 1040

EVIDENCE OF INJURY

The ordering of the following injuries is for descriptive purposes only, and is not intended to imply order of infliction or relative severity.

Injuries of the head and neck:

There is an 8 x ¾ inch cluster of punctate abrasions on the forehead. A ⅜ x ¼ inch healing wound is present on the left side of the forehead.

Injuries of the extremities:

Incision of both wrists reveals subcutaneous hemorrhage of the dorsal radial surfaces measuring up to 2 inches on the right and up to 1 ¾ inches on the left.

INTERNAL EXAMINATION

BODY CAVITIES:

The body is opened by the usual thoraco-abdominal incision and the chest plate is removed. The ribs, sternum, and vertebral bodies are visibly and palpably intact. No adhesions or abnormal collections of fluid are present in any of the body cavities. All body organs are present in normal anatomical position. The subcutaneous fat layer of the abdominal wall is ¼ inch thick.

HEAD AND CENTRAL NERVOUS SYSTEM:
(See above "Evidence of Therapy")

The scalp is reflected. The galeal and subgaleal soft tissues of the scalp are free of injury. There are no skull fractures. The remainder of the calvarium is removed. Approximately 1 ml of turbid liquid material is expressed from the anterior region of the remaining central dura. The structures at the base of the brain, including cranial nerves and blood vessels are intact. The brain weighs 1700 grams. The atlanto-occipital joint is stable. The upper spinal cord is unremarkable. (See Neuropathological Consultation)

NECK:

The anterior strap muscles of the neck are homogenous and red-brown, without hemorrhage by layer-wise dissection. The thyroid cartilage and hyoid bone are intact. The larynx is lined by intact white mucosa. The tongue is free of bite marks, hemorrhage, or other injuries.

CARDIOVASCULAR SYSTEM:

The 340 gram heart is contained in an intact pericardial sac. The epicardial surface is smooth, with minimal fat investment. The coronary arteries are present in a normal distribution, with a right-dominant pattern. Cross sections of the vessels show widely patent lumina. The myocardium is homogenous, red-brown, and firm. The valve leaflets are thin and mobile. The endocardium is

ACLU Detainee DeathII ARMY MEDCOM 1041

smooth and glistening. The aorta gives rise to three intact and patent arch vessels. The renal and mesenteric vessels are unremarkable.

RESPIRATORY SYSTEM:

The upper airway is clear of debris and foreign material; the mucosal surfaces are smooth, yellow-tan and unremarkable. The pleural surfaces are smooth, glistening and unremarkable bilaterally. The pulmonary parenchyma is diffusely congested, exuding slight to moderate amounts of blood and frothy fluid; no focal lesions are noted. The pulmonary arteries are normally developed, patent and without thrombus or embolus. The right lung weighs 680 grams; the left 500 grams.

HEPATOBILIARY SYSTEM:

The 1180 gram liver has an intact smooth capsule covering moderately congested tan-brown parenchyma with no focal lesions noted. The gallbladder contains 12 ml of thick green-brown, mucoid bile; the mucosa is velvety and unremarkable. The extrahepatic biliary tree is patent, without evidence of formed calculi, however, the bile contains numerous yellowish-tan particles. The gallbladder is mildly distended.

GASTROINTESTINAL SYSTEM:

The esophagus is lined by gray-white, smooth mucosa. The gastric mucosa is arranged in the usual rugal folds and the lumen contains 300 ml of tan food material. The small and large bowel are unremarkable. The pancreas has a normal pink-tan lobulated appearance and the ducts are clear. The appendix is present.

GENITOURINARY SYSTEM:

The right kidney weighs 140 grams; the left 160 grams. The renal capsules are smooth, semi-transparent and strip with ease from the underlying smooth, red-brown cortical surface. The cortices are sharply delineated from the medullary pyramids, which are red-purple to tan and unremarkable. The calyces, pelves and ureters are unremarkable. White bladder mucosa overlies an intact bladder wall. The bladder is empty. The testes, prostate gland and seminal vesicles are without note.

LYMPHORETICULAR SYSTEM:

The 180 gram spleen has a smooth, intact capsule covering red-purple, moderately firm parenchyma; the lymphoid follicles are unremarkable. Lymph nodes in the hilar, periaortic and iliac regions are not enlarged.

ENDOCRINE SYSTEM:

The thyroid gland is symmetric and red-brown, without cystic or nodular change. The right and left adrenal glands are symmetric, with bright yellow cortices and red-brown medullae. No masses or areas of hemorrhage are identified.

ACLU Detainee DeathII ARMY MEDCOM 1042

MUSCULOSKELETAL SYSTEM:

No non-traumatic abnormalities of muscle or bone are identified.

NEUROPATHOLOGICAL CONSULTATION

GROSS DESCRIPTION:

Brain weight: 1528 gm

The specimen consists of an irregular 6 x 4 cm fragment of dura and the brain of an adult. The central portion of the dura is thickened and sclerotic. The subdural surface is covered by a 0.2 - 0.4 cm thick granular red-brown layer of adherent coagulated blood which contains fine shiny particles consistent with metallic fragments. There is a deep groove due to cerebral craniectomy herniation over each cerebral hemisphere. On the right, the area of cerebral herniation is approximately 12 x 8 cm and involves the dorsal/lateral surfaces of the frontal and parietal lobes and the anterior/lateral occipital lobe. On the left the area of the craniotomy herniation is 8 x 6 cm and involves the dorsal/lateral frontal lobe and the anterior and lateral temporal lobe. There are multifocal, small perivascular subarachnoid hemorrhages along the cortical grooves of the craniectomy herniation. The herniated cerebral cortex is markedly swollen, discolored a dusky gray and focally hemorrhagic and necrotic. There is no net midline shift due to the decompressive effect of the craniectomies but there is severe central transtentorial and transforamen magnum herniation. Deep bilateral tentorial grooves indent each uncus approximatcly 0.8 cm from the medial margins and the herniated cortex is necrotic. The diencephalon and internal capsules are markedly compressed elongated and hemorrhagic due to central transtentorial herniation. These hemorrhages are continuous with Duret hemorrhages in the tegmentum and base of the pons and the midbrain. A deep foramen magnum groove indents each cerebellar tonsil. The leptomeninges are moderately cloudy over the cerebral convexities. Elsewhere, they are thin, delicate and transparent. The perisellar, perimesencephalic and cerebellomedullary cisterns are compressed and effaced due to brain swelling. The arteries at the base of the brain follow a normal distribution and there are no aneurismal dilatations or sites of occlusion.

Coronal sections of the cerebrum reveal the above noted changes. There is cavitary necrosis of the left frontal lobe and disruption of the frontal pole cortex. The cavity causes destruction of the left frontal white matter, the striate body, the anterior corpus callosum, the septum pellucidum and the fornices.

MICROSCOPIC EXAMINATION:

Blocks of tissue for microscopic examination are removed from: (1) left frontal lobe, (2) midcorpus callosum/caudate/internalcapsule, (3) left hippocampus, (4) left thalamus/subthalamus/substantianigra, (5) right parietal lobe, (6) left occipital lobe (calcarinecortex), (7) cerebellum, (8) midbrain and (9) pons Sections from each block are stained with H&E, and LFB techniques and immunostained for GFAP and β-amyloid.

ACLU Detainee DeathII ARMY MEDCOM 1043

MICROSCOPIC FINDINGS:

Sections show generalized acute brain edema, congestion, focal hemorrhages and bland necrosis with no inflammation or granulation tissue. The hemorrhages are related to the craniectomy herniation margins as well as the subthalamic and rostral brainstem (Duret hemorrhages). There is no accumulation of macrophages and there is no leptomeningeal inflammation. This suggests that the severe brain swelling and central herniation resulted in compression of the penetrating blood vessels with necrosis without cellular infiltrate because of compression of regional blood flow. Surrounding the damaged areas there is widespread axonal injury (positive axons) in a vascular pattern.

COMMENT:

The pattern is consistent with a process such as cerebritis associated with metallic foreign bodies due to a penetrating injury resulting in massive brain swelling requiring bilateral craniectomies. The antibiotic treatment with drainage may have obscured the inflammation but the brain swelling progressed to central transtentorial herniation with subthalamic and rostral brainstem herniation hemorrhages.

ADDITIONAL PROCEDURES

1. Documentary photographs are taken by the OAFME photographer.
2. Specimens retained for toxicology testing and/or DNA identification are: vitreous fluid, blood, spleen, liver, lung, kidney, myocardium, bile, gastric contents, adipose tissue and psoas muscle.
3. The brain is retained for further examination. The remaining dissected organs are forwarded with the body.
4. Selected portions of organs are retained in formalin.

ACLU Detainee DeathII ARMY MEDCOM 1044

FINAL AUTOPSY DIAGNOSES

I. History of penetrating head injury
   A. Cavitary necrosis of the left frontal lobe
   B. Cerebral edema
      1. Cerebral craniectomy herniation with focal hemorrhage and necrosis
      2. Central transtentorial herniation with subthalamic and rostral brainstem herniation hemorrhages
   C. Retained intracranial metallic fragments

II. Additional injuries:
   A. Punctate abrasions of the forehead
   B. Healing wound of the left side of the forehead
   C. Blunt force injury of both wrists

III. Additional findings:
   A. Bilateral pulmonary congestion (right 680 mg, left 500 mg)

IV. Toxicology: Lidocaine present in the blood

OPINION

This 40 year old male civilian died of complications arising from penetrating head injury. According to reports, the decedent presented with a history of previous gunshot wound of the head with complaints of headache, diplopia, emesis and dizziness. He underwent CT and bilateral craniectomies for brain edema. The decedent's clinical status steadily declined postoperatively until his demise.

Autopsy examination showed extensive cerebral edema (brain swelling), cavitary necrosis of the left frontal lobe and minute metallic fragments. Additional injuries included punctate abrasions of the forehead (consistent with medical therapy) and evidence of blunt force injury to both wrists. No evidence of additional significant injury or natural disease was identified. Postmortem toxicological examination showed only the therapeutic agent lidocaine.

Since the exact etiology of the penetrating injury and the circumstances under which it occurred are uncertain, the manner of death is best classified as undetermined.

(b)(6)

(b)(6) Medical Examiner (b)(6)

ACLU Detainee DeathII ARMY MEDCOM 1045

CERTIFICATE OF DEATH *(OVERSEAS)*
Acte de décès (D'Outre-Mer)

NAME OF DECEASED *(Last, First, Middle)* Nom du décédé (Nom et prénoms)	GRADE Grade	BRANCH OF SERVICE Arme	SOCIAL SECURITY NUMBER Numéro de l'Assurance Social
BTB Marush, Muhammad, Fahdil Khamat		Civilian	(b)(6)

ORGANIZATION Organisation	NATION *(e.g. United States)* Pays	DATE OF BIRTH Date de naissance	SEX Sexe
	Iraq	(b)(6) 1968	[X] MALE [ ] FEMALE

RACE Race		MARITAL STATUS État Civil			RELIGION Culte		
[X]	CAUCASOID Caucasique	[ ]	SINGLE Célibataire	[ ] DIVORCED Divorcé	[ ] PROTESTANT Protestant	[X]	OTHER (Specify) Autre (Spécifier) UNK
[ ]	NEGROID Negroide	[ ]	MARRIED Marié	[ ] SEPARATED Séparé	[ ] CATHOLIC Catholique		
[ ]	OTHER (Specify) Autre (Spécifier)	[ ]	WIDOWED Veuf		[ ] JEWISH Juif		

NAME OF NEXT OF KIN Nom du plus proche parent	RELATIONSHIP TO DECEASED Parenté du décédé avec le sus
STREET ADDRESS Domicilié à (Rue)	CITY OR TOWN OR STATE *(Include ZIP Code)* Ville (Code postal compris)

MEDICAL STATEMENT Déclaration médicale

	CAUSE OF DEATH (Enter only one cause per line) Cause du décès (N'indiquer qu'une cause par ligne)	INTERVAL BETWEEN ONSET AND DEATH Intervalle entre l'attaque et le décès
DISEASE OR CONDITON DIRECTLY LEADING TO DEATH [1] Maladie ou condition directement responsable de la mort.	Complications of penetrating head injury	Months
ANTECEDENT CAUSES Symptômes précurseurs de la mort. MORBID CONDITION, IF ANY, LEADING TO PRIMARY CAUSE Condition morbide, s'il y a lieu, menant à la cause primaire		
UNDERLYING CAUSE, IF ANY, GIVING RISE TO PRIMARY CAUSE Condition morbide, s'il y a lieu, menant à la cause primaire		
OTHER SIGNIFICANT CONDITIONS [2] Autres conditions significatives		

MODE OF DEATH Condition de décès	AUTOPSY PERFORMED Autopsie effectuée	CIRCUMSTANCES SURROUNDING DEATH DUE TO EXTERNAL CAUSES Circonstances de la mort suscitées par des causes extérieures
[ ] NATURAL Mort naturelle	[X] YES Oui [ ] NO Non	Mode of Death : Undetermined
[ ] ACCIDENT Mort accidentelle	MAJOR FINDINGS OF AUTOPSY Conclusions principales de l'autopsie	
[ ] SUICIDE Suicide	NAME OF PATHOLOGIST Nom du pathologiste (b)(6)	
[ ] HOMICIDE Homicide	SIGNATURE (b)(6) DATE Date 10 December 2008	AVIATION ACCIDENT Accident à Avion [ ] YES Oui [X] NO Non

DATE OF DEATH *(day, month, year)* Date de décès (le jour, le mois, l'année)	PLACE OF DEATH Lieu de décès
(b)(6) 2008 2245	Air Force Theater Hospital, Joint Base Balad Iraq

I HAVE VIEWED THE REMAINS OF THE DECEASED AND DEATH OCCURRED AT THE TIME INDICATED AND FROM THE CAUSES AS STATED ABOVE.
J'ai examiné les restes mortels du dé funtet je conclus que le décès est survenu à l'heure indiquée et à, la suite des causes énumérées ci-dessus.

NAME OF MEDICAL OFFICER Nom du médecin militaire ou du médecin assermenté	TITLE OR DEGREE Titre ou diplôme
(b)(6)	Medical Examiner

GRADE Grade	INSTALLATION OR ADDRESS Installation ou adresse
(b)(6)	Dover AFB, Dover DE
DATE Date 2/10/2009	SIGNATURE (b)(6)

[1] State disease, injury or complication which caused death, but not mode of dying such as heart failure, ect.
[2] State conditions contributing to the death, but not related to the disease or condition causing death.
[1] Préciser la nature de la maladie, de la blessure ou de la complication qui a contribué à la mort, mais non la manière de mourir, telle qu'un arrêt du coeur, etc.
[2] Préciser le condition qui a contribué à la mort, mais n'ayant aucun rapport avec la maladie ou à la condition qui a provoqué la mort.

DD FORM 1 APR 77 2064 REPLACES DA FORM 3565, 1 JAN 72 AND DA FORM 3565-R(PAS), 26 SEP 75, WHICH ARE OBSOLETE.

MEDCOM 1046

ACLU Detainee DeathII ARMY MEDCOM 1046

(REMOVE, REVERSE AND RE-INSERT CARBONS BEFORE COMPLETING THIS SIDE)

DISPOSITON OF REMAINS

NAME OF MORTICIAN PREPARING REMAINS	GRADE	LICENSE NUMBER AND STATE	OTHER

INSTALLATION OR ADDRESS	DATE	SIGNATURE
(b)(6)		

NAME OF CEMETERY OR CREMATORY	LOCATION OF CEMETERY OR CREMATORY

TYPE OF DISPOSTION	DATE OF DISPOSTION

REGISTRATION OF VITAL STATISTICS

REGISTRY *(Town and Country)*	DATE REGISTERED	FILE NUMBER	
		STATE	OTHER

NAME OF FUNERAL DIRECTOR	ADDRESS

SIGNATURE OF AUTHORIZED INDIVIDUAL

DD FORM 2064, APR 1977 (BACK) *USAPA V1.00*

ACLU Detainee DeathII ARMY MEDCOM 1047

ARMED FORCES INSTITUTE OF PATHOLOGY
Office of the Armed Forces Medical Examiner
1413 Research Blvd., Bldg. 102
Rockville, MD 20850
301-319-0000

AUTOPSY EXAMINATION REPORT

Name: BTB HUSAYN, Husayn Kazim
SSAN (b)(6)
Date of Birth: (b)(6) 1972

Autopsy No. (b)(6)
AFIP No. (b)(6)
Rank: Detainee

Date of Death: (b)(6) 2008
Place of Death: 115th Combat Support Hospital, Camp Bucca, Iraq

Date and Time of Autopsy: 27 SEP 2008, 1130
Place of Autopsy: Port Mortuary, Dover AFB, DE

Date of Report: 5 NOV 2008

Circumstances of Death: This 35-year-old male detainee reportedly was sitting in a holding room when he collapsed with seizure like activity. First responders initiated cardiopulmonary resuscitation (CPR) immediately and continued for 15 minutes until medical personnel arrived on scene. Upon medic arrival, the decedent was noted to have no vital signs. He was taken to the 115th Combat Support Hospital at Camp Bucca where he was pronounced dead shortly after arrival.

Authorization for Autopsy: Armed Forces Medical Examiner, IAW 10 USC 1471

Identification: Presumptive identification by incarceration number

CAUSE OF DEATH: Undetermined

MANNER OF DEATH: Undetermined

ACLU Detainee DeathII ARMY MEDCOM 1048

On 27 September 2008 at 1130, a complete postmortem examination is performed on the body of (b)(6) who was presumptively identified by his incarceration number.

CID Special Agent (b)(6) attends the autopsy.

EXTERNAL EXAMINATION

The body is received dressed in a white tee shirt, yellow pants, and white boxers. The body is that of a well-developed, well-nourished, adult male that is cold from refrigeration. He is 66 inches long, weighs 123 pounds, and appears consistent with the reported age of 35 years. Rigor mortis is dissipated. Postmortem lividity is fixed on the posterior surface of the body with moderate suffusion of the head and shoulders.

The head is covered with short black mixed with gray hair in a normal distribution. The irides are brown, corneas are dull, and the sclerae are white. The pupils are round and equal in diameter. No contact lenses are present. Scattered conjunctival petechiae are seen in both eyes. The nose is unremarkable. No foreign material is present in the nostrils or the oral cavity. The lips and frenula are atraumatic. Natural teeth are present with severe dental carries. The external auditory canals are free of blood. The ears are unremarkable and not pierced. The face has a well trimmed mustache and beard. The neck has no masses or deformities. The chest is covered with hair with no increase in the anteroposterior diameter. The abdomen is covered by hair and not distended. The external genitalia are those of a circumcised adult male. The testes are descended and free of masses. Pubic hair is present in a normal distribution. The anus and buttocks are unremarkable. There are confluent areas of Tardieu-like spots on the lateral aspect of the back. The upper and lower extremities are symmetric and without clubbing or edema.

The following tattoos are seen on the body.

- (b)(6)
-
-

CLOTHING AND PERSONAL EFFECTS

- White tee shirt
- Yellow pants
- White boxer short

MEDICAL INTERVENTION

- Endotracheal tube inserted appropriately
- Intravenous catheter inserted in the right antecubital fossa

POSTMORTEM ARTIFACTS

None

ACLU Detainee DeathII ARMY MEDCOM 1049

RADIOGRAPHS

A complete set of total body postmortem radiographs is obtained and shows evidence of medical therapy. No fractures or foreign materials are seen.

EVIDENCE OF INJURY

The chest has an approximately 5 x 2-inch contusion at the midchest section, slightly right of the anterior midline. The sternum is fractured at the level of the 4th rib. There is a focal hemorrhage of the external muscle tissue of the right 4th intercostal space.

INTERNAL EXAMINATION

BODY CAVITIES:
The body is opened with a standard Y-shaped incision. The abdominal panniculus is 2.5-cm thick at the umbilicus. The muscles of the chest and abdominal walls are normal. The rib cage, sternum, and clavicles are intact. The mediastinum is unremarkable. The visceral and parietal pleural surfaces are smooth and glistening except for several foci of pleural adhesions of the anterior and apical aspects of both lungs. There is no blood or fluid in the pericardial sac or the peritoneal cavity. The right and left pleural cavities contain 20 ml and 10 ml of clear fluid, respectively. The organs occupy their usual anatomic positions within the pleural and peritoneal cavities. There is no evidence of pericarditis or peritonitis. The omentum and retroperitoneum are unremarkable.

HEAD AND CENTRAL NERVOUS SYSTEM:
The cranial cavity is opened with a coronal incision of the scalp and removal of the calvarium. The galeal and subgaleal soft tissues of the scalp are free of injury. The calvarium is intact, as is the dura mater beneath it. There is no evidence of epidural, subdural, or subarachnoid hemorrhage. The brain weighs 1520 gm. The leptomeninges are transparent. The gyral pattern and sulci are unremarkable. The major vessels at the base of the brain have the usual anatomic distribution and no significant atherosclerosis is found. The cranial nerves are symmetrical and intact. No evidence of herniation is present. Coronal sections through the cerebral hemispheres reveal no lesions. The ventricles are of normal size and contain clear cerebrospinal fluid. Transverse sections through the brain stem and cerebellum are unremarkable. There are no skull fractures. The atlanto-occipital joint is stable. The spinal cord is not examined in its entirety.

NECK:
The larynx and trachea are in the midline. There is no hemorrhage in the skin, fat or sternocleidomastoid muscles of the anterior neck. In situ layer-wise dissection of the neck's strap muscles shows no abnormalities. The thyroid cartilage and hyoid bone are intact. The larynx has smooth pink-tan mucosa without focal lesions. No foreign material is present. The tongue is free of bite marks, hemorrhage, or other injuries. The soft tissues of the neck are free of hemorrhage. No fractures or dislocations of the cervical vertebrae are detected.

ACLU Detainee DeathII ARMY MEDCOM 1050

CARDIOVASCULAR SYSTEM:
The 340-gm heart is contained in an intact pericardial sac. The epicardial surface is smooth, with minimal fat investment. There are no epicardial petechiae. The coronary arteries are present in a normal distribution with a right dominant pattern. Multiple cross sections of the vessels show focal soft atheroma in the left anterior descending and left circumflex coronary arteries. The left main coronary artery is patent. The left anterior descending coronary artery is focally (75%) narrowed at approximately 3 cm downstream from the origin and 50% focal narrowing of the lumen within 1 cm distal of the more severe lesion. The circumflex coronary artery shows focal 25% narrowing of its lumen. The right coronary artery is grossly unremarkable. Thrombosis of the coronary arteries is not present. The myocardium is homogenous, dark red-brown, and soft with no gross myocardial fibrosis noted. No defects in the atrial or ventricular septa are present. The valve leaflets are thin and mobile. The circumferences of the cardiac valves are within normal limit for age and heart size. The left ventricle measures 1.4 cm, right ventricle 0.4 cm, and interventricular septum 1.3 cm in thickness. The endocardium is smooth and glistening.

The aorta gives rise to three intact and patent arch vessels. There are soft atheromas of the intima throughout its length. No evidence of aneurysm, coarctation, dissection, or laceration of the aorta is noted. The renal and mesenteric vessels are unremarkable.

RESPIRATORY SYSTEM:
The right and left lungs weigh 760 and 700 gm, respectively. The trachea is complete, without malformation, from the larynx to the carina. There is no aspirated gastric material or aspirated blood in the trachea. The lungs and hilar nodes are moderately anthracotic. There are several small blebs of approximately 2 – 3 mm in maximum dimension at the apex of the upper lobe of the right lung. On cut section, there is no aspirated blood apparent. The pulmonary parenchyma is diffusely congested and edematous. There is no consolidation present. The upper lobe of the left lung has a small focus of calcification near the periphery. There is no pulmonary contusion. Pulmonary thromboemboli are not present.

HEPATOBILIARY SYSTEM:
The 1280-gm liver has a smooth capsule and a sharp anterior border. The parenchyma is reddish-brown and has a lobular architecture. No mass lesions or other abnormalities are seen. The gallbladder is present and contains green-black mucoid bile and no stones. The mucosal surface is green and velvety. The extrahepatic biliary tree is patent.

HEMOLYMPHATIC SYSTEM:
The 80-gm intact spleen has a red, purple capsule. The parenchyma is maroon, with distinct Malpighian corpuscles. Lymph nodes are not prominent in the cervical region, thoracic or peritoneal cavities.

UROGENITAL SYSTEM:
The right and left kidneys weigh 120 and 140 gm, respectively. The renal capsules strip with ease from the underlying smooth cortical surfaces. There is a small 4-mm simple cyst containing clear fluid on the right cortical surface. The cut surfaces are red-tan, with uniformly thick cortices and sharp corticomedullary junctions. The kidneys are congested. The pelves are unremarkable and the ureters are normal in course and caliber. There are no stones or tumors in

ACLU Detainee DeathII ARMY MEDCOM 1051

the kidneys, pelves, ureters, or bladder. White bladder mucosa overlies an intact bladder wall. The bladder contains a scant amount of urine. The prostate is normal in size, with lobular, yellow-tan parenchyma. The seminal vesicles are unremarkable. The testes are free of mass lesions, contusions, or other abnormalities.

GASTROINTESTINAL TRACT:
The esophagus is intact and lined by smooth, grey-white mucosa. The stomach contains 200 ml of dark tan-brown congealed food particles. The gastric mucosa shows no focal lesion. The gastric wall is intact. The small and large intestines are unremarkable. The appendix is present.

ENDOCRINE SYSTEM:
The thyroid gland is normal in size and symmetric with dark red-brown parenchyma. No masses are present.

The right and left adrenal glands are symmetric, with bright yellow cortices and grey medullae. No masses or areas of hemorrhage are identified.

PANCREAS:
The pancreas is firm and yellow-tan, with the usual lobular architecture. No mass lesions or other abnormalities are seen.

MUSCULOSKELETAL SYSTEM:
The vertebral column and pelvis are visibly and palpably intact. The musculature is normally developed and of the usual color and consistency.

OTHER PROCEDURES

1. Photographic evidence is obtained by the OAFME photographers.
2. Specimens for toxicology: blood, bile, vitreous, urine, gastric content, liver tissue, kidney tissue, lung tissue, spleen tissue, brain tissue, heart tissue, and adipose tissue.
3. Specimen for DNA analysis: psoas muscle.
4. Representative tissue samples are retained in formalin.
5. Dissected organs are forwarded with the body.
6. Clothing articles are retained by CID.

MICROSCOPIC EXAMINATION

Slide key:
(1) Left anterior descending coronary artery; (2) Sinoatrial (SA) nodal region; (3 – 4) Atrioventricular (AV) nodal region; (5) Anterior left ventricular wall; (6) Lateral left ventricular wall; (7) Posterior left ventricular wall; (8) Interventricular septum; (9 – 13) Lungs; (14) Liver, spleen, pancreas; (15) Kidneys, adrenal glands, thyroid; (16) Pons; (17) Medulla; (18) Upper cervical cord; (19) Cerebellum; (20) Frontal lobe; (21) Hippocampus; (22) Basal ganglia; (23) Occipital lobe.

ACLU Detainee DeathII ARMY MEDCOM 1052

Heart: left anterior descending coronary artery shows thickening of the intima with foamy macrophages and fibrosis resulting in approximately 50% luminal narrowing. See consultation report below for additional information.

Lungs: congestion and moderate anthracosis, mild emphysematous changes of the periphery

Liver: portal areas show no increase in inflammatory cells infiltrate with unremarkable arterial and bile duct structures, mild congestion of the central vein regions

Spleen: no pathologic changes

Pancreas: autolyzed

Kidneys: congestion

Adrenal glands: congestion

Thyroid: no pathologic changes

Brain and spinal cord: no pathologic changes

ARMED FORCES INSTITUTE OF PATHOLOGY CONSULTATION
Cardiovascular Pathology

There is mild to moderate atherosclerosis of the LAD with --- intimal thickening with minimal intraplaque hemorrhage. The conduction fibers at the level of the penetrating / branching bundles demonstrate dilated vascular space (? lymphatic) and a small amount of fat which is a natural variant. I do not identify a morphologic substrate for sudden death. The few lymphocytes in the atrial tissue on slide 2 are of no significance.

(b)(6)

Chief of Cardiovascular Pathology

ACLU Detainee DeathII ARMY MEDCOM 1053

FINAL AUTOPSY DIAGNOSES:

I. Natural disease diagnoses
- A. Mild to moderate atherosclerotic cardiovascular disease
  - a. Gross 50 – 70% luminal narrowing of the left anterior coronary artery
  - b. Gross 25% luminal narrowing of the circumflex artery
  - c. Soft atheroma of the aorta
- B. Mild emphysematous changes of the lung with small peripheral air blebs
- C. Simple cortical cyst of the right kidney

II. Other finding
- A. Pulmonary congestion and edema
- B. Moderate pulmonary anthracosis

III. Medical therapy
- A. Cardiopulmonary resuscitation injuries
  - a. Fracture of the sternum
  - b. Focal hemorrhage of the external muscle tissue of the right 4th intercostal space
  - c. Contusion at the midchest section
- B. Endotracheal tube inserted appropriately
- C. Intravenous catheter inserted in the right antecubital fossa

IV. Identifying marks
- A. (b)(6)
- B.
- C.

V. Toxicology results
- A. No ethanol detected in the blood and vitreous fluid
- B. Carboxyhemoglobin saturation in the blood less than 1%
- C. No cyanide detected in the blood
- D. No common screened drugs detected in the blood, except atropine

ACLU Detainee DeathII ARMY MEDCOM 1054

OPINION

This 35-year-old male died from unknown causes. The terminal event of a sudden collapse suggested a cardiac anomaly as a possible cause of death. The autopsy revealed mild to moderate atherosclerotic cardiovascular disease, however, no definitive anatomical cause of death could be identified. Toxicology analysis of the postmortem sample was negative for volatiles, carbon monoxide, cyanide, and common screened drugs. The focal injuries of the chest were most consistent with cardiopulmonary resuscitation.

Based on available investigation and autopsy finding, the cause and manner of death are classified as undetermined.

(b)(6)

(b)(6) **Medical Examiner**

(b)(6)

(b)(6) **Armed Forces Medical Examiner**

ACLU Detainee DeathII ARMY MEDCOM 1055

CERTIFICATE OF DEATH *(OVERSEAS)*
Acte dé décès (D'Outre-Mer)

NAME OF DECEASED (Last, First, Middle) Nom du décédé (Nom et prénoms)	GRADE Grade	BRANCH OF SERVICE Arme	SOCIAL SECURITY NUMBER Numéro de l'Assurance Social
Husayn, Husayn, Kazim		Civilian	(b)(6)
ORGANIZATION Organisation	NATION (e.g. United States) Pays: Iraq	DATE OF BIRTH Date de naissance	SEX Sexe: ☐ MALE ☐ FEMALE

RACE Race		MARITAL STATUS État Civil		RELIGION Culte		
X	CAUCASOID Caucasique		SINGLE Célibataire		DIVORCED Divorcé	PROTESTANT Protestant		OTHER (Specify) Autre (Spécifier)
	NEGROID Negroide		MARRIED Marié		SEPARATED Séparé	CATHOLIC Catholique	X	
	OTHER (Specify) Autre (Spécifier)		WIDOWED Veuf			JEWISH Juif		

NAME OF NEXT OF KIN Nom du plus proche parent	RELATIONSHIP TO DECEASED Parenté du décédé avec le sus
STREET ADDRESS Domicilé à (Rue)	CITY OR TOWN OR STATE *(Include ZIP Code)* Ville (Code postal compris)

MEDICAL STATEMENT Déclaration médicale

	CAUSE OF DEATH (Enter only one cause per line) Cause du décès (N'indiquer qu'une cause par ligne)	INTERVAL BETWEEN ONSET AND DEATH Intervalle entre l'attaque et le décès
DISEASE OR CONDITON DIRECTLY LEADING TO DEATH [1] Maladie ou condition directement responsable de la mort. [1]	Undetermined	
ANTECEDENT CAUSES Symptômes précurseurs de la mort. — MORBID CONDITION, IF ANY, LEADING TO PRIMARY CAUSE Condition morbide, s'il y a lieu, menant à la cause primaire		
ANTECEDENT CAUSES Symptômes précurseurs de la mort. — UNDERLYING CAUSE, IF ANY, GIVING RISE TO PRIMARY CAUSE Condition morbide, s'il y a lieu, menant à la cause primaire		
OTHER SIGNIFICANT CONDITIONS [2] Autres conditions significatives [2]		

MODE OF DEATH Condition de décès	AUTOPSY PERFORMED Autopsie effectuée	CIRCUMSTANCES SURROUNDING DEATH DUE TO EXTERNAL CAUSES Circonstances de la mort suscitées par des causes extérieures
☐ NATURAL Mort naturelle	☒ YES Oui ☐ NO Non	Mode of Death : Undetermined
☐ ACCIDENT Mort accidentelle	MAJOR FINDINGS OF AUTOPSY Conclusions principales de l'autopsie	
☐ SUICIDE Suicide	NAME OF PATHOLOGIST Nom du pathologiste: (b)(6)	
☐ HOMICIDE Homicide	SIGNATURE (b)(6) — DATE Date: 27 September 2008	AVIATION ACCIDENT Accident à Avion: ☐ YES Oui ☒ NO Non

DATE OF DEATH (day, month, year) Date de décès (le jour, le mois, l'année)	PLACE OF DEATH Lieu de décès
(b)(6) 2008	Iraq

I HAVE VIEWED THE REMAINS OF THE DECEASED AND DEATH OCCURRED AT THE TIME INDICATED AND FROM THE CAUSES AS STATED ABOVE.
J'ai examiné les restes mortels du dé funtet je conclus que le décés est survenu à l'heure indiquée et à, la suite des causes énumérées ci-dessus.

NAME OF MEDICAL OFFICER Nom du médicin militaire ou du médicin sanitaire	TITLE OR DEGREE Titre ou diplôme
(b)(6)	Medical Examiner

GRADE Grade	INSTALLATION OR ADDRESS Installation ou adresse
(b)(6)	Dover AFB, Dover DE
DATE Date: 11/10/2008	SIGNATURE (b)(6)

[1] State disease, injury or complication which caused death, but not mode of dy
[2] State conditions contributing to the death, but not related to the disease or condition causing death.
[1] Préciser la nature de la maladie, de la blessure ou de la complication qui a contribué à la mort, mais non la manière de mourir, tele qu 'un arrêt du coeur, etc
[2] Préciser la condition qui a contribué à la mort, mais n'ayant aucun rapport avec la maladie ou à la condition qui a provoqué la mort.

DD FORM 1 APR 77 2064 — REPLACES DA FORM 3565, 1 JAN 72 AND DA FORM 3565-R(PAS), 26 SEP 75, WHICH ARE OBSOLETE.

MEDCOM 1056

ACLU Detainee DeathII ARMY MEDCOM 1056

ARMED FORCES INSTITUTE OF PATHOLOGY
Office of the Armed Forces Medical Examiner
1413 Research Blvd., Bldg. 102
Rockville, MD 20850
301-319-0000

AUTOPSY EXAMINATION REPORT

Name: (BTB) HASAN, Mahmud Rashid
ISN: (b)(6)
Date of Birth: (BTB (b)(6) 1967
Date of Death (b)(6) 2008
Date/Time of Autopsy: 5 AUG 2008 @ 1315 hrs
Date of Report: 10 OCT 2008

Autopsy No. (b)(6)
AFIP No.: (b)(6)
Rank: Civilian/Detainee
Place of Death: Iraq
Place of Autopsy: Port Mortuary, Dover AFB, Dover DE

Circumstances of Death: This 41-year-old detainee was admitted to the combat hospital ICU complaining of weakness, nausea, and headaches. He was initially diagnosed with pneumonia and was treated with antibiotics. His condition continued to decline and he progressed into a coma. The preliminary diagnosis for his condition was lung cancer with brain metastasis. He was pronounced dead on (b)(6) 2008.

Authorization for Autopsy: Armed Forces Medical Examiner, per U.S. Code 10, Section 1471

Identification: Presumptive identification per CID investigation.

CAUSE OF DEATH: **METASTATIC CARCINOMA**

MANNER OF DEATH: **NATURAL**

ACLU Detainee DeathII ARMY MEDCOM 1057

EXTERNAL EXAMINATION

The body is that of a well-developed, well-nourished nude male. The body weighs 126 pounds, measures 67 inches in length, and appears compatible with the reported age of 41 years. The body is cold. Rigor is present to an equal degree in all extremities. Lividity is present and fixed on the posterior surface of the body, except in areas exposed to pressure.

The head is normocephalic, and the scalp hair is black/grey. Facial hair consists of black/grey mustache and beard. The irides are brown. The corneae are cloudy. The conjunctivae and sclerae are unremarkable. The external auditory canals, external nares and oral cavity are free of foreign material and abnormal secretions. The nasal skeleton and maxilla are palpably intact. The lips are without evident injury. There are lower partial dentures and the upper teeth are natural. Examination of the neck reveals no evidence of injury.

The chest is unremarkable. No evidence of injury of the ribs or the sternum is evident externally. The abdomen is unremarkable. No healed surgical scars are noted. The external genitalia are those of an adult male. The posterior torso and anus are unremarkable.

Callous formation is present on the base of the feet. The fingernails are intact.

CLOTHING AND PERSONAL EFFECTS

None identified.

MEDICAL INTERVENTION

- EKG leads on left lateral arm and left lower abdominal quadrant
- Numerous needle puncture marks surrounded by contusions measuring up to 2 ½ inches in maximum dimension involving the bilateral antecubital fossae, bilateral anterior forearms, and anterior right wrist

RADIOGRAPHS

A complete set of postmortem radiographs is obtained and demonstrates the following abnormalities listed below.

EVIDENCE OF INJURY

None identified at autopsy.

ACLU Detainee DeathII ARMY MEDCOM 1058

INTERNAL EXAMINATION

BODY CAVITIES:

No abnormal collections of fluid are present in any of the body cavities. All body organs are present in normal anatomical position. The subcutaneous fat layer of the abdominal wall is 2 inches thick.

HEAD (CENTRAL NERVOUS SYSTEM) AND NECK:

See "Neuropathology Consultation" Report below. The galeal and subgaleal soft tissues of the scalp are free of injury. There are no skull fractures. The dura mater and falx cerebri are intact. The leptomeninges are thin and delicate. The cerebral hemispheres are symmetrical. The structures at the base of the brain, including cranial nerves and blood vessels are intact.

The brain weighs 1450 grams and has edematous gyri and sulci. The atlanto-occipital joint is stable. The anterior strap muscles of the neck are homogenous and red-brown, without hemorrhage by layer-wise dissection. The thyroid cartilage and hyoid bone are intact. The larynx is lined by intact tan mucosa. The tongue is free of bite marks, hemorrhage, or other injuries. Incision and dissection of the posterior neck demonstrates no deep paracervical muscular injury and no cervical spine fractures.

CARDIOVASCULAR SYSTEM:

The 360gram heart is contained in an intact pericardial sac. The epicardial surface is smooth, with minimal fat investment. The coronary arteries are present in a normal distribution, with a right-dominant pattern. Cross sections of the vessels show mild (less than 25%) focal atherosclerotic luminal stenosis of the left anterior descending coronary artery and the others are unremarkable.

The myocardium is homogenous, red-brown, and firm. The valve leaflets are thin and mobile. The walls of the left ventricle, interventricular septum, and right ventricle are 1.2, 0.8, and 0.2 centimeter thick, respectively. The endocardium is smooth and glistening. The aorta displays atherosclerotic streaks and gives rise to three intact and patent arch vessels. The renal and mesenteric vessels are unremarkable.

RESPIRATORY SYSTEM:

The upper airway is clear of debris and foreign material: the mucosal surfaces are smooth, yellow-tan and unremarkable. There is a right upper lobe pleural adhesion and the remaining surface showing a smooth, glistening appearance. The pulmonary parenchyma displays multiple tan lesions measuring up to 0.7 centimeters in maximum dimension involving the right upper, left upper, and left lower lobes of the lungs. The pulmonary arteries are normally developed, patent and without thrombus or embolus. The right lung weighs 780grams and the left lung weighs 650 grams.

ACLU Detainee DeathII ARMY MEDCOM 1059

HEPATOBILIARY SYSTEM:

The 1520 grams liver has an intact smooth capsule covering moderately congested tan-brown parenchyma with multiple tan lesions measuring up to 1 centimeter in maximum dimension.

The gallbladder contains 6 milliliters of green-brown, mucoid bile; the mucosa is velvety and unremarkable. The extrahepatic biliary tree is patent, without evidence of calculi.

GASTROINTESTINAL SYSTEM:

The esophagus is lined by gray-white, smooth mucosa. The gastric mucosa is arranged in the usual rugal folds and the lumen contains 150 milliliters of green fluid. The small and large bowels are unremarkable. The pancreas has a normal pink-tan lobulated appearance and the ducts are clear. The appendix is present.

GENITOURINARY SYSTEM:

The right and left kidneys weighs 90 grams. The renal capsules are smooth and thin, semi-transparent and strip with ease from the underlying smooth, red-brown cortical surface. There are multiple tan lesions in both kidneys which measure up to 1 centimeter in maximum dimension. The cortices are sharply delineated from the medullary pyramids, which are red-purple to tan and unremarkable. The calyces, pelves and ureters are unremarkable. The tan bladder mucosa overlies an intact bladder wall. The bladder contains no urine. The testes, prostate gland and seminal vesicles are unremarkable.

LYMPHORETICULAR SYSTEM:

The spleen weighs 50 grams has a smooth, intact capsule covering red-purple, moderately firm parenchyma; the lymphoid follicles are unremarkable. Lymph nodes in the hilar, periaortic and iliac regions are not enlarged.

ENDOCRINE SYSTEM:

The pituitary gland is left *in situ* and is unremarkable. The thyroid gland is symmetric and red-brown, without cystic or nodular change. The left adrenal gland has a tan lesion that measures 0.8 centimeter in maximum dimension. The right adrenal gland is unremarkable.

MUSCULOSKELETAL SYSTEM:

No non-traumatic abnormalities of muscle or bone are identified.

ACLU Detainee DeathII ARMY MEDCOM 1060

MICROSCOPIC EXAMINATION

Selected portions of organs are retained in formalin, with preparation of histology slides:

Right Upper Lobe (slide 1), Right Middle and Lower lobes of lung (slide 2), Liver (slide 3), left lower lobe of lung (slide 4), left upper lobe and spleen (slide 5), left kidney (slide 6), left adrenal (slide 7), and right kidney (slide 8): sections of the organs display areas of metastatic carcinoma with pleomorphic nuclei admixed with necrosis. The spleen and right middle/left lower lobes of the lung displayed on metastatic involvement.

ADDITIONAL PROCEDURES

1. Documentary photographs are taken by OAFME.
2. Personal effects are released to the appropriate mortuary operations representatives.
3. Specimens retained for toxicology testing and/or DNA identification are: vitreous fluid, blood, bile, gastric contents, spleen, liver, lung, kidney, myocardium, adipose tissue and skeletal muscle.
4. The dissected organs are forwarded with body.

ACLU Detainee DeathII ARMY MEDCOM 1061

NEUROPATHOLOGY CONSULTATION

FINAL DIAGNOSIS

GROSS DESCRIPTION:

Brain weight: 1437 gm

The specimen consists of the intracranial dura and brain of an adult.

The intracranial dura is not remarkable. The venous sinuses are patent.

The brain is markedly swollen with wide, flattened gyri and compressed sulci. The perisellar, perimesencephalic and basal cisterns are completely effaced due to swelling. Deep tentorial grooves indent each uncus approximately 1 cm from the medial margin on the right and 0.8 cm on the left due to downward transtentorial pressure. The cerebellar tonsils are deeply molded by the foramen magnum due to downward trans-foramen magnum intracranial pressure. A regional nonhemorrhagic (artefactual) disruption of a 4 x 4.5 cm area of the right lateral parietal lobe communicates with an approximately 5 x 5 x 4.5 cm cavity of the right posterior/inferior frontal and anterior occipital lobe white matter. Accompanying the brain is a firm, friable, 4.5 x 5 x 4 cm pink-tan neoplastic mass consistent with metastatic neoplasm, with diffuse necrotic, granular yellow-white cut surfaces which has been artifactually extruded from the above noted right frontal occipital cerebral cavity.

The leptomeninges are thin, delicate and transparent. The midbrain and pons are markedly enlarged. The arteries at the base of the brain follow a normal distribution and there are no aneurysmal dilatations or sites of occlusion. All the identifiable cranial nerve roots are not remarkable.

Coronal sections of the cerebrum reveal marked white matter edema and swelling of the right frontal lobe associated with the above noted neoplasm with effacement of the

ACLU Detainee DeathII ARMY MEDCOM 1062

gray/white matter margins and right trans-falcine cingulate gyrus herniation due to leftward pressure across the falx cerebri. The adjacent right lateral ventricle is partially collapsed and the opposite left ventricle is enlarged reflecting partial compression of the left foramen of Munro.

A second granular friable mass (3.5 x 4 x 3.5 cm), similar to the above described lesion is situated in the posterior-inferior right frontal lobe and invades the lateral basal ganglia and the sub-insular cortex.

There is multifocal hemorrhage and necrosis of the right inferior thalamus and the bilateral subependymal areas of each thalamus. A 0.3 to 0.5 cm thick layer of granular, friable neoplastic tissue similar to the above lesions encases the occipital horn of the left lateral ventricle.

Sections of the midbrain and pons show marked swelling due to tegmental Duret hemorrhages and necrosis. The tegmentum of the medulla is edematous. The substantia nigra and locus coeruleus are well pigmented.

PHOTOGRAPHS: yes

MICROSCOPIC EXAMINATION:

Blocks of tissue for microscopic examination are removed from: (1) right lateral frontal lobe, (2) right striate body, (3) right insular tumor, (4) right lateral parietal lobe, (5) external tumor, (6) pons, (7) cerebellum, (8) left occipital lobe, (9) medulla, (10) dura and (11) right hippocampus.

Sections from each block are stained with H&E, Bielschowsky and LFB techniques and immunostained for β–APP, GFAP, β–amyloid, Tau-2, ubiquitin, synuclein.

DIAGNOSIS:

Multifocal (right frontal, right parietal/occipital, left occipital) metastatic, anaplastic, necrotic carcinoma with:

1. Extensive perineoplastic edema
2. Trans-falcine (leftward), trans-tentorial and trans foramen magnum herniation
3. Duret hemorrhage of midbrain and rostral pons tegmentum.
4. Partial obstruction of left foramen of Munro

(b)(6)

NEUROPATHOLOGIST

ACLU Detainee DeathII ARMY MEDCOM 1063

FINAL AUTOPSY DIAGNOSES

I. Metastatic Carcinoma
- A. Multifocal (right frontal, right parietal/occipital, left occipital) lesions of the brain
- B. Carcinoma with pleomorphic nuclei admixed with necrosis
- C. Extensive perineoplastic edema
- D. Trans-falcine (leftward), trans-tentorial and trans-foramen magnum herniation
- E. Duret hemorrhage of midbrain and rostal pons tegmentum
- F. Partial obstruction of left foramen of Munro
- G. Tumor involvement of the bilateral lungs, left adrenal gland, liver, and kidneys

II. Pre-existing Natural Disease:
- A. Bilateral emphysematous lungs
- B. Atherosclerotic cardiovascular disease
  1. Left anterior deceasing, focal/mild
  2. Aorta, atherosclerotic streaks present

III. Evidence of Medical Therapy: As described above

IV. Post-Mortem Changes: As described above

V. Identifying Body Marks: None identified

VI. Toxicology (AFIP):
- A. VOLATILES: No ethanol detected in the blood and vitreous fluid
- B. DRUGS: No screened drugs of abuse/medications detected in the urine
- C. CYANIDE: No cyanide detected in the blood
- D. CARBON MONOXIDE: Carboxyhemoglobin saturation in the blood was less than 1%.

OPINION

This 41-year-old detainee (b)(6) died of clinically diagnosed lung cancer which spread (metastasized) to the brain, left adrenal gland, liver, and kidneys. The primary tumor was not identified in the lungs. However, the metastasized tumors were of the adenocarcinoma type which is consistent with occult lung tumor. At autopsy, the body did not display evidence of blunt or sharp force injury to suggest foul play. The toxicology screen is negative. The manner of death is natural.

(b)(6)

(b)(6) Medical Examiner

(b)(6)

(b)(6) Medical Examiner

ACLU Detainee DeathII ARMY MEDCOM 1064

ACLU Detainee DeathII ARMY MEDCOM 1065

CERTIFICATE OF DEATH *(OVERSEAS)*
Acte dé décès (D'Outre-Mer)

NAME OF DECEASED *(Last, First, Middle)* Nom du décédé (Nom et prénoms)	GRADE Grade	BRANCH OF SERVICE Arme	SOCIAL SECURITY NUMBER Numéro de l'Assurance Social
BTB Hasan, Mahmud, Rashid		Civilian	(b)(6)

ORGANIZATION Organisation	NATION *(e.g. United States)* Pays	DATE OF BIRTH Date de naissance	SEX Sexe
	Iraq	(b)(6) 1967	[X] MALE [ ] FEMALE

RACE Race		MARITAL STATUS État Civil			RELIGION Culte		
[X]	CAUCASOID Caucasique		SINGLE Célibataire		DIVORCED Divorcé		PROTESTANT Protestant
[ ]	NEGROID Negriode		MARRIED Marié		SEPARATED Séparé		CATHOLIC Catholique
[ ]	OTHER (Specify) Autre (Spécifier)		WIDOWED Veuf			[ ]	JEWISH Juif

[X]	OTHER (Specify) Autre (Spécifier)	Islam	

NAME OF NEXT OF KIN Nom du plus proche parent	RELATIONSHIP TO DECEASED Parenté du décéde avec le sus
STREET ADDRESS Domicilé à (Rue)	CITY OR TOWN OR STATE *(Include ZIP Code)* Ville (Code postal compris)

MEDICAL STATEMENT Déclaration médicale

CAUSE OF DEATH (Enter only one cause per line) Cause du décès (N'indiquer qu'une cause par ligne)		INTERVAL BETWEEN ONSET AND DEATH Intervalle entre l'attaque et le décès
DISEASE OR CONDITON DIRECTLY LEADING TO DEATH [1] Maladie ou condition directement responsable de la mort	Metastatic carcinoma	
ANTECEDENT CAUSES Symptômes précurseurs de la mort. MORBID CONDITION, IF ANY, LEADING TO PRIMARY CAUSE Condition morbide, s'il y a lieu, menant à la cause primaire		
UNDERLYING CAUSE, IF ANY, GIVING RISE TO PRIMARY CAUSE Condition morbide, s'il y a lieu, menant à la cause primaire		
OTHER SIGNIFICANT CONDITIONS [2] Autres conditions significatives [2]		

MODE OF DEATH Condition de décès	AUTOPSY PERFORMED Autopsie effectuée [X] YES Oui [ ] NO Non	CIRCUMSTANCES SURROUNDING DEATH DUE TO EXTERNAL CAUSES Circonstances de la mort suscitées par des causes extérieures
[X] NATURAL Mort naturelle	MAJOR FINDINGS OF AUTOPSY Conclusions principales de l'autopsie	
[ ] ACCIDENT Mort accidentelle		
[ ] SUICIDE Suicide	NAME OF PATHOLOGIST Nom du pathologiste (b)(6)	
[ ] HOMICIDE Homicide	SIGNATURE (b)(6) DATE Date 5 August 2008	AVIATION ACCIDENT Accident à Avion [ ] YES Oui [X] NO Non

DATE OF DEATH (day, month, year) Date de décès (le jour, le mois, l'année)	PLACE OF DEATH Lieu de décès
(b)(6) 2008 1605	Camp Cropper Iraq

I HAVE VIEWED THE REMAINS OF THE DECEASED AND DEATH OCCURRED AT THE TIME INDICATED AND FROM THE CAUSES AS STATED ABOVE.
J'ai examiné les restes mortels du dé funtet je conclus que le décès est survenu à l'heure indiquée et à, la suite des causes énumérées ci-dessus.

NAME OF MEDICAL OFFICER Nom du médicin militaire ou du médicin sanitaire	TITLE OR DEGREE Titre ou diplômé
(b)(6)	Medical Examiner

GRADE Grade	INSTALLATION OR ADDRESS Installation ou adresse
(b)(6)	Dover AFB, Dover DE
DATE Date 10/24/2008	SIGNATURE (b)(6)

[1] State disease, injury or complication which caused death, but not mode of dying such as heart failure, ect.
[2] State conditions contributing to the death, but not related to the disease or condition causing death.
[1] Préciser le nature de la maladie, de la blessure ou de la complication qui a contribué à la mort, mais non la manière de mourir, telle qu 'un arrêt du coeur, etc
[2] Préciser le condition qui a contribué à la mort, mais n'ayant aucun rapport avec la maladie ou à la condition qui a provoqué la mort.

DD FORM 1 APR 77 **2064** REPLACES DA FORM 3565, 1 JAN 72 AND DA FORM 3565-R(PAS), 26 SEP 75, WHICH ARE OBSOLETE.

MEDCOM 1066

ACLU Detainee DeathII ARMY MEDCOM 1066

(REMOVE, REVERSE AND RE-INSERT CARBONS BEFORE COMPLETING THIS SIDE)

DISPOSITON OF REMAINS

NAME OF MORTICIAN PREPARING REMAINS	GRADE	LICENSE NUMBER AND STATE	OTHER

INSTALLATION OR ADDRESS	DATE	SIGNATURE
(b)(6)		

NAME OF CEMETERY OR CREMATORY	LOCATION OF CEMETERY OR CREMATORY

TYPE OF DISPOSTION	DATE OF DISPOSTION

REGISTRATION OF VITAL STATISTICS

REGISTRY *(Town and Country)*	DATE REGISTERED	FILE NUMBER	
		STATE	OTHER

NAME OF FUNERAL DIRECTOR	ADDRESS

SIGNATURE OF AUTHORIZED INDIVIDUAL

DD FORM 2064, APR 1977 (BACK) *USAPA V1.00*

ACLU Detainee DeathII ARMY MEDCOM 1067

ARMED FORCES INSTITUTE OF PATHOLOGY
Office of the Armed Forces Medical Examiner
1413 Research Blvd., Bldg. 102
Rockville, MD 20850
301-319-0000

FINAL AUTOPSY REPORT

Name: **BTB** Karim, Ala Shnaywir
SSAN: (b)(6)
Date of Birth: (b)(6) 1982
Date of Death (b)(6) 2008
Date/Time of Autopsy: 09 APR 2008 @ 0900
Date of Report: 15 JUL 2008

Autopsy No.: (b)(6)
AFIP No.: (b)(6)
Grade: Civilian, Detainee
Place of Death: Iraq
Place of Autopsy: Dover Mortuary
Dover AFB, DE

Circumstances of Death: This 25 year-old detainee was being detained in Theater Internment Facility (TIF) Camp Bucca, when as reported, he was observed to be vomiting outside of his tent. When questioned, he complained of being dizzy and vomiting blood. He was brought to the TIF hospital where he was listed in serious condition with a possible aneurysm. He was urgently MEDEVAC'd to the combat support hospital in Balad. While in the air, his condition worsened and the aircraft was diverted to Al Kut. All resuscitative measures were unsuccessful.

Authorization for Autopsy: Office of the Armed Forces Medical Examiner, IAW 10 USC 1471.

Identification: Presumptive identification via review of all accompanying paperwork. Post-mortem fingerprints taken and dental exam performed. Suitable specimen for DNA analysis obtained.

CAUSE OF DEATH: Hemorrhage of the right cerebellum

MANNER OF DEATH: Natural

ACLU Detainee DeathII ARMY MEDCOM 1068

EXTERNAL EXAMINATION

The body is that of a well-developed, well-nourished male. The body is 69 ½ inches in length, weighs 215 pounds, and appears compatible with the stated age of 25 years old. The body is cold. Lividity is fixed on the posterior surface of the body except in the areas exposed to pressure. The head and neck are suffused. Rigor is resolving to an equal degree in all extremities. There is marbling of the skin of both shoulders.

The scalp hair is black. On the back of the head is a 1-inch linear scar. Facial hair consists of a beard. The irides are indistinct. The corneae are cloudy. The conjunctivae are pale with no petechiae. The sclerae are white. The oral cavity, external nares, and external auditory canals are free of foreign material or abnormal secretions. There are no petechiae of the oral mucosa.

The chest is symmetric. The genitalia are those of a circumcised adult male. The anus is atraumatic.

The upper and lower extremities are symmetric and without clubbing or edema. The fingernails are intact. On the lateral right thigh is a 2 x 1-inch scar. A 2 x ¼-inch scar is on the left knee. On the right knee is a 1 x ½-inch healing abrasion.

CLOTHING AND PERSONAL EFFECTS

The body is clad in socks. Accompanying the body are three syringes, two bottles of vecuronium, and a bottle of midazolam (submitted to toxicology).

MEDICAL INTERVENTION

An endotracheal tube is in the oral cavity and trachea. On the anterior torso are multiple EKG lead pads. A catheter is in the urethra and attached to a catch bag that contains 700 milliliters of yellow urine. Intravenous catheters are in the left groin, right wrist, and left antecubital fossa. There are multiple needle puncture marks of both clavicles, right antecubital fossa, and left wrist. There is gauze around the left wrist.

RADIOGRAPHS

A complete set of post-mortem radiographs is obtained and reveal no evidence of trauma.

EVIDENCE OF INJURY

There is no evidence of significant external or internal recent injury.

INTERNAL EXAMINATION

BODY CAVITIES:
The ribs, sternum, and vertebral bodies are visibly and palpably intact. There are 100 milliliters of serosanguineous fluid in both chest cavities. No adhesions are present in any of the body cavities. The organs occupy their usual anatomic positions.

HEAD (CENTRAL NERVOUS SYSTEM) and NECK:
The galeal and subgaleal soft tissues of the scalp are free of injury. There are no skull fractures. The dura mater and falx cerebri are intact. The leptomeninges are thin and delicate. There is no epidural or subdural hemorrhage. There is focal subarachnoid hemorrhage of the right cerebellum. The brain weighs 1270 grams and is examined after

ACLU Detainee DeathII ARMY MEDCOM 1069

fixation. The cerebral hemispheres are symmetrical and the structures at the base of the brain are intact. The gyri and sulci are unremarkable. The surface of the right cerebellum is soft. Coronal sections through the cerebral hemispheres reveal no lesions. Transverse sections through the brain stem and cerebellum reveal a 3.0 x 3.0 x 3.0 centimeter area of hemorrhagic, soft, and friable tissue of the right cerebellum and scattered punctuate hemorrhages of the pons.

The anterior strap muscles of the neck are homogenous and red-brown (by layer-wise dissection). There is hemorrhage around the puncture sites superior to the clavicles. The thyroid cartilage and hyoid bone are intact. The larynx is lined by intact white mucosa. The tongue is free of bite marks, hemorrhage, or other injuries. The thyroid is symmetric and dark brown, without cystic or nodular change. Incision and dissection of the posterior neck demonstrates no deep paracervical muscular injury and no cervical spinal column fractures.

RESPIRATORY SYSTEM:
The upper airway is clear of debris and foreign material. The mucosal surfaces are smooth, yellow-tan and unremarkable. The right and left lungs weigh 700 and 700 grams, respectively. The pulmonary parenchyma red-purple exuding moderate amounts of blood. The pulmonary arteries are normally developed and patent without thrombus or embolus.

CARDIOVASCULAR SYSTEM:
The heart weighs 380 grams and is contained in an intact pericardial sac. The epicardial surface is smooth, with minimal fat investment. The coronary arteries are present in a normal distribution, with a right-dominant pattern. There is tunneling of the proximal left anterior descending coronary artery (0.5 centimeters below the epicardium for 2.0 centimeters). The coronary arteries are widely patent. The myocardium is homogenous. The valve leaflets are thin and mobile. The walls of the left ventricle, interventricular septum, and right ventricle are 0.8, 0.8, and 0.2 centimeters, respectively. The right ventricle is dilated. The aorta and its major branches arise normally and follow the usual course and are unremarkable. The vena cava and its major tributaries return to the heart in the usual distribution and are free of thrombi.

LIVER & BILIARY SYSTEM:
The 2000 gram liver has an intact, smooth capsule and a sharp anterior border. The parenchyma is tan-brown with the usual lobular architecture with no focal lesions noted. The gallbladder contains 5 milliliters of dark-green bile. There is cholesterolosis of the gall bladder mucosa. The extrahepatic biliary tree is patent.

SPLEEN:
The 350 gram spleen has a smooth, intact, red-purple capsule. The parenchyma is maroon with unremarkable lymphoid follicles.

ACLU Detainee DeathII ARMY MEDCOM 1070

PANCREAS:
The pancreas is red-tan with a lobulated appearance. No mass lesions or other abnormalities are seen.

ADRENALS:
The right and left adrenal glands are symmetric, with mild autolytic changes. No masses or areas of hemorrhage are identified.

GENITOURINARY SYSTEM:
The right and left kidneys weigh 170 and 160 grams, respectively. The external surfaces are intact and smooth. The cut surfaces are tan-red and the cortex is delineated from the medullary pyramids. The pelves are unremarkable and the ureters are normal in course and caliber. The bladder contains scant urine. The prostate and testes are unremarkable.

GASTROINTESTINAL TRACT:
The esophagus is intact and lined by smooth, grey-white mucosa. The stomach, small bowel, colon, and appendix are unremarkable. The stomach contains 20 milliliters of brown fluid.

MUSCULOSKELETAL:
Muscle development is normal. No bone or joint abnormalities are identified.

MICROSCOPIC EXAMINATION

Cerebellum (Slides 1 and 2): Parenchyma hemorrhage with dilated and tortuous blood vessels. Extensive loss of Purkinje cells and cells of the granular layer. Focal subarachnoid hemorrhage.

Pons (Slide 3): Scattered, hyper-eosiniophilic neurons.

ADDITIONAL PROCEDURES

1. Specimens retained for toxicology testing and/or DNA identification are: Blood, vitreous fluid, bile, urine, liver, myocardium, lung, kidney, spleen, psoas muscle, adipose tissue and gastric contents.
2. The dissected organs are forwarded with the body. The brain is retained for further examination.
3. Selected portions of organs are retained in formalin.
4. Personal effects are released with the body.
5. Recovered evidence: None.
6. Skin incisions of the posterior torso, buttocks and extremities reveal no evidence of trauma.
7. Documentary photographs are taken by (b)(6) (OAFME). Assisting with the autopsy is (b)(6) OAFME).

ACLU Detainee DeathII ARMY MEDCOM 1071

FINAL AUTOPSY DIAGNOSES

I. **Hemorrhage of the right cerebellum:**
   A. Parenchyma hemorrhage of the right cerebellum with extensive loss of Purkinje cells
   B. Focal subarachnoid hemorrhage of the right cerebellum
   C. Punctate hemorrhages of the pons (consistent with herniation)

II. **Additional natural disease:**
   A. Tunneling of the proximal left anterior descending coronary artery
   B. Cholesterolosis

III. **Evidence of medical intervention:** As describe above

IV. **Identifying marks:** As described above

V. **Post-mortem changes:** As described above

VI. **Toxicology (AFIP):**
   A. VOLATILES: No ethanol detected in the blood and vitreous fluid
   B. CARBON MONOXIDE: The carboxyhemoglobin saturation in the blood was 4%[1]
   C. CYANIDE: No cyanide detected in the blood
   D. DRUGS: The following drugs were detected
      1. Lidocaine (urine)
      2. Promethazine (urine; none detected in the blood)
      3. Pseudoephedrine (urine; none detected in the blood)
      4. Midazolam (urine; none detected in the blood)
      5. Acetaminophen (urine)
      6. Vecuronium (0.73 mg/L in the blood) and its metabolite 3-Desacetylvecuronium (blood)

OPINION

This 25 year-old detainee (b)(6) died of a hemorrhage of the right cerebellum. The toxicology was positive for medications used in resuscitation (lidocaine, midazolam, and vecuronium), anti-nausea medication (promethazine) and over-the-counter medications (pseudoephedrine and acetaminophen). The manner of death is Natural.

(b)(6)

(b)(6) Medical Examiner

[1] Carboxyhemoglobin saturations of 0-3% are expected for non-smokers and 3-10% for smokers.

ACLU Detainee DeathII ARMY MEDCOM 1072

CERTIFICATE OF DEATH *(OVERSEAS)*
Acte dé décès (D'Outre-Mer)

NAME OF DECEASED (Last, First, Middle) Nom du décédé (Nom et prénoms)	GRADE Grade	BRANCH OF SERVICE Arme	SOCIAL SECURITY NUMBER Numéro de l'Assurance Social
BTB Karim, Ala, Shnaywir		Civilian	(b)(6)

ORGANIZATION Organisation	NATION (e.g. United States) Pays	DATE OF BIRTH Date de naissance	SEX Sexe
(b)(6)		(b)(6) 1982	[X] MALE [ ] FEMALE

RACE Race		MARITAL STATUS État Civil			RELIGION Culte		
[X]	CAUCASOID Caucasique		SINGLE Célibataire		DIVORCED Divorcé		PROTESTANT Protestant
	NEGROID Negriode		MARRIED Marié		SEPARATED Séparé		CATHOLIC Catholique
	OTHER (Specify) Autre (Spécifier)		WIDOWED Veuf			[X]	OTHER (Specify) Autre (Spécifier) Islam
							JEWISH Juif

NAME OF NEXT OF KIN Nom du plus proche parent	RELATIONSHIP TO DECEASED Parenté du décéde avec le sus
STREET ADDRESS Domicilé à (Rue)	CITY OR TOWN OR STATE *(Include ZIP Code)* Ville (Code postal compris)

MEDICAL STATEMENT Déclaration médicale

	CAUSE OF DEATH (Enter only one cause per line) Cause du décés (N'indiquer qu'une cause par ligne)	INTERVAL BETWEEN ONSET AND DEATH Intervalle entre l'attaque et le décés
DISEASE OR CONDITON DIRECTLY LEADING TO DEATH [1] Maladie ou condition directement responsable de la mort [1]	Hemorrhage of the right cerebellum	
ANTECEDENT CAUSES Symptômes précurseurs de la mort. MORBID CONDITION, IF ANY, LEADING TO PRIMARY CAUSE Condition morbide, s'il y a lieu, menant à la cause primaire		
UNDERLYING CAUSE, IF ANY, GIVING RISE TO PRIMARY CAUSE Condition morbide, s'il y a lieu, menant à la cause primaire		
OTHER SIGNIFICANT CONDITIONS [2] Autres conditions significatives [2]		

MODE OF DEATH Condition de décés	AUTOPSY PERFORMED Autopsie effectuée [X] YES Oui [ ] NO Non	CIRCUMSTANCES SURROUNDING DEATH DUE TO EXTERNAL CAUSES Circonstances de la mort suscitées par des causes extérieures
[X] NATURAL Mort naturelle	MAJOR FINDINGS OF AUTOPSY Conclusions principales de l'autopsie	
[ ] ACCIDENT Mort accidentelle		
[ ] SUICIDE Suicide	NAME OF PATHOLOGIST Nom du pathologiste (b)(6)	
[ ] HOMICIDE Homicide	SIGNATURE Signature (b)(6) DATE Date 9 April 2008	AVIATION ACCIDENT Accident à Avion [ ] YES Oui [X] NO Non

DATE OF DEATH (day, month, year) Date de décès (le jour, le mois, l'année)	PLACE OF DEATH Lieu de décés
(b)(6) 2008	Iraq

I HAVE VIEWED THE REMAINS OF THE DECEASED AND DEATH OCCURRED AT THE TIME INDICATED AND FROM THE CAUSES AS STATED ABOVE.
J'ai examiné les restes mortels du dé funtet je conclus que le décés est survenu à l'heure indiquée et à, la suite des causes énumérées ci-dessus.

NAME OF MEDICAL OFFICER Nom du médicin militaire ou du médicin sanitaire	TITLE OR DEGREE Titre ou diplômé
(b)(6)	Medical Examiner

GRADE Grade	INSTALLATION OR ADDRESS Installation ou adresse
(b)(6)	Dover AFB, Dover DE
DATE Date 7/17/2008	SIGNATURE Signature (b)(6)

[1] State disease, injury or complication which caused death, but not mode of dying such as heart failure, ect.
[2] State conditions contributing to the death, but not related to the disease or condition causing death.
[1] Préciser la nature de la maladie, de la blessure ou de la complication qui a contribué à la mort, mais non la manière de mourir, telle qu'un arrêt du coeur, etc
[2] Préciser la condition qui a contribué à la mort, mais n'ayant aucun rapport avec la maladie ou à la condition qui a provoqué la mort.

DD FORM 1 APR 77 2064 REPLACES DA FORM 3565, 1 JAN 72 AND DA FORM 3565-R(PAS), 26 SEP 75, WHICH ARE OBSOLETE.

MEDCOM 1073

ACLU Detainee DeathII ARMY MEDCOM 1073

ARMED FORCES INSTITUTE OF PATHOLOGY
Office of the Armed Forces Medical Examiner
1413 Research Blvd., Bldg. 102
Rockville, MD 20850
301-319-0000

AUTOPSY EXAMINATION REPORT

Name: BTB Razzaq Abd-Al, Luay Mustafa
TMEP: (b)(6)
Date of Birth (b)(6) 1986
Date of Death (b)(6) 2008
Date/Time of Autopsy: 09 Apr 2008
From 1000 to 1200 hours
Date of Report: 02 May 2008

Autopsy No.: (b)(6)
AFIP No.: (b)(6)
Rank: Civilian detainee
Place of Death: Iraq
Place of Autopsy: Port Mortuary
DAFB, Dover, DE

Circumstances of Death: This civilian detainee was reportedly found hanging in his cell by his pants that he made into a noose. During the course of his internment, he admitted traveling from Syria to become a suicide bomber. Further, he displayed many erratic behaviors and signs of a possible mental impairment. Prior to his death, he was placed on a 24-hour watch due to a possible threat of self-harm. The watch consisted of checks every 15 minutes and his confinement was solitary. The detainee was found deceased in his cell by a member of the US Guard Forces.

Authorization for Autopsy: Armed Forces Medical Examiner, per 10 U.S. Code 1471

Identification: Presumptive identification is established by the examination of accompanying paper work.

CAUSE OF DEATH: Hanging

MANNER OF DEATH: Suicide

ACLU Detainee DeathII ARMY MEDCOM 1074

EXTERNAL EXAMINATION

The body is that of a nude well-developed, well-nourished male. The body weighs 172 pounds, is 68 inches in length and appears compatible with the reported age of 26 years. The body is cold. Rigor is passing. Lividity is present and fixed on the posterior surface of the body, except in areas exposed to pressure. Marbling of the skin of the left lower extremity and left forearm is seen. There is a slight green discoloration of the skin of the right lower quadrant of the abdomen. The normocephalic head is congested, and the scalp hair is brown, short and curly. Facial hair consists of a stubble beard. The irides are brown. The corneae are cloudy. The conjunctivae are congested with numerous petechiae seen bilaterally. Numerous petechiae are seen on the skin of the upper and lower eyelids. The sclerae are white. The external auditory canals, external nares and oral cavity are free of foreign material and abnormal secretions. The earlobes are not pierced. The nasal skeleton and maxilla are palpably intact. The lips are without evident injury. The teeth are natural and the left upper central incisor is missing. The neck is described in the Evidence of Injury section below. The chest is unremarkable. No evidence of injury of the ribs or the sternum is evident externally. The abdomen is unremarkable. The external genitalia are those of an adult circumcised male. The posterior torso and anus are without note. The fingernails are intact. (b)(6) (b)(6) tattoo (b)(6) A Dover tag (b)(6) is attached to the left ankle. Two name tags are attached to the left hand. A hospital ID bracelet is attached to the right wrist and is inscribed with the numbers, (b)(6)

CLOTHING AND PERSONAL EFFECTS

- None

MEDICAL INTERVENTION

- Endotracheal intubation
- Triple lumen catheter of the right subclavian vein
- Two automatic defibrillator pads on the right and left sides of the chest
- One needle puncture in the right antecubital fossa and two needle punctures in the left antecubital fossa
- Pulse oximeter on the second digit of the left hand

RADIOGRAPHS

The findings demonstrated:

- Healed fracture of the left clavicle
- Heavy lung congestion bilaterally

ACLU Detainee DeathII ARMY MEDCOM 1075

EVIDENCE OF INJURY

There is a 9 inch brown discontinuous ligature furrow of the skin of the front and left side of the neck. The furrow extends to the left side of the back of the neck and is directed obliquely upwards at an approximate 20 degree angle. The ligature furrow crosses above the thyroid cartilage 9 inches below the top of the head and extends superiorly to the left side of the neck, passing 3-1/4 inches below the left external auditory meatus and 8-1/2 inches below the top of the head. The highest point of the furrow is on the left side of the back of the neck located 7 inches below the top of the head and 1 inch to the left of the posterior midline. The furrow only extends 1 inch to the right of the anterior midline. The width of the furrow is 1/4 inch. The depth of the furrow is 1/8 inch. The skin within the furrow is dried and abraded. An anterior neck dissection shows no injury to the underlying soft tissues or hemorrhage into the strap muscles. The hyoid bone and thyroid cartilage are intact.

There is a 1 inch contusion of the posterior/distal aspect of the right leg.

INTERNAL EXAMINATION

BODY CAVITIES:

The body is opened by the usual thoraco-abdominal incision and the chest plate is removed. The ribs, sternum, and vertebral bodies are visibly and palpably intact. No adhesions or abnormal collections of fluid are present in any of the body cavities. All body organs are present in normal anatomical position. The subcutaneous fat layer of the abdominal wall is 1-1/2 inches thick.

HEAD AND CENTRAL NERVOUS SYSTEM:

The brain is retained for examination after formalin fixation. The scalp is reflected. The galeal and subgaleal soft tissues of the scalp are free of injury. There are no skull fractures. The calvarium of the skull is removed. The dura mater and falx cerebri are intact. There is no epidural or subdural hemorrhage present. The leptomeninges are thin and delicate. There is a 1-3/4 x 1 inch remote contusion of the left frontal lobe of the brain and a 2 x 1/4 inch remote contusion of the right frontal lobe of the brain. Clear cerebrospinal fluid surrounds the 1250 gram brain, which has unremarkable gyri and sulci. Coronal sections through the cerebral hemispheres reveal no non-traumatic lesions. Transverse sections through the brain stem and cerebellum are unremarkable. The atlanto-occipital joint is stable. The upper cervical spinal cord is unremarkable.

NECK:

The anterior strap muscles of the neck are homogenous and red-brown, without hemorrhage by layer-wise dissection. The thyroid cartilage and hyoid bone are intact. The larynx is lined by intact white mucosa. The tongue is free of bite marks, hemorrhage, or other injuries. Incision and dissection of the posterior neck demonstrates no deep paracervical muscular injury and no cervical spine fractures.

ACLU Detainee DeathII ARMY MEDCOM 1076

CARDIOVASCULAR SYSTEM:

The 300 gram heart is contained in an intact pericardial sac. The epicardial surface is smooth, with minimal fat investment. The coronary arteries are present in a normal distribution, with a right-dominant pattern. Cross sections of the vessels show wide patency. The myocardium is homogenous, red-brown, and firm. The valve leaflets are thin and mobile. The walls of the left ventricle, interventricular septum, and right ventricle are 1.0, 1.2 and 0.4 cm thick, respectively. The endocardium is smooth and glistening. The aorta gives rise to three intact and patent arch vessels. The renal and mesenteric vessels are unremarkable.

RESPIRATORY SYSTEM:

The upper airway is clear of debris and foreign material; the mucosal surfaces are smooth, yellow-tan and unremarkable. The pleural surfaces are smooth, glistening and unremarkable bilaterally. The pulmonary parenchyma is diffusely congested and edematous, exuding slight to moderate amounts of blood and frothy fluid; no focal lesions are noted. The pulmonary arteries are normally developed, patent and without thrombus or embolus. The right lung weighs 640 grams; the left 530 grams.

HEPATOBILIARY SYSTEM:

The 1630 gram liver has an intact smooth capsule covering dark red-brown, moderately congested tan-brown parenchyma with no focal lesions noted. The gallbladder is empty; the mucosa is velvety and unremarkable. The extrahepatic biliary tree is patent, without evidence of calculi.

GASTROINTESTINAL SYSTEM:

The esophagus is lined by gray-white, smooth mucosa. The gastric mucosa is arranged in the usual rugal folds and the lumen contains 5 ml of brown fluid. The small and large bowels are unremarkable. The pancreas has a normal pink-tan lobulated appearance and the ducts are clear. The appendix is present.

GENITOURINARY SYSTEM:

The right kidney weighs 120 grams; the left 120 grams. The renal capsules are smooth and thin, semi-transparent and strip with ease from the underlying smooth, red-brown cortical surface. The cortex is sharply delineated from the medullary pyramids, which are red-purple to tan and unremarkable. The calyces, pelves and ureters are unremarkable. White bladder mucosa overlies an intact bladder wall. The bladder contains approximately 3 ml of turbid yellow urine. The testes, prostate gland and seminal vesicles are without note.

ACLU Detainee DeathII ARMY MEDCOM 1077

LYMPHORETICULAR SYSTEM:

The 210 gram spleen has a smooth, intact capsule covering red-purple, moderately firm parenchyma; the lymphoid follicles are unremarkable. Lymph nodes in the hilar, periaortic and iliac regions are not enlarged.

ENDOCRINE SYSTEM:

The pituitary gland is unremarkable. The thyroid gland is symmetric and red-brown, without cystic or nodular change. The right and left adrenal glands are symmetric, with bright yellow cortices and red-brown medullae. No masses or areas of hemorrhage are identified.

MUSCULOSKELETAL SYSTEM:

No non-traumatic abnormalities of muscle or bone are identified.

ADDITIONAL PROCEDURES

1. Documentary photographs are taken by OAFME staff photographer (b)(6)
2. (b)(6) OAFME staff autopsy assistant, assisted with the autopsy.
3. Specimens retained for toxicology testing and/or DNA identification are: brain, heart, lung, liver, spleen, kidney, skeletal muscle, adipose tissue, blood, urine, gastric contents, and vitreous fluid.
4. The dissected organs are forwarded with body.

MICROSCOPIC EXAMINATION

Brain (Slides 1 and 2) – Disrupted cortex with white matter gliosis

ACLU Detainee DeathII ARMY MEDCOM 1078

FINAL AUTOPSY DIAGNOSES:

I. Hanging: Discontinuous ligature furrow of the front and left side of the neck
II. Minor Injuries: Contusion of the right leg
III. Remote Injuries: Remote contusions of the left and right frontal lobes of the brain and a healed fracture of the left clavicle
IV. Natural Disease: None
V. Medical Therapy: As described above
VI. Postmortem Changes: As described above
VII. Identifying Marks: As described above
VIII. Toxicology (AFIP):
- **A. VOLATILES: No ethanol is detected in the blood and vitreous fluid**
- **B. DRUGS: No screened drugs of abuse or medications (including mefloquine) are detected in the blood**
- **C. CYANIDE: There is no cyanide detected in the blood**
- **D. CARBON MONOXIDE: The carboxyhemoglobin saturation in the blood is less than 1%**

OPINION

This male civilian detainee, BTB (b)(6) died of hanging. He was found hanging in a cell by his pants that he made into a noose. He was the only occupant of the cell. The carboxyhemoglobin saturation in the blood is not elevated. The toxicology screen is negative. The manner of death is suicide.

(b)(6)

(b)(6) MEDICAL EXAMINER

ACLU Detainee DeathII ARMY MEDCOM 1079

CERTIFICATE OF DEATH *(OVERSEAS)*
Acte de décès (D'Outre-Mer)

NAME OF DECEASED (Last, First, Middle) Nom du décédé (Nom et prénoms)	GRADE Grade	BRANCH OF SERVICE Arme	SOCIAL SECURITY NUMBER
BTB Razzaq, Abd Al, Luay Mustafa		Civilian	(b)(6)

ORGANIZATION Organisation	NATION (e.g. United States) Pays	DATE OF BIRTH Date de naissance	SEX Sexe
	Syria	(b)(6) 1986	[X] MALE [ ] FEMALE

RACE Race		MARITAL STATUS État Civil		RELIGION Culte	
[X]	CAUCASOID Caucasique	[ ]	SINGLE Célibataire	[ ]	DIVORCED Divorcé
[ ]	NEGROID Negroïde	[ ]	MARRIED Marié	[ ]	SEPARATED Séparé
[ ]	OTHER (Specify) Autre (Spécifier)	[ ]	WIDOWED Veuf	[ ]	PROTESTANT Protestant
				[ ]	CATHOLIC Catholique
				[ ]	JEWISH Juif
				[X]	OTHER (Specify) Autre (Spécifier): Sunni-Islam

NAME OF NEXT OF KIN Nom du plus proche parent	RELATIONSHIP TO DECEASED Parenté du décédé avec le sus
STREET ADDRESS Domicile à (Rue)	CITY OR TOWN OR STATE (Include ZIP Code) Ville (Code postal compris)

MEDICAL STATEMENT Déclaration médicale

CAUSE OF DEATH (Enter only one cause per line) Cause du décès (N'indiquer qu'une cause par ligne)		INTERVAL BETWEEN ONSET AND DEATH Intervalle entre l'attaque et le décès
DISEASE OR CONDITON DIRECTLY LEADING TO DEATH [1] Maladie ou condition directement responsable de la mort.	Hanging	
ANTECEDENT CAUSES Symptômes précurseurs de la mort. — MORBID CONDITION, IF ANY, LEADING TO PRIMARY CAUSE Condition morbide, s'il y a lieu, menant à la cause primaire		
ANTECEDENT CAUSES Symptômes précurseurs de la mort. — UNDERLYING CAUSE, IF ANY, GIVING RISE TO PRIMARY CAUSE Condition morbide, s'il y a lieu, menant à la cause primaire		
OTHER SIGNIFICANT CONDITIONS [2] Autres conditions significatives [2]		

MODE OF DEATH Condition de décès	AUTOPSY PERFORMED Autopsie effectuée	CIRCUMSTANCES SURROUNDING DEATH DUE TO EXTERNAL CAUSES Circonstances de la mort suscitées par des causes extérieures
[ ] NATURAL Mort naturelle	[X] YES Oui [ ] NO Non	
[ ] ACCIDENT Mort accidentelle	MAJOR FINDINGS OF AUTOPSY Conclusions principales de l'autopsie	
[X] SUICIDE Suicide	NAME OF PATHOLOGIST Nom du pathologiste (b)(6)	
[ ] HOMICIDE Homicide	SIGNATU (b)(6) DATE Date 9 April 2008	AVIATION ACCIDENT Accident d'Avion [ ] YES Oui [X] NO Non

DATE OF DEATH (day, month, year) Date de décès (le jour, le mois, l'année)	PLACE OF DEATH Lieu de décès
(b)(6) 2008	Iraq

I HAVE VIEWED THE REMAINS OF THE DECEASED AND DEATH OCCURRED AT THE TIME INDICATED AND FROM THE CAUSES AS STATED ABOVE.
J'ai examiné les restes mortels du dé funtet je conclus que le décès est survenu à l'heure indiquée et à, la suite des causes énumérées ci-dessus.

NAME OF MEDICAL OFFICER Nom du médicin militaire ou du médicin sanitaire	TITLE OR DEGREE Titre ou diplôme
(b)(6)	Medical Examiner

GRADE Grade	INSTALLATION OR ADDRESS Installation ou adresse
(b)(6)	Dover AFB, Dover DE
DATE Date 5/7/2008	SIGNATUR (b)(6)

[1] State disease, injury or complication which caused death, but not mode
[2] State conditions contributing to the death, but not related to the disease or condition causing death
[1] Préciser la nature de la maladie, de la blessure ou de la complication qui a contribué à la mort, mais non la manière de mourir, telle qu'un arrêt du coeur, etc
[2] Préciser la condition qui a contribué à la mort, sans n'avoir aucun rapport avec la maladie ou à la condition qui a provoqué la mort

DD FORM 1 APR 77 2064 REPLACES DA FORM 3565, 1 JAN 72 AND DA FORM 3565-R(PAE), 28 SEP 75, WHICH ARE OBSOLETE.

ACLU Detainee DeathII ARMY MEDCOM 1080

ARMED FORCES INSTITUTE OF PATHOLOGY
Office of the Armed Forces Medical Examiner
1413 Research Blvd., Bldg. 102
Rockville, MD 20850
301-319-0000

AUTOPSY EXAMINATION REPORT

Name: Al-Saaida, Muhammed A.
Detainee Number: (b)(6)
Date of Birth: (b)(6) 1965
Date of Death (b)(6) 2009
Date/Time of Autopsy: 29 Jul 2009 @ 0900
Date of Report: 21 Sep 2009

Autopsy No.: (b)(6)
AFIP No.: (b)(6)
Rank: Detainee
Place of Death: Iraq
Place of Autopsy: Port Mortuary,
Dover Air Force Base, DE

Circumstances of Death: This 44 year-old detainee was being held in custody in Iraq. By report, he was witnessed to collapse by several other detainees at approximately 1600 on (b)(6) 2009. Resuscitation was initiated and he was transferred to the nearest medical facility. All resuscitative efforts were unsuccessful.

Authorization for Autopsy: Armed Forces Medical Examiner, per U.S. Code 10, Section 1471.

Identification: Positive identification by ante-mortem and post-mortem fingerprint comparison.

CAUSE OF DEATH: **Atherosclerotic cardiovascular disease**

MANNER OF DEATH: **Natural**

ACLU Detainee DeathII ARMY MEDCOM 1081

EXTERNAL EXAMINATION

The body is received in a black body bag. Attached to the outermost bag are two paper tags with the name (b)(6) The body is unclad. Paper bags are present on the hands. A paper tag is attached to the left great toe labeled with the name (b)(6) (b)(6) A white tag labeled (b)(6) is placed on the left ankle at intake by mortuary affairs.

The body is that of a well-developed, well-nourished male. The body weighs 170-pounds and measures 67-inches in length. The body is cold. Rigor is present to an equal degree in all extremities. Lividity is present and fixed on the posterior surface of the body, except in areas exposed to pressure. There is mild marbling of the upper and lower extremities.

Injuries to the head and neck are described below in "Evidence of Injury." The head is normocephalic, and the scalp hair is black-gray and short. Facial hair consists of a black-gray beard and moustache. The irides appear brown in color. The corneas are cloudy. The conjunctivae are congested. The sclerae are congested. The external auditory canals, external nares and oral cavity are free of foreign material and abnormal secretions. The earlobes are not pierced. The nasal skeleton and maxilla are palpably intact. The lips are without evident injury. The teeth are natural and in good condition. The neck is straight, and the trachea is midline and mobile.

The chest is symmetric with no external evidence of injury to the ribs or sternum. The posterior torso demonstrates no evidence of trauma. The abdomen is flat with no healed surgical scars present. The genitalia are those of a circumcised adult male. Pubic hair is present in a normal distribution. The anus is non-traumatic. The testes are descended with no palpable masses present.

Injuries to the extremities are described in "Evidence of Injury." The upper and lower extremities are symmetric and without clubbing, edema, fractures, lacerations or deformities. The fingernails are intact and trimmed. The toenails are dystrophic.

Well-healed irregular scars are present on both lower extremities. There are three scars on the medial right thigh, each measuring ½ x ½-inches. There is a 12 x 1-inch irregular scar on the lateral left thigh. There is a 3 x 1-inch irregular scar and a ½ x ½-inch scar on the anterior left thigh. There is a 3 x 1-inch scar on the popliteal fossa of the right knee. There are numerous radio-opaque foreign bodies identified on radiography in both lower extremities that are too small to be recovered.

CLOTHING AND PERSONAL EFFECTS

The following clothing items are received with the body at the time of autopsy:

- Yellow shirt (torn)
- Yellow sweatpants
- White boxer shorts

MEDICAL INTERVENTION

- EKG leads on anterior torso (6)
- Defibrillator pads on left upper torso and left upper back
- Intravascular catheters in the right and left antecubital fossae
- Anterior right rib fractures of 4-5th ribs
- Anterior left rib fracture of 4th rib

RADIOGRAPHS

A complete set of postmortem radiographs is obtained and show no evidence of acute injury.

ACLU Detainee DeathII ARMY MEDCOM 1082

EVIDENCE OF INJURY

Minor injuries:

A ½ x ¼-inch superficial abrasion is on the anterior surface of the scalp. A ½ x ¼-inch abrasion is on the dorsal surface of the left hand.

INTERNAL EXAMINATION

BODY CAVITIES:

See "Medical Intervention." No excess fluid is in the pleural, pericardial, or peritoneal cavities. The organs occupy their usual anatomic positions. The subcutaneous fat layer of the abdominal wall is unremarkable.

HEAD (CENTRAL NERVOUS SYSTEM) and NECK:

See "Evidence of Injury." The galeal and subgaleal soft tissues of the scalp are free of injury. There are no skull fractures. The dura mater is intact with no evidence of hemorrhage. The leptomeninges are thin and delicate. Clear cerebrospinal fluid surrounds the 1383-gram brain, which has unremarkable gyri and sulci. The brain was retained and fixed for Neuropathology consultation (see Appendix A: Neuropathology Consultation). The atlanto-occipital joint is stable. The upper spinal cord is unremarkable.

The anterior strap muscles of the neck are homogenous and red-brown, without hemorrhage. The thyroid cartilage and hyoid bone are intact. The larynx is lined by intact white mucosa. The thyroid gland is symmetric and red-brown, without cystic or nodular change. The tongue is free of bite marks, hemorrhage, or other injuries. Incision and dissection of the posterior neck demonstrates no deep paracervical muscular injury and no cervical spine fractures.

RESPIRATORY SYSTEM:

The airways are clear of debris and foreign material and the mucosal surfaces are smooth, yellow-tan, and unremarkable. The right and left lungs weigh 680-grams each. The external surfaces are smooth and deep red-purple. The pulmonary parenchyma is diffusely congested and edematous. No mass lesions or areas of consolidation are present. The pulmonary arteries are normally developed and patent. The diaphragm is intact.

CARDIOVASCULAR SYSTEM:

The 480-gram heart is contained in an intact pericardial sac. The epicardial surface is smooth, with moderate fat investment. The coronary arteries are present in a normal distribution, with a left-dominant pattern. The proximal left anterior descending coronary artery has greater than 90% atherosclerotic narrowing. The mid left anterior descending coronary artery has a tunnel measuring 0.3-centimeters in depth and 1.5-centimeters in length. The circumflex artery has 50% atherosclerotic narrowing. The right coronary artery has 10% atherosclerotic narrowing. Cross-sections through the myocardium show a 3-centimeter pale area of the posterior left ventricle and posterior ventricular septum. The valve leaflets are thin and mobile. The walls of the left ventricle, interventricular septum, and right ventricle are 1.3, 1.5, and 0.3-centimeters thick, respectively. The endocardium is smooth and glistening. The aorta gives rise to three intact and patent arch vessels with mild atherosclerotic plaque. The renal, mesenteric, and iliac vessels as well as the venae cavae are unremarkable.

ACLU Detainee DeathII ARMY MEDCOM 1083

HEPATOBILIARY SYSTEM:

The 1700-gram liver has an intact, smooth capsule and a sharp anterior border. The parenchyma is tan-brown and congested, with the usual lobular architecture. No mass lesions or other abnormalities are seen. The gallbladder contains 10-milliliters of green-black bile and no stones. The mucosal surface is green and velvety.

LYMPHORETICULAR SYSTEM:

The 160-gram spleen has a smooth, intact, red-purple capsule. The parenchyma is maroon and congested. Lymph nodes in the hilar, periaortic, and iliac regions are unremarkable.

ENDOCRINE SYSTEM:

The pituitary gland is unremarkable. The thyroid gland has been described (see NECK, above). The right and left adrenal glands are symmetric, with bright yellow cortices and red-brown medullae. No masses or areas of hemorrhage are identified.

GENITOURINARY SYSTEM:

The right and left kidneys weigh 160-grams each. The external surfaces are intact and smooth. The cut surfaces are red-tan and congested, with uniformly thick cortices and sharp corticomedullary junctions. The pelves are unremarkable and the ureters are normal in course and caliber. White bladder mucosa overlies an intact bladder wall. The bladder contains approximately 8-milliliters of urine. The prostate is normal in size, with lobular, yellow-tan parenchyma. The seminal vesicles are unremarkable. The testes are free of mass lesions, contusions, or other abnormalities.

GASTROINTESTINAL TRACT:

The esophagus is intact and lined by smooth, gray-white mucosa. The stomach contains approximately 375-milliliters of tan fluid and partially digested food particles. The gastric wall is intact. The duodenum, loops of small bowel and colon are unremarkable. The pancreas is autolyzed with no mass lesions or other abnormalities seen. The appendix is present.

MUSCULOSKELETAL SYSTEM:

No non-traumatic abnormalities of the muscles or bones of the appendicular and axial skeletons are identified. Dissection of the skin of the back, upper and lower extremities show no evidence of deep tissue hemorrhage. Dissection of the skin of the ankles and wrists show no evidence of hemorrhage.

MICROSCOPIC EXAMINATION

Selected portions of organs are retained in formalin with preparation of histologic slides.

- The liver shows congestion and no significant periportal inflammation or portal fibrosis. There is mild steatosis.
- The kidney shows autolysis of the proximal tubules with relative sparing of the glomeruli, distal tubules, and collecting system. There is occasional glomerulosclerosis, mild-moderate hyaline arteriolosclerosis, and scattered patchy chronic inflammation.
- The spleen shows congested parenchyma with normal lymphoid follicle formation and autolytic change.

ACLU Detainee DeathII ARMY MEDCOM 1084

- The lung shows atelectasis with multifocal congestion with no significant intra-alveolar or interstitial inflammation.
- The thyroid shows normal follicles with no increased inflammation or fibrosis.
- The myocardium shows properly arranged myocytes that are with mild enlargement ("boxcar" nuclei). There is no significant increase in fibrosis or inflammation
- The proximal left anterior descending coronary artery shows greater than 90% atherosclerotic narrowing.
- The mid left anterior descending coronary artery shows tunneling of the artery into the myocardium
- The posterior wall of the left ventricle shows extensive fibrosis with no significant acute or chronic inflammation

Slide key:
Slide 1: Thyroid, liver
Slide 2: Spleen, kidney
Slide 3: Right lung
Slide 4: Left lung
Slide 5: Proximal left anterior descending coronary artery
Slide 6: Mid left anterior descending coronary artery with tunneling
Slide 7: Posterior left ventricle

ADDITIONAL PROCEDURES AND REMARKS

1. Documentary photographs are taken by (b)(6) (AFMES staff photographer). Assisting with the autopsy is (b)(6) (AFMES staff).
2. Personal effects are released to the appropriate mortuary operations representatives.
3. Specimens retained for toxicology testing and/or DNA identification are: vitreous fluid, blood, urine, bile, gastric contents, lung, liver, spleen, kidney, psoas muscle, adipose tissue, and myocardium.
4. The dissected organs are forwarded with body.
5. No evidence is recovered.

ACLU Detainee DeathII ARMY MEDCOM 1085

FINAL AUTOPSY DIAGNOSES

I. **Minor abrasions:**
   a. Superficial abrasion on anterior surface of the scalp
   b. Superficial abrasion on dorsal surface of the left hand

II. **Natural disease:**
   a. Severe coronary atherosclerosis
      i. Greater than 90% atherosclerotic narrowing of the proximal left anterior descending coronary artery
      ii. 50% atherosclerotic narrowing of the circumflex artery
      iii. 10% atherosclerotic narrowing of the right coronary artery
      iv. Remote infarction of the posterior left ventricle and posterior ventricular septum
   b. Tunneling of the mid left anterior descending coronary artery

III. **Medical therapy:**
   a. EKG leads (6)
   b. Defibrillator pads (2)
   c. Intravascular catheters in right and left antecubital fossae
   d. Fractures of anterior right 4-5th ribs and anterior left 4th rib, consistent with cardiopulmonary resuscitation

IV. **Post-mortem changes:**
   a. Rigor is present and equal in all extremities
   b. Lividity is posterior and fixed except in areas exposed to pressure
   c. The body temperature is cold
   d. Changes of decomposition including marbling of the upper and lower extremities

V. **Identifying marks:**
   a. Scars: multiple scars on both lower extremities with associated retained radio-opaque foreign bodies identified radiographically

VI. **Toxicology:**
   a. Volatiles: No ethanol is detected in the blood
   b. Drugs: No screened medications or drugs of abuse are detected in the blood
   c. Carbon Monoxide[1]: carboxyhemoglobin saturation in the blood was less than 1%
   d. Cyanide: No cyanide is detected in the blood

[1] Carboxyhemoglobin saturations of 0-3% are expected for non-smokers and 3-10% for smokers.

ACLU Detainee DeathII ARMY MEDCOM 1086

OPINION

This detainee, (b)(6) died as a result of atherosclerotic cardiovascular disease. He had greater than 90% atherosclerotic narrowing of the proximal left anterior descending coronary artery, 50% atherosclerotic narrowing of the circumflex artery, and 10% atherosclerotic narrowing of the right coronary artery. There was fibrosis of the posterior wall of the left ventricle and posterior ventricular septum indicating a healed infarction. The histologic changes in the kidney are consistent with hypertension. The toxicology screen is negative for ethanol, carbon monoxide, cyanide, drugs of abuse, and screened medications. The manner of death is natural.

(b)(6)

(b)(6) Medical Examiner

(b)(6)

(b)(6) Medical Examiner

ACLU Detainee DeathII ARMY MEDCOM 1087

Appendix A: Neuropathology Consultation

GROSS DESCRIPTION:

Brain weight: 1383 mg

The specimen consists of the dura and brain of an adult.

The intracranial dura is not remarkable. The venous sinuses are patent.

Due to early autolysis, the external features of the brain are slightly discolored red-brown and the cut surfaces are discolored gray. The brain is well fixed.

The leptomeninges are thin, delicate and transparent. The cerebral gyri have an anatomically normal size, configuration and consistency. The perisellar, perimesencephalic and cerebellomedullary cisterns have a normal configuration and size.

There is no sign of herniation or midline shirt. Moderately deep tentorial grooves indent each uncus approximately 0.4 cm from the medial margins. The cerebellar tonsils have a normal configuration. The external aspects of the brainstem and cerebellum are not remarkable. The arteries at the base of the brain follow a normal distribution and show moderately severe atherosclerosis. There are no aneurismal dilatations or sites of occlusion. The identifiable cranial nerve roots are not remarkable.

Coronal sections of the cerebrum reveal no focal or diffuse abnormalities in the cortex, white matter or deep nuclear structures. Due to autolysis, the septum pellucidum is almost completely dissolved. There is no midline shift. Sections of the midbrain, pons, medulla and cerebellum show no diffuse or focal abnormalities. The substantia nigra and locus coeruleus are well pigmented. Except as noted, the ventricular system has an anatomically normal size and configuration. The aqueduct of Sylvius and the foramina of Luschka and Magendie are patent. The choroid plexus is unremarkable and the ependymal surfaces are smooth and glistening.

PHOTOGRAPHS: Yes

MICROSCOPIC EXAMINATION:

Blocks of tissue for microscopic examination are removed from : (1) left frontal lobe, (2) anterior corpus callosum/cingulate gyri/septum pellucidum, (3) left insula/claustrum/external capsule/putamen/globus pallidus/internal capsule, (4) right thalamus/posterior limb of internal capsule, (5) left hippocampus, (6) left occipital lobe/occipital horn of lateral ventricle, (7) right cerebellum, (8) left pons/medulla/cerebellum (cerebellomedullary cistern), (9) dura.

Sections from each block are stained with H&E, LFB, Bielschowsky and iron (Prussian Blue) techniques and immunostained for β-amyloid precursor protein (β-APP).

MICROSCOPIC FINDINGS:

The microscopic sections show mild/moderate autolysis of the ependymal surfaces and septum pellucidum.

ACLU Detainee DeathII ARMY MEDCOM 1088

In the section of cerebellomedullary cistern that includes midline cerebellum and floor of the fourth ventricle there are small foci of acute subarachnoid hemorrhage in the cerebellar folia that are consistent with agonal ischemia. There is no associated vascular anomaly or tumor.
In scattered areas of the cerebral cortex and basal ganglia there are individual moderaltely eosinophilic neurons suggestive of early ischemic neuronal injury.

DIAGNOSIS:

Brain, autopsy:

1. Early ischemic neuronal injury
2. Mild postmortem autolysis

(b)(6)

NEUROPATHOLOGIST
15 Sep 2009

ACLU Detainee DeathII ARMY MEDCOM 1089

CERTIFICATE OF DEATH *(OVERSEAS)*
Acte de décès (D'Outre-Mer)

NAME OF DECEASED *(Last, First, Middle)* Nom du décédé (Nom et prénoms)	GRADE Grade	BRANCH OF SERVICE Arme	SOCIAL SECURITY NUMBER Numéro de l'Assurance Social
Al-Saaida, Muhammed, Abd Frayh		Civilian	(b)(6)

ORGANIZATION Organisation	NATION *(e.g. United States)* Pays	DATE OF BIRTH Date de naissance	SEX Sexe
	Iraq	(b)(6) 1965	[X] MALE [ ] FEMALE

RACE Race		MARITAL STATUS État Civil			RELIGION Culte		
[X]	CAUCASOID Caucasique	[ ]	SINGLE Célibataire	[ ] DIVORCED Divorcé	[ ]	PROTESTANT Protestant	[ ] OTHER (Specify) Autre (Spécifier)
[ ]	NEGROID Negroide	[ ]	MARRIED Marié	[ ] SEPARATED Séparé	[ ]	CATHOLIC Catholique	[X]
[ ]	OTHER (Specify) Autre (Spécifier)	[ ]	WIDOWED Veuf		[ ]	JEWISH Juif	

NAME OF NEXT OF KIN Nom du plus proche parent	RELATIONSHIP TO DECEASED Parenté du décédé avec le sus
STREET ADDRESS Domicilé à (Rue)	CITY OR TOWN OR STATE *(Include ZIP Code)* Ville (Code postal compris)

MEDICAL STATEMENT Déclaration médicale

	CAUSE OF DEATH (Enter only one cause per line) Cause du décès (N'indiquer qu'une cause par ligne)	INTERVAL BETWEEN ONSET AND DEATH Intervalle entre l'attaque et le décès
DISEASE OR CONDITON DIRECTLY LEADING TO DEATH [1] Maladie ou condition directement responsable de la mort [1]	Atherosclerotic cardiovascular disease	
ANTECEDENT CAUSES Symptômes précurseurs de la mort. MORBID CONDITION, IF ANY, LEADING TO PRIMARY CAUSE Condition morbide, s'il y a lieu, menant à la cause primaire		
UNDERLYING CAUSE, IF ANY, GIVING RISE TO PRIMARY CAUSE Condition morbide, s'il y a lieu, menant à la cause primaire		
OTHER SIGNIFICANT CONDITIONS [2] Autres conditions significatives [2]		

MODE OF DEATH Condition de décès	AUTOPSY PERFORMED Autopsie effectuée	CIRCUMSTANCES SURROUNDING DEATH DUE TO EXTERNAL CAUSES Circonstances de la mort suscitées par des causes extérieures
[X] NATURAL Mort naturelle	[X] YES Oui [ ] NO Non	
[ ] ACCIDENT Mort accidentelle	MAJOR FINDINGS OF AUTOPSY Conclusions principales de l'autopsie	
[ ] SUICIDE Suicide	NAME OF PATHOLOGIST Nom du pathologiste (b)(6)	
[ ] HOMICIDE Homicide	SIGNATURE (b)(6) DATE Date 29 July 2009	AVIATION ACCIDENT Accident à Avion [ ] YES Oui [X] NO Non

DATE OF DEATH *(day, month, year)* Date de décès (le jour, le mois, l'année)	PLACE OF DEATH Lieu de décès
(b)(6) 2009	Camp Bucca Iraq

I HAVE VIEWED THE REMAINS OF THE DECEASED AND DEATH OCCURRED AT THE TIME INDICATED AND FROM THE CAUSES AS STATED ABOVE.
J'ai examiné les restes mortels du dé funtet je conclus que le décès est survenu à l'heure indiquée et à, la suite des causes énumérées ci-dessus

NAME OF MEDICAL OFFICER Nom du médecin militaire ou du médecin sanitaire	TITLE OR DEGREE Titre ou diplôme
(b)(6)	Medical Examiner

GRADE Grade	INSTALLATION OR ADDRESS Installation ou adresse
(b)(6)	Dover AFB, Dover DE
DATE Date 9/21/2009	SIGNATURE (b)(6)

[1] State disease, injury or complication which caused death, but not mode of dying such as heart failure, ect.
[2] State conditions contributing to the death, but not related to the disease or condition causing death.
[1] Préciser la nature de la maladie, de la blessure ou de la complication qui a contribué à la mort, mais non la manière de mourir, telle qu 'un arrêt du coeur, etc
[2] Préciser la condition qui a contribué à la mort, mais n'ayant aucun rapport avec la maladie ou à la condition qui a provoqué la mort.

DD FORM 1 APR 77 2064 REPLACES DA FORM 3565, 1 JAN 72 AND DA FORM 3565-R(PAS), 26 SEP 75, WHICH ARE OBSOLETE.

MEDCOM 1090

ACLU Detainee DeathII ARMY MEDCOM 1090

(REMOVE, REVERSE AND RE-INSERT CARBONS BEFORE COMPLETING THIS SIDE)

DISPOSITON OF REMAINS

NAME OF MORTICIAN PREPARING REMAINS	GRADE	LICENSE NUMBER AND STATE	OTHER

INSTALLATION OR ADDRESS	DATE	SIGNATURE
(b)(6)		

NAME OF CEMETERY OR CREMATORY	LOCATION OF CEMETERY OR CREMATORY

TYPE OF DISPOSTION	DATE OF DISPOSTION

REGISTRATION OF VITAL STATISTICS

REGISTRY *(Town and Country)*	DATE REGISTERED	FILE NUMBER	
		STATE	OTHER

NAME OF FUNERAL DIRECTOR	ADDRESS

SIGNATURE OF AUTHORIZED INDIVIDUAL

DD FORM 2064, APR 1977 (BACK) *USAPA V1.00*

ACLU Detainee DeathII ARMY MEDCOM 1091

ARMED FORCES INSTITUTE OF PATHOLOGY
Office of the Armed Forces Medical Examiner
1413 Research Blvd., Bldg. 102
Rockville, MD 20850
1-301-319-0000

AUTOPSY EXAMINATION REPORT

Name: Fallah (Ismail), Mahmud Al Juburi
Approx Age: 30-years old
Date of Death (b)(6) 2009
Date/Time of Autopsy: 11 JUL 2009/1300
Date of Report: 07 OCT 2009

Autopsy No.: (b)(6)
AFIP No.: (b)(6)
Rank: Detainee
Place of Death: Iraq
Place of Autopsy: BIAP Mortuary
BIAP, Iraq

Circumstances of Death: This young adult male (b)(6) was placed in flex cuffs while being taken into custody by assault forces in Iraq. Investigative reports indicate that (b)(6) broke loose from his restraints and attempted to gain control of an assault force member's weapon. (b)(6) received small arms fire from other members of the assault force.

Authorization for Autopsy: Armed Forces Medical Examiner, per 10 U.S. Code 1471

Identification: Presumptive identification by accompanying reports, identification tags and documentation. Postmortem fingerprint examination and postmortem DNA samples are taken for profile purposes should exemplars becomes available for positive identification.

CAUSE OF DEATH: Multiple Gunshot Wounds

MANNER OF DEATH: Homicide

ACLU Detainee DeathII ARMY MEDCOM 1092

EXTERNAL EXAMINATION

Injuries will be described in detail in a separate section, and will only be briefly alluded to in the remainder of the report, for purposes of orientation and completeness. The body is that of a well-developed, well-nourished appearing, young adult male detainee of undetermined age (approximately 30-years old). The body is received clad in a blood and body fluid soaked tan tunic, white sleeveless undershirt, and white boxer shorts. The remains are 70-inches in length, and weigh approximately 123-pounds. Lividity is present and fixed on the posterior surface of the body except in areas exposed pressure. Rigor is present to an equal degree in all extremities. The temperature of the body is that of the refrigeration unit.

The head is normocephalic, and the scalp is covered with wavy black hair, in a normal distribution and measuring up to 2-inches in greatest length. There is a trim black mustache and the remainder of the face is clean shaven. The irides are brown. The corneae are clear. The conjunctivae are pale. The pupils are round and equal in diameter. The sclerae are white and without petechial hemorrhage. The external nares and oral cavity are free of foreign material and abnormal secretions. The earlobes are unremarkable. The nares are patent and the lips are atraumatic. The nasal skeleton and maxillae are palpably intact. The teeth appear natural and in good condition. The neck is straight, and the trachea is midline and mobile.

The chest is symmetric. The abdomen is flat. The genitalia are those of a normal adult circumcised male. The testes are descended and free of masses. Body hair is present in a normal male distribution. The buttocks and anus are unremarkable.

The upper and lower extremities are symmetric and without clubbing, edema, or non-traumatic abnormalities. The fingernails are intact and the nail beds are cyanotic.

No tattoos or surgical scars are noted.

CLOTHING AND PERSONAL EFFECTS

The following clothing items and personal effects are present on or accompany the body at the time of autopsy:

- White boxer shorts
- Tan tunic
- White sleeveless undershirt

MEDICAL INTERVENTION

No evidence of medical intervention is in place at the time of autopsy.

ACLU Detainee DeathII ARMY MEDCOM 1093

RADIOGRAPHS

A complete set of postmortem radiographs is obtained and demonstrates the following:

- No retained bullet fragments in the head and chest
- Multiple non-depressed skull fractures and anterior pneumocephalus
- Transverse and oblique fractures of the right temporal and bilateral frontal bones
- Transverse frontoethmoidal fracture with fractures of the frontal and ethmoid sinuses and cribriform plate
- Bilateral asymmetric lung consolidation, right greater than left
- Pneumomediastinum and pneumopericardium
- No fractures/dislocations of the spine or extremities
- Soft tissue calcification in the medial left proximal thigh

EVIDENCE OF INJURY

The ordering of the following injuries is for descriptive purposes only, and is not intended to imply order of infliction or relative severity. All wound pathways are given relative to standard anatomic position.

A. Multiple gunshot wounds:

I. Gunshot wound of the head:

A gunshot entrance wound is on the underside of the jaw located 9-inches below the top of the head and 3/4-inches to the left of the anterior midline. The circular wound measures 3/8-inches in diameter. No soot or stippling is present within the wound or on the surrounding skin. The wound path perforates skin, basilar skull (predominantly the sphenoid bone), right cerebral hemisphere, sagittal suture at the vertex of the calvarium, and right parietal scalp. The bullet exits the vertex of the head 1/2-inches to the right of the anterior midline via an obliquely oriented (along the 5 to 11 o'clock axis) 1 1/2 x 3/4-inch lacerated wound with extension lacerations measuring up to 3/4-inches. No bullet or bullet fragments are recovered. The wound path is directed slightly front to back, slightly left to right, and upwards. Associated with the wound path is bleeding into the wound tract, comminuted fractures of the basilar skull (disruption of both anterior and both middle cranial fossae), linear fractures of the frontal and left parietal bones, diastatic fractures along the coronal and sagittal sutures, pulpifying lacerations of both frontal lobes of the brain, diffuse subarachnoid hemorrhage, bilateral periorbital ecchymosis, avulsive loss of the pituitary gland, and disruption of the circle of Willis.

II. Gunshot wound of the head:

A gunshot entrance wound is on the right temporal scalp located 3 1/4-inches below the top the head and 4-inches to the right of the anterior midline. The circular wound measures 1/4-inches with an eccentric marginal abrasion along the 6 to 12 o'clock margin measuring up to 1/8-inches at the 9 o'clock position. There is a cone of dense gunpowder stippling extending from the 12 to 6 o'clock margin 2-inches onto the right side of the forehead. The wound path perforates the right temporal scalp, the right side of the calvarium at the pterion, both

ACLU Detainee DeathII ARMY MEDCOM 1094

Evidence of Injury (cont):

II. Gunshot wound of the head (cont):
frontal lobes of the brain, left temporal bone, and left temporal scalp. The bullet exits the left temporal scalp via a 1/2-inch lacerated exit wound located 2 3/4-inches below the top the head and 3 5/8-inches to the left of the anterior midline. No bullet or bullet fragments are recovered. The wound path is directed right to left, slightly back to front, and slightly upward. Associated with the wound path is bleeding into the wound tract, comminuted fractures of the basilar skull (disruption of both anterior and both middle cranial fossae), linear fractures of the frontal and left parietal bones, diastatic fractures along the coronal and sagittal sutures, pulpifying lacerations of both frontal lobes of the brain, diffuse subarachnoid hemorrhage, subgaleal hemorrhage overlying fractures of both temporal bones and the occipital bone, and bilateral periorbital ecchymosis.

III. Gunshot wound of the chest:
On the right anterior chest is a gunshot entrance wound located 6-inches below the top the shoulder and 5 1/2-inches to the right of the anterior midline of the torso. The horizontally oriented ovoid wound measures 3/8 x 1/4-inches with an eccentric marginal abrasion along the lateral margin of the wound measuring up to 1/2-inches at the 9 o'clock position. Faint gunpowder stippling extends from the lateral margin of the abraded entrance wound measuring up to 1-inch at the 9 o'clock position. On the lateral right arm is a 3/4 x 1/2-inch area of faint stippling. The wound path perforates skin, muscle, anterior right third rib, soft tissues of the anterior mediastinum, left anterior 4th intercostal space, muscle, and skin. The bullet exits the left anterior chest along the anterior axillary line via a 1/2-inch lacerated exit wound with eccentric marginal abrasion along the 12 to 6 o'clock margin measuring up to 1/8-inch at the 3 o'clock position that is located 8-inches below the top the shoulder and 8-inches to the left of the anterior midline. No bullet or bullet fragments are recovered. The wound path is directed front to back, right to left, and slightly downward. Associated with the wound path is bleeding into the wound tract, non quantifiable hemorrhage into the anterior mediastinum, fractures of the anterior aspects of the 2nd through 4th ribs bilaterally, fracture of the sternum at the level of the 3rd ribs, and contusions of the upper lobes of both lungs.

IV. Gunshot wound of the left arm:
On the anterior left arm is a gunshot entrance wound located 8-inches below the top of the shoulder and in the midline of the upper extremity in the anatomic position. The circular wound measures 3/8-inches in diameter and has an adjacent vertically oriented discontinuous 2 x 3/8-inch contused abrasion. No soot or gun powder stippling are at present within the wound or on the surrounding skin. The wound path perforates skin, subcutaneous tissues, muscle, subcutaneous tissues, and skin. The bullet exits the posterior left arm via a 1/4-inch diameter lacerated exit wound located 8-inches below the top of the shoulder and in the posterior midline of the upper extremity in the anatomic position. No bullet or bullet fragments are recovered. The wound path is

ACLU Detainee DeathII ARMY MEDCOM 1095

Evidence of Injury (cont):

directed right to left, front to back, and without vertical deviation. Associated with the wound path is bleeding into the wound tract.

B. Additional autopsy findings

I. Injuries to the Head and Neck:
Above the lateral right eyebrow at the frontal hairline is a 3/4 x 1/2-inch superficial abrasion. Blood drains from both the external auditory canals.

II. Injuries to the torso:
On the left anterior chest approximately 4 inches below the left nipple is an obliquely oriented (along the 5 to 11 o'clock axis) 3/4 x 1/4-inch superficial abrasion. In the left lower quadrant of the abdomen are 2 discontinuous horizontally oriented curvilinear abrasions spaced approximately 1 1/2-inches apart and measuring up to 4 1/4-inches in greatest dimension. Above the left iliac crest is a 3/4 x 1/2-inch superficial abrasion. Along the left inguinal crease and anterior upper thighs is a 4 x 2 1/2-inch cluster of discontinuous superficial abrasions measuring up to 2-inches in greatest dimension.

III. Injuries to the extremities:
On the lateral dorsal aspect of the distal right forearm is a horizontally oriented faint 2 1/4 x 1/8-inch contusion without injury to the underlying soft tissues. On the distal left forearm is a circumferential 1/8-inch superficial contusion without injury to the underlying soft tissues.
On the anterior left thigh is a 7 x 5-inch cluster of patterned (paired markings with an approximate 1 1/2-inch spacing) superficial commingled abrasions and superficial puncture wounds measuring up to 1-inch in greatest dimension. Similar clusters of superficial abrasions and superficial puncture wounds measuring up to 1-inch in greatest dimension are noted on the left knee, proximal medial left leg, left popliteal fossa, and left proximal posterior leg. Reflection of the skin and subcutaneous tissues of the back, buttocks, and extremities with incision of the underlying muscles demonstrates no evidence of significant blunt force injuries.

INTERNAL EXAMINATION

The following descriptions pertain to uninjured tissues. See "Evidence of Injury" section for additional information.

BODY CAVITIES:
(See "Evidence of Injury")
The body is opened by the usual thoraco-abdominal incision and the chest plate is removed. The vertebral bodies are visibly and palpably intact. No adhesions or abnormal collections of fluid are present in the pleural, pericardial, or peritoneal cavities. All body organs are present in their normal anatomic positions. There is no internal evidence of blunt force or penetrating injury to the thoraco-abdominal region.

The subcutaneous fat layer of the abdominal wall is 1/2-inches thick.

ACLU Detainee DeathII ARMY MEDCOM 1096

HEAD AND CENTRAL NERVOUS SYSTEM:
(See above "Evidence of Injury")
The scalp is reflected. No epidural or subdural hemorrhages are noted. The leptomeninges are thin and delicate. the brain weighs 1420-grams. Where uninjured, the cerebral hemispheres are symmetrical with unremarkable gyri and sulci. The structures at the base of the brain, including cranial nerves and blood vessels, have no non-traumatic abnormalities.
Coronal sections of the uninjured tissues demonstrate sharp demarcation between white and grey matter, without hemorrhage or contusive injury. The ventricles are of normal size. The basal ganglia, brainstem, cerebellum, and arterial systems are free of non-traumatic abnormalities. The atlanto-occipital joint is stable.

NECK:
The anterior strap muscles of the neck are homogeneous and red-brown, without hemorrhage. The thyroid cartilage and hyoid bone are intact. The larynx is lined by intact white mucosa. The tongue is free of bite marks, hemorrhage, or other injuries.

Incision and dissection of the posterior neck demonstrates no deep paracervical muscular injury and no cervical spine fractures.

RESPIRATORY SYSTEM:
(See above "Evidence of Injury")
The upper airway is clear of debris and foreign material; the mucosal surfaces are smooth, yellow-tan and unremarkable. The pleural surfaces are smooth, glistening and unremarkable bilaterally. The pulmonary parenchyma, where uninjured, is salmon pink, diffusely congested and edematous, exuding slight to moderate amounts of blood and frothy fluid. No mass lesions or areas of consolidation are present. The right and left lungs weigh 710 and 500-grams, respectively.

CARDIOVASCULAR SYSTEM:
(See above "Evidence of Injury")
The pericardial surfaces are smooth, glistening and unremarkable. The 310-gram heart is contained in an intact pericardial sac free of significant fluid or adhesions. The epicardial surface is smooth, with minimal fat investment. The coronary arteries arise normally, follow the usual distribution in a right dominant pattern, are widely patent, and without evidence of thrombosis or significant atherosclerosis. The myocardium is homogeneous, red-brown, firm and unremarkable; the atrial and ventricular septae are intact. The walls of the left and right ventricles are 1.0 and 0.3-centimeters thick, respectively. The valve leaflets are thin and mobile. The aorta and its major branches arise normally, follow the usual course and are free of significant abnormalities. There is mild atherosclerotic streaking in the thoracic aorta. The venae cavae and their major tributaries return to the heart in the usual distribution and are free of thrombi. The renal and mesenteric vessels are unremarkable.

ACLU Detainee DeathII ARMY MEDCOM 1097

HEPATOBILIARY SYSTEM:
The hepatic capsule is smooth, glistening and intact, covering dark red-brown, moderately congested parenchyma. No mass lesions or other abnormalities are noted. The gallbladder contains 5-milliliters of green-brown mucoid bile; the mucosa is velvety and unremarkable. The extrahepatic biliary tree is patent and without evidence of calculi. The liver weighs 1690-grams.

GASTROINTESTINAL TRACT:
The esophagus is intact and lined by smooth, gray-white mucosa. The gastric wall is intact and the stomach contains approximately 30-milliliters of thin tan fluid. The gastric mucosa is arranged in the usual rugal folds. The duodenum, loops of small bowel and colon are unremarkable. The appendix is present.

GENITOURINARY SYSTEM:
The right and left kidneys weigh 120 and 110-grams, respectively. The renal capsules are smooth and thin, semi-transparent and strip with ease from the underlying smooth, red-brown cortical surface. The cut surfaces are red-tan and congested, with uniformly thick cortices and sharp corticomedullary junctions. The pelves and calyces are unremarkable. The ureters are normal in course and caliber. White bladder mucosa overlies an intact bladder wall. The urinary bladder is empty. The prostate is normal in size, with lobular, yellow-tan parenchyma. The seminal vesicles are unremarkable. The testes are free of mass lesions, contusions, or other abnormalities.

LYMPHORETICULAR SYSTEM:
The 170-gram spleen has a smooth, intact capsule covering maroon, moderately firm parenchyma; the lymphoid follicles are unremarkable. Lymph nodes in the hilar, periaortic, and iliac regions are not enlarged.

ENDOCRINE SYSTEM:
(See above "Evidence of Injury")
The thyroid gland is symmetric and red-brown, without cystic or nodular change. The pancreas is firm and yellow-tan, with the usual lobular architecture. No mass lesions or other abnormalities are noted. The right and left adrenal glands are symmetric, with bright yellow cortices and grey medullae. No masses or areas of hemorrhage are identified.

MUSCULOSKELETAL SYSTEM:
Muscle development appears normal. No non-traumatic bone or joint abnormalities are noted.

ACLU Detainee DeathII ARMY MEDCOM 1098

ADDITIONAL PROCEDURES

1. Documentary photographs are taken by (b)(6) OAFME staff photographer.
2. Specimens retained for toxicology testing and/or DNA identification are: Blood, vitreous fluid, gastric contents, bile, heart, spleen, liver, lung, kidney, brain, adipose tissue, and skeletal muscle.
3. Full body radiographs are obtained and demonstrate the above findings.
4. Selected portions of organs are retained in formalin.
5. The dissected organs are forwarded with the body.
6. Personal effects are released to the mortuary affairs representatives.

MICROSCOPIC EXAMINATION

Selected portions of organs are retained in formalin, without preparation of histologic slides.

ACLU Detainee DeathII ARMY MEDCOM 1099

FINAL AUTOPSY DIAGNOSES:

I. Multiple gunshot wounds
A. Gunshot wound of the head
1. Entrance: On the underside of the jaw, to the left of the anterior midline. No evidence of close range discharge of a firearm.
2. Injured: Skin, basilar skull (predominantly the sphenoid bone), right cerebral hemisphere, sagittal suture at the vertex of the calvarium, and right parietal scalp
3. Exit: Vertex of the head, to the right of the midline
4. Recovered: No bullet or bullet fragments are recovered
5. Direction: Slightly front to back, slightly left to right, and upwards
6. Associated injuries: Bleeding into the wound tract, comminuted fractures of the basilar skull (disruption of both anterior and both middle cranial fossae), linear fractures of the frontal and left parietal bones, diastatic fractures along the coronal and sagittal sutures, pulpifying lacerations of both frontal lobes of the brain, diffuse subarachnoid hemorrhage, bilateral periorbital ecchymosis, avulsive loss of the pituitary gland, and disruption of the circle of Willis

B. Gunshot wound of the head
1. Entrance: Right temporal scalp. Dense stippling on the skin of the forehead adjacent to the wound.
2. Injured: Right temporal scalp, the right side of the calvarium at the pterion, both frontal lobes of the brain, left temporal bone, and left temporal scalp
3. Exit: Left temporal scalp
4. Recovered: No bullet or bullet fragments are recovered
5. Direction: Right to left, slightly back to front, and slightly upward
6. Associated injuries: Bleeding into the wound tract, comminuted fractures of the basilar skull (disruption of both anterior and both middle cranial fossae), linear fractures of the frontal and left parietal bones, diastatic fractures along the coronal and sagittal sutures, pulpifying lacerations of both frontal lobes of the brain, diffuse subarachnoid hemorrhage, subgaleal hemorrhage overlying fractures of both temporal bones and the occipital bone, and bilateral periorbital ecchymosis

C. Gunshot wound of the chest
1. Entrance: Right anterior chest. Stippling on the right lateral edge of the wound and on the lateral right arm
2. Injured: Skin, muscle, anterior right third rib, soft tissues of the anterior mediastinum, left anterior 4th intercostal space, muscle, and skin
3. Exit: Left anterior chest along the anterior axillary line
4. Recovered: No bullet or bullet fragments are recovered
5. Direction: Front to back, right to left, and slightly downward
6. Associated injuries: Bleeding into the wound tract, non quantifiable hemorrhage into the anterior mediastinum, fractures of the anterior aspects of the 2nd through 4th ribs bilaterally, fracture of the sternum at the level of the 3rd ribs, and contusions of the upper lobes of both lungs.

ACLU Detainee DeathII ARMY MEDCOM 1100

D. Gunshot wound of the left arm
1. Entrance: Anterior left arm. No evidence of close range discharge of a firearm
2. Injured: Skin, subcutaneous tissues, muscle, subcutaneous tissues, and skin
3. Exit: Posterior left arm
4. Recovered: No bullet or bullet fragments are recovered
5. Direction: Right to left, front to back and without significant vertical deviation
6. Associated injuries: Bleeding into the wound tract

II. Additional injuries
A. Superficial abrasion of the face
B. Superficial patterned abrasions and superficial puncture wounds of the torso and left lower extremity
C. Superficial contusions of both forearms without underlying soft tissue injury

III. Evidence of natural disease consists of mild atherosclerotic streaking of the thoracic aorta

IV. No evidence of medical intervention is in place at the time of autopsy

V. Postmortem changes
A. Lividity is fixed on the posterior surface of the body except in areas exposed to pressure
B. Rigor is present to an equal degree in all extremities

VI. Toxicology results
A. Volatiles: The blood and vitreous fluid were examined for the presence of ethanol at a cutoff of 20 mg/dL. No ethanol was detected.
B. Drugs: The blood was screened for acetaminophen, amphetamine, antidepressants, antihistamines, barbiturates, benzodiazepines, cannabinoids, chloroquine, mefloquine, cocaine, dextromethorphan, lidocaine, narcotic analgesics, opiates, phencyclidine, phenothiazines, salicylates, sympathomimetic amines, and verapamil by gas chromatography, color test or immunoassay. The following drugs were detected: None detected.
C. Carbon Monoxide: The carboxyhemoglobin saturation in the blood was 6% as determined by spectrophotometry with a limit of quantitation of 1%. Carboxyhemoglobin saturations of 0-3% are expected for non-smokeers and 3-10% for smokers. Saturations above 10% are considered elevated and are confirmed by gas chromatography.
D. Cyanide: There was no cyanide detected in the blood. The limit of quantitation for cyanide is 0.25 mg/L.

ACLU Detainee DeathII ARMY MEDCOM 1101

OPINION

This approximately 30-year old detainee (b)(6) died as the result of multiple (4) gunshot wounds. There are two (2) gunshot wounds of the head. Evidence of intermediate range discharge of a firearm is noted surrounding the entrance wound on the right temple. No evidence of close range discharge of a firearm is noted on the entrance wound beneath the chin. Co-mingling of the wound paths in the head does not allow for identification of the order of infliction. The severity of the combined gunshot wounds to the head would have resulted in immediate death. The gunshot wound of the chest injured the ribs, sternum, and soft tissues of the anterior chest cavity. Evidence of intermediate range discharge of a firearm is noted on the surrounding tissues of the chest and right arm. Although not injuring vital structures directly, this injury may have ultimately resulted in death. The gunshot wound of the left arm did not injure vital structures and most likely represents re-entry of the projectile that exited the left side of the chest. No bullet or bullet fragments were recovered.

The injuries to both forearms are consistent with the reported use of restraints. No restraints were available for examination at the time of autopsy. The additional superficial patterned injuries on the torso and left leg did not injure vital structures.

Postmortem analysis of the body fluids was negative for the presence of ethanol, carbon monoxide, cyanide, screened medications and screened illicit drugs of abuse.

The manner of death is best classified as homicide.

(b)(6)

(b)(6) Medical Examiner

ACLU Detainee DeathII ARMY MEDCOM 1102

CERTIFICATE OF DEATH *(OVERSEAS)*
Acte dé décès (D'Outre-Mer)

NAME OF DECEASED *(Last, First, Middle)* Nom du décédé (Nom et prénoms)	GRADE Grade	BRANCH OF SERVICE Arme	SOCIAL SECURITY NUMBER Numéro de l'Assurance Social
BTB Fallah (Ismail), Mahmud Al Juburi,		Civilian	AFIP: (b)(6)

ORGANIZATION Organisation	NATION *(e.g. United States)* Pays	DATE OF BIRTH Date de naissance	SEX Sexe
	Iraq		[X] MALE [ ] FEMALE

RACE Race		MARITAL STATUS État Civil				RELIGION Culte			
[X]	CAUCASOID Caucasique	[ ]	SINGLE Célibataire	[ ]	DIVORCED Divorcé	[ ]	PROTESTANT Protestant	[X]	OTHER (Specify) Autre (Spécifier)
[ ]	NEGROID Negriode	[ ]	MARRIED Marié	[ ]	SEPARATED Séparé	[ ]	CATHOLIC Catholique		
[ ]	OTHER (Specify) Autre (Spécifier)	[ ]	WIDOWED Veuf			[ ]	JEWISH Juif		

NAME OF NEXT OF KIN Nom du plus proche parent	RELATIONSHIP TO DECEASED Parenté du décède avec le sus
STREET ADDRESS Domicilé à (Rue)	CITY OR TOWN OR STATE *(Include ZIP Code)* Ville (Code postal compris)

MEDICAL STATEMENT Déclaration médicale

CAUSE OF DEATH (Enter only one cause per line) Cause du décès (N'indiquer qu'une cause par ligne)		INTERVAL BETWEEN ONSET AND DEATH Intervalle entre l'attaque et le décès
DISEASE OR CONDITON DIRECTLY LEADING TO DEATH [1] Maladie ou condition directement responsable de la mort.	Multiple Gunshot Wounds	
ANTECEDENT CAUSES Symptômes précurseurs de la mort. — MORBID CONDITION, IF ANY, LEADING TO PRIMARY CAUSE Condition morbide, s'il y a lieu, menant à la cause primaire		
UNDERLYING CAUSE, IF ANY, GIVING RISE TO PRIMARY CAUSE Condition morbide, s'il y a lieu, menant à la cause primaire		
OTHER SIGNIFICANT CONDITIONS [2] Autres conditions significatives [2]		

MODE OF DEATH Condition de décès	AUTOPSY PERFORMED Autopsie effectuée [X] YES Oui [ ] NO Non	CIRCUMSTANCES SURROUNDING DEATH DUE TO EXTERNAL CAUSES Circonstances de la mort suscitées par des causes extérieures
[ ] NATURAL Mort naturelle	MAJOR FINDINGS OF AUTOPSY Conclusions principales de l'autopsie	
[ ] ACCIDENT Mort accidentelle		
[ ] SUICIDE Suicide	NAME OF PATHOLOGIST Nom du pathologiste (b)(6)	
[X] HOMICIDE Homicide	SIGNATURE Signature (b)(6) — DATE Date 11 July 2009	AVIATION ACCIDENT Accident à Avion [ ] YES Oui [X] NO Non

DATE OF DEATH *(day, month, year)* Date de décès (le jour, le mois, l'année)	PLACE OF DEATH Lieu de décès
(b)(6) 2009	Iraq

I HAVE VIEWED THE REMAINS OF THE DECEASED AND DEATH OCCURRED AT THE TIME INDICATED AND FROM THE CAUSES AS STATED ABOVE.
J'ai examiné les restes mortels du dé funtet je conclus que le décès est survenu à l'heure indiquée et à, la suite des causes énumérées ci-dessus.

NAME OF MEDICAL OFFICER Nom du médicin militaire ou du médicin sanitaire	TITLE OR DEGREE Titre ou diplômé
(b)(6)	Medical Examiner

GRADE Grade	INSTALLATION OR ADDRESS Installation ou adresse
(b)(6)	Dover AFB, Dover DE
DATE Date 11/23/2009	SIGNATURE Signature (b)(6)

[1] State disease, injury or complication which caused death, but not mode of dying such as heart failure, ect.
[2] State conditions contributing to the death, but not related to the disease or condition causing death.
[1] Préciser la nature de la maladie, de la blessure ou de la complication qui a contribué à la mort, mais non la manière de mourir, telle qu 'un arrêt du coeur, etc
[2] Préciser la condition qui a contribué à la mort, mais n'ayant aucun rapport avec la maladie ou à la condition qui a provoqué la mort.

DD FORM 1 APR 77 2064 REPLACES DA FORM 3565, 1 JAN 72 AND DA FORM 3565-R(PAS), 26 SEP 75, WHICH ARE OBSOLETE.

ACLU Detainee DeathII ARMY MEDCOM 1103

ARMED FORCES INSTITUTE OF PATHOLOGY
Office of the Armed Forces Medical Examiner
1413 Research Blvd., Bldg. 102
Rockville, MD 20850
1-301-319-0000
(FAX 1-301-319-0635)

FINAL AUTOPSY REPORT

Name: Al Hanashi, Muhammad Ahmad A.S. Autopsy No.: (b)(6)
ID No: (b)(6) AFIP No. (b)(6)
Date of Birth: Unknown Rank: Civilian (Detainee)
Date of Death: (b)(6) 2009 Place of Death: Guantanamo Bay
Date of Autopsy: 03 JUN 2009, 1300 hours Place of Autopsy: US Naval Hospital
Date of Report: 23 JUN 2009 Guantanamo Bay, Cuba

Circumstances of Death:
(b)(6) a civilian detainee, was found unresponsive with a ligature (elastic band) around his neck in his cell at the Behavior Health Unit (BHU), Joint Task Force Guantanamo Bay, Cuba at approximately 2200 hours on (b)(6) 2009. The ligature was cut and resuscitation efforts were started immediately in the cell and continued at the local medical treatment facility. All efforts failed to revive him. He was pronounced dead at 2259 hours.

(b)(6) medical records reveal a long history of adjustment disorder, anti-social personality disorder and stressors of confinement. He has a history of suicide ideations gestures and multiple failed suicide attempts. He was on hunger strike since January 2009 and was enteraly fed. The case is under investigation by the Naval Criminal Investigative Service (NCIS).

Authorization for Autopsy: Office of the Armed Forces Medical Examiner, IAW Title 10 US Code 1471

Identification:
(b)(6) is identified by visual recognition and his detainee identifications tags. Fingerprints are obtained by NCIS and a tissue sample is collected for DNA identification, if needed.

CAUSE OF DEATH:
Asphyxia due to ligature strangulation

MANNER OF DEATH:
Suicide

ACLU Detainee DeathII ARMY MEDCOM 1104

NCIS PRELIMINARY INVESTIGATION

According to preliminary NCIS investigation, while the shift guards were performing periodic checks on the detainees at the BHU, the decedent was viewed through the cell window and noted to not be breathing. He was seen on the floor of his cell, on his right side in the fetal position. (b)(6) was reported to have been covered with a blanket with his hands and feet exposed. He was facing the right cell wall with head slightly tilted. The guards entered the cell and secured the decedent's hands and feet prior to placing him on his back. The guards noticed a ligature consisting of an elastic band tightly wrapped at least twice around the neck and twisted on the left side. The ligature was wrapped tightly and had to be cut (at the most twisted part) from the decedent's neck. It was removed in two pieces. No pulse or spontaneous breathing was noted. CPR was immediately started. Passive vomiting occurred during CPR.

At approximately 2120 hours the decedent requested to speak to a nurse and asked for a sleeping aid. He was last known alive approximately 10-15 minutes later when he asked the guard to close his "bean hole cover", a sign that he was ready to go to sleep. He appeared, to the guards, in "good spirit" and did not appear upset. He was discovered unresponsive a few minutes later at approximately 2155 hours.

MEDICAL RECORDS REVIEW

The available mental health records are screened by the prosector and the ovserving civilian medical examiner prior to the autopsy; see "Postmortem Examination".

Screening of the mental health records reveals a psychiatric history of adjustment disorder, antisocial personality disorder and stressors of confinement. The decedent has a history of suicide ideations, suicide gestures and multiple suicide attempts by hanging, neck ligature, self inflicted sharp force injuries and frequent blunt force trauma to the head. On January 2009 he started a hunger strike and has been fed enteraly. He has been on a suicide watch at the BHU, where he is seen daily by the medical staff. He had five suicide attempts in May 2009.

LIGATURE

The ligature is collected as evidence by NCIS at the scene and examined by the prosector and the observing civilian medical examiner prior to the autopsy.

The ligature is almost identical to the elastic band of a white brief, medium size 34-36, issued to the detainees at the detention facility. The ligature consists of two segments, with a combined aggregate length of approximately 23 ½" and width of approximately 1". The smaller of the two segments measures 6 ½" in length. The ligature fibers are

ACLU Detainee DeathII ARMY MEDCOM 1105

elongated and distorted at the junction of the two cut edges c/w the history of cutting the ligature at the twisted part. There are no blood stains noted on the ligature.

POSTMORTEM EXAMINATION

The postmortem examination, (b)(6) of (b)(6) is performed at the US Naval Hospital (USNH), Guantanamo Bay, Cuba on (b)(6) 2009, starting at approximately 1300 hours. Full body radiological studies are obtained at the USNH. Photographs are obtained by (b)(6) OAFME Photographer. Attending the autopsy as medicolegal observers are (b)(6) Medical Examiner (b)(6) (b)(6) and Special Agents (b)(6) from the NCIS.

EXTERNAL EXAMINATION

The body is that of a well-developed, well-nourished Caucasian male clad in khaki shirt and pants without undergarments; see "Clothing and Personal Effects". The feet are held together with white plastic flexi cuffs and the hands are held together with black plastic flexi cuffs. The flexi cuffs were cut open to facilitate the completion of the radiological studies. The hands are covered in brown paper bags, secured by adhesive tape; see "Evidence". A blue colored plastic identification band encircles the right wrist.

The height and weight noted on the identification wrist band are 68" and 120 lb, respectively. The body appears consistent with the reported height and weight. Rigor is present to an equal degree in all extremities. Lividity is present and fixed on the posterior surface of the body, except in areas exposed to pressure. Body temperature is cold due to refrigeration.

The scalp hair is black, long, covers the back of the neck and is matted. Vomit is noted on the top and back of the head. The facial hair consists of black mustache and beard. The forehead reveals dark small raised lesions; see "Evidence of Injuries". The eyes are unremarkable. The irides are brown. The corneae are slightly cloudy. The conjunctivae appear injected with no significant petechiae. The sclerae are white with no petechiae. The external auditory canals, external nares and oral cavity are free of foreign material and abnormal secretions. The nasal skeleton is palpably intact. The tongue is unremarkable. The lips are without evident injury. The frenulae are unremarkable. The teeth are natural and unremarkable. Examination of the neck reveals a broad patterned impression on the anterior neck and dark colored impression on the posterior neck; see "Evidence of Injury".

The chest is unremarkable. No injury of the ribs or sternum is evident externally. The abdomen is unremarkable with no evidence of major surgical scars. The posterior torso is unremarkable with no evidence of trauma. A healing ¾ x ½" ulcer of unknown etiology is

ACLU Detainee DeathII ARMY MEDCOM 1106

noted on the right lower back, immediately below the waist. The external genitalia are those of a normal adult circumcised male.

The extremities are unremarkable with no evidence of recent trauma. Linear broad impressions are noted on the right wrist and ankles, consistent with the history of use of the flexi cuff ties.

Multiple well healed scars are noted on the right anterior neck, scalp, right arm, right shoulder, left anticubital fossa, left thumb, both knees, left shin and the dorsal surface of the left foot; photographed for documentation. No tattoos, other major surgical scars or identifying marks are noted.

EVIDENCE OF INJURY

Neck Trauma:

External examination of the neck reveals a ligature impression around the neck. A broad reddish discoloration is noted on the skin of the anterior neck, overlying the thyroid cartilage measuring 1 1/2" in it maximum width on the midline. The ligature mark has a maximum width of 1 ½" at the anterior midline, is slightly upwardly angled towards the posterior neck. The ligature impression on the right side of the neck is tapered into a triangular shape with its apex below the angle of the mandible and is associated with non-patterned faint contusions, see "Opinion". The ligature impression is incomplete and fades and disappears below the ears. A small superficial abrasion is noted below the right ear; see "Opinion". A thin dark linear discoloration is noted on the posterior neck; see "Opinion".

Dissection and examination of the strap muscles of the neck reveals localized hemorrhage on the right side of the sterno-hyoid muscle, underlying the above noted ligature impression and contusion on the right side of the neck. No other trauma is noted. The hyoid bone and thyroid cartilage are intact.

Other Injuries:

Examination of the forehead reveals a small cluster of dark raised lesions, on the midline, in an area measuring ¾ x ½" with underlying mild subcutaneous hemorrhage and no underlying skull fractures; see "Opinion".

A fracture of the anterior right 5th rib is noted with minimal surrounding hemorrhage; see "Opinion".

ACLU Detainee DeathII ARMY MEDCOM 1107

A well healed scar overlies a malunion fracture of the right humerus is noted, consistent with remote unrelated trauma (firearm injury in 2002 per medical records). There is a superficial healing abrasion on the left shin. No other significant injuries are noted.

Serial incisions on the back and upper and lower extremities reveal no evidence of trauma. The incisions are photographed for documentation.

CLOTHING and PERSONAL EFFECTS

The deceased is clad in khaki shirt and pants, general issue of the detention center. No personal effects are noted on the body. The clothing is photographed and collected by NCIS present during autopsy.

MEDICAL INTERVENTION

Evidence of active medical intervention is noted as follows:

- An endotracheal tube.
- Central venous line
- Multiple intravenous puncture sites on right arm and anticubital fossa.
- External automatic defibrillator pads on the chest.

INTERNAL EXAMINATION

BODY CAVITIES:
Bilateral adhesions are noted in both pleural cavities. No abnormal collections of fluid are present in any of the body cavities. All body organs are present in the normal anatomical position. The subcutaneous fat layer of the abdominal wall is unremarkable. There is no internal evidence of blunt or sharp force injury to the thoraco-abdominal region.

HEAD: (CENTRAL NERVOUS SYSTEM)
See "Evidence of Injury"
The dura mater and falx cerebri are intact. There is no epidural or subdural hemorrhage present. The leptomeninges are thin and delicate. The cerebral hemispheres are symmetrical. The structures at the base of the brain, including cranial nerves and blood vessels, are intact. Coronal sections through the cerebral hemispheres reveal no lesions. Transverse sections through the brain stem and cerebellum are unremarkable. The brain weighs 1300 grams. Serial sectioning of the brain reveals unremarkable parenchyma and no evidence of trauma.

ACLU Detainee DeathII ARMY MEDCOM 1108

NECK:
See "Evidence of Injury".
Examination of the soft tissues of the neck including strap muscles, thyroid gland and large vessels are unremarkable and without traumatic abnormalities. The hyoid bone and thyroid cartilage are intact.

CARDIOVASCULAR SYSTEM:
The pericardial surfaces are smooth, glistening and unremarkable; the pericardial sac is free of significant fluid and adhesions. The coronary arteries arise normally, follow the usual distribution and are widely patent with no atherosclerotic changes. The epicardium is smooth and unremarkable. The myocardium is dark red-brown, firm and grossly

unremarkable. The valves exhibit the usual size, texture and position relationship and are unremarkable. The aorta and its major branches arise normally, follow the usual course and are widely patent, free of significant atherosclerosis and other abnormality. The venae cavae and their major tributaries return to the heart in the usual distribution and are free of thrombi. The heart weighs 280 grams.

RESPIRATORY SYSTEM:
The upper airway is clear of debris and foreign material; the mucosal surfaces are smooth, yellow-tan and unremarkable. The pleural surfaces reveal presence of bilateral adhesions, more pronounced on the posterior and lateral surfaces. The pulmonary parenchyma is red-purple and exudes a moderate amount of bloody fluid with no focal lesions identified. The pulmonary arteries are normally developed, patent and without thrombus or embolus. The right and left lung weigh 650 grams and 600 grams, respectively.

LIVER & BILIARY SYSTEM:
The hepatic capsule is smooth, glistening and intact, covering dark red-brown, moderately congested parenchyma with no focal lesions noted. The gallbladder contains green-brown, mucoid bile; the mucosa is velvety and unremarkable. The extrahepatic biliary tree is patent, without evidence of calculi. The liver weighs 1300 grams.

ALIMENTARY TRACT:
The esophagus is lined by gray-white, smooth mucosa. The gastric mucosa is arranged in the usual rugal folds and is unremarkable. The stomach is distended with partially digested food with no evidence of mucosal or vascular injury. The small and large bowels are unremarkable. The pancreas has a normal pink-tan lobulated appearance and the ducts are patent. The appendix is present and unremarkable.

GENITOURINARY SYSTEM:
The renal capsules are smooth and thin, semi-transparent and strip with ease from the underlying smooth, red-brown cortical surfaces. The cortices are sharply delineated from the medullary pyramids, which are red-purple to tan and unremarkable. The calyces, pelves and ureters are unremarkable. The urinary bladder is unremarkable and contains clear yellow urine. The right and left kidneys weigh 100 grams each.

ACLU Detainee DeathII ARMY MEDCOM 1109

The external genitalia are those of a circumcised adult male with bilaterally descended unremarkable testes.

RETICULOENDOTHELIAL SYSTEM:
The spleen has a smooth, intact capsule covering red-purple, moderately firm parenchyma; the lymphoid follicles are unremarkable. The regional lymph nodes appear normal. The spleen weighs 120 grams.

ENDOCRINE SYSTEM:
The pituitary, thyroid and adrenal glands are unremarkable.

MUSCULOSKELETAL SYSTEM:
See "Evidence of Injury".
Muscle development is normal. No other bone or joint abnormalities are noted.

EVIDENCE

The clothing, plastic flexi cuffs and the brown bags around the hands are collected and submitted to the NCIS agents attending the autopsy. The ligature is examined and retained by NCIS.
(Note: An intact white brief similar to the one issued to the decedent is provided by NCIS for examination and comparison to the ligature. The ligature is identical to the elastic band of the examined brief)

RADIOLOGICAL STUDIES

Radiographs reveal no recent skeletal fractures or abnormalities. A remote healed (malunion) fractured right humerus is noted.

MICROSCOPIC EXAMINATION

Representative sections of the major organs are retained without preparation of histological slides.

TOXICOLOGY

Carbon Monoxide:
- Carboxyhemoglbin saturation in blood is less than 1% (expected normal limits)

Cyanide:
- Not detected

Volatiles (Blood and Vitreous fluid):
- No ethanol is detected.

ACLU Detainee DeathII ARMY MEDCOM 1110

Screened medication and drugs of abuse:

- Screened in urine and confirmed in blood:
  Positive Acetaminophen 5 mg/L (0.5 mg %)
  Positive Benzodiazepine: Lorazepam 0.025 mg/L (0.003 mg %)
  Positive Benzodiazepine: 7-Aminoclonazepam 0.03 mg/L (0.003 mg %)
  Positive Sympathomimetic amine: Pseudoephedrine 0.3 mg/L (0.03 mg%)

ADDITIONAL PROCEDURES

1. Documentary photographs are taken by OAFME photographer, (b)(6) (b)(6)
2. Full body radiographs are obtained by Department of Radiology, Naval Hospital Guantanamo Bay, Cuba.
3. Specimens retained for toxicological and/or DNA identification are: Blood (heart), vitreous fluid, bile, urine, stomach contents, and tissue samples from liver, lung, kidney, spleen, brain, psoas and heart muscle and adipose tissue.
4. Representative sections of organs are retained in formalin without preparation of histological slides.
5. Clothing and other evidence are photographed for documentation and submitted to NCIS agents attending the autopsy.

FINAL AUTOPSY DIAGNOSIS

I. Asphyxia by ligature strangulation:

A. Ligature mark partially encircling the neck with possible twist on the right side.
B. No evidence of other neck trauma or fractures.
C. No evidence of significant traumatic injuries.

II. Evidence:

- Collected evidence submitted to NCIS.

III. Toxicology:

A. Volatiles (Blood and Vitreous fluid): No ethanol is found.
B. Screened drugs of abuse and medications (Blood):
Positive for: Acetaminophen, Benzodiazepine and its metabolites and Pseudoephedrine.

ACLU Detainee DeathII ARMY MEDCOM 1111

OPINION

(b)(6) a civilian detainee of unknown age, died from asphyxia due to ligature strangulation by tightly wrapping the elastic band of his underwear multiple times around the neck and apparently securing it with a twist on the right side of the neck and a head tilt. Autopsy reveals no evidence of other significant trauma or evidence of maltreatment.

The raised lesions noted on the forehead are consistent with reported history of witnessed repeated self-inflected hitting/banging of the head on the detention facility walls. The contusions noted on the right side of the neck may be associated with the ligature twist or by the guards' initial attempts to manually remove the ligature. The non-displaced right 5th rib fracture noted during examination is consistent with CPR and resuscitation efforts.

Toxicological studies positive for Acetaminophen, Benzodiazepine and its metabolite and Pseudoephedrine. The positive medications are within their therapeutic level and are non-contributory to the cause of death.

Review of the decedent's medical records reveals multiple stressors, multiple suicide ideations and gestures and multiple suicide attempts by multiple modalities as early as 2003. The decedent was on hunger strike since January 2009 and had five suicide attempts in May 2009.

Based upon the available information, the manner of death is "Suicide" (b)(6)

(b)(6)

(b)(6) Medical Examiner

ACLU Detainee DeathII ARMY MEDCOM 1112

CERTIFICATE OF DEATH *(OVERSEAS)*
Acte de décès (D'Outre-Mer)

NAME OF DECEASED *(Last, First, Middle)* Nom du décédé (Nom et prénoms)	GRADE Grade	BRANCH OF SERVICE Arme	SOCIAL SECURITY NUMBER Numéro de l'Assurance Social
Al Hanashi, Muhammad Ahmad, A. S.		Civilian	(b)(6)

ORGANIZATION Organisation	NATION *(e.g, United States)* Pays	DATE OF BIRTH Date de naissance	SEX Sexe
	Yemen		[X] MALE [ ] FEMALE

RACE Race		MARITAL STATUS État Civil			RELIGION Culte		
[X]	CAUCASOID Caucasique	[ ]	SINGLE Célibataire	[ ] DIVORCED Divorcé	[ ]	PROTESTANT Protestant	[X] OTHER (Specify) Autre (Spécifier): Other
[ ]	NEGROID Negroide	[ ]	MARRIED Marié	[ ] SEPARATED Séparé	[ ]	CATHOLIC Catholique	
[ ]	OTHER (Specify) Autre (Spécifier)	[ ]	WIDOWED Veuf		[ ]	JEWISH Juif	

NAME OF NEXT OF KIN Nom du plus proche parent	RELATIONSHIP TO DECEASED Parenté du décédé avec le sus
STREET ADDRESS Domicilé à (Rue)	CITY OR TOWN OR STATE *(Include ZIP Code)* Ville (Code postal compris)

MEDICAL STATEMENT Déclaration médicale

CAUSE OF DEATH (Enter only one cause per line) Cause du décès (N'indiquer qu'une cause par ligne)		INTERVAL BETWEEN ONSET AND DEATH Intervalle entre l'attaque et le décès
DISEASE OR CONDITON DIRECTLY LEADING TO DEATH [1] Maladie ou condition directement responsable de la mort [1]	Asphyxia due to Ligature Strangulation	
ANTECEDENT CAUSES Symptômes précurseurs de la mort — MORBID CONDITION, IF ANY, LEADING TO PRIMARY CAUSE Condition morbide, s'il y a lieu, menant à la cause primaire		
ANTECEDENT CAUSES Symptômes précurseurs de la mort — UNDERLYING CAUSE, IF ANY, GIVING RISE TO PRIMARY CAUSE Condition morbide, s'il y a lieu, menant à la cause primaire		
OTHER SIGNIFICANT CONDITIONS [2] Autres conditions significatives [2]		

MODE OF DEATH Condition de décès	AUTOPSY PERFORMED Autopsie effectuée [X] YES Oui [ ] NO Non	CIRCUMSTANCES SURROUNDING DEATH DUE TO EXTERNAL CAUSES Circonstances de la mort suscitées par des causes extérieures
[ ] NATURAL Mort naturelle	MAJOR FINDINGS OF AUTOPSY Conclusions principales de l'autopsie	
[ ] ACCIDENT Mort accidentelle		
[X] SUICIDE Suicide	NAME OF PATHOLOGIST Nom du pathologiste (b)(6)	
[ ] HOMICIDE Homicide	SIGNATURE (b)(6) DATE Date 3 June 2009	AVIATION ACCIDENT Accident à Avion [ ] YES Oui [X] NO Non

DATE OF DEATH *(day, month, year)* Date de décès (le jour, le mois, l'année)	PLACE OF DEATH Lieu de décès
(b)(6) 2009 (b)(6)	Joint Task Force Guantanamo Bay Cuba

I HAVE VIEWED THE REMAINS OF THE DECEASED AND DEATH OCCURRED AT THE TIME INDICATED AND FROM THE CAUSES AS STATED ABOVE
J'ai examiné les restes mortels du dé funtet je conclus que le décès est survenu à l'heure indiquée et à, la suite des causes énumérées ci-dessus.

NAME OF MEDICAL OFFICER Nom du médicin militaire ou du médicin sanitaire	TITLE OR DEGREE Titre ou diplômé
(b)(6)	Medical Examiner

GRADE Grade	INSTALLATION OR ADDRESS Installation ou adresse
(b)(6)	Dover AFB, Dover DE
DATE Date 6/16/2009	SIGNATURE (b)(6)

[1] State disease, injury or complication which caused death, but not mo
[2] State conditions contributing to the death, but not related to the disease or condition causing death
[1] Préciser la nature de la maladie, de la blessure ou de la complication qui a contribué à la mort, mais non la manière de mourir, telle qu'un arrêt du coeur, etc
[2] Préciser la condition qui a contribué à la mort, mais n'ayant aucun rapport avec la maladie ou à la condition qui a provoqué la mort

DD FORM 1 APR 77 2064 REPLACES DA FORM 3565, 1 JAN 72 AND DA FORM 3565-R(PAS), 26 SEP 76, WHICH ARE OBSOLETE.

MEDCOM 1113

ACLU Detainee DeathII ARMY MEDCOM 1113

ARMED FORCES INSTITUTE OF PATHOLOGY
Office of the Armed Forces Medical Examiner
1413 Research Blvd., Bldg. 102
Rockville, MD 20850
301-319-0000

AUTOPSY EXAMINATION REPORT

Name: (BTB) HAMID, Adnan Naif
ISN: (b)(6)
TMEP (b)(6)
Date of Birth: (BTB) (b)(6) 1966
Date of Death: (b)(6) 2009

Autopsy No.: (b)(6)
AFIP No.: (b)(6)
Rank: Civilian Detainee
Place of Death: Iraq

Date/Time of Autopsy: 19 MAY 2009 @ 1130
Place of Autopsy: Port Mortuary, Dover AFB, DE

Date of Report: 07 JUL 2009

Circumstances of Death: This 43-year-old Iraqi Civilian detainee, who had a medical history significant for anemia and thrombocytopenia, began to experience acute distress which resulted in death despite aggressive resuscitation efforts.

Authorization for Autopsy: Armed Forces Medical Examiner, per U.S. Code 10, Section 1471.

Identification: Positive identification is established by comparison of postmortem fingerprint examination and antemortem fingerprint records. A postmortem DNA sample is obtained .

CAUSE OF DEATH: **PULMONARY EMBOLISM**

MANNER OF DEATH: **NATURAL**

ACLU Detainee DeathII ARMY MEDCOM 1114

EXTERNAL EXAMINATION

The body is that of a well-developed, well-nourished Caucasoid male received unclad. The body weighs 167-pounds, is 64-inches in length and appears compatible with the reported age of 33-years. The body is cold. Rigor is passing and present to an equal degree in all extremities. Violaceous lividity is present and fixed on the posterior surface of the body, except in areas exposed to pressure. The body is unembalmed.

The head is normocephalic, and the scalp hair is gray-black and up to 1 ½-inches in length. Facial hair consists of a gray-black moustache and beard stubble. The irides are brown, the pupils are round and equal in size, the corneae are cloudy, the conjunctivae are unremarkable, and the sclerae are white. The external auditory canals, external nares and oral cavity are free of foreign material and abnormal secretions. The earlobes are not pierced. The nasal skeleton and maxilla are palpably intact. The lips and oral mucous membranes are without evident injury. The teeth are natural and in good condition. Examination of the neck reveals no evidence of injury; the trachea is palpably in the midline of the neck. Evidence of medical therapy is present, see below.

The chest is symmetric with normally formed male breasts that are free of masses. No evidence of injury of the ribs or the sternum is evident externally. Evidence of medical therapy is present, see below. The abdomen is flat without recent trauma. Healed surgical scars are not noted on the torso. The external genitalia are those of a normal adult circumcised male, and the pubic hair is in an appropriate distribution. The posterior torso and anus are without note.

The extremities are symmetric and normally formed without evidence of significant recent trauma. A ½ x ½-inch abrasion is on the right knee region. The fingernails are trimmed and intact. The toenails are unremarkable. Tattoos are not noted on the extremities.

CLOTHING AND PERSONAL EFFECTS

- A green personal effects bag accompanies the body which contains an identification band which matches the reported name and ISN of the decedent.
- No clothing or other personal effects accompanies the remains.

MEDICAL INTERVENTION

- A therapeutic needle stick-mark on the right side of the neck is covered by medical gauze and tape
- Defibrillator burn/abrasion on the central chest
- Therapeutic needle stick-marks in both antecubital fossae

RADIOGRAPHS

A complete set of postmortem radiographs and CT images are obtained and demonstrates the following:

- No recent fractures
- No metallic foreign bodies

ACLU Detainee DeathII ARMY MEDCOM 1115

EVIDENCE OF INJURY

There is no evidence of significant recent injury.

INTERNAL EXAMINATION

BODY CAVITIES:
The body is opened by the usual thoraco-abdominal incision and the chest plate is removed. The sternum and vertebral bodies are visibly and palpably intact. No adhesions or abnormal collections of fluid are present in any of the body cavities. All body organs are present in normal anatomical position. The anterior 2nd – 5th right ribs and the left 2nd – 4th left ribs are fractured with associated soft tissue hemorrhage.

The subcutaneous fat layer of the abdominal wall is ¾-inches thick.

HEAD AND CENTRAL NERVOUS SYSTEM:
The scalp is reflected. The galeal and subgaleal soft tissues of the scalp are free of injury. There are no skull fractures. The calvarium of the skull is removed. The dura mater and falx cerebri are intact. There is no epidural, subdural or subarachnoid hemorrhage present. The leptomeninges are thin and delicate. The cerebral hemispheres are symmetrical with an unremarkable pattern of gyri and sulci. The blood vessels at the base of the brain are intact and symmetrical without significant atherosclerosis. The cranial nerves are likewise symmetrical and intact.

The brain weighs 1,300-grams. Coronal sections through the cerebral hemispheres reveal no lesions. The ventricles of the brain are of normal size and contain clear cerebrospinal fluid. Transverse sections through the brain stem and cerebellum are unremarkable; as is the upper spinal cord. The atlanto-occipital joint is stable.

NECK:
The anterior strap muscles of the neck are homogenous and red-brown, without hemorrhage by layer-wise dissection. The thyroid cartilage and hyoid bone are intact. The larynx is lined by intact white mucosa. The tongue is free of bite marks, hemorrhage, or other injuries.

CARDIOVASCULAR SYSTEM:
The 420-gram heart is contained in an intact pericardial sac. The epicardial surface is smooth, with minimal fat investment. The coronary arteries arise normally and are present in a normal distribution, with a right-dominant pattern. Cross sections of the major coronary arteries demonstrate the following: the left anterior descending coronary artery has multifocal luminal narrowing greater than 75% by calcified atherosclerotic plaque. The mid-portion of the left circumflex coronary artery has 50% focal luminal narrowing, and the right coronary artery has multifocal luminal narrowing greater than 75% narrowing by atherosclerotic plaque.

The myocardium is homogenous, red-brown, and firm without focal softening, discoloration or fibrosis. The valve leaflets are thin and mobile. The walls of the left ventricle, inter-ventricular septum, and right ventricle are 1.8, 1.9, and 0.6-centimeters thick, respectively. The chambers of the

ACLU Detainee DeathII ARMY MEDCOM 1116

heart are not dilated, and the endocardium is smooth and glistening.

The aorta has moderate calcified atherosclerosis, predominantly in the abdominal region, and gives rise to three intact and patent arch vessels. The renal and mesenteric vessels are unremarkable.

RESPIRATORY SYSTEM:
The upper airway is clear of debris and foreign material: the mucosal surfaces are smooth, yellow-tan and unremarkable. The parietal pleural surfaces are smooth, glistening and unremarkable bilaterally.

The right lung weighs 960-grams; the left 580-grams. The pulmonary parenchyma is diffusely congested and edematous, exuding slight to moderate amounts of blood and frothy fluid; no focal lesions are noted. The visceral pleural surfaces are smooth and glistening with anthracosis bilaterally.

The pulmonary arteries are normally developed and patent. The lumens of the right and left pulmonary arteries are occluded by multiple fragments of thrombi. The emboli have striations, tributary casts and valve markings and are of a caliber consistent with a venous origin. Emboli are found extending into the peripheral branches of the pulmonary arteries in the lung parenchyma.

HEPATOBILIARY SYSTEM:
The 1,640-gram liver has an intact smooth capsule covering moderately congested tan-brown parenchyma with no focal lesions noted.

The gallbladder contains 10-milliliters of green-brown, mucoid bile; the mucosa is velvety and unremarkable. The extrahepatic biliary tree is patent, without evidence of calculi.

GASTROINTESTINAL SYSTEM:
The esophagus is lined by gray-white, smooth mucosa. The gastric mucosa is arranged in the usual rugal folds and the lumen contains 200-milliliters of brown fluid with food.

The small and large bowels are unremarkable. The pancreas has a normal pink-tan lobulated appearance. The appendix is present.

GENITOURINARY SYSTEM:
The right kidney weighs 130-grams; the left 140-grams. The renal capsules are smooth and thin, semi-transparent and strip with ease from the underlying smooth, red-brown cortical surfaces.

The cortices are sharply delineated from the medullary pyramids, which are red-purple to tan and unremarkable. The cortex of the left kidney has a 0.8 x 0.5-centimeter wedge-shaped region of hemorrhage with central calcification. The calyces, pelves and ureters are unremarkable.

White bladder mucosa overlies an intact bladder wall. The bladder contains approximately 5-milliliters of cloudy urine. The testes, prostate gland and seminal vesicles are without note.

ACLU Detainee DeathII ARMY MEDCOM 1117

LYMPHORETICULAR SYSTEM:
The thymus is small, fatty and otherwise unremarkable. The 320-gram spleen has a smooth, intact capsule covering red-purple, moderately firm parenchyma; the lymphoid follicles are unremarkable.

Lymph nodes in the hilar, periaortic and iliac regions are not enlarged. The hilar lymph nodes demonstrate mild anthracosis, but are otherwise unremarkable.

ENDOCRINE SYSTEM:
The pituitary gland is examined *in situ* and is grossly unremarkable. The thyroid gland is symmetric and red-brown, without cystic or nodular change. The parathyroid glands are not identified. The right and left adrenal glands are symmetric, with bright yellow cortices and red-brown medullae; no masses or areas of hemorrhage are identified.

MUSCULOSKELETAL SYSTEM:
No abnormalities of muscle or bone are identified.

Superficial posterior incisions fail to demonstrate any injuries of the posterior torso; extended dissection around the ankle and wrist regions fail to demonstrate any evidence of binding or physical restraint.

Dissections of the deep veins of both posterior legs fail to demonstrate thrombosis.

MICROSCOPIC EXAMINATION

Selected portions of organs are retained in formalin, without preparation of histology slides.

TOXICOLOGY

VOLATILES: The blood and vitreous fluid are examined for the presence of volatile compounds including ethanol at a cutoff of 20-milligrams per deciliter. No ethanol is detected.

DRUGS: The blood is screened for medications and drugs of abuse including acetaminophen, amphetamine, antidepressants, antihistamines, barbiturates, benzodiazepines, cannabinoids, chloroquine, mefloquine, cocaine, dextromethorphan, lidocaine, narcotic analgesics, opiates, phencyclidine, phenothiazines, salicylates, sympathomimetic amines and verapamil by gas chromatography, color test or immunoassay. The following drugs are detected:

> Positive Lidocaine: Lidocaine is detected in the blood by gas chromatography and confirmed by gas chromatography/mass spectrometry.

CARBON MONOXIDE: The carboxyhemoglobin saturation in the blood is less than 1% as determined by spectrophotometry with a limit of quantitation of 1%. Saturations above 10% are considered elevated and are confirmed by gas chromatography.

CYANIDE: The blood is tested for cyanide with a limit of quantitation of 0.25-milligrams per liter. No cyanide is detected.

ACLU Detainee DeathII ARMY MEDCOM 1118

ADDITIONAL PROCEDURES

1. Documentary photographs are taken by (b)(6) AFMES staff photographer.
2. Autopsy assistance is provided by (b)(6) AFMES autopsy assistant.
3. The Criminal Investigative Division (CID) representative attending the autopsy is Special Agent (b)(6)
4. Specimens retained for toxicology testing and/or DNA identification are: vitreous fluid, blood, urine, bile, gastric contents, spleen, liver, lung, kidney, brain, myocardium, adipose tissue and skeletal muscle.
5. The unembalmed body and dissected organs are returned to the point of origin by Mortuary Operations personnel.

FINAL AUTOPSY DIAGNOSES

I. Pulmonary Embolism
- A. Both pulmonary arteries are occluded by multiple fragments of thrombotic emboli which extend into the deep parenchymal branches
- B. The emboli have striations, tributary casts and valve markings, consistent with a deep venous thrombotic origin
- C. Associated pulmonary congestion, bilateral
- D. Deep venous thromboses are not identified within the limitations of this examination (the origin of the thrombotic emboli is not identified)

II. Hypertensive Arteriosclerotic Cardiovascular Disease
- A. Mild cardiomegaly (heart weight is 420-grams; the expected maximal heart weight is 334-grams for body weight) with concentric left ventricular hypertrophy
- B. Severe arteriosclerotic disease all three major coronary arteries
- C. Moderate calcified atherosclerosis in the abdominal aorta
- D. Probable embolic infarct of the left kidney

III. Splenomegaly (spleen weight is 320-grams; the expected maximal spleen weight is 134-grams for body weight)

IV. No evidence of abuse or physical restraint is identified.

V. Evidence of Medical Therapy
- A. Therapeutic needle stick-marks on the right side of the neck and both antecubital fossae
- B. Defibrillator burn/abrasion on the central chest
- C. Fractures of the anterior right and left ribs (attempted resuscitation related)

VI. Post-Mortem Changes
- A. Rigor is passing and equal in all extremities
- B. Lividity is posterior and fixed except in areas exposed to pressure
- C. The body temperature is cold

ACLU Detainee DeathII ARMY MEDCOM 1119

VII. Identifying Body Marks: None noted

VIII. Toxicology

A. No ethanol is detected in the blood and vitreous fluid.
B. No screened drugs of abuse are detected in the blood.
C. Lidocaine (a medication associated with resuscitation efforts) is present in the blood
D. The carboxyhemoglobin saturation in the blood is less than 1%.
E. No cyanide is detected in the blood.

OPINION

This 43-year-old Iraqi civilian detainee (b)(6) died of a pulmonary embolism. The source of the embolic thrombi were not identified, but based on the appearance of the emboli, they most likely originated from the deep veins of the leg (s). Failure to identify this site as the origin of the emboli by dissection of the legs does not preclude this conclusion. Severe hypertensive arteriosclerotic cardiovascular disease was also present, as demonstrated by increased heart weight, increased thickness of the left ventricle of the heart, atherosclerotic disease of the aorta and severe narrowing of all three major coronary arteries of the heart. The embolic infarction of the left kidney likely originated from the atherosclerotic disease present in the aorta. An enlarged spleen was also identified at autopsy. No evidence of physical abuse or physical restraint was identified at autopsy. Toxicological testing was negative for ethanol, screened drugs of abuse, elevated carboxyhemoglobin or cyanide in the blood. A medication associated with resuscitation (Lidocaine) was detected in the blood. The manner of death is natural.

(b)(6)

(b)(6) Medical Examiner

ACLU Detainee DeathII ARMY MEDCOM 1120

CERTIFICATE OF DEATH *(OVERSEAS)*
Acte dé décès (D'Outre-Mer)

NAME OF DECEASED *(Last, First, Middle)* Nom du décédé (Nom et prénoms)	GRADE Grade	BRANCH OF SERVICE Arme	SOCIAL SECURITY NUMBER Numéro de l'Assurance Social
BTB Hamid, Adnan, N		Civilian	(b)(6)
ORGANIZATION Organisation	**NATION** *(e.g. United States)* Pays: Iraq	**DATE OF BIRTH** Date de naissance	**SEX** Sexe: [X] MALE [ ] FEMALE

RACE Race		MARITAL STATUS État Civil			RELIGION Culte		
[X]	CAUCASOID Caucasique	[ ]	SINGLE Célibataire	[ ] DIVORCED Divorcé	[ ] PROTESTANT Protestant	[X]	OTHER (Specify) Autre (Spécifier): UNK
[ ]	NEGROID Negroide	[ ]	MARRIED Marié	[ ] SEPARATED Séparé	[ ] CATHOLIC Catholique		
[ ]	OTHER (Specify) Autre (Spécifier)	[ ]	WIDOWED Veuf		[ ] JEWISH Juif		

NAME OF NEXT OF KIN Nom du plus proche parent	RELATIONSHIP TO DECEASED Parenté du décédé avec le sus
STREET ADDRESS Domicilé à (Rue)	**CITY OR TOWN OR STATE** *(Include ZIP Code)* Ville (Code postal compris)

MEDICAL STATEMENT Déclaration médicale

	CAUSE OF DEATH (Enter only one cause per line) Cause du décès (N'indiquer qu'une cause par ligne)	INTERVAL BETWEEN ONSET AND DEATH Intervalle entre l'attaque et le décès
DISEASE OR CONDITON DIRECTLY LEADING TO DEATH[1] Maladie ou condition directement responsable de la mort	Pulmonary Embolism	Unknown
ANTECEDENT CAUSES Symptômes précurseurs de la mort. — MORBID CONDITION, IF ANY, LEADING TO PRIMARY CAUSE Condition morbide, s'il y a lieu, menant à la cause primaire		
UNDERLYING CAUSE, IF ANY, GIVING RISE TO PRIMARY CAUSE Condition morbide, s'il y a lieu, menant à la cause primaire		
OTHER SIGNIFICANT CONDITIONS[2] Autres conditions significatives[2]		

MODE OF DEATH Condition de décès	AUTOPSY PERFORMED Autopsie effectuée	CIRCUMSTANCES SURROUNDING DEATH DUE TO EXTERNAL CAUSES Circonstances de la mort suscitées par des causes extérieures
[X] NATURAL Mort naturelle	[X] YES Oui [ ] NO Non	
[ ] ACCIDENT Mort accidentelle	MAJOR FINDINGS OF AUTOPSY Conclusions principales de l'autopsie	
[ ] SUICIDE Suicide	NAME OF PATHOLOGIST Nom du pathologiste: (b)(6)	
[ ] HOMICIDE Homicide	SIGN (b)(6) — DATE Date: 19 May 2009	AVIATION ACCIDENT Accident à Avion: [ ] YES Oui [X] NO Non

DATE OF DEATH (day, month, ye... Date de décès (le jour, le mois, l'a... cès: (b)(6) 2009 — Camp Taji Iraq

I HAVE VIEWED THE REMAINS OF THE DECEASED AND DEATH OCCURRED AT THE TIME INDICATED AND FROM THE CAUSES AS STATED ABOVE.
J'ai examiné les restes mortels du dé funtet je conclus que le décès est survenu à l'heure indiquée et à, la suite des causes énumérées ci-dessus.

NAME OF MEDICAL OFFICER Nom du médicin militaire ou du médicin sanitaire	TITLE OR DEGREE Titre ou diplômé
(b)(6)	Medical Examiner

GRADE Grade	INSTALLATION OR ADDRESS Installation ou adresse
(b)(6)	Dover AFB, Dover DE
DATE Date: 6/30/2009	SIGNATUR (b)(6)

[1] State disease, injury or complication which caused death, but not mode...
[2] State conditions contributing to the death, but not related to the disease...
[1] Préciser la nature de la maladie, de la blessure ou de la complication qui a contribué à la mort, mais non la manière de mourir, telle qu'un arrêt du coeur, etc
[2] Préciser la condition qui a contribué à la mort, mais n'ayant aucun rapport avec la maladie ou à la condition qui a provoqué la mort

DD FORM 1 APR 77 2064 — REPLACES DA FORM 3565, 1 JAN 72 AND DA FORM 3565-R(PAS), 26 SEP 75, WHICH ARE OBSOLETE.

MEDCOM 1121

ACLU Detainee DeathII ARMY MEDCOM 1121

ARMED FORCES INSTITUTE OF PATHOLOGY
Office of the Armed Forces Medical Examiner
1413 Research Blvd., Bldg. 102
Rockville, MD 20850
301-319-0000

AUTOPSY EXAMINATION REPORT

Name: **BTB** Ibrahim, Ahmad Awwad
ISN: (b)(6)
Date of Birth: **BTB** (b)(6) 1987
Date of Death: (b)(6) 2009
Date/Time of Autopsy: 22 Jan 2009 @ 1000
Date of Report: 07 APR 2009

Autopsy No.: (b)(6)
AFIP No.: (b)(6)
Rank: Civilian Detainee
Place of Death: Iraq
Place of Autopsy: Port Mortuary, Dover AFB, DE

Circumstances of Death: This 21-year-old Iraqi Civilian was a detainee at Camp Bucca, Iraq when he reportedly awoke with shortness of breath and clutching his chest. He lost consciousness and was transported to the guard by other detainees. Medical personnel were dispatched and brought him to the medical facility where all resuscitative efforts were unsuccessful.

Authorization for Autopsy: Armed Forces Medical Examiner, per U.S. Code 10, Section 1471

Identification: Presumptive identification is established by mortuary identification tags. Fingerprints and a DNA sample are taken for comparison to an exemplar if one becomes available.

CAUSE OF DEATH: **Lymphocytic Myocarditis**

MANNER OF DEATH: **Natural**

ACLU Detainee DeathII ARMY MEDCOM 1122

EXTERNAL EXAMINATION

The body is that of a well-developed, well-nourished unclad male. The body weighs 177 pounds, is 73 inches in length and appears compatible with the reported age of 21 years. The body is cold. Rigor is absent in all extremities. Lividity is present and fixed on the posterior surface of the body, except in areas exposed to pressure. There is slight marbling of the torso and both lower extremities.

The head is normocephalic, and the scalp hair is short black. Facial hair consists of black beard and moustache stubble. The irides are brown. The corneae are cloudy. The conjunctivae are congested. The sclerae are white. The external auditory canals, external nares and oral cavity are free of foreign material and abnormal secretions. The nasal skeleton and maxilla are palpably intact. There is a 3/8 x 1/8 inch dried abrasion on the left side of the forehead. On the left temple is a 3/4 x 1/2 inch abrasion. On the bridge of the nose is a 1/4 x 1/16 inch abrasion. The lips are without evident injury. The teeth are natural and in good condition. Examination of the neck reveals no evidence of injury; the trachea is palpably in the midline of the neck.

The chest is symmetric with normally formed male breasts that are free of masses. There is a 4 x 3-inch patterned burn / abrasion on the right side of the chest. On the lateral left side of the chest is a 3-1/2 x 3-1/2 patterned burn / abrasion. The abdomen is flat without recent trauma. Healed surgical scars are not noted on the torso. The external genitalia are those of a circumcised adult male, and the pubic hair is in an appropriate distribution. There is mild folliculitis on the posterior torso and the anus is without note.

The extremities are symmetric and normally formed without evidence of significant recent trauma. There is a 2 x 1 inch contusion on the dorsal surface of the left hand. There are three abrasions each measuring 1/8 x 1/8-inch on the dorsal surface of the left hand. The fingernails are trimmed and intact. The toenails are unremarkable. A tattoo (b)(6)
(b)(6)

CLOTHING AND PERSONAL EFFECTS

- Personal effects (contained in a green personal effects bag attached to the left wrist) are removed by Port Mortuary personnel prior to autopsy
- Accompanying the body are yellow boxer shorts (cut), yellow pants (cut), and yellow sweat pants (cut)

MEDICAL INTERVENTION

- EKG patch on the left lower quadrant of the abdomen
- Multiple needle sticks on the chest, bilateral antecubital areas, and right inguinal area
- Interosseous catheter is noted in the anterior right leg
- Burn abrasions on the chest from the defibrillator pads

ACLU Detainee DeathII ARMY MEDCOM 1123

RADIOGRAPHS

A complete set of postmortem radiographs and CT images are obtained and demonstrates the following:

- Multiple bilateral anterior rib fractures (CPR related)
- No skull, vertebral, or long bone fractures
- No metallic foreign bodies are noted

EVIDENCE OF INJURY

There is no evidence of recent significant injury.

INTERNAL EXAMINATION

BODY CAVITIES:
The body is opened by the usual thoraco-abdominal incision and the chest plate is removed. The ribs, sternum, and vertebral bodies are visibly and palpably intact. There are bilateral pleural adhesions with areas of loculated clear fluid in the pleural space. There are adhesions between the diaphragm and the right lobe of the liver. There are no abnormal collections of fluid in the pericardial or peritoneal cavities. All body organs are present in normal anatomical position.

HEAD AND CENTRAL NERVOUS SYSTEM:
The scalp is reflected. The galeal and subgaleal soft tissues of the scalp are free of injury. There are no skull fractures. The calvarium of the skull is removed. The dura mater and falx cerebri are intact. There is no epidural, subdural or subarachnoid hemorrhage present. The leptomeninges are thin and delicate. The cerebral hemispheres are symmetrical. The blood vessels at the base of the brain are intact and symmetrical without significant atherosclerosis. The cranial nerves are likewise symmetrical and intact.

The brain weighs 1,436-grams and is fixed prior to further examination and submission for expert consultation. See Addendum A for complete details.

NECK:
The anterior strap muscles of the neck are homogenous and red-brown, without hemorrhage. The thyroid cartilage and hyoid bone are intact. The larynx is lined by intact white mucosa. The tongue is free of bite marks, hemorrhage, or other injuries.

CARDIOVASCULAR SYSTEM:
The 460-gram heart is contained in an intact pericardial sac. The epicardial surface is smooth, with minimal fat investment. The coronary arteries arise normally and are present in a normal distribution, with a right-dominant pattern. Cross sections of the major coronary arteries demonstrate no luminal narrowing. The heart is fixed prior to further examination and submission for expert consultation. See Addendum B for complete details.

ACLU Detainee DeathII ARMY MEDCOM 1124

The aorta is without atherosclerosis and gives rise to three intact and patent arch vessels. The renal and mesenteric vessels are unremarkable.

RESPIRATORY SYSTEM:
The upper airway is clear of debris and foreign material; the mucosal surfaces are smooth, yellow-tan and unremarkable. The parietal pleural surfaces have extensive adhesions bilaterally.

The right lung weighs 1,720-grams; the left 1,040-grams. The pulmonary parenchyma is diffusely congested and edematous, exuding copious amounts of blood and frothy fluid; no focal lesions are noted. The visceral pleural surfaces have extensive adhesions bilaterally.

The pulmonary arteries are normally developed, patent and without thrombus or embolus.

HEPATOBILIARY SYSTEM:
The 1,760-gram liver has an intact smooth capsule covering moderately congested tan-brown parenchyma with no focal lesions noted. There are adhesions over the right lobe of the liver extending to the diaphragm.

The gallbladder contains 1-milliliter of green-brown, mucoid bile; the mucosa is velvety and unremarkable. The extrahepatic biliary tree is patent, without evidence of calculi.

GASTROINTESTINAL SYSTEM:
The esophagus is lined by gray-white, smooth mucosa. The gastric mucosa is arranged in the usual rugal folds and the lumen contains 400-milliliters of brown granular fluid.

The small and large bowels are unremarkable. The pancreas has a normal pink-tan lobulated appearance. The appendix is present.

GENITOURINARY SYSTEM:
The right kidney weighs 160-grams; the left 140-grams. The renal capsules are smooth and thin, semi-transparent and strip with ease from the underlying smooth, red-brown cortical surfaces.

The cortices are sharply delineated from the medullary pyramids, which are red-purple to tan and unremarkable. The calyces, pelves and ureters are unremarkable.

White bladder mucosa overlies an intact bladder wall. The bladder contains approximately 5-milliliters of cloudy yellow urine. The testes, prostate gland and seminal vesicles are without note.

LYMPHORETICULAR SYSTEM:
The thymus is small, fatty and otherwise unremarkable. The 280-gram spleen has a smooth, intact capsule covering red-purple, moderately firm parenchyma; the lymphoid follicles are unremarkable.

Lymph nodes in the hilar, periaortic and iliac regions are not enlarged.

ACLU Detainee DeathII ARMY MEDCOM 1125

ENDOCRINE SYSTEM:
The pituitary gland is examined *in situ* and is grossly unremarkable. The thyroid gland is symmetric and red-brown, without cystic or nodular change. The parathyroid glands are not identified. The right and left adrenal glands are symmetric, with bright yellow cortices and red-brown medullae; no masses or areas of hemorrhage are identified.

MUSCULOSKELETAL SYSTEM:
Superficial posterior skin incisions are negative for traumatic injuries. Superficial incisions of each ankle and wrist region show no evidence of trauma or binding. No non-traumatic abnormalities of muscle or bone are identified.

SLIDE KEY AND MICROSCOPIC EXAMINATION

1. Kidney – Unremarkable glomeruli with post mortem autolysis of the tubules.
   Liver – Normal hepatic architecture with congestion and mild chronic peri-portal inflammation.
   Spleen – Congestion with autolysis and no focal lesions.

2. Lung (all five lobes) – Pulmonary congestion with extravasated red blood cells in the alveolar spaces and pulmonary edema.

TOXICOLOGY

The blood and vitreous fluid are examined for the presence of volatile compounds including ethanol at a cutoff of 20-milligrams per deciliter. No ethanol is detected.

The blood is screened for medications and drugs of abuse including acetaminophen, amphetamine, antidepressants, antihistamines, barbiturates, benzodiazepines, cannabinoids, chloroquine, mefloquine, cocaine, dextromethorphan, lidocaine, narcotic analgesics, opiates, phencyclidine, phenothiazines, salicylates, sympathomimetic amines and verapamil by gas chromatography, color test or immunoassay. The following drugs were detected:

- Positive Lidocaine: Lidocaine was detected in the blood by gas chromatography and confirmed by gas chromatography/mass spectrometry.

The carboxyhemoglobin saturation in the blood was less than 1% as determined by spectrophotometry with a limit of quanitation of 1%.

There was no cyanide detected in the blood. The limit of quanitation for cyanide is 0.25-milligrams per liter.

ADDITIONAL PROCEDURES

1. Documentary photographs are taken by (b)(6) OAFME staff photographer.
2. Personal effects are released to the appropriate mortuary operations representatives.
3. Specimens retained for toxicology testing and/or DNA identification are: vitreous fluid, blood, bile, gastric contents, heart, spleen, liver, lung, kidney, myocardium, adipose tissue and skeletal muscle.

ACLU Detainee DeathII ARMY MEDCOM 1126

4. The dissected organs are forwarded with body except for the heart and brain.
5. The heart is sent for Cardiovascular Pathology consultation.
6. The brain is sent for Neuropathology consultation.

FINAL AUTOPSY DIAGNOSES

I. Cardiovascular System (see Addendum B)
- A. Lymphocytic Myocarditis
- B. Right ventricular dilatation, mild

II. Natural diseases or pre-existing conditions identified:
- A. Pulmonary congestion, edema, and adhesions
- B. Hepatosplenomegaly
- C. Cerebral edema

III. Evidence of Medical Therapy:
- A. EKG patch on left lower quadrant of the abdomen
- B. Multiple therapeutic needle sticks
- C. Interosseous catheter in the right anterior leg
- D. Burn abrasions on the chest from the defibrillator pads

IV. Post-Mortem Changes:
- A. Rigor is absent in all extremities
- B. Lividity is posterior and fixed except in areas exposed to pressure
- C. There is marbling of the torso and both lower extremities
- D. The body temperature is cold to touch

V. Identifying Body Marks:
- A. Tattoo (b)(6)

VI. There is no evidence of trauma or physical abuse.

VII. Toxicology:
- A. No ethanol was detected in the blood and vitreous fluid
- B. Lidocaine is detected in the blood
- C. No carbon monoxide was detected in the blood
- D. No cyanide was detected in the blood

ACLU Detainee DeathII ARMY MEDCOM 1127

OPINION

This 21-year-old, BTB (b)(6) died of lymphocytic myocarditis. Per investigation (b)(6) was found by other detainees complaining of shortness of breath and clutching his chest. While the other detainees were bringing him to the guard he lost consciousness. Medical personnel were dispatched and took (b)(6) to the medical facility where resuscitative efforts were unsuccessful. At autopsy, he had extensive adhesions around both his lungs as well as on the right upper lobe of the liver. His heart showed mild right ventricular dilatation with histological evidence of lymphocytic myocarditis. There is no evidence of trauma or foul play. A review of the limited medical records available was non-contributory. The toxicological screen for ethanol, carbon monoxide, cyanide, and illicit drugs of abuse are negative. The toxicological screen for medications was positive for lidocaine which if more than likely from resuscitative efforts.

Myocarditis is defined as inflammatory changes in the heart muscle and is characterized by myocyte (individual heart muscle cells) necrosis (death). The causes of myocarditis are numerous and can be roughly divided into infectious, toxic, and immunologic etiologies, with viral etiologies most common. Coxsackievirus B is the most common viral cause of myocarditis but other viruses implicated in causing myocarditis include influenza virus, echovirus, herpes simplex virus, hepatitis, Epstein-Barr virus, and cytomegalovirus. Nonviral infectious causes include diphtheria, Chagas disease, Streptococcal species, Staphylococcal species, Bartonella, Brucella, Leptospira, and Salmonella species. Toxic myocarditis can be caused by medications such as penicillin, doxorubicin, zidovudine (AZT) or environmental toxins such as lead, arsenic, and insect stings (scorpion or spiders). Immunologic etiologies of myocarditis encompass a number of clinical syndromes and include systemic lupus erthematosus, rheumatoid arthritis, scleroderma, Kawasaki disease, sarcoidosis, and giant cell arteritis.[1234] The decedent has no history of toxic exposure and there is no evidence of bacterial or systemic disease. The histological finding in this case of a lymphocytic infiltrate within the heart muscle is suggestive of a viral cause of his myocarditis.

The manner of death is Natural.

(b)(6)

(b)(6) Medical Examiner

(b)(6)

(b)(6) Medical Examiner (b)(6)

[1]Baboonian C, Davies MJ, Booth JC, McKenna W: Coxsackie B viruses and human heart disease. *Curr Top Microbiol Immunol* 1997; 223:31-52.
[2]Feldman AM, McNamara D: Myocarditis. *N Engl J Med* 2000; 343:1388-1398.
[3]Weinstein C, Fenoglio JJ: Myocarditis. *Hum Pathol* 1987; 18:613-618.
[4]Maron BJ: Medical progress: Sudden death in young athletes. *N Engl J Med* 2003; 349:1064-1075.

ACLU Detainee DeathII ARMY MEDCOM 1128

ADDENDUM A: Neuropathology Consultation Report

ARMED FORCES INSTITUTE OF PATHOLOGY
NEUROPATHOLOGY REPORT
CASE NUMBER: (b)(6)
PATIENT NAME (b)(6)
DATE OF EXAMINATION: 02/19/09

GROSS DESCRIPTION:

Brain weight: 1436 gm

The specimen consists of the brain of an adult.

The brain is diffusely swollen with widened gyri, narrowed sulci, effaced basilar cisterns, swollen cerebellar tonsils and an effaced cerebellomedullary cistern. Moderately deep tentorial grooves indent each uncus approximately 0.6 cm from the medial margins. There is no associated visible uncal cortical or cerebellar tonsil cortical injury.

The leptomeninges are thin, delicate and transparent. Except as noted, the cerebral gyri have normal configuration and consistency.

There is no sign of midline shift. Except as noted, the external aspects of the brainstem and cerebellum are not remarkable. The arteries at the base of the brain follow a normal distribution and are free of atherosclerosis. There are no aneurysmal dilatations or sites of occlusion. The identifiable cranial nerve roots are not remarkable.

Coronal sections of the cerebrum reveal dissolution of the septum pellucidum due to edema and early autolysis. The demarcation between cerebral gray and white matter is blurred due to swelling and edema. There are no focal lesions in the cortex, white matter or deep nuclear structures. There is no midline shift. Sections of the midbrain, pons, medulla and cerebellum show no focal abnormalities. The substantia nigra and locus coeruleus are well pigmented.

The ventricular system and aqueduct of Sylvius are patent. The third ventricle is compressed due to brain swelling. The ventricular system is otherwise unremarkable with an anatomically normal configuration. The choroid plexus is unremarkable and the ependymal surfaces are smooth and glistening.

ACLU Detainee DeathII ARMY MEDCOM 1129

PHOTOGRAPHS: Yes

MICROSCOPIC EXAMINATION:

Blocks of tissue for microscopic examination are removed from: (1) right frontal lobe, (2) anterior corpus callosum/cingulate gyri/septum pellucidum, (3) right mid frontal lobe, (4) left uncus, (5) left insula/claustrum/putamen/globus pallidus/anterior limb of internal capsule, (6) left thalamus/substantia nigra/red nucleus/posterior limb of internal capsule, (7) right hippocampus/lateral geniculate nucleus/temporal horn of lateral ventricle/ choroid plexus, (8) mid corpus callosum/cingulate gyri/caudate nucleus/internal capsule, (9) right calcarine cortex/occipital horn of lateral ventricle, (10) cerebellum, (11) midbrain, (12) pons and (13) medulla.

Sections from each block are stained with H&E and LFB/Bodian techniques and immunostained for β–amyloid precursor protein (β-APP).

COMMENT:

Microscopic sections show diffuse edema and widespread eosinophilic neurons (acute ischemic neuronal injury) in the frontal, cingulate gyral, hippocampal (subiculum), occipital, and basal ganglia gray matter.

There is no evidence of inflammation or trauma.

(b)(6)

NEUROPATHOLOGIST

ACLU Detainee DeathII ARMY MEDCOM 1130

ADDENDUM B: Cardiovascular Pathology Consultation Report

DEPARTMENT OF DEFENSE
ARMED FORCES INSTITUTE OF PATHOLOGY
WASHINGTON, DC 20306-6000

AFIP Interdepartmental Consultation Report

AFIP ACCESSION NO.	SEQUENCE NO.
(b)(6)	
(b)(6)	SSN: (b)(6)
(b)(6)	

February 17, 2009

(b)(6)
AFIP (b)(6)
1413 Research Blvd.
Bldg. 102
Rockville, MD 20850

DIAGNOSIS: (b)(6) **Heart, autopsy:**
-Lymphocytic myocarditis
-Mild right ventricular dilatation

History: 21 year old Iraqi male; height 185 cm, weight 80 kg; awoke with shortness of breath, collapsed, and could not be resuscitated; autopsy showed pleural adhesions

Heart: 460 g (per contributor) (predicted normal value 341 g, upper limit 481 g for 184 cm male); closed foramen ovale; mild right ventricular dilatation: left ventricular cavity diameter 27 mm, left ventricular free wall thickness 13 mm, anterior ventricular septum thickness 12 mm, posterior ventricular septum thickness 17 mm, right ventricular cavity diameter from acute angle to septum 43 mm, posterior right ventricle thickness 4 mm; valves grossly unremarkable; aortic root diameter 17 mm, pulmonary trunk diameter 15 mm; focal anterior and lateral left ventricular white discoloration; histologic sections demonstrate lymphocytic infiltrates primarily involving the subepicardial region of the left ventricle with patchy infiltrates in the subendocardial and mid myocardial regions and in the right ventricle with associated myocyte necrosis and healing areas with granulation tissue and fibrosis

Coronary arteries: Normal ostia; right dominance; no gross atherosclerosis

ACLU Detainee DeathII ARMY MEDCOM 1131

AFIP ACCESSION NO. SEQUENCE NO.
(b)(6)
(b)(6) **SSN:**
(b)(6)
February 17, 2009

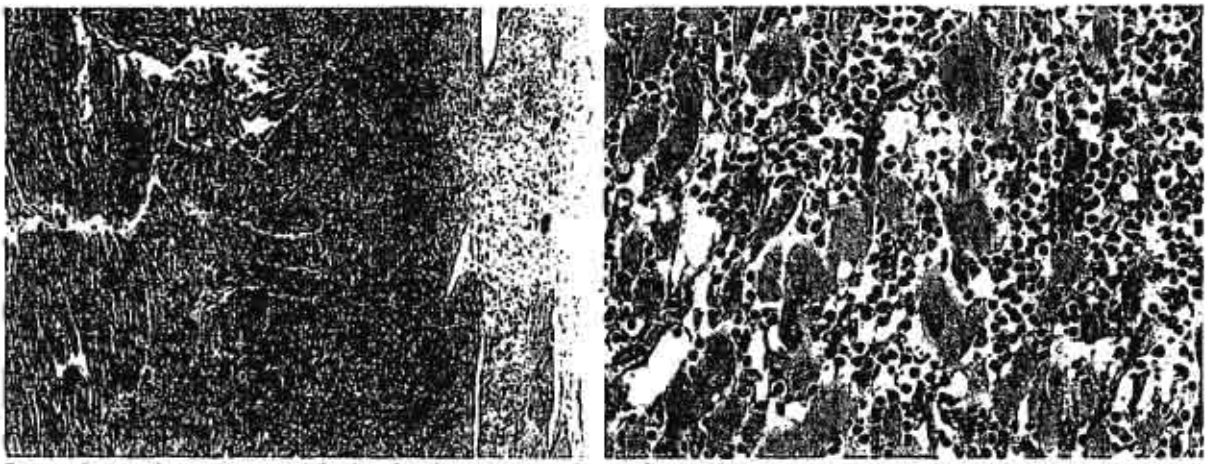

Lymphocytic myocarditis in the left ventricle (left) with myocyte necrosis (right)

A copy of this report has been faxed to you at (b)(6)

(b)(6)

Department of Cardiovascular Pathology

ACLU Detainee DeathII ARMY MEDCOM 1132